



Title	Chopart amputation with tendon balancing
Author(s)	Ouchi, Kazuo; Oi, Naoyuki; Sato, Mari; Yabuki, Shoji; Konno, Shin-Ichi
Citation	Fukushima Journal of Medical Science. 69(1): 67-71
Issue Date	2023
URL	http://ir.fmu.ac.jp/dspace/handle/123456789/1952
Rights	© 2023 The Fukushima Society of Medical Science. This article is licensed under a Creative Commons [Attribution-NonCommercial-ShareAlike 4.0 International] license.
DOI	10.5387/fms.2022-40
Text Version	publisher

This document is downloaded at: 2023-05-15T03:21:53Z



Chopart amputation with tendon balancing

Kazuo Ouchi¹⁾, Naoyuki Oi¹⁾, Mari Sato¹⁾, Shoji Yabuki²⁾ and Shin-ichi Konno³⁾

¹⁾Department of Rehabilitation Medicine, School of Medicine, Fukushima Medical University, Fukushima, Japan, ²⁾School of Health Sciences, Fukushima Medical University, Fukushima, Japan, ³⁾Department of Orthopaedic Surgery, School of Medicine, Fukushima Medical University, Fukushima, Japan

(Received November 18, 2022, accepted February 28, 2023)

Abstract

Background : When foot necrosis occurs due to lower limb blood flow disorder caused by diabetes or peripheral arterial occlusion, many patients require lower limb amputation. The functional prognosis after lower limb amputation largely depends on whether the heel can be preserved. However, there are many reports that Chopart amputation causes varus and equinus deformity, and is functionally unfavorable. We herein report a case of Chopart amputation performed with muscle balancing. Postoperatively, the foot was not deformed and the patient was able to walk independently with a foot prosthesis. **Case :** A 78-year-old man presented with ischemic necrosis of his right forefoot. The range of necrosis extended to the central part of the sole, so Chopart amputation was performed. In the operation, to prevent varus and equinus deformity, the Achilles tendon was lengthened, the tibialis anterior tendon was transferred through a tunnel created in the neck of talus, and the peroneus brevis tendon was transferred through a tunnel created in the anterior part of the calcaneus. At the final follow-up 7 years after the operation, no varus or equinus deformity was observed. The patient became able to stand up and walk on his heel without a prosthesis. In addition, step motion was possible by wearing a foot prosthesis.

Key words : Chopart amputation, tendon balancing, foot prosthesis

Introduction

For blood flow disorders caused by diabetes or peripheral arterial occlusive disease, revascularization therapy is used to salvage the affected limb; however, many patients require lower limb amputation when foot necrosis occurs. Lower limb amputation can involve removal of the toes, foot, lower leg, and/or thigh, and the functional prognosis varies greatly depending on whether the heel can be preserved. This is because if the heel can be preserved, the patient can bear weight on the affected limb without a prosthesis but in cases where the lower leg or thigh is amputated, the patient cannot bear weight on the affected limb without wearing an artificial leg. Especially in the elderly, even if a prosthetic leg is made, there are many cases where

practical walking with the prosthetic leg is not possible due to weakened muscles and physical strength. There are many reports that amputation distal to the Lisfranc joint causes no functional problems, but Chopart amputation can cause postoperative varus and equinus deformity due to muscle imbalance^{1,2)}, resulting in poor functional performance. In Chopart amputation, the tibialis anterior tendon, which is the dorsiflexor muscle, is cut, so the strength of the dorsiflexor is lost, and the strength of the plantar flexor muscles is relatively increased^{3,4)}. As a result, equinus deformity occurs, at which point plantar contact becomes impossible, and calluses and ulcers form at the amputation stump, resulting in a marked decrease in walking ability. Okawa *et al.* reported that, among 31 cases of Chopart amputation, a total of 22 cases (71%) had

Corresponding author : Kazuo Ouchi, MD E-mail : ouchik@fmu.ac.jp

©2023 The Fukushima Society of Medical Science. This article is licensed under a Creative Commons [Attribution-NonCommercial-ShareAlike 4.0 International] license.
<https://creativecommons.org/licenses/by-nc-sa/4.0/>

equinus deformity, including 14 with varus and equinus deformity, and eight with equinus deformity alone⁵). We herein report a case in which Chopart amputation was performed with balanced muscle strength, the foot did not progress to deformity, and the patient was able to walk independently with a foot prosthesis.

Case

A 78-year-old man underwent vascular graft replacement for an abdominal aortic aneurysm. Immediately after the operation, his right foot turned blue, the dorsalis pedis artery was not palpable, and thromboembolism occurred in the right lower limb. In addition, thrombus occlusion from the popliteal artery to the 3-artery bifurcation was observed at the site below the right knee. Thrombectomy with a catheter was immediately performed and a 3-cm thrombus was removed. Alprostadil was used as an anticoagulant. Ischemic necrosis occurred in the right forefoot, which turned black, and the range of necrosis extended to the central part of the sole three months after operation

(Fig. 1-A, B, C). It would have been difficult to cover the amputated end with well vascularized soft tissue if we had performed Lisfranc amputation, so lower leg amputation was planned. However, walking with a prosthetic leg was predicted to be difficult due to weakened muscles after a prolonged bedridden state. We considered surgical methods that preserve the heel so that the patient could bear weight without a prosthesis, so Chopart amputation was performed. In the operation, a fish mouth incision was made in the margin of the normal tissue to expose and amputate the Chopart joint. To prevent varus and equinus deformity, we reconstructed the cut tibialis anterior tendon, which is a dorsiflexor muscle, and weakened the plantar flexor muscle strength. The Achilles tendon was lengthened with a Z-plasty. In order to balance the plantar dorsiflexor tendon, the lengthened Achilles tendon was sutured at an ankle plantar dorsiflexion position of 0 degrees, resulting in an extension of 2 cm. Then the tibialis anterior tendon was transferred through a tunnel created in the neck of talus, and the peroneus brevis tendon was transferred through a tunnel created in the anterior part of the calcaneus. Next,

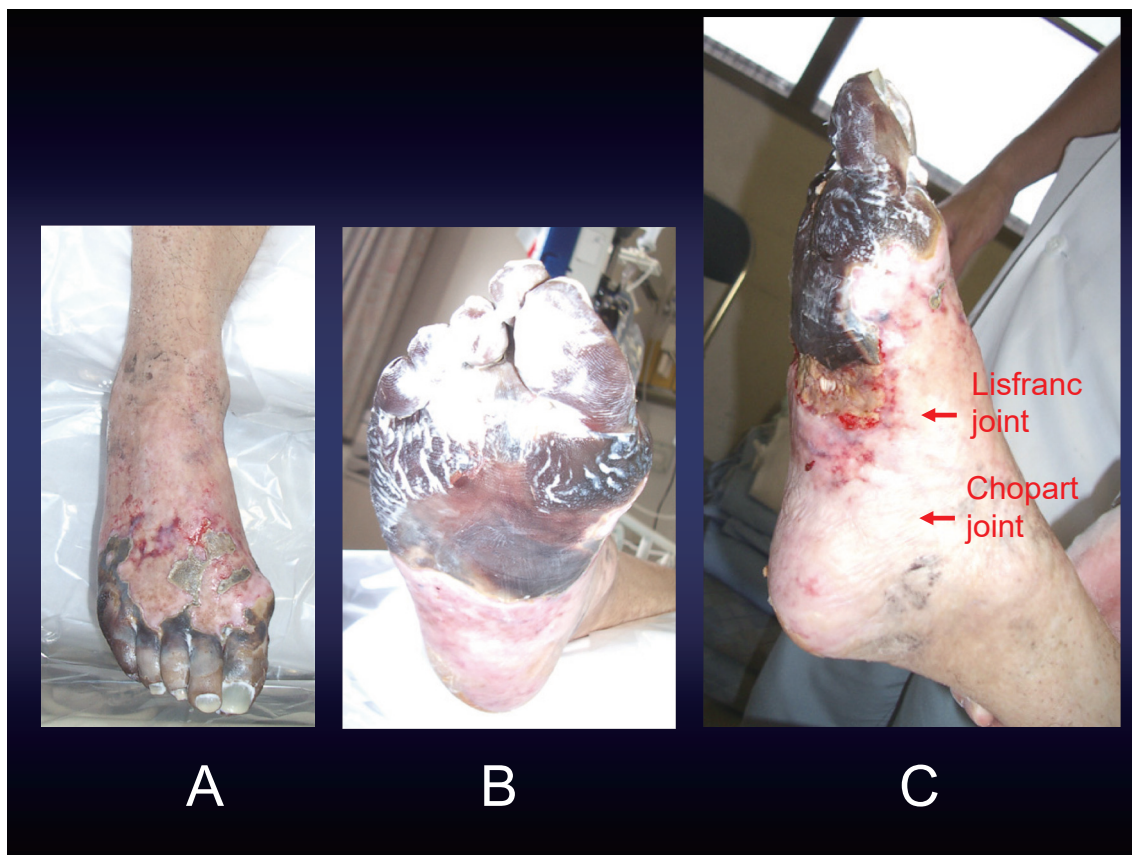


Fig. 1. Appearance of a necrotic foot. 1-A, front ; 1-B, plantar ; 1-C, lateral. Necrosis was observed in the right forefoot, and the range of necrosis extended to the center of the sole.

after extending the Achilles tendon to 0-degree plantar dorsiflexion of the ankle and suturing it, the tibialis anterior tendon, which had moved to the talus, was tensioned at 5 degrees dorsiflexion of the ankle, and fixed to the talus with staples. Similarly, the tendon of the peroneus brevis, which had been moved to the calcaneus, was tensioned at 5 degrees dorsiflexion of the ankle, and fixed to the calcaneus with staples. Postoperative radiographs showed good fixation of the staples and no varus or equinus deformity (Fig. 2-A, B).

Four weeks after the operation, the wound at the amputation end was closed, and no complications, such as infection or re-necrosis, occurred. At the final follow-up 7 years after the operation, no varus or equinus deformity was observed. Active dorsiflexion and plantarflexion of the ankle was possible, and the range of motion was 5 degrees of dorsiflexion and 10 degrees of plantarflexion (Fig. 3-A, B, C). The patient became able to stand up and walk on his heel without a prosthesis. Six weeks after the operation, a foot prosthesis was made to enable the stepping motion of the foot (Fig. 4-A, B). The patient found it easy to put the foot prosthesis on by himself. Five years postoperatively, he was able to walk for approximately 1 km, as well as get on and off busses independently.

Discussion

Elderly patients with diabetes or peripheral vascular disease, who have necrotic limbs that require amputation, often have significant muscle weakness. There are cases in which it is difficult to achieve practical walking, because the patient's muscles are not strong enough to use a prosthetic leg, even if a lower-leg or thigh prosthesis is attached after lower leg amputation or thigh amputation. If the foot can be amputated so that the heel can be preserved, heel-loaded walking without a prosthetic leg would be possible and functionally good. However, if the area of necrosis is large and the heel cannot be preserved, there is no choice but to amputate the lower leg. An advantage of Chopart amputation is that the heel can be retained untouched, resulting in no change in leg length^{6,7}, so the patient can bear weight even without using a prosthetic leg⁸⁻¹⁰. A disadvantage of the Chopart amputation is that all dorsiflexor strength is lost, resulting in relatively strong plantar flexor strength and development of equinus deformity. To overcome this shortcoming, in the present case we performed Chopart amputation with transfer of the tibialis anterior tendon and lengthening of the Achilles tendon, so the patient was able to bear weight without developing equinus deformity.

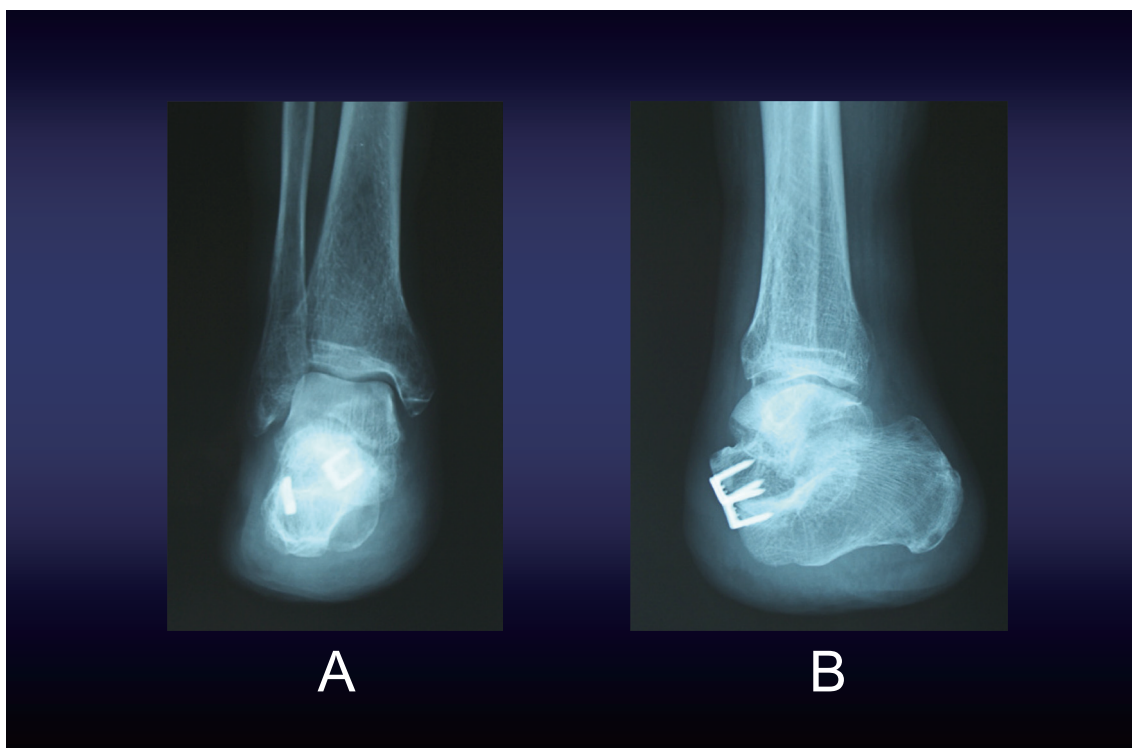


Fig. 2. Postoperative radiograph. 2-A, anteroposterior view ; 2-B, lateral view. Varus and equinus deformity was not observed.

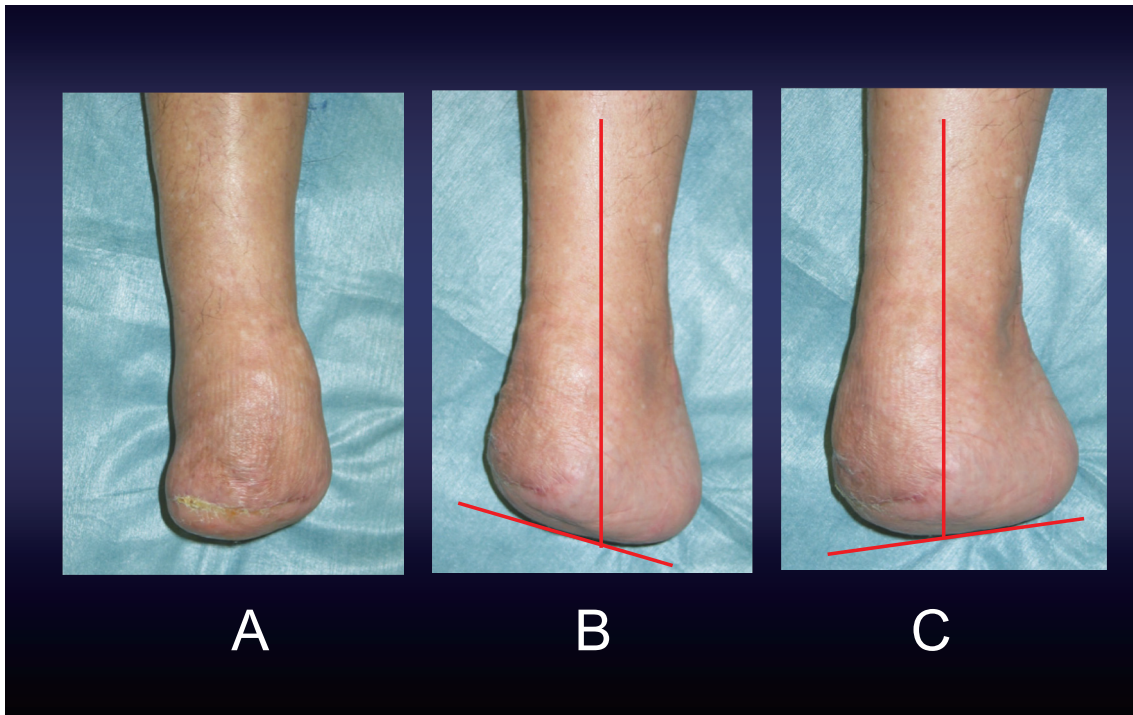


Fig. 3. Appearance of the right foot 2 years after surgery. 3-A, frontal view ; 3-B, lateral dorsiflexion image ; 3-C, lateral plantarflexion image. The range of motion of the right ankle joint was 5 degrees of dorsiflexion and 10 degrees of plantar flexion.

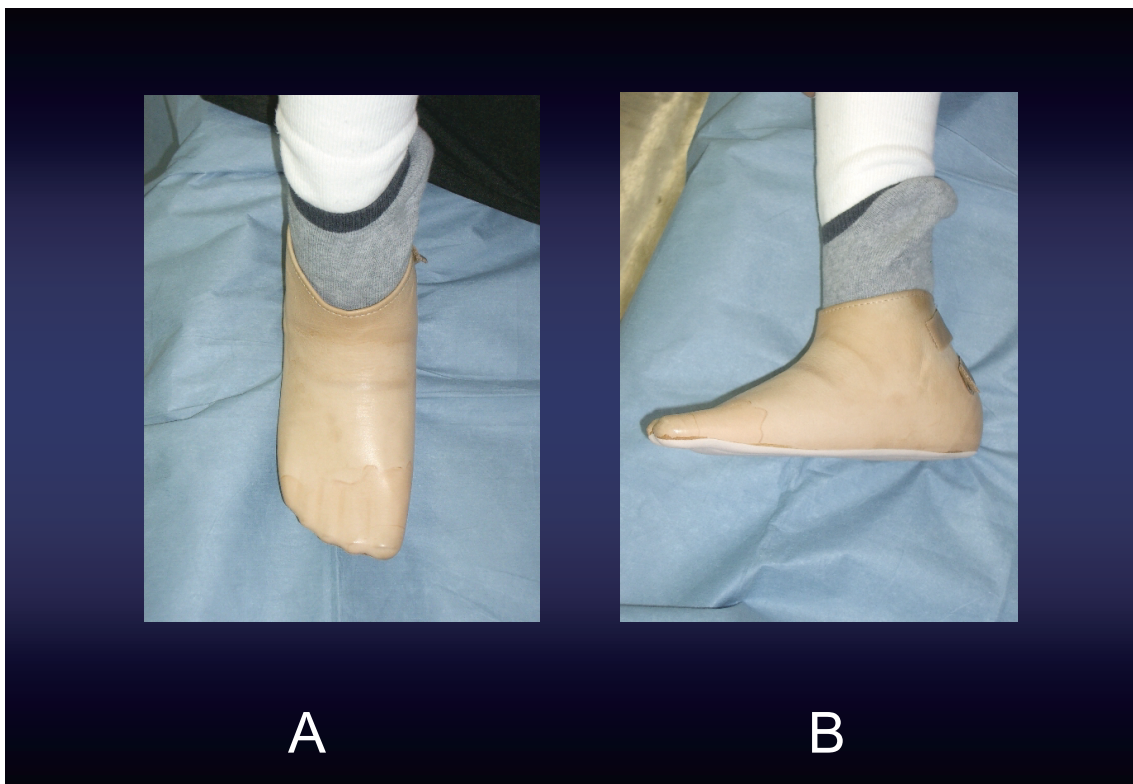


Fig. 4. A foot prosthesis attached to the right foot. 4-A, front view ; 4-B, side view.

In diabetic necrosis, the extent of necrosis is often unclear, and re-necrosis may occur at the amputation edge¹¹⁻¹³. In the present case, necrosis was caused by thromboembolism after cardiac surgery, and because the boundary between the necrotic tissue and normal tissue was clear, we were able to resect the normal tissue while preserving as much of it as possible.

Patients with Chopart amputation usually require the use of an ankle-foot orthosis or boot prosthesis because the remaining tarsal bone is short^{14,15}. However, if there is no varus and equinus deformity, and the foot has sufficient stability and support under load, sufficient walking ability can be obtained with a foot prosthesis. In the present case, sufficient muscle strength was preserved at the amputation stump, so the patient was able to walk using a foot prosthesis instead of an ankle-foot orthosis.

Conclusion

We reported a case in which Chopart amputation combined with tendon transfer and lengthening was performed. As a result, the patient was able to walk independently using a foot prosthesis without varus and equinus deformity of the foot.

Disclosure statement

The authors have nothing to disclose.

References

1. Reyzelman AM, Hadi S, Armstrong DG. Limb salvage with Chopart's amputation and tendon balancing. *J Am Podiatr Med Assoc*, **89** : 100-103, 1999.
2. Green CJ, Bibbo C, McArdle A, Knight C. A Functional Chopart's Amputation With Tendon Transfers. *J Foot Ankle Surg*, **60**(1) : 213-217, 2021.
3. Letts M, Pyper A. The modified Chopart's amputation. *Clin Orthop Relat Res*, **256** : 44-49, 1990.
4. Lieberman JR, Jacobs RL, Goldstock L, Durham J, Fuchs MD. Chopart amputation with percutaneous heel cord lengthening. *Clin Orthop Relat Res*, **296** : 86-91, 1993.
5. Okawa T, Ando N, Tsuchiya K, Sokubu Setsudan oyobi Gisoku. Saigaiigaku [in Japanese], **14** : 329-337, 1971. J
6. Yoho RM, Wilson PK, Gerres JA, Freschi S. Chopart's amputation : a 10-year case study. *J Foot Ankle Surg*, **47** : 326-331, 2008.
7. Blanco JS, Herring JA. Congenital Chopart amputation. A functional assessment. *Clin Orthop Relat Res*, **256** : 14-21, 1990.
8. DeGere MW, Grady JF. A modification of Chopart's amputation with ankle and subtalar arthrodesis by using an intramedullary nail. *J Foot Ankle Surg*, **44**(4) : 281-286, 2005.
9. Krause FG, Pfander G, Henning J, Shafiqi M, Weber M. Ankle dorsiflexion arthrodesis to salvage Chopart's amputation with anterior skin insufficiency. *Foot Ankle Int*, **34**(11) : 1560-1568, 2013.
10. Godoy-Santos AL, Fonseca FC, de Cesar-Netto C, Bang K, Pires EA, Armstrong DG. Staged salvage of diabetic foot with Chopart amputation and intramedullary nailing. *SAGE Open Med Case Rep*, **9** : 2050313X211046732, 2021.
11. Brodell JD Jr, Ayers BC, Baumhauer JF, DiGiovanni BF, Flemister AS, Ketz JP, Oh I. Chopart Amputation : Questioning the Clinical Efficacy of a Long-standing Surgical Option for Diabetic Foot Infection. *J Am Acad Orthop Surg*, **28**(16) : 684-691, 2020.
12. Schade VL, Roukis TS, Yan JL. Factors associated with successful Chopart amputation in patients with diabetes : a systematic review. *Foot Ankle Spec*, **3**(5) : 278-284, 2010.
13. Faglia E, Clerici G, Frykberg R, *et al*. Outcomes of Chopart Amputation in a Tertiary Referral Diabetic Foot Clinic : Data From a Consecutive Series of 83 Hospitalized Patients. *J Foot Ankle Surg*, **55**(2) : 230-234, 2016.
14. Cohen-Sobel E, Caselli MA, Rizzuto J. Prosthetic management of a Chopart amputation variant. *J Am Podiatr Med Assoc*, **84**(10) : 505-510, 1994.
15. Heim M. A new orthotic device for Chopart amputees. *Orthop Rev*, **23**(3) : 249-252, 1994.