


Journal Pre-proof



Clinical phenotype of adolescent and adult patients with extracranial vascular malformation

A. Tuleja, S. Bernhard, G. Hamvas, T.A. Andreotti, J. Rössler, L.M. Boon, M. Vikkula, R. Kammer, F. Haupt, Y. Döring, I. Baumgartner

PII: S2213-333X(23)00140-3

DOI: <https://doi.org/10.1016/j.jvsv.2023.03.012>

Reference: JVSV 1590

To appear in: *Journal of Vascular Surgery: Venous and Lymphatic Disorders*

Received Date: 14 October 2022

Revised Date: 8 March 2023

Accepted Date: 8 March 2023

Please cite this article as: A. Tuleja, S. Bernhard, G. Hamvas, T.A. Andreotti, J. Rössler, L.M. Boon, M. Vikkula, R. Kammer, F. Haupt, Y. Döring, I. Baumgartner, Clinical phenotype of adolescent and adult patients with extracranial vascular malformation, *Journal of Vascular Surgery: Venous and Lymphatic Disorders* (2023), doi: <https://doi.org/10.1016/j.jvsv.2023.03.012>.

This is a PDF file of an article that has undergone enhancements after acceptance, such as the addition of a cover page and metadata, and formatting for readability, but it is not yet the definitive version of record. This version will undergo additional copyediting, typesetting and review before it is published in its final form, but we are providing this version to give early visibility of the article. Please note that, during the production process, errors may be discovered which could affect the content, and all legal disclaimers that apply to the journal pertain.

Copyright © 2023 Published by Elsevier Inc. on behalf of the Society for Vascular Surgery.

1 **Clinical phenotype of adolescent and adult patients with extracranial vascular**
2 **malformation**

3

4 A. Tuleja ^{*1), 4)}; S. Bernhard ^{*1)}; G. Hamvas¹⁾; T.A. Andreotti^{3), 4)}; J. Rössler³⁾; L. M. Boon⁶⁾; M.
5 Vikkula^{6), 7)}; R. Kammer¹⁾; F. Haupt⁵⁾; Y. Döring^{1), 2), 8), 9)}; I. Baumgartner¹⁾

6 * These two authors contributed equally to this work.

7

8 ¹⁾ Division of Angiology, Swiss Cardiovascular Center, Inselspital, Bern University, Hospital,
9 Bern, Switzerland

10 ²⁾ Department for BioMedical Research (DBMR), University of Bern, Bern, Switzerland

11 ³⁾ Division of Pediatric Hematology and Oncology, Department of Pediatrics, Inselspital -
12 University Hospital of Bern, University of Bern, Bern, Switzerland

13 ⁴⁾ Graduate School for Health Sciences, University of Bern, Bern, Switzerland

14 ⁵⁾ Department of Radiology, Inselspital, Bern University, Hospital, Bern, Switzerland

15 ⁶⁾ Center for Vascular Anomalies, Division of Plastic Surgery, VASCERN VASCA European
16 Reference Centre, Saint Luc University Hospital, Avenue Hippocrate 10, 1200, Brussels,
17 Belgium.

18 ⁷⁾ Human Molecular Genetics, de Duve Institute, University of Louvain, Avenue Hippocrate 74,
19 1200, Brussels, Belgium.

20 ⁸⁾ Institute for Cardiovascular Prevention (IPEK), Ludwig-Maximilians-University Munich
21 (LMU), 80336 Munich, Germany

22 ⁹⁾ DZHK (German Centre for Cardiovascular Research), Partner Site Munich Heart Alliance,
23 80336 Munich, Germany

1

2 **Corresponding author:**

3 Aleksandra Tuleja, MD

4 Division for Angiology, Swiss Cardiovascular Centre, University Hospital Bern

5 3010 Bern, Switzerland

6 Phone: +41 31 664 18 10

7 Fax: +41 31 632 0428

8 Email: aleksandra.tuleja@insel.ch

9

10

11

12

13

14

15

16

17

18

19

20

1 **Key words: vascular malformation, phenotype, overgrowth**

2 **ARTICLE HIGHLIGHTS**

3 **Type of Research: Single-center cross-sectional study**

4

5 **Key Findings:** Adolescent and adult patients with extracranial vascular malformations were on
6 average 35 years old and had predominantly simple venous malformations (n=238, 52 %). Pain
7 was the most commonly reported symptom in all patients, although it was more pronounced in
8 those with simple venous and arteriovenous malformations.

9

10 **Take home Message:** In addition to vascular changes, simple vascular malformations are
11 accompanied by growth abnormalities of soft and solid tissues, which should be taken into
12 account in the classification.

13

14

15 **Table of Contents Summary**

16 In this single center, cross- sectional study, we characterize the adolescent and adult population
17 with extracranial vascular malformation (n= 457) according to the updated ISSVA classification.

18

1 **Abstract**

2 Background: In recent years, genotypic characterization of congenital vascular malformations
3 (CVM) has gained attention; however, the spectrum of clinical phenotype remains difficult to
4 attribute to a genetic cause and is rarely described in the adult population.

5 Aim: The aim of this study is to describe a consecutive series of adolescent and adult patients in a
6 tertiary center, where a multimodal phenotypic approach was used for diagnosis.

7 Methods: We analyzed clinical findings, imaging, and laboratory results at initial presentation,
8 and set a diagnosis according to the International Society for the Study of Vascular Anomalies
9 (ISSVA) classification for all consecutively registered patients older than 14 years of age who
10 were referred to the Center for Vascular Malformations at the University Hospital of Bern
11 between 2008 and 2021.

12 Results: 457 patients were included for analysis (mean age 35 years; females 56%). Simple
13 CVMs were the most common (n=361, 79 %), followed by CVM associated with other anomalies
14 (n=70, 15%), and combined CVM (n=26, 6%). Venous malformations (n=238) were the most
15 common CVM overall (52%), and the most common simple CVM (66%). Pain was the most
16 frequently reported symptom in all patients (simple, combined and vascular malformation with
17 other anomalies). Pain intensity was more pronounced in simple venous and arteriovenous
18 malformation. Clinical problems were related to the type of CVM diagnosed, with bleeding and
19 skin ulceration in arteriovenous malformations, localized intravascular coagulopathy in venous
20 malformations and infectious complications in lymphatic malformations. Limb length difference
21 occurred more often in patients with CVM associated with other anomalies as compared to
22 simple or combined CVM (22.9 vs 2.3%, $p < 0.001$). Soft tissue overgrowth was seen in one
23 quarter of all patients independent of the ISSVA group.

1 Conclusions: In our adult and adolescent population with peripheral vascular malformations,
2 simple venous malformations predominated, with pain as the most common clinical symptom. In
3 a quarter of cases, patients with vascular malformations presented with associated anomalies on
4 tissue growth. The differentiation of clinical presentation with or without accompanying growth
5 abnormalities need to be added to the ISSVA classification. Phenotypic characterization
6 considering vascular and non-vascular features remains the cornerstone of diagnosis in adult-as
7 well as pediatric patients.

8

9 **Introduction**

10 Over the past two decades ^{1,2} multiple somatic and germline mutations, known from oncogenic
11 pathways (*PIK3/AKT/mTOR* ^{3,4,5} and *RAS/MAPK/ERK* ^{6,7,8}), were identified to underlie
12 congenital vascular malformations (CVM) and started to pave the way for an emerging number
13 of targeted therapies repurposed from other indications.^{9,10} However, the rapid increase in
14 genetic knowledge should be accompanied by advanced clinical investigation and accurate
15 classification in order to be meaningful. Classification systems have transformed over the years,
16 from the first publication of Mulliken and Glovicki in 1982 ¹¹ followed by the Hamburg
17 classification ^{12,13} to the International Society for the Study of Vascular Anomalies (ISSVA)
18 classification, established in 1996 and updated in 2018.¹⁴ The advantages of the ISSVA
19 classification are the uniform semantics, comparability of data, and constant development in face
20 of new genetic findings, which ultimately resulted in the differentiation of seemingly identical
21 phenotypes into subtypes with specific genetic background. Careful, multimodal processing of
22 patient data in the interaction of different specialties is needed to clarify complex structural

1 differences within well-defined classes of CVMs and might help to explain some of the apparent
2 inconsistencies between phenotype and genotype.¹⁵

3 Available literature on clinical presentation is prone to biases due to perspective of the
4 supervising discipline and the referral base of each center. Consequently, single-center studies do
5 not always have a representative distribution of their patient population,^{16, 17} do not show age
6 disaggregated data^{17, 18} or present one region preferably.^{19, 20} Many publications are limited to
7 pediatric population^{21, 22, 23} rather dominated by lymphatic²⁴ and complex malformations
8 associated with other anomalies^{25, 26} or a particular subgroup of CVM with or without genetic
9 assessment.^{17, 20} Furthermore, the classification of patients often lacks clearly described clinical
10 criteria for diagnosis, the classification used or the handling of unclear diagnoses.^{16, 17, 20, 27} As a
11 result, despite the some descriptions of the above-mentioned populations, it becomes almost
12 impossible to compare them.

13
14 The aim of this study is to characterize a consecutive series of adolescent and adult patients with
15 symptomatic CVM outside the central nervous system seen in a tertiary Center for Vascular
16 Malformations in Switzerland classified according to ISSVA using the internationally established
17 phenotype-guided approach for diagnosis.

18

19

20 **Methods**

21 **Study population**

22 This analysis is based on a cross-sectional, single center registry enrolling consecutive patients
23 referred to the “Vascular Malformation Center, Division of Angiology, University Hospital of

1 Bern” between January 2008 and November 2021. Adolescents and adult patients (≥ 14 years) at
2 the time of first presentation with CVM outside of the central nervous system (extra-cranial,
3 extra-spinal) were enrolled. CVM were classified according to the 2018-updated ISSVA
4 classification. The local ethic committee approved the study and all patients signed a general
5 informed consent (IC) for coded data analysis and publication of anonymized data. Patients with
6 questionable diagnosis of CVM, withdrawal of IC, or refusal to undergo the necessary diagnostic
7 procedure were excluded from the analysis.

8

9 **Data collection**

10 Referred patients with identified CVM were registered in a dedicated database (ClinicWinData,
11 E&L Clinical Systems, CWD) of the Division of Angiology since 2008. Each patient’s file
12 comprises standardized information about patient-specific and disease-specific data. Further
13 definitions of data and the description of the data monitoring procedure can be found in the
14 Supplement.

15 **Cross-reading process**

16 The main study investigators (AT, SB, IB) reviewed all patient data collected from 2008 to 2021
17 and diagnosed the patients according to the 2018 updated ISSVA classification. For this purpose,
18 we implemented the internationally recognized phenotype-guided diagnostic guidelines based on
19 the European Reference Network VASCERN for capillary, lymphatic and venous lesions.^{28, 29}
20 We provided an internal flowchart for diagnosis of comprehensive arteriovenous lesions (Figure
21 1). If data were missing to define the diagnosis, patients were contacted and asked either to
22 complete the data (e.g. family history) or to return for consultation. In cases where no consensus
23 could be reached between the study investigators, the diagnosis was determined after in a

1 dedicated multidisciplinary vascular malformation board, involving the SINERGIA research
2 group (project title “VASCSequ”) and VASCERN specialists.

3

4 **Data Analysis**

5 Statistical analysis and data visualization was performed with R-Studio version 4.1.2 (2021-11-
6 01). Categorical data were presented as number and percentage, and continuous data as mean
7 with standard deviation or median with interquartile range (for normal and non-normal
8 distributions, respectively). The level of statistical significance was set at 5% ($p < 0.05$). For
9 multiple comparisons, we adjusted the significance threshold using the Holm-Bonferroni
10 correction.

11 Patients were assigned to ISSVA classification groups (simple; combined; associated with other
12 anomalies) and within the group of simple CVM. Simple CVM were further categorized in
13 subgroups according to vessel type involved (venous (VM), arteriovenous (AVM), capillary
14 (CM), lymphatic (LM)). For the comparison of categorical variables (e.g., signs and symptoms)
15 we used the Fischer's exact test, while differences in continuous variables in age and d-dimer
16 difference tested against the null hypothesis of no difference using ANOVAs. We compared
17 maximal levels of pain, mean levels of pain and minimal levels of pain across CVM groups and
18 across subcategories of simple CVM using Kruskal and Wallis rank sum tests.

19

20 **Results**

21 **Study population**

22 Between 2008 and 2021, 595 patients from a catchment area of approximately 1.5 million people
23 were enrolled in the Bernese Vascular Malformation Registry. Our population consisted mainly

1 of people with Swiss nationality (78%), living in nearby regions (84%), with data on racial
2 affiliation available for only 11% of patients, the majority of whom defined their origin as
3 Caucasian (92%). Figure 2 shows a flowchart of the study population with the 457 patients
4 enrolled for further analysis. Among the included patients, there were 258 women (56.5%) with
5 a mean age of 35.07 years (SD =15.87) at first presentation. Prior to the first presentation, 235
6 patients had undergone treatment for vascular malformations (surgery, laser, sclerotherapy, or
7 targeted therapy). Between 2008 and 2021, 64 patients underwent alcohol embolization, 39
8 underwent surgery (in 19 cases combined with sclerotherapy), and 8 underwent sclerotherapy
9 with other sclerosants. A total of 173 patients were contacted for missing data; 98/173 provided
10 the missing information (telephone consultation, n=32; mailed questionnaire, n=44; follow-up
11 visit, n=22) and were included in the study. Patients with unclear diagnosis or incomplete
12 documentation (n=48) were excluded. The majority of excluded patients (90, 65%) did not meet
13 the age criterion.

14 Out of the 457 patients included, the majority was diagnosed with simple CVM (n=361, 79%)
15 followed by CVM with other anomalies (n=70, 15%) and combined CVM (n=26, 6%) (Figure 2).
16 Venous malformation (VM) was the most common CVM and presented mostly as simple CVM,
17 whereas capillary malformation (CM) was more often associated with other anomalies. The
18 involvement of vessel type within the ISSVA classification is presented in Figure 3.

19 The largest proportion of patients with CVM associated with other anomalies was represented by
20 the Osler–Weber–Rendu syndrome or hereditary hemorrhagic telangiectasia (HHT, n=28, 40%)
21 followed by the Klippel-Trenaunay syndrome (KTS, n=25, 35%) and Parkes-Weber syndrome
22 (PWS, n=7, 10%). Individual patients with rare or borderline syndromes were classified as
23 "other", and included *PTEN* hamartoma-tumor syndrome (PTEN, n=1), Servelle-Martorell

1 syndrome (n=1), CLOVES syndrome (n=2), Proteus syndrome (n=1), Di-Gorgy syndrome with
2 combined capillary-lymphatic malformation of the extremities (n=1), diffuse capillary
3 malformation with bone overgrowth and soft tissue hypotrophy and aplasia of deep venous
4 system (n=1), and PROS other than KTS or CLOVES (n=3) (Figure 2). Additionally, two
5 patients with an extensive, simple AVM were diagnosed with neurofibromatosis type 1
6 (confirmed by a germline *NF1* mutation) and Marfan syndrome (confirmed by a germline *FBNI*
7 mutation as well as a somatic *KRAS* mutation), respectively.

8 Tissue compartments involved and anatomical location are given in Supplemental Figures 1 and
9 2.

10 **Clinical presentation**

11 Pain affected 56% of all adolescent and adult patients and was the most frequent reason to seek
12 medical attention. Levels of maximum, minimum and mean pain had comparable intensity
13 among the main ISSVA groups (simple, combined and with other anomalies). However, maximal
14 pain intensity and mean pain intensity were significantly higher in patients with simple VM and
15 AVM compared to patients with simple LM and CM (Kruskal-Wallis $\chi^2 = 34.48$, $df = 8$,
16 $p=0.00003$ and Kruskal-Wallis $\chi^2 = 15.80$, $df = 8$, $p = 0.045$ for maximal pain and mean pain
17 intensity, Figure 4).

18 Signs and symptoms with regard to vascular and non-vascular involvement according to the
19 ISSVA groups and the subgroups of simple CVM are presented in Table 1a and 1b with
20 corresponding illustration of clinical examples in Figure 5 a-h.

21 Regarding clinical presentation related to vascular involvement among main ISSVA groups
22 (Table 1a), there was a significantly higher proportion of bleeding events and lymphedema

1 among the CVM associated with other anomalies. The level of D-dimers was on average higher
2 among patients with combined and syndromic malformations than in simple CVM. Regarding
3 non-vascular signs and symptoms, there was a significant difference in limb length (bone
4 overgrowth) and skeletal deformation among CVM patients with other anomalies. Soft tissue
5 overgrowth was evenly distributed in simple, combined and CVM associated with other
6 anomalies.

7 In patients with simple CVM (Table 1b), ulcerations predominated in patients with AVM,
8 infectious complications and lymphedema in patients with LM, and thrombophlebitis and LIC in
9 patients with VM. Regarding non-vascular signs and symptoms in these subgroups, limb length
10 difference occurred more frequently in simple CM (two cases of simple CM with undergrowth
11 (CMU) Fig. 5h), and in six patients with simple AVM (Fig. 5e). Soft tissue hypertrophy was
12 equally distributed among subgroups of simple CVM.

13 The occurrence of limb length difference determined further classification of patients with VM
14 and CM. Patients with VM and limb length overgrowth were further classified as incomplete
15 KTS (n=1, Fig. 5b) or with limb length undergrowth as Servelle-Martorell syndrome (n=1, Fig.
16 5c) and were included in the group of CVM associated with other anomalies. Those with no limb
17 length difference were classified as simple VM (n=238). The limb length difference in
18 association with CM resulted in the diagnosis of diffuse CM with overgrowth (DCMO, n=1, Fig.
19 5f) or CM with undergrowth (CMU, n=2, Fig. 5h). Patients with AVM and limb length
20 difference remained in the group of simple CVM (n=6, Fig. 5e); only when AVM was combined
21 with CM and limb length difference were they further classified as syndromic CVM (PWS n=7,
22 Fig. 5d). We did not register any patients with simple LM and limb length difference. Table 2
23 provides a schematic overview of the diagnostic spectrum of vascular malformation with limb

1 length differences and the potential classification gap in patients with AVM and this non-vascular
2 finding.

3 **Discussion**

4 In this cross-sectional study, we characterize the phenotype of a consecutive, series of
5 adolescent and adult patients with symptomatic extracranial/extraspinal CVM. We found a
6 predominance of simple CVM and of simple VM. Simple CVM occurred mainly in the lower
7 extremities with subcutaneous and muscular involvement in the vast majority of patients. The
8 most commonly reported symptom was pain, present in half of the patients, and was particularly
9 associated with VM and AVM. Soft tissue overgrowth was the dominating non-vascular finding
10 in one-fourth of the patients, irrespective of assignment to the ISSVA group. Bleeding events,
11 skeletal deformation, limb length differences were rather indicative of CVM associated with
12 other abnormalities.

13 To the best of our knowledge, this is the first study describing an adolescent-adult patient series
14 with symptomatic CVM. Most published studies focus on a pediatric or mixed age population.^{16,}
15 ^{21, 22, 30} Those that report the prevalence in the pediatric population partially overlap with our
16 findings of a predominance of VM,^{20, 22} but differ in the proportion of other ISSVA subgroups.
17 The differences in distribution of the different ISSVA groups of CVMs in adults compared to
18 children may be due to i) an age-dependency of clinical problems that are in the foreground, such
19 as organ-impairing LM in children or progressive high-flow AVM in adults, ii) a more frequent
20 recurrence of symptoms in some malformations or progression of the disease after puberty, iii) a
21 different perception of symptoms by the patient and caregivers. Whatever the reason for the
22 differences between children and adults, these populations are intrinsically different both
23 physically and mentally and, depending on the defined age, also legally. The priority in pediatric

1 care remains maintaining growth and development, whereas in adults, patient care is guided by
2 patient needs and subjective measures of quality of life. In these nonfatal diseases, the choice of
3 treatment, including molecular targeted therapy, requires consideration.

4 This work contributes to the epidemiological aspects of CVM. Our data show that patients can
5 become symptomatic and first diagnosed for CVM at the average age of 30 years upwards, so
6 estimates of incidence made on the basis of neonatal and stillborn prevalence are misleading.³¹⁻³⁴
7 The reported prevalence of CVM between 0.1-1.5% originating from the aforementioned studies
8 is probably an underestimation in the overall population context. In the absence of cross-sectional
9 studies, the exact prevalence and anatomical predisposition of extracranial CVM remains unclear;
10 we need to await results of large registry studies to estimate a realistic prevalence³⁵ and to
11 adequately adjust the treatment resources.

12 For the clinical diagnosis, we implemented the international VASCERN guidelines based on the
13 ISSVA classification^{28,36} to ensure a proper diagnosis and comparability of the data. Diagnosis
14 based on the clinical examination and complementary diagnostic tests according to the phenotype
15 helps to guide further diagnostic tests and limits the need of tissue biopsies (i.e., for
16 immunohistochemistry and for the analysis of somatic mutations) to cases with unclear findings.
17 Unclear findings accompanied our diagnostics especially in case of simple and combined CVM
18 with the same vascular denominator, as in the case of VM and LVM or CM and CVeM; those are
19 often indistinguishable lesions based on clinical and even imaging criteria. We assessed vascular
20 and non-vascular aspects of CVM and our results support the clinical experience, that various
21 CVMs often share the same symptoms and signs, which makes clinical differentiation
22 challenging.³⁷ In particular, patients with CM showed a wide spectrum of findings, including soft
23 tissue overgrowth and limb length difference that fits with the broad range of findings of simple

1 CM in the ISSVA classification. Nevertheless, we have observed cases of simple AVM with limb
2 length difference and a quarter of all CVM patients presented with soft tissue overgrowth. The
3 ISSVA classification doesn't describe explicitly these features, which indicates that further
4 differentiation of phenotypes will be necessary to clarify the associations between phenotype and
5 genotype or local paracrine effects emanating from mutated cells.

6 Nevertheless, some limitations ought to be mentioned. A possible selection bias comes from the
7 German-speaking imprint of our region, the vascular focus of our center and the university
8 framework of the hospital. This limitation probably diminished the referral of simple CM and is
9 evident in the proportion of CM that have been classified as simple and as a part of the
10 syndromes (18% vs. 63%). We held monthly interdisciplinary board meetings to discuss referrals
11 to dermatology, ENT, plastic surgery, or pediatrics, but the majority of those simple cases are
12 presumably treated in smaller centers. Furthermore, some data (e.g., family history on genetic
13 diseases and malignancies) were not systematically assessed at the beginning of this registry and
14 have been collected only subsequently. This study has other disadvantages due to its retrospective
15 design, including the fact that at this time we cannot provide quality of life indicators or specific
16 surveys for both baseline and post-treatment status. Prospective studies in our center will take
17 these indicators into account. Systematic tissue sampling for NGS and immunohistochemistry
18 were only recently introduced, and therefore were not taken into consideration in the diagnostic
19 procedure.

20 **Implications**

21 Phenotypic characterization considering vascular and non-vascular features remains the
22 cornerstone of diagnosis in adult and pediatric patients. Genotypic characterization will enrich the

1 overall picture of these diseases, and guide towards new, targeted therapeutic opportunities
2 emerging on the horizon.

3 **Conclusions**

4 In the adult and adolescent population with peripheral vascular malformations, simple venous
5 malformations predominated, with pain as the most common clinical symptom. In a quarter of
6 cases, patients with vascular malformations showed features associated with non-vascular tissue
7 growth. The differentiation of phenotypes with or without accompanying growth abnormalities
8 should be considered in the ISSVA classification, especially in the context of arteriovenous
9 malformations, where this feature occurred most frequently.

10

11

12 **Acknowledgements**

13 L. M. Boon and M. Vikkula are members of the Vascular Anomaly Working Group (VASCA
14 WG) of the European Reference Network for Rare Multisystemic Vascular Diseases
15 (VASCERN) - Project ID: 769036.

16 We are grateful to all the family members for their invaluable participation.

17 The authors wish to thank P. Stähli for expert assistance in data science and managing the data,
18 and F. Helfenstein for statistical support.

19 The Swiss National Science Foundation under the Sinergia project No. CRSII5_193694 funded
20 this project.

1 These studies were also financially supported by the Fonds de la Recherche Scientifique - FNRS
2 Grants T.0026.14 & T.0247.19 (to MV), T.0146.16 and P.C013.20 (to LMB).

3 **Declaration of Conflicting Interests:**

4 JR is currently an employee of Novartis Pharma AG.

5 RK is an investigator in a Novartis Pharma AG Study entitled: EPIK-P2: A Phase II double-blind
6 study with an upfront, 16-week randomized, placebo-controlled period, to assess the efficacy,
7 safety and pharmacokinetics of alpelisib (BYL719) in pediatric and adult patients with PIK3CA-
8 related overgrowth spectrum (PROS)

9 All other authors declare no conflicts of interests.

1 References

- 2 1. Vikkula M, Boon LM, Mulliken JB. Molecular genetics of vascular malformations. *Matrix Biol.*
3 2001;20(5-6):327-35.
- 4 2. Brouillard P, Vikkula M. Vascular malformations: localized defects in vascular morphogenesis.
5 *Clin Genet.* 2003;63(5):340-51.
- 6 3. Martinez-Corral I, Zhang Y, Petkova M, Ortsäter H, Sjöberg S, Castillo SD, et al. Blockade of
7 VEGF-C signaling inhibits lymphatic malformations driven by oncogenic PIK3CA mutation. *Nat Commun.*
8 2020;11(1):2869.
- 9 4. Limaye N, Kangas J, Mendola A, Godfraind C, Schlögel MJ, Helaers R, et al. Somatic Activating
10 PIK3CA Mutations Cause Venous Malformation. *Am J Hum Genet.* 2015;97(6):914-21.
- 11 5. Brouillard P, Schlögel MJ, Homayun Sepehr N, Helaers R, Queisser A, Fastré E, et al. Non-hotspot
12 PIK3CA mutations are more frequent in CLOVES than in common or combined lymphatic malformations.
13 *Orphanet J Rare Dis.* 2021;16(1):267.
- 14 6. Revencu N, Fastré E, Ravoet M, Helaers R, Brouillard P, Bisdorff-Bresson A, et al. RASA1 mosaic
15 mutations in patients with capillary malformation-arteriovenous malformation. *J Med Genet.*
16 2020;57(1):48-52.
- 17 7. Amyere M, Revencu N, Helaers R, Pairet E, Baselga E, Cordisco M, et al. Germline Loss-of-
18 Function Mutations in EPHB4 Cause a Second Form of Capillary Malformation-Arteriovenous
19 Malformation (CM-AVM2) Dereglating RAS-MAPK Signaling. *Circulation.* 2017;136(11):1037-48.
- 20 8. Revencu N, Boon LM, Mendola A, Cordisco MR, Dubois J, Clapuyt P, et al. RASA1 mutations and
21 associated phenotypes in 68 families with capillary malformation-arteriovenous malformation. *Hum Mutat.*
22 2013;34(12):1632-41.
- 23 9. Van Damme A, Seront E, Dekeuleneer V, Boon LM, Vikkula M. New and Emerging Targeted
24 Therapies for Vascular Malformations. *Am J Clin Dermatol.* 2020;21(5):657-68.
- 25 10. Hammer J, Seront E, Duez S, Dupont S, Van Damme A, Schmitz S, et al. Sirolimus is efficacious
26 in treatment for extensive and/or complex slow-flow vascular malformations: a monocentric prospective
27 phase II study. *Orphanet J Rare Dis.* 2018;13(1):191.
- 28 11. Mulliken JB, Glowacki J. Hemangiomas and vascular malformations in infants and children: a
29 classification based on endothelial characteristics. *Plast Reconstr Surg.* 1982;69(3):412-22.
- 30 12. Lee BB, Laredo J, Lee TS, Huh S, Neville R. Terminology and classification of congenital vascular
31 malformations. *Phlebology.* 2007;22(6):249-52.
- 32 13. Gloviczki P, Duncan A, Kalra M, Oderich G, Ricotta J, Bower T, et al. Vascular malformations: an
33 update. *Perspect Vasc Surg Endovasc Ther.* 2009;21(2):133-48.
- 34 14. Dasgupta R, Fishman SJ. ISSVA classification. *Semin Pediatr Surg.* 2014;23(4):158-61.
- 35 15. Shovlin CL, Simeoni I, Downes K, Frazer ZC, Megy K, Bernabeu-Herrero ME, et al. Mutational
36 and phenotypic characterization of hereditary hemorrhagic telangiectasia. *Blood.* 2020;136(17):1907-18.
- 37 16. Greene AK, Liu AS, Mulliken JB, Chalache K, Fishman SJ. Vascular anomalies in 5,621 patients:
38 guidelines for referral. *J Pediatr Surg.* 2011;46(9):1784-9.
- 39 17. Ten Broek RW, Eijkelenboom A, van der Vleuten CJM, Kamping EJ, Kets M, Verhoeven BH, et
40 al. Comprehensive molecular and clinicopathological analysis of vascular malformations: A study of 319
41 cases. *Genes Chromosomes Cancer.* 2019;58(8):541-50.
- 42 18. Pahl KS, Kim K, Sams C, Alvarez H, Smith SV, Blatt J. Inconsistency in classifying vascular
43 anomalies: What's in a name? *Pediatr Blood Cancer.* 2018;65(3).
- 44 19. Liu AS, Mulliken JB, Zurakowski D, Fishman SJ, Greene AK. Extracranial arteriovenous
45 malformations: natural progression and recurrence after treatment. *Plast Reconstr Surg.* 2010;125(4):1185-
46 94.
- 47 20. Estébanez A, Puche-Torres M, Sanchis García JM, Cuñat A, Pinazo Canales MI, Rausell Félix MF,
48 et al. Characteristics of mucocutaneous vascular malformations drawn from a decade of a multidisciplinary
49 committee experience. *Dermatol Ther.* 2021;34(5):e15074.

- 1 21. Vogel SA, Hess CP, Dowd CF, Hoffman WY, Kane AJ, Rajaii R, et al. Early versus later
2 presentations of venous malformations: where and why? *Pediatr Dermatol.* 2013;30(5):534-40.
- 3 22. Sires JD, Williams N, Huilgol SC, Harvey I, Antoniou G, Dawson J. An integrated multidisciplinary
4 team approach to the management of vascular anomalies: challenges and benefits. *Pediatr Surg Int.*
5 2020;36(10):1149-56.
- 6 23. Herrlin Jensen A, Jensen JS, Kjær ER, Grønhøj C, Hjuler T. Danish registry study showed increased
7 incidence of paediatric haemangiomas and congenital vascular malformations from 1996 to 2015. *Acta*
8 *Paediatrica.* 2020;109(12):2727-8.
- 9 24. Akyüz C, Yariş N, Kutluk MT, Büyükpamukçu M. Benign vascular tumors and vascular
10 malformations in childhood: a retrospective analysis of 1127 cases. *Turk J Pediatr.* 1997;39(4):435-45.
- 11 25. Yang B, Li L, Zhang LX, Sun YJ, Ma L. Clinical Characteristics and Treatment Options of Infantile
12 Vascular Anomalies. *Medicine (Baltimore).* 2015;94(40):e1717.
- 13 26. De Maria L, De Sanctis P, Balakrishnan K, Tollefson M, Brinjikji W. Sclerotherapy for Venous
14 Malformations of Head and Neck: Systematic Review and Meta-Analysis. *Neurointervention.* 2020;15(1):4-
15 17.
- 16 27. Oktay BK, Kaçar AG, Özel S, Ocak S, Celkan T. Clinical course of pediatric large vascular
17 anomalies located in the extremities. *Turk Arch Pediatr.* 2021;56(3):213-8.
- 18 28. VACERN. The VASCA Working Group, built upon Multidisciplinary Centres of Excellence for
19 Vascular Anomalies. Available from: [https://vascern.eu/expertise/rare-diseases-wgs/vasca-
20 wg/#1461009936186-03acb16b-9d4d](https://vascern.eu/expertise/rare-diseases-wgs/vasca-wg/#1461009936186-03acb16b-9d4d).
- 21 29. Ghaffarpour N, Baselga E, Boon LM, Diociaiuti A, Dompmartin A, Dvorakova V, et al. The
22 VASCERN-VASCA working group diagnostic and management pathways for lymphatic malformations.
23 *Eur J Med Genet.* 2022;65(12):104637.
- 24 30. Steiner FT, T.; FitzJohn, F.; T.Tan, S;. Stratification and characteristics of common venous
25 malformation by anatomical location. *JPRAS Open.* 2017;13:29-40.
- 26 31. Stevenson AC, Johnston HA, Stewart MI, Golding DR. Congenital malformations. A report of a
27 study of series of consecutive births in 24 centres. *Bull World Health Organ.* 1966;34 Suppl(Suppl):9-127.
- 28 32. al-Gazali LI, Dawodu AH, Sabarinathan K, Varghese M. The profile of major congenital
29 abnormalities in the United Arab Emirates (UAE) population. *J Med Genet.* 1995;32(1):7-13.
- 30 33. Jacobs AH, Walton RG. The incidence of birthmarks in the neonate. *Pediatrics.* 1976;58(2):218-22.
- 31 34. Himmetoglu O, Tiras MB, Gursoy R, Karabacak O, Sahin I, Onan A. The incidence of congenital
32 malformations in a Turkish population. *Int J Gynaecol Obstet.* 1996;55(2):117-21.
- 33 35. Groenen KHJ, Jacobsen A, Kersloot MG, Dos Santos Vieira B, van Enckevort E, Kaliyaperumal R,
34 et al. The de novo FAIRification process of a registry for vascular anomalies. *Orphanet J Rare Dis.*
35 2021;16(1):376.
- 36 36. Borst AJ, Nakano TA, Blei F, Adams DM, Duis J. A Primer on a Comprehensive Genetic Approach
37 to Vascular Anomalies. *Front Pediatr.* 2020;8:579591.
- 38 37. Bernhard SM, Tuleja A, Laine JE, Haupt F, Häberli D, Hügel U, et al. Clinical presentation of
39 simple and combined or syndromic arteriovenous malformations. *J Vasc Surg Venous Lymphat Disord.*
40 2022;10(3):705-12.

Figure 1: Internal simplified diagnostic flowchart for arteriovenous lesions.

Figure 2: Flow chart of patients stratified by main ISSVA groups.

Figure 3: Pie charts illustrating the proportion of the affected vascular types (arteriovenous, capillary, lymphatic, or venous) in relation to main CVM groups (simple, combined, with other anomalies).

For example: the arteriovenous vessel type was most commonly seen in simple CVM (80/117, 68%); it occurred once in the form of combined malformations and was part of malformations with other anomalies in 36 patients.

Arteriovenous, lymphatic, and venous vessel types were most commonly part of simple CVM; only the capillary vessel type was predominantly part of CVM with other anomalies (probably due to selection bias in a university hospital).

Figure 4: Distribution of pain among a. the main ISSVA groups and b. among the subgroup of simple CVMs.

The horizontal line in the middle of each boxplot represents the median. The lower and upper hinges correspond to the first and third quartiles (the 25th and 75th percentiles). The upper whisker extends from the hinge to the largest value no further than $1.5 * \text{inter-quartile range (IQR)}$. The lower whisker extends from the hinge to the smallest value at most $1.5 * \text{IQR}$ of the hinge. Note that pain scores cannot take negative values or values above 10 and data points beyond 0 and 10 are due the jittering of the data.

Figure 5: Representative clinical examples of soft tissue and/or limb length difference (bone overgrowth or undergrowth) in patients with different classes of CVM.

The first row demonstrates patients with Klippel-Trénaunay Syndrome (KTS) or Parkes-Weber syndrome (PWS):

- a) classical KTS with capillary malformation (CM) of the patella region, persistence of marginal vein and corrected bone overgrowth;
- b) Incomplete KTS (components: persistence of marginal vein, limb length difference and soft tissue overgrowth, no CM);
- c) Servelle- Marotell syndrome with multifocal venous malformation, persistence of marginal vein and hypotrophy of affected leg;
- d) classical PWS with CM, AVM and soft tissue and bone hypertrophy;
- e) patient with simple AVM accompanied with bone and soft tissue overgrowth, without CM, diagnosed as simple AVM.

The second row depicts patients with simple CM and overgrowth disorders:

- f) diffuse CM with overgrowth (DCMO),
- g) DCMO with overgrowth of the bone, but soft tissue hypotrophy,
- h) CM with undergrowth (CMU); an entity already described in the literature, but not yet in the ISSVA classification.

Tables:

Table 1a: Demographics and clinical presentation of the study population stratified by main ISSVA groups.

* indicates statistically non-significant result for rejecting null hypothesis according to Holm-Bonferroni correction

Table 1b: Demographics and clinical presentation of the patients with simple CVM.

^{a)} microvascular AVM (CM-AVM according to Frey S. et al)

* indicates statistically non-significant result for rejecting null hypothesis after Holm-Bonferroni correction

Table 2: Schematic representation of diagnostic entities involving limb length difference.

*diffuse capillary malformation with overgrowth (DCMO)- capillary malformation with overgrowth (DMO)- capillary malformation with undergrowth (CMU)

** incomplete Klipper- Trénaunay syndrome (without capillary component)

*** potential classification gap

Journal Pre-proof

Tables

Table 1a: Demographics and clinical presentation of the study population stratified by main ISSVA groups.

	ISSVA classification			p
	simple	combined	with other anomalies	
Number	361	26	70	
Woman, n (%)	209 (57.9)	14 (53.8)	35 (50.0)	0.458*
Age, mean (SD)	34.41 (15.8)	38.12 (17.8)	37.34 (15.2)	0.222*
Family history of CVM, n (%)	20 (5.5)	1 (3.8)	8 (11.4)	0.156*
Vascular signs and symptoms n (%)				
Ulceration	9 (2.5)	1 (3.8)	1 (1.4)	0.769*
Abscess or infection	6 (1.7)	1 (3.8)	3 (4.3)	0.326*
Lymphedema (primary and secondary)	14 (3.8)	2 (7.7)	13 (18.6)	<0.001
Phlebedema	21 (5.8)	5 (19.2)	9 (12.9)	0.009*
Thrombophlebitis	30 (8.3)	0 (0.0)	5 (7.1)	0.301*
D-dimers, mean (SD)	686.25 (1641.81)	3193.38 (7653.46)	3158.95 (5650.87)	<0.001
LIC	61 (26.5)	7 (43.8)	10 (50.0)	0.037*
Bleeding	14 (3.9)	4 (15.4)	22 (31.4)	<0.001
Non- vascular signs, n (%)				
Soft tissue overgrowth	92 (25.5)	8 (30.8)	19 (27.1)	0.817*
Limb length difference	8 (2.2)	1 (3.8)	16 (22.9)	<0.001
Skeletal deformation	0 (0.0)	2 (7.7)	6 (8.6)	<0.001

* indicates statistically non-significant result for rejecting null hypothesis according to Holm-Bonferroni correction

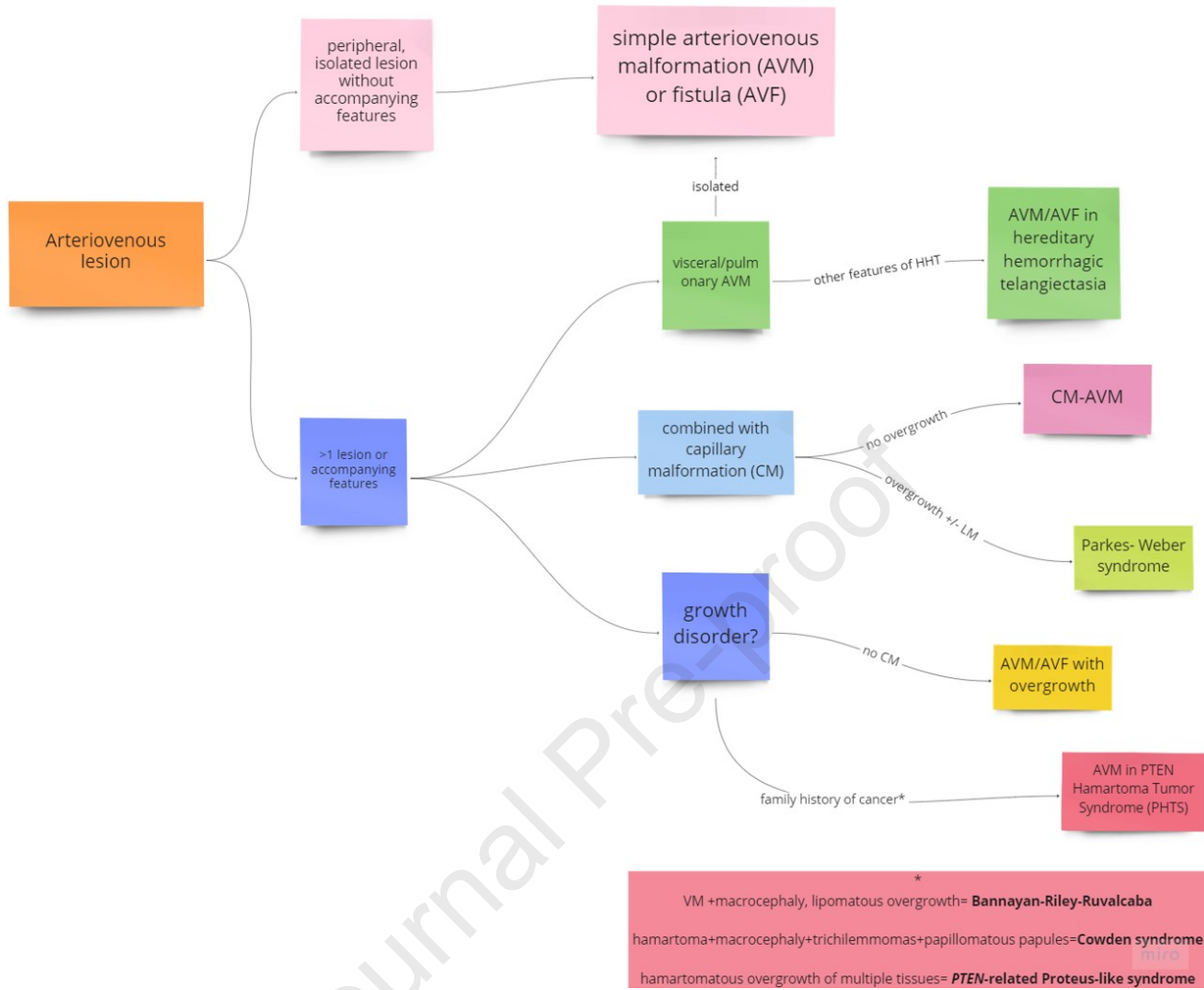
Table 1b: Demographics and clinical presentation of the patients with simple CVM.

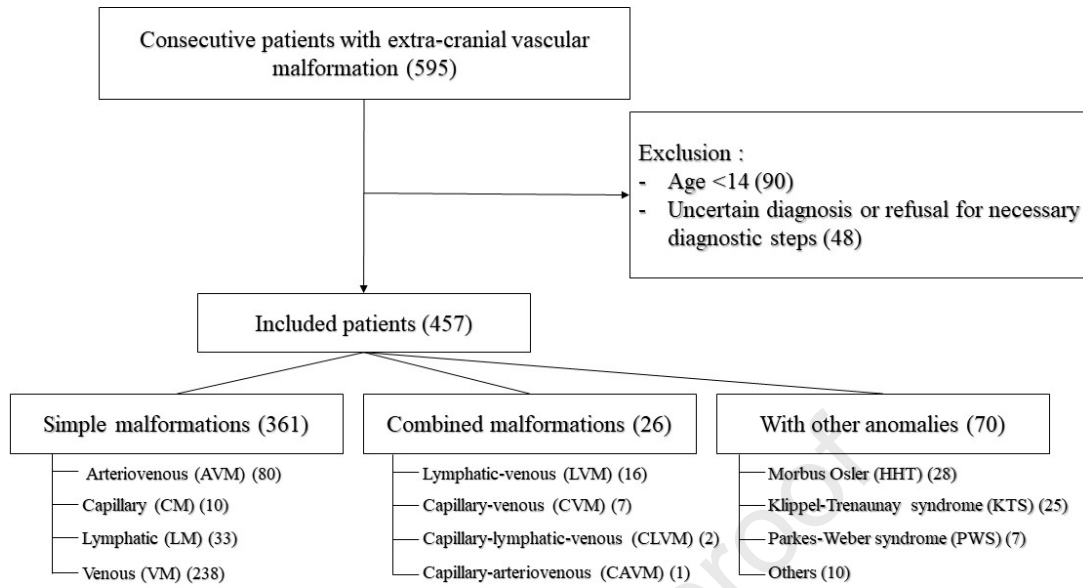
Simple congenital vascular malformation					
	AVM	CM	LM	VM	p-value
Number	80	10	33	238	
Woman, n (%)	46 (57.5)	8 (80.0)	18 (54.5)	137 (57.6)	0.537*
Age, mean (SD)	41.0 (15.6)	22.7 (8.0)	37.5 (18.8)	32.3 (14.9)	<0.001
Family history of CVM (%)	3 (3.8)	1 (10.0)	2 (6.1)	14 (5.9)	0.816*
Vascular signs, n (%)					
Ulceration	7 (8.8)	0 (0.0)	1 (3.0)	1 (0.4)	0.001
Abscess or infection	3 (3.8)	0 (0.0)	3 (9.1)	0 (0.0)	0.001
Lymphedema (primary and secondary)	3 (3.8)	0 (0.0)	11 (33.3)	0 (0.0)	<0.001
Phlebedema	0 (0.0)	0 (0.0)	0 (0.0)	21 (8.8)	0.009*
Thrombophlebitis	3 (3.8) ^{a)}	0 (0.0)	0 (0.0)	27 (11.3)	0.03*
D-dimer, mean (SD)	266.2 (227.8)	147.7 (99.2)	141.1 (119.2)	779.8 (1785.6)	0.297*
LIC	3 (3.8)	0 (0.0)	0 (0.0)	58 (24.7)	0.028*
Bleeding	6 (7.5)	0 (0.0)	0 (0.0)	8 (3.4)	0.193*
Non-vascular signs, n (%)					
Soft tissue overgrowth	25 (31.2)	2 (20.0)	4 (12.1)	61 (25.6)	0.198*
Limb length difference	6 (7.5)	2 (20.0)	0 (0.0)	0 (0.0)	<0.001
Skeleton deformation	0 (0.0)	0 (0.0)	0 (0.0)	0 (0.0)	NaN

* indicates statistically non-significant result for rejecting null hypothesis according to Holm-Bonferroni correction

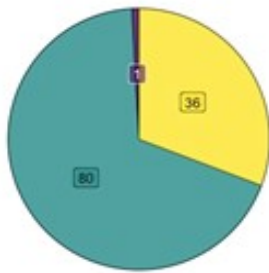
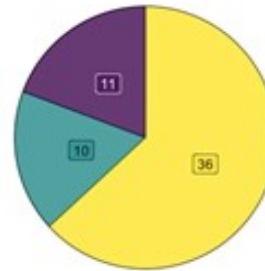
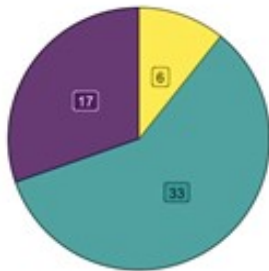
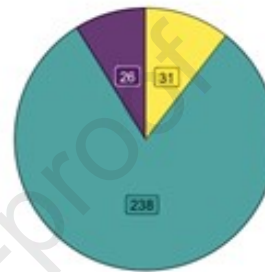
Table 2: Schematic representation of diagnostic entities involving limb length difference.

Vascular component	Limb length difference	Diagnosis according to ISSVA
CM	No	Simple/ non-syndromic CM
	Yes	Simple/ DCMO-CMO-CMU*
VM	No	Simple VM
	Yes	Incomplete KTS**/ Servelle-Martorell
AVM	No	Simple AVM
	Yes	Simple AVM***

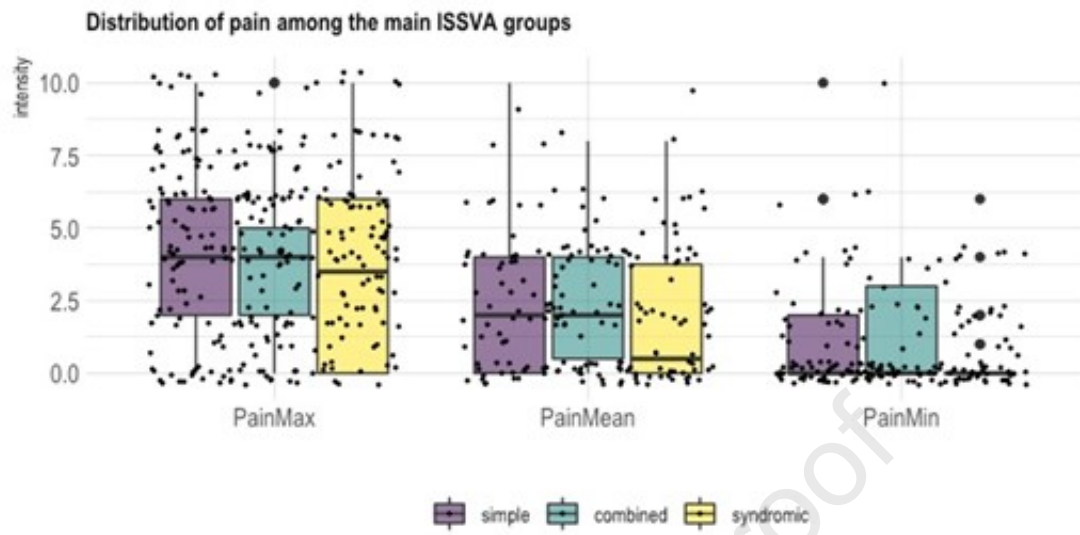


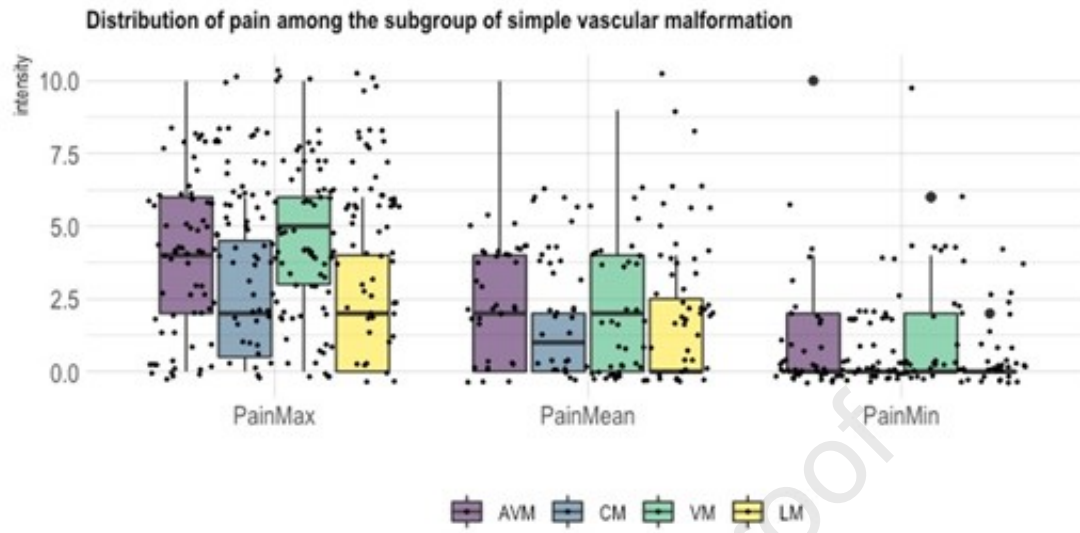


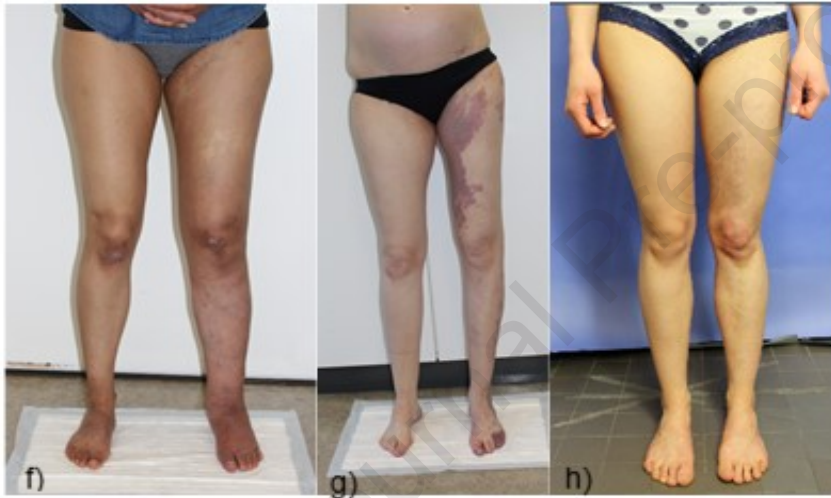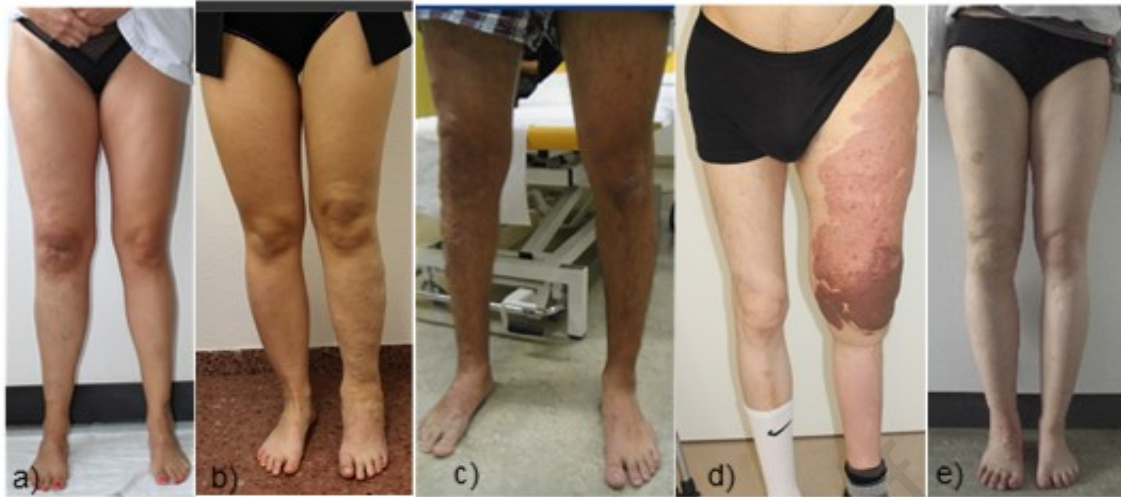Simple malformations (361)			
Arteriovenous (AVM) (80)	Capillary (CM) (10)	Lymphatic (LM) (33)	Venous (VM) (238)
Malformation (AVM) (80) Fistula (AVF) (0)	Nonsyndromic cutaneous CM (5) CM with bone and/or soft tissues overgrowth (CMO) (2) CM with bone and/or soft tissues undergrowth (CMU) (3)	Common (cystic) LM (21) Primary lymphedema (11) Generalized lymphatic anomaly (1)	Common VM (233) Blue rubber bleb nevus syndrome (2) Glomuvenous malformation (3)

Arteriovenous**Capillary****Lymphatic****Venous**

CVM group  simple  combined  with other anomalies







1 Supplement

2

3 Methods

4 Definitions

5 A questionable diagnosis of CVM was defined as a diagnosis that could not be confirmed by
6 diagnostic studies or was inadequately documented (lacking photographic documentation and
7 at least one other imaging modality as well as a description of the clinical presentation).

8 The patient-specific data comprised demographics, classification of CVM according to
9 ISSVA, and family history related to inborn genetic diseases. Patients were classified to have
10 simple CVM (i.e. capillary malformation, CM; lymphatic malformation, LM; venous
11 malformation, VM; arteriovenous malformation, AVM), combined CVM affecting more than
12 one vessel type (e.g. capillary-venous malformation, CVeM; capillary-lymphatic-venous
13 malformation, CLVM, capillary-arterio-venous malformation, CAVM), CVM associated with
14 other anomalies, and unclassified CVM. Malformation of major named vessels was filled as
15 an additional finding. In case of patients with unclear classification, the decision was
16 discussed at the interdisciplinary board meeting and diagnosis was defined by consensus.
17 Missing information were continuously updated or completed during the regular patient
18 follow-up visits. Duplex ultrasound was used to distinguish between "high-flow" and "low-
19 flow" lesions. High flow in terms of flow pattern in pulsed- wave Doppler ultrasound, was
20 defined as a spontaneous high velocity and low resistance pulsatile flow in the area of the
21 malformation and inflowing arteries and pulsatile, high velocity flow in outflowing veins.
22 Low flow was defined as a completely or partially compressible lacunal/tubular/cystic
23 structure without spontaneous flow, but flow provocation upon compression. Localization,
24 involvement of tissue compartments and soft tissue overgrowth were defined by magnetic
25 resonance imaging (MRI). Anatomically, the upper extremity (arm and hand), lower

1 extremity (limb and foot), trunk (thorax, abdomen, pelvis, and genitals), and neck/face were
2 distinguished. Tissue compartments were separated into cutis, subcutis, muscles, bones, joints
3 and visceral organs.

4 Disease-specific clinical data comprised symptoms, clinical findings, laboratory results, photo
5 documentation from each consultation, thermographic pictures, duplex ultrasound, and
6 contrast enhanced MRI of the involved region. Optional imaging included digital subtraction
7 angiography (DSA) in patients the arteriovenous malformations, direct phlebography in
8 venous malformations, and fluorescein microlymphography (FITC) when indicated.

9 The intensity of disease-related pain was classified using the Numeric Pain Scale (NRS),
10 ranging from 0 (no pain) to 10 (the worst pain the patient could imagine); the minimal,
11 maximal and average pain intensity was documented. Soft tissue overgrowth was defined as
12 local overgrowth in an area of the CVM compared with the surrounding tissue and was cross-
13 checked with MRI results. Limb length difference was assessed by long-leg radiography.
14 Lymphedema was defined as a pitting, palpable swelling with positive Stemmer sign and
15 pathological FITC microlymphography (if needed). Phlebedema was characterized by ankle
16 swelling in the presence of other symptoms of venous insufficiency (telangiectasia, varicose
17 vein, dermatitis). Any type of bleeding related to CVM was recorded. For the assessment of
18 localized intravascular coagulopathy (LIC) D-dimer levels were routinely measured in venous
19 blood samples, using an immunoturbidimetrically method with the cut-off set at 500 mg/L.

20

21 Data monitoring

22 Patient-specific and disease-specific data of all patients included in the study was regularly
23 exported from the CWD database for quality control. The export was performed via the
24 Clinical Data Warehouse (CDWH) cockpit, a tool provided by the Insel Data Science Center

1 (IDSC), ensuring that only data from patients with a valid consent could be exported. The
2 Cockpit filtering tool selects all data from patients in the study until the export date and
3 assigns a unique 20-digit hash key to each subject (pseudo-id) which serves as an identifier in
4 the pseudonymized export file, as well as a primary key to link additional datasets that contain
5 genetic and radiology data. The key list with the patient-id (PID) and the pseudo-id is only
6 accessible by the study nurse, ensuring that no identifying information is accessible for
7 persons outside the Division of Angiology. A script runs automatic and reproducible checks
8 on the exported data for completeness, consistency and plausibility. Any deviation from the
9 rules is tagged, and each record with one or more tags is saved in a file that will be sent to the
10 study nurse for further clarification and appropriate data correction in cooperation with an
11 investigator in CWD using the pseudo-id. Files used for analysis are stored on the centralized
12 SharePoint server of the University Hospital of Bern with user management, version control
13 and a dedicated folder structure. Additional or new information on patients was regularly
14 included in the monitoring process.

15

16

17

18

19

20

21

22

23

1

2

3

4

5

6

7

8

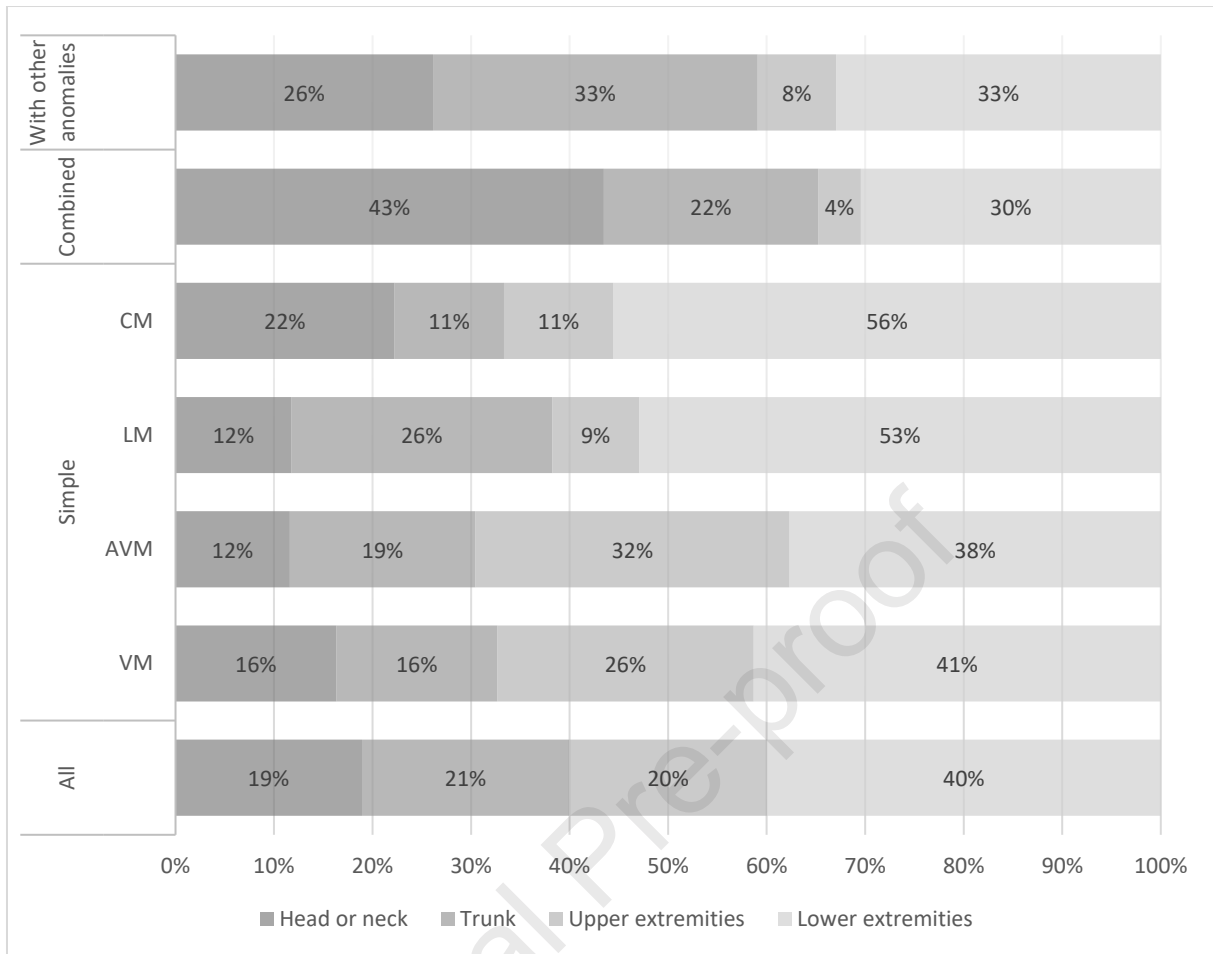
9

10

11 Supplemental Figures

12

13 **Supplemental Figure 1:** Localization of vascular malformation



1

2

3

4

5

6

7

8

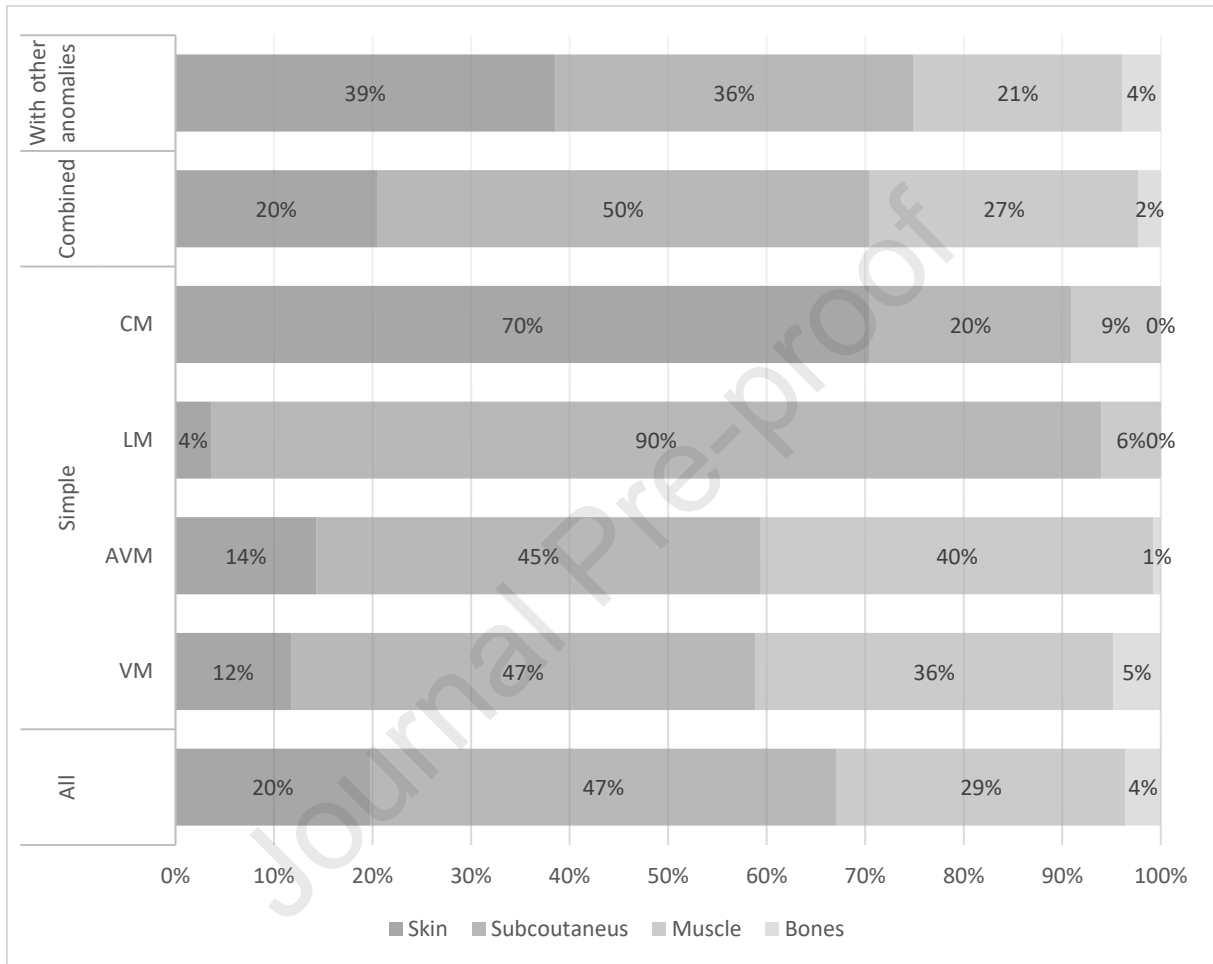
9

10

1

2

3 **Supplemental Figure 2: Tissue involvement in different types of CVM**



4

5

6

7

8

9

10

Journal Pre-proof