

# Acute Type A Aortic Dissection

Citation for published version (APA):

Massi, F., Mureddu, S., Di Mauro, M., Ferrandu, P., Triggiani, M., & Portoghese, M. (2022). Acute Type A Aortic Dissection: How Many Patients Are Suitable for Endovascular Ascending Aortic Repair? *European Journal of Vascular and Endovascular Surgery*, 64(1), 130-131. Advance online publication. <https://doi.org/10.1016/j.ejvs.2022.03.039>

## Document status and date:

Published: 01/07/2022

## DOI:

[10.1016/j.ejvs.2022.03.039](https://doi.org/10.1016/j.ejvs.2022.03.039)

## Document Version:

Publisher's PDF, also known as Version of record

## Document license:

Taverne

## Please check the document version of this publication:

- A submitted manuscript is the version of the article upon submission and before peer-review. There can be important differences between the submitted version and the official published version of record. People interested in the research are advised to contact the author for the final version of the publication, or visit the DOI to the publisher's website.
- The final author version and the galley proof are versions of the publication after peer review.
- The final published version features the final layout of the paper including the volume, issue and page numbers.

[Link to publication](#)

## General rights

Copyright and moral rights for the publications made accessible in the public portal are retained by the authors and/or other copyright owners and it is a condition of accessing publications that users recognise and abide by the legal requirements associated with these rights.

- Users may download and print one copy of any publication from the public portal for the purpose of private study or research.
- You may not further distribute the material or use it for any profit-making activity or commercial gain
- You may freely distribute the URL identifying the publication in the public portal.

If the publication is distributed under the terms of Article 25fa of the Dutch Copyright Act, indicated by the "Taverne" license above, please follow below link for the End User Agreement:

[www.umlib.nl/taverne-license](http://www.umlib.nl/taverne-license)

## Take down policy

If you believe that this document breaches copyright please contact us at:

[repository@maastrichtuniversity.nl](mailto:repository@maastrichtuniversity.nl)

providing details and we will investigate your claim.

## RESEARCH LETTER

## Acute Type A Aortic Dissection: How Many Patients Are Suitable for Endovascular Ascending Aortic Repair?

Francesco Massi <sup>a,\*</sup>, Simone Mureddu <sup>b</sup>, Michele Di Mauro <sup>c</sup>, Paolo Ferrandu <sup>b</sup>, Michele Triggiani <sup>a</sup>, Michele Portoghese <sup>b</sup>

<sup>a</sup> Department of Cardiovascular and Thoracic Surgery, Giuseppe Mazzini Hospital, Teramo, Italy

<sup>b</sup> Department of Cardiovascular and Thoracic Surgery, Azienda Ospedaliera Universitaria di Sassari, Sassari, Italy

<sup>c</sup> Department of Cardiothoracic and Vascular Surgery, Maastricht University Medical Centre, Maastricht, The Netherlands

Open aortic surgery is the gold standard for treatment of acute type A aortic dissection (TAAD). Ascending thoracic endovascular aortic repair (aTEVAR) has been reported for the treatment of a few patients with acute TAAD excluded from open surgical treatment; however, the anatomical feasibility of aTEVAR has not been extensively explored.

This study aimed to investigate the theoretical feasibility of aTEVAR through retrospective analysis of both computed tomography angiography (CTA) images and clinical characteristics of a consecutive series of 103 patients undergoing open repair for acute TAAD between 2015 and 2020 in a single centre.

Two experienced cardiac surgeons independently examined only high quality CTA images with electrocardiogram gating on a digital workstation (OsiriX MD, Pixmeo Sarl, Bernex, Switzerland): 62 patients (60.2%); male (62.9%); mean age  $69 \pm 15$  years. Patients with low quality CTA (slice thickness  $> 1$  mm, inadequate arterial phase or presence of artefact) were excluded from further imaging analysis (41 patients; male 51.2%; mean age  $63 \pm 11$  years). Patients with low quality CTA presented with haemodynamic instability in 9.8%; dysrhythmias/tachycardia in 26.8%; pericardial effusion in 17.1%; and myocardial, cerebral, spinal, visceral or limb malperfusion in 14.6% (data not significantly different from patients with high quality CTA).

The feasibility of aTEVAR in acute TAADs was related to the fulfilment of the following strict criteria: (1) Entry tear (ET) distal to Zone OA (from the aortic annulus to the distal margin of highest coronary artery); (2) Proximal and distal landing zone (LZ)  $\geq 20$  mm length; (3) True lumen (TL) aortic diameter  $\leq 38$  mm and total aortic diameter  $\leq 46$  mm (outer wall to outer wall) at proximal and distal LZ; and (4) Absence of coronary grafts in ascending aorta, mechanical aortic valve, grade 3/4 aortic valve regurgitation, and coronary malperfusion.

These criteria are based on experience of TEVAR in the descending aorta, reports of aTEVAR performed using common thoracic endografts, and their instruction for use (IFU), considering that 46 mm is the maximum diameter for commercially available grafts.

The mean number of ETs in the ascending aorta and aortic arch was 2.17. The locations of the most proximal ETs were, respectively: Zone OA, 24.2%; Zone OB (from above the coronary to the distal margin of right pulmonary artery), 46.8%; Zone OC (from the right pulmonary artery border to the innominate artery), 16.1%; and Zone 1, 12.9%. Mean aortic diameters and lengths are shown in [Figure 1](#) (Panel A). Intraclass correlation coefficient calculated for intra- and interobserver variability demonstrated excellent reliability (ICC  $> .9$ ) of aortic measurements.

Eleven patients (17.7%) were eligible for aTEVAR (eight had most proximal ET in zone OB). Thirty-six patients (58.1%) had an inadequate proximal LZ (ET in zone OA/OB), associated with poor distal LZ (18 patients), aortic valve regurgitation (13 patients), coronary malperfusion (four patients). Six patients (9.7%) had a good proximal LZ but a poor distal LZ (ET in zone OC/1). Nine patients (14.5%) had only an inadequate distal LZ but the supra-aortic vessels were not dissected.

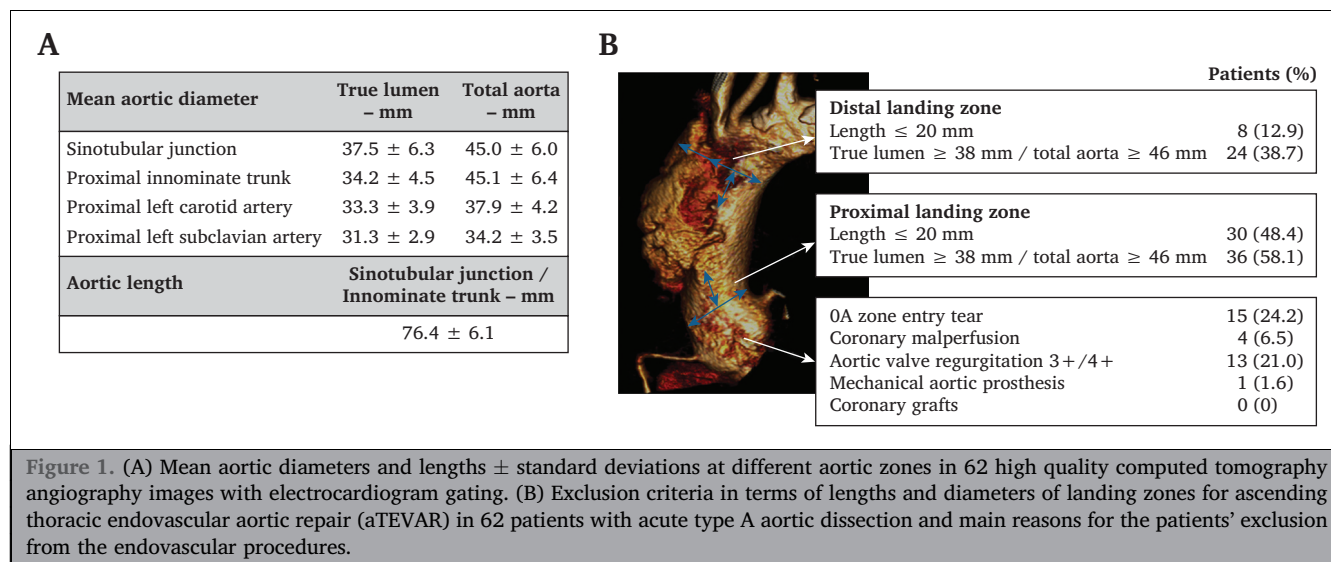
The reasons for patient unsuitability for aTEVAR are described in [Figure 1](#) (Panel B); the main anatomical reason was a poor proximal LZ. Most proximal ETs are mainly located in the proximity of the sinotubular junction; an evident limit to aTEVAR since it could lead to harmful complications.<sup>1</sup> Some attempts have been made to extend the feasibility of endovascular treatment to zone OA using customised "Endobentall" grafts; however, there are several limitations and disadvantages, and there are currently no reports of "Endobentall" on acute TAAD.<sup>2</sup>

An inadequate distal LZ with no dissected supra-aortic vessels was present in 14.5% of patients (ET in zone OC/1). This limitation was overcome in a few case series with additional endovascular/surgical procedures on supra-aortic vessels (extra-anatomic debranching/branched endografts/chimney techniques),<sup>3,4</sup> which could extend the distal LZ and suitability for aTEVAR up to 32.3% in this study.

There are differing views on adequate LZ in acute TAAD. A 2 cm LZ length is important with degenerative aneurysms but may be less of a concern with focal entry tears. A 20% oversize of the aortic TL is probably overestimated for a subtle dissected aortic wall: the endograft is mostly implanted in a non-dilated TL to seal the ET, and after aortic remodelling it could have no further function. Many authors

\* Corresponding author. Cardiovascular and Thoracic Surgery Department, Giuseppe Mazzini Hospital, Piazza Italia, 64100, Teramo, Italy.

E-mail address: francescomassi78@gmail.com (Francesco Massi).



recommend oversize by 5 – 10% in acute pathology without exceeding the original aortic diameter;<sup>1,5</sup> however, significant flow dynamics in the ascending aorta can influence the stability of the graft and recent case series with custom made endografts suggest an oversizing of 15 – 30%.<sup>3</sup> This was a feasibility study and did not evaluate outcomes; mid/long term results of aTEVAR applying different anatomical criteria on patient selection are still unavailable and unpredictable.

This study was limited by its retrospective nature, exiguous patient population, and high number of low quality CTAs (39.8%). The latter probably reflects the 'middle of the night' nature of the problem: 80.5% of low quality CTAs were performed in peripheral hospitals ( $p < .001$ ). Moreover, the anatomical exclusion criteria were not specific for characteristics of acutely dissected ascending aorta and obtained from IFU of endografts not specifically made for that pathology in that specific zone.

In conclusion, a small proportion of patients with acute TAAD could hypothetically be eligible for aTEVAR (17.7%) with standard endografts: inadequate proximal LZ is the main issue. The use of additional aortic arch procedures would increase the feasibility of aTEVAR to up to one third of patients. A high quality electrocardiogram gated CTA is mandatory to evaluate the anatomical feasibility but a lot of patients still receive poor quality exams.

#### CONFLICT OF INTEREST STATEMENT AND FUNDING

None.

#### REFERENCES

- Roselli EE, Idrees J, Greenberg RK, Johnston DR, Lytle BW. Endovascular stent grafting for ascending aorta repair in high-risk patients. *J Thorac Cardiovasc Surg* 2015;**149**:144–51.
- Felipe Gaia D, Bernal O, Castilho E, Baeta Neves Duarte Ferreira C, Dvir D, Simonato M, et al. First-in-Human Endo-Bentall Procedure for Simultaneous Treatment of the Ascending Aorta and Aortic Valve. *JACC Case Rep* 2020;**12**:480–5.
- Law Y, Tsilimparis N, Rohlfes F, Makaloski V, Debus ES, Kölbel T. Combined Ascending Aortic Stent-Graft and Inner Branched Arch Device for Type A Aortic Dissection. *J Endovasc Ther* 2018;**25**: 561–5.
- Zhao Y, Feng J, Yan X, Zhu G, Zhou J, Li Z, et al. Outcomes of the Chimney Technique for Endovascular Repair of Aortic Dissection Involving the Arch Branches. *Ann Vasc Surg* 2019;**58**: 238–47.
- Khoynezhad A, Donayre CE, Walot I, Koopmann MC, Kopchok GE, White RA. Feasibility of endovascular repair of ascending aortic pathologies as part of an FDA-approved physician-sponsored investigational device exemption. *J Vasc Surg* 2016;**63**:1483–95.

#### Keywords:

Acute type A aortic dissection, Ascending aorta, Ascending endovascular aortic repair, aTEVAR, Computed tomography angiography, Endovascular procedures

Available online 9 April 2022

© 2022 European Society for Vascular Surgery. Published by Elsevier B.V. All rights reserved.

<https://doi.org/10.1016/j.ejvs.2022.03.039>