



Universiteit
Leiden
The Netherlands

Sensorineural hearing loss after adoptive cell immunotherapy for melanoma using MART-1 specific T cells: a case report and its pathophysiology

Duinkerken, C.W.; Rohaan, F.W.; Weger, V.A. de; Lohuis, P.J.F.M.; Latenstein, M.N.; Theunissen, E.A.R.; ... ; Zuur, C.L.

Citation

Duinkerken, C. W., Rohaan, F. W., Weger, V. A. de, Lohuis, P. J. F. M., Latenstein, M. N., Theunissen, E. A. R., ... Zuur, C. L. (2019). Sensorineural hearing loss after adoptive cell immunotherapy for melanoma using MART-1 specific T cells: a case report and its pathophysiology. *Otology And Neurotology*, 40(7), e674-e678.
doi:10.1097/MAO.0000000000002332

Version: Publisher's Version
License: [Creative Commons CC BY-NC-ND 4.0 license](https://creativecommons.org/licenses/by-nc-nd/4.0/)
Downloaded from: <https://hdl.handle.net/1887/3589614>

Note: To cite this publication please use the final published version (if applicable).

Sensorineural Hearing Loss After Adoptive Cell Immunotherapy for Melanoma Using MART-1 Specific T Cells: A Case Report and Its Pathophysiology

*Charlotte W. Duinkerken, †Maartje W. Rohaan, ‡Vincent A. de Weger,
*§Peter J. F. M. Lohuis, *Merel N. Latenstein, ||Eleonoor A. R. Theunissen,
*§Alfons J. M. Balm, ¶Wouter A. Dreschler, †John B. A. G. Haanen, and *§Charlotte L. Zuur

*Department of Head and Neck Oncology and Surgery; †Department of Medical Oncology; ‡Division of Pharmacology, the Netherlands Cancer Institute, Amsterdam, the Netherlands; §Department of Maxillofacial Surgery; ||Department of Otorhinolaryngology; and ¶Department of Audiology, Amsterdam University Medical Center, Amsterdam, the Netherlands

Objective: To illustrate a case of sensorineural hearing loss (SNHL) after immunotherapy based on T cell receptor (TCR) gene therapy using modified T cells recognizing melanoma antigen recognized by T cells 1 for disseminated melanoma.

Patient: We present a 59-year-old woman with profound subacute bilateral SNHL including unilateral deafness after immunotherapy based on TCR gene therapy using modified T cells recognizing melanoma antigen recognized by T cells 1 for disseminated melanoma. Ten days after treatment, the patient developed hearing loss of 57 dB hearing loss air conduction at pure-tone average 0.5–1–2–4 kHz in the right ear, and >100 dB hearing loss air conduction at pure-tone average 0.5–1–2–4 in the left ear. The right ear recovered partially, while the left ear remained deaf, despite oral prednisolone (1.0 mg/kg) and salvage treatment with three transtympanic injections of 0.5 ml dexamethasone (4.0 mg/ml).

Conclusion: Based on our presented case and a vast amount of literature there is circumstantial evidence that TCR gene therapy for melanoma targets the perivascular macrophage-like melanocytes in the stria vascularis, resulting in SNHL. We suggest that SNHL after TCR gene therapy may be caused by a disruption of the blood–labyrinth–barrier and the endolymphatic potential and/or a sterile inflammation of the stria vascularis. In severe cases like our subject, we posit that endolymphatic hydrops or hair cell loss may cause irreversible and asymmetrical deafness. Steroid prophylaxis via transtympanic application is debatable. **Key Words:** Adoptive cell therapy—Melanoma—SNHL—T cell receptor therapy—Treatment-related hearing loss.

Otol Neurotol 40:e674–e678, 2019.

T cell receptor (TCR) gene therapy is an internationally appreciated novel treatment option for metastatic melanoma, which is currently tested for its efficacy and toxicity (1). In melanoma antigen recognized by T cells 1 (MART-1)-specific TCR gene therapy, peripheral blood T cells are genetically modified by engraftment of a MART-1-specific TCR that recognizes melanoma cancer cells (1–3). Small phase I/II studies reported partial tumor response rates up to 13 to 30% for patients with melanoma progressing upon previous therapies (1). Interestingly, this specific form of TCR gene therapy introduced a novel likely cause of treatment-related sensorineural hearing loss (SNHL) into our clinical practice (4). We aim to present a case of asymmetric SNHL including deafness on one side after

MART-1-specific TCR gene therapy and to discuss its potential pathophysiology. The unilateral deafness demonstrated here will probably influence the design of possible future treatment strategies for these patients with regard to the indication for TCR gene therapy itself or possible combinations with other forms of immunotherapy.

CASE PRESENTATION

A 59-year-old woman with metastatic cutaneous melanoma was included in a phase I/IIa clinical trial (EudraCT no. 2011-002941-36) using MART-1-specific TCR transduced T cells. Audiometry revealed normal baseline hearing capacity (Fig. 1). First, the patient underwent apheresis. Next, she was treated with cyclophosphamide and fludarabine for the depletion of lymphocytes. One week later, 2.5×10^8 TCR-modified T cells were reinfused into the patient.

In the evening of day 9 after infusion of T cells, she complained of subacute bilateral hearing loss. The next

Address correspondence and reprint requests to Charlotte W. Duinkerken, M.D., Plesmanlaan 121, 1066 CX Amsterdam, the Netherlands; E-mail: c.duinkerken@nki.nl

The authors disclose no conflicts of interest.

DOI: 10.1097/MAO.0000000000002332

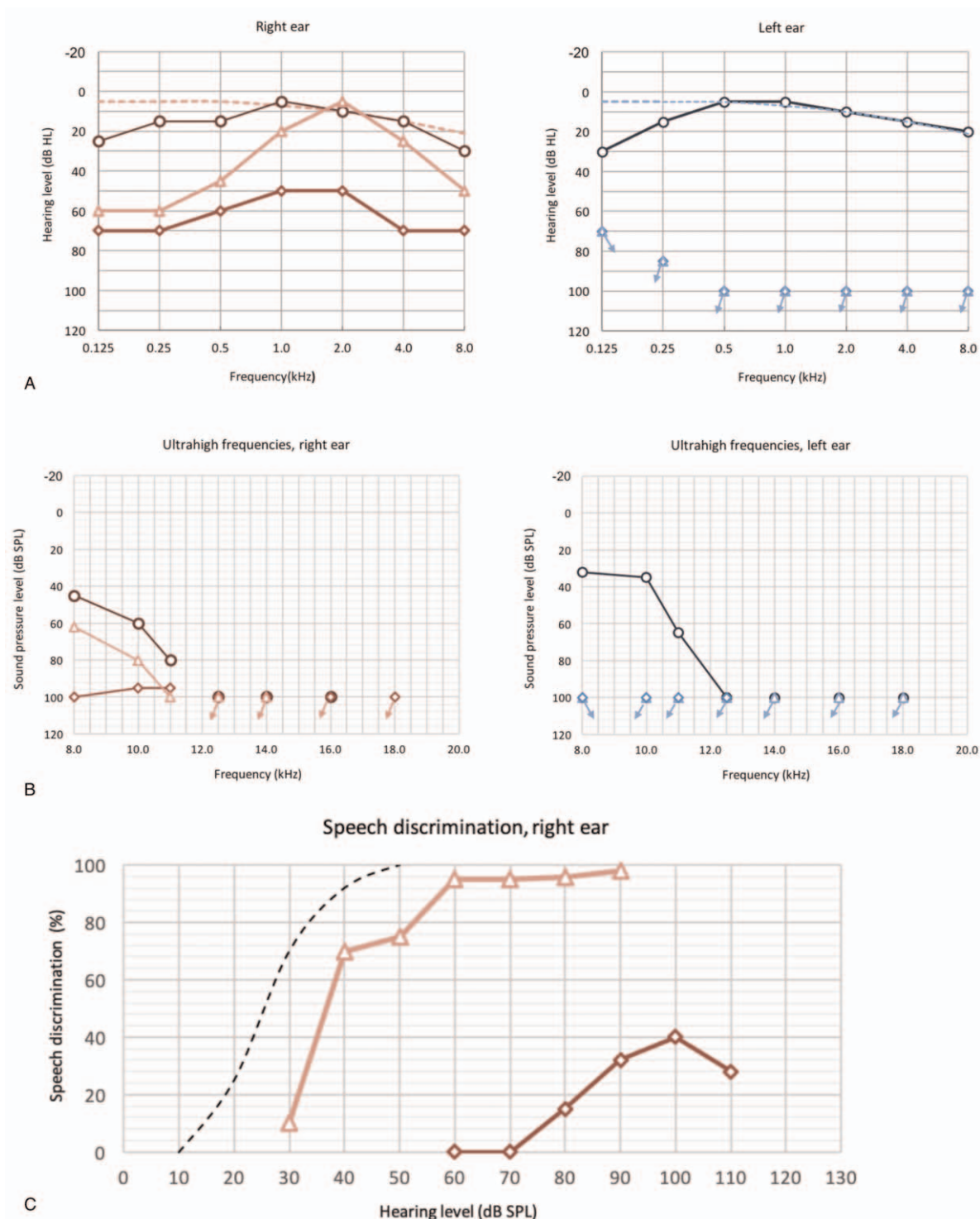


FIG. 1. Audiometric testing results for baseline hearing level (○); hearing level at onset of clinically overt hearing loss, which is 10 days after T cell receptor modified T cell infusion (◇); and the hearing level at end of steroid treatment (△). **A**, Pure-tone audiometry, only air conduction (AC) thresholds are shown. Ten days after infusion of TCR transduced T cells, hearing level was asymmetrically reduced to 57 dB HL AC at pure-tone average (PTA) 0.5–1–2–4 kHz in the right ear and >100 dB HL AC at PTA 0.5–1–2–4 kHz in the left ear—the left ear could not be measured with adequate masking. After systemic steroid treatment, the right ear recovered to 24 dB HL AC at PTA 0.5–1–2–4 kHz. The left ear remained deaf. **B**, High-frequency audiometry. The high frequencies in the right ear partially recovered. However, high frequencies could not be heard in the left ear, which did not recover after steroid treatment. *The SPL thresholds shown at 8 kHz have been converted from HL according to ISO 389-1. **C**, Speech perception for the right ear. Baseline discrimination scores are missing. At the onset of symptoms, the maximum discrimination score was reduced to 40% at 100 dB SPL, which improved to a maximum of nearly 100% at 60 dB SPL. In the left ear, there was no measurable speech perception. TCR indicates T cell receptor; SPL, sound pressure level; HL, hearing loss.

Downloaded from http://journals.lww.com/otology-neurotology by BhdMf5ePHkav1zEoun1tIQN4a+kLHEZqshIH on 07/11/2023

morning, she reported bilateral “deafness.” Audiometric testing showed asymmetric SNHL with a pure-tone average 0.5–1–2–4 kHz of 57 dB hearing level air conduction in the right ear and a deaf left ear. Immediately, systemic prednisolone (1 mg/kg/d) was administered. After 2 weeks, the right ear significantly improved. In an attempt to rescue the left ear, 0.5 ml topical dexamethasone (4.0 mg/ml) was given transtympanically at days 25, 27, and 33 after T cell infusion. Nevertheless, the left ear remained deaf. The right ear recovered to 24 dB hearing level air conduction at pure-tone average 0.5–1–2–4 kHz with speech discrimination of 97% at 60 dB sound pressure level (Fig. 1C). Repeated audiometry after 1 month showed similar results (not shown). The patient did not complain of vestibular symptoms or tinnitus. Unfortunately, the patient died from progressive disease 4 months after treatment; therefore further follow-up was impossible.

DISCUSSION

To our knowledge, this is the first patient described in the literature that suffered SNHL including deafness on one side after TCR gene therapy for melanoma.

TCR gene therapy is a relatively novel type of immunotherapy using autologous peripheral blood T cells obtained from the patient through apheresis. These T cells are genetically modified *in vitro* to possess specific TCRs to target antigens expressed on melanoma cells (1,3–5), for example MART-1, which is expressed on 80% of melanoma cells (6). Next, the T cells are expanded and reintroduced into the patient to kill the melanoma. Interestingly, this therapy can be accompanied by SNHL, decreased vision, and skin rash (4,7). These are probably “*off-tumor on-target*” side-effects, because melanocytes with identical antigens can be found in the inner ear, uvea, and epithelium of the skin (8).

The cochlear stria vascularis plays an important role in the cochlear electromechanical transmission of sound (Fig. 2A) (9–12). In the endolymph of the ductus cochlearis a potential of +80 mV is preserved, the so-called endolymphatic potential (EP). The EP is needed for the transmission of mechanical sound to electrical propagation of sound by the hair cells (HCs) (11). Various ion-channels facilitate potassium (K^+)-recycling into the endolymph to maintain the EP (9,11,13,14). Both the basal and marginal cellular layer of the stria vascularis are linked by impermeable tight-junctions that prevent electrochemical communication with adjacent structures (Fig. 2A). Hence, the stria vascularis serves as a blood–labyrinth barrier (BLB) that protects the cochlea from toxic substances and prevents ionic exchange (9,11,15). BLB impairment, among others, causes several forms of SNHL, including noise-induced hearing loss and autoimmune SNHL (9,10,12,14,16–18). The intermediate cells, also known as perivascular macrophage-like melanocytes (PVM/Ms), are essential for BLB function and K^+ -homeostasis (9–16,18,19). We hypothesize that the TCR-modified T cells target these PVM/Ms, because

these melanocytes express melanoma-identical antigens (8). In two trials of Seaman et al. and Johnson et al. half of the 68 patients developed SNHL after TCR gene therapy (4,7). Generally, SNHL recovered completely after topical steroid application, but the role and timing of administration remain unclear. We aim to discuss the potential pathophysiology of SNHL after TCR gene therapy.

First, we think that TCR gene therapy can disrupt the BLB and cochlear K^+ -recycling. Once the reinfused T cells have invaded the stria vascularis, they may target the PVM/Ms. PVM/Ms produce the pigment epithelium-derived factor, which upregulates tight-junction proteins (12,16,18). If TCR gene therapy targets the PVM/Ms, these tight-junctions may be disrupted (Fig. 2B). Subsequent leakage of electrolytes may cause an EP drop and diminished mechano-electrical transduction of sound. Additionally, TCR gene therapy possibly affects cochlear K^+ -transportation. Different ion-transporters regulate K^+ -recycling, including *KCNJ10* expressed by the PVM/Ms (Fig. 2A) (11,13). If the PVM/Ms are being targeted, K^+ -recycling may be hampered and subsequently, insufficient K^+ will be available for the marginal cells to maintain the EP. Severe EP changes may induce HC loss, resulting in permanent SNHL (20). The ability to recover may depend on the duration and/or degree of EP deterioration. Therefore, it is plausible that SNHL after TCR gene therapy may be the result of an interruption of the BLB and K^+ -homeostasis.

Second, it could be that TCR gene therapy causes a (sterile) inflammation of the stria vascularis with cytokine involvement and reactive edema (Fig. 2B). Cytokines may cause HC degeneration, as is observed in neomycin ototoxicity (21), noise-induced SNHL (22), and cytomegalovirus-related SNHL (23). Furthermore, toxic levels of reactive oxygen species are known to induce cochlear cell apoptosis in cisplatin ototoxicity (24,25) and cytomegalovirus-related SNHL (23). Potentially, TCR gene therapy might similarly initiate cochlear cell degeneration by cytokines and reactive oxygen species.

As a result of the above-suggested changes after TCR gene therapy, it may be that endolymphatic hydrop formation takes place, as is for example seen after BLB destruction in guinea pigs (26,27). Leakage of the BLB enables osmotic influx of ions and fluids into the cochlear duct, which elevates the endolymphatic volume. Perhaps, this might have caused a laceration of the Reissner’s membrane with subsequent deafness. Although there is circumstantial evidence that TCR gene therapy causes SNHL by targeting the PVM/Ms, direct evidence for this causality is lacking. Therefore, it would be valuable to study our proposed pathophysiology in, for example, MART-1 knock-out mice.

Interestingly, the pathophysiology of SNHL after TCR gene therapy seems comparable to SNHL in the Vogt–Koyanagi–Harada disease (VKH). In this autoimmune disease, which is initiated by anti-gp100 (28,29) and/or anti-MART-1 (30) antibodies, melanocytes in the epithelium of the skin, uvea, and cochlea are damaged. Remarkably, in both VKH (28) and TCR gene therapy SNHL can progress asymmetrically, while other forms of

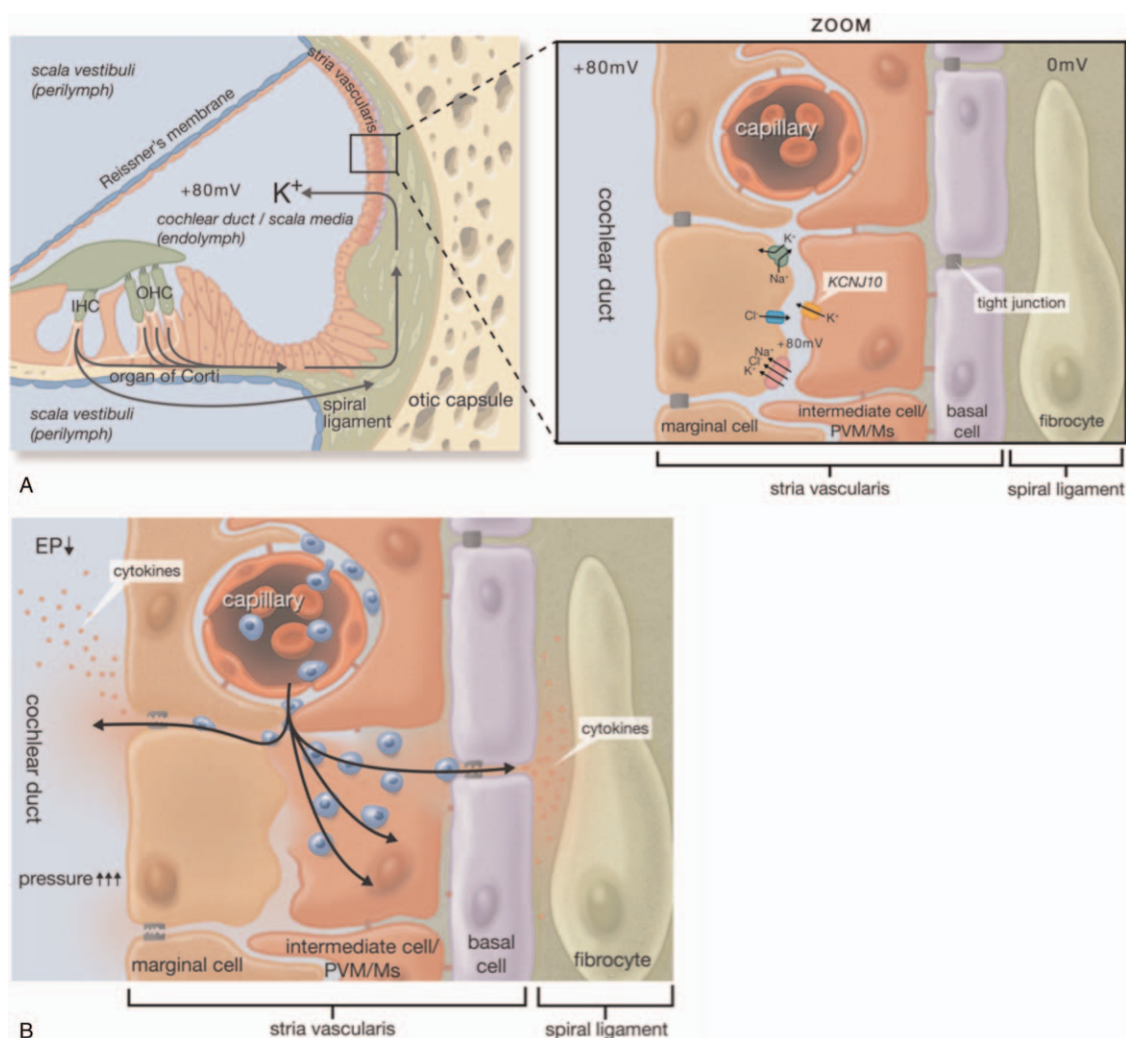


FIG. 2. *A, Left:* a schematic cross-section through the human cochlea, depicting the potassium (K^+) recycling. K^+ is recycled from the organ of Corti's inner and outer hair cells (IHC and OHC) into the spiral ligament and subsequently via the stria vascularis back into the endolymph of the cochlear duct to become available again for the electrochemical transmission of sound. *Right (zoom):* a schematic model of the capillaries and the three types of cells situated in the stria vascularis: the basal cells, the intermediate cells (or PVM/Ms) and the marginal cells. Furthermore, the most important ion-transporters for K^+ -recycling are shown, like the *KCNJ10* transporter located at the PVM/Ms. The tight-junctions play an important role in the function of the blood-labyrinth barrier because they prevent electrochemical communication between the stria vascularis and adjacent structures. *B,* An overview of the proposed hypothetical mechanisms behind the development of hearing loss after T cell receptor gene therapy for melanoma. The T cells may infiltrate the stria vascularis and then recognize and damage the PVM/Ms, potentially resulting in ion- and fluid-leakage of the blood-labyrinth barrier. The tight-junctions may break, resulting in an increased permeability of the stria vascularis. The leakage of ions and fluid may lead to a drop of the endolymphatic potential (EP), edema and/or an elevated pressure in the stria vascularis and cochlear duct. Ultimately, it could be that this results in the formation of endolymphatic hydrops and/or a laceration of the Reissner's membrane. The infiltration of T cells may also be accompanied by an inflammatory response with the involvement of cytokines, which may damage the cochlear structures. PVM/Ms indicates perivascular macrophage-like melanocytes.

ototoxicity generally develop symmetrically (31). It could be that the immunopathology in VKH and TCR gene therapy is site-dependent, resulting in asymmetric hearing changes. In our opinion, the asymmetric aspect of our patient's SNHL and recovery may be another indication of the supposed underlying multifactorial pathophysiology discussed above.

The ability to recover from cochlear inflammation depends on the severity of inflammation (27). Indeed, the occurrence of SNHL after TCR gene therapy seems to

be dose-dependent (7). PVM/Ms are supposedly capable of self-renewal (10,17,32) and subsequent normalization of the homeostasis likely improves hearing capacity. We suggest that our patient developed cochlear damage before the PVM/Ms got the chance to recover. However, the follow-up was relatively short compared with previous studies (4,7). Theoretically, hearing capacity could have improved at a later state. Unfortunately, the patient died of progressive disease after 4 months, leaving no opportunity for repeated audiometry.

Hearing capacity significantly improves after steroid treatment in VKH (29). Accordingly, steroid therapy may prevent potential sterile stria inflammation proposed by us to potentially be caused by TCR gene therapy. In this respect, transtympanic application might be an ideal strategy, as systemic steroids may affect the anticancer effect of the T cells and higher cochlear dosing can be achieved with transtympanic application (33). Following earlier observations that SNHL starts 7 to 10 days after the infusion of T cells (4,7), it may be considered to start steroid application around the time of the infusion of T cells and continue this for 10 days.

In conclusion, there is circumstantial evidence that TCR gene therapy for melanoma targets the PVM/Ms in the stria vascularis, resulting in SNHL. We suggest that SNHL may be caused by a disruption of BLB and the EP and/or a sterile inflammation of the stria vascularis. Hypothetically, endolymphatic hydrops or HC loss may cause irreversible and asymmetric deafness. It would be valuable to test our proposed theories in animal studies.

Acknowledgments: The authors thank P.M. van Brussel for providing the illustration shown in Figure 2.

REFERENCES

- Rohaam MW, Wilgenhof S, Haanen J. Adoptive cellular therapies: The current landscape. *Virchows Arch* 2019;474:449–61.
- June CH, Riddell SR, Schumacher TN. Adoptive cellular therapy: A race to the finish line. *Sci Transl Med* 2015;7:280ps7.
- Merhavi-Shoham E, Itzhaki O, Markel G, Schachter J, Besser MJ. Adoptive cell therapy for metastatic melanoma. *Cancer J* 2017;23:48–53.
- Johnson LA, Morgan RA, Dudley ME, et al. Gene therapy with human and mouse T-cell receptors mediates cancer regression and targets normal tissues expressing cognate antigen. *Blood* 2009;114:535–46.
- Morgan RA, Dudley ME, Wunderlich JR, et al. Cancer regression in patients after transfer of genetically engineered lymphocytes. *Science* 2006;314:126–9.
- Chen YT, Stockert E, Jungbluth A, et al. Serological analysis of Melan-A (MART-1), a melanocyte-specific protein homogeneously expressed in human melanomas. *Proc Natl Acad Sci U S A* 1996;93:5915–9.
- Seaman BJ, Guardiani EA, Brewer CC, et al. Audiovestibular dysfunction associated with adoptive cell immunotherapy for melanoma. *Otolaryngol Head Neck Surg* 2012;147:744–9.
- Plonka PM, Passeron T, Brenner M, et al. What are melanocytes really doing all day long...? *Exp Dermatol* 2009;18:799–819.
- Shi X. Pathophysiology of the cochlear intrastrial fluid-blood barrier (review). *Hear Res* 2016;338:52–63.
- Zhang W, Zheng J, Meng J, Neng L, Chen X, Qin Z. Macrophage migration inhibitory factor mediates viability and apoptosis of PVM/Ms through PI3K/AKT pathway. *Neuroscience* 2017;360:220–9.
- Locher H, de Groot JC, van Iperen L, Huisman MA, Frijns JH, Chuva de Sousa Lopes SM. Development of the stria vascularis and potassium regulation in the human fetal cochlea: Insights into hereditary sensorineural hearing loss. *Dev Neurobiol* 2015;75:1219–40.
- Zhang W, Dai M, Fridberger A, et al. Perivascular-resident macrophage-like melanocytes in the inner ear are essential for the integrity of the intrastrial fluid-blood barrier. *Proc Natl Acad Sci U S A* 2012;109:10388–93.
- Zdebek AA, Wangemann P, Jentsch TJ. Potassium ion movement in the inner ear: Insights from genetic disease and mouse models. *Physiology (Bethesda)* 2009;24:307–16.
- Zhang F, Dai M, Neng L, et al. Perivascular macrophage-like melanocyte responsiveness to acoustic trauma—a salient feature of stria barrier associated hearing loss. *FASEB J* 2013;27:3730–40.
- Ciuman R. Stria vascularis and vestibular dark cells: Characterisation of main structures responsible for inner-ear homeostasis, and their pathophysiological relations. *J Laryngol Otol* 2009;123:151–62.
- Neng L, Zhang F, Kachelmeier A, Shi X. Endothelial cell, pericyte, and perivascular resident macrophage-type melanocyte interactions regulate cochlear intrastrial fluid-blood barrier permeability. *J Assoc Res Otolaryngol* 2013;14:175–85.
- Shi X. Resident macrophages in the cochlear blood-labyrinth barrier and their renewal via migration of bone-marrow-derived cells. *Cell Tissue Res* 2010;342:21–30.
- Yang Y, Dai M, Wilson TM, et al. Na⁺/K⁺-ATPase alpha1 identified as an abundant protein in the blood-labyrinth barrier that plays an essential role in the barrier integrity. *PLoS One* 2011;6:e16547.
- Shi X. Physiopathology of the cochlear microcirculation. *Hear Res* 2011;282:10–24.
- Liu H, Li Y, Chen L, et al. Organ of Corti and Stria Vascularis: Is there an interdependence for survival? *PLoS One* 2016;11:e0168953.
- Sun S, Yu H, Yu H, et al. Inhibition of the activation and recruitment of microglia-like cells protects against neomycin-induced ototoxicity. *Mol Neurobiol* 2015;51:252–67.
- Fujioka M, Kanzaki S, Okano HJ, Masuda M, Ogawa K, Okano H. Proinflammatory cytokines expression in noise-induced damaged cochlea. *J Neurosci Res* 2006;83:575–83.
- Schachtele SJ, Mutnal MB, Schleiss MR, Lokensgard JR. Cytomegalovirus-induced sensorineural hearing loss with persistent cochlear inflammation in neonatal mice. *J Neurovirol* 2011;17:201–11.
- Rybak LP, Whitworth CA, Mukherjee D, Ramkumar V. Mechanisms of cisplatin-induced ototoxicity and prevention. *Hear Res* 2007;226:157–67.
- Brock PR, Knight K, Freyer DR. Platinum-induced ototoxicity in children: A consensus review on mechanisms, predisposition, and protection, including a new international society of pediatric oncology boston ototoxicity scale. *J Clin Oncol* 2012;30:2408–17.
- Ma C, Billings P, Harris JP, Keithley EM. Characterization of an experimentally induced inner ear immune response. *Laryngoscope* 2000;110 (3 pt 1):451–6.
- Bouman H, Klis S, de Groot J, Huizing E, Smoorenburg G, Veldman J. Induction of endolymphatic hydrops in the guinea pig by perisacular deposition of sepharose beads carrying and not carrying immune complexes. *Hear Res* 1998;117:119–30.
- Lavezzo MM, Sakata VM, Morita C, et al. Vogt-Koyanagi-Harada disease: Review of a rare autoimmune disease targeting antigens of melanocytes. *Orphanet J Rare Dis* 2016;11:29.
- Morita S, Nakamaru Y, Obara N, Masuya M, Fukuda S. Characteristics and prognosis of hearing loss associated with Vogt-Koyanagi-Harada disease. *Audiol Neurootol* 2014;19:49–56.
- Sugita S, Sagawa K, Mochizuki M, Shichijo S, Itoh K. Melanocyte lysis by cytotoxic T lymphocytes recognizing the MART-1 melanoma antigen in HLA-A2 patients with Vogt-Koyanagi-Harada disease. *Int Immunol* 1996;8:799–803.
- Schacht J, Talaska AE, Rybak LP. Cisplatin and aminoglycoside antibiotics: hearing loss and its prevention. *Anat Rec (Hoboken)* 2012;295:1837–50.
- Dai M, Yang Y, Omelchenko I, et al. Bone marrow cell recruitment mediated by inducible nitric oxide synthase/stromal cell-derived factor-1alpha signaling repairs the acoustically damaged cochlear blood-labyrinth barrier. *Am J Pathol* 2010;177:3089–99.
- Chandrasekhar SS. Intratympanic dexamethasone for sudden sensorineural hearing loss: Clinical and laboratory evaluation. *Otol Neurotol* 2001;22:18–23.