



Universiteit
Leiden
The Netherlands

Feasibility and safety of intranasally administered mesenchymal stromal cells after perinatal arterial ischaemic stroke in the Netherlands (PASSIoN) a first-in-human, open-label intervention study

Baak, L.M.; Wagenaar, N.; Aa, N.E. van der; Groenendaal, F.; Dudink, J.; Tataranno, M.L.; ... ; Benders, M.J.N.L.

Citation

Baak, L. M., Wagenaar, N., Aa, N. E. van der, Groenendaal, F., Dudink, J., Tataranno, M. L., ... Benders, M. J. N. L. (2022). Feasibility and safety of intranasally administered mesenchymal stromal cells after perinatal arterial ischaemic stroke in the Netherlands (PASSIoN): a first-in-human, open-label intervention study. *The Lancet Neurology*, 21(6), 528-536. doi:10.1016/S1474-4422(22)00117-X

Version: Publisher's Version

License: [Leiden University Non-exclusive license](#)

Downloaded from: <https://hdl.handle.net/1887/3575973>

Note: To cite this publication please use the final published version (if applicable).



Feasibility and safety of intranasally administered mesenchymal stromal cells after perinatal arterial ischaemic stroke in the Netherlands (PASSIoN): a first-in-human, open-label intervention study

Lisanne M Baak*, Nienke Wagenaar*, Niek E van der Aa, Floris Groenendaal, Jeroen Dudink, Maria Luisa Tataranno, Ubah Mahamuud, Cornelia H Verhage, Rian M J C Eijssermans, Liesbeth S Smit, Reint K Jellema, Timo R de Haan, Hendrik J ter Horst, Willem P de Boode, Sylke J Steggerda, Henk-Jan Prins, Colin G de Haar, Linda S de Vries, Frank van Bel, Cobi J Heijnen, Cora H Nijboer†, Manon J N L Benders†

Summary

Lancet Neurol 2022; 21: 528–36

See [Comment](#) page 497

*Co-first authors

†Contributed equally

Department of Neonatology (L M Baak MD, N Wagenaar PhD, N E van der Aa PhD, F Groenendaal PhD, J Dudink PhD, M L Tataranno PhD, U Mahamuud BSc, Prof L S de Vries PhD, Prof F van Bel PhD, Prof M J N L Benders PhD), and Child Development and Exercise Center (C H Verhage, R M J C Eijssermans), and Department for Developmental Origins of Disease (C H Nijboer PhD), University Medical Center, Utrecht Brain Center and Wilhelmina Children's Hospital, Utrecht University, Utrecht, Netherlands; Department of Neurology, Erasmus MC-Sophia Children's Hospital, Rotterdam, Netherlands (L S Smit MD); Department of Neonatology, Maastricht University Medical Center, Maastricht, Netherlands (R K Jellema PhD); Department of Neonatology, Emma Children's Hospital, Academic Medical Center, Amsterdam University Medical Center, Amsterdam, Netherlands (T R de Haan PhD); Department of Neonatology, Beatrix Children's Hospital, University Medical Center Groningen, University of Groningen, Groningen, Netherlands (H J ter Horst PhD); Department of Neonatology, Radboud University Medical Center, Radboud Institute for Health Sciences, Amalia Children's Hospital, Nijmegen, Netherlands (Prof W P de Boode PhD); Department of Neonatology, Willem-Alexander Children's

Background Perinatal arterial ischaemic stroke (PAIS) is an important cause of neurodevelopmental disabilities. In this first-in-human study, we aimed to assess the feasibility and safety of intranasally delivered bone marrow-derived allogeneic mesenchymal stromal cells (MSCs) to treat PAIS in neonates.

Methods In this open-label intervention study in collaboration with all neonatal intensive care units in the Netherlands, we included neonates born at full term (≥ 36 weeks of gestation) with MRI-confirmed PAIS in the middle cerebral artery region. All eligible patients were transferred to the neonatal intensive care unit of the Wilhelmina Children's Hospital. Neonates received one dose of $45\text{--}50 \times 10^6$ bone-marrow derived MSCs intranasally within 7 days of presenting signs of PAIS. The primary endpoints were acute and subacute safety outcomes, including vital signs, blood markers, and the occurrence of toxicity, adverse events, and serious adverse events. The occurrence of unexpected cerebral abnormalities by a repeat MRI at 3 months of age was a secondary endpoint. As part of standard clinical follow-up at Wilhelmina Children's Hospital, we assessed corticospinal tract development on MRI and performed motor assessments at 4 months of age. This study is registered with ClinicalTrials.gov, NCT03356821.

Findings Between Feb 11, 2020, and April 29, 2021, ten neonates were enrolled in the study. Intranasal administration of MSCs was well tolerated in all ten neonates. No serious adverse events were observed. One adverse event was seen: a mild transient fever of 38°C without the need for clinical intervention. Blood inflammation markers (C-reactive protein, procalcitonin, and leukocyte count) were not significantly different pre-administration versus post-administration and, although thrombocyte levels increased ($p=0.011$), all were within the physiological range. Follow-up MRI scans did not show unexpected structural cerebral abnormalities. All ten patients had initial pre-Wallerian changes in the corticospinal tracts, but only four (40%) patients showed asymmetrical corticospinal tracts at follow-up MRI. Abnormal early motor assessment was found in three (30%) infants.

Interpretation This first-in-human study demonstrates that intranasal bone marrow-derived MSC administration in neonates after PAIS is feasible and no serious adverse events were observed in patients followed up until 3 months of age. Future large-scale placebo-controlled studies are needed to determine the therapeutic effect of intranasal MSCs for PAIS.

Funding Netherlands Organization for Health Research and Development (ZonMw).

Copyright © 2022 Published by Elsevier Ltd. All rights reserved.

Introduction

Perinatal arterial ischaemic stroke (PAIS) has an incidence of one in 5000–10000 full-term livebirths^{1,2} and is an important cause of neurodevelopmental disabilities later in life. Depending on the artery involved, lifelong consequences of PAIS occur in 50–75% of patients, which include unilateral spastic cerebral palsy, cognitive dysfunction, epilepsy, visual field deficits, and language deficits.³ Currently, no treatment is available to alleviate the neurological consequences in these infants, which leaves an urgent need to develop novel protective or regenerative therapeutic interventions. Advances made in the past decade in early treatment options for neonates, such as

hypothermia used in perinatal asphyxia,⁴ or thrombolytic therapy used in adult stroke,⁵ are unfortunately not applicable to PAIS. Promising experimental treatment regimens, such as erythropoietin, are currently being assessed in clinical trials, but their efficacy is still unknown.⁶

Mesenchymal stromal cells (MSCs) show neuro-regenerative potential in animal models of hypoxic ischaemic brain injury.⁷ Intranasal administration is a minimally invasive route for MSC delivery. In animal models, this method enabled MSCs to migrate directly into the brain within several hours,⁸ thereby preventing the loss of cells in other organs (such as the liver and

Research in context

Evidence before this study

We searched MEDLINE, Cochrane, and ClinicalTrials.gov for papers published in English, French, or Dutch between database inception and Nov 20, 2021, that reported on the use of mesenchymal stromal cells (MSCs) in neonates. Our search had no restrictions on the type of publication. Our search returned no clinical trials in which MSCs were intranasally administered to neonates. Three clinical trials assessed intratracheal or intraventricular umbilical cord-derived allogeneic MSC therapy in preterm neonates for the indication of bronchopulmonary dysplasia and intraventricular haemorrhage. These trials did not report any deaths, serious adverse events, or dose-limiting toxicities attributable to MSC transplantation.

Added value of this study

To our knowledge, this study provides the first evidence for the feasibility and safety of intranasally administered bone

marrow-derived allogeneic MSCs after perinatal arterial ischaemic stroke in full-term neonates (≥ 36 weeks gestation). Consistent with preclinical research and clinical trials with MSCs in different patient populations, we did not observe any serious adverse events in patients followed up until 3 months of age.

Implications of all the available evidence

Until now, treatment for neonates with perinatal arterial ischaemic stroke has focused on supportive care; however, such care has no long-term protective or curative effect on the brain, leaving the patients with an unmet need for a repair-promoting treatment strategy. This study serves as a starting point for future trials using cell-based therapies for intranasally administered neuroregeneration or tissue repair in neonates. Future large-scale, placebo-controlled studies are needed to determine the therapeutic efficacy of intranasal MSCs.

Hospital, Leiden University Medical Center, Leiden, Netherlands (S J Steggerda PhD); Cell Therapy Facility, Pharmacy Department, University Medical Center Utrecht, Utrecht, Netherlands (H-J Prins PhD, C G de Haar PhD); Department of Symptom Research, Division of Internal Medicine, University of Texas M.D. Anderson Cancer Center, Houston, TX, USA (Prof C J Heijnen PhD)

Correspondence to: Prof Manon J N L Benders, University Medical Centre Utrecht, Wilhelmina Children's Hospital, Utrecht 3508 AB, Netherlands
m.benders@umcutrecht.nl

lungs) after systemic (eg, intravenous) administration.^{9,10} Intranasal application of MSCs, isolated from human or mouse bone marrow, led to substantial neuroregeneration in murine models of ischaemic brain injury, with reduction of infarct size as well as improved long-term motor and cognitive outcomes.^{8,11}

Until now, no clinical trials with intranasally administered MSCs have been conducted in neonates. Three clinical trials were performed with intratracheal or intraventricular allogeneic umbilical cord-derived MSCs in preterm neonates.^{12–14} In these trials, no deaths, serious adverse events, or dose-limiting toxicities were observed. However, clinically significant effects of MSCs on neurodevelopmental outcome up to 2 years of age have not yet been demonstrated. Several clinical trials for adult stroke showed that intravenously delivered autologous bone marrow-derived MSCs improved clinical neurological outcome without any serious adverse events, although efficacy has not been demonstrated in large randomised controlled trials.¹⁵ In sum, MSCs have shown promising neuroregenerative potential in preclinical studies and appear to be safe in human clinical trials.

To the best of our knowledge, the safety of intranasal MSC therapy in neonates has never been assessed. Therefore, in the PASSIoN (Perinatal Arterial Stroke treated with Stromal cells IntraNasally) trial, we aimed to assess for the first time the feasibility and safety of intranasal delivery of allogeneic bone marrow-derived MSCs to treat PAIS.

Methods

Study design and participants

PASSIoN is an open-label, single-arm, nationwide intervention study designed to determine if intranasal MSC treatment in neonates with PAIS is both feasible

and safe. Feasibility was defined as the workability to diagnose, transfer, and treat patients within 7 days after presenting with signs of PAIS, and to restrict the time between MSC preparation and administration to a maximum of 4 h. Safety was assessed by vital signs at the time of treatment, blood sampling before and after MSC treatment, the occurrence of any adverse event or toxicity in the first 3 months after treatment (primary endpoints), and unexpected structural cerebral abnormalities on a follow-up MRI at 3 months (secondary endpoint).

Neonates were eligible for the study if they had been born at one of the ten neonatal intensive care units in the Netherlands and had signs of suspected PAIS (ie, seizures [clinical or subclinical], respiratory difficulties, or both). Clinical seizures refers to visible seizures (ie, the infant has hemiconvulsions of the arm or leg, or both). Subclinical seizures are only visible on an (amplitude-integrated) EEG. All eligible patients were transferred to the neonatal intensive care unit of the Wilhelmina Children's Hospital (part of the University Medical Center, Utrecht, Netherlands) for confirmation of PAIS by MRI, then MSC treatment, within 7 days after presentation. Infants were included consecutively, except during a predefined inclusion pause until the 3-month follow-up MRI scans of the first three included patients had been performed. Inclusion criteria were neonates with a gestational age of at least 36 weeks, written parental consent, and predominantly unilateral PAIS within the area of the middle cerebral artery confirmed by MRI within 7 days after presenting with signs. We only included infants with PAIS that suffered ischaemic injury to the corticospinal tracts, cortex, white matter, and (part of the) basal ganglia. Strokes were classified according to the vascular territories, as described by Govaert and colleagues,¹⁶ in combination with specific anatomical hallmarks, as described by

Wagenaar and colleagues.³ We excluded patients with any proven or suspected major congenital anomaly or chromosomal or metabolic disorder, those with an infection of the CNS, and babies with no realistic prospects of survival (as determined by the infant's clinician).

This study was approved by the Dutch Central Committee on Research Involving Human Subjects. The reporting of the study adhered to the CONSORT statement for pilot studies. The study protocol is available in the appendix (pp 6–67).

See Online for appendix

Procedures

All study procedures were performed at Wilhelmina Children's Hospital. We collected clinical information (pregnancy and labour details, baseline characteristics of the neonate) from patients' hospital charts; these data were obtained during admission to the first neonatal intensive care unit and upon admission to Wilhelmina Children's Hospital. Patients were seen by clinicians after initial admission (after admission to Wilhelmina Children's Hospital) and for at least 4 days after MSC treatment, then again at the age of 3 months when the follow-up MRI was done. In an addition to the study protocol, and as part of routine clinical care at our institution, patients were also evaluated at the age of 4 months—which included an evaluation by a neonatologist who assessed early motor function by General Movements Assessment, Hand Assessment for Infants (HAI), and Hammersmith Infant Neurological Examination (HINE). No additional neuroimaging was performed.

Patients received MSCs (from a healthy 12-year-old male donor) as soon as possible after confirmation of PAIS, but within 7 days after presenting with signs. A description of the production, characterisation, and preparation of allogeneic bone marrow-derived MSCs is available in the appendix (pp 3, 5). Before MSC administration, material was collected from both nostrils of each patient, for bacterial culture. To detect infection or inflammation, blood levels of C-reactive protein and procalcitonin were measured, and a complete blood count was performed, both the day before and the day after MSC administration. 30 min before MSC administration, the nasal cavity was cleaned with saline. During the procedure, the neonate was placed in a supine position with gentle fixation of the head in the midline (appendix p 4). Neonates received one dose of $45\text{--}50 \times 10^6$ MSCs via intranasal droplets (± 0.3 mL per nostril), delivered by a doctor with a small 2-cm catheter attached to a 1.0-mL plastic syringe. The target dose was 50×10^6 MSCs, with a maximal range of 10% allowed to account for inherent variation in the preparation method. After MSC administration, the nose was not suctioned for at least 12 h to allow optimal MSC migration from the nasal cavity.

Adverse events and serious adverse events (treatment-related and otherwise), as described by the Medical

Research Involving Human Subjects Act, were monitored for at least 4 days while the patient remained in the neonatal intensive care unit at the Wilhelmina Children's Hospital. Additionally, vital parameters were measured, comprising clinically significant changes in heart rate (<60 beats per min [bpm] or >160 bpm), oxygen saturation ($<85\%$); blood pressure (below or above the 5th percentile, dependent on gestational age), and body temperature ($<36.0^\circ\text{C}$ or $>38.0^\circ\text{C}$).

MRI was performed within 7 days after presenting with signs of PAIS and repeated at 3 months of age, as part of standard clinical care to improve long-term outcome prediction. All patients were scanned on the same 3.0 Tesla whole-body system, including eight-channel head coil (Achieva; Philips Medical Systems, Best, Netherlands), as previously described.¹⁷ Images included at least axial 3D T1-weighted, T2-weighted imaging (slice thickness: 2 mm without gap), diffusion-weighted imaging (DWI; slice thickness: 3 mm without gap), and magnetic resonance angiography (slice thickness: 1 mm without gap). Both the diagnostic and follow-up MRI scans were reviewed by a paediatric radiologist independently from two experienced neuro-neonatologists (MJNLB and JD). In addition to confirming and classifying the PAIS, we also looked for unexpected structural cerebral abnormalities other than those caused by the stroke (eg, tumour formation or signs of infection).

As a post-hoc investigation, we also assessed structures proven to be predictive for long-term outcome—ie, corticospinal tracts, basal ganglia, and thalami.^{3,18} Structures were considered affected when diffusion restriction was visible on the neonatal DWI (pre-Wallerian degeneration) or when volume loss or asymmetry (as a result of Wallerian degeneration) was visible on T1-weighted or T2-weighted images (or both) at 3-month follow-up. The corticospinal tracts, including the posterior limb of the internal capsule (PLIC) and the cerebral peduncles, were scored as symmetrical, equivocal, or asymmetrical, and the involved part of the PLIC (anterior, posterior, or middle or full) or peduncle (lateral, medial, or middle or full) was specified.³

As routine clinical follow-up at Wilhelmina Children's Hospital, an experienced neonatologist and physiotherapist (RMJCE) evaluated gross motor function at 4 months using the General Movements Assessment. With this test, the quality of general movements was scored according to Einspieler and colleagues,¹⁹ resulting in a score for fidgety movements (either normal, abnormal exaggerated, sporadic, or absent, with an abnormal score defined as sporadic or absent²⁰) and a revised motor optimality score (range 5–28, with an abnormal score defined as ≤ 14).¹⁹ The HINE²¹ and HAI²² were performed to assess symmetry of motor function. The HINE consists of five categories (cranial nerve function, posture, movements, tone, and reflexes and reactions), resulting in a global motor score (range 0–78,

with an abnormal score defined as <63) and a score for the number of asymmetries (abnormal score defined as more than five asymmetries).²³ The HAI, which was performed and scored by a qualified occupational therapist (CHV), as described by Krumlinde-Sundholm and colleagues,²² resulted in an each-hand sum score (range 0–24), a both-hands measure (range 0–100), and an asymmetry index (range 0–100%). An abnormal score on the HAI was defined in two ways: first, as an asymmetry index of at least 9% or a both-hands measure of 44 or lower at 13–14 weeks of age; or second, as an asymmetry index of at least 30% or a both-hands measure of 49 or lower at 15–19 weeks of age.²⁴ Moreover, a side difference of at least 2 points between the each-hand sum score was considered an aberrant score.²⁵

Statistical analysis

Categorical data are presented as numbers and percentages, and continuous variables are presented as medians and IQRs. All vital sign and blood parameters at baseline and 24 h after MSC administration were compared using Wilcoxon signed-rank tests; Z scores were calculated, and a p value of less than 0.05 was considered significant. MRI characteristics were expressed in percentages and analysed qualitatively.

Data were analysed using R Studio Desktop, version 1.4.1717 (RStudio, Boston, MA, USA), and SPSS Statistics, version 26.0 (IBM, Armonk, NY, USA). PASSIoN is registered with ClinicalTrials.gov, NCT03356821.

Role of the funding source

The funder of the study had no role in study design, data collection, data analysis, data interpretation, or writing of the report.

Results

Between Feb 11, 2020, and April 29, 2021, 24 patients were eligible for the study, of whom 14 neonates were excluded. Ten did not meet inclusion criteria, two could not be included because they became eligible during the predefined pause in enrolment while waiting for follow-up MRI scans of the first three included patients, and two parents declined to provide their consent. Following MSC administration, one patient was found to have microcephaly and minor facial dysmorphisms. Assessment by the clinical geneticist raised no suspicion for a syndrome, and the SNP array was normal. The clinical characteristics of the ten included neonates are shown in table 1, and the appendix (p 1) contains an overview of the clinical and MRI characteristics per patient. Six neonates had a complicated delivery; three were delivered by emergency caesarean section due to fetal distress and three, delivered vaginally, had low Apgar scores combined with the need for mechanical ventilation. All patients had low Thompson scores and were, therefore, not eligible for therapeutic hypothermia. Nine patients presented

with clinical seizures, with six patients also presenting with a respiratory incident or apnoea, at a median of 13 h (IQR 12–22) after birth; and the tenth patient (patient 3) had only subclinical seizures. All ten patients received anti-seizure medication, with seven (70%) patients needing more than two anti-seizure medications to control seizures.

In all ten cases, it was feasible to transfer children to the Wilhelmina Children's Hospital to repeat the MRI scan within 7 days of presenting with signs of PAIS, and to keep the time between preparation and administration of MSCs within 4 h. Neonates received intranasal administration of MSCs at a median age of 6.1 days (IQR 5.4–6.6). A dose of 50×10^6 cells (one patient received 45×10^6 cells) was administered in a median volume of 656 μL (IQR 623–706). Four patients sneezed during or shortly after administration without nasal discharge.

We did not observe any serious adverse events or signs of toxicity after treatment and during the 3 month follow-up period. One adverse event was reported in patient 8, who developed a fever of 38 °C 1 h after MSC administration

Patients (n=10)	
Sex	
Male	4 (40%)
Female	6 (60%)
Gestational age, weeks	40.3 (39.9–41.1)
Birthweight, g	3415 (3140–3834)
Delivery mode	
Vaginal	7 (70%)
Emergency caesarean	3 (30%)
Apgar score at 1 min	6 (4–8)
Apgar score at 5 min	8 (6–8)
Resuscitation or support at delivery	6 (60%)
Meconium-stained fluid	4 (40%)
Presenting symptoms	
Clinical seizures	9 (90%)
Respiratory incident or apnoea*	6 (60%)
Age at onset of symptoms, h	13 (12–22)
Use of at least two anti-seizure medications	7 (70%)
Lesion side	
Left	6 (60%)
Right	2 (20%)
Bilateral stroke	2 (20%)
Stroke territory	
Anterior branch MCA	1 (10%)
Main MCA	1 (10%)
Middle branch MCA	4 (40%)
Posterior branch MCA	3 (30%)
Cortical stroke in MCA territory	1 (10%)

Data are n (%) or median (IQR). MCA=middle cerebral artery. *Hypoventilation or unexplained decrease in oxygen saturation.

Table 1: Baseline characteristics of the study population

	Pre-treatment	Post-treatment	Z score*	p value*
C-reactive protein, mg/L	0.50 (0.5–3.8)	0.75 (0.5–3.8)	0	1.0
Procalcitonin, µg/L	0.10 (0.08–0.18)	0.10 (0.08–0.13)	-1.69	0.09
Leukocytes, 10 ⁹ cells per L	10.7 (9.8–11.3)	10.1 (9.2–11.1)	-1.02	0.31
Haemoglobin, mmol/L	10.9 (10.2–11.6)	10.7 (9.4–10.8)	-1.99	0.07
Thrombocytes, 10 ⁹ cells per L	255.5 (213.8–325.0)	309.0 (269.3–358.0)	-2.61	0.011

Data are median (IQR). *Calculated by a Wilcoxon signed rank test for pairwise comparison.

Table 2: Blood infection markers before and after treatment with mesenchymal stromal cells

	Neonatal MRI (n=10)	Follow-up MRI (n=10)
Age, days	4 (3–5)	88 (84–95)
Perirolandic area	7 (70%)	5 (50%)
ALIC	4 (40%)	3 (30%)
PLIC	10 (100%)	4 (40%)
Middle or full PLIC	6 (60%)	..
Posterior PLIC	4 (40%)	..
Peduncle	8 (80%)	1 (10%)
Lateral peduncle	6 (60%)	..
Middle or full peduncle	2 (20%)	..
Basal ganglia	5 (50%)	5 (50%)
Thalamus	8 (80%)	4 (40%)
Additional injury	8 (80%)	5 (50%)

Data are n (%) or median (IQR). ALIC=anterior limb of the internal capsule. PLIC=posterior limb of the internal capsule.

Table 3: Characterisation of areas and structures damaged on neonatal and follow-up MRI scans

that resolved spontaneously after 2 h, without clinical signs of distress or illness, and other vital parameters stayed within normal ranges. Except for patient 8, we did not observe in any patients fever, hypotension, hypertension, bradycardia, tachycardia, or hypoxia during hospital stay, or any illness in the first 3 months of life. Blood inflammation markers (C-reactive protein, procalcitonin, and leukocyte count) were all within normal ranges and did not differ between pre-administration and post-administration (table 2). Thrombocyte levels increased significantly (Z score -2.61 , $p=0.011$) after MSC administration but were within physiological ranges for all patients; only patient 6 had thrombocytopenia before MSC administration. The bacterial cultures of the nostrils of three patients (patients 1, 4, and 7) showed colonisation with *Staphylococcus aureus* before administration.

MRI scans done at Wilhelmina Children's Hospital were performed within 7 days of birth (table 3),

corresponding to a median of 3.8 days (IQR 2.7–5.3) after the onset of signs of PAIS. When a patient underwent an MRI scan at the referring hospital, MRI scans were repeated at the study site before MSC administration to secure comparability with the follow-up MRI, and between patients. Most patients had a stroke in the left hemisphere ($n=6$, 60%; table 1), and stroke territory mainly involved the middle or posterior branch of the middle cerebral artery (figure). Two patients had bilateral strokes: patient 1 had an additional stroke in the left ACA region, and patient 8 had an additional small cortical right middle cerebral artery stroke, and a left cerebellar stroke (anterior inferior cerebellar artery). Additional brain injury was common ($n=8$), including additional focal ischaemic lesions ($n=7$) or watershed injury ($n=3$). Magnetic resonance angiography done in one patient (patient 1) showed thrombosis in a major cerebral artery. All ten patients showed pre-Wallerian degeneration of the corticospinal tracts on neonatal DWI, six of whom had involvement of the middle part of the PLIC or peduncle (or both).

At the 3-month follow-up MRI scan, at a median age of 88 (IQR 84–95) days, there were no unexpected structural cerebral abnormalities, such as signs of infections, tumour formation, or haemorrhages. Five (50%) patients had brain injuries additional to the stroke, including enlarged ventricles indicative of brain volume loss ($n=2$), global brain volume loss ($n=1$), volume loss in watershed areas ($n=1$), or asymmetrical myelination of the optic radiation ($n=1$). Four (40%) patients showed asymmetrical myelination of the PLIC, and one patient showed an asymmetrical volume of the cerebral peduncle. Of the four neonates that sneezed during MSC administration, three had symmetrical corticospinal tracts. Gliosis or volume asymmetry of the basal ganglia or thalamus was present in five (50%) and four (40%) patients, respectively.

At 4 months, patients' motor function was assessed (median age 18 weeks [IQR 14⁶–18⁴]; table 4). HINE could not be done for patient 4, nor could the General Movements Assessment for patient 5, due to logistical problems. Three patients had one or more abnormal test scores, according to reference values (patients 1, 5, and 8). On the General Movements Assessment, patients 1 and 8 had sporadic and absent fidgety movements, respectively, and had a revised motor optimality score below 14. Patients 1 and 5 demonstrated multiple motor asymmetries in the HINE assessment. On the HAI, patient 1 showed marked asymmetry in hand movements, whereas patients 5 and 8 demonstrated mild asymmetry of hand movements with an absolute difference of three points between hands. Patient 4 showed decreased movements of both hands during the HAI assessment; however, the observer rated the testing circumstances as suboptimal, therefore this result might not be reliable.

Discussion

The first-in-human PASSIoN trial demonstrated short-term feasibility and safety of intranasal MSC administration for term neonates with PAIS. No serious adverse events were observed up to 3 months after intranasal MSC administration. Only one patient had a mild transient fever shortly after administration, an adverse event that has also been described in adults who received intravenous bone marrow-derived MSCs.¹⁵ No signs of infection or inflammatory reactions to MSC administration were recorded, as measured by vital sign parameters or blood markers. We did observe a significant increase in platelet counts after MSC administration, although levels were within the physiological range. This increase was probably caused by the expected developmental increase in the number of platelets during the first 2 weeks after birth.²⁶ Furthermore, two patients with low thrombocyte levels before MSC administration recovered to the normal range during the following days. Although probably not of direct clinical importance, we recommend assessing thrombocyte levels in future MSC trials in neonates.

No unexpected structural cerebral abnormalities were observed on the repeat MRI at 3-month follow-up. In animal studies, MSCs have been shown to be short-lived and are almost undetectable in the brain 3 days after (intranasal) administration.²⁷ Several studies have shown that intranasally administered allogeneic MSCs will not survive or integrate into the brain, and hence will not lead to long-term adverse events.⁷ Long-term safety of MSC treatment has been shown by animal pathology studies,^{7,28} and clinical studies in patients with stroke¹⁵ have not demonstrated any long-term adverse effects (up to 4 years). We plan to monitor our patients at regular timepoints in our follow-up programmes, using a nationally standardised protocol for cognitive and motor development until at least 2 years of age.²⁹ We conclude from our results that intranasal MSC administration is feasible within 7 days after presentation with signs of PAIS, and that MSC treatment is safe as assessed during the first 3 months of life.

In experimental models, hypoxic ischaemic brain injury has been shown to induce changes in the neurovascular environment that activate neurogenesis; however, such changes are not sufficient to restore lost brain tissue.¹¹ We hypothesised that the neuroregenerative effects of MSCs after ischaemic brain damage, as seen in animal models, mainly rely on the reduction of

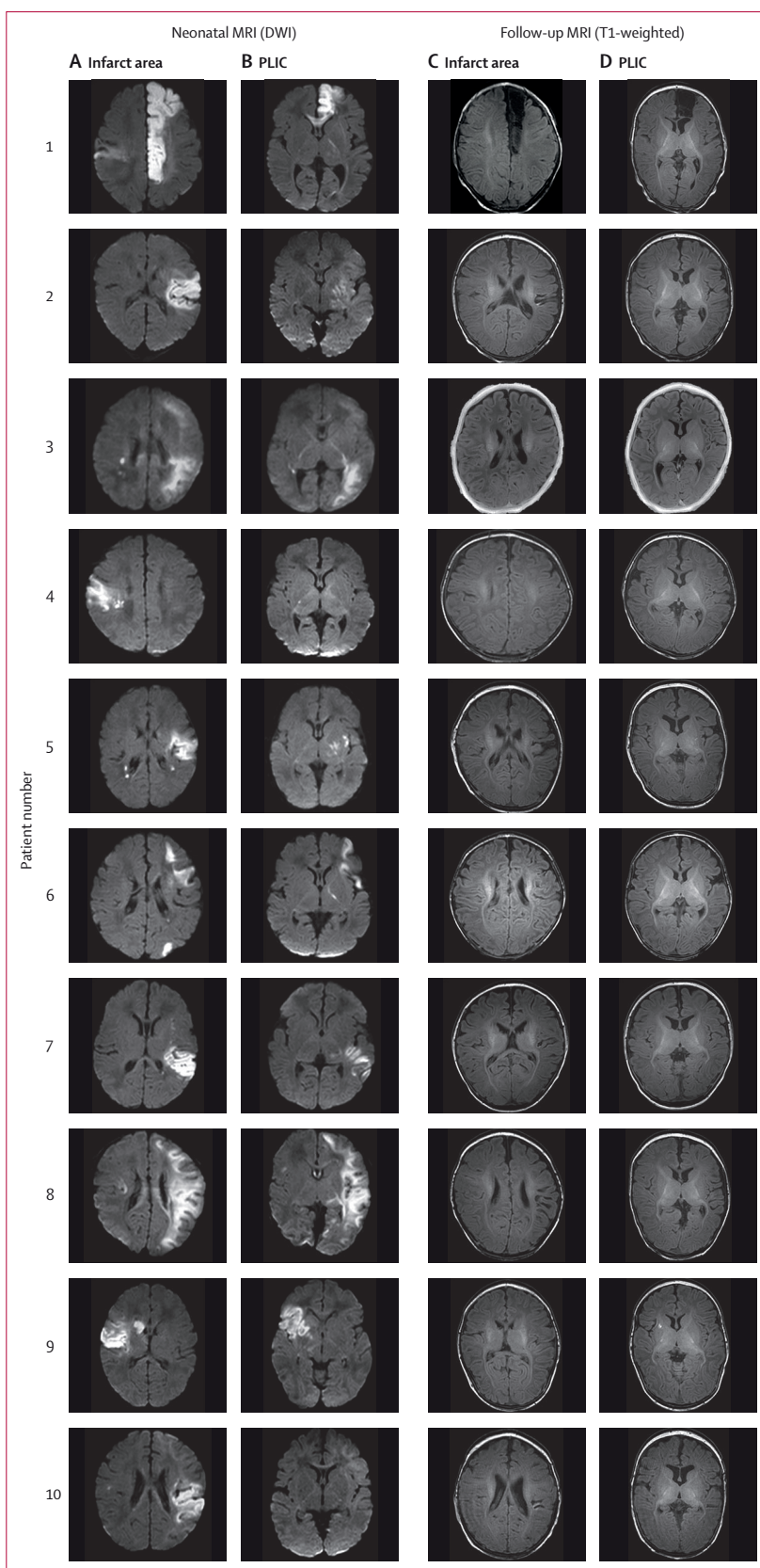


Figure: Axial neonatal and follow-up MRI scans of all treated patients

Neonatal MRI scans were performed within 7 days of presentation of signs of PAIS, before MSC administration. Follow-up MRI scans were performed at around 3 months of age. Neonatal diffusion-weighted MRI showing the largest infarcted area (A), neonatal diffusion-weighted MRI at the level of the PLIC (B), follow-up T1-weighted MRI at the level of the largest infarcted area (C), follow-up T1-weighted MRI at the level of the PLIC (D). DWI=diffusion-weighted imaging. PLIC=posterior limb of the internal capsule.

	Post-term age, weeks	General Movements Assessment		Hand Assessment for Infants				Hammersmith Infant Neurological Examination	
		Fidgety movements	MOS-R	Ipsilesional EaHS	Contralesional EaHS	Both-hands measure	Asymmetry index (%)	Score	Number of asymmetries
1	14 ³	Sporadic*	10*	10	7*	32*	30*	54	4
2	13 ⁶	Normal	22	14	14	47	0	61	0
3	11 ¹	Normal	26	15	16	52	6	60	0
4	19 ⁴	Normal	24	12	11	40*†	8	NP	NP
5	20 ¹	NP	NP	21	18*	60	14	65	5
6	18 ¹	Normal	22	20	20	61	0	68	0
7	18 ⁴	Normal	28	17	18	54	6	66.5	0
8	19 ³	Absent*‡	13*	21	18*	66	14	66.5	1
9	18	Normal§	28	20	18	59	10	69.5	1
10	18 ¹	Abnormal¶ exaggerated¶¶	18	18	18	58	0	67.5	1
Total	18 (14 ⁶ –18 ¹⁴)	NA	22 (18–26)	18 (14–20)	18 (15–18)	56 (48–60)	7 (2–13)	67 (61–68)	1 (0–1)

The bottom row specifies median (IQR) for the infants as a group, when possible. Post-term age is given in weeks, with the number of additional days superscripted. MOS-R=Motor Optimality Score-Revised. EaHS=each hand sum score. HINE=Hammersmith Infant Neurological Examination. NP=not performed. NA=not applicable. *Abnormal test scores according to reference values in literature. †Suboptimal testing circumstances. ‡Assessed at 12⁵ weeks. §Sporadic but age-adequate fidgety movements. ¶Assessed at 14⁶ weeks.

Table 4: Motor assessments at 4 months of age for all ten infants, by patient number

inflammation after ischaemic damage, and the stimulation of endogenous repair mechanisms.¹¹ Such stimulation is thought to be mediated by paracrine effects of MSCs, which change the cerebral growth factor milieu into an environment that promotes repair, thereby boosting endogenous neural stem cells to proliferate and differentiate into new brain tissue.²⁷ We based the dose of MSCs used in our study on the mean body mass and brain volume of human neonates versus neonatal mice. The human dose—equivalent to the lowest effective dose in a mouse model of ischaemic brain injury (0.5–1.0×10⁶ cells per mouse)—was calculated as 50×10⁶ MSCs per patient,^{8,11,27,30} without an additive effect of multiple dosages over a single dose.⁸ Preclinical studies have also shown that intranasally administered MSCs migrate specifically to the affected hemisphere when administered up to 10 days, but not 17 days, after the insult. A loss of chemotactic signals in the lesion site might impair migration of MSCs from the nasal cavity after this time window.⁸ Therefore, we decided to treat patients within 7 days after presentation of signs of PAIS. Once their therapeutic effects are confirmed, we aim to optimise the dosing and timing of MSC treatment in future clinical studies. Moreover, we aim to use advanced imaging techniques (such as such as diffusion tensor imaging and connectivity analyses) to assess the effect of MSC administration on myelination, network formation, and functional reorganisation and, most importantly, on functional developmental outcome.

Both umbilical cord-derived (either allogeneic or autologous) and bone marrow-derived MSCs are under investigation for their neuroregenerative potential. Since comparative studies are absent, statements about

superiority of one type of MSC over another cannot be made at this point. In our current study, we administered allogeneic bone marrow-derived MSCs since we have the most experience with this type of MSC from our experimental studies, and we could ensure a readily available (ie, off-the-shelf) supply of MSCs of high quality. Biobanks with allogeneic umbilical cord-derived MSCs were not available for our study population and autologous umbilical cord-derived MSCs could not be cultivated to provide sufficient doses within our 7-day time window.

Although other groups have reported different administration routes for umbilical cord-derived MSCs for other forms of perinatal brain damage,^{14,31,32} PASSIoN is the first study to report on intranasal MSC administration in humans. Intranasally administered MSCs are thought to migrate from the nasal cavity to the brain lesion via the cribriform plate, followed by several possible routes into the brain parenchyma (eg, CSF, meningeal circulation, the rostral migratory stream, and trigeminal nerve) under the influence of chemokines produced by the lesion site, such as SDF1 and CXCL10.^{9,30} Intranasal administration of MSCs is a minimally invasive way to deliver the cells rapidly to damaged brain areas within several hours, and it prevents loss of MSCs in other peripheral organs, as has been seen after systemic (eg, intravenous) administration.^{8–10} This approach makes intranasal application a promising non-invasive strategy to treat neonates with various types of perinatal brain injury. The intranasal route has also been shown to be an effective way to deliver stem cells to the brain in several animal models of CNS diseases.¹⁰ Studies are currently underway to further map the distribution and homing of intranasally administered MSCs in the ischaemic brain.

For example, Vaes and colleagues showed that the distribution of intranasally delivered MSCs was low in off-target organs compared with cerebral delivery in a mouse model of preterm brain injury.³³

Until now, treatment for neonates with PAIS has mainly focused on supportive care, but this care has no long-term protective or curative effect on the brain, leaving patients with an unmet need for a repair-promoting treatment strategy. Since neuroprotective strategies such as whole-body cooling are currently not feasible after PAIS due to the restricted time window for effectiveness of several hours after an hypoxic ischaemic insult, the therapeutic focus has been on interventions that stimulate repair (eg, erythropoietin).⁶ Additional to the study protocol, we assessed damage to the corticospinal tracts on MRI and performed early motor assessments. On neonatal DWI done before MSC treatment, pre-Wallerian degeneration at the level of the PLIC or cerebral peduncle (or both) was visible in all ten patients, including six who had involvement of the middle part of the PLIC. However, six (60%) patients had a symmetrical PLIC or peduncle at follow-up MRI at 3 months, including three of the four neonates who sneezed during MSC administration. Two studies previously noted that, at follow-up imaging (done at 3 months to 6·5 years), 0–38% of patients showed a symmetrical corticospinal tract on MRI after abnormalities were noted in the corticospinal tracts on neonatal DWI.^{18,34} Wallerian degeneration is strongly associated with the development of motor disabilities in later life.^{18,35} In our study, all patients with asymmetry in motor function during early motor assessments had follow-up MRI scans at 3 months that showed Wallerian degeneration of the corticospinal tracts. Because our study only assessed feasibility and safety of MSC treatment, we could not measure efficacy of this therapeutic strategy. Further studies are needed to investigate the possible efficacy of MSC therapy for motor disabilities after PAIS. In particular, placebo-controlled studies with longer follow-up periods than reported here are needed to assess the efficacy of intranasal MSC therapy. We aim to describe the long-term neuroregenerative and functional effects of MSC therapy in a future randomised placebo-controlled trial.

PASSIoN has several limitations. First, our study assessed the proof-of-principle of MSC treatment in only ten patients, without a control group, and we reported follow-up assessments up to 4 months of age. Therefore, we cannot exclude the occurrence of rare or late adverse events or make any conclusions on efficacy. Second, we could not assess distribution and homing of the intranasally administered MSCs in the neonates—as we have done in preclinical studies—and are, therefore, not able to make any statement about the migration of MSCs to the infarcted area. Finally, we did not perform any quantitative analysis of brain volume or white matter tracts; these measures will be necessary to describe efficacy of MSC treatment in future trials.

The PASSIoN trial was designed to make a first step towards clinical application of MSC therapy to treat PAIS. We have provided the first evidence for the feasibility and safety of bone marrow-derived allogeneic MSCs to treat brain damage in neonates. Regarding safety, no serious adverse events were observed in our ten patients, who were followed up for safety outcomes until the age of 3 months. Future studies should determine the therapeutic effect of intranasal MSCs on cerebral and neurodevelopmental outcomes, working towards development of a new treatment for this vulnerable group of patients to ultimately improve their quality of life.

Contributors

LMB and NW performed the investigation, handled project administration, analysed the data, and wrote the original draft of the manuscript. NEvdA, FG, JD, M-LT, CHV, RMJCE, LSS, RKJ, TRdH, HJtH, WPdB, and SJS performed the investigation. UM aided with project administration. H-JP and CGdH conceptualised the study, performed preclinical investigations, and provided resources by means of preparation of the MSC product and validation of the production process. LSdV, FvB, CJH, CHN, and MJNLB acquired funding, conceptualised the study, and supervised the work LMB and NW accessed and verified the underlying data. All authors reviewed and edited the manuscript, had full access to all the data in the study, and accept responsibility for the decision to submit for publication.

Declaration of interests

We declare no competing interests.

Data sharing

Data collected for the study cannot be made available for others, since the parents of study participants did not give consent to share data with other parties. Study details can be found on ClinicalTrials.gov, and the study protocol is available in the appendix (pp 6–67).

Acknowledgments

This study was supported by the Netherlands Organization for Health Research and Development (ZonMw), the Netherlands (TAS Research Grant 11600200). We thank A F Bos for his expertise and assistance on the scoring of the General Movements Assessment.

References

- Gale C, Statnikov Y, Jawad S, Uthaya SN, Modi N. Neonatal brain injuries in England: population-based incidence derived from routinely recorded clinical data held in the National Neonatal Research Database. *Arch Dis Child Fetal Neonatal Ed* 2018; **103**: F301–06.
- Sorg AL, von Kries R, Klemme M, Gerstl L, Felderhoff-Müser U, Dziętko M. Incidence estimates of perinatal arterial ischemic stroke in preterm- and term-born infants: a national capture-recapture calculation corrected surveillance study. *Neonatology* 2021; **118**: 727–33.
- Wagenaar N, Martinez-Biarge M, van der Aa NE, et al. Neurodevelopment after perinatal arterial ischemic stroke. *Pediatrics* 2018; **142**: e20174164.
- Jacobs SE, Berg M, Hunt R, Tarnow-Mordi WO, Inder TE, Davis PG. Cooling for newborns with hypoxic ischaemic encephalopathy. *Cochrane Database Syst Rev* 2013; **2013**: CD003311.
- Wardlaw JM, Murray V, Berge E, del Zoppo GJ. Thrombolysis for acute ischaemic stroke. *Cochrane Database Syst Rev* 2014; **2014**: CD000213.
- Benders MJ, van der Aa NE, Roks M, et al. Feasibility and safety of erythropoietin for neuroprotection after perinatal arterial ischemic stroke. *J Pediatr* 2014; **164**: 481–86.
- Wagenaar N, Nijboer CH, van Bel F. Repair of neonatal brain injury: bringing stem cell-based therapy into clinical practice. *Dev Med Child Neurol* 2017; **59**: 997–1003.
- Donega V, van Velthoven CTJ, Nijboer CH, et al. Intranasal mesenchymal stem cell treatment for neonatal brain damage: long-term cognitive and sensorimotor improvement. *PLoS One* 2013; **8**: e51253.

- 9 Danielyan L, Schäfer R, von Arnim-Mayerhofer A, et al. Intranasal delivery of cells to the brain. *Eur J Cell Biol* 2009; **88**: 315–24.
- 10 Li YH, Feng L, Zhang GX, Ma CG. Intranasal delivery of stem cells as therapy for central nervous system disease. *Exp Mol Pathol* 2015; **98**: 145–51.
- 11 Donega V, Nijboer CH, Braccioli L, et al. Intranasal administration of human MSC for ischemic brain injury in the mouse: in vitro and in vivo neuroregenerative functions. *PLoS One* 2014; **9**: e112339.
- 12 Ahn SY, Chang YS, Kim JH, Sung SI, Park WS. Two-year follow-up outcomes of premature infants enrolled in the phase I trial of mesenchymal stem cells transplantation for bronchopulmonary dysplasia. *J Pediatr* 2017; **185**: 49–54.
- 13 Ahn SY, Chang YS, Lee MH, et al. Stem cells for bronchopulmonary dysplasia in preterm infants: a randomized controlled phase II trial. *Stem Cells Transl Med* 2021; **10**: 1129–37.
- 14 Ahn SY, Chang YS, Sung SI, Park WS. Mesenchymal stem cells for severe intraventricular haemorrhage in preterm infants: phase I dose-escalation clinical trial. *Stem Cells Transl Med* 2018; **7**: 847–56.
- 15 Lalu MM, Montroy J, Dowlathshahi D, et al. From the lab to patients: a systematic review and meta-analysis of mesenchymal stem cell therapy for stroke. *Transl Stroke Res* 2020; **11**: 345–64.
- 16 Govaert P. Sonographic stroke templates. *Semin Fetal Neonatal Med* 2009; **14**: 284–98.
- 17 Kersbergen KJ, Leemans A, Groenendaal F, et al. Microstructural brain development between 30 and 40 weeks corrected age in a longitudinal cohort of extremely preterm infants. *Neuroimage* 2014; **103**: 214–24.
- 18 De Vries LS, Van der Grond J, Van Haastert IC, Groenendaal F. Prediction of outcome in new-born infants with arterial ischaemic stroke using diffusion-weighted magnetic resonance imaging. *Neuropediatrics* 2005; **36**: 12–20.
- 19 Einspieler C, Bos AF, Krieger-Tomantschger M, et al. Cerebral palsy: early markers of clinical phenotype and functional outcome. *J Clin Med* 2019; **8**: 1616.
- 20 Einspieler C, Peharz R, Marschik PB. Fidgety movements—tiny in appearance, but huge in impact. *J Pediatr (Rio J)* 2016; **92** (suppl 1): S64–70.
- 21 Haataja L, Mercuri E, Regev R, et al. Optimality score for the neurologic examination of the infant at 12 and 18 months of age. *J Pediatr* 1999; **135**: 153–61.
- 22 Krumlinde-Sundholm L, Ek L, Sicola E, et al. Development of the Hand Assessment for Infants: evidence of internal scale validity. *Dev Med Child Neurol* 2017; **59**: 1276–83.
- 23 Hay K, Nelin M, Carey H, Chorna O, Moore-Clingenpeel Ma Mas M, Maitre N. Hammersmith Infant Neurological Examination Asymmetry Score distinguishes hemiplegic cerebral palsy from typical development. *Pediatr Neurol* 2018; **87**: 70–74.
- 24 Ryll UC, Krumlinde-Sundholm L, Verhage CH, et al. Predictive validity of the Hand Assessment for Infants in infants at risk of unilateral cerebral palsy. *Dev Med Child Neurol* 2021; **63**: 436–43.
- 25 Ek L, Eliasson AC, Sicola E, et al. Hand Assessment for Infants: normative reference values. *Dev Med Child Neurol* 2019; **61**: 1087–92.
- 26 Wiedmeier SE, Henry E, Sola-Visner MC, Christensen RD. Platelet reference ranges for neonates, defined using data from over 47,000 patients in a multihospital healthcare system. *J Perinatol* 2009; **29**: 130–36.
- 27 Donega V, Nijboer CH, van Tilborg G, Dijkhuizen RM, Kavelaars A, Heijnen CJ. Intranasally administered mesenchymal stem cells promote a regenerative niche for repair of neonatal ischemic brain injury. *Exp Neurol* 2014; **261**: 53–64.
- 28 Donega V, Nijboer CH, van Velthoven CTJ, et al. Assessment of long-term safety and efficacy of intranasal mesenchymal stem cell treatment for neonatal brain injury in the mouse. *Pediatr Res* 2015; **78**: 520–26.
- 29 Rijken M; The National Working Group for Neonatal Follow-up (NL). Guidelines for national neonatal follow-up (Aanbeveling landelijke neonatale follow-up). Jan 1, 2015. <https://www.nvk.nl/themas/kwaliteit/richtlijnen/richtlijn?componentid=5537794&tagtitel=Intensive+Care,Neonatologie> (accessed April 21, 2022).
- 30 van Velthoven CTJ, Kavelaars A, van Bel F, Heijnen CJ. Nasal administration of stem cells: a promising novel route to treat neonatal ischemic brain damage. *Pediatr Res* 2010; **68**: 419–22.
- 31 Cotten CM, Murtha AP, Goldberg RN, et al. Feasibility of autologous cord blood cells for infants with hypoxic-ischemic encephalopathy. *J Pediatr* 2014; **164**: 973–979.e1.
- 32 Tsuji M, Sawada M, Watabe S, et al. Autologous cord blood cell therapy for neonatal hypoxic-ischaemic encephalopathy: a pilot study for feasibility and safety. *Sci Rep* 2020; **10**: 4603.
- 33 Vaes JEG, van Kammen CM, Trayford C, et al. Intranasal mesenchymal stem cell therapy to boost myelination after encephalopathy of prematurity. *Glia* 2021; **69**: 655–80.
- 34 Domi T, deVeber G, Shroff M, Kouzmitcheva E, MacGregor DL, Kirton A. Corticospinal tract pre-wallerian degeneration: a novel outcome predictor for pediatric stroke on acute MRI. *Stroke* 2009; **40**: 780–87.
- 35 Kirton A, Shroff M, Visvanathan T, deVeber G. Quantified corticospinal tract diffusion restriction predicts neonatal stroke outcome. *Stroke* 2007; **38**: 974–80.