

Neridronate in bone marrow edema syndrome. Efficacy and safety of two therapeutic regimens

Alfredomaria Lurati,¹ Antonella Laria,¹ Paola Faggioli,² Antonio Tamburello,² Laura Castelnovo,² Antonino Mazzone²

¹Rheumatology Unit, Fornaroli Hospital, Magenta (MI); ²Internal Medicine Unit, Legnano Hospital, Legnano (MI), Italy

Abstract

The bone marrow edema syndrome (BMES) is a severely disabling pain syndrome without a definite treatment and refers to transient clinical conditions with unknown pathogenic mechanism, such as transient osteoporosis of the hip, regional migratory osteoporosis, and reflex sympathetic dystrophy. Magnetic resonance imaging is used for early diagnosis and monitoring of its progression. Early differentiation from other aggressive conditions with long-term sequelae is essential in order to avoid unnecessary treatment. The aim of this monocentric trial was to test the efficacy and the safety of amino-bisphosphonate neridronate administered in two different regimens in patients with BMES.

192 patients with BMES secondary to osteoarthritis localized in the knee, hip, wrist or foot were randomly assigned to intravenous (iv) infusion of 100 mg neridronate given four times over

10 days (Group A, 72 subjects) or alternatively to iv infusions of 100 mg every 21 days over 3 months (Group B, 120 subjects). Magnetic resonance image (MRI) was performed at baseline and after 180 days. We assessed a 0-100 mm pain visual analogue scale (VAS) in each patient, too. Outcomes were MRI changes and VAS changes. A control group (35 patients) was enrolled too, treated conservatively with non-steroidal anti-inflammatory drugs and articular rest.

We observed a significant improvement in MRI with the resolution of bone marrow lesions present at the baseline ($P < 0.01$), without a significant difference between Group A and Group B. The VAS score decreased significantly during the study in both groups ($P < 0.05$) without a significant difference between the two treatment groups ($P > 0.1$). Both groups showed a significant clinical and radiologic improvement compared with the control group ($P < 0.001$).

In patients with BMES, the infusions of neridronate 100 mg every 21 days over 3 months or alternately every 3 days over 10 days were associated with clinically relevant and persistent benefits without significant differences between the two treatment schedules. These results provide conclusive evidence that the use of bisphosphonates, at appropriate doses, is the treatment of choice in BMES.

Correspondence: Alfredomaria Lurati, Rheumatology Unit, Fornaroli Hospital, via Donatore Sangue 50, 20013 Magenta (MI), Italy.
E-mail: alfredomaria.lurati@pec.it; alfredomaria.lurati@asst-ovestmi.it

Key words: Bone marrow edema; neridronate.

Contributions: each author participated in data collection, data analysis and the final draft of the article.

Conflict of interest: A. Lurati received a grant from Sanofi-Aventis in 2020. The remaining authors have no conflicts of interest.

Availability of data and materials: data available on request due to privacy/ethical restrictions.

Ethics approval and consent to participate: this study was conducted in accordance with the ethics principles of the Declaration of Helsinki and was approved by the local research ethics committees. All patients signed informed consent to the treatment.

Received for publication: 24 December 2019.
Accepted for publication: 26 May 2020.

©Copyright: the Author(s), 2020
Licensee PAGEPress, Italy
Beyond Rheumatology 2020; 2:34
doi:10.4081/br.2020.34

This article is distributed under the terms of the Creative Commons Attribution Noncommercial License (by-nc 4.0) which permits any noncommercial use, distribution, and reproduction in any medium, provided the original author(s) and source are credited.

Introduction

The bone marrow edema syndrome (BMES) is a radiologic finding consisting of the pathologic accumulation of interstitial fluid and fibrosis in associated structures of the trabecular subchondral bone, resulting in pain and functional limitation.^{1,2} BMES can be categorized as primary if no underlying cause cannot be identified or is secondary to other pathologic conditions. Trauma is the most common cause of the secondary form of BMES, but also vascular congestive disorders are related to BMES, resulting in diminished blood perfusion and hypoxia of the bone marrow due to intramedullary increased pressure.³⁻⁶ The gold standard diagnostic criterion is to perform magnetic resonance imaging (MRI), which shows inflammatory areas in the bone marrow with an intact cartilage surface. Bone marrow lesions present with clear radiologic patterns. On T1-weighted imaging studies, it displays low signal intensity, whereas in fat-suppressed T2-weighted images it displays high signal intensity. In addition, contrast-enhanced MRI studies show signal hyperintensity in BMES.^{7,8} The primary objective in treating BMES is to reduce the duration and degree of pain and disability, and to prevent osteonecrosis or trabecular bone failure. As to the medical treatments, mostly glucocorticoids, prostaglandin inhibitors and bisphosphonates were used.⁹⁻¹²

Neridronate is an amino-bisphosphonate structurally similar to alendronate and pamidronate, differing only in the number of methyl groups of the side chain, being five for neridronate, three for alendronate and two for pamidronate. In this study, we evaluated the efficacy and safety of 2 treatment regimens of neridronate administered by iv infusion in patients with BMES.¹³⁻¹⁵

Materials and Methods

Study design

Patients with symptomatic osteoarthritis of knee, hip, wrist or foot that showed at baseline bone lesions at MRI were treated with neridronate (Abiogen Pharma, Pisa, Italy) either in a standard dose of 100 mg/8 ml i.v. ampules given four times over 10 days (Group A) or at the same dose but given every 21 days over 3 months (Group B). In both groups, patients were randomly enrolled and neridronate were diluted in a 500 ml saline isotonic solution and infused over 2 h. A control group treated exclusively with rest and NSAIDs was enrolled too. Inclusion criteria were: a continuous worsening of joint pain, pain intensity >30 mm on a visual analogue scale (VAS) ranging from 0 (no pain) to 100 mm (maximal pain) and a dedicated knee MRI scan showing large (>1 cm) BMLs. Exclusion criteria were hepatic, renal, endocrine, haematological, cardiac, pulmonary or neurological diseases and diabetic patients taking insulin or oral hypoglycaemic drugs; routine laboratory abnormalities (including calcaemia and glomerular filtration rate); prior treatment with BPs; an MRI scan with significant joint effusion, subchondral bone attrition and/or evidence of bursitis or tendonitis; knee pain resulting from definite knee trauma. The patients were asked not to take any analgesics or NSAIDs throughout the study period.

The diagnosis of OA and the absence of concomitant other rheumatic diseases was performed by two experienced rheumatologists.

This study was conducted in accordance with the ethics principles of the Declaration of Helsinki and was approved by the local research ethics committees. All patients signed informed consent to the treatment.

Magnetic resonance imaging protocol included spin

High-resolution, three-dimensional MRI was obtained for each patient before the start of the treatment (<2 months) and after 90 days from the last infusion. All MRIs were evaluated by a skilled musculoskeletal radiologist who was blinded to the patient's treatment. All MRI examinations were performed with a 1.5T scanner (Magnetom Espree, Siemens, Berlin, Germany). The echo T1-weighted sequences [repetition time (TR) 580 ms, echo time (TE) 12 ms, number of signal averages 2, thickness 3.0 mm, intersection gap 0.5 mm] were on the sagittal, coronal and transverse planes; spin echo T2-weighted sequences (TR 4.000 ms, TE 30/100 ms, one signal acquired, thickness 3.0 mm, intersection gap 0.5 mm) were on the sagittal and transverse planes; proton density-weighted sequence with fat/suppression (TR 2800 ms, TE 40 ms, one signal acquired, thickness 3.0 mm, intersection gap 0.5 mm) were on the coronal plane. Bone marrow lesions (BMLs) were identified as areas of increased signal intensity on fat-suppressed T2-weighted images.

Outcomes

The primary outcome of the study was the variation of BME

in MRI. A reduction of bone marrow lesions $\geq 50\%$ was considered a good response to the therapy. The secondary outcome was the change in the pain score of the affected joint measured by VAS (0-100 mm) 15 from the baseline at the day of the last infusion (T1: day 10 in Group 1 or day 63 in Group 2) and after 90 days from the last infusion of each group (T2). The response to treatment was defined as a 50% reduction in the VAS from baseline to each endpoint.

Adverse events

All patients were informed about a possible acute-phase reaction (polyarthralgia and/or fever) occurring after iv amino-bisphosphonate administration.²¹⁻²³ Physicians at the study sites reported adverse events (AEs) and serious adverse events that were coded as preferred terms in the Medical Dictionary for Regulatory Activities (MedDRA) system. According to investigator judgement, a drug-related AE was defined as definitely, probably or possibly related to study treatment. A non-drug-related AE was defined as unlikely or not related.

Statistical analysis

The statistical analysis was performed using SPSS 22 (SPSS, Chicago, IL, USA). The sample size calculation was performed assuming a two-tailed probability of type I error equal to 0.05. As suggested in the literature, assuming a reduction in VAS score of >20 mm in patients treated with the standard neridronate scheduling (Group A) and an efficacy on MRI bone edema in $\geq 65\%$ of patients with a sample size of 180 patients (ratio 1:2), we achieved a 80% power to detect a proportion of 75% of patients treated with the alternative scheduling (Group B). The results were expressed as mean (\pm S.D.). Changes vs baseline were tested by a one-way analysis of variance (ANOVA) and then by paired t-test. The Chi-square was used for dichotomous variable (e.g. proportion of responders). Significance was set at a $P < 0.05$. Logistic regression was used to establish a relationship between the variables collected and the treatment regimens and the outcomes.

Results

A total of 192 patients were recruited in Group A (72 patients) or Group B (120 patients). In the whole population, the mean age was 61.8 years ± 12 (min 28-max 89); mean BMI was 27.1 ± 5.5 (min 24-max 42); VAS mean value at baseline was 72.4 ± 13.2 (min 30-max 100), at T1 (day 10 for group A and day 63 for group B) was 43 ± 17.8 and at T2 (90 days after last infusion for both groups) was 19.7 ± 17.1 SD (min 0-max 90). There were no significant differences between the two groups in demographic and clinical characteristics at baseline ($P > 0.05$) (Table 1). We observed a significant improvement in the two groups both in terms of MRI and VAS at T1 and T2. A reduction of >50% of bone marrow lesions was observed in 67.6% of subjects at T1 and 79.8% at T2. In parallel, the VAS score fell to 43.7 ± 17.7 at T1 and 19.7 ± 17.2 respectively. We performed further analyzes to evaluate any differences between the two groups and did not observe a significant difference in MRI response ($P > 0.05$) and VAS reduction ($P > 0.05$) both in T1 and T2 (Figure 1). Interestingly, a significant difference in terms of VAS and MRI findings was observed in each time point between the treated groups (A and B) and the control group, suggesting that the changes are due to the treatment carried out and not to the natural evolution of the disease.

A Spearman's Rho and a subsequent logistic regression analysis did not show a significant relationship between gender, group of treatment, age, BMI, anatomical site involved and the MRI or VAS response ($P>0.1$). During the study about 30% of the subjects reported some kind of side effect, the most frequent of which was the acute phase reaction (polyarthralgia, fever), reported by 20.2% after the first infusion. In all patients, these symptoms disappeared within 2 days. No patients showed decreases in serum calcium values requiring treatment. No patients complained of serious adverse events as atypical fractures or osteonecrosis of the jaw during the follow-up period (6 months after T2). Frequency of each side effect was the same in the two groups ($P=0.23$).

Discussion and Conclusions

Bisphosphonates (BPs) are a metabolically stable analogue of inorganic pyrophosphate. They are anticatabolic agents, exerting their effects by inhibiting components of the intracellular meval-

Table 1. Frequency and percentage of each joint involvement in the whole population. P values between Group A and Group B were >0.05 .

	Frequency	Percentage
Ankle	24	12.5
Foot	43	22.4
Knee	38	19.8
Wrist	32	16.6
Femur	34	17.7
Sacroiliac	10	5.2
Shoulder	9	4.7
Elbow	1	0.5
Vertebra	1	0.5

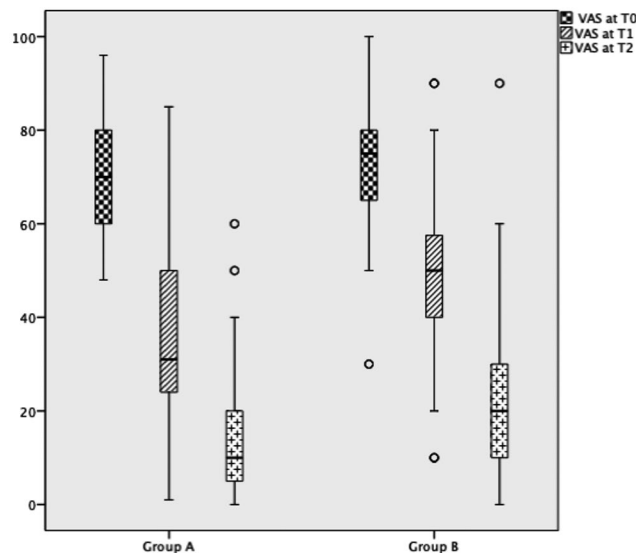


Figure 1. VAS mean values during the study in the two groups.

onate pathway and preventing prenylation of intracellular proteins in osteoclasts. BPs have shown to improve bone density in a variety of conditions, such as osteogenesis imperfecta.²⁴ The mechanism of action responsible for the brilliant results observed with bisphosphonates in the treatment of BMES remains conjectural, mainly because the exact pathophysiology of the disease is still unknown. The most obvious action of bisphosphonate in bones is its capacity to inactivate osteoclast formation and activity.^{25,26}

Varenna *et al.* observed that high levels of markers of bone resorption at baseline are predictive of a positive response to bisphosphonate therapy.²⁷ Some animal studies documented the positive results of parenteral bisphosphonates on osteonecrosis with a better preservation of histological architecture, trabecular number as well as macroscopic appearance of the femoral head.^{28,29} Moreover, there are positive results reported in the treatment of human osteonecrosis by bisphosphonates.³⁰⁻³⁸ Bartl *et al.* described as more than 90% of patients treated with ibandronate achieved a good clinical response compared to 20% of the control group. Positive results have also been reported in four randomized clinical trials using a single iv infusion of 7.5mg alendronate,³⁹ i.v. clodronate (300 mg for 10 days)⁴⁰ i.v. pamidronate (60 mg once)⁴¹ and 40mg daily oral alendronate for 12-16 weeks.⁴² However, none of these studies provided conclusive evidence of its efficacy mainly because of their limited size with 10-20 treated patients per study. Varenna *et al.* demonstrated the efficacy of iv neridronate in the treatment of bone marrow lesions in acute painful knee osteoarthritis and in the Complex Regional Pain Syndrome type I (CRPS-I).^{43,44} We can support these findings with our data, as we found a significant improvement of VAS and MRI with both therapy schedules without a significant difference between the more intensive scheme (group A) and the deferred scheme (Group B). A limitation in our study is the absence of a standardized radiologic score to quantify the extent of bone marrow lesions in each site at baseline and after the treatment. Moreover, in this study we did not include patients who were going to be retreated for incomplete response or no response to the first treatment. Therefore, we did not verify if a second cycle of neridronate can give some response in term of VAS or MRI. Considering these issues, our data confirms the efficacy of BPs, particularly neridronate, in BMES. No differences in efficacy and side effects were observed in the 2 treatment regimens. Further studies are necessary to understand if these results are able to delay or to halt the progression of the disease

References

1. Sampson MJ, Kabbani M, Krishnan R, et al. Improved clinical outcome measures of knee pain and function with concurrent resolution of subchondral bone marrow edema lesion and joint effusion in an osteoarthritic patient following pentosan polysulphate sodium treatment: a case report. *BMC Musculoskelet Disord* 2017;18:396.
2. Gao F, Sun W, Li Z, et al. Extracorporeal shock wave therapy in the treatment of primary bone edema syndrome of the knee: a prospective randomized controlled study. *BMC Musculoskelet Disord* 2015;16:379.
3. Eriksen EF. Treatment of bone marrow lesions (bone marrow edema). *Bonekey Rep* 2015;4:755.
4. Mirghasemi SA, Trepman E, Sadeghi MS, et al. Bone marrow edema syndrome in the foot and ankle. *Foot Ankle Int* 2016;37:1364-73.

5. Patel S. Primary bone marrow edema syndromes. *Rheumatology (Oxford)* 2014;53:785-92.
6. Manara M, Varenna M. A clinical overview of bone marrow edema. *Reumatismo* 2014;66:184-96.
7. Bonadio MB, Ormond Filho AG, Helito CP, et al. Bone marrow lesion: image, clinical presentation, and treatment. *Magn Reson Insights* 2017;10:1178623x17703382.
8. Geith T, Niethammer T, Milz S, et al. Transient bone marrow edema syndrome versus osteo-necrosis: perfusion patterns at dynamic contrast-enhanced MR imaging with high temporal resolution can allow differentiation. *Radiology* 2017;283:478-85.
9. Eriksen EF. Treatment of bone marrow lesions (bone marrow edema). *BoneKEy Rep* 2015;4:755.
10. Sobti A, James J, Sobti S, et al. Bone marrow edema syndrome, revisiting a forgotten entity. *Open J Orthop* 2020;10:21-4.
11. Baumbach SF, Pfahler V, Bechtold-Dalla Pozza S, et al. How we manage bone marrow edema. An interdisciplinary approach. *J Clin Med* 2020;9:551.
12. Fragoulis GE, Iliopoulos A, Evangelatos G. Zoledronic acid in nine patients with transient osteoporosis of the hip. *Clin Rheumatol* 2020;39:291-3.
13. Varenna M, Adami S, Rossini M, et al. Treatment of complex regional pain syndrome type I with neridronate: a randomized, double-blind, placebo-controlled study. *Rheumatology* 2013;52:534-42.
14. Erwann G, Maelle M, Prange N, et al. Syntheses of phosphonic esters of alendronate, pamidronate and neridronate. *Eur J Organ Chem* 2007;3380-91.
15. Corrado A, Colia R, Cantatore FP. Neridronate: from experimental data to clinical use. *Clin Med Insights Ther* 2017;9:1-8.
16. Zhang W, Doherty M, Peat G, et al. EULAR evidence-based recommendations for the diagnosis of knee osteoarthritis. *Annals Rheum Dis* 2010;69:483-9.
17. Zhang W, Doherty M, Leeb BF, et al. EULAR evidence-based recommendations for the diagnosis of hand osteoarthritis: report of a task force of ESCISIT. *Annals Rheum Dis* 2009;68:8-17.
18. Zhang W, Doherty M, Arden N, et al. EULAR evidence based recommendations for the management of hip osteoarthritis: report of a task force of the EULAR Standing Committee for International Clinical Studies Including Therapeutics (ESCISIT). *Annals Rheum Dis* 2005;64:669-81.
19. Zhang W, Doherty M. EULAR recommendations for knee and hip osteoarthritis: a critique of the methodology. *Br J Sports Med* 2006;40:664-9.
20. Kohn MD, Sassoon AA, Fernando ND. Classifications in Brief: Kellgren-Lawrence classification of osteoarthritis. *Clin Orthop Relat Res* 2016;474:1886-93.
21. Brunner F, Schmid A, Kissling R, et al. Bisphosphonates for the therapy of complex regional pain syndrome I - systematic review. *Eur J Pain* 2009;13:17-21.
22. Huskisson EC. Measurement of pain. *Lancet* 1974;2:1127-31.
23. Adami S, Bhalla AK, Dorizzi R, et al. The acute-phase response after bisphosphonate administration. *Calcif Tissue Int* 1987;41:326-33.
24. Glorieux FH, Bishop NJ, Plotkin H, et al. Cyclic administration of pamidronate in children with severe osteogenesis imperfecta. *N Engl J Med* 1998;339:947-95.
25. Rodan GA, Reszka AA. Bisphosphonate mechanism of action. *Curr Mol Med* 2002;2:571-7.
26. Varenna M, Zucchi F, Ghiringhelli D, et al. Intravenous clodronate in the treatment of reflex sympathetic dystrophy syndrome. A randomized, double blind, placebo controlled study. *J Rheumatol* 2000;27:1477-83.
27. Cremers S, Drake MT, Ebetino FH et al. Pharmacology of bisphosphonates. *Br J Clin Pharmacol* 2019;85:1052-62.
28. Little DG, Smith NC, Williams PR, et al. Zoledronic acid prevents osteopenia and increases bone strength in a rabbit model of distraction osteogenesis. *J Bone Miner Res* 2003;18:1300-7.
29. Kim HK, Randall TS, Bian H, et al. Ibandronate for prevention of femoral head deformity after ischemic necrosis of the capital femoral epiphysis in immature pigs. *J Bone Joint Surg Am* 2005;87:550-7.
30. Ramachandran M, Ward K, Brown RR, et al. Intravenous bisphosphonate therapy for traumatic osteonecrosis of the femoral head in adolescents. *J Bone Joint Surg Am* 2007;89:1727-34.
31. Agarwala S, Jain D, Joshi VR, Sule A. Efficacy of alendronate, a bisphosphonate, in the treatment of AVN of the hip. A prospective open-label study. *Rheumatology (Oxford)* 2005;44:352-9.
32. Nishii T, Sugano N, Miki H, et al. Does alendronate prevent collapse in osteonecrosis of the femoral head? *Clin Orthop Relat Res* 2006;443:273-9.
33. Kim HK, Randall TS, Bian H, et al. Ibandronate for prevention of femoral head deformity after ischemic necrosis of the capital femoral epiphysis in immature pigs. *J Bone Joint Surg Am* 2005;87:550-7.
34. Aigner N, Petje G, Schneider W, et al. Bone marrow edema syndrome of the femoral head: treatment with the prostacyclin analogue iloprost vs. core decompression: an MRI controlled study. *Wienklin Wochenschr* 2005;117:130-5.
35. Korompilias AV, Karantanas AH, Lykissas MG, Beris AE. Bone marrow edema syndrome. *Skeletal Radiol* 2009;38:425-36.
36. Ringe JD, Dorst A, Faber H. Effective and rapid treatment of painful localized transient osteoporosis (bone marrow edema) with intravenous ibandronate. *Osteoporos Int* 2005;16:2063-8.
37. Agarwala S, Shah S, Joshi VR. The use of alendronate in the treatment of avascular necrosis of the femoral head: follow-up to eight years. *J Bone Joint Surg Br* 2009;91:1013-8.
38. Bartl C, Imhoff A, Bartl R. Treatment of bone marrow edema syndrome with intravenous Ibandronate. *Arch Orthop Trauma Surg* 2012;132:1781-8.
39. Adami S, Fossaluzza V, Gatti D, et al. Bisphosphonate therapy of reflex sympathetic dystrophy syndrome. *Ann Rheum Dis* 1997;56:201-4.
40. Varenna M, Zucchi F, Ghiringhelli D, et al. Intravenous clodronate in the treatment of reflex sympathetic dystrophy syndrome. A randomized, double blind, placebo controlled study. *J Rheumatol* 2000;27:1477-83.
41. Robinson JN, Sandom J, Chapman PT. Efficacy of pamidronate in complex regional pain syndrome type I. *Pain Med* 2004;5:276-80.
42. Manicourt DH, Brasseur JP, Boutsens Y, et al. Role of alendronate in therapy for posttraumatic complex regional pain syndrome type I of the lower extremity. *Arthritis Rheum* 2004;50:3690-7.
43. Varenna M, Zucchi F, Failoni S, et al. Intravenous neridronate in the treatment of acute painful knee osteoarthritis: a randomized controlled study. *Rheumatology* 2015;54:1826-32.
44. Varenna M, Adami S, Rossini M, et al. Treatment of complex regional pain syndrome type I with neridronate: a randomized, double-blind, placebo-controlled study. *Rheumatology* 2013;52:534-42.