



# The Journal of Global Radiology

Ensuring Medical Imaging Access for All

## ORIGINAL RESEARCH

# Ultrasound-guided Intralesional Bleomycin Injection (IBI) for Treatment of Cutaneous Hemangiomas and Vascular Malformations

Yousuf Memon<sup>1\*</sup>, Nuzhat Irfan Malik<sup>1</sup>, Naveed Anjum<sup>2</sup>, S. Kamran Ahmed<sup>3</sup>, Sadaf Saeed<sup>4</sup>

<sup>1</sup>The Indus Hospital, Department of Radiology, Karachi, Pakistan

<sup>2</sup>The Indus Hospital, Department of Ear, Nose & Throat, Karachi, Pakistan

<sup>3</sup>The Indus Hospital, Department of Orthopedics, Karachi, Pakistan

<sup>4</sup>The Indus Hospital, Department of Plastic Surgery, Karachi, Pakistan

\*Corresponding author. Current address: The Indus Hospital, Landhi Local Road, Karachi, Pakistan; [nuzhat.irfan24@gmail.com](mailto:nuzhat.irfan24@gmail.com)

### OPEN ACCESS

© 2016 Memon, Malik, Anjum, Ahmed and Saeed. This open access article is distributed under a Creative Commons Attribution 4.0 License (<https://creativecommons.org/licenses/by/4.0/>)

DOI: 10.7191/jgr.2016.1022

Received: 2/23/2016

Accepted: 5/16/2016

Published: 7/7/2016

**Citation:** Memon Y, Malik NI, Anjum N, Ahmed SK, Saeed S, et al. Ultrasound-guided intralesional bleomycin injection (IBI) for treatment of cutaneous hemangiomas and vascular malformations. *J Glob Radiol.* 2016;2(1):Article 2.

**Keywords:** cutaneous hemangioma, vascular malformation, bleomycin

**Word count:** 4,431

### Abstract

**Purpose:** To report the therapeutic outcome of ultrasound-guided intralesional injection of bleomycin in the treatment of cutaneous hemangiomas and vascular malformations.

**Material & Methods:** The medical records of patients with cutaneous hemangiomas and vascular malformations treated with the intralesional injection of bleomycin under ultrasound guidance between August 2009 and June 2013 at the Indus Hospital, Karachi were reviewed retrospectively using a computerized medical record information management system. Data were extracted using a pre-coded performa that included patient demographics, type and location of lesion, number of treatments, presenting/pre- and post-treatment clinical symptoms (pain, swelling, heaviness, size, discoloration), ultrasound appearance and vascularity, and post-treatment side effects. The dose range of bleomycin was 0.5-1.0 mg/kg, but not exceeding 15 mg in a single session. A maximum of four treatments were given in any given patient except for one, who presented with recurrence after a year of complete resolution. Therapeutic outcome was determined using review of ultrasound images and recorded clinical assessment. Treatment response was categorized as: (i) complete resolution [more than 90% reduction]; (ii) substantial reduction [more than 50% reduction]; (iii) mild reduction [25% reduction]; or, (iv) no improvement [<10% reduction].

**Results:** A total of 30 patients (16 female, 14 male), ranging in age from 8 months to 48 years (mean age 10.2 years), were treated from 2009 to 2013. There were 23 hemangiomas. Seven were vascular malformations, of which five were lymphatic malformations and two were venous malformations. Twenty-eight lesions were located in the head and neck region, and two were peripheral. In 24 of the 30 patients (76%), treatment had been completed. In six patients (21%) treatment was ongoing at the time of this report. Seventeen of the 23 hemangiomas (74%) were completely resolved clinically and on ultrasound, five (22%) showed substantial improvement and one (4%) showed mild improvement. In five of the seven vascular malformations (71%) lymphatic malformations resolved completely, and two (29%) venous malformations showed substantial improvement. Of the 13 patients presenting with discoloration, there was complete resolution in one (7.7%), marked reduction in 11 (84.6%) and mild reduction in one (7.7%). Of seven patients presenting with pain, there was complete resolution in two (28.6%), marked reduction in two (28.6%), mild reduction in two (28.6%), and no improvement in one (14.3%). There were no pulmonary complications.

**Conclusion:** Ultrasound-guided intralesional injection of bleomycin is an option to consider for the treatment of certain types of cutaneous hemangiomas and vascular malformations. Prospective studies should be undertaken to understand the various factors contributing to therapeutic success.

## Introduction

HEMANGIOMAS and vascular malformations are developmental benign lesions that can occur in any organ. Frequently they are incidentally discovered. Internal hemorrhage may result in serious complications. Cutaneous hemangiomas and vascular malformations, on the other hand, are readily detectable and may result in functional compromise and/or permanent disfigurement. Hemangiomas are vasoproliferative neoplasms and are divided into infantile and congenital depending on age at presentation. Vascular malformations are commonly present at birth, usually in the head and neck region. They are subdivided into slow flow – a combination of capillary, venous and lymphatic – and fast flow, which has an arterial component (1). The majority of vascular malformations are small or self-limiting as the child grows older, but in some, lesions may grow with age. These may be treated surgically or with sclerosing agents. Bleomycin (BLM), also known as bleomycin or pingamycin, is primarily a cytotoxic anti-tumor antibiotic drug. It has sclerosing properties on direct contact with endothelium. Compared to surgery, intralesional bleomycin injection (IBI) is a simple, practical and noninvasive method of treatment that limits the number of secondary procedures (2, 3). BLM was first isolated as a Cu<sup>2+</sup>-containing glyco-oligopeptide antibiotic from the culture medium of streptomyces verticillatus. It was soon found to be an anticancer agent and has since become one of the most widely used anticancer drugs (4, 5). We selected bleomycin as first line treatment for hemangiomas and vascular malformations, as it was low-cost and easily available.

Bleomycin is usually used as an antineoplastic drug to treat many kinds of cancer, such as lymphoma, cervical cancer, head and neck cancer, and testicular cancer. Bleomycin is the most commonly used sclerosing agent for the treatment of vascular anomalies in China. Histological investigation shows that bleomycin can cause injury and detachment of endothelial cells and lead to narrowing or occlusion of the vessels (6).

A variety of techniques are used in the treatment of cutaneous hemangiomas and vascular malformations. Laser therapy is most effective for superficial lesions, surgical excision and skin flap elevation in early childhood, and has the best cosmetic results (7), but the technique is technically demanding.

In this study, we present our experience of clinical outcomes in treating patients presenting with hemangiomas and vascular malformations with bleomycin through ultrasound-guided intralesional injection at our tertiary care hospital.

Surgical removal at an early stage of the child's life would be beneficial to reestablish a normal appearance, thus minimizing psychosocial problems. However, there is argument among clinicians that complete surgical resection is difficult and often involves massive bleeding, severe scars, and injury of the facial nerves. The main advantages of IBI are the absence of external scarring and the low number of complications as compared with surgical treatment. Studies show that sclerotherapy is good for small diameter vessels. Therefore, intralesional injection of bleomycin in the cervical-facial region has been a routine therapy and has proven to be effective for the last 20 years (2, 3, 8, 9).

Use of ultrasonography and Doppler is an additional and recent technology to the existing treatment procedure to rate the blood stream. It allows for unequivocal classification as to venous, arterial, or lymphatic malformation, and a simple noninvasive method to distinguish slow-flow from fast-flow vascular malformation (10). Therefore, if ultrasound guidance technique is used for the patient selection, and later in the treatment of hemangiomas and vascular malformations, improved results may be seen.

## Materials and methods

After IRB approval, a retrospective chart review was conducted on patients with a diagnosis of hemangiomas and venous malformation located in either the head and neck region (n=28) or peripheral (n=2), who were treated between August 2009 and June

2013. Patient selection was made on the basis of history, clinical examination, grey-scale ultrasound, color Doppler and spectral Doppler parameters. Lesions with slow and medium flow rates, along with very small or non-detectable venous outflow rates, were selected for IBI. According to Puig's classification system of vascular malformations, based on anatomical and hemodynamic features, these vascular malformations belonged to type I and type II lesions (Table 1) (11, 12).

**Table 1.** Puig's classification scheme.

I. Isolated malformation without peripheral drainage
II. Malformation that drains into normal veins
III. Malformation that drains into dilated veins
IV. Malformation that represents dysplastic venous ectasia

Both infantile and congenital hemangiomas were included. RICH in congenital hemangiomas were excluded, as were multiple and midline hemangiomas in infantile hemangiomas. Any patients with lesions involving mediastinum or trachea, deep soft tissues or arteriovenous malformations and patients with incomplete data were excluded.

Patients' demographic data, including age, sex, weight, location and size of the lesion, clinical history, ultrasound images with color, spectral and Doppler analysis, bleomycin dose, clinical response, side effects, and follow-up were recorded. Color photographs of the lesions were taken before, during, and after completion of the treatment to help parents see the regression of the lesion over time.

Prior to treatment, all patients underwent a thorough clinical evaluation to exclude any systemic disease, and ultrasound examination with Doppler and duplex analysis of the lesion were performed. Informed consent was acquired from the parents prior to commencement of sclerotherapy.

### Procedure

Injections were prepared by dissolving a 15 mg powdered bleomycin ampoule in 15 ml of normal saline, giving a bleomycin concentration of 1 mg/ml.

In accordance with the published guidelines, the bleomycin dose was calculated at 0.5-1 mg / kg of body weight, with a maximum of 15 mg per session and 40mg per patient (13).

All procedures were performed under general anesthesia. Ultrasound scanning was done using a portable Sonosite ultrasound machine with a linear array probe (7.5 -10 MHz). Under aseptic conditions bleomycin was injected in vascular channels that appeared anechoic on grey scale (consistent with vascular channels in hemangioma), venous malformations and cystic spaces in lymphatic malformation at multiple sites using a 23-gauge needle. Following this treatment, local pressure was applied to the soft tissue around the lesion in order to prolong contact time of bleomycin with the vessel wall. Localized pressure over injection site assured hemostasis. Larger lesions required multiple injections.

This procedure required short-stay hospital admission for four hours post-procedure observation for local or systemic complications. At 3-4 week follow-up, clinical and ultrasound assessments were done to evaluate response to treatment, and assess whether further bleomycin injection was necessary or not. Lesion size was measured, and vascularity by Doppler was documented. Clinically, the lesion was evaluated for swelling, discoloration, pain, pressure symptoms or ulceration. In absence of optimal response, injections were repeated until four treatment sessions had been performed, or the lesion was cured.

Treatment response was categorized as: (i) complete resolution (>90%); (ii) substantially reduced (<50% reduction); (iii) mildly reduced (<25% reduction); or, (iv) no improvement (<10% reduction).

**Table 2.** Clinical and ultrasound outcomes of bleomycin sclerotherapy in hemangiomas and vascular malformations.

Case	Age	Sex	Site	Size (cm)	Lesion type	Sclerotherapy sessions	Clinical outcome	Ultrasound outcome
1	1 yr	M	Neck	6.0	LM	4	>90%	>90%
2	13 yrs	M	Cheek	9	CH	2 -contd	>50%	>50%
3	15 yrs	F	Cheek	4	CH	2-contd	>90%	>90%
4	2 yrs	M	Mandible	2.5	VM	4	>50%	>50%
5	13 yrs	M	Cheek	6.5	IH	3	>90%	>90%
6	16 yrs	F	Leg	25	CH	4	>25%	>25%
7	14 yrs	M	Cheek	2	IH	4	>90%	>90%
8	8 yrs	F	Cheek	7.8	IH	2-contd	>50%	>50%
9	20 yrs	M	Lip	3.8	IH	2	>90%	>90%
10	22 yrs	M	Mandible	4.6	CH	4	>90%	>90%
11	3 yrs	F	Neck	5.5	LM	3	>90%	>90%
12	10 mos	F	Cheek	2.1	IH	2	>90%	>90%
13	11 yrs	M	Mandible	8.5	IH	2	>50%	>50%
14	9 yrs	F	Cheek	2.5	IH	2	>90%	>90%
15	5 yrs	M	Hand	20	CH	2 -contd	>50%	>50%
16	2 yrs	F	Neck	3.5	LM	6	>90%	>90%
17	10 mos	F	Ear	5.0	IH	2	>90%	>90%
18	9yrs	F	Cheek	4.4	IH	2	>90%	>90%
19	3yrs	M	Neck	10	LM	2	>90%	>90%
20	6 yrs	M	Mandible	1.5	VM	1	>50%	>50%
21	1 yr	M	Cheek	1.5	IH	1-contd	>90%	>90%
22	10 yrs	F	Cheek	3.0	IH	4	>90%	>90%
23	11 mos	F	Cheek	5.8	IH	3	>90%	>90%
24	10 mos	F	Cheek	7.0	IH	3	>90%	>90%
25	48 yrs	F	Tongue	1.5	CH	3	>90%	>90%
26	32 yrs	M	face	4.5	CH	3	>90%	>90%
27	20 yrs	M	Ear	6.2	IH	3	>90%	>90%
28	28 yrs	F	Cheek	1.1	CH	2	>90%	>90%
29	1 mos	F	Neck	10	LM	4	>90%	>90%
30	8 mos	F	Cheek	2.0	IH	3-contd	>90%	>90%

**Abbreviations:** IH: infantile hemangioma; CH: congenital hemangioma; LM; lymphatic malformation; VM: venous malformations; contd: continued

## Results

A total of thirty patients with hemangiomas and vascular malformations were treated with intralesional bleomycin injection (Table 2). Twenty-three patients had hemangiomas, and seven had vascular malformations (5 lymphatic, 2 venous). Twenty-four patients completed the treatment. Treatment of six patients is ongoing at the time of writing this report. There were 14 males and 16 females in the study, ages 8 months to 48 years.

Twenty-eight lesions were located in the head and neck region, and two were peripheral. One of the hemangiomas was on the hand, involving the little finger, hypothenar eminence and part of the distal forearm. The other was on the leg, involving the lateral surface of thigh. The rest of the hemangiomas were noticed on the face in variable locations: two on the ear lobule, three near the mandible, one on the inferior surface of tongue, one on the lower lip, and the rest were on either of the cheeks. All lymphatic malformations were

noted around the neck, whereas two venous malformations were located at the mandible.

Eighteen lesions were small to medium in size, measuring 0.5 -5 cm. Ten lesions were large, at 5-10 cm, and two were extensive, measuring larger than 20 cm each in size.

Nine patients had prior treatment, including alcohol/ steroid injection and surgery, while the remaining twenty-one patients had only the intralesional bleomycin treatment regimen reported here.

Seventeen of the 23 hemangiomas (74%) were completely resolved clinically and on ultrasound, while five (22%) showed marked improvement and one (4%) showed mild improvement. Of the seven vascular malformations, five (71%) lymphatic malformations resolved completely, and 2 (29%) venous malformations showed substantial improvement. Treatment was maximum in small to medium sized lesions, with 17 of 18 (99%) showing marked improvement. Among large and extensive lesions, 8 of 12 (70%) showed marked improvement. Twenty-two patients (73%) received

**Table 3.** Overall clinical response of 30 hemangioma/vascular malformation patients treated with Intralesional bleomycin injections at The Indus Hospital, Karachi (2009-2013).

Treatment outcome	Treatment completed (n=24)	Treatment continued (n=6)	Overall
Completely resolved or substantially reduced	23 (95.8%)	3 (50%)	26 (86.7%)
Mildly reduced	1 (4.2%)	3 (50%)	4 (13.3%)

only one to three treatment sessions. The maximum number of treatments was four sessions, with the exception of one case in which a patient's lymphatic malformation was completely resolved after four sessions, but showed recurrence after a year of treatment and was markedly reduced after two more sessions (Table 2).

Overall treatment was completed in twenty-four patients (96%) of patients. Two patients underwent major surgery due to insignificant response to bleomycin. These patients had hemangiomas in extremities, with lesions greater than 20 cm. Twenty-two patients did not require additional treatment. Twenty-three of 24 patients (95.3%) showed overall improvement, with no residual lesion and scarring according to the parents' and clinicians' observation, as well as ultrasound follow-up. All patients who received complete treatment presented with swelling. Twelve of thirteen patients (92%) who presented with discoloration of the skin overlying the lesion showed complete to marked resolution (Table 3). There were few bleomycin-related complications: one patient had fever, which subsided within 24 hours with antipyretics; one patient developed minor superficial ulceration, likely due to bleomycin leakage into the superficial tissues, which healed over four weeks time, leaving minimum scarring. There were no cases of pulmonary fibrosis (Table 4).

**Table 4.** Complications encountered in patients treated with intralesional bleomycin injection.

Immediate Complications	No. of patients
Fever	1
Vomiting	1
Flu	0
Late Complications	No. of patients
Ulceration	1
Coughing	0
Pulmonary fibrosis	0

**Case descriptions**

**Case 1:** 8 year-old female presented with left cheek hemangioma measuring 7.8 cm x 3.5 cm on ultrasound, with no prior treatment received. Intralesional bleomycin was administered in doses of 10 mg per session (Fig 1).

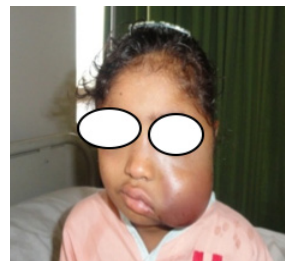Same patient after two treatment sessions of intralesional bleomycin, at an interval of one session per month. The patient was followed up for two years at six monthly intervals, and shows no recurrence (Fig 2).

**Case 2:** Female age 2 years presented with swelling on neck present since birth. Figure 3 shows part of large macrocystic lymphatic malformation measuring 3.5 cm x 1.1 cm on ultrasound. Excellent response was observed clinically and >50% reduction on ultrasound after first session of U/S guided IBI (Fig. 4).

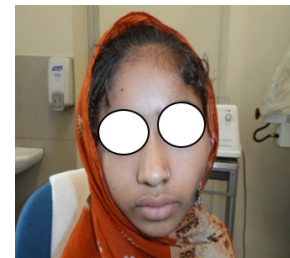**Case 3:** Swelling in left mandible in female age 3 years 11 months present since 18 months of age. On ultrasound mixed lymphatic malformation can be seen in Figure 5. Complete resolution with no cystic spaces and only residual fibrotic tissue after three treatment sessions (Fig. 6).

**Case 4:** 22 year-old male with hemangioma in right cheek measuring 5.7 cm x 2.7 cm presenting as hypervascular on color Doppler (Fig. 7a/7b). Follow up after first injection shows reduction of up to 2.9 cm x 1.6 cm, with blood flow reduced by more than 90% (Fig. 8a/8b).

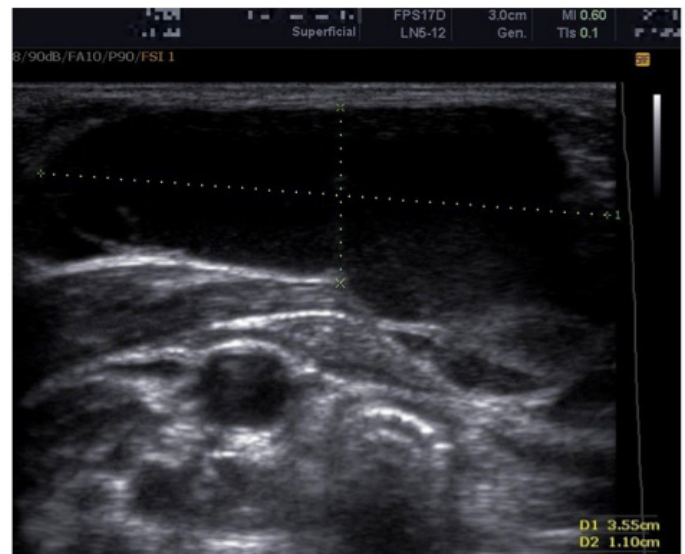
**Fig. 1.** 8 year-old female presenting with left cheek hemangioma.



**Fig. 2.** Same patient as in Fig. 1 after two treatment sessions of intralesional bleomycin, at an interval of one session per month.

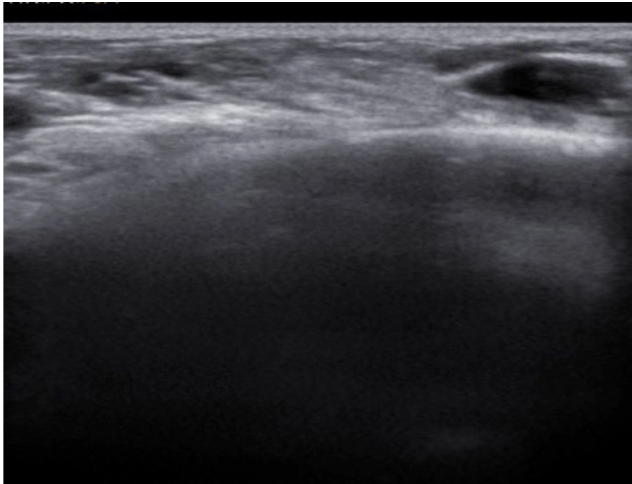


**Fig. 3.** Part of large macrocystic lymphatic malformation on neck present since birth in 2 year-old female.

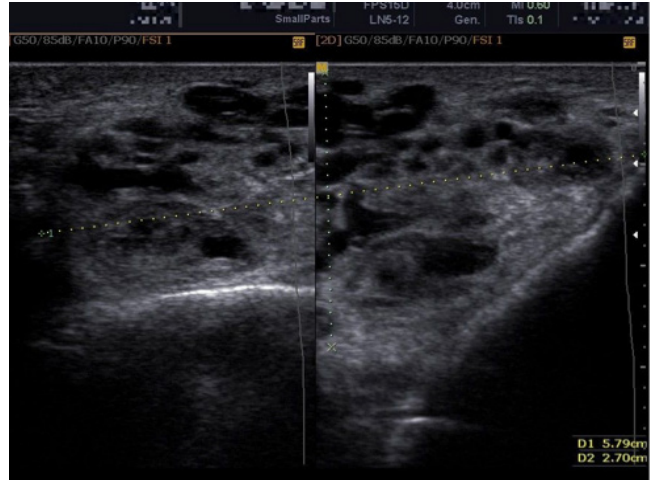




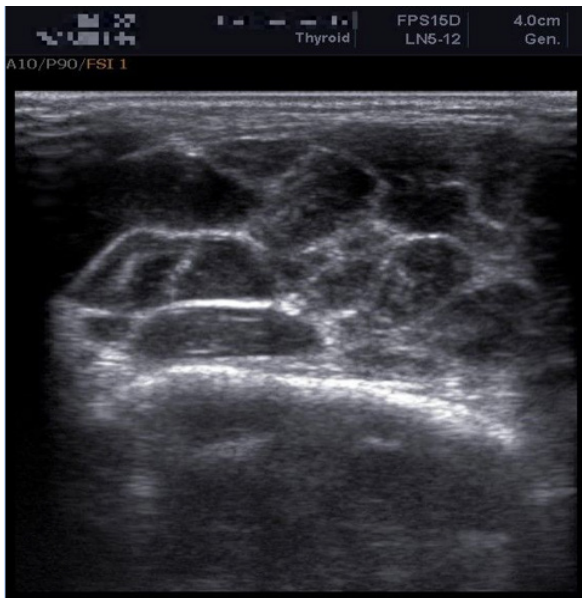**Fig. 4.** Greater than 50% reduction on ultrasound after first session of U/S guided IBI.



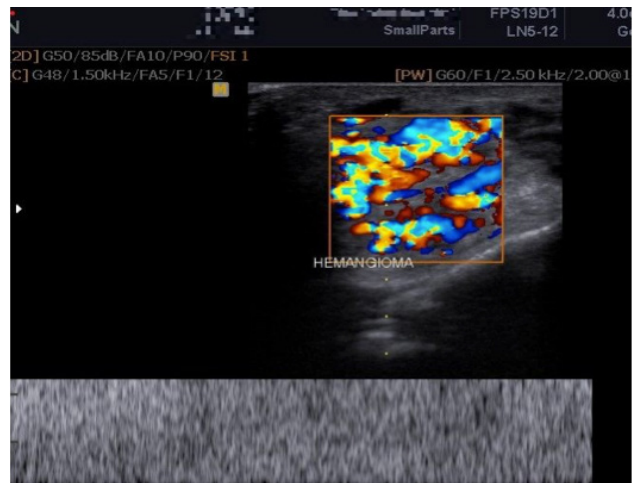
**Fig. 7a.** Hemangioma in right cheek of 22 year-old male, measuring 5.7 cm x 2.7 cm and presenting as hypervascular on color Doppler.



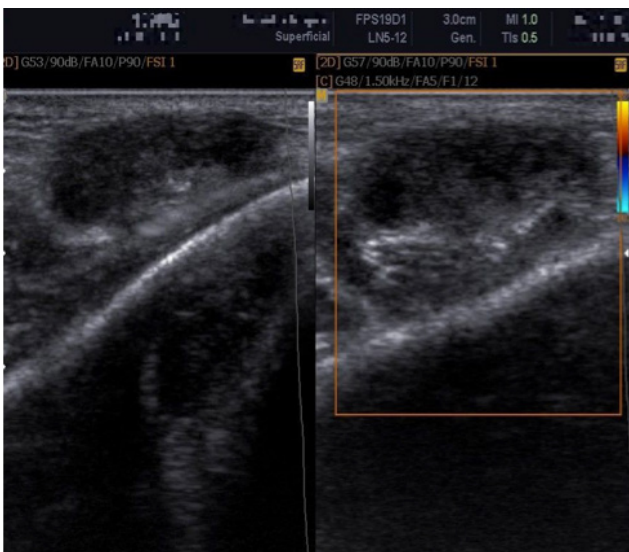
**Fig. 5.** Swelling in left mandible in female age 3 years 11 months, present since 18 months of age. On ultrasound mixed lymphatic malformation.



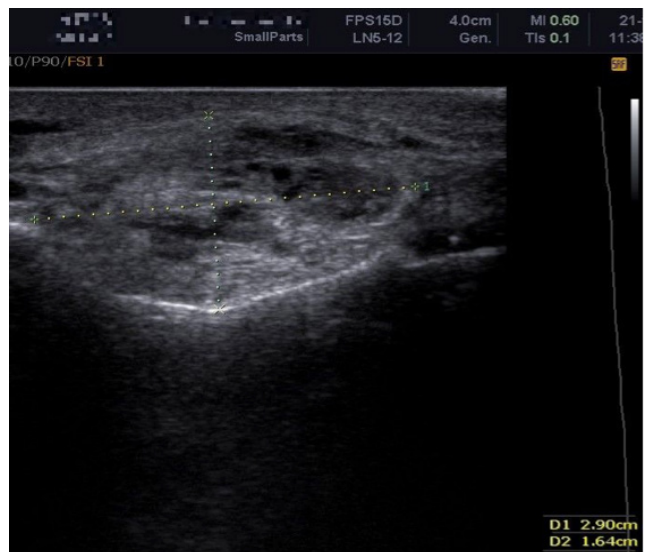**Fig. 7b.** Hemangioma in right cheek of 22 year-old male, measuring 5.7 cm x 2.7 cm and presenting as hypervascular on color Doppler.



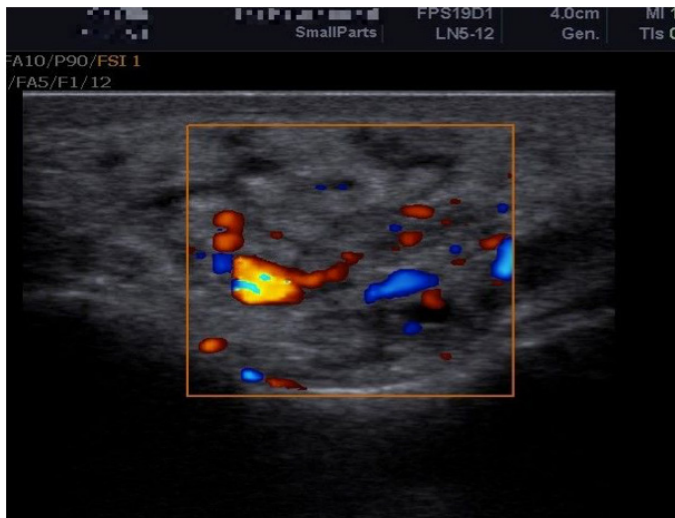
**Fig. 6.** Complete resolution with no cystic spaces and only residual fibrotic tissue after three treatment sessions.



**Fig. 8a.** Same patient as in Fig. 7a/7b after first injection; substantial reduction apparent with blood flow reduced more than 90%.



**Fig. 8b.** Same patient as in Fig. 7a/7b after first injection; substantial reduction apparent with blood flow reduced more than 90%.



## Discussion

A new classification adopted by the International Society for the Study of Vascular Anomalies (ISSVA) in 1996, based on that described by Mulliken and Glowacki (1), shows that vascular lesions now include vasoproliferative neoplasms and vascular malformations. Hemangiomas, the most common vasoproliferative neoplasms, are classified as infantile and congenital hemangiomas. Infantile hemangiomas present between the second and ninth weeks of life. They undergo a proliferative growth phase until they reach their full size. Congenital hemangiomas, on the other hand, are fully formed at birth (14). Both types are characterized by endothelial proliferation (15). They are more common in females, 80% occurring in the head and neck. Based on the natural history of hemangiomas, 50% completely resolved by age 5 and 70% by 7 years of age. Improvement may or may not occur in the remaining (16).

Two main types of congenital hemangiomas have been described: Non-involuting congenital hemangiomas (NICH), which present at birth and show proportional growth without regression, and rapidly involuting congenital hemangiomas (RICH), which present at birth and regress completely within two years (14).

Although cutaneous hemangiomas are most common and easily identified, they can also occur in extracutaneous sites, including the liver, gastrointestinal tract, central nervous system, pancreas, gall bladder, thymus, spleen, lymph nodes, lung, urinary bladder and adrenal glands (17).

Vascular malformations are always present at birth, and, unlike hemangiomas, have normal endothelial turnover. They grow progressively in size with age, and never involute spontaneously. Increase in size may occur due to infection, trauma, bleeding or hormonal changes. Vascular malformations are subdivided into capillaries, veins, arteries, lymphatics, or a combination of these vessel types. Haemodynamically, the vascular malformations can be further divided into high-flow or low-flow lesions (1, 18). Capillary, lymphatic and venous malformations are classified as slow-flow lesions, and arterial malformations, arteriovenous fistulas, and arteriovenous malformations are classified as high-flow lesions (8, 19, 20). Lymphatic malformations (LMs) are developmental anomalies consisting of abnormally formed lymphatic channels and cystic spaces of varying size. Morphologically, LMs include: microcystic, macrocystic, and mixed. The macrocystic type is comprised of single or multiloculated cysts that vary in size from a few millimeters to several centimeters. Microcystic LMs contain variable fibrous/fatty components, tiny cysts, or ectatic channels (21). Treatment is indicated when the lesions become symptomatic

by causing functional disturbances, or for disfigurement or cosmetic reasons (1, 18).

Several treatment options are available for above-vascular lesions: plastic surgery, embolization and sclerotherapy. Sclerotic therapy may be achieved by intralesional injections of corticosteroids, use of interferon, or by laser therapy, cryosurgery or radiations (22). Surgical excision and sclerotherapy are most commonly used in clinical practice. Plastic surgery intervention is reserved for deep lesions. But it is often associated with massive bleeding, and poor cosmetic results from scarring or nerve injury. Laser therapy is effective only for small and superficial lesions (7).

Propranolol has recently been used to treat infantile hemangiomas. Other drugs include steroids followed by chemotherapeutic agents, such as vincristine (23, 24).

Selection of the treatment modality depends on the type, location, and size of the lesions, as well as the treatment cost and techniques available. Each of these approaches has advantages and disadvantages based on clinical results. Percutaneous sclerotherapy is regarded as a minimally invasive, low-cost and reliable modality for the treatment. It involves injection of a sclerosant into the lesion through the skin. It is usually safe and effective for small to medium sized lesions. Previous studies have shown that sclerotherapy is a helpful preoperative adjunct treatment for larger lesions. It can reduce surgical blood loss and decrease the area of surgical resection (25). The main advantages are no external scarring and few complications, as compared with surgical treatment. Therefore, sclerotherapy is selected as a better alternative in the treatment of vascular malformations and hemangiomas in the face and neck (7, 8, 21, 26).

Many sclerosants, including boiling water, sodium morrhuate, absolute ethanol, sodium tetradecyl sulfate, and bleomycin (7, 8) have been attempted in treating hemangiomas and vascular malformations. Bleomycin is an antineoplastic agent that has been reported to successfully treat lymphatic malformations (27, 28) and, in smaller studies, hemangiomas (29, 30). Bleomycin has been used as alternative sclerosant as it has been shown to have a sclerosant effect on endothelial cells of the cyst wall of lymphangiomas (29-32).

The mechanism of action of bleomycin involves swelling of endothelial cells and discontinuation of tunica intima with increased thickness of the walls leading to narrowing of the lumen and ultimately occlusion (6, 13). Proper injections into the vascular spaces leads to gradual fibrous degeneration and resultant lesion regression, with no fibrosis and scarring. It is a minimally invasive treatment with good results, and has therefore been in use for last two decades (2, 3, 9, 13, 28, 33).

We compared our report with other larger series of bleomycin treatment of maxillofacial hemangiomas. Our technique was similar to that reported earlier. A 1.0 mg/ml concentration was used, though Zheng et al. used a concentration of 2 mg/ml for the venous malformations. We conducted up to four sessions per patient; others reported 1-5 sessions, with an average of 3.5 sessions. Bleomycin injection is generally safe, with reversible complications such as fever and vomiting. One patient (3%) suffered from skin ulceration, but in a larger series of 249 and 66 patients, no ulceration was reported (13,16). We report a high degree of success, with 96% of hemangiomas cured or substantially reduced. Zheng et al. report a lower success rate of 75-84% for venous and lymphatic malformations. In another series, Hou et al. achieved 88% cure or substantial reduction in 66 patients. It is possible our results are better than larger series due to our smaller patient cohort (13,16).

There were no cases of pulmonary fibrosis among patients in this study. Pulmonary fibrosis is a known complication and has been reported in some oncology patients who received a high cumulative dose of bleomycin. Some studies have indicated a risk of pulmonary fibrosis in patients receiving more than 160 mg of bleomycin systemically (31). It is reported that the total dose must not exceed 5 mg/kg, or approximately 20 mg in total, for this to occur in infants (22).

Bleomycin injection without ultrasound guidance is based on clinical examination, and injection into the lesion after aspiration of



blood. It has been faced with problems including dispersion of drug into surrounding tissue with significantly reduced therapeutic effect, or invasion of important tissues adjacent to the lesion such as nerves, salivary glands or vessels, which can lead to serious complications. Ultrasound guidance was first used by Yamaki (32) with VMs in the cervical-facial region by intralesional injection of absolute alcohol, and he researched this method in detail with reported advantages like prevention of intra-arterial injections (34, 35).

In this study, we evaluated the therapeutic outcome of injection of bleomycin in treatment of hemangiomas and VMs. The ultrasound imaging evaluated the size of lesions, macro/microcystic, tissue plane occupied, and the relationship between lesions and surrounding tissues, so that the effects of treatment could be improved by ensuring the precise injection position. The Doppler scan showed the vascularity and velocity of flow. It was observed that there are certain factors that affected outcomes: type of lesion, the size and location of the malformations.

## Conclusion

These encouraging results were mainly relevant to the precise injection of bleomycin into lesions under ultrasound guidance, which made the drug concentrations localize in the lesion so as to improve the therapeutic effect and reduce complications. However, there are some weaknesses in this study. First, there was no control group in this report. We only did a retrospective study, not a prospective one. Second, only superficial lesions were included, as MRI was not available in our setup and patients could not afford MRI from another institute.

## Acknowledgments

The authors would like to thank Lubna Samad, Amal Mohiuddin, Sundus Iftikhar for their support in clinical evaluation, selection of patients for IBI, data extraction, literature search and data analysis on SPSS.

## Conflict of interest

The authors have no conflicts of interest to report.

## References

- Mulliken JB, Glowacki J. Hemangiomas and vascular malformations in infants and children: a classification based on endothelial characteristics. *Plast Reconstr Surg.* 1982;69(3):412-22. PubMed PMID: 7063565.
- Omidvari S, Nezakatgoo N, Ahmadloo N, Mohammadianpanah M, Mosalaei A. Role of intralesional bleomycin in the treatment of complicated hemangiomas: prospective clinical study. *Dermatol Surg.* 2005;31(5):499-501. PubMed PMID: 15962730.
- Muir T, Kirsten M, Fourie P, Dippenaar N, Ionescu GO. Intralesional bleomycin injection (IBI) treatment for haemangiomas and congenital vascular malformations. *Pediatr Surg Int.* 2004;19(12):766-73. doi: 10.1007/s00383-003-1058-6. PubMed PMID: 14740248.
- Ostrowski MJ. An assessment of the long-term results of controlling the accumulation of malignant effusions using intracavity bleomycin. *Cancer.* 1986;57(4):721-7.
- Ming LJ. Structure and function of "metalloantibiotics". *Med Res Rev.* 2003;23(6):697-762. doi: 10.1002/med.10052. PubMed PMID: 12939790.
- Yang Y, Sun M, Cheng X, Hu X, Zhang P, Ma Q, et al. Bleomycin A5 plus dexamethasone for control of growth in infantile parotid hemangiomas. *Oral Surg Oral Med Oral Pathol Oral Radiol Endod.* 2009;108(1):62-9. doi: 10.1016/j.tripleo.2009.02.022. PubMed PMID: 19451005.
- Yildirim I, Cinar C, Aydin Y, Cayci C. Sclerotherapy to a large cervicofacial vascular malformation: a case report with 24 years' follow-up. *Head Neck.* 2005;27(7):639-43. doi: 10.1002/hed.20198. PubMed PMID: 15880394.
- Lee CH, Chen SG. Direct percutaneous ethanol instillation for treatment of venous malformation in the face and neck. *Br J Plast Surg.* 2005;58(8):1073-8. doi: 10.1016/j.bjps.2005.04.014. PubMed PMID: 16055097.
- Pienaar C, Graham R, Geldenhuys S, Hudson DA. Intralesional bleomycin for the treatment of hemangiomas. *Plast Reconstr Surg.* 2006;117(1):221-6. doi: 10.1097/01.prs.0000194906.61805.b0. PubMed PMID: 16404271.
- Hou R, Guo J, Hu K, Yang Y, Wang L, Kong L, et al. A clinical study of ultrasound-guided intralesional injection of bleomycin A5 on venous malformation in cervical-facial region in China. *J Vasc Surg.* 2010;51(4):940-5. doi: 10.1016/j.jvs.2009.11.038. PubMed PMID: 20347690.
- Puig S, Aref H, Chigot V, Bonin B, Brunelle F. Classification of venous malformations in children and implications for sclerotherapy. *Pediatr Radiol.* 2003;33(2):99-103. doi: 10.1007/s00247-002-0838-9. PubMed PMID: 12557065.
- Puig S, Casati B, Staudenherz A, Paya K. Vascular low-flow malformations in children: current concepts for classification, diagnosis and therapy. *Eur J Radiol.* 2005;53(1):35-45. doi: 10.1016/j.ejrad.2004.07.023. PubMed PMID: 15607851.
- Zheng JW, Yang XJ, Wang YA, He Y, Ye WM, Zhang ZY. Intralesional injection of Pingyangmycin for vascular malformations in oral and maxillofacial regions: an evaluation of 297 consecutive patients. *Oral Oncol.* 2009;45(10):872-6. doi: 10.1016/j.oraloncology.2009.02.011. PubMed PMID: 19628423.
- Mulliken JB, Enjolras O. Congenital hemangiomas and infantile hemangioma: missing links. *J Am Acad Dermatol.* 2004;50(6):875-82. doi: 10.1016/j.jaad.2003.10.670. PubMed PMID: 15153887.
- Roberts N. Infantile haemangioma: harmless 'strawberry' or life-threatening vascular anomaly? *Clinical medicine.* 2009;9(4):385-9.
- Hou J, Wang M, Tang H, Wang Y, Huang H. Pingyangmycin sclerotherapy for infantile hemangiomas in oral and maxillofacial regions: an evaluation of 66 consecutive patients. *Int J Oral Maxillofac Surg.* 2011;40(11):1246-51. doi: 10.1016/j.ijom.2011.07.906. PubMed PMID: 21893396.
- Infantile Hemangioma [Internet]. 2015. Available from: <http://emedicine.medscape.com/article/1083849-overview>.
- Betz CS, Jager HR, Brookes JA, Richards R, Leunig A, Hopper C. Interstitial photodynamic therapy for a symptom-targeted treatment of complex vascular malformations in the head and neck region. *Lasers Surg Med.* 2007;39(7):571-82. doi: 10.1002/lsm.20535. PubMed PMID: 17868106.
- Berenguer B, Burrows PE, Zurakowski D, Mulliken JB. Sclerotherapy of craniofacial venous malformations: complications

- and results. *Plast Reconstr Surg.* 1999;104(1):1-11; discussion 2-5. PubMed PMID: 10597669.
20. Choi YH, Han MH, Kwon O-K, Cha SH, Chang K-H. Craniofacial cavernous venous malformations: percutaneous sclerotherapy with use of ethanolamine oleate. *J Vasc Interv Radiology.* 2002;13(5):475-82.
21. Alomari AI, Karian VE, Lord DJ, Padua HM, Burrows PE. Percutaneous sclerotherapy for lymphatic malformations: a retrospective analysis of patient-evaluated improvement. *J Vasc Interv Radiol.* 2006;17(10):1639-48. doi: 10.1097/01.RVI.0000239104.78390.E5. PubMed PMID: 17057006.
22. Sundine MJ, Wirth GA. Hemangiomas: an overview. *Clin Pediatr (Phila).* 2007;46(3):206-21. doi: 10.1177/0009922806290455. PubMed PMID: 17416876.
23. Denoyelle F, Leboulanger N, Enjolras O, Harris R, Roger G, Garabedian EN. Role of Propranolol in the therapeutic strategy of infantile laryngotracheal hemangioma. *Int J Pediatr Otorhinolaryngol.* 2009;73(8):1168-72. doi: 10.1016/j.ijporl.2009.04.025. PubMed PMID: 19481268.
24. Leaute-Labreze C, Dumas de la Roque E, Hubiche T, Boralevi F, Thambo JB, Taieb A. Propranolol for severe hemangiomas of infancy. *N Engl J Med.* 2008;358(24):2649-51. doi: 10.1056/NEJMc0708819. PubMed PMID: 18550886.
25. Gelbert F, Enjolras O, Deffrenne D, Aymard A, Mounayer C, Merland JJ. Percutaneous sclerotherapy for venous malformation of the lips: a retrospective study of 23 patients. *Neuroradiology.* 2000;42(9):692-6. PubMed PMID: 11071446.
26. Zhou Q, Zheng JW, Mai HM, Luo QF, Fan XD, Su LX, et al. Treatment guidelines of lymphatic malformations of the head and neck. *Oral Oncol.* 2011;47(12):1105-9. doi: 10.1016/j.oraloncology.2011.08.001. PubMed PMID: 21906990.
27. Qin ZP, Xin ZF, Ren L, Liu XJ, Yao SG. Long-term results of intratumorous bleomycin-A5 injection for head and neck lymphangioma. *Oral Surgery, Oral Medicine, Oral Pathology, Oral Radiology, and Endodontology.* 1998;86(2):139-44.
28. Tanigawa N, Shimomatsuya T, Takahashi K, Inomata Y, Tanaka K, Satomura K, et al. Treatment of cystic hygroma and lymphangioma with the use of bleomycin fat emulsion. *Cancer.* 1987;60(4):741-9.
29. Kullendorff CM. Efficacy of bleomycin treatment for symptomatic hemangiomas in children. *Pediatr Surg Int.* 1997;12(7):526-8. doi: 10.1007/BF01258718. PubMed PMID: 9238123.
30. Sarihan H, Mocan H, Yildiz K, Abes M, Akyazici R. A new treatment with bleomycin for complicated cutaneous hemangioma in children. *Eur J Pediatr Surg.* 1997;7(3):158-62. doi: 10.1055/s-2008-1071080. PubMed PMID: 9241503.
31. Baskin D, Tander B, Bankaoglu M. Local bleomycin injection in the treatment of lymphangioma. *Eur J Pediatr Surg.* 2005;15(6):383-6. doi: 10.1055/s-2005-872922. PubMed PMID: 16418953.
32. Yamaki T, Nozaki M, Fujiwara O, Yoshida E. Duplex-guided foam sclerotherapy for the treatment of the symptomatic venous malformations of the face. *Dermatol Surg.* 2002;28(7):619-22. PubMed PMID: 12135522.
33. Zhao J-H, Zhang W-F, Zhao Y-F. Sclerotherapy of oral and facial venous malformations with use of pingyangmycin and/or sodium morrhuate. *International journal of oral and maxillofacial surgery.* 2004;33(5):463-6.
34. Yamaki T, Nozaki M, Sakurai H, Takeuchi M, Soejima K, Kono T. Prospective randomized efficacy of ultrasound-guided foam sclerotherapy compared with ultrasound-guided liquid sclerotherapy in the treatment of symptomatic venous malformations. *J Vasc Surg.* 2008;47(3):578-84. doi: 10.1016/j.jvs.2007.11.026. PubMed PMID: 18295109.
35. Yamaki T, Nozaki M, Sasaki K. Color duplex-guided sclerotherapy for the treatment of venous malformations. *Dermatol Surg.* 2000;26(4):323-8. PubMed PMID: 10759818.