

University of Massachusetts Medical School

eScholarship@UMMS

---

School of Medicine Student Publications

School of Medicine

---

2015-3

## Prehabilitation Before Lumpectomy Can Prevent Loss of Range of Motion

Zehra B. Omer

*University of Massachusetts Medical School*

*Et al.*

Let us know how access to this document benefits you.

Follow this and additional works at: [https://escholarship.umassmed.edu/som\\_pubs](https://escholarship.umassmed.edu/som_pubs)



Part of the [Orthopedics Commons](#), and the [Rehabilitation and Therapy Commons](#)

---

### Repository Citation

Omer ZB, Baima J. (2015). Prehabilitation Before Lumpectomy Can Prevent Loss of Range of Motion.

School of Medicine Student Publications. Retrieved from [https://escholarship.umassmed.edu/som\\_pubs/](https://escholarship.umassmed.edu/som_pubs/)

1

This material is brought to you by eScholarship@UMMS. It has been accepted for inclusion in School of Medicine Student Publications by an authorized administrator of eScholarship@UMMS. For more information, please contact [Lisa.Palmer@umassmed.edu](mailto:Lisa.Palmer@umassmed.edu).

# Prehabilitation Before Lumpectomy Can Prevent Loss of Range of Motion

Zehra Omer, BA <sup>1</sup>, Jennifer Baima, MD <sup>1,2</sup>

<sup>1</sup> University of Massachusetts Medical School, <sup>2</sup>University of Massachusetts Memorial Health Care

## ABSTRACT

Decline in physical functioning such as loss of ROM, decreased strength, and pain following surgery for breast cancer is a well-documented phenomenon associated with difficulties in performing activities of daily living (ADL). Studies have shown that rehabilitation interventions during the treatment period following breast cancer surgery result in improvements in shoulder pain and range of motion; however, no study to date has investigated the effectiveness of interventions initiated before surgery (prehabilitation) for breast cancer.

Here, we report the case of a 73 year old woman with a 20 year history of bilateral subacromial bursitis and left shoulder pain who began an independent daily shoulder exercise regimen as instructed by a physiatrist 2.5 weeks prior to left sided lumpectomy for breast cancer, and continued the exercises following the operation. One month post-surgery, physical exam revealed no loss in range of motion (ROM) in flexion and abduction of the left and right shoulders. The patient reported intermittent pain, manageable with NSAIDs, which started only after tamoxifen use.

KEY WORDS: Breast cancer surgery, Shoulder Pain, Prehabilitation

## INTRODUCTION

Some breast cancer patients experience shoulder pain and limited shoulder abduction for months to years after surgery. This is particularly common in breast cancer patients who have undergone axillary lymph node dissection. Worse pain does not always correlate with time since surgery or advanced age. In addition, unfavorable changes in the size and function of shoulder muscles have been documented after breast cancer treatment. Rehabilitation throughout the course of treatment including surgery, chemotherapy, and radiation has been shown to combat some of these changes after treatments.

Prehabilitation, the use of exercise before an intervention to improve outcomes after an intervention, for even as few as two weeks before surgery for lung cancer can lung function and improve decrease postoperative respiratory morbidity. This has been demonstrated in patients with COPD and lung cancer, who might not otherwise have been candidates for life-saving lung resection surgery. Similarly, the use of trimodal prehabilitation (exercise, anxiety reduction, and nutrition) improves postoperative outcomes in colorectal patients. Although there have been no clinical trials investigating the efficacy of prehabilitation for shoulder pain, diminished range of motion, and weakness after breast cancer surgery, there is one case report that demonstrates improvement in expected function in a patient who had prehabilitation prior to receiving chemotherapy treatment of breast cancer.

A prehabilitation program of universal exercises, with a focus on shoulder abduction, may provide significant benefit to this patient population.

## CASE DESCRIPTION

This is the case of a 73 year old woman with a 20 year history of episodic bilateral subacromial bursitis and chronic persistent left shoulder pain whose pain has been managed with over-the-counter naproxen and aspirin.

She does not report any history of trauma to the neck or left shoulder. Her pain is primarily in the left anterior shoulder. It is worse with reaching and better with rest. Although she found physical therapy helpful for her lumbar stenosis, she has not found good exercises for her shoulder.

Functionally, she is independent in all activities of daily living. Her past medical history is significant for osteoarthritis, chronic back pain due to prior traumatic compression fracture and lumbar stenosis managed with exercises.

The patient was diagnosed one week prior to physiatry appointment with a 9-mm well-differentiated invasive ductal carcinoma in the upper outer quadrant of left breast. She was referred to physiatry by her oncology provider prior to left sided lumpectomy with possible axillary lymph node dissection.

At the time of initial physical exam, she rated her left shoulder pain (ipsilateral to breast cancer) at 2/10. Inspection of the trunk and upper limbs revealed no focal atrophy or rashes. No spine or upper limb deformities were detected. There was no palpable cervical lymphadenopathy. There was minimal tenderness over the left subacromial bursa. Spurling's test was negative. There was a painful arc on the left. Strength was normal and symmetric in the upper limbs throughout; however, the patient reported pain with resisted shoulder abduction and external rotation. Abduction range of motion was 120° on the right and 110° on the left on goniometer measurement.

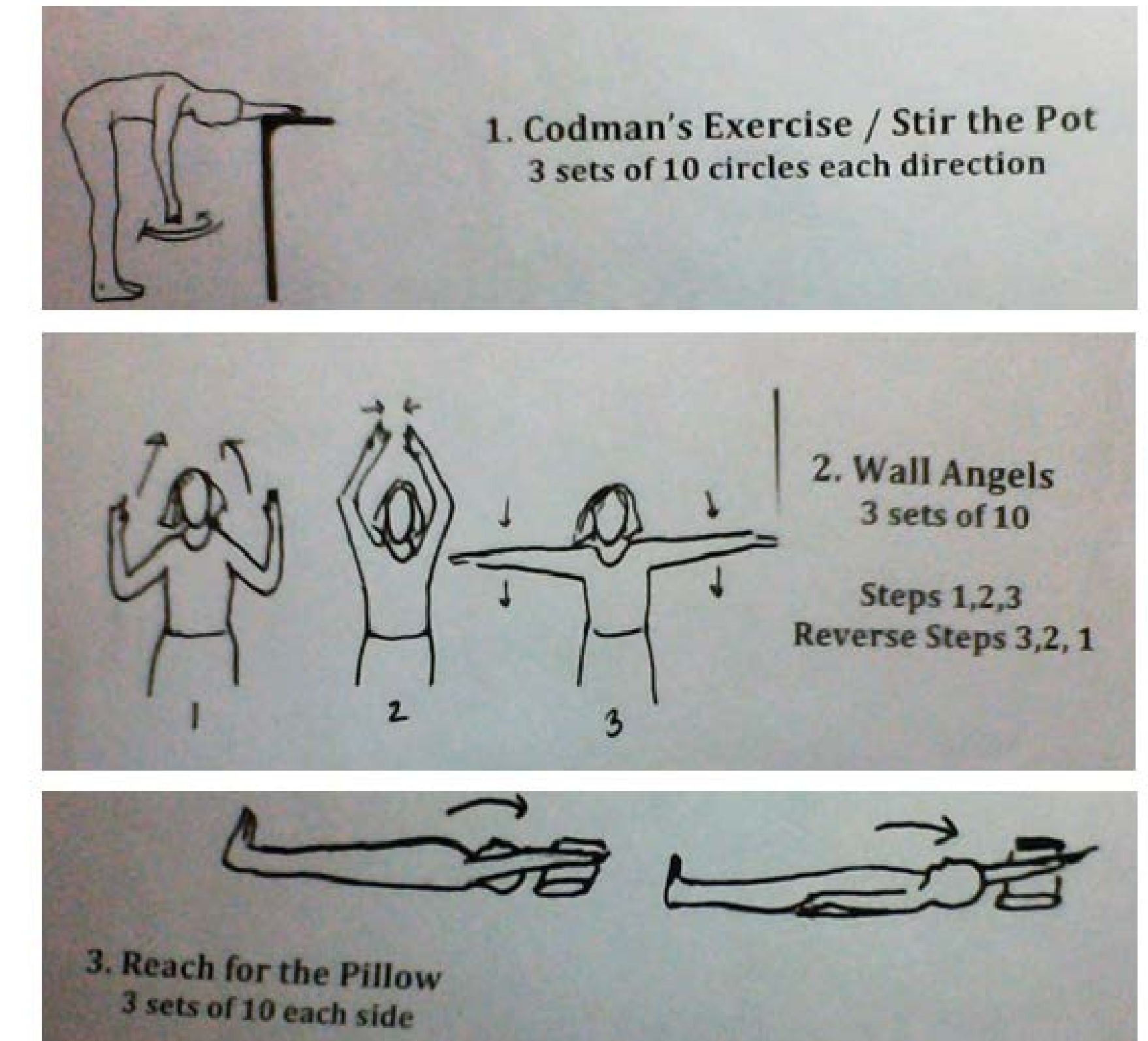
## INTERVENTION

The patient was instructed to follow an independent daily shoulder exercise regimen (Figure xx) at home until her scheduled lumpectomy (two and a half weeks after beginning the exercises) and continue the exercises following the operation.

The operation consisted of left breast lumpectomy with sentinel lymph node biopsy. The patient tolerated the procedure well. She reported performing these exercises as instructed, with the exception of the "wall angels."

## Correspondence:

Zehra B. Omer ([zehra.omer@umassmed.edu](mailto:zehra.omer@umassmed.edu)),  
Jennifer Baima, MD ([jennifer.baima@umassmemorial.org](mailto:jennifer.baima@umassmemorial.org))



## RESULTS

One month post-surgery, the patient rated her shoulder pain as 0/10. Physical exam revealed no loss in range of motion (ROM) in flexion and abduction of the left and right shoulders. The patient reported intermittent pain, manageable with NSAIDs, which started only after tamoxifen use.

## CONCLUSION

A daily regimen of a few independent shoulder exercises prior to and following lumpectomy for breast cancer may prevent the development of shoulder dysfunction that is often reported after cancer treatment.

## REFERENCES