

2015-04-29


Adipose Tissue Therapeutics for Scar Rehabilitation after Thermal Injury

Dylan Perry
University of Massachusetts Medical School

Et al.

Let us know how access to this document benefits you.

Follow this and additional works at: <https://escholarship.umassmed.edu/ssp>

 Part of the [Pathological Conditions, Signs and Symptoms Commons](#), [Plastic Surgery Commons](#), [Skin and Connective Tissue Diseases Commons](#), [Therapeutics Commons](#), and the [Tissues Commons](#)

Repository Citation

Perry, Dylan; Lujan-Hernandez, Jorge R.; Chappell, Ava; Min, So Yun; Appasani, Raghu; Rojas-Rodriguez, Raziell; Chin, Michael S.; Corvera, Silvia; and Lalikos, Janice F., "Adipose Tissue Therapeutics for Scar Rehabilitation after Thermal Injury" (2015). University of Massachusetts Medical School. *Senior Scholars Program*. Paper 191.

<https://escholarship.umassmed.edu/ssp/191>

This material is brought to you by eScholarship@UMMS. It has been accepted for inclusion in Senior Scholars Program by an authorized administrator of eScholarship@UMMS. For more information, please contact Lisa.Palmer@umassmed.edu.

Introduction

THE PROBLEM

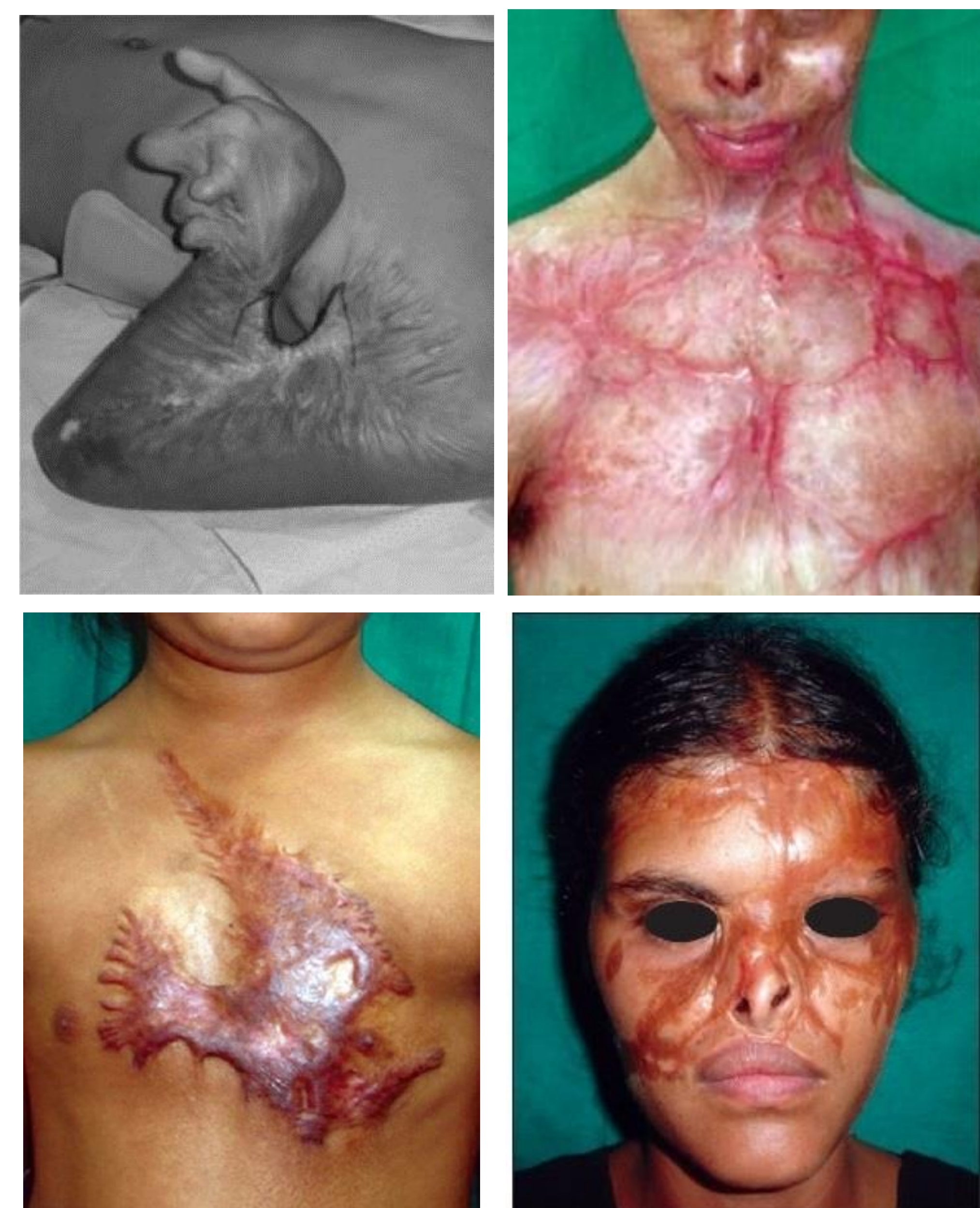- Burn injuries are common and always lead to scarring. Deep burns and those taking longer to heal often heal pathologically.
- Scarring, especially pathological hypertrophic scarring, leads to morbid symptoms (pain, pruritus), functional impairment, and negative aesthetic and psychiatric consequences.
- Traditional treatment is excision and skin grafting, a large operation with donor site morbidity and is problematic in complex anatomical areas (face, hands). Other treatment modalities (lasers, silicone, steroids) have side effects, low effectiveness, or lack of supporting evidence.

A POTENTIAL SOLUTION

- Autologous adipose tissue grafting ("Fat Grafting") and adipose-derived stem cell (ADSC) therapy may improve wound healing and scar outcomes in acute burn, excisional, and radiation skin injury models.
- Clinical case reports suggest adipose therapeutics may improve the remodeling of chronically scarred skin tissue by improving skin color, texture, pliability, and patient symptoms. At least one clinical trial is ongoing.
- Most basic research focuses on acute phase intervention, few if any studies examine adipose derived therapeutics for improved remodeling of chronic scars.

PROJECT GOALS

- Determine if adipose tissue can improve scar remodeling subacutely after acute wound healing phases have concluded in a mouse model of thermal injury.
- Compare the effects of processed lipoaspirate to adipose-derived stem cells.



Examples of burn scarring. Hypertrophic scar areas are raised and erythematous. Note also changes in texture, pigmentation, and contraction of skin limiting mobility.

Goel A, Shrivastava P. Post-burn scars and scar contractures. Indian J Plast Surg. 2010 Sep;43(Suppl):S63-71.

MARIANO E, ILFELD B, CHENG G, NICODEMUS H, SANTHANAM SURESH Feasibility of ultrasound-guided peripheral nerve block catheters for pain control on pediatric medical missions in developing countries. Paediatr Anaesth. 2008 July; 18(7): 598-601.

Materials & Methods

- N = 50 CD1 Nu/Nu (Athymic, nude) mice received standardized 70°C 10s burn (under anesthesia and analgesia) with a brass rod to dorsal skin and monitored for six weeks while chronic scars formed (Fig 1-3).
- At six weeks animals were randomized to five groups (Table 1); non-injected controls received no injection, other groups received subcutaneous injection of 0.6mL human lipoaspirate, human ADSCs in matrigel hydrogel suspension, or matrigel control. Adipose tissue from discarded human pannus. ADSCs from SVF ex-vivo culture.
- Skin perfusion measured with Hyperspectral Imaging (HSI) and digital photos were taken at 4 time points.
- Mice were sacrificed at 10 weeks post-burn (PB) (4 weeks after engraftment) for skin histology.
- Scar wound area and oxy and deoxy hemoglobin (HSI measures) were determined at all time points.
- Skin tissue samples were stained for vascularity (CD31) and collagen composition (Picro-Sirius red, Masson's Trichrome). Matrigel explants were H&E stained.

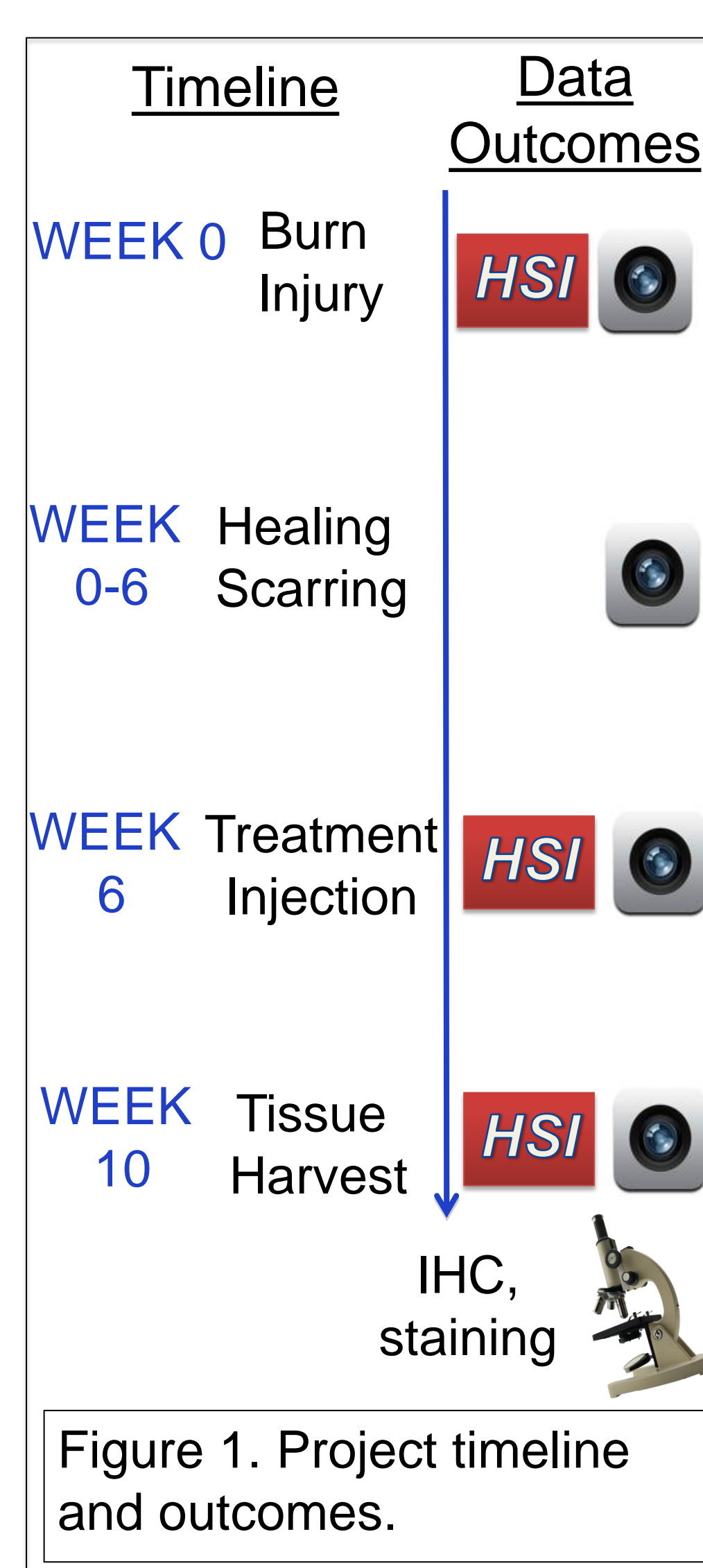

Figure 1. Project timeline and outcomes.

Table 1	Group 1	Group 2	Group 3	Group 4	Group 5
Treatment	Non-injected Control	Matrigel Control	Human high density Lipoaspirate	Low Dose (10 ⁴) ADSCs in Matrigel	High Dose (10 ⁶) ADSCs in Matrigel
Sample	N=10	N=10	N=10	N=10	N=10

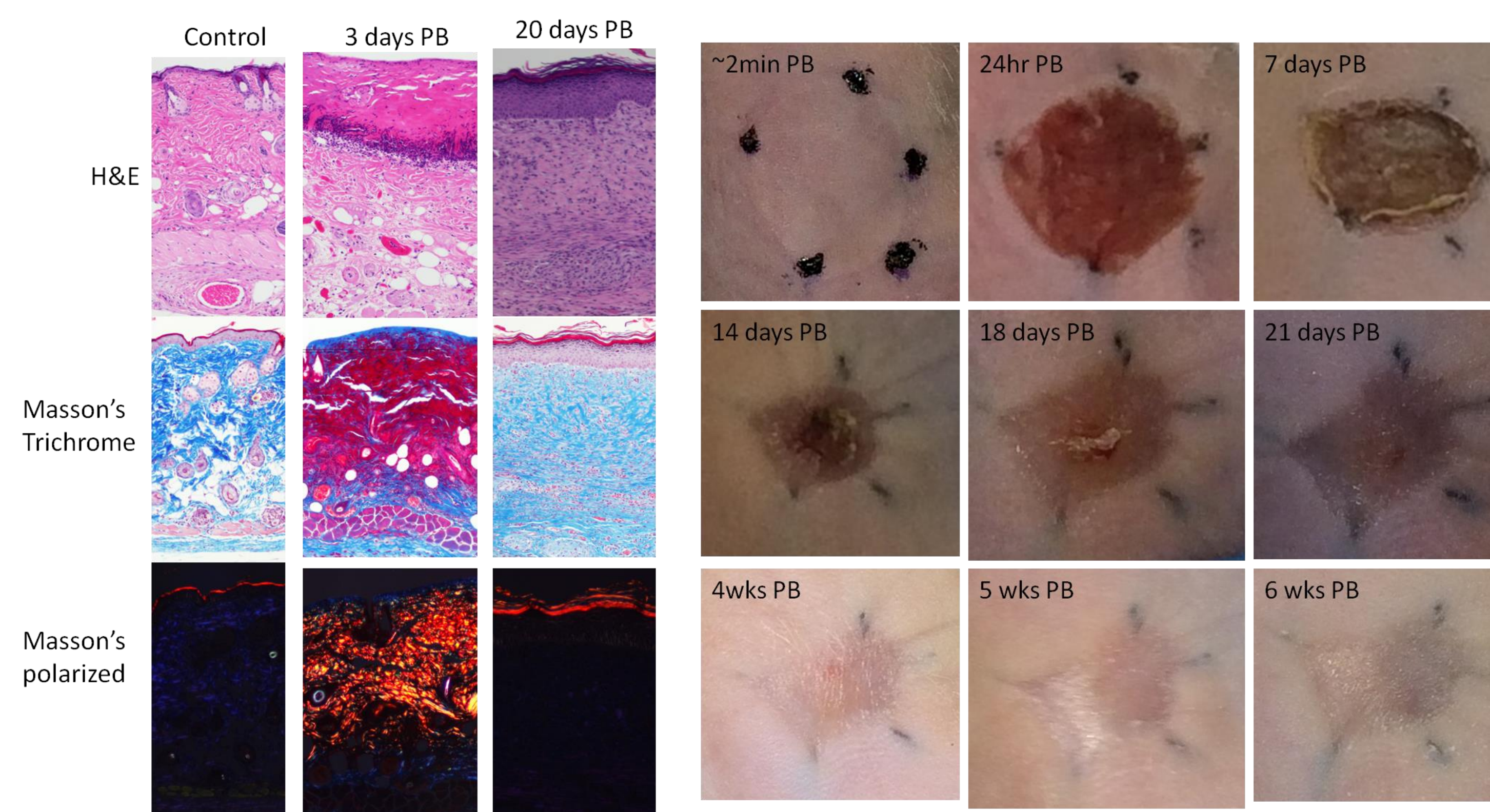


Figure 2. Scar micro and macroscopic progression from pilot study. Fig 3 (below) shows scar area progression through 6 weeks post-burn due to scar contraction.

Results

- **Scar wound area:** Lipoaspirate treated mice had significantly reduced perceived scar area compared to controls at 10 weeks (Fig 4).
- **Histology:** CD31 IHC trouble. Dermal vessels visualized on Masson's Trichrome counted in 3 hpf/slide show increase in G3 compared to G1 (Fig 5). Collagen picro photomorphometry ongoing. H&E stain of matrigel explants show living cells within hydrogel matrix.
- **Hyperspectral imaging:** Changes in oxy, deoxy, and total hemoglobin (Hb) consistent all mice until week 6 prior to treatment (not shown). G3 significantly increased oxy Hb from week 6 to 10 compared to other groups (Fig 6). G3-5 significantly lower deoxy Hb compared G1 10:6 wks (~-0.9, not shown). Total Hb reduced (~-0.9) in G4-5 compared to G1 at 10:6 wks (not shown).
- **ADSC FACS analysis:** CD34-, CD45-, CD24-, CD144-, CD90+, CD44+, CD29+, CD73 and CD105 mostly – (Fits MSC phenotype.)

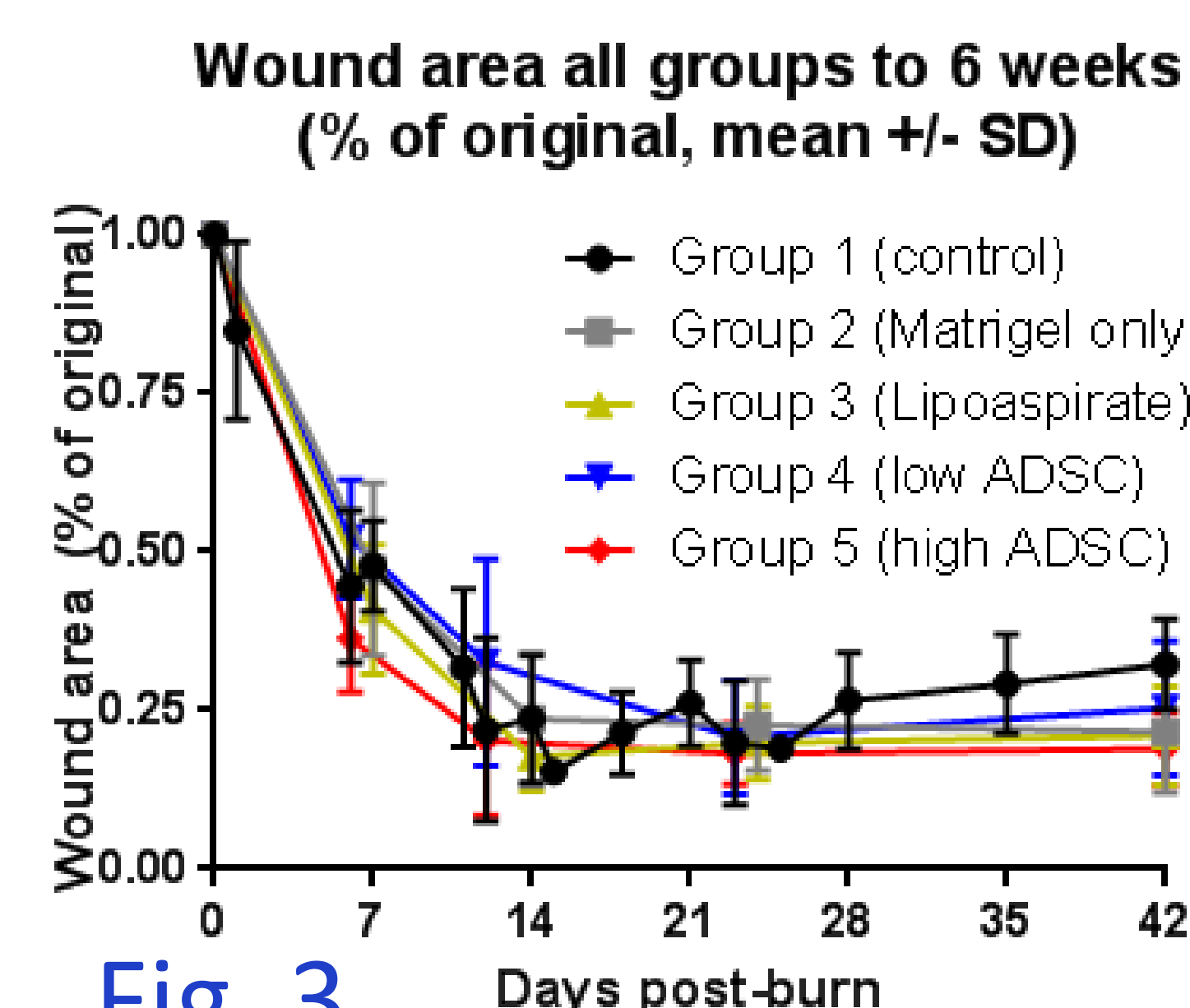


Fig. 3

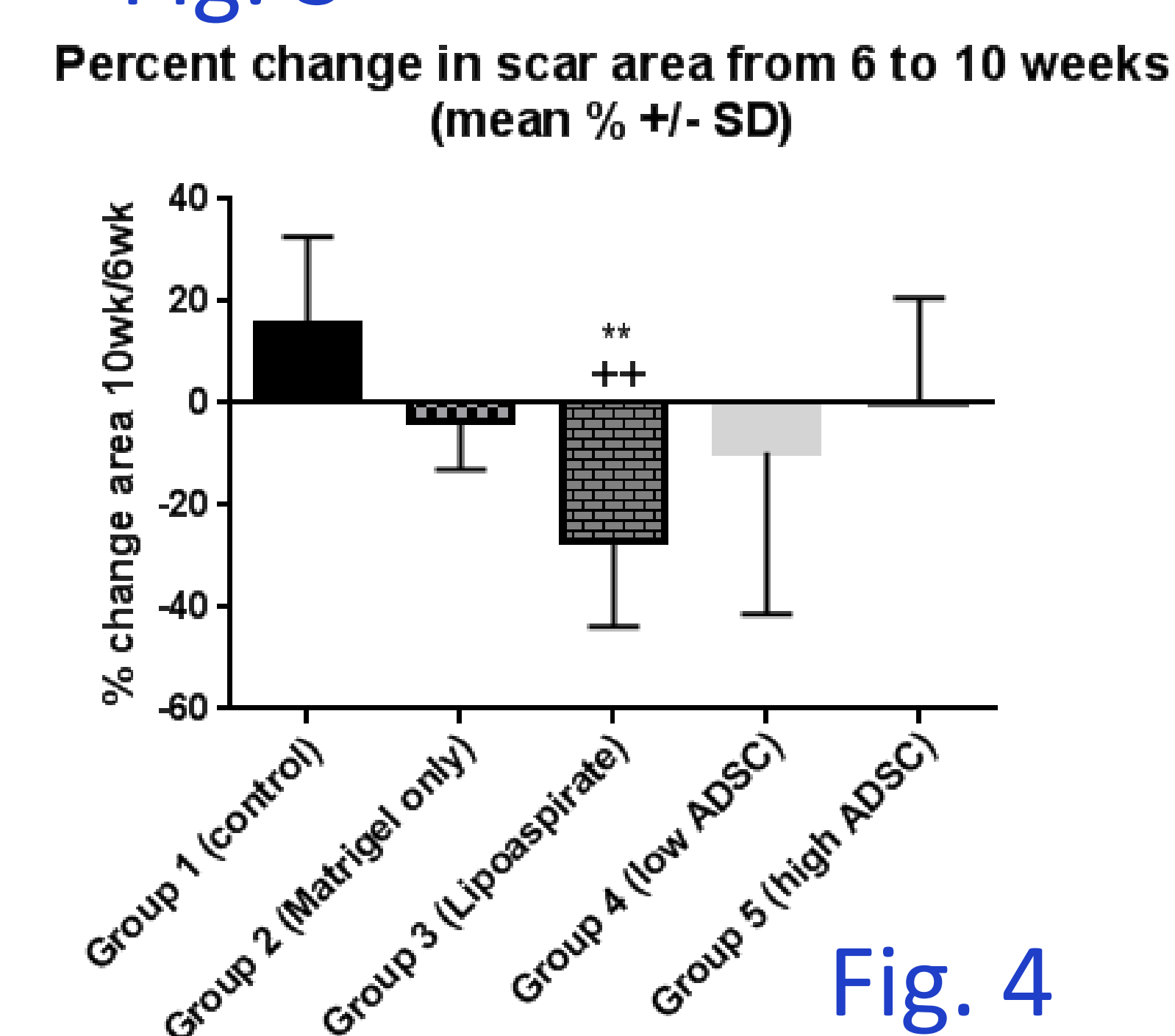


Fig. 4

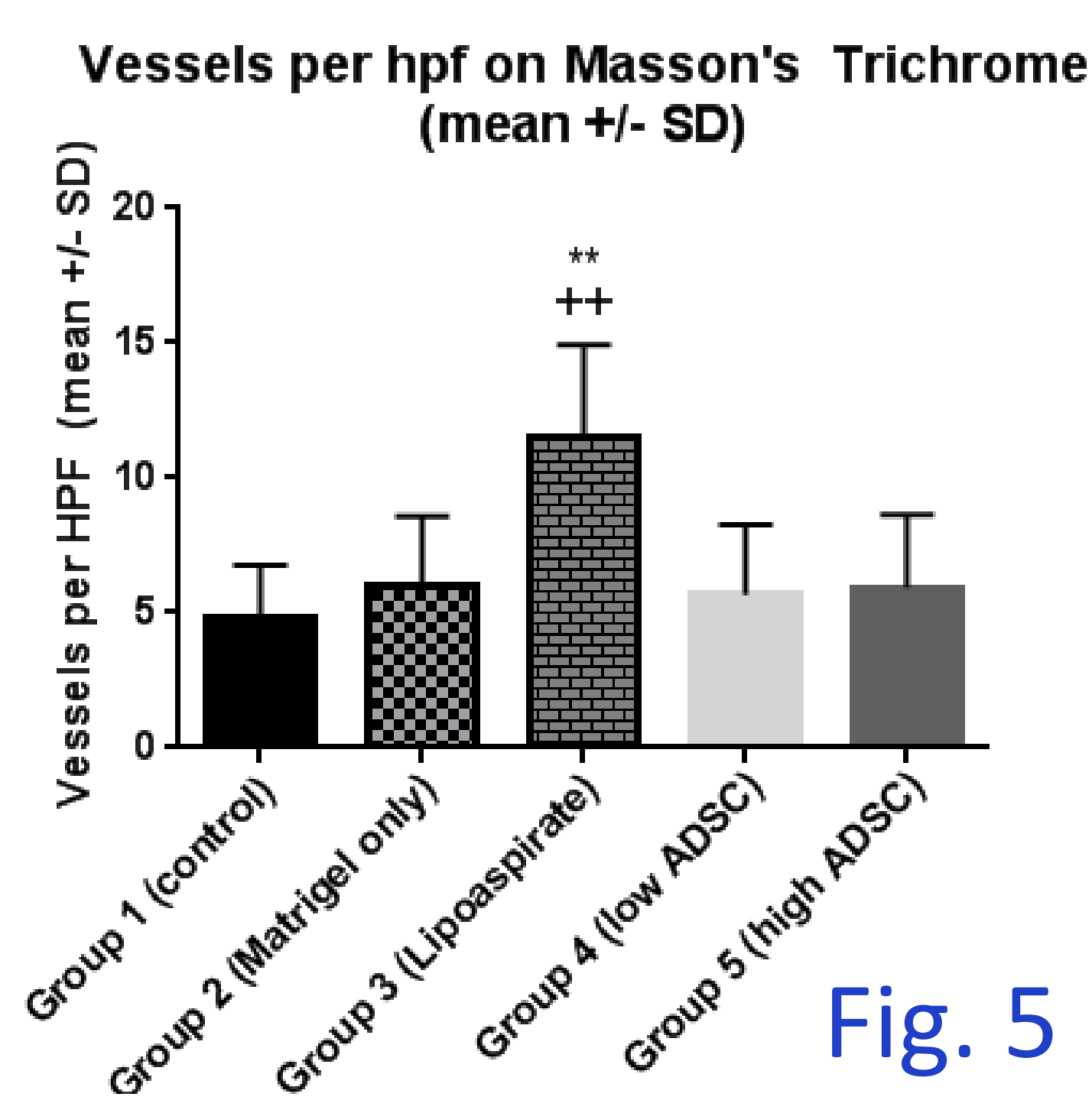


Fig. 5

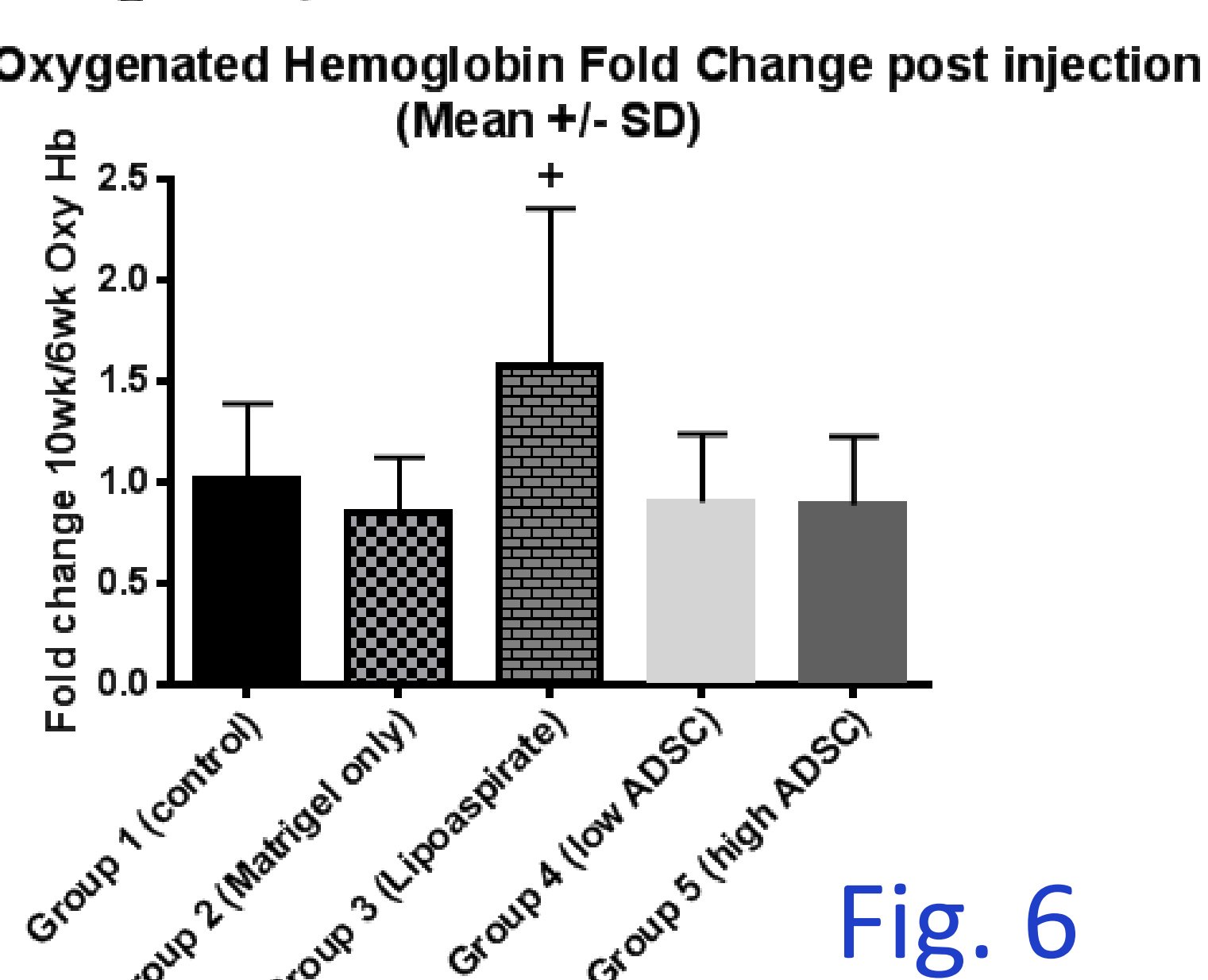


Fig. 6

* p < 0.05 vs. group 1, ** p < 0.01 vs. group 1, + p < 0.05 vs. group 2, ++ p < 0.01 vs. group 2

Conclusions

- Lipoaspirate may improve scar remodeling, possibly mediated by increased blood vessel density improving oxygenation, resulting in smaller perceived scar area.
- Lipoaspirate may retain a native scaffold allowing improved cell survival and angiogenesis preferentially to de novo vasculogenesis from direct ADSC differentiation.
- ADSCs, although promising in other studies, did not improve scar area, perfusion, or BV density in this model. Matrigel may have contributed to this finding as growth factor penetration to healing site may be limited.
- Limitations: Variability in mouse skin phenotype may have contributed error. Burn models are difficult to standardize: burn injury may not have been equal across all mice. Time and resources limited extent of analysis.

Future Directions

- Molecular analysis of scar remodeling targets such as TGF-β1/3, α-SMA, col1,3, VEGF, MMP9, SMAD-3.
- Experiment with other hydrogels or no hydrogel in case this was a factor in reducing ADSC efficacy.
- Continue attempts at improving photomorphometric analysis of picrosirius red collagen staining.
- Include a "supercharged" lipoaspirate group for comparison (Lipo + ADSCs).
- Consider porcine studies, a higher fidelity human skin model and better model of hypertrophic scarring.
- Consider consultation with dermatopathology experts for new clues for histological analysis.

References

1. Klinger M, Marazzi M, Vigo D, Torre M. Fat injection for cases of severe burn outcomes: a new perspective of scar remodeling and reduction. Aesthetic Plast Surg. 2008 May;32(3):465-9.
2. Sultan SM, Barr JS, Butala P, Davidson EH, Weinstein AL, Knobel D, Saadeh PB, Warren SM, Coleman SR, Hazen A. Fat grafting accelerates revascularisation and decreases fibrosis following thermal injury. J Plast Reconstr Aesthet Surg. 2012 Feb;65(2):219-27.
3. Yun IS, Jeon YR, Lee WJ, Lee JW, Rah DK, Tark KC, Lew DH. Effect of human adipose derived stem cells on scar formation and remodeling in a pig model: a pilot study. Dermatol Surg. 2012 Oct;38(10):1678-88.
4. Klinger M, Caviglioli F, Klinger FM, Giannasi S, Bandi V, Banzatti B, Forcellini D, Maione L, Catania B, Vinci V. Autologous fat graft in scar treatment. J Craniofac Surg. 2013 Sep;24(5):1610-5.
5. Hassan WU, Greiser U, Wang W. Role of adipose-derived stem cells in wound healing. Wound Repair Regen. 2014 May-Jun;22(3):313-25.
6. Loder S, Peterson JR, Agarwal S, Eboda O, Brownley C, DeLaRosa S, Ranganathan K, Cederna P, Wang SC, Levi B. Wound healing after thermal injury is improved by fat and adipose-derived stem cell isografts. J Burn Care Res. 2015 Jan-Feb;36(1):70-6.
7. Domergue S, Jorgensen C, Noël D. Advances in Research in Animal Models of Burn-Related Hypertrophic Scarring. J Burn Care Res. 2014 Oct 29.

Contact Info:

Dylan Perry
Medical Student, MS4
Division of Plastic Surgery
Dylan.Perry@UMassMed.edu