

University of Massachusetts Medical School

**eScholarship@UMMS**

---

[Open Access Articles](#)

[Open Access Publications by UMMS Authors](#)

---

2000-07-08


## The N-methyl-D-aspartate antagonist CNS 1102 protects cerebral gray and white matter from ischemic injury following temporary focal ischemia in rats

Wolf-Rudiger Schabitz

*Et al.*

### Let us know how access to this document benefits you.

Follow this and additional works at: <https://escholarship.umassmed.edu/oapubs>

 Part of the [Life Sciences Commons](#), and the [Medicine and Health Sciences Commons](#)

---

#### Repository Citation

Schabitz W, Li F, Fisher M. (2000). The N-methyl-D-aspartate antagonist CNS 1102 protects cerebral gray and white matter from ischemic injury following temporary focal ischemia in rats. Open Access Articles. Retrieved from <https://escholarship.umassmed.edu/oapubs/1661>

This material is brought to you by eScholarship@UMMS. It has been accepted for inclusion in Open Access Articles by an authorized administrator of eScholarship@UMMS. For more information, please contact [Lisa.Palmer@umassmed.edu](mailto:Lisa.Palmer@umassmed.edu).

# Stroke

American Stroke  
Association<sup>SM</sup>

A Division of American  
Heart Association



JOURNAL OF THE AMERICAN HEART ASSOCIATION

## **The N-Methyl-D-Aspartate Antagonist CNS 1102 Protects Cerebral Gray and White Matter From Ischemic Injury Following Temporary Focal Ischemia in Rats Editorial Comment**

Wolf-R. Schäbitz, Fuhai Li, Marc Fisher and Pak H. Chan

*Stroke* 2000;31;1709-1714

Stroke is published by the American Heart Association, 7272 Greenville Avenue, Dallas, TX 75214  
Copyright © 2000 American Heart Association. All rights reserved. Print ISSN: 0039-2499. Online  
ISSN: 1524-4628

The online version of this article, along with updated information and services, is located on the World Wide Web at:

<http://stroke.ahajournals.org/cgi/content/full/31/7/1709>

Subscriptions: Information about subscribing to Stroke is online at  
<http://stroke.ahajournals.org/subscriptions/>

Permissions: Permissions & Rights Desk, Lippincott Williams & Wilkins, a division of Wolters Kluwer Health, 351 West Camden Street, Baltimore, MD 21202-2436. Phone: 410-528-4050. Fax: 410-528-8550. E-mail:  
[journalpermissions@lww.com](mailto:journalpermissions@lww.com)

Reprints: Information about reprints can be found online at  
<http://www.lww.com/reprints>

# The N-Methyl-D-Aspartate Antagonist CNS 1102 Protects Cerebral Gray and White Matter From Ischemic Injury Following Temporary Focal Ischemia in Rats

Wolf-R. Schäbitz, MD; Fuhai Li, MD; Marc Fisher, MD

**Background and Purpose**—Cerebral white matter is as sensitive as gray matter to ischemic injury and is probably amenable to pharmacological intervention. In this study we investigated whether an N-methyl-D-aspartate (NMDA) antagonist, CNS 1102, protects not only cerebral gray matter but also white matter from ischemic injury.

**Methods**—Ten rats underwent 15 minutes of temporary focal ischemia and were blindly assigned to CNS 1102 intravenous bolus injection (1.13 mg/kg) followed by intravenous infusion (0.33 mg/kg per hour) for 3.75 hours or to vehicle (n=5 per group) immediately after reperfusion. Seventy-two hours after ischemia, the animals were perfusion fixed for histology. The severity of neuronal necrosis in the cortex and striatum was semiquantitatively analyzed. The Luxol fast blue–periodic acid Schiff stain and Bielschowsky's silver stain were used to measure optical densities (ODs) of myelin and axons, respectively, in the internal capsule of both hemispheres, and the OD ratio was calculated to reflect the severity of white matter damage.

**Results**—Neuronal damage in both the cortex and the striatum was significantly better in the drug-treated group than in the placebo group ( $P<0.05$ ). The OD ratio of both the axons ( $0.93\pm 0.08$  versus  $0.61\pm 0.18$ ;  $P<0.01$ ) and the myelin sheath ( $0.95\pm 0.07$  versus  $0.67\pm 0.19$ ;  $P=0.01$ ) was significantly higher in the CNS 1102 group than in the placebo group. The neurological score was significantly improved in the drug-treated group ( $P<0.05$ ).

**Conclusions**—The NMDA receptor antagonist CNS 1102 protects not only cerebral gray matter but also white matter from ischemic injury, most probably by preventing degeneration of white matter structures such as myelin and axons. (*Stroke*. 2000;31:1709-1714.)

**Key Words:** cerebral ischemia, focal ■ middle cerebral artery occlusion ■ N-methyl-D-aspartate ■ white matter ■ rats

Acute central nervous system injuries such as ischemic stroke are accompanied by a marked elevation in the extracellular glutamate concentration.<sup>1</sup> Toxic activation of glutamate receptors, or excitotoxicity, is an important trigger of neuronal death.<sup>2</sup> Glutamate-triggered  $\text{Ca}^{2+}$  influx can be specifically blocked by antagonists of the receptor-mediated,  $\text{Ca}^{2+}$ -conducting N-methyl-D-aspartate (NMDA) channels that are predominantly on neurons. NMDA receptor antagonists such as MK 801 or CNS 1102 (Cerestat) protect gray matter from ischemic injury.<sup>3-6</sup> Cerebral white matter was shown to be sensitive to acute ischemia and can probably be protected by pharmacological intervention.<sup>7</sup> In contrast to gray matter, glutamate is not thought to play an important role in white matter ischemic injury.<sup>8,9</sup> As suggested by in vitro studies,  $\text{Ca}^{2+}$  overload in ischemic axons is related to activation of  $\text{Na}^{+}$  channels rather than a function of a glutamate receptor stimulation.<sup>9</sup> Clinically, it is important to understand and treat white matter ischemic changes that are common in the elderly. To our knowledge, no in vivo studies exist concerning pharmacological protection of cerebral white

## See Editorial Comment, page 1714

matter changes after cerebral ischemia. In this study we investigated whether pharmacological intervention with a potent neuroprotectant, the noncompetitive NMDA antagonist CNS 1102, could be used to protect white matter structures after focal cerebral ischemia.

## Materials and Methods

All procedures were approved by our institutional Animal Research Committee. In 10 male Sprague-Dawley rats weighing 300 to 350 g, 15 minutes of temporary focal cerebral ischemia was induced by the intraluminal suture occlusion method. All experiments were performed in a blinded manner. Nonfasted animals were randomly assigned before surgery to receive CNS 1102 dissolved in saline (n=5) or the same amount of vehicle (n=5).

The animals were intraperitoneally anesthetized with chloral hydrate (400 mg/kg body wt). The left femoral artery was cannulated with PE-50 polyethylene tubing for continuous monitoring of arterial blood pressure and blood sampling for analysis of blood gases. Measurements were recorded before surgery and 30 and 180 minutes after ischemic onset. Rectal temperature was maintained during

Received January 27, 2000; final revision received April 20, 2000; accepted April 20, 2000.

From the Department of Neurology, University of Massachusetts Memorial Health Care and University of Massachusetts Medical School, Worcester. Reprint requests to Marc Fisher, MD, Department of Neurology, UMass Memorial Health Care, 119 Belmont St (Memorial Campus), Worcester, MA, 01605.

© 2000 American Heart Association, Inc.

Stroke is available at <http://www.strokeaha.org>

## Physiological Variables in CNS 1102-Treated Animals and Controls

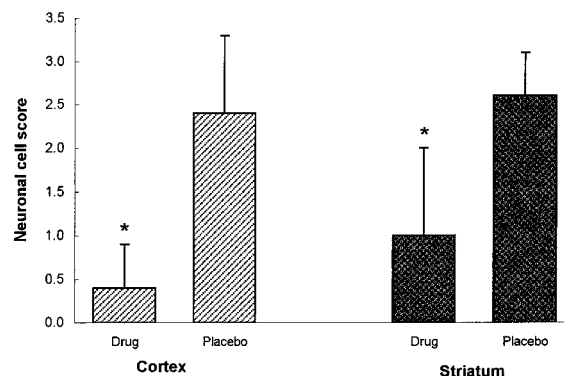
	CNS 1102	Controls
Baseline		
pH	7.32±0.03	7.35±0.03
Pco <sub>2</sub> , mm Hg	45±10	46±3
Po <sub>2</sub> , mm Hg	75±13	74±6
MABP, mm Hg	64±5	64±7
Body temperature, °C	36.3±0.6	36.6±0.5
30 min after MCAO		
pH	7.35±0.03	7.33±0.04
Pco <sub>2</sub> , mm Hg	45±5	46±7
Po <sub>2</sub> , mm Hg	71±12	71±14
MABP, mm Hg	70±14	68±11
Body temperature, °C	37.1±0.2	36.9±0.3
180 min after MCAO		
pH	7.34±0.03	7.34±0.02
Pco <sub>2</sub> , mm Hg	42±5	42±4
Po <sub>2</sub> , mm Hg	78±7	82±11
MABP, mm Hg	78±10	78±8
Body temperature, °C	37.1±0.2	37.0±0.2

Data are mean±SD. MABP indicates mean arterial blood pressure; MCAO, middle cerebral artery occlusion. Differences between groups in each variable were not statistically significant ( $P>0.05$ , 1-factor ANOVA).

surgery at 37°C with a feedback-regulated heating lamp. The right middle cerebral artery was occluded via a transvascular approach, as previously described.<sup>10,11</sup> Briefly, the right common carotid artery and the right external carotid artery were exposed through a midline neck incision. The proximal portions of the common carotid artery and the external carotid artery were first ligated with a 3-0 silk suture. A 4-0 monofilament nylon suture (length 40 mm), whose tip had been rounded by heating near a flame and then coated with silicon (Bayer), was inserted through an arteriotomy of the common carotid artery and gently advanced into the internal carotid artery. Positioned approximately 17 mm from the bifurcation, the tip of the suture occludes the proximal anterior cerebral artery, the origins of the middle cerebral artery, and the posterior communicating artery. To prevent bleeding, the common carotid artery was loosely ligated with a 3-0 silk suture just distal to the arteriotomy.

An intravenous bolus injection of the drug (1.13 mg/kg in saline) or the vehicle (saline) was started immediately after reperfusion (15 minutes after vessel occlusion), followed by a continuously intravenous infusion for 3.75 hours at a dose of 0.33 mg/kg per hour of CNS 1102 or physiological saline. CNS 1102 has a half-life of 63 minutes, is lipophilic, and easily crosses the blood-brain barrier, like most other noncompetitive NMDA antagonists.<sup>4</sup> The chemical structure of CNS 1102 was reported in a previous study.<sup>4</sup> After discontinuation of the infusion, the animals were allowed to recover from the anesthesia and were neurologically scored with a 5-point scale: 0, no neurological deficit; 1, failure to extend left forepaw fully; 2, circling to the left; 3, falling to the left; and 4, no spontaneous walking with a depressed level of consciousness.

Over the next 3 days the animals had free access to food and water. The neurological examination was performed daily in all animals. On the fourth day the animals were anesthetized again with chloral hydrate and transcardially perfused fixed with 4% paraformaldehyde in 0.1 mmol/L phosphate buffer for histological and immunohistochemical studies. The heads were decapitated and were allowed to fix overnight in 4% paraformaldehyde. On the next day, the brains were removed from the skull and immersed again in the same fixative solution at 4°C. Each brain was then sectioned into 5



**Figure 1.** Neuronal cell damage in the striatum and cortex after 15 minutes of transient ischemia followed by 72 hours of reperfusion in the CNS 1102-treated group and placebo group ( $P<0.05$ , Mann-Whitney *U* test).

coronal slices of 2-mm slice thickness. These were labeled A (frontal) through E (occipital). Histology sections (approximately 6  $\mu$ m thick) were obtained from the paraffin blocks and stained with hematoxylin and eosin (H&E), Luxol fast blue-periodic acid Schiff (LFB-PAS), Bielschowsky's silver impregnation, and glial fibrillary acidic protein (GFAP). The pathological assessments were performed by observers blinded to the treatment groups.

For the study of the white matter, 1 slice at the level of the anterior commissure was selected.<sup>7</sup> The LFB-PAS and Bielschowsky's silver stains were used to measure optical densities (ODs) of myelin (LFB-PAS) and axons (Bielschowsky's stain) in the ipsilateral internal capsule and contralateral homologous area. The measured OD values reflect the stainability of white matter, and a decreased OD value indirectly reflects destruction of white matter because of loss of stainability. The OD measurement was previously used to evaluate the activity of glial cells.<sup>12</sup> Measurements were made on images collected with a video-imaging microscope system with the use of a computerized cytomorphometric analysis (Global Laboratory Analysis System). At a magnification of  $\times 20$ , the ODs of 10 nonoverlapping areas of 5000  $\mu$ m<sup>2</sup> were measured from each side of the brain in the same corresponding area. The OD ratio in myelin and axons was calculated by dividing the ipsilateral OD by the contralateral OD. For quantification of neuronal damage, H&E stain was used to evaluate neuronal necrosis in the striatum and cortex with a 5-point scale: 0, no neuronal necrosis; 1, individual neuronal necrosis; 2, selective neuronal necrosis (SNN); 3, widespread neuronal necrosis; and 4, pannecrosis. GFAP staining was used to evaluate changes of glial cells.

After acquisition of all data, the randomization code was broken. Data were presented as mean±SD. One-factor ANOVA was used to compare physiological variables. White matter data (OD ratio) were compared between the 2 groups with an unpaired 2-tailed *t* test. A Mann-Whitney *U* test corrected for ties was performed for nonparametric variables (neurological score and gray matter data). A *P* value  $<0.05$  was considered statistically significant.

## Results

Physiological variables, presented in the Table, showed no significant differences between the 2 groups ( $P>0.05$ ). The percent body weight decline did not differ between the 2 groups (15.3% versus 13.4%). The neurological score at day 4 was significantly worse in the placebo than in the CNS 1102-treated group ( $1.0\pm 0.5$  versus  $0.4\pm 0.3$ ;  $P<0.05$ ).

The histopathological analysis revealed that 3 of the 5 rats in the placebo group had widespread neuronal necrosis in both the cortex and striatum, and 2 other rats had SNN in the striatum and individual neuronal necrosis or SNN in the frontoparietal cortex. These changes were accompanied by

astrogliosis and microglia activation. In the CNS 1102-treated rats, 2 rats showed normal cerebral gray matter, 1 had individual neuronal necrosis only in the striatum, and 2 other animals demonstrated SNN in the striatum and individual neuronal death in the cortex. Overall statistical analysis revealed that both cortical and striatal neuronal damage in the CNS 1102-treated group were significantly better than in the placebo group ( $P < 0.05$ ), as shown in Figure 1.

Representative photomicrographs chosen from the internal capsule from both groups are shown in Figure 2. White matter in the 2 control animals that had SNN in the gray matter appeared vacuolized. The myelin sheaths and axons were moderately damaged. A moderate astrocytic reaction with increased GFAP immunoreactivity and a few microglia occurred in the same area. Oligodendrocytes proliferated in the periphery of the white matter lesion. Three other animals in the control group that had severe ischemic lesions also developed severe white matter damage. Myelin sheaths lost their LFB-PAS stainability and appeared as empty spaces (vacuoles) separating myelin sheaths in the lesion areas of white matter (Figure 2B and 2E). Axons appeared as irregular, twisted profiles and showed segmental fragmentation with Bielschowsky's stain (Figure 2H). Increased cellular reactions occurred in the injured white matter that included inflammatory cells, in particular macrophages. Hypertrophied astrocytes with strong GFAP immunoreactivity and activated microglia were found in the lesion area. In the CNS 1102-treated group, 3 rats with essentially normal gray matter revealed no substantial damage to white matter. The 2 other animals with mild gray matter injury had mild vacuolization and mild damage of myelin sheaths with moderate astrocytic and microglial reactions (Figure 2C and 2F). Axons were well preserved (Figure 2I). Overall statistical analysis demonstrated that axonal injury in cerebral white matter (OD ratio:  $0.93 \pm 0.08$  in the CNS 1102-treated group versus  $0.61 \pm 0.18$  in the placebo group;  $P < 0.01$ ) and damage to the myelin sheath (OD ratio:  $0.95 \pm 0.07$  in the CNS 1102-treated group versus  $0.67 \pm 0.19$  in the placebo group;  $P = 0.01$ ) was significantly reduced by CNS 1102 treatment (Figure 3).

## Discussion

This study demonstrates that a noncompetitive NMDA receptor antagonist, CNS 1102, protects cortical and striatal neurons from ischemic injury and significantly reduces ischemic damage in white matter structures such as myelin and axons. This qualitative observation of reduced white matter injury should, in the future, be confirmed by a more quantitative approach such as a Western blot analysis of axonal and myelin injury. Clinically, CNS 1102 improved the neurological outcome. No significant difference in physiological parameters and weight loss was observed between the 2 groups during the experiment as it has been reported by other investigators.<sup>4,5</sup>

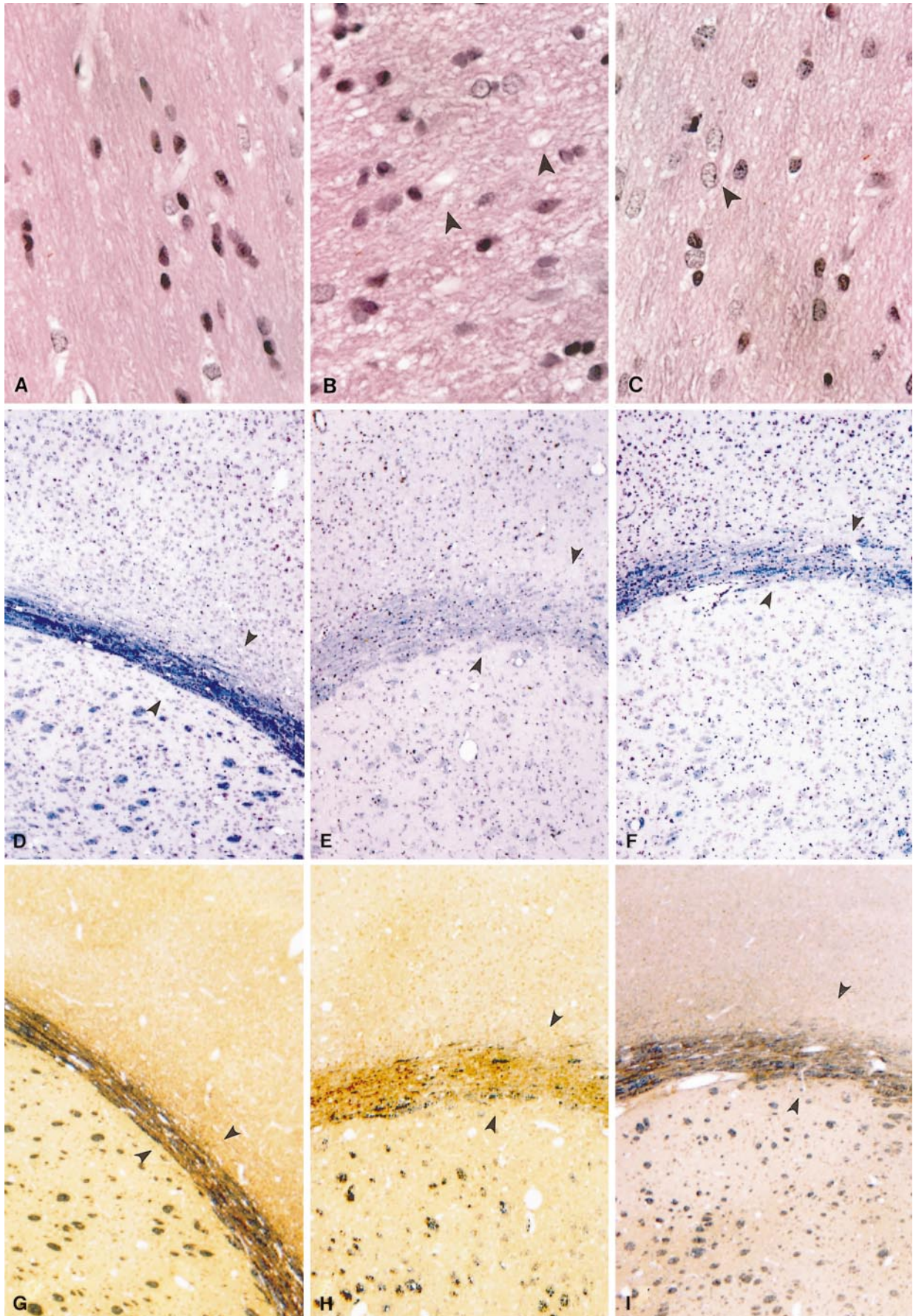
Cerebral ischemia triggers an excessive release of glutamate, producing overstimulation of glutamate receptors, especially the NMDA receptor. The subsequent cellular  $Ca^{2+}$  overload is generally thought to represent the "final common pathway," leading to necrotic cell death of neurons.<sup>13</sup> NMDA antagonists that prevent the  $Ca^{2+}$  influx through NMDA

receptor blockade of  $Ca^{2+}$  channels have successfully been used to treat neuronal injury after experimental ischemia in vivo.<sup>3-6</sup> CNS 1102 (Cerestat) in particular is a well-investigated NMDA antagonist that has potent neuroprotective effects.<sup>6</sup> CNS 1102 in this study protected striatal and cortical neurons from temporary focal cerebral ischemia. Similar results have been reported on ischemic lesion size with the use of the same dose after permanent and temporary focal cerebral ischemia.<sup>4,5</sup>

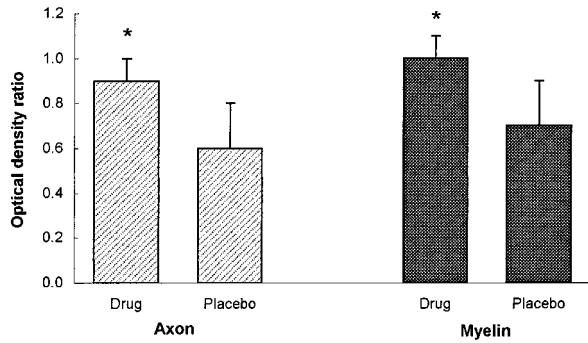
The main novel finding in this study is that CNS 1102 protects white matter structures such as axons and myelin from ischemic injury. This finding is of importance because it demonstrates that white matter damage after ischemia may be treatable and could be of particular clinical interest for the future treatment of lacunar strokes. Although studies have demonstrated that white matter is susceptible to ischemic injury, the mechanisms of white matter injury are not well characterized.<sup>7,14</sup> In contrast to gray matter ischemia, in vitro studies suggest that activation of glutamate receptors may not be a key event in the mediation of ischemic cerebral white matter injury. Recent studies suggested some possible explanations for ischemic white matter injury.<sup>8</sup> First, the  $Na^+, K^+$ -ATPase of CNS axons fails after ischemia, leading to accumulation of axoplasmic  $Na^+$  through noninactivating  $Na^+$  channels. Coupled with severe  $K^+$  depletion that results in large membrane depolarization, high intracellular  $Na^+$  stimulates the reverse operation of  $Na^+-Ca^{2+}$  exchanger, causing axonal  $Ca^{2+}$  overload that results in white matter injury by activating  $Ca^{2+}$ -dependent enzymes.<sup>8,9</sup> Accumulation of intracellular  $Ca^{2+}$  and subsequent damage to the myelin sheath can also occur through reversal of the electrogenic  $Na^+, K^+$ -glutamate transporter after axonal depolarization.<sup>8,15</sup> Second, oligodendrocytes that myelinate the axon can be damaged in vitro by glutamate exposure, which does not appear to involve glutamate receptor activation.<sup>16</sup> Third,  $\alpha$ -amino-3-hydroxy-5-methyl-4-isoxasole propionic acid (AMPA)/kainate seems to be more toxic to oligodendrocytes. It has been shown that oligodendrocytes contain the AMPA receptor and can be damaged in vivo by AMPA or kainate.<sup>17</sup> Lastly, degeneration secondary to gray matter damage, so-called wallerian degeneration, may be another important contributor to white matter injury. Excitotoxic lesions in the thalamus or basal ganglia have been shown experimentally to secondarily damage white matter structures such as the myelin and axon within 2 to 4 days.<sup>18</sup> White matter damage observed in the present study may be related to wallerian degeneration because survival time in our study was within this time frame (3 days), and the gray matter lesion was primarily in the striatum with selective neuronal necrosis in the cortex.

On the basis of the mechanisms of white matter injury described above, protection of white matter from ischemic injury may be obtained by blocking  $Na^+$  channel,<sup>8</sup> reducing  $Ca^{2+}$  load,<sup>8</sup> inhibiting AMPA receptors,<sup>8,17</sup> or protecting gray matter.<sup>8</sup> The protective effect of ketamine, an NMDA receptor antagonist, on anoxic optic nerve was previously reported and was supposed to be related to its blocking voltage-gated  $Na^+$  channels.<sup>19</sup> Interestingly, an NMDA receptor antagonist was demonstrated to protect the spinal cord from ischemic injury.<sup>20</sup> It is not known whether the NMDA antagonist









**Figure 3.** OD ratio between the ipsilateral and contralateral white matter (axon and myelin) in the CNS 1102-treated group and placebo group after 15 minutes of transient ischemia followed by 72 hours of reperfusion (\* $P < 0.05$ , unpaired 2-tailed  $t$  test).

exerted its action on spinal gray matter or white matter.<sup>8</sup> It seems unlikely that the protective affect of NMDA receptor antagonists on white matter is mediated by direct NMDA receptor, since neither the axon nor the myelin has been proven to contain NMDA receptors. The most plausible mechanism of the neuroprotective effect of CNS 1102 in the present study is likely a secondary prevention of white matter damage by neuroprotection of cerebral gray matter. Clearly, further studies will be needed to elucidate how NMDA receptor antagonists protect white matter from ischemic injury.

In this study white matter damage was induced with the intraluminal suture occlusion model. The short occlusion time was chosen to provide demonstrable white matter damage, to keep gray matter damage minimal, and to guarantee a long survival time. However, to further understand white matter damage in vivo and to explore how drugs protect white matter in vivo, an animal model of pure white matter ischemia would be useful. This is thus far not available for both technical and pathophysiological reasons.

In conclusion, the present study suggests that besides the previously known protective effects of this NMDA antagonist, additional protection of white matter structures such as myelin and axons after focal cerebral ischemia does occur. The role of NMDA antagonists in protecting white matter from ischemic injury needs further clarification. The study of in vivo white matter injury after focal ischemia is of particular clinical relevance because of the prevalence of lacunar strokes.

### Acknowledgments

This study was supported by the Harrington Neurological Research Fund. We thank Dr Kai-Feng Liu of Henry Ford Hospital, Detroit, Mich, for her help with the histology study.

### References

- Benevise H, Drejer J, Schousboe A, Diemer NH. Elevation of extracellular concentrations of glutamate and aspartate in rat hippocampus during transient cerebral ischemia monitored by intracerebral dialysis. *J Neurochem.* 1984;43:1369–1374.
- Choi DW. Glutamate neurotoxicity and diseases of the nervous system. *Neuron.* 1988;1:623–630.
- Park CK, Nehls DG, Graham DI, Teasdale GM, McCulloch J. The glutamate antagonist MK-801 reduces focal ischemic brain damage in the rat. *Ann Neurol.* 1988;24:543–551.
- Minematsu K, Fisher M, Li L, Davis MA, Knapp AG, Cotter RE, McBurney RN, Sotak CH. Effects of a novel NMDA antagonist on experimental stroke rapidly and quantitatively assessed by diffusion-weighted MRI. *Neurology.* 1993;43:397–403.
- Hasegawa Y, Latour LL, Sotak CH, Dardzinski BJ, Fisher M. Temperature dependent change of apparent diffusion coefficient of water in normal and ischemic brain of rats. *J Cereb Blood Flow Metab.* 1994;14:383–390.
- Lees KR. Cerestat and other NMDA antagonists in ischemic stroke. *Neurology.* 1997;49(suppl 4):S66–S69.
- Pantoni L, Garcia JH, Gutierrez JA. Cerebral white matter is highly vulnerable to ischemia. *Stroke.* 1996;27:1641–1647.
- Stys PK. Anoxic and ischemic injury of myelinated axons in CNS white matter: from mechanistic concepts to therapeutics. *J Cereb Blood Flow Metab.* 1998;18:2–25.
- Waxman SG, Black JA, Ransom BR, Stys PK. Anoxic injury of rat optic nerve: ultrastructural evidence for coupling between  $\text{Na}^+$  influx and  $\text{Ca}^{2+}$ -mediated injury in myelinated CNS axons. *Brain Res.* 1994;644:197–204.
- Zea Longa E, Weinstein PR, Carlson S, Cummins R. Reversible middle cerebral artery occlusion without craniectomy in rats. *Stroke.* 1989;20:84–91.
- Schäbitz WR, Schwab S, Spranger M, Hacke W. Intraventricular brain-derived neurotrophic factor reduces infarct size after focal cerebral ischemia in rats. *J Cereb Blood Flow Metab.* 1997;17:500–506.
- Ye Z-R, Liu K-F, Gutierrez JA, Garcia JH. Glial responses associated with transient MCA-occlusion and delayed neuronal death. *J Neuropathol Exp Neurol.* 1997;56:574. Abstract.
- Kristian T, Siesjö BK. Calcium in ischemic cell death. *Stroke.* 1998;29:705–718.
- Follis F, Scremin OU, Blisard KS, Scremin AM, Pett SB, Scott WJ, Kessler RM, Wernly JA. Selective vulnerability of white matter during spinal cord ischemia. *J Cereb Blood Flow Metab.* 1993;13:170–178.
- Nicholls D, Attwell D. The release and uptake of excitatory amino acids. *Trends Pharmacol Sci.* 1990;11:462–468.
- Oka A, Belliveau MJ, Rosenberg PA, Volpe JJ. Vulnerability of oligodendroglia to glutamate: pharmacology, mechanisms and prevention. *J Neurosci.* 1993;13:1441–1453.
- McDonald JW, Althomson SP, Hyrc KL, Choi DW, Goldberg MP. Oligodendrocytes from forebrain are highly vulnerable to AMPA/kainate receptor-mediated excitotoxicity. *Nature Med.* 1998;4:291–297.
- Dusart I, Marty S, Peschanski M. Demyelination and remyelination by Schwann cells and oligodendrocytes after kainate-induced neuronal depletion in the central nervous system. *Neuroscience.* 1992;51:137–148.
- Ransom BR, Waxman SG, Davis PK. Anoxic injury of CNS white matter: protective effect of ketamine. *Neurology.* 1990;40:1399–1403.
- Madden KP, Clark WM, Marcoux FW, Probert AJ, Weber ML, Rivier J, Zivin JA. Delayed therapy of experimental ischemia with competitive  $N$ -methyl-D-aspartate antagonists in rabbits. *Stroke.* 1993;24:1068–1071.

**Figure 2.** Representative photomicrographs from the internal capsule showing histopathological changes of cerebral white matter after 15 minutes of transient ischemia followed by 72 hours of reperfusion in both CNS 1102-treated and placebo-treated animals. A through C, H&E stain (magnification  $\times 160$ ). A, Normal white matter in the nonischemic contralateral hemisphere. B, Vacuolization (arrowheads) and increased cellular reaction in ischemic cerebral white matter of a placebo-treated animal. C, Relatively better-preserved cerebral white matter in a CNS 1102-treated animal (ischemic side). Note moderately enlarged astrocytic nucleus (arrowhead). D through F, LFB-PAS stain (magnification  $\times 20$ ). D, Normal myelin sheaths in the nonischemic contralateral white matter (blue color, arrowheads). E, Myelin sheaths that were broken into fragments with vacuoles showed less LFB-PAS stainability in a placebo-treated rat (arrowheads). F, Better-preserved myelin in a CNS 1102-treated animal (arrowheads). G through I, Bielschowsky's silver stain impregnation (magnification  $\times 20$ ). G, Normal axons in nonischemic contralateral white matter organized in bundles (dark color, arrowheads). H, Irregular twisted axons with segmental fragmentation showed less stainability in a placebo-treated animal (arrowheads). I, Better-preserved axons in a CNS 1102-treated animal (arrowheads).

## Editorial Comment

During the past 2 decades, basic and preclinical studies have demonstrated the significant involvement of glutamate neurotoxicity in neuronal death and infarction after cerebral ischemia. Despite this understanding, clinical trials that used neuroprotective agents which targeted glutamate neurotoxicity and other biochemical cascades involved in neuronal death have failed.<sup>1</sup> It is suggested that alternative and/or new therapeutic strategies are needed. One possible strategy is to protect white matter from ischemic injury. In this article, Schäbitz and colleagues have provided intriguing results which demonstrate that an NMDA antagonist protects both cerebral gray and white matter from ischemic injury after temporary focal ischemia in rats. This is a somewhat surprising but novel finding, since it is known that the axons and myelin sheaths may not contain NMDA receptors. Nevertheless, the authors have provided some plausible explanations for their observations. Because white matter oligodendrocytes are known to be vulnerable to AMPA/kainate receptor-

mediated excitotoxicity,<sup>2</sup> the possible AMPA/kainate receptor agonist property of this drug needs further evaluation. This study provides an impetus for additional therapeutic studies that will target the white matter after transient focal cerebral ischemia.<sup>3</sup>

**Pak H. Chan, PhD**, *Guest Editor*  
*Neurosurgical Laboratories*  
*Stanford University*  
*Palo Alto, California*

### References

1. Dirnagl U, Iadecola C, Moskowitz MA. Pathobiology of ischaemic stroke: an integrated view. *Trends Neurosci.* 1999;22:391-397.
2. McDonald JW, Althomsons SP, Hyrc KL, Choi DW, Goldberg, MP. Oligodendrocytes from forebrain are highly vulnerable to AMPA/kainate receptor-mediated excitotoxicity. *Nat Med.* 1998;4:291-297.
3. Dewar D, Yam P, McCulloch J. Drug development for stroke: importance of protecting cerebral white matter. *Eur J Pharmacol.* 1999;375:41-50.