

## ORIGINAL RESEARCH

# Modified plasmakinetic enucleation and resection of the prostate by three glands: proposal of a novel anatomical treatment for benign prostatic hyperplasia

Shaolei Nie<sup>1,2</sup>, Jun Wang<sup>2</sup>, Yufeng Peng<sup>2</sup>, Jianming Lou<sup>1,\*</sup>, Yipeng Xu<sup>3,4,5,\*</sup>

<sup>1</sup>The Graduate School, Zhejiang Chinese Medical University, 310000 Hangzhou, Zhejiang, China

<sup>2</sup>Department of Urology, QuZhou Kecheng Hospital, 324000 Quzhou, Zhejiang, China

<sup>3</sup>Department of Urology, Zhejiang Cancer Hospital, 310000 Hangzhou, Zhejiang, China

<sup>4</sup>The Key Laboratory of Zhejiang Province for Aptamers and Theranostics, 310022 Hangzhou, Zhejiang, China

<sup>5</sup>Institute of Basic Medicine and Cancer (IBMC), Chinese Academy of Sciences, 310022 Hangzhou, Zhejiang, China

**\*Correspondence**

xuyip1631@zjcc.org.cn

(Yipeng Xu);

202011122511537@zcmu.edu.cn

(Jianmin Lou)

**Abstract**

Transurethral resection of the prostate (TURP) cannot completely resect hyperplastic tissues and is often associated with high recurrence rate and short recurrence interval. Western and Chinese scholars have reported higher incidences of stress urinary incontinence (SUI) with traditional enucleations. This study investigated the potential applicability of Modified Plasmakinetic Enucleation and Resection of the Prostate by three glands (MPKERP) in treating benign prostatic hyperplasia (BPH). Between April 2020 and June 2021, 28 patients underwent MPKERP for BPH. The surgical procedures included (1) surgical capsule exploration; (2) moderate range enucleation; (3) middle gland enucleation; (4) sector resection at 12 o'clock in the lithotomy position; (5) cut residual distal urethral mucosa; (6) lateral hyperplastic glands enucleation. All 28 patients recovered well after the surgery, and the curative effect was satisfactory. The average operation time was  $68.9 \pm 21.8$  min, the average weight of excised glands was  $62.5 \pm 19.1$  g, the average indwelling catheter time was  $4.6 \pm 0.6$  d, and the average bladder washing time was  $28.6 \pm 9.5$  h. The average postoperative 1-day hemoglobin decrease was  $10.2 \pm 9.8$  g/L. Only one severe hyperplasia patient had transient SUI (incidence rate: 3.6%). No complications, such as urethral stricture, dysuria, urinary incontinence and urinary retention, were reported during follow-up. International Prostate Symptoms Score (IPSS), quality of life (QOL), maximum urinary flow rate (Qmax) and post-void residual volume (PVR) significantly improved three months after surgery ( $p < 0.0001$ ). The MPKERP can enucleate and resect the hyperplastic glands anatomically in an orderly manner and pay attention to expanding space, reducing resistance, reducing the damage of pushing and pulling, protecting the urethral sphincter complex (USC), and reducing the incidence of urinary incontinence. Altogether, our findings support MPKERP as an improved surgical technique worthy of promotion, and it is more suitable for grass-roots hospitals that lack hardware equipment.

**Keywords**

Benign prostatic hyperplasia (BPH); Modified plasmakinetic enucleation and resection of prostate by three glands (MPKERP); Stress urinary incontinence (SUI); Urethral sphincter complex (USC); Space; Resistance; Push and pull injury

## 1. Introduction

Benign prostatic hyperplasia (BPH) is one of the most commonly diagnosed urinary disorders in middle-aged and older men globally. With the aging and lifestyle changes in China, the number of BPH patients requiring surgical treatment has significantly increased. Although transurethral resection of the prostate (TURP) has been the gold-standard surgical procedure for treating BPH for over 90 years [1], it has several limitations, such as extensive blood loss during treatment, transurethral resection syndrome (TURS), and inability to completely resect hyperplastic tissues with a high recurrence rate and short recurrence interval, thus restricting its clinical application to some

extent [2, 3].

Considering the excellent hemostatic effect of bipolar technologies in treating BPH, Professor Liu, a Chinese scholar, innovatively combined bipolar plasma with his proposed intraluminal prostate enucleation using the mirror sheath as a finger in 2002 to gradually peel off the hyperplastic glands along the prostate surgical envelope under direct visualization and thoroughly treat prostate hyperplasia [4]. Subsequently, multiple randomized controlled studies have shown that bipolar plasma endoscopic enucleation of the prostate was associated with less blood loss, shorter hospital stay and catheter indwelling time, and was not limited by prostate volume [5–7]. Additionally, it has become increasingly widely used with the emergence of

various energy platforms.

Stress urinary incontinence (SUI) is an inevitable complication. Its treatment requires constant technological improvements to effectively resect as many glands as possible while maximizing patients' continence. From April 2020 to June 2021, our team, with the premise of maintaining the thoroughness of enucleation, focused on enlarging the space and reducing the resistance and the push-pull injury using a Modified Plasmakinetic Enucleation and Resection of the Prostate by three glands (MPKERP) to treat 28 patients with BPH. The treatment was safe and effective and achieved good curative effects. Thus, in this study, we detailed our experience using the proposed MPKERP as a potential attempt to improve the therapeutic outcomes of BPH patients.

## 2. Materials and Methods

### 2.1 Clinical data

From April 2020 to June 2021, 28 BPH patients underwent MPKERP. Table 1 summarizes the essential characteristics of the patients. All patients were preoperatively diagnosed with BPH by B-ultrasound and postoperatively *via* histopathology of the resected tissues. The study inclusion criteria were: (1) repeated urinary retention (no urination or two urinary retentions after at least one after the removal of the urinary catheter); (2) ineffective treatment with 5- $\alpha$  reductase inhibitors or  $\alpha$  receptor blockers alone or in combination; (3) presence of repeated urinary tract infection and secondary hematuria; (4) complicated with bladder stones; and (5) secondary upper urinary tract hydrops (with or without renal impairment). The exclusion criteria were the presence of cardiopulmonary and other vital organ dysfunction, coagulation dysfunction (platelets  $<30 \times 10^9/L$ , prothrombin time  $>30$  s), prostate cancer or urethral strictures, and prior history of prostate and urethral surgery. All patients were followed up at the outpatient clinic for one month and closely followed up for three months. Additionally, their clinical conditions were systematically reviewed and scored after three months.

**TABLE 1. Basic characteristics of patients with benign prostatic hyperplasia.**

Variables	Data (n = 28)
Age, year	70.9 $\pm$ 7.6 (58–82)
International Prostate Symptoms Score (IPSS)	24.36 $\pm$ 3.04 (20–31)
Quality of life (QOL)	4.96 $\pm$ 0.63 (4–6)
Maximum urinary flow rate (Qmax), mL/s	7.8 $\pm$ 1.2 (6–10)
Post-void residual volume (PVR), mL	108.4 $\pm$ 72.4 (55–300)

### 2.2 Surgical procedures

The patients were placed in the lithotomy position intraoperatively, administered routine lumbar complex combined anes-

thesia, underwent perineal disinfection, connected to bipolar plasma equipment (electric cut 160 W, electric coagulation 80 W) and tissue collector, and given saline irrigation solution and an F22 three lumen urinary catheter.

**Surgical capsule exploration:** Using caput gallinaginis as a sign, on its left or right side, we performed a sharp binding, slow cutting and slow pushing to focus on surgical capsule vessels or prostate stones (Fig. 1A).

**Enucleation of glands in a moderate range (from 3 to 9 o'clock in the lower part):** We separated the glands along the surgical envelope from the 3 to 9 o'clock of the hyperplastic glands on both sides, which were carefully manipulated, accurately performed hemostasis to ensure clear visualization of the surgical field, and avoided lose layers and violent push-pull manoeuvres (Fig. 1B).

**Enucleation of the middle gland:** Deep along the surgical envelop layer facing the bladder neck, the hyperplastic of the middle lobe gland (thin and wide) was electrically dissected at the 6 o'clock position near the neck orifice as the enucleation sign to reduce the resistance of the middle lobe to avoid violent traction injury, while preserving the bladder neck and internal urethral sphincter intact (Fig. 1C).

**Sector resection of the 12 o'clock glands:** Using caput gallinaginis as the anatomical landmark, we reversely marked the distal urethral mucosa. The glands were resected (fan-shaped) with close attention to the intersection of the two glandular lobes, deep into the surgical capsule, and far within the external urethral sphincter (Fig. 1D).

**Cut residual distal urethral mucosa (from 12 to 3 and 9 o'clock in the upper part):** We connected the pre-specified landmarks, severed the distal urethral mucosa, protected the external urethral sphincter, and reduced the push-pull injury to the external urethral sphincter upon enlarging the enucleation of the bilateral gland (Fig. 1E).

**Enucleation of the lateral hyperplastic glands:** The right hyperplastic gland was enucleated along the surgical envelope, with a small quantity of tissue traction at 11 o'clock on the tip. Equally, with a small quantity of tissue traction at 1 o'clock, we radically resected the entire left hyperplastic gland (Fig. 1F).

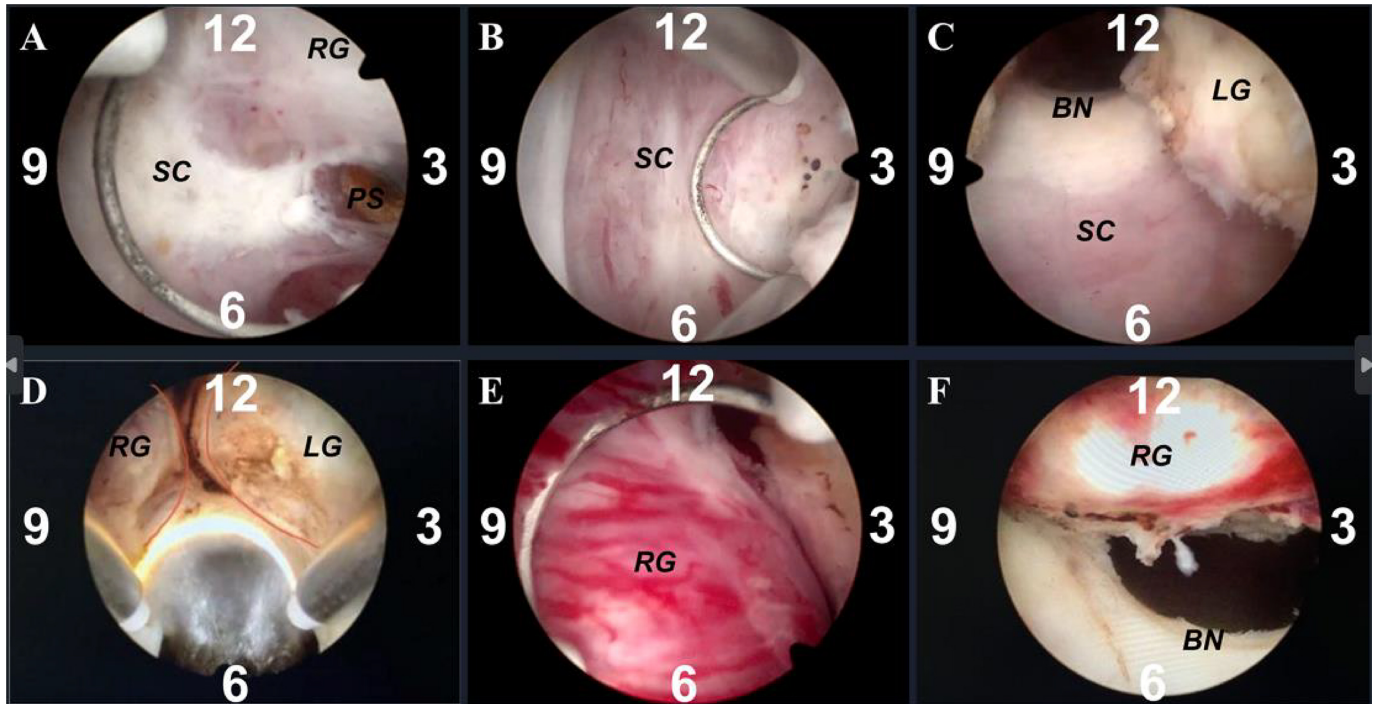
Tissue rinsing, hemostasis and local trimming.

### 2.3 Postoperative therapy

Postoperative routine indwelling catheterization and continuous bladder irrigation were performed postoperatively. According to the recovery of the patients, bladder irrigation was stopped in time, indwelling catheterization was removed, and paid careful attention to urination, urine control and hemoglobin levels on postoperative day one. Empirical broad-spectrum antibiotics were given for three days postoperatively. Upon discharge, the patients were advised to drink more warm water, avoid sedentary periods and exercises that could affect the surgical site (*i.e.*, biking), and so on.

### 2.4 Statistical methods

All data were processed and analyzed using the SPSS v25 (IBM Corp., Armonk, NY, USA) and GraphPad Prism v9 (GraphPad Software, Inc., San Diego, CA, USA). The data of IPSS score, QOL score, and Qmax preoperative and postoper-



**FIGURE 1. Surgical procedures of MPKERP.** (A) Surgical capsule exploration; (B) Enucleation of glands on both sides from 3 to 9 o'clock in the lower part; (C) Enucleation of the middle gland; (D) Sector resection of the 12 o'clock glands; (E) cut residual distal urethral mucosa from 12 to 3 and 9 o'clock in the upper part; (F) Enucleation of lateral hyperplastic glands. Abbreviations: MPKERP, Modified Plasmakinetic Enucleation and Resection of the Prostate by three glands; SC, surgical capsule; BN, bladder neck; RG, right gland lobe; LG, left gland lobe; PS, prostate stone.

ative differences were consistent with the normal distribution. The unpaired *t*-test was used for the mean comparison. The data of PVR preoperative and postoperative differences were severely skewed, and the rank sum test was used for the mean comparison.

### 3. Results

#### 3.1 Perioperative outcomes

All 28 patients successfully underwent surgery. The operative time ranged from 40 to 120 min, with an average of 68.9 ( $\pm 21.8$ ) min. The average weight of the excised glands was 62.5 ( $\pm 19.1$ ) g. Intraoperatively, hemostasis was thoroughly performed, the visual fields were clear, patients' vital signs were stable, and no transfusions were needed. The decrease in hemoglobin level range was from  $-8$  to 34 g/L on the first day after the operation, with an average decrease of 10.2 ( $\pm 9.8$ ) g/L. Of note, the hemoglobin level of three patients was not decreased but increased,  $-8$ ,  $-7$ , and  $-3$ , respectively, and for one patient, the level remained unchanged. Postoperatively, the wound surface of the prostatic fossa was smooth, and the bladder neck and sphincter were well protected (Fig. 2). Postoperative bladder irrigation time ranged between 18 to 48 h (average, 28.6  $\pm$  9.5 h), and catheter retention time was 4–6 d (average, 4.6  $\pm$  0.6 d). One patient had transient SUI (incidence rate, 3.6%) after the surgery and recovered spontaneously within 48 h after anal contraction and pelvic floor muscle exercise. All others voided well with immediate continence after removing the urinary catheter. Table 2 summarizes the perioperative outcomes of the investigated BPH

patients.

**TABLE 2. Perioperative characteristics of the patients.**

Variables	Data (n = 28)
Overall operating time (min)	68.9 $\pm$ 21.8
weight of excised glands (g)	62.5 $\pm$ 19.1
Drop in hemoglobin on day 1 (g/L)	10.2 $\pm$ 9.8
Bladder irrigation time (h)	28.6 $\pm$ 9.5
Catheterization time (d)	4.6 $\pm$ 0.6
Stress urinary incontinence (%)	3.6

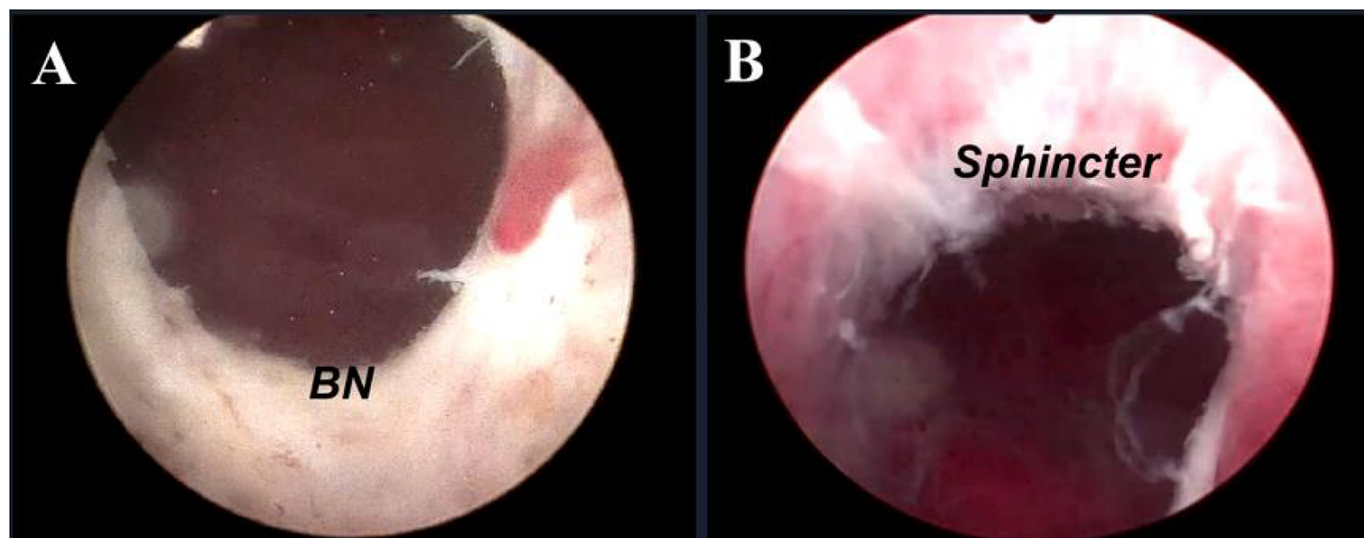
#### 3.2 Functional outcomes

Interim follow-up of functional outcomes showed statistically significant differences in IPSS score, QOL score, Qmax, and PVR three months after surgery compared to before surgery ( $p < 0.0001$ ) (Table 3).

#### 3.3 Follow-up outcomes

The scores of IPSS are 3.64  $\pm$  1.42 and 2.74  $\pm$  0.92 at 6 months and 12 months after surgery (Fig. 3A), the scores of QOL are 1.09  $\pm$  0.59 and 0.96  $\pm$  0.47 at 6 months and 12 months after surgery (Fig. 3B). PVR are 16.8  $\pm$  10.2 mL and 17.2  $\pm$  9.7 mL during the follow-up period at 6 months and 12 months (Fig. 3D). MPKERP contributed to significant and stable decrease in IPSS score, QOL score and PVR ( $p < 0.0001$ ). Qmax are 22.5  $\pm$  1.9 mL/s and 21.7  $\pm$  1.4 mL/s at





**FIGURE 2. Enucleation based on the surgical capsule.** (A) Complete enucleation of the hyperplastic glands and the wound surface of the prostatic fossa was smooth; (B) The sphincter was well-protected.

**TABLE 3. Preoperative versus 3-month postoperative functional outcomes.**

Variables	Preoperative	Postoperative (3 mon)	<i>p</i> value
IPSS	24.36 ± 3.04	3.96 ± 1.43	<0.0001
QOL	4.96 ± 0.63	1.14 ± 0.52	<0.0001
Qmax (mL/s)	7.8 ± 1.2	19.9 ± 1.7	<0.0001
PVR (mL)	108.4 ± 72.4	17.7 ± 8.1	<0.0001

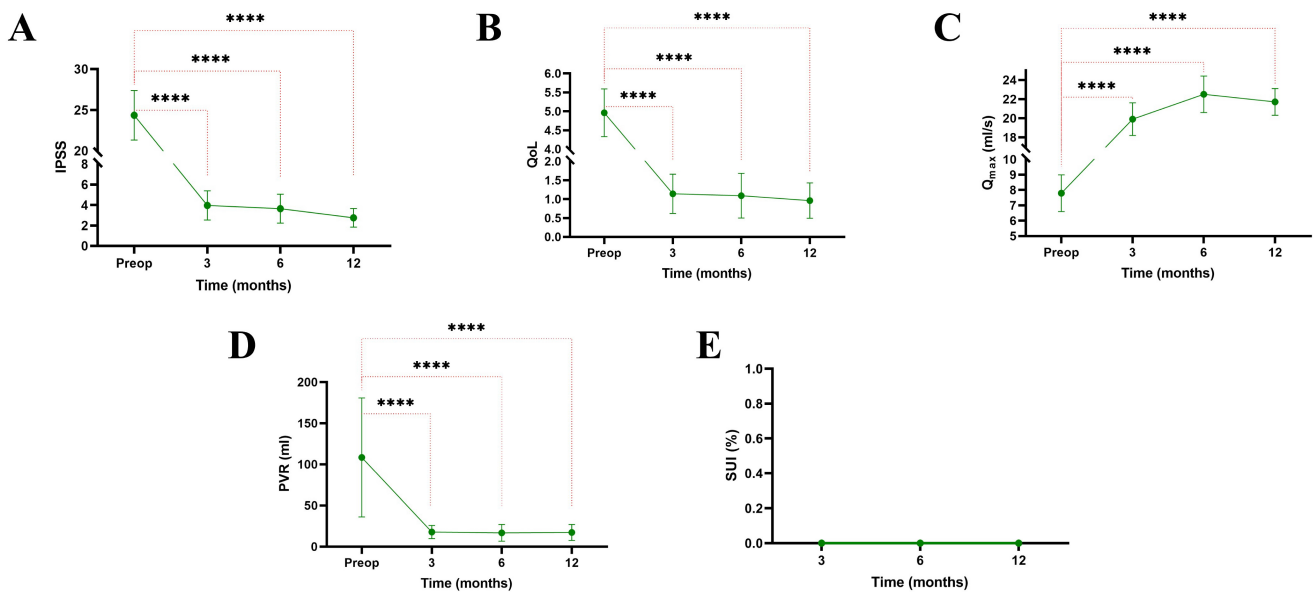
6 months and 12 months after surgery (Fig. 3C). Follow-up of Qmax outcomes also contributed to significant and stable improvement ( $p < 0.0001$ ). SUI is postoperative statistics data, and it keeps 0 during the 1-year follow-up (Fig. 3E).

#### 4. Discussion

Chinese authoritative scholars have reported that the incidence of SUI after bipolar enucleation of the prostate (bTUEP) could be up to 9.6% [4], while authoritative Western scholars reported that electrical enucleation and electrode creation were associated with higher incidences of SUI [3]. In this present study, no patients reported any complications, such as urethral stricture, dysuria, long-term urinary incontinence, and urinary retention. The postoperative indwelling catheter time was slightly longer due to the surgery's initial careful maneuvers and safety precautions undertaken, which might have contributed to no patient failure to urinate due to wound edema, infection or unstable bladder spasm after the removal of the catheter. Among the 28 patients, only one had transient SUI after surgery and recovered within 48 h after anal contraction and pelvic floor muscle exercise. Analysis of functional outcomes showed that the objective scores (IPSS and QOL) and Qmax were significantly improved at the three-month follow-up compared with preoperative conditions ( $p < 0.0001$ ). Moreover, the follow-up data indicated the mainte-

nance of good urinary functions and that the patients' urinary conditions had improved significantly within one year after surgery (Fig. 3).

Presently, more attention is paid to "urinary continence" after prostatectomy. Although SUI could be a temporary and recoverable condition, its impact on patients' quality of life cannot be ignored [8]. The anatomical zonation of the prostatic glands is remarkable and points the direction for subsequent clinical work [9]. Many scholars have studied the anatomical structure of the urethral sphincter and urethral sphincter complex before and after surgical treatment and have also set the target for surgeries. The male urethral sphincter complex extends from the bladder neck to the perineum (urogenital subdiaphragmatic fascia), such as the cylindrical wraparound urethra. It consists of a smooth urethral sphincter (anterior prostatic sphincter) and a striated urethral sphincter (extra urethral sphincter). The urethral sphincter complex is compressed outward by hyperplasia of the transitional zone and periurethral glands, resulting in the formation of the surgical envelope by the urethral sphincter complex. The proliferation of the transitional zone and periurethral glands can squeeze the urethral sphincter complex outward, resulting in the formation of the surgical envelope. Damage to the urethral sphincter complex can cause urinary incontinence and retrograde ejaculation [10, 11]. However, we found no significantly impactful scientific literature on lobular plasma enucleation on PubMed; thus, our team combined theoretical cognition and clinical experience to reconceptualize the anatomical structure. MPKERP is based on the precise anatomy of the patient to accurately locate the inner and outer boundaries, accurately explore the surgical envelope, gradually lobulate the posterior lobe of the middle lobe to expand the operation space, reduce the removal resistance, reduce the push-pull injury, maximize the protection of the integrity of the urethral sphincter complex, and pursue the lowest incidence of urinary incontinence. It is an easy-to-master procedure that does not require expensive hardware and has a low incidence of complications. Based on the promising results obtained, we aim to further expand the



**FIGURE 3. Follow-up outcomes.** (A,B) Surgery contributed to a significant decrease in postoperative IPSS and QOL scores. (C) A significant improvement was observed in Q<sub>max</sub> during the follow-up period after surgery. (D) Mean PVR showed a steep decrease during the follow-up period after surgery. (E) Transient SUI occurred in only one case (3.6%) and the patient recovered within 48 h after anal contraction and pelvic floor muscle exercise without further treatment. No recurrence was observed in these cases during the 1-year follow-up. Emission and continence were improved and maintained.

surgical data and the follow-up period.

In our implemented surgical procedures, the following two modified points were pivotal in significantly reducing the enucleation resistance: (1) 6 o'clock resection (Fig. 4A): when the middle lobe enucleation was performed by 2/3, 6 o'clock thin and wide resection was performed, which significantly reduced the pushing resistance of the central gland lobe, indirectly reduced the strength and angle of enucleation of the scope rod, completely protected the bladder neck and internal sphincter, maximally protected the continence, and reduced retrograde ejaculation; (2) 12 o'clock resection (Fig. 4B): The position of the external urethral sphincter was determined with caput gallinaginis as the mark, the most distal resection position was marked at 12 o'clock, and the deep and far scalloped resection of the intersection glands of the bilateral lobes at 12 o'clock, which was large inside and small outside and significantly reduced the resistance to enucleation in the subsequent lateral lobes, while also serving as a prominent marker to disconnect the urethral mucosa and protect the external sphincter.

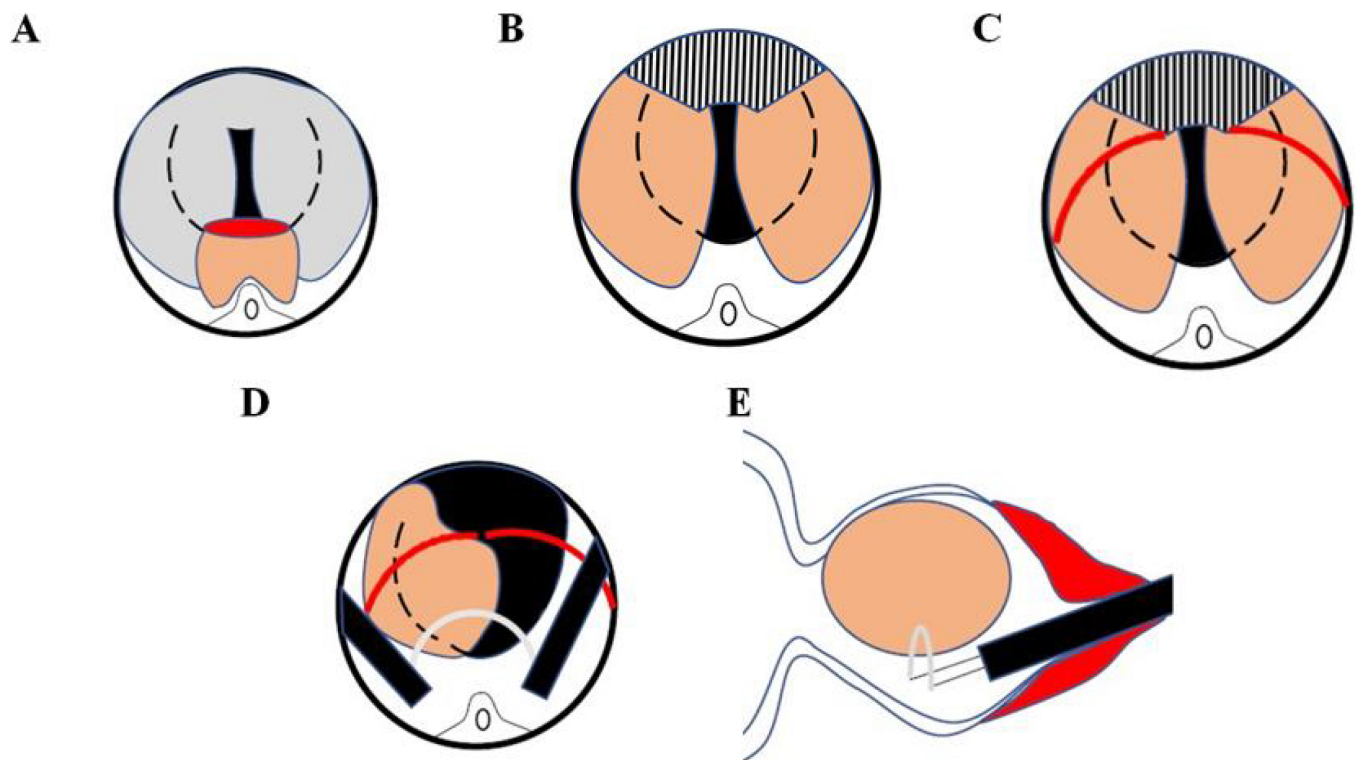
The traction injury to the external urethral sphincter caused by enucleation is significantly greater than electrocution, whereby a closer distance to the bladder neck and a greater 12 o'clock tip angle could lead to greater injury, and a longer operative time and larger glands could increase the incidence of SUI [12]. In addition to the choice of surgery, the anatomical cognition of surgeons and improvements in surgical techniques are also closely related to SUI [13, 14]. The improvement points of the surgery in this present study effectively reduced the traction injury of the endoscopic sheath list as follows: (1) Limited extension of the lateral lobe glands (Fig. 4B): before the distal urethral mucosa is cut off, we enucleate glands on both sides along the surgical capsule in a

moderate range, there will reduce the angle of enucleation and provide less blunt trauma, so it can protect external urethral sphincter better; (2) Cutting the urethral mucosa to protect the external urethral sphincter (Fig. 4C): disconnection from 12 to 3 and 9 o'clock in the upper part with clear boundary, good continuity and low probability of accidental injury; (3) Dexterous use of the electric cutting ring: when the lateral lobe was enucleated close to the neck orifice, the inner core electric cutting ring should be pushed forward with gentle action to reduce or even avoid large amplitude swinging of the mirror sheath.

We paid attention to the endpoint and direction of enucleation during enucleation of the central gland, 12 o'clock sectorial resection, and distal urethral mucosal disconnection (Fig. 4D,E). The lateral lobes continued to enucleate medially to the bladder neck, superiorly to the scalloped edge at 12 o'clock and left a little tissue traction on the left and right lateral lobes at 1 and 11 o'clock of the lithotomy position, respectively. We adjusted the direction of the electrical cutting ring and cut the proliferative tissues from bottom to top along the urethral physiological structure to reduce injury to the external urethral sphincter.

The modified methods for reducing the enucleation resistance and the pushing and pulling injury complemented each other. During the MPKERP operation, the cavity space was gradually increased, and the resistance to inter-glandular buildup decreased so that the hyperplastic glandular lobes were detached with a lighter force, a smaller angle and a shorter time to ensure excellent postoperative urethral space while achieving better urinary continence.

Combined with the postoperative performance and follow-up feedback of our group of surgical patients, we concluded



**FIGURE 4. MPKERP design concept.** (A) 6 o'clock thin and wide resection was performed, which significantly reduced the pushing resistance of the central gland lobe and indirectly reduced the strength and angle of enucleation of the scope rod; (B) We enucleated the glands on both sides along the surgical capsule from 3 to 9 o'clock in the lower part, then made a sector resection at 12 o'clock; (C) The urethral mucosa was cut off at the red lines to protect the external urethral sphincter and reduce the incidence of urinary incontinence; (D,E) The lateral lobes were continuously enucleated medially to the bladder neck and left a little tissue traction on the left and right lateral lobes at 1 and 11 o'clock of the lithotomy position, followed by adjusting the direction of the electrical cutting ring and reducing injury to the external urethral sphincter.

that: (1) For patients with <50 g hyperplastic glands, the exploration of the surgical envelope could be more complicated than for patients with apparent trilobate hyperplasia, but the surgical process and space might be better to grasp; (2) Patients with hyperplastic glands weighing 50–100 g can undergo fast and smooth enucleation, then have an anatomical resection of the prostate by three glands. (3) Enucleation can be quickly performed in patients with glands weighing >100 g. However, the space would be small and easy to labyrinth, we should not pursue speed blindly, and should require timely water decompression according to personal habits to intermittently flush out the excised tissue, guarantee the surgical field and reduce the incidence of TURS. Altogether, based on our experience, we recommend combining blunt and sharp dissection, performing slow cut and push manoeuvres, paying careful attention to underlying blood vessels, not forgetting prostatic calculus, and ensuring a clear surgical resection field.

Our study had some limitations. First, its single-center population-based design might have led to some unaccountable bias. Second, no control groups, such as TURP and TUEP, were included in this study. Third, although the data were collected prospectively, the results were retrospectively analyzed. Lastly, the number of cases in this study was small and larger cohorts with long-term results are needed to confirm our findings.

## 5. Conclusions

MPKERP was safe and reliable, demonstrated good curative effects and was associated with a low rate of urinary incontinence and few complications. In addition, MPKERP could be easily performed by plasma equipment alone in primary hospitals with poor hardware conditions, which is worthy of further investigations and popularization.

## ABBREVIATIONS

MPKERP, Modified Plasmakinetic Enucleation and Resection of the Prostate by three glands; BPH, benign prostatic hyperplasia; TURP, transurethral resection of the prostate; TURS, transurethral resection syndrome; bTUEP, bipolar transurethral enucleation of the prostate; USC, urethral sphincter complex; SUI, stress urinary incontinence; IPSS, International Prostate Symptoms Score; QOL, quality of life; Qmax, maximum urinary flow rate; PVR, post-void residual volume.

## AVAILABILITY OF DATA AND MATERIALS

The data are contained within this article.

## AUTHOR CONTRIBUTIONS

SLN—designed the research study, performed the research, wrote the manuscript. JW and YFP—provided help and advice on surgery. YPX and JML—analyzed the data and provided help and advice on paper-writing. All authors contributed to editorial changes in the manuscript. All authors read and approved the final manuscript.

## ETHICS APPROVAL AND CONSENT TO PARTICIPATE

The study was approved by the ethical committee of QuZhou Kecheng Hospital (kcy2022-007). Written informed consent was obtained from all patients before study participation.

## ACKNOWLEDGMENT

The authors thank The Urology Department of Zhejiang Cancer Hospital provided the Internet service for this study.

## FUNDING

This work was supported by grants from the Natural Science Foundation of Zhejiang Province (Q20H160035).

## CONFLICT OF INTEREST

The authors declare no conflict of interest.

## SUPPLEMENTARY MATERIAL

Supplementary material associated with this article can be found, in the online version, at <https://oss.jomh.org/files/article/1654367066279297024/attachment/Supplementary%20material.mp4>.

## REFERENCES

- [1] Strelbel RT, Kaplan SA. The state of TURP through a historical lens. *World Journal of Urology*. 2021; 39: 2255–2262.
- [2] Rassweiler J, Teber D, Kuntz R, Hofmann R. Complications of transurethral resection of the prostate (TURP)—incidence, management, and prevention. *European Urology*. 2006; 50: 969–980.
- [3] Miernik A, Gratzke C. Current Treatment for Benign Prostatic Hyperplasia. *Deutsches Ärzteblatt International*. 2020; 117: 843–854.
- [4] Xu P, Xu A, Chen B, Zheng S, Xu Y, Li H, *et al*. Bipolar transurethral enucleation and resection of the prostate: whether it is ready to supersede TURP? *Asian Journal of Urology*. 2018; 5: 48–54.
- [5] Zhu L, Chen S, Yang S, Wu M, Ge R, Wu W, *et al*. Electrosurgical enucleation versus bipolar transurethral resection for prostates larger than 70 mL: a prospective, randomized trial with 5-year followup. *The Journal of Urology*. 2013; 189: 1427–31.
- [6] Luo YH, Shen JH, Guan RY, Li H, Wang J. Plasmakinetic enucleation of the prostate vs plasmakinetic resection of the prostate for benign prostatic hyperplasia: comparison of outcomes according to prostate size in 310 patients. *Urology*. 2014; 84: 904–10.
- [7] Bebi C, Turetti M, Lievore E, Ripa F, Rocchini L, Spinelli MG, *et al*. Bipolar transurethral enucleation of the prostate: is it a size-independent endoscopic treatment option for symptomatic benign prostatic hyperplasia? *PLoS One*. 2021; 16: e0253083.
- [8] Buckley BS, Lapitan MCM, Glazener CM. The effect of urinary incontinence on health utility and health-related quality of life in men following prostate surgery. *Neurourology and Urodynamics*. 2012; 31: 465–469.
- [9] McNeal JE. The zonal anatomy of the prostate. *The Prostate*. 1981; 2: 35–49.
- [10] Koraitim MM. The male urethral sphincter complex revisited: an anatomical concept and its physiological correlate. *Journal of Urology*. 2008; 179: 1683–1689.
- [11] Sinha S, Sinha U, Malis V, Bhargava V, Sakamoto K, Rajasekaran M. Exploration of male urethral sphincter complex using diffusion tensor imaging (DTI)-based fiber-tracking. *Journal of Magnetic Resonance Imaging*. 2018; 48: 1002–1011.
- [12] Li X, He F, Huang C, Zhang L, Liu Q, Song J. Development and validation of a nomogram for predicting early stress urinary incontinence following endoscopic enucleation of the prostate. *World Journal of Urology*. 2021; 39: 3447–3453.
- [13] Walz J, Burnett AL, Costello AJ, Eastham JA, Graefen M, Guillonneau B, *et al*. A critical analysis of the current knowledge of surgical anatomy related to optimization of cancer control and preservation of continence and erection in candidates for radical prostatectomy. *European Urology*. 2010; 57: 179–92.
- [14] Endo F, Shiga Y, Minagawa S, Iwabuchi T, Fujisaki A, Yashi M, *et al*. Anteroposterior dissection HoLEP: a modification to prevent transient stress urinary incontinence. *Urology*. 2010; 76: 1451–5.

**How to cite this article:** Shaolei Nie, Jun Wang, Yufeng Peng, Jianming Lou, Yipeng Xu. Modified plasmakinetic enucleation and resection of the prostate by three glands: proposal of a novel anatomical treatment for benign prostatic hyperplasia. *Journal of Men's Health*. 2023; 19(4): 51-57. doi: 10.22514/jomh.2023.034.