

available at www.sciencedirect.com
journal homepage: www.europeanurology.com/eufocus



Prostate Cancer

Magnetic Resonance Imaging Follow-up of Targeted Biopsy-negative Prostate Lesions

Vasilis Stavrinos^{a,b,c,*}, Ece Eksi^d, Ron Finn^a, Larissa Texeira-Mendes^e, Sarina Rana^c, Nick Trahearn^f, Alistair Grey^c, Francesco Giganti^{a,g}, Eric Huet^h, Gaelle Fiardⁱ, Alex Freeman^j, Aiman Haider^j, Clare Allen^g, Alex Kirkham^g, Alexander P. Cole^k, Tom Collins^c, Douglas Pendse^g, Louise Dickinson^g, Shonit Punwani^g, Nora Pashayan^l, Mark Emberton^{a,c}, Caroline M. Moore^{a,c}, Clement Orczyk^{a,c}

^aDivision of Surgery & Interventional Science, University College London, London, UK; ^bThe Alan Turing Institute, London, UK; ^cDepartment of Urology, University College London Hospitals NHS Foundation Trust, London, UK; ^dCEDAR, Knight Cancer Institute, School of Medicine, Oregon Health and Science University, Portland, OR, USA; ^eUCL Cancer Institute, University College London, London, UK; ^fInstitute of Cancer Research, Sutton, UK; ^gDepartment of Radiology, University College London Hospitals NHS Foundation Trust, London, UK; ^hTRePCa, Université Paris Est-Créteil, Créteil, France; ⁱDepartment of Urology, Grenoble Alpes University Hospital, Université Grenoble Alpes, CNRS, Grenoble, France; ^jDepartment of Pathology, University College London Hospitals NHS Foundation Trust, London, UK; ^kDivision of Urological Surgery, Harvard Medical School, Boston, MA, USA; ^lDepartment of Applied Health Research, Institute of Epidemiology & Health, University College London, London, UK

Article info

Article history:

Accepted March 23, 2023

Associate Editor: Christian Gratzke

Keywords:

Prostate
Magnetic resonance imaging
Targeted biopsy

Abstract

Background: The optimal radiological follow-up of prostate lesions negative on magnetic resonance imaging (MRI)-targeted biopsy (MRI-TB) is yet to be optimised.

Objective: To present medium-term radiological and clinical follow-up of biopsy-negative lesions.

Design, setting, and participants: The records for men who underwent multiparametric MRI at the UCLH one-stop clinic for suspected prostate cancer between September 2017 and March 2020 were reviewed ($n = 1199$). Patients with Likert 4 or 5 lesions were considered ($n = 495$), and those with a subsequent negative MRI-TB comprised the final study population ($n = 91$).

Outcome measurements and statistical analysis: Baseline and follow-up MRI and biopsy data (including prostate-specific antigen [PSA], prostate volume, radiological scores, and presence of any noncancerous pathology) were extracted from reports. The last follow-up date was the date of the last test or review in clinic.

Results and limitations: Median follow-up was 1.8 yr (656 d, interquartile range [IQR] 359–1008). At baseline, the median age was 65.4 yr (IQR 60.7–70.0), median PSA was 7.1 ng/ml (IQR 4.7–10.0), median prostate volume was 54 ml (IQR 39.5–75.0), and median PSA density (PSAD) was 0.13 ng/ml² (IQR 0.09–0.18). Eighty-six men (95%) had Likert 4 lesions, while the remaining five (5%) had Likert 5 lesions. Only 21 men (23%) had a single lesion; most had at least two. Atrophy was the most prevalent pathology on MRI-TB, present in 64 men (74%), and followed by acute inflammation in 42 (46%), prostatic intraepithelial neoplasia in 33 (36%), chronic inflammation in 18 (20%), atypia in

* Corresponding author. Division of Surgery & Interventional Science, University College London, Charles Bell House, 43-45 Foley Street, London W1W 7TS, UK.
E-mail address: v.stavrinos@ucl.ac.uk (V. Stavrinos).

<https://doi.org/10.1016/j.euf.2023.03.011>

2405-4569/© 2023 The Author(s). Published by Elsevier B.V. on behalf of European Association of Urology. This is an open access article under the CC BY license (<http://creativecommons.org/licenses/by/4.0/>).

Please cite this article as: V. Stavrinos, E. Eksi, R. Finn et al., Magnetic Resonance Imaging Follow-up of Targeted Biopsy-negative Prostate Lesions, Eur Urol Focus (2023), <https://doi.org/10.1016/j.euf.2023.03.011>

13 (14%), and granulomatous inflammation in three (3%). Fifty-eight men had a second MRI study (median 376 d, IQR 361–412). At the second MRI, median PSAD decreased to 0.11 ng/ml² (IQR 0.08–0.18). A Likert 4 or 5 score persisted only in five men (9%); 40 men (69%) were scored Likert 3, while the remaining 13 (22%) were scored Likert 2 (no lesion). Of 45 men with a Likert ≥ 3 score, most only had one lesion at the second MRI (28 men; 62%). Of six men with repeat MRI-TB during the study period, two were subsequently diagnosed with prostate cancer and both had persistent Likert 4 scores (at baseline and at least one follow-up MRI).

Conclusions: Most biopsy-negative MRI lesions in the prostate resolve over time, but any persistent lesions should be closely monitored.

Patient summary: Lesions in the prostate detected via magnetic resonance imaging (MRI) scans that are negative for cancer on biopsy usually resolve. Repeat MRI can indicate persistent lesions that might need a second biopsy.

© 2023 The Author(s). Published by Elsevier B.V. on behalf of European Association of Urology. This is an open access article under the CC BY license (<http://creativecommons.org/licenses/by/4.0/>).

1. Introduction

Although we and others have shown that the decision to sample Prostate Imaging-Reporting and Data System (PI-RADS) or Likert 3 prostate magnetic resonance imaging (MRI) phenotypes can be informed by factors such as prostate-specific antigen density (PSAD) and lesion characteristics, targeting of clearly suspicious lesions (PI-RADS or Likert 4–5) is widely considered uncontroversial (at least for the time being) [1,2]. Nonetheless, one in five highly suspicious lesions are negative on MRI-targeted biopsy (MRI-TB): in PRECISION, 31% of PI-RADS 4/5 lesions and 6% of 5/5 lesions did not yield cancer on targeting [3]. The challenges in negative MRI-TB scenarios are (1) to distinguish false-positive MRI from false-negative biopsy findings and (2) to determine the level of follow-up stringency required to ensure no new or misclassified disease is missed. As mentioned, we previously addressed the former question by showing that MRI false positivity is associated with specific clinicoradiological attributes such as lower PSAD and T2 or contrast-enhanced sequence signals without substantial diffusion restriction [2]. In this paper we address the latter question by providing medium-term radiological outcomes for biopsy-negative lesions. We specifically demonstrate that such lesions largely resolve over time and their resolution goes hand in hand with a reduction in PSAD.

2. Patients and methods

2.1. Clinic setting

The University College London Hospitals (UCLH) prostate cancer one-stop clinic is a specialist service specifically designed for men with an MRI-TB indication. Following an abnormal PSA result in the community, patients are admitted for multiparametric MRI (mpMRI) immediately reported by an experienced urologist. MRI scans are routinely scored according to the Likert system at the prostate level (therefore deriving an overall Likert score) and separately for each lesion. If the mpMRI is positive (ie, the PI-RADS or Likert score for the prostate or any lesion is ≥ 3) and there is a clinical indication, the patient is offered the option to undergo MRI-TB. TBs are performed in a cognitive manner (ie, without fusion software) and although the number of deployments

per target depends on lesion volume, an average of four cores per lesion is common practice. After the biopsy is performed, the patient is sent home and the result is communicated a few days later either remotely or in person.

2.2. Patient selection and follow-up

For this study, all patients who attended the UCLH one-stop clinic and underwent mpMRI over a 2.5-yr period between September 2017 and March 2020 were considered ($n = 1199$). All scans were reported by radiologists highly experienced in prostate MRI reporting (>1000 prostate MRI scans per year). All MRI reports were retrieved and men with an overall Likert score of 4 or 5 ($n = 495$) were further scrutinised to identify those who underwent MRI-TB under visual registration ($n = 462$). MRI-TB pathology reports were retrieved and patients with negative histology were finally selected, comprising the final study population of 91 men (Fig. 1A). For this group, all subsequent MRI and pathology reports were also retrieved; the last day of follow-up was defined as the date of the last investigation (MRI or biopsy), urology clinic letter, or prostate intervention, depending on which occurred first. The interval between baseline MRI and any event of interest was calculated in days (Fig. 1B).

2.3. Information extraction and analysis

Baseline MRI information was recorded for all patients, including prostate volume and PSA at the time of MRI, number of lesions, overall and lesion-level Likert scores, and lesion location (peripheral and/or transitional zone, right-left, base-mid-apex). In addition, MRI-TB pathology information such as the presence of inflammation (acute, chronic, or granulomatous), prostatic intraepithelial neoplasia (PIN), atrophy, or atypia was recorded for the entire prostate (ie, if either entity was found in any targeted areas) and at the index lesion level (ie, the highest-scoring lesion). For all follow-up MRI scans and MRI-TBs, the same radiological and pathology information was recorded (PSA, prostate volume, number of lesions, overall Likert score, presence of any significant non-cancerous pathology). Results for continuous and categorical variables were summarized using simple statistics such as the median, interquartile range (IQR), and proportion. The co-occurrence of noncancerous pathologies was assessed via multiple correspondence analysis. R version 4.2.1 statistical software (R Foundation for Statistical Computing, Vienna, Austria; <http://www.R-project.org/>) was used for analyses and visualisations.

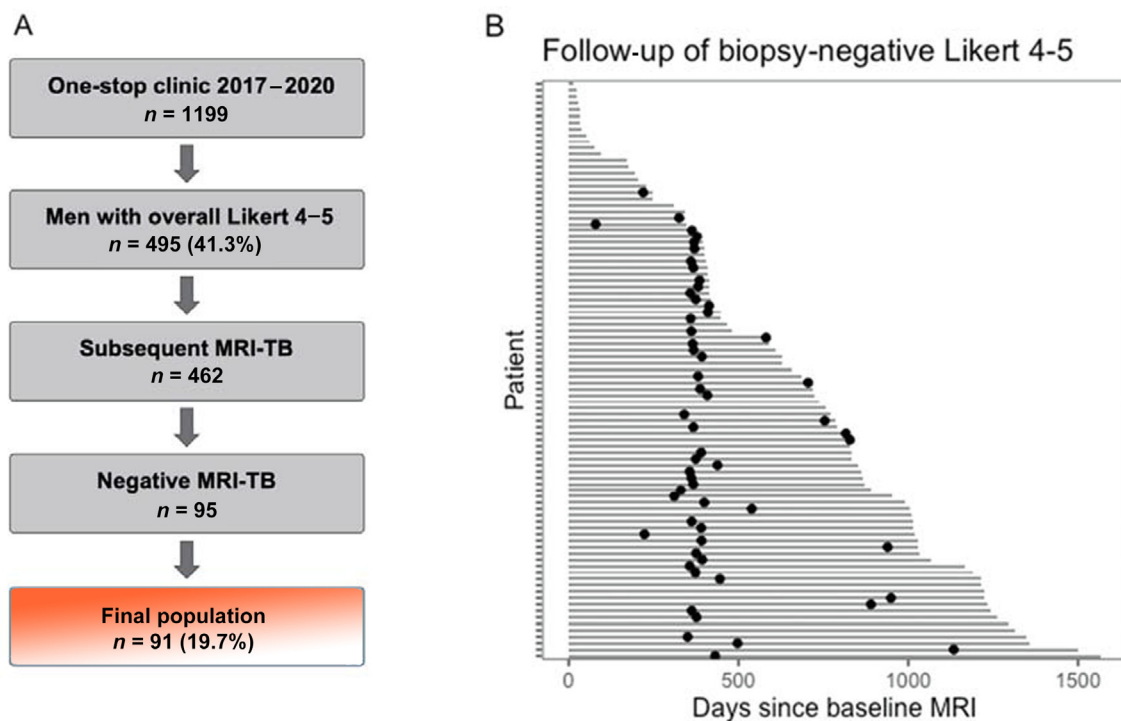


Fig. 1 – Patient selection and follow-up. (A) The list of all University College London Hospitals (UCLH) patients seen at the one-stop clinic during the study period was scrutinised for men with an overall Likert score of 4 or 5 (41.3% of the total) and a subsequent magnetic resonance imaging (MRI)-targeted biopsy (MRI-TB). After exclusion of four patients previously diagnosed with cancer but seen at the one-stop clinic to expedite their assessment, a final population of 91 men (19.7% of those with a high Likert score and subsequent MRI-TB) was selected for this study. (B) The median follow-up for the entire cohort was approximately 1.8 yr (656 d; interquartile range [IQR] 359–1008); follow up in days (grey bars) and repeat MRI examinations (black dots) are shown for all patients. Repeat MRI at 1 yr is standard practice at UCLH for biopsy-negative cases; out of 91 men, 58 had a second scan (median interval from baseline: 376 d [IQR 361–412]), while a small number of patients had more MRI scans.

Table 1 – Clinical characteristics at baseline and follow-up MRI^a

Parameter	Baseline MRI	MRI 1	MRI 2	MRI 3
Patients (n)	91	58	11	2
Median age, yr (IQR)	65.4 (60.7–70)	NA	NA	NA
Median time from baseline, d (IQR)	–	376 (361–412)	890 (752–996)	NA
Median prostate volume, ml (IQR)	54 (39.5–75)	55 (45–69)	65 (55–77)	NA
Median PSA, ng/ml (IQR)	7.1 (4.7–10)	7 (4.8–9.2)	8 (7–12)	NA
Median PSAD, ng/ml ² (IQR)	0.13 (0.09–0.18)	0.11 (0.08–0.18)	0.13 (0.13–0.16)	NA
Overall Likert score, n (%)				
2	0	13 (22)	4 (36)	1
3	0	40 (69)	6 (55)	1
4	86 (95)	5 (9)	1 (9)	0
5	5 (5%)	0	0	0
Number of lesions (Likert 3–5), n (%)	(n = 91)	(n = 45)	(n = 7)	
1	21 (23)	28 (62)	3 (43)	1
2	50 (55)	15 (34)	4 (57)	0
3	14 (15)	2 (4)	0	0
4	6 (7)	0	0	0

MRI = magnetic resonance imaging; IQR = interquartile range; PSA = prostate-specific antigen; PSAD = PSA density; NA = not applicable.

^a Most patients had Likert 4 lesions and multiple targetable areas on MRI. Of 91 men, 58 had a second MRI that demonstrated a clear shift towards lower Likert score, fewer lesions, and lower PSAD. A small number of men had a third and fourth follow-up MRI that demonstrated similar findings.

3. Results

3.1. Baseline characteristics

The baseline characteristics are presented in Table 1. The median PSA and age at presentation were 7.1 ng/ml (IQR 4.7–10.0) and 65.4 yr (IQR 60.7–70.0), respectively. Prostate

volumes were calculated using the ellipsoid formula. The median prostate volume at baseline was 54 ml (IQR 39.5–75.0), giving a median PSAD of 0.13 ng/ml² (IQR 0.09–0.18). Of 91 men, 86 (95%) had a Likert MRI score of 4/5 and the remaining five (5%) had a score of 5/5. Only 21 men (23%) had a single lesion; the remaining 70 (77%) had at least two lesions. At the prostate level, atrophy was

by far the most prevalent noncancerous pathology on MRI-TB (Table 2 and Fig. 2A), which was present in 64 men (74%). This was followed by acute inflammation in 42 men (46%), PIN in 33 (36%), chronic inflammation in 18 (20%), atypia in 13 (14%), and granulomatous inflammation in three (3%). Lesion-level analyses generally echoed these findings (Fig. 2B). Multiple correspondence analysis of prostate-level pathology demonstrated that acute inflammation was often observed in specimens with atrophy, while the presence of PIN was more often noted in specimens with atypia (Fig. 2C). Regardless of their hierarchy, lesions were mainly distributed in the peripheral zone, and most spanned the middle and apical prostate segments (Supplementary Fig. 1).

3.2. Clinical, radiological, and MRI-TB follow up

The median follow-up for the entire cohort was approximately 1.8 yr (656 d, IQR 359–1008). Follow-up information is given in Table 1. Of 91 men, 58 had a second MRI (median interval from baseline 376 d, IQR 361–412). The median prostate volume at the second MRI was 55 ml (IQR 45–69), median PSA was 7 ng/ml (IQR 4.8–9.2), and median PSAD decreased to 0.11 ng/ml² (IQR 0.08–0.18). These changes were accompanied by substantial shifts in MRI scores (Fig. 3): only five out of 58 men (9%) had a persistently high overall Likert score of 4, while 40 (69%) were scored as Likert 3 and the remaining 13 (22%) as Likert 2 (no visible lesion). In addition, of the 45 men with Likert ≥ 3 scores, most now had only one lesion (28 men; 62%). Eleven men had a third MRI (with a persisting Likert 4 score in one patient), and the proportion of men without lesions increased further in comparison to the second scan (four men; 36%).

Of the six men who had repeat MRI-TB during the study period, two were subsequently diagnosed with prostate cancer and both had persistent Likert 4 scores (at baseline and at least one follow-up MRI). The first patient (age 57 yr; no abnormal pathology) was diagnosed 3.7 yr (1357 d) after baseline and underwent radical prostatectomy (RP) for a 7-ml Gleason 3 + 4 cancer. The second patient (age

68 yr; PIN, atypia, and atrophy on pathology) was diagnosed 3.3 yr (1222 d) after baseline with Gleason 4 + 4 disease at RP. The remaining four patients with repeat MRI-TB were negative for cancer; their pathology is given in Table 2. Four patients in total had benign prostatic hyperplasia treatment (transurethral resection, laser enucleation, or embolization), all within 2.3 yr from baseline.

4. Discussion

This work further contributes to the evidence base on the fate of TB-negative prostate MRI lesions. We showed that most of these highly scoring phenotypes are associated with atrophy or other noncancerous pathologies and short-term radiological resolution (both in terms of score severity and lesion number) is their most likely outcome, usually accompanied by a decrease in PSAD. In a similar series of 88 TB-negative cases described by Meng and colleagues [4], the rate of persistently high-scoring lesions was higher at 27% (12/45 men with a second MRI). This could be attributed to multiple factors, including different targeting, MRI acquisition, and reporting protocols (PI-RADS v2 was used instead of Likert). The rate of cancer on subsequent MRI-TB was five out of eight men, in comparison to two out of six in our series. Other authors more recently reported that the rate of subsequent clinically significant cancer on follow-up targeting ranges from 4.9% to 23% [5,6]. An equally interesting parallel finding in the Meng study is the low rate of subsequent cancer on concurrent systematic biopsy in those with decreasing radiological scores (2/13 men; 15%) [4]. These results could imply that nonresolution of targeted lesions foreshadows prostate cancer diagnosis, while subsequent cancer risk outside these areas is low. This view is corroborated by recent work in larger cohorts: Kinnaird and colleagues [5] reported no clinically significant cancer in men with negative follow-up MRI. In a carefully designed study by Barletta and colleagues [6] with median follow-up of 31 mo for 68 men who underwent a follow-up TB, the 3-yr survival free from a clinically significant cancer diagnosis survival was 92% for those with positive and 65% for those with negative follow-up MRI.

Similarly, Kornienko and colleagues [7] reported that among 84 men with PI-RADS 4 or 5 lesions and repeat MRI, more than half of the lesions were downgraded to PI-RADS ≤ 3 at a median of 28 mo, while clinically significant disease was detected in 10/24 of these men who also underwent repeat biopsy, all with persistent MRI lesions.

Pepe and Pennisi [8] estimated that the rate of some form of inflammation for PI-RADS 5 lesions was approximately 37%. Meng and colleagues [4] also found that inflammation, atypia, and other pathologies were prevalent at baseline—just as in our population—but these were not predictive of subsequent cancer. This should not be necessarily taken as an indication against a causal relationship between inflammation and cancer, for reasons discussed elsewhere [9]. However, determining the histopathology of TB-negative lesions is important because, despite past assertions, formal studies on the topic have only started to appear recently: glandular-stromal alterations, acute or chronic inflammation, and vascular changes have now been

Table 2 – Prostate-level MRI-TB pathology at baseline and follow-up^a

	MRI-TB sample	
	Baseline	Follow-up
Patients (n)	91	6
Cancer (n)	–	2
Benign pathology, n (%)	91	4
Chronic inflammation	18 (20)	1 (25)
Acute inflammation	42 (46)	2 (50)
Granulomatous inflammation	3 (3)	0
Prostatic intraepithelial neoplasia	33 (36)	3 (75)
Atypia	13 (14)	1 (25)
Atrophy	67 (74)	3 (75)

MRI = magnetic resonance imaging; TB = targeted biopsy.

^a At baseline MRI-TB, atrophy was the dominant finding, followed by acute inflammation, PIN and chronic inflammation. Six men had a second MRI-TB at some point during the study period, and two were diagnosed with cancer that was later treated with surgery. The findings for the remaining four largely emulate baseline pathology.

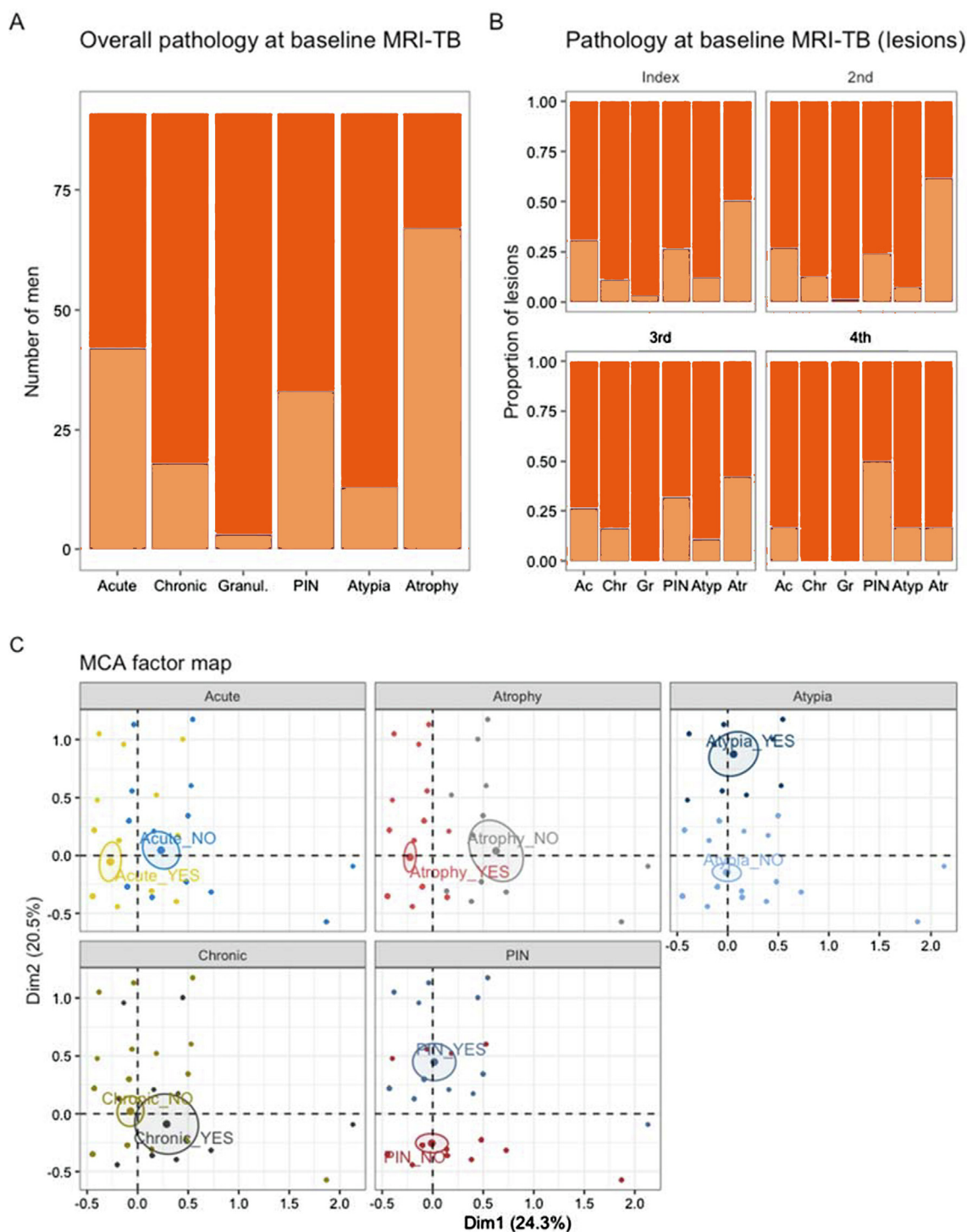


Fig. 2 – Magnetic resonance imaging (MRI)-targeted biopsy (MRI-TB) pathology at baseline. Atrophy (Atr), acute inflammation (Ac), prostatic intraepithelial neoplasia (PIN), and chronic inflammation (Chr) were the dominant pathological findings at baseline at both (A) the prostate and (B) the lesion level, indicating that their prevalence is similar across targetable areas, regardless of whether the lesion was primary (index) or secondary. (C) Multiple correspondence analysis (MCA) of prostate-level pathology data confirmed that almost half of the data variance observed can be explained by two principal components, one related to atrophy and acute inflammation (horizontal axis) and the second one related more to the presence of PIN and atypia (vertical axis). In the MCA plot, names ending in _NO indicate the absence of a particular pathology, and those ending in _YES indicate presence. Gr = granulomatous inflammation; Atyp = atypia.

found in most false-positive MRI lesions and, interestingly, are more prevalent and more synchronous in MRI-TB tissue in comparison to systematic biopsy cores from the same patients [10–12]. Although our population did not undergo standard systematic sampling, our multiple correspondence

analysis showed that atrophy on MRI-TB is closely associated with acute inflammation, whereas PIN often co-occurs with atypia. Whether this implies the existence of two distinct MRI false-positive types with a different microstructural basis or a reporting artefact remains to be

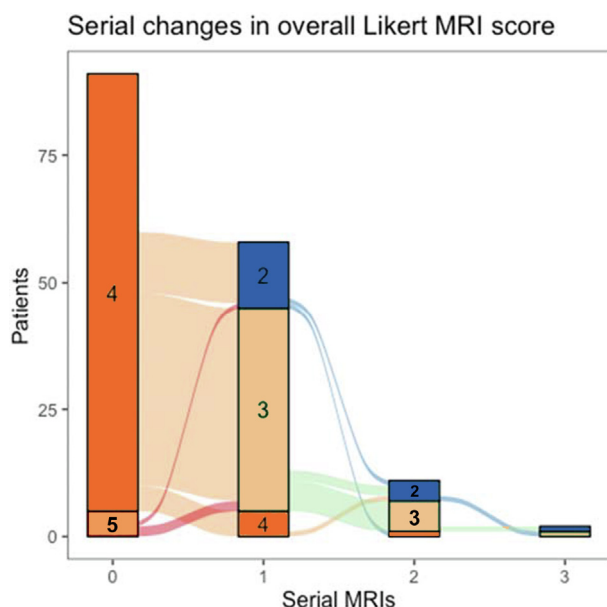


Fig. 3 – Overall changes in Likert score on serial magnetic resonance imaging (MRI). Although all 91 men had a Likert score of 4 or 5 at baseline, among the 58 men who had at least one follow-up MRI, most scores were downgraded (predominantly to Likert 3). This trend continued in additional follow-up MRIs. A small number of Likert 4 phenotypes persisted on serial imaging; interestingly, the two men subsequently diagnosed with cancer on follow up MRI-targeted biopsy had persistently high scores (Likert 4) in their serial MRI scans.

seen. We also note that biopsy-negative lesions in our population mostly spanned the middle and apical peripheral zone.

The main limitations of our study include the almost complete lack of repeat biopsy data and the nonblinding of the reporting urologists to the initial biopsy result, which could influence scoring of follow-up MRIs. The lack of systematic sampling also comes with a small risk of missing significant disease, although this risk has been deemed to be small and inherently acceptable in the TB era [13]. Even though the Likert scheme was used instead of PI-RADS v2, there is substantial experience with this score in our institution; it is also endorsed by UK policy makers and its performance against PI-RADS v2 has been favourably assessed by other authors [14–16]. In addition to the main limitations, we should also note that the assessment of non-cancerous pathologies is not as standardised as the reporting for prostate cancer pathology. Here, reporting of noncancerous entities was binary (simple presence or absence of inflammation or PIN) even though a quantitative approach could be necessary for more accurate histology-MRI correlations. Finally, although our study is informative, longer follow-up is an important prerequisite for advocating a particular monitoring strategy, which we cannot propose on the basis of our findings. For the moment, we note that most TB-negative lesions improve over time and the short-term risk of subsequent significant cancer in the small number of men who undergo repeat targeting is associated with lesion persistence rather than resolution. Equally, the combination of negative follow-up MRI with low PSAD can be reassuring: Barletta and colleagues [6] reported a

3-yr rate of clinically significant disease of 6% among such cases. Collectively, these observations align with systematic review evidence supporting the view that repeat MRI with follow-up targeting in cases of persistently suspicious imaging findings is a reasonable management approach, although larger studies are required [17].

5. Conclusions

In conclusion, negative MRI-TB of highly-scoring prostate lesions is associated with noncancerous entities such as PIN, inflammation, and atrophy. Such lesions tend to regress to less suspicious phenotypes, commonly accompanied by a reduction in PSAD after the first year. Although repeat biopsy should always be considered if there is suspicion of missed significant disease (especially when lesions persist over time), repeat PSA imaging in selected cases could be a clinical alternative that spares men from early repeat biopsies.

Author contributions: Vasilis Stavrinides had full access to all the data in the study and takes responsibility for the integrity of the data and the accuracy of the data analysis.

Study concept and design: Stavrinides, Orczyk.

Acquisition of data: Rana, Texeira-Mendes, Freeman, Haider, Allen, Kirkham, Collins, Pendse, Dickinson, Punwani.

Analysis and interpretation of data: Stavrinides, Eksi, Finn.

Drafting of the manuscript: Stavrinides, Orczyk.

Critical revision of the manuscript for important intellectual content: Trahearn, Grey, Giganti, Huet, Fiard, Freeman, Haider, Allen, Kirkham, Cole, Collins, Pendse, Dickinson, Punwani, Pashayan.

Statistical analysis: Stavrinides.

Obtaining funding: Stavrinides.

Administrative, technical, or material support: Texeira-Mendes, Trahearn.

Supervision: Orczyk, Moore, Emberton.

Other: None.

Financial disclosures: Vasilis Stavrinides certifies that all conflicts of interest, including specific financial interests and relationships and affiliations relevant to the subject matter or materials discussed in the manuscript (eg, employment/affiliation, grants or funding, consultancies, honoraria, stock ownership or options, expert testimony, royalties, or patents filed, received, or pending), are the following: None.

Funding/Support and role of the sponsor: Vasilis Stavrinides previously received funding from the UKRI (MRC Clinical Research Training Fellowship MR/S005897/1), the European Association of Cancer Research (Travel Fellowship), the Mason Medical Research Foundation and Prostate Cancer UK (UCL-UCLH Centre of Excellence Fund), and acknowledges further funding from the Alan Turing Institute (EPSRC EP/N510129/1), Cancer Research UK (EDDAMC-2021\100001), the Medical Research Foundation (MRF-152-0004-CTA-STAV-C0813) and the Prostate Cancer Foundation & John Black Charitable Foundation (Young Investigator Award 21YOUN04). Ece Eksi received funding from Cancer Research UK (EDDAMC-2021\100001). Francesco Giganti acknowledges previous funding from a UCL Graduate Research Scholarship and a Brahm PhD scholarship in memory of Chris Adams, is a recipient of the 2020 Young Investigator Award (20YOUN15) funded by the Prostate Cancer Foundation / CRIS Cancer Foundation and reports consulting fees from Lucida

Medical LTD outside of the submitted work. Alex Kirkham is supported by the UCLH/UCL Biomedical Research Centre. Mark Emberton is a UK National Institute of Health Research (NIHR) Senior Investigator and receives research support from the UCLH/UCL NIHR Biomedical Research Centre. Caroline M. Moore is supported by a UK NIHR Professorship, Movember, Prostate Cancer UK, and the EAU Research Foundation. The sponsors played a role in analysis and interpretation of the data, and preparation and review of the manuscript.

Appendix A. Supplementary data

Supplementary data to this article can be found online at <https://doi.org/10.1016/j.euf.2023.03.011>.

References

- [1] Brizmohun Appayya M, Sidhu HS, Dikaios N, et al. Characterizing indeterminate (Likert-score 3/5) peripheral zone prostate lesions with PSA density, PI-RADS scoring and qualitative descriptors on multiparametric MRI. *Br J Radiol* 2017;91:20170645. <https://doi.org/10.1259/bjr.20170645>.
- [2] Stavrinides V, Syer T, Hu Y, et al. False positive multiparametric magnetic resonance imaging phenotypes in the biopsy-naïve prostate: are they distinct from significant cancer-associated lesions? Lessons from PROMIS. *Eur Urol* 2021;79:20–9. <https://doi.org/10.1016/j.eururo.2020.09.043>.
- [3] Kasivisvanathan V, Rannikko AS, Borghi M, et al. MRI-targeted or standard biopsy for prostate-cancer diagnosis. *N Engl J Med* 2018;378:1767–77.
- [4] Meng X, Chao B, Chen F, Huang R, Taneja SS, Deng FM. Followup of men with PI-RADSTM 4 or 5 abnormality on prostate magnetic resonance imaging and nonmalignant pathological findings on initial targeted prostate biopsy. *J Urol* 2021;205:748–54.
- [5] Kinnaird A, Sharma V, Chuang R, et al. Risk of prostate cancer after a negative magnetic resonance imaging guided biopsy. *J Urol* 2020;204:1180–6.
- [6] Barletta F, Stabile A, Mazzone E, et al. How to optimize follow-up in patients with a suspicious multiparametric MRI and a subsequent negative targeted prostate biopsy. Results from a large, single-institution series. *Urol Oncol* 2022;40:103.e17–e24.
- [7] Kornienko K, Reuter M, Maxeiner A, et al. Follow-up of men with a PI-RADS 4/5 lesion after negative MRI/Ultrasound fusion biopsy. *Sci Rep* 2022;12:13603.
- [8] Pepe P, Pennisi M. Negative biopsy histology in men with PI-RADS score 5 in daily clinical practice: incidence of granulomatous prostatitis. *Clin Genitourin Cancer* 2020;18:e684–7.
- [9] Langston ME, Sfanos KS, Khan S, et al. Why do epidemiologic studies find an inverse association between intraprostatic inflammation and prostate cancer: a possible role for colliding bias? *Cancer Epidemiol Biomarkers Prev* 2021;30:255–9.
- [10] Sheridan AD, Nath SK, Aneja S, et al. MRI-ultrasound fusion targeted biopsy of Prostate Imaging Reporting and Data System version 2 category 5 lesions found false-positive at multiparametric prostate MRI. *Am J Roentgenol* 2018;210:W218–25.
- [11] Hupe MC, Offermann A, Tharun L, et al. Histomorphological analysis of false positive PI-RADS 4 and 5 lesions. *Urol Oncol* 2020;38:636.e7–e12. <https://doi.org/10.1016/j.urolonc.2020.01.017>.
- [12] Gordetsky JB, Ullman D, Schultz L, et al. Histologic findings associated with false-positive multiparametric magnetic resonance imaging performed for prostate cancer detection. *Hum Pathol* 2019;83:159–65.
- [13] Norris JM, Carmona Echeverria LM, Bott SRJ, et al. What type of prostate cancer is systematically overlooked by multiparametric magnetic resonance imaging? An analysis from the PROMIS cohort. *Eur Urol* 2020;78:163–70.
- [14] Latifoltojar A, Appayya MB, Barrett T, Punwani S. Similarities and differences between Likert and PIRADS v2.1 scores of prostate multiparametric MRI: a pictorial review of histology-validated cases. *Clin Radiol* 2019;74:895.e1–e15.
- [15] Khoo CC, Eldred-Evans D, Peters M, et al. Likert vs PI-RADS v2: a comparison of two radiological scoring systems for detection of clinically significant prostate cancer. *BJU Int* 2020;125:49–55.
- [16] Zawaideh JP, Sala E, Pantelidou M, et al. Comparison of Likert and PI-RADS version 2 MRI scoring systems for the detection of clinically significant prostate cancer. *Br J Radiol* 2020;93:20200298.
- [17] Grivas N, Lardas M, Espinós EL, et al. Prostate cancer detection percentages of repeat biopsy in patients with positive multiparametric magnetic resonance imaging (Prostate Imaging Reporting and Data System/Likert 3–5) and negative initial biopsy. A mini systematic review. *Eur Urol* 2022;82:452–7.