

CASE STUDY

Head injury in a haemophilia patient – Nursing considerations: a case report

Sulochana B, Roseminu Varghese, Girish Menon

A person with haemophilia is at risk of intracranial haemorrhage caused by spontaneous or traumatic events, potentially resulting in long-term disability. Early initiation of timely treatment is essential to prevent this. In developing countries, morbidity and mortality is common in intracerebral haemorrhage (ICH) cases with haemophilia as a result of patients and family members having inadequate knowledge, lack of awareness regarding referral, lack of availability of treatment products, and delays in the treatment decision. These barriers can potentially be managed by the haemophilia nurse taking responsibility for the coordination of care. This case report addresses the nurse-coordinated care of a haemophilic patient with ICH in a developing country, and may provide insight into the benefits of a haemophilia nurse undertaking a coordinating role.

Keywords: *Bleeding, Brain injury, Haemophilia, Haemorrhage, Head injury, Nursing care*

SULOCHANA B

Associate Professor, Department of Fundamentals of Nursing, Manipal College of Nursing, Manipal

ROSEMINU VARGHESE

Lecturer, Department of Fundamentals of Nursing, Manipal College of Nursing, Manipal
Email: rm.varghese@manipal.edu.

GIRISH MENON

Professor and Head of the Department of Neurosurgery, Kasturba Medical College, Manipal



© Shutterstock

As part of the collaborative multidisciplinary team caring for the patient, the haemophilia nurse coordinator plays a pivotal role in coordinating patient care.

Coagulation disorders are rare, and people with haemophilia can experience severe health issues during their lifetime. When accidents or trauma occur, there is a greater risk of mortality in this population, with intracranial haemorrhage being the most common cause^[1]. Seizures, psychomotor impairment, statomotor impairment, and decreased quality of life are the most common morbidities^[2]. Clotting factor is essential for people with haemophilia, but the high cost of treatment means that it is unaffordable to many in India. Furthermore, only a small number of haemophilia treatment centres offer the care, extensive monitoring and treatment that patients need. In this situation, a collaborative team approach can facilitate early treatment and management, with nurses playing a significant role in coordinating patient care.

PRESENTATION

A 26-year-old male weighing 58 kg presented to the emergency department following a road traffic accident, with facial abrasions, lacerations to the

This is an Open Access article distributed under the terms of the Creative Commons Attribution-NonCommercial-NoDerivs License (<https://creativecommons.org/licenses/by-nc-nd/3.0/>) which permits use and distribution in any medium, provided the original work is properly cited, the use is non-commercial, and no modifications or adaptations are made. Copyright is retained by the authors.

skull, periorbital ecchymosis (raccoon or panda eyes) and otorrhea. He was unconscious and had had two episodes of vomiting. On examination, the Glasgow Coma Scale score was found to be 12 (eye opening 2, verbal response 4, motor response 6). The pupils were 2mm bilaterally equal and reactive to light. Blood pressure was 110/70 mmHg, pulse 55 beats per minute, and temperature 98.6°F.

The patient was diagnosed with haemophilia during childhood. Aged three years, he had a head injury that continued to bleed for 10 hours. At the age of four years, an oral cavity bled for 22 days after the extraction of a tooth. During these episodes, the patient was treated with blood and blood products, as the availability of factor concentrate was scarce. At the age of six years, he started developing symptoms including blood in the stool when he had a stomach upset, bilateral swelling of the ankle joints, restricted movement and tenderness. Delayed wound healing following injury was also reported. At the age of 10 years, the patient was diagnosed with haemophilia A (< 1% Factor VIII levels) when a healthcare professional referred him to the haemophilia treatment centre. The delay in referral may have been due to lack of awareness of the disease and inadequate availability of healthcare services in the vicinity of the remote village in which his family lived.

MANAGEMENT AND OUTCOME

The patient was admitted to the neuro ICU for further treatment. A CT scan revealed right parietal contusion, quadrigeminal cistern, fourth ventricular haemorrhage, and no significant mass effect or hydrocephalus (Figure 1). Thus, the patient was diagnosed with a moderate head injury.

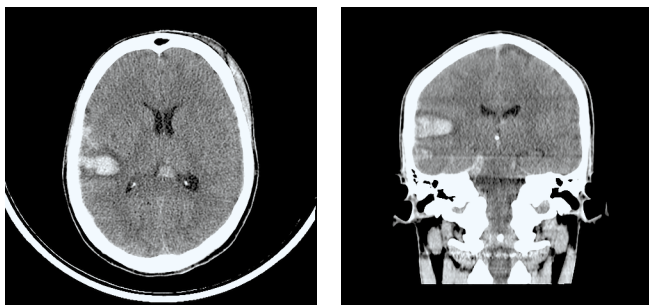


Figure 1: CT scan showing right parietal contusion, quadrigeminal cistern and fourth ventricular haemorrhage.

The most important aspect of treating a head injury in a haemophilic patient is the quick replacement of coagulation factor. In this patient, for the first three days, a total of 26,100 IU (100%) of factor concentrate

was administered intravenously, every eight hours, by nurses who had been trained by the haemophilia nurse coordinator. Following this, the patient was given 600 IU (20 IU/kg) twice-weekly for four weeks. Laboratory investigations revealed haemoglobin 14g/dl, haematocrit 41.6%, and prothrombin APTT 34.1 seconds (as patient was receiving factor concentrate), control 10.7 seconds, INR 1.06, PT 11.3 seconds.

The patient was monitored in the ICU for two days. He recovered well with conservative management and medications such as antiepileptics, diuretics, anti-oxidants, and proton pump inhibitors. During the acute phase, he was placed in neutral position and ICU nurses administered eye care, mouth care, skin hygiene, a bowel regimen to avoid constipation, and regular physiotherapy. He was stable, asymptomatic and was discharged on the sixth day. The nurses provided discharge instructions.

On follow-up, after two-weeks, the CT was found to be normal, but the patient had developed blurred vision. There was no requirement to administer further clotting factor concentrate.

THE NURSE'S ROLE AS COORDINATOR OF CARE

The provision of coordinated care of haemophilia patients during the acute phase is essential. Many healthcare professionals are not aware of this rare disease and its management in the event of head injury. The haemophilia nurse coordinator therefore has a vital role in communicating, informing and educating both the patient's family and other healthcare professionals.

By being part of the collaborative multidisciplinary team caring for the patient, the haemophilia nurse coordinator plays a pivotal role in coordinating patient care^[3]. In this case, coordinated care was delivered to the patient by the critical care nurses and the haemophilia nurse coordinator working as a team. The haemophilia nurse coordinator was responsible for the development of an action plan for the patient, including communication between all healthcare professionals involved; performing an initial assessment of the patient's health status and need for clotting factor concentrate based on the treatment plan; and assisting in the early management and treatment, review and follow-up of the patient.

The administration of factor concentrate is a key educational aspect in cases such as this, as it is likely to be new to nurses working in the neuro ICU. The haemophilia nurse coordinator gave "incidental" teaching at the bedside when administering clotting factor concentrate as a means of familiarising the

ICU nurses with methods of administration^[4]. This incidental teaching also meant that the critical care nurses were able to recognise the risk of bleeding, and better monitor the surgical site and drainage tubes, contributing to a better outcome for the patient. The nurses also demonstrated effective skills in factor transfusion as per the protocol, and were cautious with regard to the clinical signs of intracranial pressure (ICP).

As a care coordinator, the haemophilia nurse also has a key role in educating patients and their families, and can act as the primary point of contact for patients with an acute problem, as well as giving appropriate care. In this particular case, discharge planning included the provision of health education to both the patient and the patient's relative on the management advised by the physician, assessment of secondary bleeding, the risk of seizures, precautions to prevent bleeding, and follow-up. Instructions for the patient's care at home included arrangements for the administration of factor concentrate, signs and symptoms of intracranial bleeding, and self-care. The nurse's involvement in the care had a positive impact on the improvement of the patient's health status.

DISCUSSION

Accurate assessment is essential in the management of haemophilia patients with a head injury, and a quick decision is critical. The neurological status should be monitored effectively; signs of increased ICP should be noted and managed by placing the head and neck of the patient in a straight alignment, as this improves cerebral venous drainage^[5]. The literature suggests that haemophiliacs with minor head trauma should receive early clotting factor concentrate replacement. Vital components of nursing management include turning the patient frequently, with continuous observation of the ICP; providing eye care, mouth and skin hygiene; utilising all evidence-based bundles for prevention of infection; providing a bowel regimen to prevent constipation the rise of intra-abdominal pressure and ICP; and performing regular physiotherapy^[6].

CONCLUSION

Management of head injury in haemophilic centres must follow a collective approach, with careful haemodynamic maintenance, respiratory care, fluid

administration, and standard care for the prevention of secondary brain injury, maintaining an acceptable CPP, enhancing cerebral oxygenation, and preventing internal bleeding^[7]. This requires the efforts of a collaborative multidisciplinary team including neuro physicians, neurosurgeons, haemophilia nurse coordinators, critical care nurses, respiratory therapists, physiotherapists, and other healthcare professionals. Particularly when resources are scarce, education plays a vital role in better healthcare for the maintenance of haemophiliacs.

ACKNOWLEDGEMENTS

The authors have advised no interests that might be perceived as posing a conflict or bias.

Informed consent has been obtained from the individual reported in this case study.

REFERENCES

1. Antunes SV, Vicari P, Cavalheiro S, Bordin JO. Intracranial haemorrhage among a population of haemophilic patients in Brazil. *Haemophilia* 2003; 9(5): 573–7. Available from: <http://doi.org/10.1046/j.1365-2516.2003.00789.x> (accessed 7 November 2017).
2. Witmer C. M., Raffini, L. J., & Manno, C. S. (2007). Utility of computed tomography of the head following head trauma in boys with haemophilia. *Haemophilia*, 13(5), 560–566. <http://doi.org/10.1111/j.1365-2516.2007.01546.x> (accessed 7 November 2017).
3. Khair K, Chaplin S. What is a nurse-led service? A discussion paper. *Journal of Haemophilia Practice* 2017;4(1): 1–10. Available from: <http://doi.org/10.17225/jhp00100> (accessed 7 November 2017).
4. Riley L, Womack M, Zappa S. Chapter 8: Emergency room care. In: *Nurses' Guide to Bleeding Disorders*. National Hemophilia Foundation, 1995. Available from: <https://www.hemophilia.org/sites/default/files/document/files/Nurses-Guide-Chapter-8-Emergency-Room-Care.pdf> (accessed 7 November 2017).
5. Sahni R, Jesse, W. Management of intracerebral hemorrhage. *Vascular Health and Risk Management* 2007; 3(5): 701–9.
6. Haddad S, Arabi Y. Critical care management of severe traumatic brain injury in adults. *Scandinavian Journal of Trauma, Resuscitation and Emergency Medicine* 2012; 20(1): 12. Available from: <http://doi.org/10.1186/1757-7241-20-12> (accessed 7 November 2017).
7. Chandy M. Treatment Options in the Management of Hemophilia in Developing Countries. *Treatment of Hemophilia*, 37. World Federation of Hemophilia, 2005. Available from: [http://www.hemophiliabangalore.org/Pdf File\(H\)/Treatment_Options_Dev_Countries.pdf](http://www.hemophiliabangalore.org/Pdf%20File(H)/Treatment_Options_Dev_Countries.pdf) (accessed 7 November 2017).