

CASE REPORT

COVID-19 related acute limb ischaemia: A case series

Jih Huei Tan, Henry Chor Lip Tan, Addy Aun Wei Ang, Ida Arinah Mahadi, Zi Huan Khoo, Po Hong Tan, Mohamad Yuzaidi, Rizal Imran Alwi, Tuan Nur Azmah Tuan Mat

Tan JH, Tan HCL, Ang AAW, Ida AM, Khoo ZH, Tan PH, Mohamad Y, Rizal IA, Tuan NATM. COVID-19 related acute limb ischaemia: A case series. *Malays Fam Physician*. 2023;18:8. <https://doi.org/10.51866/cr.168>

Keywords:

COVID-19, Limb ischaemia, Arterial occlusive disease, Thrombolysis

Authors:

Jih Huei Tan

(Corresponding author)
MBBS (Manipal), DrSurg (UKM)
Department of General Surgery,
Hospital Sultanah Aminah,
Jalan Masjid Sultan Abu Bakar,
Johor Bahru, Malaysia.
Email: huei_87@hotmail.com

Henry Chor Lip Tan

MD (UCSI), DrSurg (UKM)
Department of General Surgery,
Hospital Sultanah Aminah,
Jalan Masjid Sultan Abu Bakar,
Johor Bahru, Malaysia.

Addy Aun Wei Ang

MBBS (IMU)
Department of General Surgery,
Hospital Sultanah Aminah,
Jalan Masjid Sultan Abu Bakar,
Johor Bahru, Malaysia.

Ida Arinah Mahadi

MBBS MD (USM)
Department of General Surgery,
Hospital Sultanah Aminah,
Jalan Masjid Sultan Abu Bakar,
Johor Bahru, Malaysia.

Zi Huan Khoo

MBBS (NUI)
Department of General Surgery,
Hospital Sultanah Aminah,
Jalan Masjid Sultan Abu Bakar,
Johor Bahru, Malaysia.

Abstract

COVID-19 infection or vaccination is rarely associated with arterial occlusive disease of the extremities. The surgical department of a hospital in Johor, Malaysia, recorded a significant increase in the number of COVID-19-related acute limb ischaemia when the rates of COVID-19 were high both locally and internationally. The clinical presentation and management of acute limb ischaemia associated with COVID-19 infection or vaccination are largely underreported in Johor. Herein, we report a case series of 12 patients managed with strategies ranging from purely anticoagulation to catheter-directed thrombolysis and surgical embolectomy. This case series describes the clinical presentation, risk profiles, treatment approaches and limb outcomes of the patients. The amputation rate was high in view of unfavourable factors, including delayed presentation, high-risk factors and severe COVID-19. Three cases of potential COVID-19 vaccine-related acute limb ischaemia were included. COVID-19-related acute limb ischaemia can be minimised with heightened alert, pre-emptive optimisation with proper hydration and consideration for early prophylactic anticoagulation in high-risk cases.

Introduction

COVID-19 infection has been reported to be associated with an increased incidence of thrombotic events that require emergency surgical interventions. The spectrum of vascular emergencies reported encompasses venous and arterial thromboembolisms.¹ Arterial thromboembolism in the extremities (upper and lower limbs) with resultant acute limb ischaemia is the least commonly observed type. Current international guidelines recommend early initiation of pharmacological prophylaxis against venous thromboembolism in patients with COVID-19, similar to local Malaysian guidelines.¹ Despite early prophylaxis, the incidence of thrombotic events remains high in patients with concomitant COVID-19.² In comparison with venous occlusion, acute limb ischaemia in patients with COVID-19 due to arterial thromboembolism is rare. A systematic review of case reports identified that early surgical revascularisation may improve morbidity outcomes and reduce amputation rates.² Malaysia had seen a surge in COVID-19 infection in June 2021 along with a concomitant rise in the number of acute limb ischaemia cases. There are no clear guidelines towards the management of limb ischaemia in patients with COVID-19. The current management is largely individualised to each

patient and extrapolated from non-COVID-19 literature.² Hence, this case series highlights all cases of COVID-19-associated limb ischaemia treated in the general surgical department of Hospital Sultanah Aminah, Johor Bahru. The clinical course and management of each patient are discussed.

Case presentation

This case series included all patients with COVID-19-associated limb ischaemia during the surge of COVID-19 infection in Hospital Sultanah Aminah, Johor Bahru, Malaysia, from June to September 2021. Patient data were retrieved retrospectively: age, sex, ethnicity, cardiovascular risk factors, involved blood vessels and medical and surgical managements with the eventual outcome (morbidity, mortality and amputation rates). These data were subsequently analysed and tabulated for comparison. The case series included all patients with acute limb ischaemia secondary to COVID-19 infection or vaccination who were referred to our surgical department during the 4-month study period.

Herein, there were nine cases of COVID-19-associated limb ischaemia that were referred to our general surgical department. The patients were aged between 25 and 84 years; the sex

Po Hong Tan

MBBS IMU
Department of General Surgery,
Hospital Sultanah Aminah,
Jalan Masjid Sultan Abu Bakar,
Johor Bahru, Malaysia.

Mohamad Yuzaidi

MMed Surg (UKM)
Department of General Surgery,
Hospital Sultanah Aminah,
Jalan Masjid Sultan Abu Bakar,
Johor Bahru, Malaysia.

Rizal Imran Alwi

MMed Surg (UKM)
Department of General Surgery,
Hospital Sultanah Aminah,
Jalan Masjid Sultan Abu Bakar,
Johor Bahru, Malaysia.

Tuan Nur Azmah Tuan Mat

MMed Surg (UKM)
Department of General Surgery,
Hospital Sultanah Aminah,
Jalan Masjid Sultan Abu Bakar,
Johor Bahru, Malaysia.

Open Access: This is an Open Access article licensed under the Creative Commons Attribution (CC BY 4.0) license, which permits others to distribute, remix, adapt and build upon this work, for commercial use, provided the original author(s) and source are properly cited. See: <http://creativecommons.org/licenses/by/4.0/>

distribution was equal; and the majority of the patients were Malays, considering that Malays are the ethnic majority in Malaysia. Most patients (n=8) had severe COVID-19 pneumonia requiring oxygen supplementation. Six of them required endotracheal intubation and mechanical ventilation. Eight patients had lower limb ischaemia, while one patient had upper limb ischaemia. There were two elderly patients (age of >70 years) in our series, both of whom had cardiovascular risk factors and comorbidities. The major blood vessels involved were the iliac, femoral and popliteal arteries (**Table 1**). From the data tabulation, we observed that the younger patients had a lower threshold and higher incidence towards involvement of the end-artery ischaemia of the digits (**Table 1**).

Table 1. COVID-19 infection-related peripheral vascular thrombosis.

No.	Age, ethnicity and sex	Highest COVID-19 stage	Cardiovascular risk(s)	Presentation	Vessel involved	Medical management	Surgical management	Outcome
1	48 years, Chinese, male	Stage 5b	None	Left leg gangrene for 1 week (Missed acute limb ischaemia Rutherford 3)	Left common iliac total occlusion (CTA)	S/C Clexane 60 mg BD	Left AKA and embolectomy	Survived with left AKA
2	41 years, Malay, male	Stage 4a	Smoking Diabetes	Left foot discolouration for 6 days (Acute-on-chronic left lower limb ischaemia Rutherford 2b)	Left popliteal, left anterior tibial artery (CTA) (Figures 1–3)	IV Heparin -> oral rivaroxaban and aspirin	Angioplasty with alteplase infusion	Survived with no amputation
3	75 years, Chinese, female	Stage 5b	Hypertension Dyslipidaemia Atrial fibrillation Stroke	Left leg discolouration for 1 week with reduced consciousness (Acute left lower limb ischaemia Rutherford 3)	Distal SFA to below the trifurcation (clinical and Doppler)	S/C Clexane 60 mg BD	-	Died before amputation
4	66 years, Malay, male	Stage 5b	None	Dusky discolouration of the toes after 2 weeks of ICU stay (Rutherford 3)	Crural vessels (dorsalis pedis and posterior tibial) (clinical and Doppler)	IV Heparin -> S/C Clexane 60 mg BD	Refused left BKA	Died 1 week later
5	84 years, Malay, male	Stage 5b	Hypertension Diabetes Left femoral fracture (walking frame) Ischaemic heart disease	Chest pain with high troponin T level (NSTEMI), sudden onset of left leg pain for 1 day (Rutherford 2b)	Left CFA onwards	S/C Clexane 60 mg BD	-	Died 1 day following limb ischaemia onset
6	42 years, Malay, female	Stage 1	Diabetes Hypertension	Left hand pain and bluish discolouration for 2 days (Rutherford 2a)	Brachial artery thrombosis	IV Heparin -> S/C Clexane 80 mg BD	Left brachial artery embolectomy	Survived with no functional disability
7	25 years, Indian, female	Stage 5b	None	required noradrenaline for inotropic support due to septic shock (Rutherford 3)	Toe digital arteries	S/C Clexane 60 mg BD	-	Died
8	27 years, Malay, female	Stage 5b	Pregnant and underwent caesarean section 6 days prior, highest fraction of oxygen requirement of 100% with noradrenaline inotropic support	Lower limb and right upper limb bluish discolouration for 2 days	Finger and toe digital arteries and left iliofemoral deep vein thrombosis	S/C Clexane 60 mg BD	-	Died 1 day after gangrene onset

Table 1. Continued

No.	Age, ethnicity and sex	Highest COVID-19 stage	Cardiovascular risk(s)	Presentation	Vessel involved	Medical management	Surgical management	Outcome
9	59 years, Malay, female	Stage 4b	Required noradrenaline for inotropic support	Bluish discolouration of the toes for 1 week Acute limb ischaemia Rutherford 3	Toe digital arteries- left 1st, 2nd and 3rd toes and right 2nd and 3rd toes (clinical and Doppler)	SC Clexane 40 mg BD	Autoamputation	Survived

Rutherford 1 = limb viable

Rutherford 2a = limb marginally threatened

Rutherford 2b = limb immediately threatened

Rutherford 3 = limb irreversibly damaged

CTA = computed tomography angiography

CFA = common femoral artery

SFA = superficial femoral artery

AKA= above-the-knee amputation

BKA= below-the-knee amputation

-> means 'later changed to'

In this case series, two patients underwent revascularisation surgery, and both had successful limb salvage. These were case numbers 2 and 6, respectively, as listed in Table 1; of them, catheter-directed thrombolysis and brachial embolectomy were performed (**Figures 1–3**).

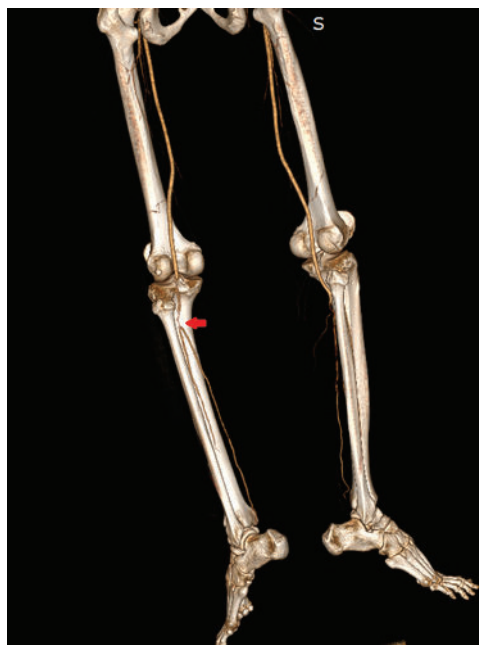

Figure 1. Computed tomography angiography of the lower limb of case number 2 reveals that the left proximal anterior tibial artery is partially occluded (red arrow).

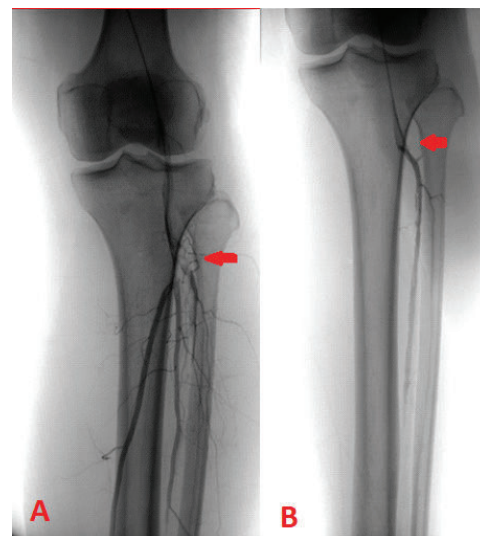


Figure 2. Catheter angiography of the lower limb of case number 2 reveals that the proximal anterior tibial artery is partially occluded (red arrow, A). The catheter is advanced into the proximal anterior tibial artery, and thrombolysis is successfully achieved, showing no more occlusion (red arrow, B).

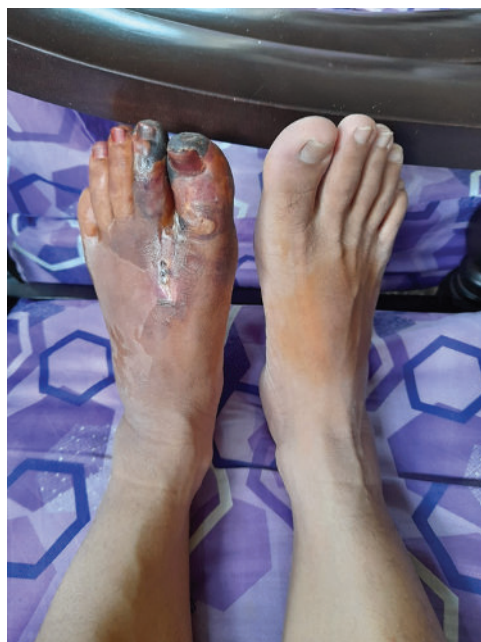

Figure 3. Left toe tip gangrene demarcated 1 month post-thrombolysis of the anterior tibial artery in case number 2.

Both case numbers 2 and 6 were in the younger age group of early 40s with a good premorbid

status. Case numbers 7–9 showed a different pattern of thrombosis that only involved the end artery of the digits with no medium-to-large-vessel occlusion (**Table 1**). Concomitant COVID-19-associated limb ischaemia was associated with a lower survival rate; five of the nine patients eventually died. The patients who did not survive were unfit for surgery, as they had a higher preoperative risk owing to severe comorbidities or severe COVID-19 (**Table 1**).

There were three patients who developed peripheral vascular thrombosis after recent COVID-19 vaccination. Two of them had thrombosis in the upper limbs two days following vaccination, and one had lower limb arterial thrombosis a week after vaccination. All three patients developed thrombotic events following injection of the second dose of COVID-19 vaccine. One patient who was a smoker and had diabetes underwent below-the-knee amputation after embolectomy of the occluded tibial arteries. The remaining two patients were treated conservatively and had successful limb salvage (**Table 2**).

Table 2. COVID-19 vaccination-related peripheral vascular thrombosis.

Age, ethnicity and sex	Highest COVID-19 stage	Cardiovascular risk(s)	Presentation	Vessel involved	Medical	Surgical	Outcome
45 years, Chinese, male	2nd dose, 2 days	None	Shortness of breath and reversible bluish discoloration of the left 2nd to 5th fingers 2 days following vaccination	Finger digital arteries - left 2nd to 5th fingers (CTA)	-	-	Survived with preservation of all digits
67 years, Malay, female	2nd dose, 1 week	Tobacco smoking Diabetes	Bluish discoloration of the foot for 1 week (acute limb ischaemia Rutherford 3)	External iliac and distal popliteal (CTA)	IV Heparin > warfarin	BKA with embolectomy of ATA and PTA	Survived with BKA
60 years, Chinese, male	2nd dose, 2 days	End-stage renal failure with left radiocephalic fistula	Left forearm and hand swelling 2 days after vaccination	Brachial artery and cephalic vein thrombosis	-	-	Survived with thrombosed fistula

CTA = Computed tomography angiogram

Discussion

Malaysia recorded a surge of COVID-19 infection from June to September 2021, reaching a peak of 10,000 cases daily.³ During the same period, we recorded an increase in the number of patients in our surgical department who were diagnosed with peripheral vascular thromboembolism related to COVID-19 infection or vaccination. This increasing trend of disease incidence has also been reported in other regions with a large number of COVID-19 infection.^{2,4,5}

Owing to paucity of data on related management strategies, most cases of acute

limb ischaemia associated with COVID-19 have been managed as per current treatment guidelines for regular cases without COVID-19 infection. The rate of successful revascularisation and consequent limb salvage together with the overall survival appeared to be adversely affected by acquired hypercoagulopathy due to COVID-19 infection.⁴ In our setting, although there were constraints owing to a high patient load, the management strategies were optimised with a combined general and vascular surgical board consultation. In this way, treatment strategies were better tailored to each patient, taking into consideration all factors, including COVID-19

stage, requirement of isolation, grade of limb ischaemia and local ICU availability (based on age/comorbidities/premorbidity function/family support).

In the management guidelines for COVID-19 and acute limb ischaemia,¹ there is a recommendation for the use of intermittent dosing of anticoagulants, such as enoxaparin (Clexane) – Clexane requires no monitoring of the coagulation profile and avoids frequent refilling of heparin-contained syringes in infusion pumps – and non-operative procedures, such as catheter-directed thrombolysis – this avoids general anaesthesia for vascular bypass surgery or embolectomy.

Limb amputation is often resorted to as a life-saving procedure without attempts at revascularisation after careful consideration of patient age, premorbid factors and cardiovascular risks. In comparison with a European study,⁴ our case series had a low revascularisation rate, as only candidates with favourable parameters were selected. Accordingly, the success rate of revascularisation appeared higher in our series. This case series also included three cases of COVID-19 vaccination-related acute limb ischaemia.

Herein, there were a total of three cases of upper limb thrombosis, with one case related to a thrombosed radiocephalic arteriovenous fistula (Table 2). Only one case had risk factors of heavy tobacco use, diabetes and elderly age, which required limb amputation. Interestingly, all three cases had peripheral vascular thrombotic events after the second dose of vaccination, which differ from other reported cases in which such events occurred after the first dose of vaccination.⁶ All three cases had normal platelet counts, which is not related to the more frequent thrombosis as a result of antibody against platelet factor 4 (i.e. vaccine-induced immune thrombotic thrombocytopenia [VITT]). In VITT, the platelet count is often low with clinical signs and symptoms of bleeding tendencies. Enzyme-linked immunosorbent assays for heparin-induced thrombocytopenia and serotonin-release assays can be used to detect and confirm VITT. If VITT is suspected, heparin should be discontinued and replaced with an alternative anticoagulant. Platelet transfusion should be avoided, and intravenous immunoglobulin should be considered in patients with these clinically suspicious features.⁶ In our three cases, the thrombotic events may not be

directly related to vaccination but may be due to dehydration and activation of proinflammatory markers, leading to prothrombotic states following vaccination. As a general rule, primary care practitioners providing COVID-19 vaccination should advise patients on adequate fluid intake and rest and emphasise early surgical referral in cases of suspected acute limb ischaemia.

This article highlights the importance of early identification of patients with cardiovascular risk factors, such as smoking, diabetes and elderly age, making them at a high risk of arterial thrombotic events following COVID-19 infection. Heightened awareness of COVID-19-related arterial limb complications may improve patient outcomes through early diagnosis and management with judicious intravenous fluid therapy and initiation of prophylactic anticoagulation in high-risk cases. Survival is often dependent on the severity of COVID-19 pneumonia.¹ From the surgical perspective, revascularisation or limb amputation may also be life-saving. Awareness and prompt detection of acute limb ischaemia symptoms, such as paraesthesia, pain and sensory loss, are important for improving outcomes via early vascular intervention.^{2,4}

Conclusion

Acute limb ischaemia, a vascular event that may be associated with COVID-19 pneumonia or vaccination, may lead to significant morbidity and mortality. Our case series described the treatment of 12 patients with acute limb ischaemia associated with COVID-19 infection or vaccination. Although there were constraints, the management of these patients provided unprecedented experience to our team, which could then help establish a centre of care. Our study supports the data that early and appropriate intervention with medical care and revascularisation improves limb salvage and functional outcomes. We believe that patients with high cardiovascular risk profiles should be monitored for possible thrombotic complications. Patients given COVID-19 vaccine should be advised on adequate fluid intake and early consultation if signs of vascular compromise arise.

Acknowledgements

Nil.

Conflicts of interest

The authors declare no conflicts of interest. No funding was received.

Author contributions

Tan JH and Henry TCL drafted the manuscript and collected the data. Addy AAW, Ida AM, Khoo ZH and Tan PH collected the data. Mohamad Y, Rizal IA and Tuan NATM critically appraised the manuscript.

Patients' consent for the use of images and content for publication

Informed consent for the publication of the case series and accompanying images was obtained from the patients.

What is new in this case report compared to the previous literature?

- With the rising number of COVID-19 infections, there is a concomitant increase in the incidence of acute limb ischaemia.
- COVID-19-related acute limb ischaemia may present with subtle symptoms. However, early intervention during the golden hour is important to avoid major amputation.
- Optimisation of cardiovascular risk factors and adequate hydration are essential strategies at the primary care level to avoid COVID-19 vaccine- or COVID-19 infection-related limb ischaemia.

What is the implication to patients?

- Any subtle symptoms of signs shall warrant early referral for vascular assessment either in the form of doppler or angiogram.
- Early intervention when the limb is still viable may avoid major amputation.

References

1. Cuker A, Tseng EK, Nieuwlaat R, et al. American Society of Hematology 2021 guidelines on the use of anticoagulation for thromboprophylaxis in patients with COVID-19. *Blood Adv.* 2021;5(3):872-888. doi:10.1182/bloodadvances.2020003763
2. Galyfos G, Sianou A, Frountzas M, et al. Acute limb ischemia among patients with COVID-19 infection. *J Vasc Surg.* 2022;75(1):326-342. doi:10.1016/j.jvs.2021.07.222
3. Ministry of Health Malaysia. COVIDNOW in Malaysia. Accessed October 10, 2021. <https://covidnow.moh.gov.my/>
4. Bellosta R, Luzzani L, Natalini G, et al. Acute limb ischemia in patients with COVID-19 pneumonia. *J Vasc Surg.* 2020;72(6):1864-1872. doi:10.1016/j.jvs.2020.04.483
5. Surya SP, Santoso RM. A clinical case series of COVID-19-associated acute limb ischemia: real-world situation. *Egypt Heart J.* 2021;73(1):59. Published 2021 Jun 30. doi:10.1186/s43044-021-00187-0
6. Jones M, Boisvert A, Landry J, Petrsek PF. Limb ischemia and pulmonary artery thrombosis after the ChAdOx1 nCoV-19 (Oxford-AstraZeneca) vaccine: a case of vaccine-induced immune thrombotic thrombocytopenia. *CMAJ.* 2021;193(24):E906-E910. doi:10.1503/cmaj.210795