

ACUTE AND LONG-TERM PATHOLOGICAL EFFECTS OF COVID-19 ON THE PLACENTA DURING SECOND TRIMESTER AND LABOR

EFECTOS PATOLÓGICOS AGUDOS Y A LARGO PLAZO DEL COVID-19 EN LA PLACENTA DURANTE EL SEGUNDO TRIMESTRE Y EL PARTO

Fatih Taş¹ ; Fikri Erdemci² ; Mehmet Yılmaz³ ; Fırat Aşır⁴ ; Osman Özüdoğru⁵ ; Engin Deveci⁶ .

1. Siirt University, Siirt, Turkey. fatih1985tas@gmail.com
2. Dicle University, Diyarbakır, Turkey. fikri.erdemci@gmail.com
3. Siirt University, Siirt, Turkey. jindrmehmet@gmail.com
4. Dicle University, Diyarbakır, Turkey. fikri.erdemci@gmail.com
5. Siirt University, Siirt, Turkey. osmanozudogru2@gmail.com
6. Dicle University, Diyarbakır, Turkey. fikri.erdemci@gmail.com

*Corresponding author: Fatih Taş, email: fatih1985tas@gmail.com

Información del artículo:

Artículo original

DOI: <https://doi.org/10.33975/riuq.vol35n1.1154>

Recibido: 6 marzo 2023; Aceptado: 19 abril 2023

ABSTRACT

Background: COVID-19 pandemic has affected all the world. The consequence of the COVID-19 infection causes many disorders in many organs, one of them is the placenta. COVID-19 disease has long-term effects on various tissues after recovery. The aim of this study was to investigate the placentas of pregnant women with healthy, COVID-19 positive during the second trimester and labor.

Material and methods: A total of twenty-four pregnant women (8 patients per each group) were included in the study. Their placentas were processed for routine paraffin wax embedding protocol. The blood parameters of patients were recorded. Placental tissues were stained with hematoxylin-eosin dye and immune stained with TNF- α and ADAMTS-8. Statistical analysis was performed on blood and histological parameters.

Results: AST and CRP values of biochemical parameters were higher in women with second trimester and labor groups than in the healthy group. Also, a significant increase in ALT values was observed in the labor group. Normal histology was observed in the placentas of healthy patients. More histopathology was recorded in the placentas of COVID-19 infected women compared to healthy placentas. The expression of TNF- α and ADAMTS-8 were found significantly higher in the COVID-19 placentas compared to the non-COVID-19 group.

Conclusions: COVID-19 infection can cause pathological changes during pregnancy and labor. This study shows that COVID-19 not only acutely has adverse effects on placental pathologies but also has long-term effects. TNF- α and ADAMTS-8 primary antibodies can be a guide in demonstrating these effects.

Keywords: ADAMTS-8; Covid-19; placenta; TNF- α .

Cómo citar: Taş, Fatih., Erdemci, Fikri., Yılmaz, Mehmet., Aşır, Fırat., Özüdoğru, Osman., & Deveci, Engin. (2023). Acute and long-term pathological effects of COVID-19 on the placenta during second trimester and labor. *Revista de Investigaciones Universidad del Quindío*, 35(1), 228-235. <https://doi.org/10.33975/riuq.vol35n1.1154>

ISSN: 1794-631X e-ISSN: 2500-5782

Esta obra está bajo una licencia Creative Commons
Atribución-NoComercial-SinDerivadas 4.0 Internacional.



RESUMEN

Antecedentes: la pandemia de COVID-19 ha afectado a todo el mundo. La consecuencia de la infección por COVID-19 provoca muchos trastornos en muchos órganos, uno de ellos es la placenta. La enfermedad COVID-19 tiene efectos a largo plazo en varios tejidos después de la recuperación. El objetivo de este estudio fue investigar las placentas de mujeres embarazadas sanas, COVID-19 positivas durante el segundo trimestre y el trabajo de parto.

Material y métodos: Se incluyeron en el estudio un total de veinticuatro gestantes (8 pacientes por cada grupo). Sus placentas se procesaron para el protocolo de inclusión de cera de parafina de rutina. Se registraron los parámetros sanguíneos de los pacientes. Los tejidos placentarios se tiñeron con colorante de hematoxilina-eosina y se tiñeron inmunes con TNF- α y ADAMTS-8. El análisis estadístico se realizó sobre la sangre y los parámetros histológicos.

Resultados: Los valores de AST y PCR de los parámetros bioquímicos fueron mayores en las mujeres con segundo trimestre y grupos de trabajo de parto que en el grupo sano. Además, se observó un aumento significativo en los valores de ALT en el grupo de trabajo. Se observó histología normal en las placentas de pacientes sanas. Se registró más histopatología en las placentas de mujeres infectadas con COVID-19 en comparación con las placentas sanas. La expresión de TNF- α y ADAMTS-8 se encontró significativamente más alta en las placentas con COVID-19 en comparación con el grupo sin COVID-19.

Conclusiones: La infección por COVID-19 puede causar cambios patológicos durante el embarazo y el parto. Este estudio muestra que la COVID-19 no solo tiene efectos adversos agudos sobre las patologías placentarias, sino que también tiene efectos a largo plazo. Los anticuerpos primarios TNF- α y ADAMTS-8 pueden ser una guía para demostrar estos efectos.

Palabras clave: ADAMTS-8; Covid-19; placenta; TNF- α .

INTRODUCTION

A new Coronavirus called COVID-19 has emerged as a consequence of the Sars-CoV-2 virus in the Hubei province of China and has spread to multiple countries. The COVID-19 disease can be asymptomatic or turn into a severe lower respiratory tract infection. Today, the COVID-19 disease is known to exhibit widespread and multisystemic symptoms that involve both the respiratory system and the other systems.¹ Pregnancy complications such as miscarriage, intrauterine growth retardation, preeclampsia, and preterm delivery have been reported in pregnant women infected with the Sars-CoV virus and also associated with COVID-19 disease.² However, the effects of COVID-19 on pregnancy and fetal placental unit as well as the vertical transmission of the Sars-CoV-2 virus from mother to fetus are not sufficiently known.³ It was also reported that the COVID-19 infection seen in pregnant women during the second trimester was a risk factor for placental abnormalities and perinatal losses.⁴

COVID-19 is characterized by extreme pro-inflammatory cytokine production linked to patient mortality.⁵ Cytokines such as TNF- α secreted by macrophages and monocytes are key modulators of inflammation involved in the development of many diseases. The functions of TNF- α include leukocyte accumulation, proliferation, and differentiation at sites of injury and infection.⁶ A significant increase in serum levels of TNF- α was observed in most patients with severe COVID-19.⁷

A Disintegrin-like and Metalloproteinase with Thrombospondin motifs (ADAMTSs) are members of secreted matrix metalloproteinase family. ADAMTS-8 is an anti-angiogenic member of the ADAMTS

family and is expressed in macrophages.⁸ ADAMTS-8 plays a role in proteolysis, cell adhesion, cell fusion, and signal transduction. In addition, ADAMTS-8 is known to have an inflammation-regulatory effect.⁹ The ADAMTS enzymes have a role in all developmental stages of the embryonic and fetal periods.¹⁰

The aim of this study is to compare the placentas of pregnant women with healthy, COVID-19 infected in the second trimester and COVID-19 positive during labor by histopathological and immunohistochemical methods.

MATERIALS AND METHODS

Ethical approval was taken from Siirt University Non-Interventional Clinical Research Ethics Committee (record number: 12657). The study was performed by the Declaration of Helsinki. Written informed consent forms were obtained from all participants. The placentas of 24 pregnant women were assigned as healthy (n=8), second trimester (n=8) which infected with COVID-19 during the second trimester of pregnancy, and labor (n=8) infected with COVID-19 during labor. Patients had no other systemic disease (diabetes, hypertension, preeclampsia, etc.). Placental samples were obtained from pregnant women who applied to the Siirt Training and Research Hospital, Department of Obstetrics and Gynecology, following delivery.

Tissue processing

Paraffin embedding protocol was applied according to Aşır et al.¹¹ Placental samples were fixed in 10% buffered formalin. Samples were processed for routine paraffin wax tissue embedding. Samples were dehydrated through ascending alcohol series and soaked in xylene solution for 3x15 minutes. Later, samples were embedded and incubated in paraffin wax for 3x45 minutes. Tissue samples were placed in paraffin blocks. 5 µm-thick sections were cut and stained with hematoxylin-eosin dye. For hematoxylin-eosin, sections were brought to distilled water and stained hematoxylin for 8 minutes and eosin for 5 minutes. Sections were passed through ascending alcohol series and cleared in xylene and mounted with mounting medium. Sections were analyzed under light microscopy.

Immunostaining

Sections were brought to distilled water and washed in phosphate-buffered saline with Tween20 (PBS-T) for 3x5 minutes. Samples were washed in 3% H₂O₂ solution to prevent endogenous peroxide blockade for 20 minutes. A blocking solution was used for 8 minutes. Sections were incubated with ADAMTS-8 (Cat No: p300a, Thermo Fischer Scientific, USA) and TNF-α (Cat No: BS-5859R, Thermo Fischer Scientific, USA) primary antibodies at 4°C overnight. A secondary antibody was applied to sections for 14 minutes. After washing with PBS-T, the peroxidase solution was dropped onto slides for 15 minutes. DAB chromogen (Thermo, Cat. No: TA-125-HD) was used to observe color change. The sections were washed with PBS-T and counterstained with Gill III hematoxylin for 45 seconds. After washing the sections in PBS-T, the sections were passed through ascending alcohol series, cleared in xylene solution, and mounted with a mounting medium.

Biochemical analysis

Blood samples from pregnant patients were used for glucose, urea, aspartate aminotransferase (AST), alanine aminotransferase (ALT), C-reactive protein (CRP), uric acid, white cell count (WBC), red cell count (RBC), hemoglobin (HGB), hematocrit (HCT), platelet number (PLT), number of neutrophils (Neu), lymphocytes (Lym), eosinophils (Eos), basophils (Baso), monocytes (Mono) were recorded just before the delivery.

Statistical analysis

Immunohistochemical scoring was done according to Taş et al.¹² 10 areas from each specimen (a total of 80 areas for one group) were analyzed for staining intensity (0=no expression, 1=mild, 2=moderate, 3=dense, and 4=very dense). Statistical analysis was applied using the IBM SPSS 25.0 software. Data distribution was analyzed Shapiro-Wilk test. Kruskal Wallis for multiple comparisons and Mann Whitney Test for binary comparison were used. The data were recorded as arithmetic median (min-max). P<0.05 was recorded as the significance level.

RESULTS

Laboratory findings

Blood parameters were statistically analyzed and shown in Table 1. There was a significant difference between the groups in AST, ALT, and CRP values (p<0.05). There was a statistically significant increase in AST and CRP values in the second trimester and labor groups compared to the healthy group (p<0.05). A significant increase in ALT values was observed in the labor group compared to the other groups. No significant difference was found in terms of urea, uric acid, white blood cell (WBC), red blood cells (RBC), hemoglobin (HGB), hematocrit (HCT), platelets (PLT), neutrophils (Neu), lymphocytes (Lym), eosinophils (Eos), basophils (Baso), monocytes (Mono) (p>0.05). COVID-19 modulates blood parameters, especially during labor-time infection.

Table 1. Blood laboratory parameters of patients with healthy, second trimester, and labor groups.

PARAMETERS	HEALTHY MEDIAN (MIN-MAX)	SECOND TRIMESTER MEDIAN (MIN-MAX)	LABOR MEDIAN (MIN-MAX)	MULTIPLE COMPARISON
GLUKOZ	17.5 (11.00-22.40)	19.38 (13.00-25.68)	17.65 (9.00-127)	p=0.392
URE	17.5 (10.00-28.00)	22.00(17.00-27.00)	26.00 (13.00-36)	p=0.070
AST	8.5 (6.00-14.00)	14.00 (12.00-17.00) a	14.00 (9.00-27) b	p=0.019
ALT	4.35 (1.60-8.40)	4.15 (0.30-15.00) a	21.00 (7.00-32) b	p=0.001
CRP	2.93 (2.11-3.99)	4.85 (3.81-5.90) a	4.94 (3.38-5.70) b	p=0.001
URIC ACID	11.7 (7.54-14.04)	12.46 (9.84-19.08)	10.87 (6.20-13.91)	p=0.314
WBC	4.22 (4.06-4.84)	4.20 (3.44-4.53)	4.25 (3.71-5.40)	p=0.599
RBC	12.35 (11.20-15.40)	12.25 (10.90-14.2)	12.20 (9.60-13.20)	p=0.778
HGB	37.25 (35.40-46.20)	36.55 (33.10-41.8)	37.10 (33.00-40.70)	p=0.515
HCT	281 (42-325)	209.5 (187-230)	273 (80-545)	p=0.692

PARAMETERS	HEALTHY MEDIAN (MIN-MAX)	SECOND TRIMESTER MEDIAN (MIN-MAX)	LABOR MEDIAN (MIN-MAX)	MULTIPLE COMPARISON
PLT	8.72 (5.43-10.05)	9.25 (6.60-15.60)	7.58 (4.03-11.05)	p=0.223
NEU	2.04 (1.42-3.23)	2.12 (1.39-2.66)	1.64 (0.82-3.65)	p=0.468
LYM	0.06 (0.00-0.18)	0.07 (0.01-0.14)	0.04 (0.02-0.62)	p=0.996
EOS	0.03 (0.00-0.06)	0.03 (0.01-0.04)	0.02 (0.01-0.06)	p=0.831
BASO	0.57 (0.35-0.74)	0.72 (0.40-1.57)	0.60(0.16-1.55)	p=0.215
MONO	0.57 (0.35-0.74)	0.72 (0.40-1.57)	0.60 (0.16-1.55)	p=0.215

A: HEALTHY VS SECOND TRIMESTER, B: HEALTHY VS LABOR, C: SECOND TRIMESTER VS LABOR

Histopathological findings

Hematoxylin-eosin and immune staining of placental tissues were shown in Figure 1. Compared to healthy, placental histological structures degenerated in COVID-19-infected groups with high villous degeneration (Figure 1). TNF- α and ADAMTS-8 expression were statistically different between health, second trimester, and labor groups (p=0.008 and p=0.006, respectively). Comparing the second-trimester and labor groups, the increase in TNF- α and ADAMTS-8 in the labor group was significantly higher compared to the second-trimester group (p<0.05) (Figure 1, Table 2).

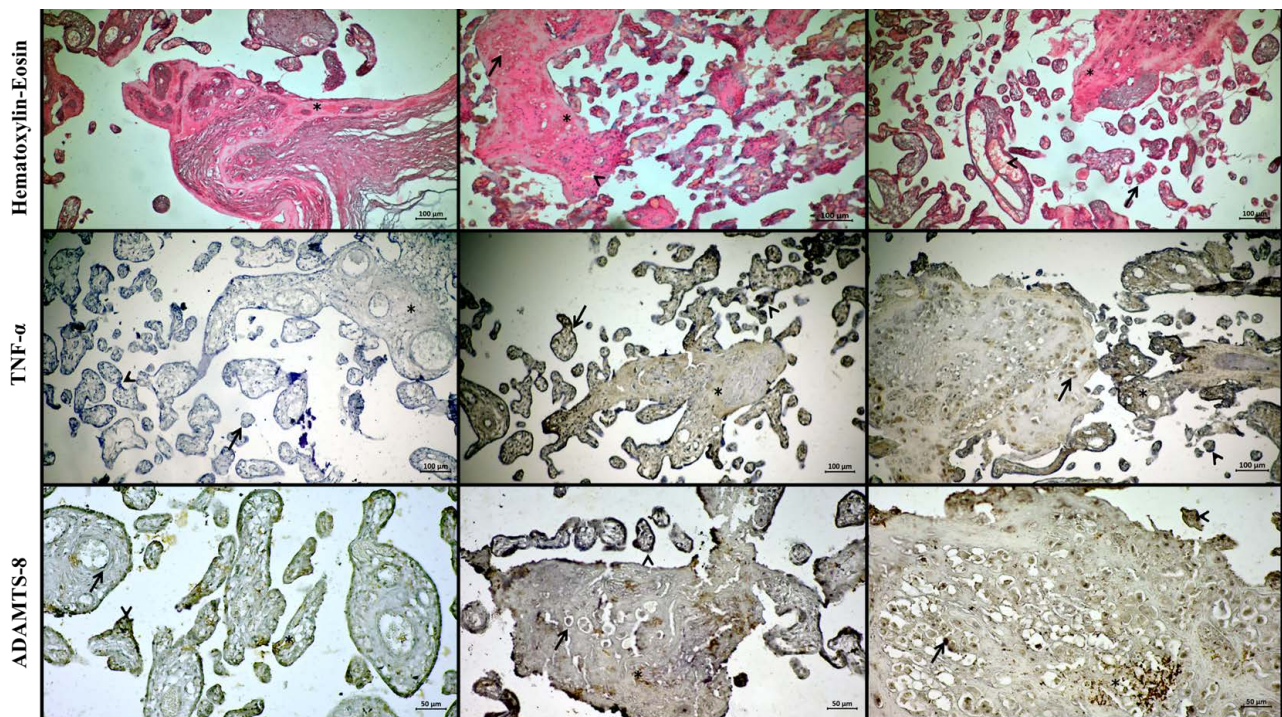


Fig. 1. Hematoxylin-eosin staining of placental tissue. Healthy group: Normal histological appearance with mild fibrin deposition (asterix). **Second-trimester group:** Degenerated decidual cells (arrow), fibrinoid deposition (asterix), dilated and congested blood vessels (arrow). **Labor group:** Chorionic villus degeneration (arrow), fibrinoid deposition (star),

vascular dilatation, and congestion (asterix). *TNF- α* immune staining of placental tissue. **Healthy group:** Very mild expression in chorionic villi (arrow), syncytial nodes (arrowhead), and villous stroma (asterix). **Second-trimester group:** Moderate expression in syncytial nodes (arrowhead), trophoblast cells (arrow), and villous stroma (asterix). **Labor group:** Intense expression in decidual cells (arrow), syncytial nodes (arrowhead), and villous stroma (asterix). *ADAMTS-8* immune staining **Healthy group:** Weak expression in syncytial nodes (arrowhead), vascular endothelium (arrow), and villous stroma (asterix). **Second-trimester group:** Mild expression in decidual cells (arrow), syncytial nodes (arrowhead), and decidual plate (asterix). **Labor group:** Intense expression in decidual cells (arrow), syncytial nodes (arrowhead), and inflammatory cells (asterix). (Scale Bar: 100 μ m, magnification: 10X).

Table 2. Comparison of TNF- α and ADAMTS-8 immune staining between groups.

PARAMETERS	HEALTHY MEDIAN (MIN- MAX)	SECOND TRIMESTER MEDIAN (MIN- MAX)	LABOR MEDIAN (MIN- MAX)	MULTIPLE COMPARISON
TNF-A	0.00 (0.00-1.00)	2.00 (2.00-4.00) a,c	4.00 (3.00-4.00) b,c	p=0.013
ADAMTS-8	0.50 (0.00-1.00)	2.00 (1.00-2.00)a,c	2.50 (2.00-4.00) b,c	p=0.008

A: HEALTHY VS SECOND TRIMESTER, B: HEALTHY VS LABOR, C: SECOND TRIMESTER VS LABOR

DISCUSSION

COVID-19 is a respiratory disease that causes hospitalization of approximately 5% of all pregnant women infected with SARS-CoV-2, leading to significant morbidity and mortality. In our study, laboratory blood parameters were recorded in the healthy, second-trimester, and labor groups. Significant elevations were observed in AST, ALT, and CRP. These data show that COVID-19 infection not only induces an inflammatory pathway but also affects the liver metabolism of the patients as in previous studies.¹³

A relationship was shown between COVID-19 and the risk of preterm delivery.¹⁴ Maternal vascular malperfusion, atherosclerosis, decidual arteriopathy, mural hypertrophy of membrane arterioles, and fibrinoid necrosis were reported in the histopathological examination of the placentas of pregnant women with SARS-CoV-2 infection in the acute period.¹⁵ In recent studies, placental pathomorphological changes were recorded in the placentas of pregnant women who were infected during the second trimester.¹⁶ In our study, we represented the histopathology of the placentas of women who were COVID-19 positive during the second trimester and labor with their laboratory blood parameters. Our results showed that increased decidual cell apoptosis, vascular dilatation and congestion, fibrinoid deposition, syncytial nodes, and inflammation in the labor group. Our results suggest that COVID-19 adversely affected the placental circulation and induction of inflammation by macrophage activity. There are limited studies investigating how the placenta is affected in COVID-19 infection cases during the second trimester of pregnancy.¹⁷ We observed that cellular degeneration and inflammation in the decidual plate, vascular dilatation and congestion in the chorionic villi; degeneration of chorionic villi and increased fibrinoid deposition in the second-trimester group. These findings are important since they suggest that histopathological changes of the COVID-19 disease are not limited to the acute period.

Increased inflammation and cytokine upregulation (TNF- α , IL-1, IL-6) is observed in COVID-19 patients.^{18,19} The main mechanism determining mortality and morbidity in this disease is considered to be the activation of the innate immune system with cytokine storm.¹⁸ TNF- α is involved in many acute inflammatory reactions and its expression is increased during inflammation.²⁰ High level of TNF- α was also recorded in the blood and tissues of COVID-19 patients.²¹ In our study, as consistent with the literature, an increase in TNF- α expression was observed in the placentas of patients infected during labor, especially in vascular endothelial cells, decidual cells, and inflammatory cells. TNF- α expression in the second-trimester group was higher than the level in the control group, predominantly in chorionic villi, syncytial nodes, and inflammatory cells. Regarding these results, proinflammatory TNF- α could be considered as a marker for detecting the long-term effects of COVID-19 infection. Therefore, in cases of COVID-19 infection at different stages of pregnancy, the TNF- α levels may be considered as a prognostic factor.

ADAMTSs play important roles in extracellular matrix remodeling, angiogenesis, cell migration, and embryonic development. These proteinases were reported to have effects on the histopathology of many diseases, including cancer and inflammatory conditions.²² ADAMTS enzymes found in the decidua and placenta are known to have roles in organogenesis and inflammation. Studies indicate that ADAMTS-8 is more expressed in maternal-fetal tissues in the early stages of pregnancy and gradually decreases in the following periods.²³ Kaya et al showed a significant increase in ADAMTS-8 expression in inflammatory and stromal cells of testicular tissues. The authors suggested that the expression of ADAMTS-8 might be a determinant protein in inflammatory testicular injury.²⁴ In our study, ADAMTS-8 expression was positive, especially in inflammatory and decidual cells in the labor group. The expression was also increased in the second-trimester group, but the increase was not as much as in the labor group. The moderate ADAMTS-8 expression in the second-trimester group may be explained by the expression of this enzyme is high in the early stages of pregnancy. This finding is consistent with our ADAMTS-8 immune staining result. In cases with a history of COVID-19 during pregnancy, ADAMTS8 and TNF- α expression may be used to determine the level of inflammation.

LIMITATIONS

This study has some limitations. The research was carried out on a total of 24 cases, however, a large number of cases in the research can contribute to more valuable results of the study. To support the immunohistochemical result, more quantitative methods could be performed.

CONCLUSION

COVID-19 causes histopathological changes in the placenta both during the second trimester and labor. This study shows that COVID-19 not only acutely has adverse effects on placental pathologies but also has long-term effects. ADAMTS8 and TNF- α expression could be used to support the inflammation level caused by COVID-19 infection, in addition to blood tests.

Conflict of interest: The authors declares the non-existence of conflicts of interest.

Contribution by author: The authors are responsible for all components of this work.

Funding or funds: No financial support was provided.

REFERENCES

- Singh A, Zaheer S, Kumar N, Singla T, Ranga S. Covid19, beyond just the lungs: a review of multisystemic involvement by Covid19. *Pathol. Res. Pract* 2021;153384. doi: 10.1016/j.prp.2021.153384
- Di Mascio D, Khalil A, Saccone G, et al. Outcome of coronavirus spectrum infections (SARS, MERS, COVID-19) during pregnancy: a systematic review and meta-analysis. *Am J Obstet Gynecol MFM* 2020;2(2):100107. DOI: 10.1016/j.ajogmf.2020.100107
- Patberg ET, Adams T, Rekawek P, et al. Coronavirus disease 2019 infection and placental histopathology in women delivering at term. *Am J Obstet Gynecol* 2021;224(4):382-e1. doi: 10.1016/j.ajog.2020.10.020
- Savchuck TV, Gychka SH, Leshchenko IV. Pathomorphological changes of the placenta in coronavirus disease (COVID-19). *Pathologia* 2021;18(2):128-35. DOI:10.31838/ijpr/2021.13.01.283
- Karki R, Sharma BR, Tuladhar S, et al. Synergism of TNF- α and IFN- γ triggers inflammatory cell death, tissue damage, and mortality in SARS-CoV-2 infection and cytokine shock syndromes. *Cell* 2021;184(1):149-68. doi: 10.1016/j.cell.2020.11.025.
- Malaviya R, Laskin JD, Laskin DL. Anti-TNF α therapy in inflammatory lung diseases. *Pharmacol Ther* 2017;180:90-8.
- Çakal B. Immunresponses COVID-19. *J Ist Faculty Med* 2021;84(2):256-63. doi: 10.1016/j.pharmthera.2017.06.008
- Ocak Z, Acar M, Gunduz E, et al. Effect of hypericin on the ADAMTS-9 and ADAMTS-8 gene expression in MCF7 breast cancer cells. *Eur Rev Med Pharmacol Sci* 2013;17(9):1185-90.
- Wagsater D, Bjork H, Zhu C, et al. ADAMTS-4 and -8 are inflammatory regulated enzymes expressed in macrophage-rich areas of human atherosclerotic plaques. *Atherosclerosis* 2008;196:514-22. doi: 10.1002/glia.23017
- Cömertoğlu İ, Sarıkaya E, Demirel M, Akyol S, Demircan K. Role of ADAMTS Gene Family in Obstetrics and Gynecology. *The Journal of Gynecology - Obstetrics and Neonatology* 2014;11(4):144-9.
- Aşır F, Nergiz Y, Pala A. Vitamin E protected the mouse adrenal gland against immobilization stress. *Pol J Vet Sci* 2022, 25(3): 447-454. DOI 10.24425/pjvs.2022.142029
- Taş F, Erdemci F, Aşır F, Maraşlı M, Deveci E. Histopathological examination of the placenta after delivery in pregnant women with COVID-19. *J Health Sci Med* 2022;5(3):868-74. doi:10.32322/jhsm.1100731
- Sabri S, Bourron O, Phan F, Nguyen LS. Interactions between diabetes and COVID-19: A narrative review. *World J Diabetes* 2021;12(10):1674-92. doi: 10.4239/wjd.v12.i10.1674.
- Khoury R, Bernstein PS, Debolt C, et al. Characteristics and outcomes of 241 births to women with severe acute respiratory syndrome coronavirus 2 (SARS-CoV-2) infection at five New York City medical centers. *Obstet Gynecol* 2020;136(2):273-82. DOI: 10.1097/AOG.0000000000004025
- Shanes ED, Mithal LB, Otero S, Azad HA, Miller ES, Goldstein JA. Placental pathology in COVID-19. *Am J Clin Pathol* 2020;154(1):23-32. DOI: 10.1093/ajcp/aqaa089
- Baud D, Greub G, Favre G, et al. Second-trimester miscarriage in a pregnant woman with SARS-CoV-2 infection. *JAMA* 2020;323(21):2198-200. doi: 10.1001/jama.2020.7233
- Abu-Amara J, Szepecht D, Al-Saad SR, Karbowski LM. Contracting COVID-19 in the first and second trimester of pregnancy: what we know - a concise qualitative systematic review. *Arch Med Sci.* 2021;17(6):1548-1557. doi: 10.5114/aoms/133121.
- Felsenstein S, Herbert JA, McNamara PS, Hedrich CM. COVID-19: Immunology and treatment options. *Clin. Immunol* 2020;215:108448. doi: 10.1016/j.clim.2020.108448.
- Taş F, Yılmaz M, Erdemci F, Aşır F, Deveci E. Examining the long-term effects of COVID-19 on the umbilical cord. *Journal of Health Sciences and Medicine.* 2022;5(5): 1371-77. doi:10.32322/jhsm.1138691.
- Feldmann M, Maini RN, Woody JN, et al. Trials of anti-tumour necrosis factor therapy for COVID-19 are urgently needed. *The Lancet* 2020;395(10234):1407-9. DOI: 10.1016/S0140-6736(20)30858-8
- Mortaz E, Tabarsi P, Jamaati H, et al. Increased Serum Levels of Soluble TNF- α Receptor Is Associated with ICU Mortality in COVID-19 Patients. *Front Immunol.* 2021;12:592727. doi:10.3389/fimmu.2021.592727
- Demircan K, Comertoglu I, Akyol S, Yiğitoğlu BN, Sarıkaya E. A new biological marker candidate in female reproductive system diseases: Matrix metalloproteinase with thrombospondin motifs (ADAMTS). *J Turk Ger Gynecol Assoc* 2014;15(4):250-5. DOI: 10.5152/jtgga.2014.14206
- Kaya S, Nergiz Y, Aşır F, Özkorkmaz EG, Erdoğan G, Deveci E. Immunohistochemical analysis of sflt-1 and Adamts-8 expression in diabetic rat testis tissue. *Int. J. of Health Serv. Res. and Policy* 2019;4(3):225-32. doi:10.23884/ijhsrp.2019.4.3.07
- Namli Kalem M, Kalem Z, Bakirarar B, Demircan K. Adamts 1, 4, 5, 8, and 9 in Early Pregnancies. *Fetal and pediatric pathology* 2017;36(5):387-99. doi: 10.1080/15513815.2017.1354410.