

## Определение концентрации сосудистого эндотелиального фактора роста в сыворотке крови пациентов с варикозным расширением вен после стандартной флебэктомии и гибридного лечения

Ф. Адылханов<sup>1</sup>, А. Фурсов<sup>1</sup>, Ю. Носо<sup>2</sup>

<sup>1</sup>Астанинский медицинский университет, Республика Казахстан,

<sup>2</sup>Университет Симане, г. Идзумо, Япония

## Determination of vascular endothelial growth factor concentration in serum of patients with varicose veins after conventional phlebectomy and hybrid treatment

F. Adylkhanov<sup>1</sup>, A. Fursov<sup>1</sup>, Y. Noso<sup>2</sup>

<sup>1</sup>Astana Medical University, Kazakhstan,

<sup>2</sup>Shimane University, Izumo City, Japan

### Реферат

**Цель.** Изучить изменение уровня сосудистого эндотелиального фактора роста (VEGF) и частоту рецидива варикозного расширения вен после стандартной флебэктомии и гибридного лечения.

**Материалы и методы.** В исследование включили 134 пациента, которых разделили на две группы в зависимости от метода лечения. Флебэктомию выполняли по стандартной методике. Гибридное лечение включало лазерную абляцию, ультразвуковую пенообразующую склеротерапию (этоксисклерол 1–3%), высокую степень лигирования, полное или частичное удаление подкожной вены. Лечение было индивидуальным для каждого пациента. Образцы сыворотки отбирали у пациентов до и через 3–12 мес после операции. Контрольную группу составили 20 здоровых лиц. Проанализированы изменения уровня VEGF в сыворотке крови пациентов до и после лечения.

**Результаты.** Средний уровень VEGF снизился в 3,95 – 5,38 раза после лечения. У пациентов, у которых возник рецидив варикозного расширения вен, уровни VEGF были выше, чем у остальных пациентов.

**Выводы.** Результаты исследования позволяют предположить наличие связи между рецидивом варикозного расширения вен и изменением уровня VEGF.

**Ключевые слова:** варикозное расширение вен; неоваскуляризация; флебэктомия; гибридное лечение; сосудистый эндотелиальный фактор роста.

### Abstract

**Objective.** To study the change of the vascular endothelial growth factor (VEGF) level and the incidence of recurrence of varicose veins after conventional phlebectomy and hybrid treatment.

**Materials and methods.** Conventional phlebectomy was performed according to standard technique. Hybrid treatment consisted of combination of methods, including laser ablation, ultrasound guided foam sclerotherapy (aethoxysklerol 1–3%), high degree of ligation (HL), total or partial stripping of saphenous vein. The treatment was personalized to every patient. This study included 134 patients, that were divided into two groups, depending on the method of treatment. Serum samples were collected from patients before operation and in 3–12 months after operation. Control group included 20 healthy persons. We analyzed mean concentration and change of the VEGF levels in patients' serum before and after treatment.

**Results.** Mean levels of VEGF decreased in 3.95 – 5.38 times after the treatment. Also, recurrent cases were estimated. In the case of the recurrence, VEGF levels were higher than in non-recurrent cases.

**Conclusions.** Therefore, results of the study suggest an association between the recurrence of varicose veins and the change of VEGF level.

**Keywords:** varicose veins; neovascularization; phlebectomy; hybrid; vascular endothelial growth factor.

### Introduction

Chronic venous insufficiency (CVI) is widely spread pathology. Symptoms of CVI can be found in 25–27% of women and 15% of men in adult population [1–2]. It affects 33 million patients over 40 years old (11 million men and 22 million women) in the USA [3]. Despite the great progress in treatment, signs of the recurrence and progression of varicose veins (VV) can be diagnosed at 21–23% of patients [4].

There are 3 general types of recurrence of VVs [5]:

1) Residual VV, (that can be found in operation area during one month or later in post operative period).

2) True recurrent VV: that appears after one month in post operative period due to neovascularization or wrong management strategy.

3) New VV, that were absent before surgery and appeared because of the disease progression [5].

Many researches mark a neovascularization or neoangiogenesis as a major reason of VV recurrence [5]. Traditionally, many surgeons believe, that the recurrence can be prevented by an adequately performed operation. Several works have questioned the traditional view. Researchers found newly formed vessels in the inguinal area of patients after ligation and stripping of great saphenous vein (GSV). This was documented by ultra sound doplerography and phlebography [6]. But results of other studies show that neovascularization appeared in a relatively small group of patients with recurrent VV. The recurrence was mostly related to an inadequate surgery and progression of the disease [7]. In fact, these statements do not always contradict to each other. Neovascularization can appear after a properly performed operation. On the other hand, the incompetence of sapheno-femoral junction (SFJ) or untreated GSV forms favorable conditions for the formation of the recurrent reflux [8].

Neovascularization can cause a reappearance of VV in 2 different ways:

- 1) Due to the enlarging of small venous branches between deep and superficial veins.
- 2) Due to the creation of new vessels that reconnects basin of deep and superficial veins [7, 9].

An important protagonist of neovascularization and angiogenesis, so called “vascular endothelial growth factor” (VEGF) was determined in 1989 by N. Ferrara, W. I. Herzel [10]. In further studies, elevated level of VEGF has been found in serum, plasma and epidermis of patients with VV [11–14].

VEGF has dual roles in organism. On the one hand, it is necessary for the stability of the endothelium and for the physiological neoangiogenesis. On the other hand, VEGF plays a leading role in the pathogenesis of oncologic diseases. VEGF is a pro-inflammatory cytokine that induces the activity of macrophages and endothelium [15]. Therefore, VEGF is necessary for the maintenance of vascular integrity and reactivity [16]. The presence of VEGF is established in the epidermis of patients with chronic venous insufficiency (CVI). Also the high level of VEGF is found in blood plasma which increases during the progression of the disease [17]. Similarly, an increase in the expression of the VEGF gene in VV is clearly associated with an incompetence of SFJ. It is considered that VEGF is induced in patients with VV to repair tissue damage caused by venous hypertension [18].

Despite the large number of patients with varicose veins, there is no general consensus on treatment strategy [19]. This is why to achieve better clinical results treatment strategy should be personalized.

## Methods

### Selection criteria

Patients with primary varicose veins of C2, C3 and C4 class according to CEAP classification were included into the study. All patients were over 18 years of age.

Exclusion criteria was following: any operations, injuries or infection 30 days before the study, blood disorders, diabetes mellitus, arterial disease (ankle-brachial index, 0.9), impaired renal or hepatic function, deep venous thrombosis (less than 1 year), pregnant or lactating women, skin ulcers, benign or malignant tumors of any localization.

Before the operation, the following studies were performed: ECG, Chest x-ray, ultrasound doplerography of veins, common blood count, urine test, biochemical blood test, coagulogram.

The diagnosis of primary or recurrent varicose vein was performed by the clinical examination and ultra sound investigation (USI) of veins.

The presence of dilated veins, varices, pathological reflux or telangiectasias was counted as signs of primary or recurrent VV. During the USI we paid attention to the consistency and the structure of walls, compressibility of veins, function of venous valves, phases of venous flow, and presence of color filling defect, reflux or any flow disturbances. We also performed a Valsalva manoeuvre, manual distal augmentation, and plantar-flexion to check calf muscle pump.

Ethical approval for this study was given by ethical committee of the Astana Medical University. Therefore study has been performed in accordance with the ethical standards laid down in the 1964 Declaration of Helsinki and its later amendments. All patients have signed an informed consent form.

### Methods of operation

In this work we used following methods of treatment:

1. Conventional phlebectomy (CP) included high ligation, saphenous trunk stripping, ligation of perforator veins, removing of dilated tributary veins.

2. Hybrid treatment (H) consisted of combination of methods, including laser ablation, ultrasound guided foam form sclerotherapy (aethoxysklerol 1–3%), high ligation (HL), total or partial stripping of saphenous vein. The treatment was personalized to every patient. Different combinations of listed methods were applied depending on clinical stage, diameter of veins, severity of reflux, and localization of VV's.

Conventional phlebectomy is a combination of several operations, such as high ligation, GSV stripping, also known as a Babcock's operation, supra- or subfascial ligation of perforator veins, and removing of dilated tributary veins [20, 21]

**Table 1. Patient baseline characteristics and study groups**

Patient characteristics at baseline	Total patients included in the study (n = 124)		Conventional phlebectomy (n=66)		Hybrid (n=58)		Control group (n=20)	
	n	%	n	%	n	%	n	%
<b>Gender</b>								
Male	67	46.00	31	46.97	36	47.05	9	45.00
Female	57	54.00	35	53.03	22	52.95	11	55.00
<b>Age (years, age range)</b>	40.3 (21-62)		40.47 (21-62)		39.2 (21-62)		38.11 (23-48)	

Therefore, to designate a combination of endovenous and open methods of surgery, we used the term hybrid treatment.

Conventional phlebectomy was known as the gold standard of treatment for varicose veins [20] This is why results of hybrid group were compared to results of CP. After initial assessment 124 patients were included in the study, a total 248 samples were studied. All patients were divided into two groups depending on the method of operation (Table 1). There was no difference in the mean age and gender distribution between study groups. The first group included 66 patients, treated with the conventional phlebectomy. This group is marked as CP. The second group consists of 58 patients, treated with hybrid method. This group is marked as H. Serum samples of twenty healthy volunteers were studied in a control group.

**Serum sampling**

Serum samples were collected from patients before operation and 3–12 month after operation. In this period first symptoms of recurrence or progression of the disease can be found. Blood samples were taken into vacuum test-tubes and then centrifuged at 3500 rpm for 10 minutes. Samples were stored at -20°C until the test. In our experiment ELISA test was conducted using a commercially available kit (Thermo Scientific 7335 Executive Way Frederick, MD 21704), according to manufacturer’s specification. Samples were defrosted at +20–+25°C prior to the experiment.

**Statistical analysis**

Data are expressed as mean, Stata software was used for statistical analyses. Student’s t-test was used to compare between the means. Differences were considered statistically significant at  $p < 0.05$ . To find the connection between the treatment method and VEGF level Pearson’s correlation coefficient ( $r$ ) was calculated.

**Results**

After conducting the experiment on the determination of VEGF level in serum of patients with varicose veins, we reached the following results.

Serum VEGF levels have a significant difference before and after treatment (Fig. 1). As we can see in CP group the mean level of serum VEGF before operation was 104.16 pg/ml, whereas after operation it decreased 3.95 times and equals

to 26.39 pg/ml ( $p < 0.05$ ,  $r=0.782$ ). Mean concentration of VEGF in hybrid group decreased 3.95 times, from 72.74 pg/ml before operation to 13.5 pg/ml after the treatment ( $p < 0.05$ ,  $r=0.252$ ) There is a direct correlation between the treatment and level of VEGF change study groups.

In case of the recurrence VEGF level was higher compared to non-recurrent cases. Also in recurrent cases VEGF level did not fell lower than 62.5 pg/ml ( $p < 0.05$ ). In control group mean level of VEGF was 24.21 pg/ml.

There was no recurrence after operation if patient’s level of VEGF was lower than 62.5pg/ml. Taking into account that in control group maximal level of VEGF was  $\leq 31.25$  pg/ml, we considered the range from 7.8 to 31.25 as a normal level of VEGF and if the range of VEGF level was higher than 62.5 pg/ml we considered it as a high level. Thus, we calculated numbers of patient with normal and high level of VEGF and analyzed the change of VEGF level before and after treatment (Fig. 2, 3).

The number of samples with high level of VEGF has decreased after the treatment. According to the results before conventional phlebectomy 39 patients showed high level of VEGF and 27 showed normal level, whereas after operation number of patient with elevated level of VEGF were equal to 5. In hybrid group the high VEGF level were found in 37 patients before operation and only in 3 patients after operation. Thus, the number of samples with normal VEGF level has increased after the treatment.

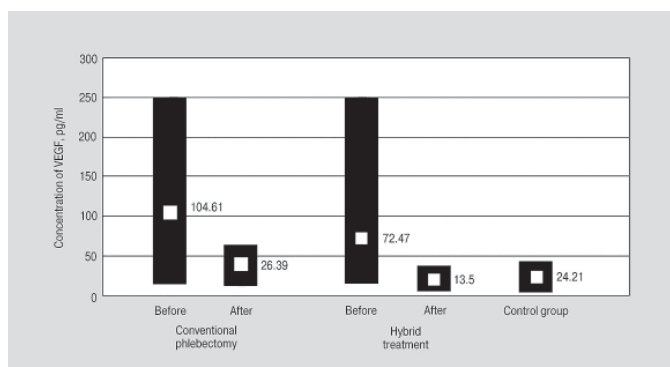


Fig. 1. Level of the VEGF before and after treatment.

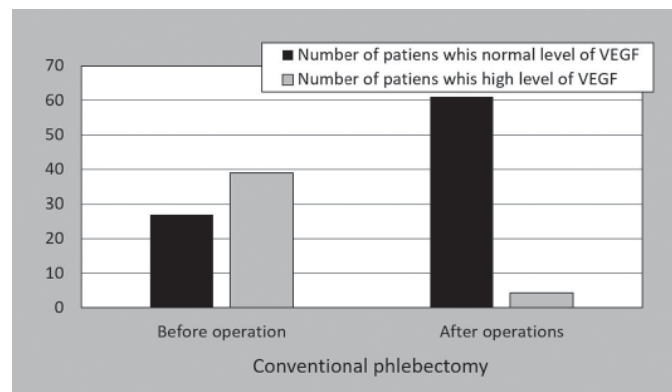


Fig. 2. Number of patients with high and normal level before and after CP.

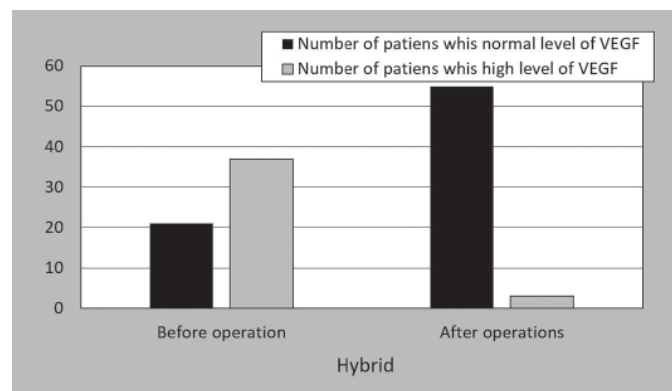


Fig. 3. Number of patients with high and normal level before and after EVLA.

**Table 2. Calculation of the number of recurrent varicose veins**

Group	Number of patients with recurrent VV	
	n	%
Conventional phlebectomy	5	7.57
Hybrid	3	5.17

**Table 3. Analysis of reasons of recurrence of varicose veins**

Group	Technical or tactical mistakes, %	True recurrent VV, %	Newly formed VV, %
Conventional phlebectomy	3.03	3.03	1.51
Hybrid	1.72	1.72	1.72

We analyzed number of recurrence of varicose veins (Table 2). After the conventional phlebectomy we found 7.57% cases of recurrences. In hybrid group 5.17% of patients showed signs of recurrence.

Speaking about the types of recurrence: of VV for CP group 3.03% of cases were connected to technical or tactical mistakes. In these cases the recurrence occurred due to unligated GSV tributaries, especially in SFJ area as well as incomplete removing of GSV trunk or/and its branches. The true recurrent VV appeared in 3.03% of cases. New VV were observed in 1.51% of cases. These cases were presented by appearance of small tortuous venous branches or/and telangiectasias.

For hybrid group technical or tactical mistakes were found in 1.72 % of cases. In this case the recurrence happened due to recanalisation of GSV branches treated with foam form sclerotherapy. The number of recurrence related to the true recurrent VV and newly formed VV was found in 1.72% of cases. These cases were presented by appearance of telangiectasias (Table 3)

**Conclusions**

After conducting the experiment on determination of VEGF level in serum of patients with varicose veins, we made the following conclusions:

- The mean level of serum VEGF in the study groups has a wide variation range. In CP groups the mean level of serum VEGF decreased 3.95 times after the treatment. The mean concentration of VEGF in hybrid group decreased 5.38 times. The observed differences are statistically significant (significance level  $p < 0.05$ ).
- The level of serum VEGF in study groups before and after operation has a direct correlation.
- In case of the recurrence, VEGF level were higher than in non-recurrent cases. Also in recurrent cases VEGF level did not fell lower than 62.5 pg/ml.
- Results of the study suggest an association between recurrence of varicose veins and change of VEGF level.
- Not only the technical and tactical mistakes can lead to the recurrence of VV, but also the process of neovascularization plays important role.

**Discussion**

The formation of new vessels after operation as a result of neovascularization has been described in previous works [22]. On the base of our results we can say that recurrence can appear even after properly performed surgery. Support to this statement can be found in the work of A. M. van Rij et al [23]. According to literature, the recurrence related to neovascularization happens in 8–60% of cases [22, 24]. Some studies revealed that there is a connection between VV and changes in VEGF level [14]. This is why we were interested to study how VEGF levels change after conventional phlebectomy and hybrid method of treatment.

After the conventional phlebectomy, new vessels are formed due to the ligation of vessels and tissue damage resulting in hypoxia [25]. This leads to the release of VEGF [26]. After the endovenous interventions damage of the endothelium may trigger the release of the VEGF. Benefits of the hybrid treatment are that it may help to avoid disadvantages of different methods of intervention. In hybrid group we had a lower recurrence rate comparing to CP group, but this didn't reach statistical significance.

We compared results of our study to the results of similar researches. In study of Florez et al. authors included 84 subjects, 44 with CVI and 40 controls. They found a prominent expression of VEGF in the VV of the CVI group than in the control group with healthy subjects [14].

In study researchers analyzed blood samples of 30 patients with primary VVs undergoing treatment with EVLA before and 1 week after operation [27]. Control group included 20 healthy persons. They found statistically significant reduction in median plasma VEGF levels before operation and rise of its level in 1 week after surgery. In our study we also found cases of normal or comparably low VEGF level in preoperative period, but after operation it decreased multiple times. We didn't find any elevation of VEGF after operation comparing to the pre-operative period. In our opinion this is connected to the period of taking of control samples. We believe rise of VEGF levels 1 week after operation in study can be connected to healing processes, as neovascularization of damaged tissue is a necessary part of healing [27, 28]. This is why we excluded any operations, injuries or infection 30 days before the study.

Yasin et al studied VEGF level of 25 patients with primary varicose veins and compared the results with 25 healthy persons. Plasma VEGF level was significantly higher in patients with varicose veins than in healthy persons [13]. This results correlate with our study, as we also found high levels of serum VEGF before treatment and decreasing of VEGF level after the treatment.

As we can see, there are studies that analyzed the relationship between VVs and VEGF. But we didn't find any studies that compared results of conventional phlebectomy with the results of hybrid treatment. According to the results of our study not only surgeon's mistakes leads to the recurrence, but also the process of neovascularization itself plays an important role in recurrence and progression of the disease. This kind of the information may help to protect surgeons in controversial cases. Further studies of this field in a larger group may lead to better understanding of the pathogenesis of the recurrence and discovering of new antiangiogenic therapy strategies in future.

**Acknowledgements**

**Funding**

The study was carried out in the framework of doctoral studies in Astana Medical University.

**Authors' contributions**

All the authors contributed equally to this work. All authors read and approved the final manuscript.

**Competing interests**

The authors who have taken part in this study declared that they do not have any conflict of interest with respect to this manuscript.

**Consent for publication**

All the authors have consented for publication of this manuscript.

**Reference**

1. CM. Epidemiology and pathophysiology of varicose veins. Techniques in vascular and interventional radiology. 2003 September; 6(3): 108–110. [https://dx.doi.org/10.1053/S1089-2516\(03\)00060-X](https://dx.doi.org/10.1053/S1089-2516(03)00060-X)
2. Criqui MH, Jamosos M, Fronck A, Denenberg JO, Langer RD, Bergan J, et al. Chronic venous disease in an ethnically diverse population – The San Diego population study. *Am J Epidemiol.* 2003 Sep 1; 158(5): 448–456. PMID: 12936900.
3. Gloviczki P, Comerota AJ, Dalsing MC, Eklof BG, Gillespie DL, Gloviczki ML, et al. The care of patients with varicose veins and associated chronic venous diseases: Clinical practice guidelines of the Society for Vascular Surgery and the American Venous Forum. *Journal of Vascular Surgery.* 2011 May; 53: 2S–48S. <https://doi.org/10.1016/j.jvs.2011.01.079>.
4. Ebner JA, Ebner A, Taurino M, Morandell S, Falk M, Stringari C, et al. Recurrent residual or progressive varicose veins: postoperative long term follow-up of 353 patients. *Ann Ital Chir.* 2017; 88(6): 526–533. PMID: 29339588.
5. Kostas T, Ioannou CV, Touloupakis E, Daskalaki E, Giannoukas AD, Tsetis D, et al. Recurrent varicose veins after surgery: A new appraisal of a common and complex problem in vascular surgery. *Eur J Vasc Endovasc Surg.* 2004 Mar; 27(3): 275–282. <https://doi.org/10.1016/j.ejvs.2003.12.006>
6. Glass GM. Neovascularization in recurrence of varices of the great saphenous vein in the groin–phlebography. *Angiology.* 1988 Jul;39(7 Pt 1):577–82. <https://doi.org/10.1177/000331978803900704>
7. El Wajeh Y, Giannoukas AD, Gulliford CJ, Suvarna SK, Chan P. Saphenofemoral venous channels associated with recurrent varicose veins are not neovascular. *Eur J Vasc Endovasc Surg.* 2004 December; 28(6): 590–594. <https://doi.org/10.1016/j.ejvs.2004.09.011>
8. Recek C. Significance of Reflux Abolition at the Saphenofemoral Junction in Connection with Stripping and Ablative Methods. *Int J Angiol.* 2015 Dec; 24(4): 249–261. <https://doi.org/10.1055/s-0035-1546439>
9. Fischer R, Linde N, Duff C, Jeanneret C, Chandler JG, Seeber P. Late recurrent saphenofemoral junction reflux after ligation and stripping of the greater saphenous vein. *J Vasc Surg.* 2001 Aug; 34(2): 236–240. <https://doi.org/10.1067/mva.2001.115802>
10. Ferrara N, Henzel WJ. Pituitary follicular cells secrete a novel heparin-binding growth factor specific for vascular endothelial cells. 1989. *Biochem Biophys Res Commun.* 2012 Aug 31;425(3):540–7. <https://doi.org/10.1016/j.bbrc.2012.08.021>.
11. Hollingsworth SJ, Powell GL, Barker SGE, Cooper DG. Primary varicose veins: Altered transcription of VEGF and its receptors (KDR, flt-1, soluble flt-1) with sapheno-femoral junction incompetence. *Eur J Vasc Endovasc Surg.* 2004 Mar; 27(3): 259–68. <https://doi.org/10.1016/j.ejvs.2003.12.015>
12. Tisato V, Zauli G, Giancesini S, Menegatti E, Brunelli L, Manfredini R, et al. Modulation of Circulating Cytokine-Chemokine Profile in Patients Affected by Chronic Venous Insufficiency Undergoing Surgical Hemodynamic Correction. *J Immunol Res.* 2014;2014:473765. 2014. <https://doi.org/10.1155/2014/473765>.
13. Yasim A, Killinc M, Aral M, Oksuz H, Kabaci M, Eroglu E, et al. Serum concentration of procoagulant, endothelial and oxidative stress markers in early primary varicose veins. *Phlebology.* 2008; 23(1):15–20. <https://doi.org/10.1258/phleb.2007.007014>.
14. Florez A, De Haro J, Bleda S, Varela C, Esparza L, Acin F. Analysis of vascular endothelial growth factor gene expression in the tissues of patients with chronic venous insufficiency. *Phlebology.* 2013; 28(1): 32–37. <https://doi.org/10.1258/phleb.2011.011102>.
15. Zachary I, Mathur A, Yla-Herttuala S, Martin J. Vascular protection – A novel nonangiogenic cardiovascular role for vascular endothelial growth factor. *Arterioscler Thromb Vasc Biol.* 2000 June; 20(6): 1512–1520. PMID: 10845866.
16. Servos S, Zachary I, Martin JF. VEGF modulates NO production: the basis of a cytoprotective effect? *Cardiovasc Res.* 1999 Mar; 41(3): 509–510. [https://doi.org/10.1016/S0008-6363\(98\)00293-4](https://doi.org/10.1016/S0008-6363(98)00293-4)
17. Shoab SS, Scurr JH, Coleridge-Smith PD. Increased plasma vascular endothelial growth factor among patients with chronic venous disease. *J Vasc Surg.* 1998 Sep; 28(3): 535–540. PMID: 9737465.
18. Howlader MH, Smith PDC. Relationship of plasma vascular endothelial growth factor to CEAP clinical stage and symptoms in patients with chronic venous disease. *Eur J Vasc Endovasc Surg.* 2004 Oct; 27(1): 89–93. <https://doi.org/10.1016/j.ejvs.2003.10.002>
19. Luebke T, Brunkwall J. Systematic review and meta-analysis of endovenous radiofrequency obliteration, endovenous laser therapy, and foam sclerotherapy for primary varicosis. *J Cardiovasc Surg (Torino).* 2008 Apr; 49(2): 213–33. PMID: 18431342.
20. Winterborn RJ, Earnshaw JJ. Crossectomy and great saphenous vein stripping. *J Cardiovasc Surg (Torino).* 2006 Feb; 47(1): 19–33. PMID: 16434942.
21. Cockett FB. The pathology and treatment of venous ulcers of the leg. *Br J Surg.* 1955 November; 43(179): 260–278. <https://doi.org/10.1002/bjs.18004317905>.
22. Nyamekye I, Shephard NA, Davies B, Heather BP, Earnshaw JJ. Clinicopathological evidence that neovascularisation is a cause of recurrent varicose veins. *Eur J Vasc Endovasc Surg.* 1998 May; 15(5): 412–415. [https://doi.org/10.1016/S1078-5884\(98\)80202-5](https://doi.org/10.1016/S1078-5884(98)80202-5).
23. Van Rij AM, Jones GT, Hill GB, Jiang P. Neovascularization and recurrent varicose veins: More histologic and ultrasound evidence. *J Vasc Surg.* 2004 Aug; 40(2): 296–302. <https://doi.org/10.1016/j.jvs.2004.04.031>
24. Van Rij AM, Jiang P, Solomon C, Christie RA, Hill GB. Recurrence after varicose vein surgery: A prospective long-term clinical study with duplex ultrasound scanning and air plethysmography. *J Vasc Surg.* 2003 Nov; 38(5): 935–943. <https://doi.org/10.1016/S0741>
25. Fischer R, Chandler JG, De Maeseneer MG, Frings N, Lefevbre-Vilarbedo M, Earnshaw JJ, et al. The unresolved problem of recurrent saphenofemoral reflux. *J Am Coll Surg.* 2002 Jul; 195(1): 80–94. [https://doi.org/10.1016/S1072-7515\(02\)01188-2](https://doi.org/10.1016/S1072-7515(02)01188-2).
26. Witmer AN, van Blijswijk BC, Dai J, Hofman P, Partanen TA, Vrensen G, et al. VEGFR-3 in adult angiogenesis. *J Pathol.* 2001 Nov; 195(4): 490–497. <https://doi.org/10.1002/path.969>.
27. Al-Zoubi NA, Yaghan RJ, Mazahreh TS, Hijazi EM, Alqudah A, Owaisy YN, et al. Evaluation of Plasma Growth Factors (VEGF, PDGF, EGF, ANG1, and ANG2) in Patients with Varicose Veins Before and After Treatment with Endovenous Laser Ablation. *Photomed Laser Surg.* 2018 Mar; 36(3): 169–173. <https://doi.org/10.1089/pho.2017.4355>.
28. Drinkwater SL, Smith A, Sawyer BM, Burnand KG. Effect of venous ulcer exudates on angiogenesis in vitro. *Br J Surg.* 2002 Jun; 89(6): 709–713. <https://doi.org/10.1046/j.1365-2168.2002.02085.x>.

Надійшла 12.12.2018