

University of Groningen

Diagnosing Mild Forms of Anorectal Malformation With Anorectal Manometry

den Hollander, Venla E C; Gerritsen, Steffie; van Dijk, Tonnis H; Trzpis, Monika; Broens, Paul M A

Published in:
AMERICAN JOURNAL OF GASTROENTEROLOGY

DOI:
[10.14309/ajg.0000000000002121](https://doi.org/10.14309/ajg.0000000000002121)

IMPORTANT NOTE: You are advised to consult the publisher's version (publisher's PDF) if you wish to cite from it. Please check the document version below.

Document Version
Publisher's PDF, also known as Version of record

Publication date:
2023

[Link to publication in University of Groningen/UMCG research database](#)

Citation for published version (APA):

den Hollander, V. E. C., Gerritsen, S., van Dijk, T. H., Trzpis, M., & Broens, P. M. A. (2023). Diagnosing Mild Forms of Anorectal Malformation With Anorectal Manometry: A Prospective Study. *AMERICAN JOURNAL OF GASTROENTEROLOGY*, 118(3), 546-552. <https://doi.org/10.14309/ajg.0000000000002121>

Copyright

Other than for strictly personal use, it is not permitted to download or to forward/distribute the text or part of it without the consent of the author(s) and/or copyright holder(s), unless the work is under an open content license (like Creative Commons).

The publication may also be distributed here under the terms of Article 25fa of the Dutch Copyright Act, indicated by the "Taverne" license. More information can be found on the University of Groningen website: <https://www.rug.nl/library/open-access/self-archiving-pure/taverne-amendment>.

Take-down policy

If you believe that this document breaches copyright please contact us providing details, and we will remove access to the work immediately and investigate your claim.

Downloaded from the University of Groningen/UMCG research database (Pure): <http://www.rug.nl/research/portal>. For technical reasons the number of authors shown on this cover page is limited to 10 maximum.

Open

Diagnosing Mild Forms of Anorectal Malformation With Anorectal Manometry: A Prospective Study

Venla E.C. den Hollander, BSc¹, Steffie Gerritsen, BSc¹, Tonnis H. van Dijk, MD², Monika Trzpis, PhD¹ and Paul M.A. Broens, MD, PhD^{1,2}

INTRODUCTION: Rectoperineal congenital anorectal malformations (CARMs) are diagnosed by examining the perineum, combined with electric stimulation (ES) of the anal sphincter performed under anesthesia. This procedure may be troublesome because it is based on the observed contractibility of the sphincter. We aimed to add 3-dimensional high-resolution anorectal manometry (3D-HRAM) to the procedure and to assess its value for diagnosing rectoperineal forms of CARM.

METHODS: We prospectively included 66 patients younger than 24 months who presented with constipation and were suspected of CARM, idiopathic constipation, or Hirschsprung disease. The patients were assessed between 2015 and 2021 at University Medical Center Groningen, the Netherlands. All patients underwent 3D-HRAM, followed by the standard diagnostic procedure for either CARM or Hirschsprung disease.

RESULTS: Of the 51 patients who underwent both 3D-HRAM and ES, we observed that patients with rectoperineal CARM revealed a pressure gap along the anterior part of the anal sphincter. Based on this observation, we diagnosed 35 patients with CARM. Subsequently, all 35 diagnoses were confirmed with ES. Sixteen patients were diagnosed as not having CARM, 100% of whom were in agreement with the gold standard—ES. Both the specificity and sensitivity of 3D-HRAM for diagnosing rectoperineal CARM were 100%.

DISCUSSION: We consider 3D-HRAM a reliable tool for diagnosing and excluding rectoperineal CARM. Using this method in patients suspected of CARM might keep infants from undergoing unnecessary interventions requiring anesthetics, such as ES. By providing objective insight into the functional capabilities of the anal sphincter, anorectal manometry adds to the diagnosis.

KEYWORDS: anorectal malformations, anorectal manometry, diagnosis, electric stimulation

Am J Gastroenterol 2023;118:546–552. <https://doi.org/10.14309/ajg.0000000000002121>

INTRODUCTION

Neonates born with a mildly displaced rectoperineal fistula may be missed during the standard neonatal examination and often present with severe constipation later in life (1,2). Diagnosing these forms can be difficult because a bowel outlet is present in the perineum. On visual examination, it is not always clear whether the outlet is centrally located or placed (partly) outside the sphincter complex. Currently, patients suspected of these forms of congenital anorectal malformations (CARMs) undergo electric stimulation (ES) of the anal sphincter, performed under anesthesia, to confirm the diagnosis and to decide on a treatment plan (3). Using ES, a mildly displaced CARM is diagnosed if fewer contractions are evoked on the anterior side of the bowel outlet rather than in the other directions surrounding the outlet. This indicates that the bowel outlet is not located in the center of the

anal sphincter complex. If this is the case, the pediatric surgeon decides whether the sphincter muscles surrounding the bowel outlet are sufficient to hold feces or whether corrective surgery is indicated. Diagnosis and recommendations regarding treatment are therefore based solely on visual examination of the location of the anal fistula in relation to the contractability of the anal sphincter by the pediatric surgeon. Studies have demonstrated that the fistula, or ectopic anus, has features that are essential for fecal continence (4–7). Correcting the malformations surgically may damage these mechanisms and may result in worse outcomes for such patients. Conservative treatment should be considered to protect these mechanisms against accidental alteration. Recent studies that investigated the efficacy of conservative treatment in patients born with minor forms of anorectal malformations demonstrated good clinical outcomes (8,9).

¹Anorectal Physiology Laboratory, Department of Surgery, University of Groningen, University Medical Center Groningen, Groningen, the Netherlands; ²Division of Pediatric Surgery, Department of Surgery, University of Groningen, University Medical Center Groningen, Groningen, the Netherlands. **Correspondence:** Paul M.A. Broens, MD, PhD. E-mail: p.m.a.broens@umcg.nl

Received June 10, 2022; accepted October 23, 2022; published online December 23, 2022

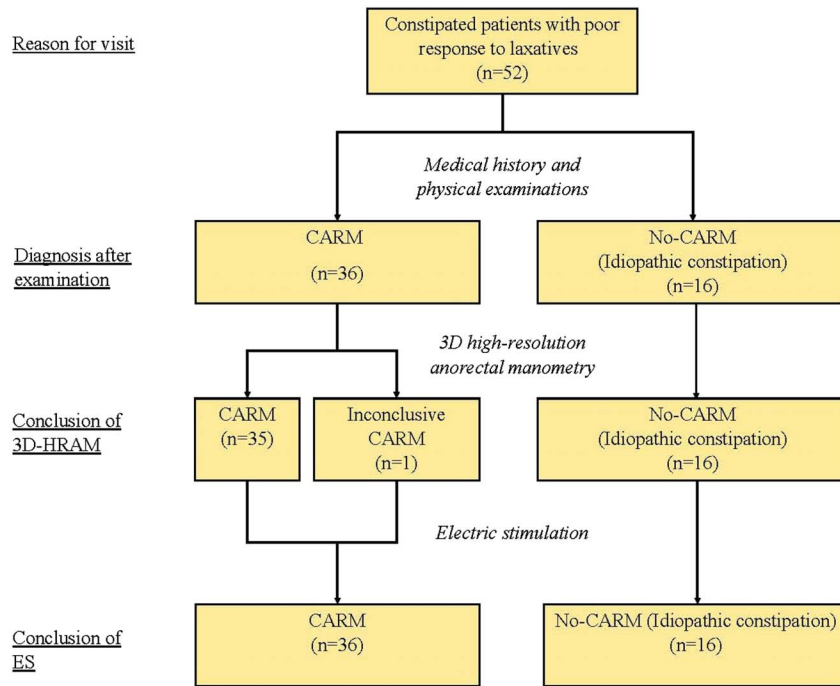


Figure 1. Flowchart of the diagnostic tests conducted: Patients were included when they experienced constipation and did not respond to laxatives. First, patients were seen by a pediatric surgeon, where they received a complete physical examination. After the initial assessment, patients underwent anorectal function tests. The anorectal function tests were followed by the gold-standard test, electric stimulation for patients suspected of CARM. The diagnoses based on all 3 examinations are presented in the yellow boxes. 3D-HRAM, 3-dimensional high-resolution anorectal manometry; CARM, congenital anorectal malformation; ES, electric stimulation.

At our medical center, we introduced the use of 3-dimensional high-resolution anorectal manometry (3D-HRAM), besides ES, to examine the functional features of the anal sphincter in patients suspected of mildly displaced CARM. 3D-HRAM can measure anal pressures through 360 degrees along the anal canal and converts these numerical outcomes into 2-dimensional (2D) and 3-dimensional (3D) images. Our preliminary analyses of these images showed that the images of patients with CARM differed from the patterns of patients without CARM. Therefore, we hypothesized that 3D-HRAM could be used to diagnose patients suspected of having a mildly displaced CARM and that 3D-HRAM can be used to provide objective information regarding the magnitude of the malformation.

The first aim of our study was to assess the diagnostic value of 3D-HRAM for rectoperineal forms of CARM, using ES as the gold standard. Our second aim was to analyze the functionality of the anal sphincter complex by measuring anal squeeze pressures. The purpose was to investigate whether anorectal manometry could be used to decide either conservative treatment or corrective surgery for optimal fecal outcomes.

METHODS

Patients

We included 66 patients younger than 24 months, who were referred to our tertiary center because of severe and chronic constipation. Before referral, all patients were treated for constipation by general pediatricians, who prescribed laxatives but to which these patients did not respond. These patients were suspected of CARM (n = 36), idiopathic constipation (n = 16), or Hirschsprung disease (n = 14). The patients suspected of CARM were all suspected of having a

mildly displaced rectoperineal fistula. We did not include patients suspected of more severe forms of CARM, such as rectovestibular fistulas. We included patients with idiopathic constipation because they undergo partially the same diagnostic tests as patients suspected of a mildly displaced CARM. Measuring healthy children younger than 24 months is not allowed for ethical reasons. We, therefore, included patients suspected of Hirschsprung disease as a negative control group for CARM because CARM and Hirschsprung disease coexistence is rare (10). All patients were measured at the Anorectal Physiology Laboratory at University Medical Center Groningen, the Netherlands, between March 2015 and January 2021. The patients suspected of CARM or a severe form of idiopathic constipation first underwent anorectal physiology tests, including 3D-HRAM, followed by ES under anesthesia (Figure 1). Patients suspected of Hirschsprung disease also underwent anorectal physiology tests, including 3D-HRAM, followed by rectal suction biopsies. The outcomes of the 3D-HRAM were used to compare the 2D and 3D images with the images of patients suspected of CARM. We collected patients’ medical history from the medical records, including information on coexisting malformations. We conducted the study in accordance with requirements of our local medical ethics review board.

Anorectal manometry equipment

The measuring equipment we used was:

1. Solar, gastrointestinal, high-resolution manometry equipment, version 8.23, from Laborie/Medical Measurement Systems BV, Enschede, the Netherlands. This equipment registers, transfers, and stores the results of the anorectal function tests.

Downloaded from http://journals.lww.com/ajg by BNDMfsePHKav1ZEoum1tQIN4a+kLHEZgpsiH04Xm0hCwycX1AWN YOpI/0HhD3i3D000dRy7/TSF14C3VC1y0abggQZxdtmKZBvYws= on 03/10/2023

- Catheter 1: Laborie/Unisensor K124059 solid state circumferential catheter with an outer diameter of 12F. This catheter has 40 sensors that measure pressure every 8 mm with 8 sensors circumferentially, over a length of 3.2 cm. It is used for the 3D-HRAM tests.
- Catheter 2: Laborie/Unisensor K12981 solid state (Boston type) circumferential catheter with an outer diameter of 12F. This catheter measures pressure every 8 mm over a total length of 6.0 cm along the anal canal and the distal rectum. It is used for the anorectal pressure tests.

We adhered to the following testing procedure. All tests were performed without anesthesia. We allowed parents to feed their infants during measurements to keep the infants occupied and stop them from trying to push out the anorectal catheter and from moving their legs. In this way, we were able to perform the measurements optimally. First, the patients underwent 3D-HRAM. For this measurement, catheter 1 was placed into the anal canal while the patient was positioned in the left lateral position. The catheter had to remain in the same position and not be allowed to move, angulate, or rotate. After correct positioning, the catheter measured the anal and rectal pressure at 360 degrees. The Laborie/MMS system registered all the anorectal pressures and presented them in 2D and 3D images, showing the circular pressures of the anal sphincter. This test took approximately 10 minutes, depending on the number of spontaneous anal contractions of the infant. At least 3 good contractions were necessary to assess the 2D and 3D images.

Second, the patients underwent the anorectal pressure test to measure basal and maximum sphincter pressure. Patients remained in the left lateral position, and catheter 2 was inserted into the anal canal after catheter 1 had been removed. The catheter remained in the anal canal without repositioning, and anal pressure was registered continuously. During these measurements, the infants also spontaneously contracted the anal sphincters, making it possible to register the maximum sphincter pressure. In between contractions, the anal resting pressure was measured. We used both pressures to quantify sphincter force. This test took approximately 10 minutes to complete.

A specialized and dedicated nurse executed the tests. The specialized nurse and an experienced pediatric medical specialist analyzed the outcomes of the tests. All tests were conducted correctly, and all outcomes could therefore be analyzed.

Diagnosis based on anorectal manometry

The 52 patients suspected of CARM or idiopathic constipation were initially diagnosed using 3D-HRAM. We diagnosed patients with a mildly displaced CARM if the 2D and 3D images revealed an interruption in the circular pressure running along the sphincter. The diagnosis was based on an interruption anterior to the bowel outlet and if the gap was measured during rest and at least 3 contractions of the anal sphincter. Patients without this interruption were diagnosed as not having a mildly displaced CARM. Patients suspected of Hirschsprung disease also underwent 3D-HRAM. The outcomes were registered as described above.

Final diagnosis

After the patients had undergone the anorectal function tests, they all received the current gold-standard test for diagnosing either CARM or Hirschsprung disease. The CARM diagnosis was based on ES performed under general anesthesia and was used to stimulate the anal sphincter. The pediatric surgeon used the Erbe NT 2

NervTest (Erbe Elektromedizin GmbH, Tübingen, Germany) device to stimulate the tissue surrounding the anal opening. If fewer or no contractions could be evoked on the anterior side of the anal opening, with the anal canal positioned more anterior in relation to the anal sphincter, then the surgeon confirmed the CARM diagnosis. We rejected the CARM diagnosis when we observed symmetrical contractions in all directions around the anal opening. This meant that the bowel outlet was surrounded and centrally located within the anal sphincter. These patients were diagnosed with idiopathic constipation.

Hirschsprung disease diagnosis was made according to the standard protocol used at our medical center. The diagnosis is based on a lack of ganglion cells and the presence of hypertrophic nerves or hyperplasia of extrinsic cholinergic nerves in the biopsy. Rectal suction biopsies were collected from all patients suspected of having Hirschsprung disease and were evaluated at the Department of Pathology. Patients diagnosed with Hirschsprung disease did not undergo ES because the anterior position of the bowel outlet was not suspected in these patients.

Patients were diagnosed with idiopathic constipation when both anorectal manometry and ES showed no interruption anterior to the bowel outlet and when Hirschsprung disease was not suspected.

Statistical analysis

Data were analyzed with SPSS 23.0 for Windows (IBM SPSS Statistics; IBM, Armonk, NY). We reported values as a number (percentage), as median (range), or as mean (SD). A Fisher exact test was used to compare the categorical variables. The continuous variables were analyzed with 1-way ANOVA. We calculated positive and negative predictive values and specificity and sensitivity by comparing the diagnoses based on the gold standard, that is, ES, with those made with 3D-HRAM. The level of statistical significance was set at $P < 0.05$.

RESULTS

Patient characteristics

Of 66 patients, 36 were suspected of CARM, 16 were suspected of idiopathic constipation, and 14 were suspected of Hirschsprung disease (Table 1). The CARM cohort and the idiopathic constipation cohort had a female predominance (72% and 62%, respectively), in contrast to the Hirschsprung disease cohort ($n = 14$), which had a male predominance (86%). Of all patients, 57 originated from the Netherlands, 5 from Turkey, 1 from Mexico, 1 from Brazil, 1 from Suriname, and 1 from Syria. The ages at the time of measurement differed significantly between the groups: Hirschsprung disease was measured and thus diagnosed earliest, whereas idiopathic constipation was diagnosed latest. The coexisting malformations are also presented in Table 1.

Comparison of 3D-HRAM and ES outcomes

All 66 patients underwent 3D-HRAM. In addition, the 52 patients suspected of CARM or idiopathic constipation underwent ES, whereas the 14 patients suspected of Hirschsprung disease underwent rectal suction biopsies. Of the 52 patients, 51 patients were eligible for analysis. Analysis of the 2D and 3D images of the 51 patients revealed that in 35 (69%) patients, the pressure surrounding the sphincter at the anterior site was interrupted during anal basal pressure measurement and the measurement of maximal sphincter contraction (Figure 2). Based on the analysis of the images, these patients received an initial diagnosis of CARM. The remaining 16 (31%) patients had no interruption of the sphincter during basal anal

Table 1. Patient characteristics

	Congenital anorectal malformation (n = 36)	Idiopathic constipation (n = 16)	Hirschsprung disease (n = 14)
Age at diagnosis, d, median (range)	86 (9–719)	332 (24–689)	8 (4–259)
Sex	Boys (28%) 10 Girls (72%) 26	Boys (38%) 6 Girls (62%) 10	Boys (86%) 12 Girls (14%) 2
Country of origin	The Netherlands 31 Mexico 1 Syria 1 Turkey 3	The Netherlands 15 Suriname 1	The Netherlands 11 Brazil 1 Turkey 2
Comorbidities	ASD 1 VSD 2 Kidney cyst 1 Renal agenesis 1 Hip dysplasia 1 Imperforate hymen 1 22q11.21 deletion syndrome 1	Cloacal bladder exstrophy 1 Tethered cord 1 VACTERL association 1 <i>Sacral agenesis</i> <i>ASD</i> <i>Esophageal atresia</i> <i>Radial aplasia</i>	Down syndrome 2 AVSD 1

Diagnoses were made with the gold-standard test, electric stimulation.

ASD, atrial septum defect; AVSD, atrioventricular septum defect; VACTERL, vertebral defects, anal atresia, cardiac defects, tracheoesophageal fistula, renal abnormalities, and limb abnormalities; VSD, ventricular septum defect.

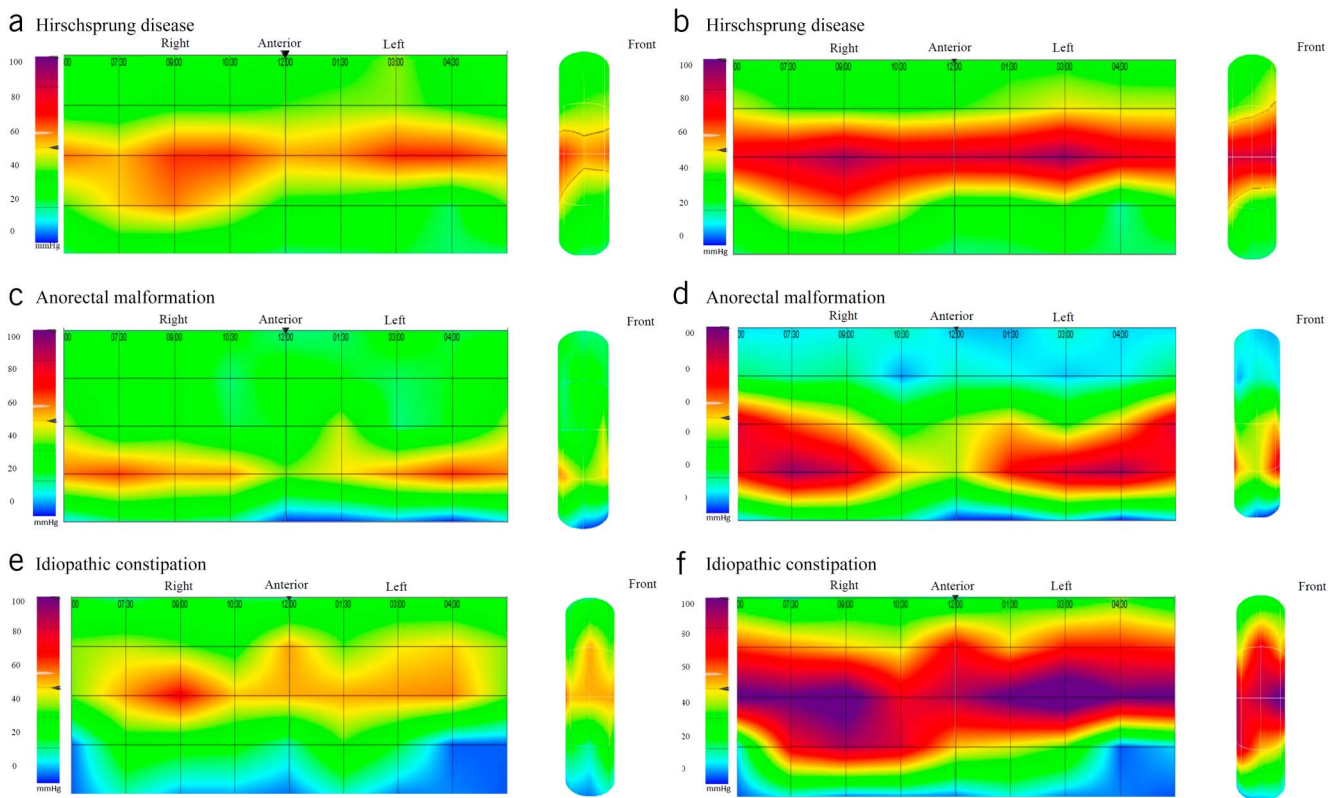


Figure 2. Outcomes of 3-dimensional high-resolution anorectal manometry: Two-dimensional (2D) images and 3-dimensional (3D) cylinders represent the circular distribution of sphincter pressures. Low pressures are shown in blue and green, and high pressures are shown with colors ranging from red to purple. (a) A patient diagnosed with Hirschsprung disease. A 2D image and a 3D cylinder during sphincter relaxation. (b) A patient diagnosed with Hirschsprung disease. A 2D image and a 3D cylinder during sphincter contraction. (c) A patient diagnosed with a mildly displaced anorectal malformation. A 2D image and a 3D cylinder during sphincter relaxation. (d) A patient diagnosed with a mildly displaced anorectal malformation. A 2D image and a 3D cylinder during sphincter contraction. (e) A patient diagnosed with idiopathic constipation. A 2D image and a 3D cylinder during sphincter relaxation. (f) A patient diagnosed with idiopathic constipation. A 2D image and a 3D cylinder during sphincter contraction.

Table 2. Specificity and sensitivity

Diagnosis by 3-dimensional high-resolution measurement	Diagnosis by electric stimulation			Formula
	Positive for CARM	Negative for CARM	Total	
Positive for CARM	35	0	35 ^a	PPV = 100%
Negative for CARM	0	16	16	NPV = 100%
Total	35	16	51	
Formula	Sensitivity = 100%		Specificity = 100%	

CARM, congenital anorectal malformation; NPV, negative predictive value; PPV, positive predictive value.

^aOne patient with an inconclusive 3-dimensional image was not included in the contingency table.

pressure measurement nor during maximal anal sphincter pressure measurement and therefore received an initial diagnosis of no CARM. Analysis of the 2D and 3D images of patients with Hirschsprung disease ($n = 14$), that is, our negative control group, revealed no interruption in the circular pressure running along the anal sphincter (Figure 2).

Of the 35 patients diagnosed with CARM using 3D-HRAM, all 35 were diagnosed with CARM by ES. Thus, 3D-HRAM had a positive predictive value of 100%. The analysis of the 2D and 3D images of 1 patient did not fit the criteria for CARM and was therefore not included in the contingency table. The images revealed an asymmetrical pressure measurement at 2 locations, thus 2 individual interruptions. These interruptions were measured during basal pressure and maximal squeeze pressure. The investigation under anesthesia revealed that the patient had both a CARM (on the anterior side) and a chronic anal fissure (on the dorsal side), which was also measured by 3D-HRAM.

ES also confirmed that of the 16 patients, whom 3D-HRAM diagnosed as no CARM, all indeed did not have CARM. Thus, 3D-HRAM had a negative predictive value of 100%.

Analyses revealed that both the sensitivity and the specificity of 3D-HRAM for diagnosing CARM were 100% (Table 2).

Anorectal manometry in patients with CARM vs Hirschsprung disease and constipated patients

To investigate the functionality of the anal sphincter in patients with CARM, the anal basal pressure and the maximum sphincter squeeze pressures were measured in all groups during the anorectal pressure test. Patients with CARM had a mean maximum sphincter pressure of 228 mm Hg (SD, 80 mm Hg), patients with Hirschsprung disease 226 mm Hg (SD, 65 mm Hg), and patients diagnosed with idiopathic constipation 243 mm Hg (SD, 86 mm Hg). These outcomes were not significantly different ($P = 0.805$).

DISCUSSION

We investigated the additional use of 3D-HRAM for diagnosing mildly displaced rectoperineal CARM and investigated whether this diagnostic tool could be used to recommend either conservative treatment or corrective surgery. We confirmed our preliminary observations that the interruptions measured using 3D-HRAM were most useful for diagnosing mildly displaced CARM. We also believe that knowledge of the resting and squeeze

pressures of the sphincters seems important when recommending further treatment because it provides more objective information than is retrieved from ES. In addition, 3D-HRAM is conducted without requiring anesthetics.

The first aim of our study was to investigate whether 3D-HRAM could be used to diagnose mildly displaced CARM. This technique provides a graphical representation of the pressure distribution surrounding the bowel outlet and reveals a characteristic pattern in patients born with this type of CARM. The analysis of this phenomenon creates the impression of a gap anterior to the anal sphincter. Importantly, this gap must be present during basal pressure measurements and maximal anal sphincter pressure. We did not observe this kind of gap in any of the patients in this cohort diagnosed with Hirschsprung disease or idiopathic constipation. ES confirmed all the diagnoses made using 3D-HRAM. It also correctly excluded CARM in all other patients.

Our study demonstrated that 3D-HRAM is a reliable additional tool to objectively diagnose or exclude a mildly displaced CARM. We showed that the sensitivity and the specificity of 3D-HRAM are 100% in both cases. Because 3D-HRAM can be conducted without requiring anesthetics and only takes approximately 10 minutes, we recommend 3D-HRAM for all patients suspected of a mildly displaced CARM.

Besides the clear visual images provided by 3D-HRAM, anorectal manometry has an additional advantage over ES in that it can measure the squeeze pressures of the anal sphincter. In general, forceful contractions of the anal sphincter are one of the essential mechanisms necessary to establish fecal continence in later life (11). If the bowel outlet is located too far from the center of the anal sphincter, insufficient pressure can be built up to withhold feces at urge, and patients will not be able to control their defecation process. In such cases, pediatric surgeons recommend corrective surgery, disregarding the fact that the decision is only based on the surgeons' observations, and surgery is not always necessary in these forms of CARM (8,9). Our study showed that the patients with CARM from our cohort had a similar mean maximum sphincter pressure as patients born with Hirschsprung disease or idiopathic constipation. This information gives the pediatric surgeon a more objective view regarding the possibility of fecal continence of the presented malformation. Conservative treatment should be seriously considered in these patients, especially when anorectal manometry demonstrates comparable maximum squeeze pressures to those with a normal positioned anal canal central in the anal sphincter. Altogether, we recommend performing anorectal manometry in all patients suspected of a mildly displaced rectoperineal fistula and to consider conservative treatment when high maximum squeeze pressures are measured. Patients with Hirschsprung disease, that is, without an anorectal malformation but with a normally positioned anus and a normal sphincter complex, were able to contract their sphincters with a mean sphincter force of 225 mm Hg. Therefore, we propose to set this pressure as the standard for recommending either conservative treatment or corrective surgery in case of a mildly displaced CARM.

We are aware that 3D-HRAM is a relatively new and expensive technique, and therefore, not all medical centers have implemented 3D-HRAM in their clinics. As a result, to the best of our knowledge, no other studies have investigated this diagnostic tool in patients suspected of a mildly displaced CARM. Furthermore, the performance of 3D-HRAM in babies and also the interpretation of the outcomes require experience and precision. The catheter must remain in the same position throughout the

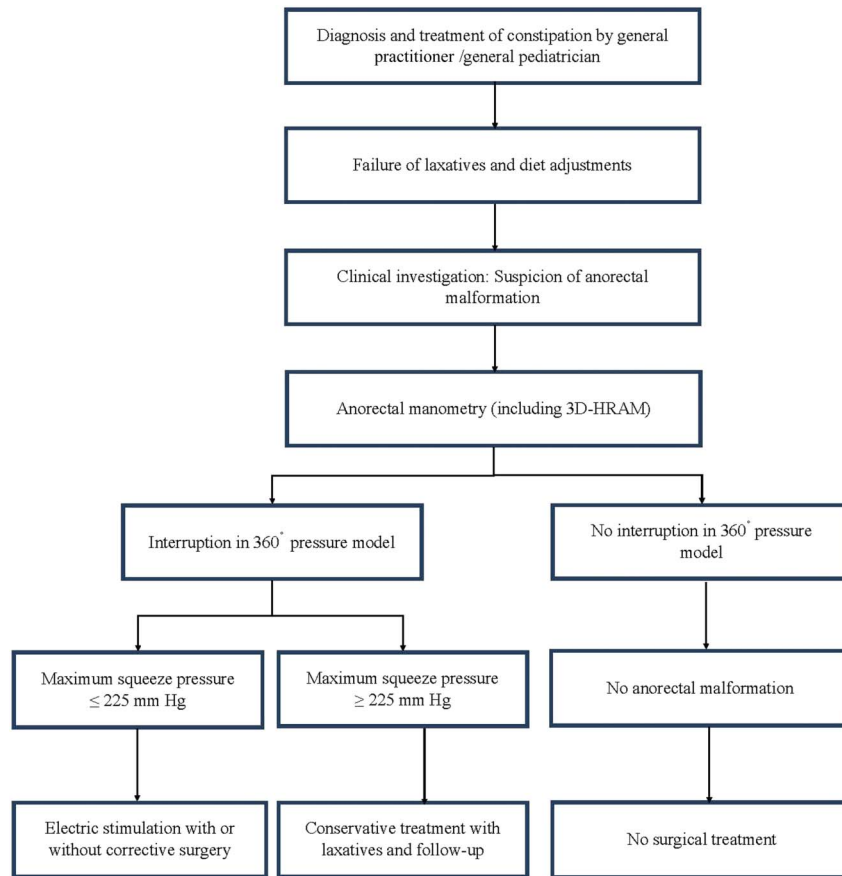


Figure 3. An algorithm presenting the proposed pathway for diagnosing rectoperineal forms of CARM. In case patients present with severe constipation who do not respond to laxatives, we propose that patients suspected of having a rectoperineal anorectal malformation should first undergo anorectal manometry, including 3D-HRAM. This diagnostic tool demonstrates either an interruption anterior to the bowel outlet or no interruption. In case of an interruption, the maximum squeeze pressures should be measured. The outcome determines whether conservative treatment or corrective surgery is recommended. We can reject the CARM diagnosis if no interruption is measured with 3D-HRAM. 3D-HRAM, 3-dimensional high-resolution anorectal manometry; CARM, congenital anorectal malformation.

measurement. A slight movement or angulation of the catheter can influence the outcomes. Therefore, in the case of the hospitals equipped with 3D-HRAM, we advise that versed specialized investigators conduct and analyze the anorectal function tests.

Despite this currently limited availability of the 3D-HRAM, its implementation is of relevant clinical value because using 3D-HRAM for diagnosing CARM instead of ES will protect babies from undergoing general anesthesia.

To summarize our recommendations, we created an algorithm for diagnosing and treating CARM (Figure 3).

The limitation of our study is that we assessed 3D-HRAM in patients suspected of 1 specific anorectal malformation type (mildly displaced rectoperineal fistula). Further research is necessary to investigate the use of 3D-HRAM in patients suspected of other types of CARM. Also, we were unable to set a cutoff value of the sphincter pressure to indicate conservative treatment or corrective surgery. We recommend further research with a new design to establish the cutoff value of the sphincter pressure that would indicate in which patient surgical treatment is relevant.

3D-HRAM is a reliable additional tool for diagnosing and excluding mildly displaced CARM. We recommend conducting 3D-HRAM in all patients suspected of a mildly displaced rectoperineal fistula. In case symmetrical pressures are measured all

around the anal orifice, the conclusion is justified that the anal canal is positioned normally, that is, central to the anal sphincter, and ES becomes unnecessary. An accurate diagnosis can be made this way, and infants are kept from needing to undergo interventions under anesthesia. If a patient is diagnosed with CARM using 3D-HRAM, the diagnosis could be confirmed using ES. Anorectal manometry could form a valuable addition to the ES diagnosis by providing an objective measurement of the functional capabilities of the anal sphincter complex, thus opening the way to an objective recommendation regarding treatment. Nevertheless, further research is necessary to investigate when to recommend conservative treatment or corrective surgery.

ACKNOWLEDGMENT

We thank S. Drager for her invaluable assistance in the Anorectal Physiology Laboratory.

CONFLICTS OF INTEREST

Guarantor of the article: Paul M.A. Broens, MD, PhD.

Specific author contributions: V.E.C.d.H.: conceptualized and designed the study, collected the data, conducted analyses, drafted the manuscript, and reviewed and revised the manuscript. S.G.: collected data, interpreted the data, and reviewed the manuscript. T.H.v.D.: designed

the data collection instruments, critically revised the manuscript, and critically reviewed the manuscript for important intellectual content. M.T.: conceptualized and designed the study, designed the data collection instruments, coordinated and supervised data collection, and critically reviewed the manuscript for important intellectual content. P.M.A.B.: conceptualized and designed the study, designed the data collection instruments, coordinated and supervised data collection, and critically reviewed the manuscript for important intellectual content. All authors approved the final manuscript as submitted and agree to be accountable for all aspects of the work.

Financial support: None to report.

Potential competing interests: None to report.

Study Highlights

WHAT IS KNOWN

- ✓ Diagnosis of rectoperineal forms of anorectal malformations is based on electric stimulation.
- ✓ This diagnostic method does not include an investigation of the functional capabilities of the fistula and the anal sphincter.
- ✓ This diagnostic method is performed under general anesthesia.

WHAT IS NEW HERE

- ✓ Three-dimensional high-resolution anorectal manometry is a safe and reliable tool to diagnose anorectal malformations.
- ✓ This diagnostic tool provides objective insight into the capabilities of the fistula and the sphincter complex.
- ✓ This diagnostic tool is performed without the use of general anesthesia.

REFERENCES

1. Lindley RM, Shawis RN, Roberts JP. Delays in the diagnosis of anorectal malformations are common and significantly increase serious early complications. *Acta Paediatr* 2007;95(3):364–8.
2. Jonker JE, Trzpis M, Broens PMA. Underdiagnosis of mild congenital anorectal malformations. *J Pediatr* 2017;186:101–4.e1.
3. Pakarinen MP, Rintala RJ. Management and outcome of low anorectal malformations. *Pediatr Surg Int* 2010;26(11):1057–63.
4. Ruttenstock EM, Zani A, Huber-Zeyringer A, et al. Pre- and postoperative rectal manometric assessment of patients with anorectal malformations: Should we preserve the fistula? *Dis Colon Rectum* 2013; 56(4):499–504.
5. Cleeve S, Lawson J, Martin J, et al. Immunohistochemical confirmation of the presence of smooth muscle in the normal neonatal anorectum and in neonates with anorectal malformations. *Pediatr Surg Int* 2011;27(10): 1069–74.
6. Kerremans RPJ, Pennickx FM, Beckers JP. Functional evaluation of ectopic anus and its surgical consequences. *Am J Dis Child* 1974;128(6): 811–4.
7. Rintala R. Postoperative internal sphincter function in anorectal malformations: A manometric study. *Pediatr Surg Int* 1990;5(2): 127–30.
8. Duci M, Fascetti-Leon F, Bogana G, et al. Conservative management of anterior located anus: A medium-long term follow up. *J Pediatr Surg* 2021;56(12):2277–80.
9. Kyrklund K, Pakarinen MP, Taskinen S, et al. Bowel function and lower urinary tract symptoms in females with anterior anus treated conservatively: Controlled outcomes into adulthood. *J Pediatr Surg* 2015; 50(7):1168–73.
10. Eltayeb AA, Refaiy A. Association of Hirschsprung's disease with anorectal malformations: The early alarming signs for diagnosis and comorbidity related to this association. *J Pediatr Surg* 2020;55(9):1981–3.
11. Levitt MA, Pena A. Anorectal malformations. *Orphanet J Rare Dis* 2007; 2(1):33.

This is an open access article distributed under the terms of the Creative Commons Attribution-Non Commercial-No Derivatives License 4.0 (CCBY-NC-ND), where it is permissible to download and share the work provided it is properly cited. The work cannot be changed in any way or used commercially without permission from the journal.