

University of Groningen

The use of 3D virtual surgical planning and computer aided design in reconstruction of maxillary surgical defects

Glas, Haye H; Vosselman, Nathalie; de Visscher, Sebastiaan A H J

Published in:
Current opinion in otolaryngology & head and neck surgery

DOI:
[10.1097/MOO.0000000000000618](https://doi.org/10.1097/MOO.0000000000000618)

IMPORTANT NOTE: You are advised to consult the publisher's version (publisher's PDF) if you wish to cite from it. Please check the document version below.

Document Version
Publisher's PDF, also known as Version of record

Publication date:
2020

[Link to publication in University of Groningen/UMCG research database](#)

Citation for published version (APA):
Glas, H. H., Vosselman, N., & de Visscher, S. A. H. J. (2020). The use of 3D virtual surgical planning and computer aided design in reconstruction of maxillary surgical defects. *Current opinion in otolaryngology & head and neck surgery*, 28(2), 122-128. <https://doi.org/10.1097/MOO.0000000000000618>

Copyright

Other than for strictly personal use, it is not permitted to download or to forward/distribute the text or part of it without the consent of the author(s) and/or copyright holder(s), unless the work is under an open content license (like Creative Commons).

The publication may also be distributed here under the terms of Article 25fa of the Dutch Copyright Act, indicated by the "Taverne" license. More information can be found on the University of Groningen website: <https://www.rug.nl/library/open-access/self-archiving-pure/taverne-amendment>.

Take-down policy

If you believe that this document breaches copyright please contact us providing details, and we will remove access to the work immediately and investigate your claim.

Downloaded from the University of Groningen/UMCG research database (Pure): <http://www.rug.nl/research/portal>. For technical reasons the number of authors shown on this cover page is limited to 10 maximum.



The use of 3D virtual surgical planning and computer aided design in reconstruction of maxillary surgical defects

Haye H. Glas, Nathalie Vosselman, and Sebastiaan A.H.J. de Visscher

Purpose of review

The present review describes the latest development of 3D virtual surgical planning (VSP) and computer aided design (CAD) for reconstruction of maxillary defects with an aim of fully prosthetic rehabilitation. The purpose is to give an overview of different methods that use CAD in maxillary reconstruction in patients with head and neck cancer.

Recent findings

3D VSP enables preoperative planning of resection margins and osteotomies. The current 3D VSP workflow is expanded with multimodal imaging, merging decision supportive information. Development of more personalized implants is possible using CAD, individualized virtual muscle modelling and topology optimization. Meanwhile the translation of the 3D VSP towards surgery is improved by techniques like intraoperative imaging and augmented reality. Recent improvements of preoperative 3D VSP enables surgical reconstruction and/or prosthetic rehabilitation of the surgical defect in one combined procedure.

Summary

With the use of 3D VSP and CAD, ablation surgery, reconstructive surgery, and prosthetic rehabilitation can be planned preoperatively. Many reconstruction possibilities exist and a choice depends on patient characteristics, tumour location and experience of the surgeon. The overall objective in patients with maxillary defects is to follow a prosthetic-driven reconstruction with the aim to restore facial form, oral function, and do so in accordance with the individual needs of the patient.

Keywords

3D VSP, CAD/CAM, maxillary, oral rehabilitation, patient specific, reconstruction

INTRODUCTION

Surgical treatment of tumours located in the maxilla can be a challenge because of anatomical constraints and impairment of function following treatment. With the introduction of 3D virtual surgical planning (VSP) and guided surgery techniques, complex resections can be planned preoperatively and can be combined with reconstructive solutions. Advantages of using 3D VSP becomes apparent in the operating room as decisions regarding resection margins, location of osteotomies, precise placement of osteosynthesis materials and dental implants are already decided upon before the surgery. Because of the high accuracy of 3D VSP, surgical resections with good tumour margin control can be obtained during ablation [1[•],2,3]. Moreover, it enables the use of bone containing multi-segment composite flaps and/or dental implants in one combined ablative and reconstructive procedure.

Therefore, 3D VSP and guided surgery is the current standard in head and neck oncologic surgery. Another form of computer-assisted surgery (CAS) includes surgical navigation. Surgical navigation is already routinely used during maxillary tumour resections and reduces tumour positive resection margins compared to conventional surgery [4,5]. VSP has been shown to be cost-effective, reproducible, accurate and opens possibilities for creative patient-specific (PS) solutions [6–9].

Department of Oral and Maxillofacial Surgery, University Medical Center Groningen, University of Groningen, Groningen, The Netherlands

Correspondence to Sebastiaan A.H.J. de Visscher, Department of Oral and Maxillofacial Surgery, University Medical Center Groningen, University of Groningen, Hanzeplein 1, 9713GZ, Groningen, The Netherlands. Tel: +31 50 3612561; fax: +31 50 3612831; e-mail: s.a.h.j.de.visscher@umcg.nl

Curr Opin Otolaryngol Head Neck Surg 2020, 28:122–128

DOI:10.1097/MOO.0000000000000618

KEY POINTS

- Successful dental rehabilitation after maxillary ablative surgery is a complex, multidisciplinary team effort.
- The overall objective in patients with maxillary defects is to follow a dental rehabilitation-driven reconstruction with the aim to restore facial form and oral function, in accordance with the individual needs of the patient.
- Integration of multimodality imaging into a single 3D VSP improves the predictability, accuracy and speed of surgical procedures.
- The design of patient-specific implants should be optimized using patient-specific finite element analysis and topology optimization.

The aim of this manuscript is to provide an overview of current state of the art routines for using 3D VSP in maxillary ablative surgery, reconstruction and dental rehabilitation. In addition, indications for expected developments in the field of 3D VSP and optimization of patient-specific implants are described.

RESECTION AND RECONSTRUCTION OF MAXILLARY DEFECTS

Resection of neoplasms in the maxilla often result in complex defects encompassing soft tissue, bone and dentition. This results in diminished aesthetics and impaired oral functions and thereby lowers the quality of life perceived [10–13]. The aim of reconstruction of maxillary and midfacial defects should be to restore form and function with minimal operative morbidity.

A variety of different single-stage reconstructive techniques in midfacial defects are used. The use of a classification system describing midfacial defects can be helpful in determining reconstructive options [14–19]. The classification of Brown *et al.* [14] is the most widely recognized classification. Despite these popular classification systems, they describe the defect focusing only on its reconstructive possibilities [20]. Often, defects do not fit in a particular classification, or the classification schemes do not take dental rehabilitation or patient factors in consideration [20].

The reconstructive ladder is a heuristic approach to reconstruction, in which the simplest and safest approach to a problem is often the preferred solution [21]. Taking the reconstructive ladder in consideration is important to manage maxillary and midfacial defects [20]. Small defects can therefore be closed by local flaps such as the buccal fat pad flap or temporalis muscle flap, especially if these are

located laterally in the posterior maxilla [15,17,20,22]. If defects limited to the palate are present and retention is possible, obturator prosthesis can be a very good option [20]. These obturators remain a simple, nonsurgical and relatively quick approach which offers immediate improvement of oral functions with reasonable outcomes. However, obturator prostheses have several drawbacks regarding oral hygiene, instability, velopharyngeal insufficiency, lack of soft tissue support, and they carry a social stigma [22,23]. With larger defects the use of pedicled or free vascularized autologous tissue transfer can offer skin, muscle, fascia and bone and can be used as a foundation for dental implants [16].

Bony reconstruction is not always necessary as retention of a prosthesis can be found on canines and incisors or zygomatic implants can be placed in these defects [16]. The most used autologous reconstruction method of a maxillary defect involving alveolus and maxillary sinus wall is the radial forearm free flap (RFFF) [14]. The fibular free flap (FFF), Iliac crest or deep circumflex iliac artery (DCIA) and the subscapular system are the most used composite flaps in maxillary reconstruction when bone is required [16,20]. The FFF is the most often used, as it can be reliably harvested and transferred, its bone stock enables reliable placement of implants, has a long vascular pedicle, high success rate, low donor site morbidity and it enables a simultaneous two team approach [16,24]. A DCIA flap offers bigger amounts of muscle and bone that has a contour better suited to reconstruct the most complex defects encompassing loss of all six walls of the maxilla [25,26]. Large complex defects that need multiple skin paddles, muscle and bone can be reconstructed by flaps based on the scapular system [27–29].

DENTAL REHABILITATION

Oral functions are not only dependent on reconstruction of the maxillary defect because, after post-operative radiotherapy, stability and retention of a prosthesis are also decreased [24]. Therefore, implants to support prostheses are widely used as part of a standard oral rehabilitation plan [30–33].

Dental rehabilitation is an essential part of the aim of reconstruction and should be planned from the beginning [15,34]. From a prosthodontics perspective, CAD assistance benefits the functional outcome. Prosthetic-driven reconstruction planning in combination with precise guided placement of dental implants carried out at time of tumour resection ahead of possible radiotherapy is a huge advantage for accelerating the process of oral rehabilitation [32,35].

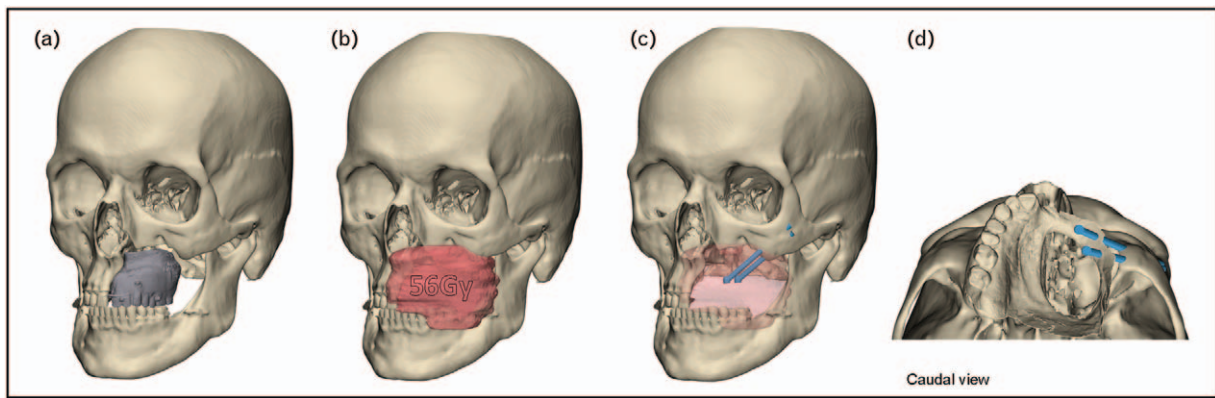


FIGURE 1. 3D VSP aiming for dental rehabilitation using zygomatic implants. Patient after maxillary resection and radiotherapy rehabilitated with obturator prosthesis resulting in inadequate oral function. With the aim of improving quality of life, zygomatic oncology implants were placed taken into account available bone volume, preferred prosthetic position and previous irradiated volumes. (a) 3D reconstruction of patient with the primary obturator prosthesis in place. (b) 3D reconstruction of the 56Gy isodosis radiation field. (c) Planning of the zygomatic implants with respect to the reconstructed radiation field. (d) 3D reconstruction of intra-oral scan combined with planned implant position to visualize available prosthetic space.

As an alternative for bone reconstruction with regular dental implants, zygomatic oncology implants can also provide a predictable in-defect support for prosthetic rehabilitation of the maxilla and can be placed at the time of ablative surgery [36,37,38]. The zygomatic implant perforated flap procedure combines autologous soft tissue reconstruction with zygomatic implant-supported dental rehabilitation [39,40]. However, the limited intra-operative visibility makes accurate placement of the zygoma implants challenging. The use of 3D VSP and guided placement by means of 3D printed

drilling and placement guides can possibly improve the success in terms of accuracy. Such 3D VSP workflow is illustrated in Fig. 1, where a traditional obturator prosthesis is replaced for zygomatic implants. Sometimes zygoma implants cannot provide satisfactory anchorage because of insufficient bone volume and composite free flaps are not indicated. In those patients, an alternative to achieve oral rehabilitation is to design patient-specific subperiosteal implants [41,42]. An example of such 3D VSP workflow including the design of a patient specific implant is seen in Fig. 2.

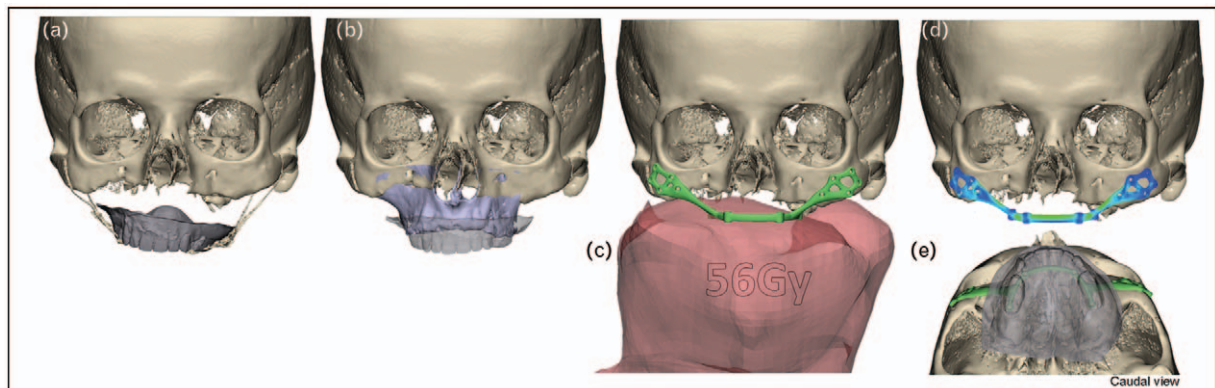


FIGURE 2. 3D VSP and CAD workflow of a patient-specific subperiosteal implant for secondary reconstruction following maxillary resection. Surgical reconstruction with composite flaps or placement of zygomatic oncology implants was not feasible. The aim of the 3D VSP was to obtain an optimal dental rehabilitation using backwards planning, starting with an optimal position of the prosthesis. (a) Patient after maxillary resection with nonfunctional obturator prosthesis (gray), fixated by zygomatic wires. (b) 3D VSP of ideal prosthetic position using a 3D reconstruction of the preablative CT scan of the maxilla (purple). (c) 3D visualization of subperiosteal implant (green) in relation to 56Gy isodosis radiotherapy field (red). The PSI subperiosteal implant was designed with the position for fixation screws circumventing the irradiated bone. (d) Implant strength and fatigue resistance was calculated using finite element analysis to withstand reported maximum occlusal loading. (e) Planned prosthetic outcome (gray) and prosthetic driven subperiosteal implant position (green).

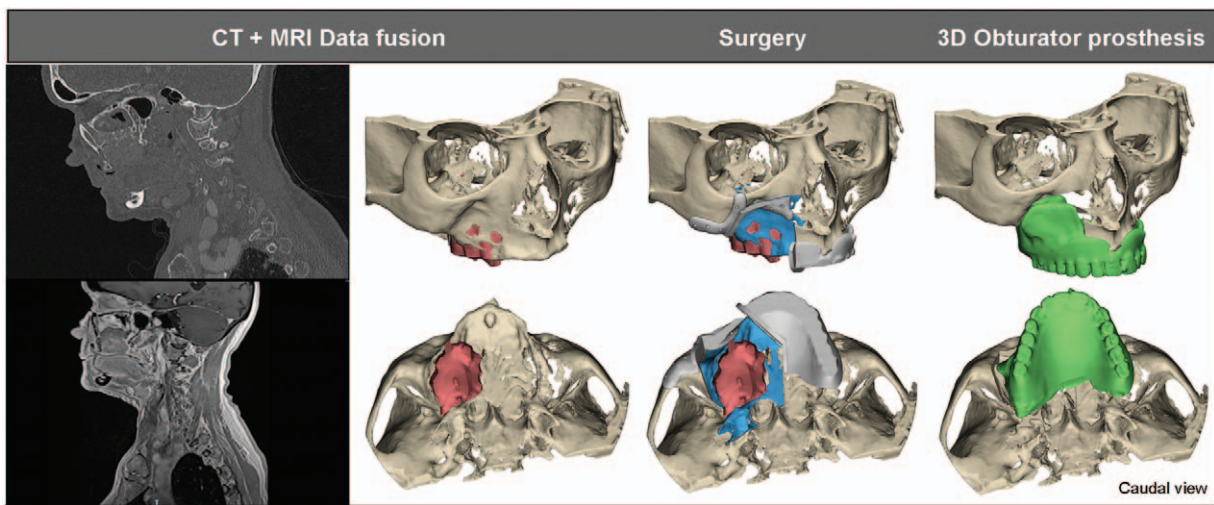


FIGURE 3. Tumour visualization based on CT and MRI data fusion. CT images are used for 3D reconstruction of bone tissue, whereas the MRI enables delineation of the tumour. This enables preoperative planning of the bone resection (blue) and thereby guide design (gray). Preoperative CAD/CAM manufactured obturator prosthesis (green) designed to obturate the defect following guided resection.

Obturator prosthesis maintain their importance in rehabilitation by bridging time to secondary surgical reconstruction of the defect. Preoperative 3D knowledge of resection planes induce new and more efficient workflows in processing surgical obturators. Several case reports describe production of 3D obturator prostheses with the advantage that they can be printed hollow and aligned to the contour of the patients' defect [43–47]. Figure 3 shows an example of a 3D VSP including guided tumour resection and a CAD/CAM manufactured obturator prosthesis.

VIRTUAL SURGICAL PLANNING AND FUTURE PERSPECTIVES

3D VSP and 3D printed cutting guides are used for complex reconstructive surgery including FFF and DCIA transplantations, combined with one stage implant placement for dental rehabilitation. Currently, in most cases, 3D VSP and guided surgery is primarily based on CT data only. 3D VSP enables planning of oncologic resections and reconstructions using computer-aided design and manufacturing (CAD/CAM) of 3D printed anatomical models, surgical guides and patient-specific implants [3,6,35,41,42]. Recent improvements in 3D VSP and CAD workflows include the use of multimodal data fusion to increase precision of determining the tumour-free resection margin. Data fusion of MRI and CT enables tumour information delineated on the MRI in spatial relation with bone information from CT. The combination of information provided by CT and MRI with regard to localization, size and shape of the tumour is important for a precise

resection [48,49]. An example of such 3D VSP workflow including MRI and CT data fusion is seen in Fig. 3. This workflow applied in mandibular tumours provided a tumour-free bone resections without preoperative deviation of the 3D VSP [1^{**}]. Tumour-free resection margins are critical for one-stage reconstruction surgery, where the reconstruction is preoperatively planned. An equivalent software pathway can be used for a variety of imaging data, like adding PET data when MRI information is inconclusive about the tumour margin [50–52]. Another recent advancement of data fusion is that of CT and radiotherapy dose. Adding radiation dose as a visual volume in the VSP workflow enables evaluation of prescribed radiation dose on tissue and avoiding areas at risk for osteoradionecrosis in patients which were previously irradiated [53–55]. Both 3D VSP workflows illustrated in Figs. 1 and 2 incorporated data fusion of the radiation dose for implant planning and design, including screw locations.

When a 3D VSP is completed and agreed on by the multidisciplinary surgical team, patient-specific 3D cutting and drilling guides and patient-specific osteosynthesis are designed and used for translation into the surgical procedure. The design of these patient-specific guides is adapted to the contour of the bone to achieve the precise resections and drill holes as intended in the VSP. An alternative method of translating the 3D VSP into the surgical procedure is intra-operative navigation, especially used in case of maxillary resection [56,57]. Compared to intra-operative navigation, 3D fitted guides lead to the most accurate bone resections [35,58–60]. However, per-operative imaging and navigated surgery enables the surgeon to act on tissue volume

changes between preoperative imaging and surgery, in contrary to the 3D fitted premade guides. With the increase of hybrid OR applications (ability of perioperative MRI and CT imaging), one can expect multimodal data fusion real-time in the operating room, updating the preoperatively made 3D VSP with recent per operative imaging data. Intraoperative imaging combined with surgical navigation is reported to be as accurate as the use of 3D printed guides [61].

The main drawback of navigation systems is that the surgeon has to look away from the surgical field in order to receive feedback from the navigation system, this leads to more difficult eye-hand coordination [62]. Augmented reality could potentially overcome this problem by translating 3D VSP to the actual surgical field with the use of head mounted devices [63]. Preliminary studies report on application of augmented reality for mandibular osteotomies and orthognathic surgery, however the added benefit for maxillary tumour resection and reconstruction has not yet been demonstrated [59,63,64].

Design and fit of 3D guides and osteosynthesis materials has to be adapted to the patient bony contour to be used in implementing the VSP into the patient. 3D-printed patient-specific anatomical models have been used for bending of the shelf osteosynthesis materials like titanium meshes and reconstruction plates. While bending a titanium mesh on a patient-specific model can lead to postoperative facial symmetry and successful clinical outcomes in maxillary reconstructions, complications can include exposure of the osteosynthesis material [54,55].

Designing and using patient-specific osteosynthesis materials has shown to be a valuable tool in the reconstruction of oncologic defects, enabling planning of adaptation of implant and screw location, based on the thickness of the bone [6,35,41,42,54,65]. Furthermore, possible surgical access can be taken into account. Mostly tailoring of osteosynthesis starts with adapting conventional plate designs and is based on experiences of the involved surgical team and technical physicians. This design process mostly lacks a systematic application of biomechanical analysis on an individual patient basis. It is reported that these osteosynthesis used for mandibular reconstruction can be subject to failure in terms of plate fracture or screw loosening, however comparable complications occur for maxillary reconstructions [66,67]. Although patient-specific osteosynthesis have been used regularly, future applications should focus on a more patient tailored approach, using 3D print technology. In this way, nearly every shape of osteosynthesis material can be produced. Therefore, an approach of more biomechanically based patient-specific designs is the logical next step. Based on

individual models including bone morphology, bite forces and anatomy a PSI is designed and manufactured. Pilot-studies have demonstrated validation of virtually modelling the muscles associated with mastication [68]. Those and other models can be used as a foundation for finite element analysis (FEA). Application of finite element models can predict behaviour of osteosynthesis materials with varying inputs of muscle forces, loads, constraints and biomechanical properties of bone. The output of FEA can be used for topology optimisation, whereby the design, structure and layout of patient-specific osteosynthesis can be optimized [69]. In addition, new materials and surface finishes should be incorporated in the PSI in order to reduce scattering on postoperative imaging and reduce occurrence of infections.

CONCLUSION

Successful rehabilitation after ablative surgery of the maxilla can be achieved through the experience and good collaboration of a multidisciplinary surgical team. The role of a technical physician enabling 3D virtual surgical planning and visualisation of the complex reconstruction of large maxillary defects is of great importance. Preoperative planning enables combined ablation surgery with prosthetic driven reconstruction treatment that benefits the functional outcome. The method of reconstruction is dependent on many factors like size and location of defect, medical condition, patient factors and previous treatments. In reconstruction of maxillary defects, the use of CAD enables a pre-planned precise, efficient and patient specific treatment with incorporation of dental rehabilitation.

Acknowledgements

We would like to thank our colleagues Dr. J. Kraeima, Dr. M.J.H. Witjes and Dr. H. Reintsema for their contribution.

Financial support and sponsorship

None.

Conflicts of interest

There are no conflicts of interest.

REFERENCES AND RECOMMENDED READING

Papers of particular interest, published within the annual period of review, have been highlighted as:

- of special interest
- of outstanding interest

1. Kraeima J, Dorgelo B, Gulbitti HA, *et al.* Multimodality 3D mandibular resection planning in head and neck cancer using CT and MRI data fusion: a clinical series. *Oral Oncol* 2018; 81:22–28.

This study is the first to report on patients treated using a multimodality CT and MRI combined workflow for 3D resection margin planning.

2. Kraeima J, Schepers RH, Van Ooijen PMA, *et al.* Integration of oncologic margins in three-dimensional virtual planning for head and neck surgery, including a validation of the software pathway. *J Cranio-Maxillofacial Surg* 2015; 43:1374–1379.
 3. Witjes MJH, Schepers RH, Kraeima J. Impact of 3D virtual planning on reconstruction of mandibular and maxillary surgical defects in head and neck oncology. *Curr Opin Otolaryngol Head Neck Surg* 2018; 26:108–114.
 4. Tarsitano A, Ricotta F, Baldino G, *et al.* Navigation-guided resection of maxillary tumours: the accuracy of computer-assisted surgery in terms of control of resection margins – a feasibility study. *J Cranio-Maxillofacial Surg* 2017; 45:2109–2114.
 5. Sukegawa S, Kanno T, Furuki Y. Application of computer-assisted navigation systems in oral and maxillofacial surgery. *Jpn Dent Sci Rev* 2018; 54:139–149.
 6. Rohner D, Guizarro-Martinez R, Bucher P, Hammer B. Importance of patient-specific intraoperative guides in complex maxillofacial reconstruction. *J Cranio-Maxillofacial Surg* 2013; 41:382–390.
 7. Dérand P, Rännar L-E, Hirsch J-M. Imaging, virtual planning, design, and production of patient-specific implants and clinical validation in craniomaxillofacial surgery. *Craniomaxillofacial Trauma Reconstr* 2012; 5:137–144.
 8. Steinbacher DM. Three-dimensional analysis and surgical planning in craniomaxillofacial surgery. *J Oral Maxillofac Surg* 2015; 73:S40–S56.
 9. Xia JJ, Phillips CV, Gateno J, *et al.* Cost-effectiveness analysis for computer-aided surgical simulation in complex craniomaxillofacial surgery. *J Oral Maxillofac Surg* 2006; 64:1780–1784.
 10. Roumanas ED. Reconstructed mandibular defects: fibula free flaps and osseointegrated implants. *Plast Reconstr Surg* 1997; 99:356–365.
 11. Schoen PJ, Reintsema H, Raghoobar GM, *et al.* The use of implant retained mandibular prostheses in the oral rehabilitation of head and neck cancer patients. A review and rationale for treatment planning. *Oral Oncol* 2004; 40:862–871.
 12. De Graeff A, De Leeuw JRJ, Ros WJG, *et al.* Long-term quality of life of patients with head and neck cancer. *Laryngoscope* 2000; 110:98–106.
 13. Huryn JM, Zlotolow IM, Piro JD, Lenchewski E. Osseointegrated implants in microvascular fibula free flap reconstructed mandibles. *J Prosthet Dent* 1993; 70:443–446.
 14. Brown JS, Shaw RJ. Reconstruction of the maxilla and midface: introducing a new classification. *Lancet Oncol* 2010; 11:1001–1008.
 15. Brown J. Reconstruction of the maxilla and midface. *Eur Arch Oto-Rhino-Laryngol* 2012; 22:161–174.
 16. Lenox ND, Kim DD. Maxillary reconstruction. *Oral Maxillofac Surg Clin North Am* 2013; 25:215–222.
 17. Cordeiro PG, Santamaria E. A classification system and algorithm for reconstruction of maxillectomy and midfacial defects. *Plast Reconstr Surg* 2000; 105:2331–2346.
 18. Okay DJ, Genden E, Buchbinder D, Urken M. Prosthodontic guidelines for surgical reconstruction of the maxilla: a classification system of defects. *J Prosthet Dent* 2001; 86:352–363.
 19. Yamamoto Y, Kawashima K, Sugihara T, *et al.* Surgical management of maxillectomy defects based on the concept of buttress reconstruction. *Head and Neck* 2004; 26:247–256.
 20. Eskander A, Kang SY, Teknos TN, Old MO. Advances in midface reconstruction: Beyond the reconstructive ladder. *Curr Opin Otolaryngol Head Neck Surg* 2017; 25:422–430.
 21. Ray E. Head and neck reconstructive surgery. *Cancer Treat Res* 2018; 174:123–143.
 22. Dalgorf D, Higgins K. Reconstruction of the midface and maxilla. *Curr Opin Otolaryngol Head Neck Surg* 2008; 16:303–311.
 23. Rogers SN, Lowe D, McNally D, *et al.* Health-related quality of life after maxillectomy: a comparison between prosthetic obturation and free flap. *J Oral Maxillofac Surg* 2003; 61:174–181.
 24. Wijbenga JG, Schepers RH, Werker PMN, *et al.* A systematic review of functional outcome and quality of life following reconstruction of maxillofacial defects using vascularized free fibula flaps and dental rehabilitation reveals poor data quality. *J Plast Reconstr Aesthet Surg* 2016; 69:1024–1036.
 25. Brown JS. Deep circumflex iliac artery free flap with internal oblique muscle as a new method of immediate reconstruction of maxillectomy defect. *Head Neck* 1996; 18:412–421.
 26. Brown JS, Jones DC, Summerwill A, *et al.* Vascularized iliac crest with internal oblique muscle for immediate reconstruction after maxillectomy. *Br J Oral Maxillofac Surg* 2002; 40:183–190.
 27. Mertens C, Freudsperger C, Bodem J, *et al.* Reconstruction of the maxilla following hemimaxillectomy defects with scapular tip grafts and dental implants. *J Cranio-Maxillofacial Surg* 2016; 44:1806–1811.
 28. Miles BA, Gilbert RW. Maxillary reconstruction with the scapular angle osteomyogenous free flap. *Arch Otolaryngol - Head Neck Surg* 2011; 137:1130–1135.
 29. Granick MS, Ramasastry SS, Newton ED, *et al.* Reconstruction of complex maxillectomy defects with the scapular-free flap. *Head Neck* 1990; 12:377–385.
 30. Smolka K, Kraehenbuehl M, Eggenberger N, *et al.* Fibula free flap reconstruction of the mandible in cancer patients: Evaluation of a combined surgical and prosthodontic treatment concept. *Oral Oncol* 2008; 44:571–581.
 31. Barber AJ, Butterworth CJ, Rogers SN. Systematic review of primary osseointegrated dental implants in head and neck oncology. *Br J Oral Maxillofac Surg* 2011; 49:29–36.
 32. Chuka R, Abdullah W, Rieger J, *et al.* Implant utilization and time to prosthetic rehabilitation in conventional and advanced fibular free flap reconstruction of the maxilla and mandible. *Int J Prosthodont* 2017; 30:289–294.
 33. Korfage A, Schoen PJ, Raghoobar GM, *et al.* Benefits of dental implants installed during ablative tumour surgery in oral cancer patients: A prospective 5-year clinical trial. *Clin Oral Implants Res* 2010; 21:971–979.
 34. Pace-Balzan A, Shaw RJ, Butterworth C. Oral rehabilitation following treatment for oral cancer. *Periodontol* 2000 2011; 57:102–117.
 35. Schepers RH, Raghoobar GM, Vissink A, *et al.* Accuracy of fibula reconstruction using patient-specific CAD/CAM reconstruction plates and dental implants: A new modality for functional reconstruction of mandibular defects. *J Cranio-Maxillofac Surg* 2015; 43:649–657.
 36. Drobyshev A, Dibirov T, Zhukova N, *et al.* Rehabilitation of patients with oncological maxillary defects. *Int J Oral Maxillofac Surg* 2017; 46:302.
 37. Butterworth CJ. Primary vs secondary zygomatic implant placement in patients with head and neck cancer—A 10-year prospective study. *Head Neck* 2019; 41:1687–1695.
- This study is the first to report on zygomatic oncology implant perforated microvascular soft tissue flap (ZIP flap) for the primary management of maxillary malignancy with surgical closure of the resultant maxillary defect.
38. Parel SM, Brånemark PI, Ohnneil LO, Svensson B. Remote implant anchorage for the rehabilitation of maxillary defects. *J Prosthet Dent* 2001; 86:377–381.
 39. Butterworth CJ, Rogers SN. The zygomatic implant perforated (ZIP) flap: a new technique for combined surgical reconstruction and rapid fixed dental rehabilitation following low-level maxillectomy. *Int J Implant Dent* 2017; 37: doi:10.1186/s40729-017-0100-8.
 40. Araya-Salas C, Brenner C, Bustos F, *et al.* Maxillary osteosarcoma and reconstruction with ZIP flap. *Int J Oral Maxillofac Surg* 2019; 48:73.
 41. Vosselman N, Merema BJ, Schepman KP, Raghoobar GM. Patient-specific sub-periosteal zygoma implant for prosthetic rehabilitation of large maxillary defects after oncological resection. *Int J Oral Maxillofac Surg* 2019; 48:115–117.
 42. Mommaerts MY. Additively manufactured sub-periosteal jaw implants. *Int J Oral Maxillofac Surg* 2017; 46:938–940.
 43. Bartellas M, Tibbo J, Angel D, *et al.* Three-dimensional printing: a novel approach to the creation of obturator prostheses following palatal resection for malignant palate tumors. *J Craniofac Surg* 2018; 29:e12–e15.
 44. Kortjes J, Dehnad H, Kotte ANT, *et al.* A novel digital workflow to manufacture personalized three-dimensional-printed hollow surgical obturators after maxillectomy. *Int J Oral Maxillofac Surg* 2018; 47:1214–1218.
 45. Murat S, Gürbüz A, Kamburoğlu K. Fabrication of obturator prosthesis by fusing CBCT and digital impression data. *Int J Comput Dent* 2018; 21:335–344.
 46. Rodney J, Chicchon I. Digital design and fabrication of surgical obturators based only on preoperative computed tomography data. *Int J Prosthodont* 2017; 30:111–112.
 47. Tasopoulos T, Chatziemmanouil D, Karaiskou G, *et al.* Fabrication of a 3D-printed interim obturator prosthesis: a contemporary approach. *J Prosthet Dent* 2019; 121:960–963.
 48. Dai J, Wang X, Dong Y, *et al.* Two- and three-dimensional models for the visualization of jaw tumors based on CT-MRI image fusion. *J Craniofac Surg* 2012; 23:502–508.
 49. Blatt S, Ziebart T, Krüger M, Pabst AM. Diagnosing oral squamous cell carcinoma: how much imaging do we really need? A review of the current literature. *J Cranio-Maxillofacial Surg* 2016; 44:538–549.
 50. Sarrión Pérez MG, Bagán JV, Jiménez Y, *et al.* Utility of imaging techniques in the diagnosis of oral cancer. *J Cranio-Maxillofacial Surg* 2015; 43:1880–1894.
 51. Van Cann EM, Rijpkema M, Heerschap A, *et al.* Quantitative dynamic contrast-enhanced MRI for the assessment of mandibular invasion by squamous cell carcinoma. *Oral Oncol* 2008; 44:1147–1154.
 52. Kolk A, Schuster T, Chlebowski A, *et al.* Combined SPECT/CT improves detection of initial bone invasion and determination of resection margins in squamous cell carcinoma of the head and neck compared to conventional imaging modalities. *Eur J Nucl Med Mol Imaging* 2014; 41:1363–1374.
 53. Kraeima J, Steenbakkens RJHM, Spijkeret FKL, *et al.* Secondary surgical management of osteoradionecrosis using three-dimensional isodose curve visualization: a report of three cases. *Int J Oral Maxillofac Surg* 2018; 47:214–219.
 54. Kraeima J, Glas HH, Witjes MJH, Schepman KP. Patient-specific precontouring of osteosynthesis plates for mandibular reconstruction: Using a three-dimensional key printed solution. *J Cranio-Maxillofacial Surg* 2018; 46:1037–1040.
 55. Liu BY, Cao G, Dong Z, *et al.* The application of 3D-printed titanium mesh in maxillary tumor patients undergoing total maxillectomy. *J Mater Sci Mater Med* 2019; 30:125.
 56. Yu H, Wang X, Zhang S, *et al.* Navigation-guided en bloc resection and defect reconstruction of craniomaxillary bony tumours. *Int J Oral Maxillofac Surg* 2013; 42:1409–1413.

57. Yu Y, Zhang WB, Liu XJ, *et al.* Three-dimensional accuracy of virtual planning and surgical navigation for mandibular reconstruction with free fibula flap. *J Oral Maxillofac Surg* 2016; 74: 1503.e1–1503.e10.
58. Pietruski P, Majak M, Wiatek-Najwer E, *et al.* Image-guided bone resection as a prospective alternative to cutting templates: a preliminary study. *J Cranio-Maxillofacial Surg* 2015; 43:1021–1027.
59. Pietruski P, Majak M, Swiatek-Najwer E, *et al.* Supporting mandibular resection with intraoperative navigation utilizing augmented reality technology – A proof of concept study. *J Cranio-Maxillofacial Surg* 2019; 47:854–859.
60. Bernstein JM, Daly MJ, Chan H, *et al.* Accuracy and reproducibility of virtual cutting guides and 3D-navigation for osteotomies of the mandible and maxilla. *PLoS One* 2017; 12:1–10.
61. Hasan W, Daly MJ, Chan HHL, *et al.* Intraoperative cone-beam CT-guided osteotomy navigation in mandible and maxilla surgery. *Laryngoscope* 2019. [Epub ahead of print]
62. Berger M, Nova I, Kallus S, *et al.* Can electromagnetic-navigated maxillary positioning replace occlusional splints in orthognathic surgery? A clinical pilot study. *J Cranio-Maxillofacial Surg* 2017; 45: 1593–1599.
63. Bosc R, Fitoussi A, Hersant B, *et al.* Intraoperative augmented reality with heads-up displays in maxillofacial surgery: a systematic review of the literature and a classification of relevant technologies. *Int J Oral Maxillofac Surg* 2019; 48:132–139.
64. Ahn J, Choi H, Hong J, Hong J. Tracking accuracy of a stereo camera-based augmented reality navigation system for orthognathic surgery. *J Oral Maxillofac Surg* 2019; 77:1070.e1–1070.e11.
65. Wilde F, Hanken H, Probst F, *et al.* Multicenter study on the use of patient-specific CAD/CAM reconstruction plates for mandibular reconstruction. *Int J Comput Assist Radiol Surg* 2015; 10:2035–2051.
66. Kimura A, Nagasao T, Kaneko T, *et al.* Adequate fixation of plates for stability during mandibular reconstruction. *J Cranio-Maxillofacial Surg* 2006; 34:193–200.
67. Van Gemert JTM, Van Es RJJ, Rosenberg AJWP, *et al.* Free vascularized flaps for reconstruction of the mandible: complications, success, and dental rehabilitation. *J Oral Maxillofac Surg* 2012; 70:1692–1698.
68. Weickenmeier J, Jabareen M, Le Révérend BJD, *et al.* Experimental and numerical characterization of the mechanical masseter muscle response during biting. *J Biomech Eng* 2017; 139:1–10.
69. Sutradhar A, Park J, Carrau D, *et al.* Designing patient-specific 3D printed craniofacial implants using a novel topology optimization method. *Med Biol Eng Comput* 2016; 54:1123–1135.