

University of Groningen

Spontaneity Assessment in Dually Innervated Gracilis Smile Reanimation Surgery

Dusseldorp, Joseph R.; van Veen, Martinus M.; Guarin, Diego L.; Quatela, Olivia; Jowett, Nate; Hadlock, Tessa A.

Published in:
JAMA facial plastic surgery

DOI:
[10.1001/jamafacial.2019.1090](https://doi.org/10.1001/jamafacial.2019.1090)

IMPORTANT NOTE: You are advised to consult the publisher's version (publisher's PDF) if you wish to cite from it. Please check the document version below.

Document Version
Publisher's PDF, also known as Version of record

Publication date:
2019

[Link to publication in University of Groningen/UMCG research database](#)

Citation for published version (APA):

Dusseldorp, J. R., van Veen, M. M., Guarin, D. L., Quatela, O., Jowett, N., & Hadlock, T. A. (2019). Spontaneity Assessment in Dually Innervated Gracilis Smile Reanimation Surgery. *JAMA facial plastic surgery*, 21(6), 551-557. <https://doi.org/10.1001/jamafacial.2019.1090>

Copyright

Other than for strictly personal use, it is not permitted to download or to forward/distribute the text or part of it without the consent of the author(s) and/or copyright holder(s), unless the work is under an open content license (like Creative Commons).

The publication may also be distributed here under the terms of Article 25fa of the Dutch Copyright Act, indicated by the "Taverne" license. More information can be found on the University of Groningen website: <https://www.rug.nl/library/open-access/self-archiving-pure/taverne-amendment>.

Take-down policy

If you believe that this document breaches copyright please contact us providing details, and we will remove access to the work immediately and investigate your claim.

Downloaded from the University of Groningen/UMCG research database (Pure): <http://www.rug.nl/research/portal>. For technical reasons the number of authors shown on this cover page is limited to 10 maximum.

Spontaneity Assessment in Dually Innervated Gracilis Smile Reanimation Surgery

Joseph R. Dusseldorp, FRACS; Martinus M. van Veen, MD; Diego L. Guarin, PhD; Olivia Quatela, BS; Nate Jowett, MD; Tessa A. Hadlock, MD



IMPORTANCE Surgeons have sought to optimize outcomes of smile reanimation surgery by combining inputs from nerve-to-masseter and cross-face nerve grafts. An objective assessment tool could help surgeons evaluate outcomes to determine the optimal neural sources for smile reanimation.

OBJECTIVE To evaluate the use of a novel video time-stamping method and standard outcome measurement tools to assess outcomes of facial reanimation surgery using various innervation strategies.

DESIGN, SETTING, AND PARTICIPANTS Cohort study assessing the outcomes of dually innervated gracilis free muscle transfers vs single-source innervated gracilis transfer performed at a tertiary care facial nerve center between 2007 and 2017 using a novel, video time-stamping spontaneity assessment method. The statistical analyses were performed in 2018.

INTERVENTIONS Dually innervated gracilis free muscle transfers or single-source innervated gracilis transfer.

MAIN OUTCOMES AND MEASURES Spontaneous smiling was assessed by clinicians and quantified using blinded time-stamped video recordings of smiling elicited while viewing humorous video clips.

RESULTS This retrospective cohort study included 25 patients (12 men and 13 women; median [range] age, 38.4 [29.3-46.0] years) treated with dually innervated gracilis free functional muscle graft for unilateral facial palsy between 2007 and 2017. Smile spontaneity assessment was performed in 17 patients and was compared with assessment performed in 24 patients treated with single-source innervated gracilis transfer (ie, nerve-to-masseter-driven or cross-face nerve graft-driven gracilis [$n = 13$]) (demographic data not available for NTM and CFNG cohorts). The use of time-stamped video assessment revealed that spontaneous synchronous oral commissure movement in a median percentage of smiles was 33% in patients with dually innervated gracilis (interquartile range [IQR], 0%-71%), 20% of smiles in patients with nerve-to-masseter-driven gracilis (IQR, 0%-50%), and 75% of smiles in patients with cross-face nerve graft-driven gracilis (IQR, 0%-100%). Clinicians graded smile spontaneity in dually innervated cases as absent in 40% ($n = 6$ of 15), trace in 33% ($n = 5$ of 15) and present in 27% ($n = 4$ of 15). No association was demonstrated between clinician-reported spontaneity and objectively measured synchronicity.

CONCLUSIONS AND RELEVANCE Dually innervated gracilis free muscle transfers may improve smile spontaneity compared with masseteric nerve-driven transfers but not to the level of cross-face nerve graft-driven gracilis transfers. Quantifying spontaneity is notoriously difficult, and most authors rely on clinical assessment. Our results suggest that clinicians may rate presence of spontaneity higher than objective measures, highlighting the importance of standardized assessment techniques.

LEVEL OF EVIDENCE 4.

Author Affiliations: Department of Otolaryngology–Head and Neck Surgery, Massachusetts Eye and Ear Infirmary and Harvard Medical School, Boston (Dusseldorp, van Veen, Guarin, Quatela, Jowett, Hadlock); Department of Plastic and Reconstructive Surgery, Royal Australasian College of Surgeons and University of Sydney, Sydney, Australia (Dusseldorp); Department of Plastic Surgery, University Medical Center Groningen, and University of Groningen, Groningen, the Netherlands (van Veen).

Corresponding Author: Joseph R. Dusseldorp, FRACS, Massachusetts Eye and Ear Infirmary, 243 Charles St, Boston, MA 02114 (drjoedusseldorp@icloud.com).

JAMA Facial Plast Surg. 2019;21(6):551-557. doi:10.1001/jamafacial.2019.1090
Published online October 31, 2019.

Two neural sources are widely used to innervate the gracilis free functional muscle transfer (FFMT) in facial reanimation: the ipsilateral nerve to masseter (NTM) or branches of the contralateral facial nerve via a cross-face nerve graft (CFNG). Both sources have distinct advantages and disadvantages. The NTM provides a robust source of motor axons and reliable postoperative oral commissure excursion with voluntary smiling.¹⁻⁴ However, conscious muscle activation is required to produce a smile, facial movements are present with prandial activity, and low rates of spontaneity have been reported.^{5,6} Cross-face nerve graft results in spontaneous movement but can lead to less oral commissure excursion and a higher chance of failure to achieve a meaningful smile on the surgical side.^{1,3,7}

In 2009, Watanabe et al⁸ suggested that combining voluntary motor input from neurotization of the masseter and gracilis with spontaneous movement from the CFNG may improve outcomes in smile reanimation. Several other groups have since performed a wide variety of dual innervation techniques.⁹⁻¹³ Good to excellent results have been reported, although various outcome measures have been used and very few studies have systematically assessed smile spontaneity.

The aim of this study was to develop an objective assessment tool to quantify spontaneous smiling and use this tool to analyze facial reanimation outcomes from various innervation strategies.

Methods

Institutional review board approval from the Massachusetts Eye and Ear Infirmary and patient written informed consent were obtained for this retrospective cohort study. All patients who underwent dually innervated gracilis FFMT for unilateral facial palsy at our institution between 2007 and 2017 were identified (n = 25). In addition, 24 patients treated with single-source (NTM- or CFNG-driven) innervated gracilis from the same time period were analyzed. Demographic data were recorded, including age, sex, the cause of facial palsy, follow-up duration at time of spontaneity assessment, and preoperative facial nerve status (flaccid vs nonflaccid). Facial nerve status was defined as long-standing flaccid facial palsy (FFP) if there was no sign of activity in any facial muscle on the affected side of the face for at least 18 months prior to reanimation surgery. The remaining patients were classified as having nonflaccid facial palsy (NFFP).¹⁴ Intraoperative neural coaptation patterns were classified as either interfascicular split, Y-shaped neurotomy, or end-to-side neurotomy (Figure 1).

Standardized outcome measures were collected using a patient-reported facial palsy-specific quality-of-life questionnaire (Facial Clinimetric Evaluation [FaCE] scale),¹⁵ photographs and videos of the face in repose and in 7 standardized facial expressions,¹⁶ clinician-graded electronic facial palsy severity assessment (using the eFACE scale),¹⁷ and objective facial landmark detection and measurement with a machine-learning model graphical user interface (Emotrics).¹⁸ Spontaneous smile was elicited using the Spontaneous Smile

Key Points

Question Can a video time-stamping method be used to measure spontaneity of smile after dually innervated gracilis smile reanimation surgery?

Findings In this cohort study of 25 patients treated with dually innervated gracilis free muscle transfers vs 24 patients treated with masseteric nerve-driven transfers (n = 11) or cross-face nerve graft-driven gracilis (n = 13), a spontaneous smile was present in a median of 33% of smiles, which was more than was present in masseteric nerve-driven transfers (20%) but less than in cross-face nerve graft-driven smile reanimation surgery (75%).

Meaning Dual innervation may improve synchronicity compared with masseteric nerve transfer but not to the level of cross-face nerve graft-driven gracilis free muscle transfer.

Assay (SSA),¹⁹ a validated technique of obtaining video recordings of elicited spontaneous smiles from patients viewing humorous video clips.

Two techniques were used to quantify spontaneous smiling. First, a blinded assessor analyzed each SSA video clip in which the upper face and the affected side of the lower face were blacked out. The assessor watched the video and time-stamped the filmstrip over the time period that a healthy side commissure movement was clearly elicited (Figure 2). The blackout was then reversed so that only the affected half of the lower face was visible, and oral commissure movements were time-stamped for a second time. The time-stamped videos were compared in a binary fashion (spontaneous smile present vs absent) and a mean of all smile moments was calculated, yielding an overall percentage of smiles within a SSA video that had synchronous oral commissure movements (Video 1 and Video 2). This method is similar to a recently published study that used a slow-motion video analysis method; however, blinding of the 2 sides of the face was not performed in that study.²⁰ Second, the medical record was reviewed to see how the clinician reported the presence or absence of spontaneous smile activity. Clinician-graded spontaneity was categorized as either absent, trace, or present. Correlation between synchronicity and clinician-reported spontaneity was assessed. Synchronicity was compared between dually innervated NTM-driven and CFNG-driven gracilis FFMTs.

Statistical Analysis

Descriptive statistics were expressed as numbers and frequencies and medians and interquartile ranges (IQRs). Differences between preoperative and postoperative data were tested using Wilcoxon signed rank tests. Correlation between synchronicity and clinician-reported spontaneity was tested using Spearman rank correlation. A Kruskal-Wallis test was used to analyze differences in oral commissure excursion on the affected side of the face for 3 neurotomy techniques used in dual innervation. Mann-Whitney *U* tests were used to test differences in synchronicity and follow-up time between dually innervated and NTM-driven or CFNG-driven gracilis FFMT. An alpha of .05 was selected, and all statistical tests were performed using SPSS version 25 (IBM).

Figure 1. Neuroorrhaphy Techniques

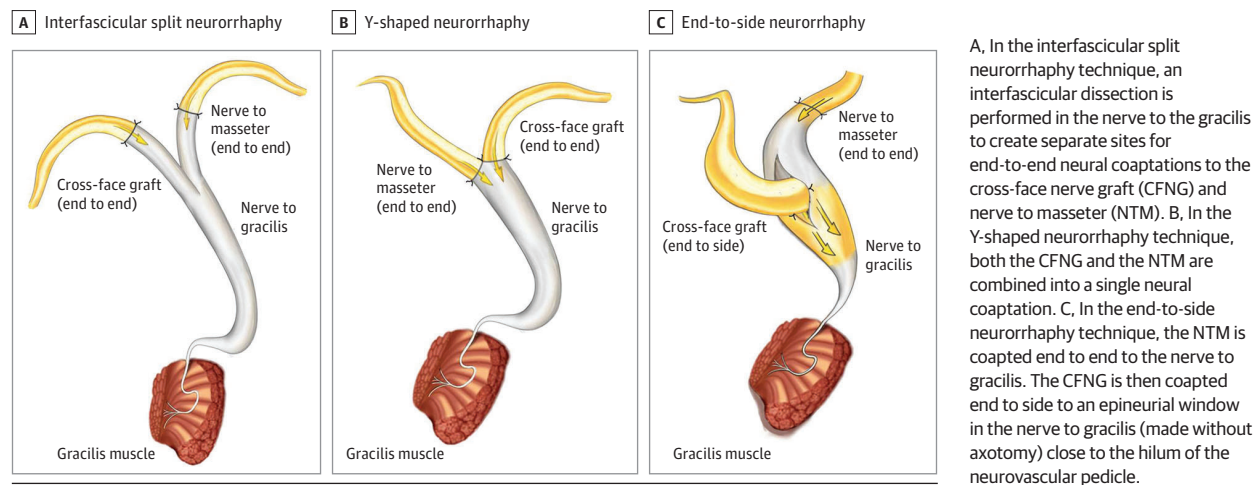



Figure 2. Manual Time-Stamping Technique



A, A blinded assessor analyzed the spontaneous smile assay (SSA) video clip in which the upper face and the affected side of the lower face were blacked out. The assessor time-stamped the filmstrip over the time period that a healthy side oral commissure movement was clearly elicited (yellow bars). B, The blackout was then reversed so that only the affected half of the lower face was visible, and oral commissure movements were time-stamped for a second time.

Time-stamps were labeled (movement present, green bars; movement absent, red bars) and a mean was calculated, yielding an overall percentage of smiles within the SSA video clip that demonstrated synchronous oral commissure movements. Synchronicity in this case was 25% (1 of 4 smiles). See Video 1 and Video 2 for further demonstration of this technique.

Results

Demographics

Dually innervated gracilis FFMT for unilateral facial palsy was performed in 37 patients between 2007 and 2017 (29 patients between 2016 and 2017, and 8 between 2007 and 2015). Eight patients had insufficient follow-up of less than 6 months at time of spontaneity assessment and 4 patients were lost to follow-up; thus, 25 patients (12 men and 13 women; median [range] age, 38.4 [29.3-46.0] years) in the dual innervation group and 24 patients (demographic data not available for NTM and CFNG cohorts) in the single-source innervation group were included in the final analysis. Median postoperative follow-up was 0.8 (IQR, 0.6-1.4) years (Table 1). Most patients (15 [60%] of 25) presented with facial palsy after tumor or trauma. Seventeen (68%) of 25 patients had FFP and 8 (32%) had NFFP. An interfascicular split neuroorrhaphy technique was used to

perform dual innervation in 15 (60%) patients, Y-shaped neuroorrhaphy was used in 6 (24%), and the end-to-side technique was used in 4 (16%) (Figure 1).

Outcome Measures

Preoperative and postoperative FaCE scale scores were available for 15 (60%) of 25 patients, and patient-reported quality-of-life scores rose from a preoperative median of 38 points (IQR, 35-53) to a postoperative median of 51 points (IQR, 38-70) ($P = .004$). Significant increases were found in static, dynamic, and total eFACE scores (Table 2). Excursion of the affected corner of the mouth with smile improved significantly from a preoperative median (IQR) of -1.2 mm (-2.6 to 2.4) to a postoperative median of 5.8 mm (IQR, 2.4 - 6.4) ($P < .001$). Additionally, symmetry of the mouth in repose and with smile improved significantly (Table 2). No difference in postoperative oral commissure excursion was found between the 3 different dual innervation neuroorrhaphy techniques.

Spontaneity Assessment

The SSA was performed in 19 (76%) of 25 patients treated with a dually innervated technique.¹⁹ Of these, 17 (89%) of 19 patients generated a spontaneous smile during the video that could be analyzed. The median (IQR) percentage of synchronous oral commissure movements in dually innervated patients was 33.0% (0%-71%). Median (IQR) synchronicity in FFP was 16.5% (0%-64%) and NFFP was 60.0% (0%-100%), although this difference was not statistically significant ($P = .33$, Mann-Whitney U test). The SSA was performed in dual innervation after a median (IQR) follow-up of 0.8 (0.7-1.1) years. Synchronous movement was not correlated with the duration of follow-up.

Table 1. Characteristics, Follow-up Time, and Innervation Techniques in Patients Treated With Dual Innervation

Characteristic	No. of Patients n = 25
Sex	
Female	13
Male	12
Median age (range), y	38.4 (29.3-46.0)
Affected side	
Left	14
Right	11
Etiology	
Acoustic neuroma resection	6
Iatrogenic injury/trauma	5
Benign tumor resection	4
Viral paralysis	4
Congenital	1
Other	5
Duration of paralysis, median (IQR), y	4.1 (2.4-12.9)
Flaccid facial palsy	17
Nonflaccid facial palsy	8
Follow-up time, median (IQR), y	0.8 (0.6-1.4)
Innervation technique	
Interfascicular split	15
Y-shaped neuroorrhaphy	6
End-to-side	4

Abbreviation: IQR, interquartile range.

Table 2. Patient-Reported Outcome Measure Improvements, Clinician-Graded Improvements, and Objective Smile Measurements Following Dual Innervation

Outcome Measure	Median (IQR)		P Value
	Preoperative	Postoperative	
FaCE scale total scores ^a	38 (35 to 53)	51 (38 to 70)	.01
eFace scores ^b			
Total	60 (57 to 66)	80 (73.3 to 83.8)	<.001
Static	74 (60 to 82.5)	88 (84.3 to 92)	<.001
Dynamic	35 (27 to 47.5)	65.5 (58.3 to 74)	<.001
Smile measurements, ^c mm			
Excursion healthy side	11.4 (8.6 to 12.8)	9.1 (5.6 to 11.7)	.05
Excursion affected side	-1.2 (-2.6 to 2.4)	5.8 (2.4 to 6.4)	<.001
Symmetry repose	5.1 (-0.3 to 10.6)	-0.6 (-4.3 to 2.7)	.002
Symmetry smile	15.7 (10.7 to 21.7)	3.2 (-0.1 to 6.7)	<.001

Abbreviations: FaCE, Facial Clinimetric Evaluation scale; IQR, interquartile range; mm, millimeters.
^a Patient-reported outcome measure.
^b Clinician-graded improvement.
^c Emotrics facial recognition software.

Clinician-assessed spontaneity was documented in 15 (88%) of 17 medical records of patients who were noted to have smiled during the SSA. Of these, clinician-graded spontaneity was rated as absent in 40.0% (n = 6 of 15), trace in 33.3% (n = 5 of 15), and present in 26.7% (n = 4 of 15). No significant correlation between synchronicity and clinician-graded spontaneity was noted (correlation coefficient, 0.347; $P = .20$).

Comparison of CFNG, Dual Innervation, and NTM

Synchronous oral commissure excursion elicited with humorous video clips occurred variably in patients treated with CFNG-driven, dually innervated, and NTM-driven gracilis FFMTs. The use of time-stamped video assessment revealed that spontaneous synchronous oral commissure movement occurred in a median percentage of 33% in patients with dually innervated gracilis (interquartile range [IQR], 0%-71%; n = 17 patients), 20% of smiles in patients with NTM-driven gracilis (IQR, 0%-50%; n = 11 patients), and 75% of smiles in patients with CFNG-driven gracilis (IQR, 0%-100%; n = 13 patients) (Figure 3). No statistical differences among groups were detected. Synchronous movement analysis was performed for CFNG-driven, dually innervated, and NTM-driven gracilis FFMTs at a median (IQR) follow-up of 1.3 (1.0-2.0) years, 0.8 (0.7-1.0) years, and 1.4 (0.4-2.0) years, respectively. There was a significantly shorter follow-up time for dually innervated cases than CFNG-driven gracilis FFMTs. Synchronous movement was more dichotomous for CFNG-driven gracilis FFMTs than dually innervated and NTM-driven gracilis FFMTs, yielding high levels of synchronicity when any movement was present, and no synchronicity in cases of complete failure of reanimation. A wider spread of synchronicity was present in dually innervated or NTM-driven cases (Figure 3).

Discussion

Several studies using various dual innervation techniques have been published since the concept was first described by Watanabe et al⁸ in 2009, and some excellent results have been reported.⁹⁻¹³ The most commonly reported outcome

assessment tool is the Terzis and Noah scale,²⁰ which consists of a clinician-graded assessment of aesthetic and functional outcome that ranges from poor to excellent. Spontaneity of smile is not included in this grading system. In numerous case series, spontaneous smile was reported to be present in nearly all cases following dual innervation, as assessed by the treating physicians.⁹⁻¹³ In 2015, Sforza et al¹³ systematically analyzed dually innervated gracilis FFMT using a humorous video and motion tracking technology and found spontaneous smiling to be present in 9 (70%) of 13 cases. No data were presented on the duration of palsy prior to surgery or the chance of spontaneous recovery. Dual innervation was performed in a single stage, and it was unclear whether any other nerve transfer procedure (ie, direct CFNG) was simultaneously performed.

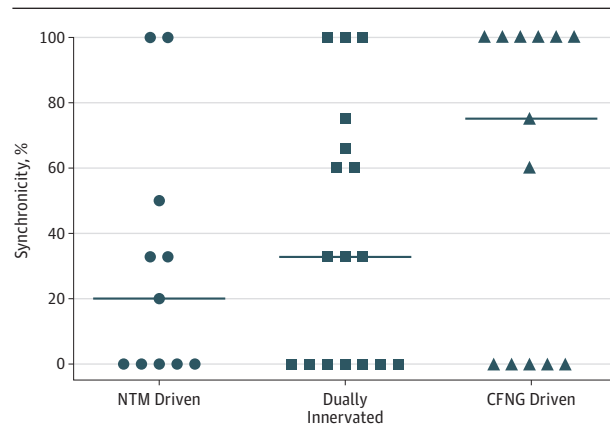
Initially, we preferred to perform 2-stage CFNG, routinely assessing for the presence of a Tinel sign at the tip of the CFNG before performing the second-stage gracilis FFMT. We performed our first case of dually innervated gracilis FFMT for smile reanimation in 2007. At that time, our indication for using dual neural sources was to optimize axonal input when questionable axonal supply was suspected within the CFNG (eg, owing to weak evoked stimulation in the donor nerve branch, poor Tinel sign, absence of a neuroma at the tip of the CFNG, or if CFNG had been used elsewhere). In order to combine 2 neural inputs, we elected to perform an interfascicular split of the anterior branch of the obturator nerve to gracilis so that 2 end-to-end neurorrhaphies could be performed with the laterally positioned NTM and the short CFNG located medially in the upper lip (Figure 1A).

Later in our experience, we offered dual innervation to older patients as a primary innervation strategy. Our goal was to augment the reliability of a NTM-driven gracilis FFMT smile with an element of the spontaneity generated from the use of CFNG. We wanted to improve on the spontaneity generated using the interfascicular split technique and decided to use a longer CFNG in the first stage, extending the graft across the face to 1 cm in front of the tragus, rather than banking it in the upper lip, as is our preference when performing gracilis transfer by using CFNG alone. This long CFNG was then coapted with the NTM in a single, Y-shaped neural coaptation to the nerve to gracilis (Figure 1B).

Our surgical technique has recently transitioned to performing a true end-to-side neurorrhaphy (also known as “supercharged” or “reverse end to side”) instead of a Y-shaped neurorrhaphy based on outcomes experienced by others (F. Biglioli, MD, personal communication, August 20, 2017). During this approach, the NTM is coapted end-to-end to the nerve to gracilis. The CFNG is then coapted end-to-side to an epineurial window in the nerve to gracilis—made without axotomy—at the hilum of the neurovascular pedicle (Figure 1C). We recommend that all patients receive postoperative physical therapy irrespective of the type of smile reanimation technique used.

We sought to assess these dual innervation techniques by using our routine panel of outcome assessment tools, including patient-reported outcome measures, clinician-graded scoring systems, and objective measurements (such

Figure 3. Synchronicity in Nerve-to-Masseter (NTM)-Driven, Dually Innervated, and Cross-Face Nerve Graft (CFNG)-Driven Gracilis Free Functional Muscle Transfers



Horizontal lines represent the median values; geometric symbols represent individual patients.

as oral commissure excursion) (Table 2). No significant differences were found between innervation techniques in terms of eFACE score improvements or oral commissure excursion.

Moreover, because the real advantage of dual innervation over NTM-driven gracilis is the presence of smile spontaneity, we sought to develop a blinded, objective measurement system to quantify the presence of synchronous smile. Although time-consuming, manual time-stamping surpassed our ability to detect spontaneity from a clinical interaction with patients. Our own clinician gradings showed no correlation with manual time-stamping in this group of dually innervated patients. This finding highlights the difficulty of quantifying spontaneous smile using a clinician-grading system alone, and it implies that there may be inherent bias in clinician assessments. Therefore, objective measurement methods of spontaneity are essential.

Synchronous oral commissure movements and spontaneous, emotional smiling are not synonymous. Synchronous oral commissure movements are a measure of how well the affected side smile is linked to the normal side via a CFNG. Spontaneous, emotional smile is much more complex, and although it is well recognized by humans, it can be difficult to quantify for study purposes. Some groups have used layperson assessment to quantify the ability of a smile to convey emotion or communicate nonverbally. For the purposes of this study, we were interested in the additional use of the CFNG and have used synchronous oral commissure movements as a proxy for spontaneous smiling. One problem with this definition is that oral commissure movements on the affected side may also occur with blink on the healthy side, when a suboptimal donor facial nerve branch has been used (Video 2). Although this synchronous movement implies the presence of successful innervation through the CFNG, it does not necessarily give information as to the ability of the smile in conveying emotion or nonverbal information. Other computer-learning techniques

quantifying the emotionality of smiling are currently being developed for this purpose.²¹

We found that synchronous movements were present in a median 33% of spontaneous smiles in our dual innervated cases, with a wide range (0% to 100%), indicating variable degrees of innervation by the CFNG or varying degrees of NTM-driven spontaneity. Interestingly, we found synchronous movement to be present in median 75% (IQR, 0%-100%) of the CFNG-driven cases. We believe that this may be owing to lower axon counts crossing the face and a weaker muscle response, especially when compared with NTM-driven gracilis muscles. Synchronous oral commissure movements were present in median 20% of smiles in NTM-driven gracilis (IQR, 0%-50%).

Existing literature suggests that dual innervation is useful for achieving both voluntary bite-driven smile and spontaneous cross-face-driven smile.⁹⁻¹³ Our experience is less convincing; we have performed many recent cases using a true end-to-side neuroorrhaphy technique but these cases have not yet had sufficient follow-up to be analyzed in this study. Overall, dual innervation performed at least as well as a typical gracilis by NTM alone. Cross-face nerve graft-driven gracilis transfer continues to be the most reliable technique for recreating a spontaneous smile, but may produce less oral commissure excursion than NTM-driven gracilis and has an overall higher failure rate.^{3,4,22}

The scientific basis of dual innervation is not well understood. Since Viterbo et al²³ reintroduced the concept of end-to-side neuroorrhaphy in 1992²⁴ there has been significant interest in optimizing reinnervation of a target muscle using a reverse end-to-side²⁵ (also known as “supercharged” end-to-side²⁶) technique. The clinical benefits of early reinnervation of the hand intrinsic muscles by supercharging end-to-side the deep motor branch of the ulnar nerve with a distal anterior interosseus nerve transfer have been reported.^{26,27} However, it is less clear whether this clinical model in fact constitutes dual innervation because regeneration of the ulnar nerve from the elbow to the hand is unreliable, and the contributions of individual nerve sources are difficult to determine clinically.²⁶ An interesting biological phenomenon to understand is what happens when 2 fronts of regenerating axons come into contact within a regenerating nerve, or when 1 axon arrives at the neuromuscular junction and there is another axon present. Does ephaptic conduction occur between regenerated axons from different origins²⁸ or does one population of axons gain dominance by a process of synaptic elimination, as has been demonstrated in developing neuromuscular junctions in vivo by Turney and Lichtman²⁹ and others?³⁰ These questions remain unanswered.

In the largest previously reported case series of dually innervated gracilis FFMT, CFNG and gracilis FFMT were performed in a single-stage procedure using a true end-to-side innervation technique.¹³ The authors assert that preserving the gracilis motor end plates by the NTM extends the window of muscle receptivity for the time it takes for the CFNG to regenerate across the face. Whether it is possible for axons to arrive at the neuromuscular junction several months after another

front of regenerating axons and either displace existing axons or create new neuromuscular junctions has not yet been investigated in animal models. Further animal studies and rigorous analysis of clinical data may improve our understanding of this biological process.

A significant proportion of healthy patients are known to co-contract the masseter muscle with smiling.³⁰ Lenz et al²⁰ found that patients with preoperative co-contraction of the zygomaticus and masseter muscles who underwent NTM-driven smile reanimation often developed a synchronous smile postoperatively. Theoretically, this finding could mean that some of the spontaneous movement in dual innervation comes from NTM input rather than CFNG input. Conversely, we recently studied patient-reported smile perception in NTM-driven smile reanimation surgery and found that self-reported spontaneous smile rates and NTM-driven smile use were low (<50%).³¹

Limitations

The present study was designed to demonstrate the utility of an objective approach to quantify spontaneous smiling; however, we did not have sufficient power to be able to make definitive conclusions on ideal neural sources in facial reanimation. Other limitations of this study include its retrospective nature, predominantly short-term follow-up (0.8 years for dual innervation vs 1.4 years for CFNG), variation in the indication for dual innervation, various neuroorrhaphy techniques used, and the inclusion of patients with FFP and NFFP. It is possible that the combination of patients with FFP and NFFP makes data interpretation more difficult because the remaining ipsilateral facial nerve function may be mistaken for CFNG-driven movement. However, in the current era, early intervention is becoming more common, and patients with long-standing, unoperated, FFP are rare. Objective assessment tools are required to be able to determine subtle differences in these complex patients. In the future, surface electromyography measurements and local anesthetic injections in the region of the CFNG may also prove useful to assess the presence or absence of a neural connection between the CFNG and the gracilis muscle, although we have not yet used these techniques.

Conclusions

We developed a blinded, objective assessment of synchronous smile and found that synchronous oral commissure movement was present in approximately one-third of the patient cohort in the present study of dually innervated facial reanimations. Additional studies of dually innervated cases with long-term follow-up and larger sample sizes are required to verify any additional utility of the dual innervation technique over the NTM-driven gracilis technique. Time-stamping is a simple and effective method of quantifying synchronicity of oral commissure movement and may help to determine the effectiveness of dual innervation at creating spontaneity, the most elusive attribute of the reanimated smile.

ARTICLE INFORMATION

Accepted for Publication: September 7, 2019.

Conflict of Interest Disclosures: Dr Jowett reported a patent to 16/069341 pending. No other disclosures were reported.

Published Online: October 31, 2019.
doi:10.1001/jamafacial.2019.1090

Author Contributions: Dr Dusseldorp had full access to all of the data in the study and takes responsibility for the integrity of the data and the accuracy of the data analysis.

Study concept and design: Dusseldorp, van Veen, Guarin, Hadlock.

Acquisition, analysis, or interpretation of data: Dusseldorp, van Veen, Quatela, Jowett, Hadlock.

Drafting of the manuscript: Dusseldorp, van Veen, Quatela, Hadlock.

Critical revision of the manuscript for important intellectual content: Dusseldorp, Guarin, Jowett, Hadlock.

Statistical analysis: van Veen.

Obtained funding: Hadlock.

Administrative, technical, or material support: Dusseldorp, Guarin, Quatela, Hadlock.

Study supervision: Dusseldorp, Jowett, Hadlock.

Meeting Presentation: Elements of this article were presented at the International Facial Nerve Symposium (IFNS); August 3 to 6, 2017, Los Angeles, California.

Additional Contributions: We thank the patients for granting permission to publish this information.

REFERENCE LIST

- Bae YC, Zuker RM, Manktelow RT, Wade S. A comparison of commissure excursion following gracilis muscle transplantation for facial paralysis using a cross-face nerve graft versus the motor nerve to the masseter nerve. *Plast Reconstr Surg*. 2006;117(7):2407-2413. doi:10.1097/01.prs.0000218798.95027.21
- Thibaut A, Chatelle C, Ziegler E, Bruno MA, Laureys S, Gosseries O. Spasticity after stroke: physiology, assessment and treatment. *Brain Inj*. 2013;27(10):1093-1105. doi:10.3109/02699052.2013.804202
- Hontanilla B, Marre D, Cabello A. Facial reanimation with gracilis muscle transfer neurotized to cross-facial nerve graft versus masseteric nerve: a comparative study using the FACIAL CLIMA evaluating system. *Plast Reconstr Surg*. 2013;131(6):1241-1252. doi:10.1097/PRS.0b013e31828bd4da
- Snyder-Warwick AK, Fattah AY, Zive L, Halliday W, Borschel GH, Zuker RM. The degree of facial movement following microvascular muscle transfer in pediatric facial reanimation depends on donor motor nerve axonal density. *Plast Reconstr Surg*. 2015;135(2):370e-381e. doi:10.1097/PRS.0000000000000860
- Hontanilla B, Cabello A. Spontaneity of smile after facial paralysis rehabilitation when using a non-facial donor nerve. *J Craniomaxillofac Surg*. 2016;44(9):1305-1309. doi:10.1016/j.jcms.2016.06.031
- Rozen S, Harrison B. Involuntary movement during mastication in patients with long-term facial paralysis reanimated with a partial gracilis free neuromuscular flap innervated by the masseteric nerve. *Plast Reconstr Surg*. 2013;132(1):110e-116e. doi:10.1097/PRS.0b013e318290f644
- Bhama PK, Weinberg JS, Lindsay RW, Hohman MH, Cheney ML, Hadlock TA. Objective outcomes analysis following microvascular gracilis transfer for facial reanimation: a review of 10 years' experience. *JAMA Facial Plast Surg*. 2014;16(2):85-92. doi:10.1001/jamafacial.2013.2463
- Watanabe Y, Akizuki T, Ozawa T, Yoshimura K, Agawa K, Ota T. Dual innervation method using one-stage reconstruction with free latissimus dorsi muscle transfer for re-animation of established facial paralysis: simultaneous reinnervation of the ipsilateral masseter motor nerve and the contralateral facial nerve to improve the quality of smile and emotional facial expressions. *J Plast Reconstr Aesthet Surg*. 2009;62(12):1589-1597. doi:10.1016/j.bjps.2008.07.025
- Okazaki M, Kentaro T, Noriko U, et al. One-stage dual latissimus dorsi muscle flap transfer with a pair of vascular anastomoses and double nerve suturing for long-standing facial paralysis. *J Plast Reconstr Aesthet Surg*. 2015;68(6):e113-e119. doi:10.1016/j.bjps.2015.02.013
- Biglioli F, Bayouh W, Colombo V, Pedrazzoli M, Rabbiosi D. Double innervation (facial/masseter) on the gracilis flap, in the middle face reanimation in the management of facial paralysis: a new concept [in French]. *Ann Chir Plast Esthet*. 2013;58(2):89-95. doi:10.1016/j.anplas.2012.12.001
- Cardenas-Mejia A, Covarrubias-Ramirez JV, Bello-Margolis A, Rozen S. Double innervated free functional muscle transfer for facial reanimation. *J Plast Surg Hand Surg*. 2015;49(3):183-188. doi:10.3109/2000656X.2014.988218
- Biglioli F, Colombo V, Tarabbia F, et al. Double innervation in free-flap surgery for long-standing facial paralysis. *J Plast Reconstr Aesthet Surg*. 2012;65(10):1343-1349. doi:10.1016/j.bjps.2012.04.030
- Sforza C, Frigerio A, Mapelli A, et al. Double-powered free gracilis muscle transfer for smile reanimation: a longitudinal optoelectronic study. *J Plast Reconstr Aesthet Surg*. 2015;68(7):930-939. doi:10.1016/j.bjps.2015.03.029
- Lindsay RW, Bhama P, Weinberg J, Hadlock TA. The success of free gracilis muscle transfer to restore smile in patients with nonflaccid facial paralysis. *Ann Plast Surg*. 2014;73(2):177-182. doi:10.1097/SAP.0b013e3182a0df04
- Kahn JB, Gliklich RE, Boyev KP, Stewart MG, Metson RB, McKenna MJ. Validation of a patient-graded instrument for facial nerve paralysis: the FaCE scale. *Laryngoscope*. 2001;111(3):387-398. doi:10.1097/00005537-200103000-00005
- Santosa KB, Fattah A, Gavilán J, Hadlock TA, Snyder-Warwick AK. Photographic standards for patients with facial palsy and recommendations by members of the Sir Charles Bell Society. *JAMA Facial Plast Surg*. 2017;19(4):275-281. doi:10.1001/jamafacial.2016.1883
- Banks CA, Bhama PK, Park J, Hadlock CR, Hadlock TA. Clinician-graded electronic facial paralysis assessment: the eFACE. *Plast Reconstr Surg*. 2015;136(2):223e-230e. doi:10.1097/PRS.0000000000001447
- Guarin DL, Dusseldorp J, Hadlock TA, Jowett N. A machine learning approach for automated facial measurements in facial palsy. *JAMA Facial Plast Surg*. 2018;20(4):335-337. doi:10.1001/jamafacial.2018.0030
- Iacolucci CM, Banks C, Jowett N, et al. Development and validation of a spontaneous smile assay. *JAMA Facial Plast Surg*. 2015;17(3):191-196. doi:10.1001/jamafacial.2015.0083
- Lenz Y, Kiefer J, Dietrich F, Stark GB, Eisenhardt SU. Pre-operative masseter muscle EMG activation during smile predicts synchronicity of smile development in facial palsy patients undergoing reanimation with the masseter nerve: a prospective cohort study. *J Plast Reconstr Aesthet Surg*. 2019;72(3):505-512. doi:10.1016/j.bjps.2018.11.011
- Dusseldorp JR, Guarin DL, van Veen MM, Jowett N, Hadlock TA. Emotion expression following smile reanimation surgery. Presented at: European Association of Plastic Surgeons (EURAPS) 29th Annual Meeting; May 17-19, 2018; Madrid, Spain.
- Viterbo F, Trindade JC, Hoshino K, Mazzoni Neto A. Latero-terminal neurotomy without removal of the epineurial sheath. experimental study in rats. *Rev Paul Med*. 1992;110(6):267-275.
- Viterbo F, Trindade JC, Hoshino K, Mazzoni Neto A. End-to-side neurotomy with removal of the epineurial sheath: an experimental study in rats. *Plast Reconstr Surg*. 1994;94(7):1038-1047. doi:10.1097/00006534-199412000-00019
- Isaacs J, Allen D, Chen LE, Nunley J II. Reverse end-to-side neurotization. *J Reconstr Microsurg*. 2005;21(1):43-48. doi:10.1055/s-2005-862780
- Barbour J, Yee A, Kahn LC, Mackinnon SE. Supercharged end-to-side anterior interosseous to ulnar motor nerve transfer for intrinsic musculature reinnervation. *J Hand Surg Am*. 2012;37(10):2150-2159. doi:10.1016/j.jhns.2012.07.022
- Davidge KM, Yee A, Moore AM, Mackinnon SE. The supercharge end-to-side anterior interosseous-to-ulnar motor nerve transfer for restoring intrinsic function: clinical experience. *Plast Reconstr Surg*. 2015;136(3):344e-352e. doi:10.1097/PRS.0000000000001514
- Lichtman JW, Livet J, Sanes JR. A technicolour approach to the connectome. *Nat Rev Neurosci*. 2008;9(6):417-422. doi:10.1038/nrn2391
- Terzis JK, Noah ME. Analysis of 100 cases of free-muscle transplantation for facial paralysis. *Plast Reconstr Surg*. 1997;99(7):1905-1921. doi:10.1097/00006534-199706000-00016
- Turney SG, Lichtman JW. Reversing the outcome of synapse elimination at developing neuromuscular junctions in vivo: evidence for synaptic competition and its mechanism. *PLoS Biol*. 2012;10(6):e1001352. doi:10.1371/journal.pbio.1001352
- Schaverien M, Moran G, Stewart K, Addison P. Activation of the masseter muscle during normal smile production and the implications for dynamic reanimation surgery for facial paralysis. *J Plast Reconstr Aesthet Surg*. 2011;64(12):1585-1588. doi:10.1016/j.bjps.2011.07.012
- van Veen MM, Dusseldorp JR, Quatela O, et al. Patient experience in nerve-to-masseter-driven smile reanimation. *J Plast Reconstr Aesthet Surg*. 2019;72(8):1265-1271. doi:10.1016/j.bjps.2019.03.037