

University of Groningen

Analysis of the position of EndoAnchor implants in therapeutic use during endovascular aneurysm repair

Goudekettering, Seline R.; van Noort, Kim; Vermeulen, J. J. M.; Ouriel, Kenneth; Jordan, William D.; Panneton, Jean M.; Slump, Cornelis H.; de Vries, Jean-Paul P. M.

Published in:
Journal of Vascular Surgery

DOI:
[10.1016/j.jvs.2018.09.035](https://doi.org/10.1016/j.jvs.2018.09.035)

IMPORTANT NOTE: You are advised to consult the publisher's version (publisher's PDF) if you wish to cite from it. Please check the document version below.

Document Version
Publisher's PDF, also known as Version of record

Publication date:
2019

[Link to publication in University of Groningen/UMCG research database](#)

Citation for published version (APA):

Goudekettering, S. R., van Noort, K., Vermeulen, J. J. M., Ouriel, K., Jordan, W. D., Panneton, J. M., Slump, C. H., & de Vries, J-P. P. M. (2019). Analysis of the position of EndoAnchor implants in therapeutic use during endovascular aneurysm repair. *Journal of Vascular Surgery*, 69(6), 1726-1735. <https://doi.org/10.1016/j.jvs.2018.09.035>

Copyright

Other than for strictly personal use, it is not permitted to download or to forward/distribute the text or part of it without the consent of the author(s) and/or copyright holder(s), unless the work is under an open content license (like Creative Commons).

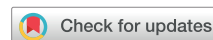The publication may also be distributed here under the terms of Article 25fa of the Dutch Copyright Act, indicated by the "Taverne" license. More information can be found on the University of Groningen website: <https://www.rug.nl/library/open-access/self-archiving-pure/taverne-amendment>.

Take-down policy

If you believe that this document breaches copyright please contact us providing details, and we will remove access to the work immediately and investigate your claim.

Downloaded from the University of Groningen/UMCG research database (Pure): <http://www.rug.nl/research/portal>. For technical reasons the number of authors shown on this cover page is limited to 10 maximum.

Analysis of the position of EndoAnchor implants in therapeutic use during endovascular aneurysm repair



Seline R. Goudekettig, MSc,^{a,b} Kim van Noort, MSc,^{a,b} Jenske J. M. Vermeulen, BSc,^{a,b} Kenneth Ouriel, MD,^c William D. Jordan Jr, MD,^d Jean M. Panneton, MD,^e Cornelis H. Slump, MSc, PhD,^b and Jean-Paul P. M. de Vries, MD, PhD,^f *Nieuwegein, Enschede, and Groningen, The Netherlands; New York, NY; Atlanta, Ga; and Norfolk, Va*

ABSTRACT

Objective: The aim of this study was to analyze the penetration depth, angles, distribution, and location of deployment of individual EndoAnchor (Medtronic Vascular, Santa Rosa, Calif) implants.

Methods: Eighty-six primary and revision arm patients (procedural success, 53; persistent type IA endoleak, 33) treated for type IA endoleaks with a total of 580 EndoAnchor implants from a subset of the Aneurysm Treatment Using the Heli-FX Aortic Securement System Global Registry (ANCHOR) were included in this study. Procedural success was defined as the absence of a type IA endoleak on the first postprocedural computed tomography scan after the EndoAnchor implantation procedure. Endograft malapposition along the circumference was assessed at the first postoperative computed tomography scans and expressed as clock-face range and width in degrees and normalized such that the center was translated to 0 degrees. The position and penetration of each EndoAnchor implant were measured as the clock-face orientation. EndoAnchor implant penetration into the aortic wall was categorized as follows: good penetration, ≥ 2 mm; borderline penetration, < 2 mm or ≥ 2 -mm gap between the endograft and aortic wall; or no penetration. The orthogonal and longitudinal angles between the EndoAnchor implant and the interface plane of the aortic wall were determined. Location of deployment was investigated for each EndoAnchor implant and classified as maldeployed when it was above the fabric or in a gap > 2 mm between the endograft and aortic wall due to > 2 -mm thrombus or positioning of the EndoAnchor implant below the aortic neck.

Results: A total of 170 (29%) EndoAnchor implants had maldeployment and were therefore beyond recommended use and not useful. After EndoAnchor implantation, the procedural success and persistent type IA endoleak groups had 3 (1%) and 4 (2%) EndoAnchor implants positioned above the fabric as well as 60 (18%) and 103 (42%) placed in a gap > 2 mm, respectively. The amount of EndoAnchor implants with good, borderline, and no penetration was significantly different between both groups (success vs type IA endoleak) after exclusion of maldeployed EndoAnchor implants (235 [87.4%], 14 [5.2%], and 20 [7.4%] vs 97 [68.8%], 18 [12.8%], and 26 [18.4%], respectively; $P < .001$). Good penetration EndoAnchor implants were more closely aligned with a 90-degree orthogonal angle than the borderline penetration and non-penetrating EndoAnchor implants. The longitudinal angle was more distributed, which was observed through all three penetration groups.

Conclusions: In this subcohort of ANCHOR patients, almost 30% of the EndoAnchor implants had maldeployment, which may be prevented by careful preoperative planning and measured intraoperative deployment. If endoleaks are due to > 2 -mm gaps, EndoAnchor implants alone may not provide the intended sealing, and additional devices should be considered. (*J Vasc Surg* 2019;69:1726-35.)

Keywords: EndoAnchor implant; Endovascular aneurysm repair; Abdominal aortic aneurysm; Type IA endoleak; Aneurysm neck

The Heli-FX EndoAnchor System (Medtronic Vascular, Santa Rosa, Calif) was developed to ensure durable endograft sealing and fixation as an adjunct to endovascular aneurysm repair (EVAR). Prophylactic use of EndoAnchor implants can prevent migration and the occurrence of type IA endoleaks after EVAR.¹ In addition,

EndoAnchor implants can be used therapeutically to prevent persistent migration as well as to treat acute and late type IA endoleaks.² The EndoAnchor implant's helical design allows safe attachment of the endograft to the aortic wall, at the same time minimizing the risk of perforation of adjacent structures. When deployed

From the Department of Vascular Surgery, St. Antonius Hospital, Nieuwegein^a; the MIRA Institute of Biomedical Technology and Technical Medicine, University of Twente, Enschede^b; Syntactx, New York^c; the Department of Vascular Surgery, Emory University School of Medicine, Atlanta^d; the Division of Vascular Surgery, Eastern Virginia Medical School, Norfolk^e; and the Department of Vascular Surgery, University Medical Center Groningen, Groningen.^f

This research received a restricted grant from Medtronic, Inc.

Author conflict of interest: J.M.P., W.D.J., and J.P.d.V. are consultants and on the Scientific Advisory Board for Medtronic, Inc.

Correspondence: Seline R. Goudekettig, MSc, Department of Vascular Surgery, St. Antonius Hospital, Koekoekslaan 1, 3435 CM, Nieuwegein, The Netherlands (e-mail: s.goudekettig@antoniusziekenhuis.nl).

The editors and reviewers of this article have no relevant financial relationships to disclose per the JVS policy that requires reviewers to decline review of any manuscript for which they may have a conflict of interest.

0741-5214

Copyright © 2018 by the Society for Vascular Surgery. Published by Elsevier Inc. <https://doi.org/10.1016/j.jvs.2018.09.035>

circumferentially, EndoAnchor implants increase fixation strength to that of a surgical hand-sewn anastomosis. However, this strength can be achieved only if the EndoAnchor implants successfully penetrate the aortic wall at least 2 mm.³⁻⁵

A recent publication demonstrated the association between aortic neck characteristics and successful EndoAnchor penetration in patients with type IA endoleaks. The aortic neck diameter and neck calcium thickness were independent predictors for individual EndoAnchor implant maldeployment. Moreover, a larger number of nonpenetrating EndoAnchor implants were associated with an increased risk for type IA endoleaks.⁵ However, the reasons for failed EndoAnchor implant penetration in the aortic wall were not investigated. Technical errors affect successful penetration, including placement of EndoAnchor implants above the fabric, deployment at a tangential angle to the aortic wall, and placement at the site of a large gap between the aortic wall and endograft.

The aim of this study was to analyze the relationship between EndoAnchor deployment and successful resolution of type IA endoleaks, including their distribution along the circumference of the neck, penetration depth into the aortic wall, and angle of penetration. This information is essential to demonstrate and to emphasize the importance of preoperative planning and intraoperative techniques, leading to improved use of EndoAnchor implants in resolving type IA endoleaks.

METHODS

Selection of patients. A subset of patients from the Aneurysm Treatment Using the Heli-FX Aortic Securement System Global Registry (ANCHOR; NCT01534819) were included in this study. The study was conducted according to the Declaration of Helsinki, and informed consent was obtained for every patient.

Patients from ANCHOR were included in this study only if the indication for EndoAnchor use was to treat a type IA endoleak and the first postprocedural computed tomography (CT) angiography scan was of sufficient quality (arterial-phase contrast, no slice thickness >3 mm or artifacts [eg, bare-metal stents, extension cuffs, or glue]). Patients were excluded when aortic extension cuffs were implanted at the time of EndoAnchor implantation because the sequence of the deployment of the additional material was unknown. As well, the use of an aortic extension cuff precludes the assessment of whether success might be attributable to the cuff or the EndoAnchor implants or both. Of note, the current results are not representative for the whole ANCHOR cohort because of the strict exclusion criteria.

The study cohort was composed of a subset of patients from both the primary and revision arms of the ANCHOR cohort. The primary arm consisted of patients treated for an intraoperative type IA endoleak; the revision arm

ARTICLE HIGHLIGHTS

- **Type of Research:** Multicenter retrospective analysis of prospectively collected data of the Aneurysm Treatment Using the Heli-FX Aortic Securement System Global Registry (ANCHOR)
- **Key Findings:** EndoAnchor treatment of type IA endoleaks resulted in a 30% rate of maldeployment, increased failure with a >2-mm gap between the endograft and aortic wall, and higher degree of success when EndoAnchors had good penetration (>2 mm).
- **Take Home Message:** This study suggests that EndoAnchor penetration >2 mm is essential to successful treatment of type IA endoleaks.

comprised those with EndoAnchor implant use as a secondary intervention for type IA endoleak or endograft migration after EVAR. The study population was divided into a nonsuccessful and successful cohort on the basis of persistence of type IA endoleak after treatment of EndoAnchor implants at 1-month follow-up.

Imaging studies and measurement protocol. Measurements were performed on the preprocedural and first postprocedural CT scans, using a 3mensio vascular workstation (V9.0 SPI; Pie Medical Imaging BV, Maastricht, The Netherlands). Median time between the procedure and first postprocedural CT scan was 36 days (interquartile range [IQR], 25-47 days). The median slice thickness was 2 mm (range, 0.6-3.0 mm). A center lumen line (CLL) was semiautomatically drawn through the lumen of the aorta and adjusted manually if necessary. The orifices of the renal arteries, proximal endograft fabric markers, each EndoAnchor implant, and aortic bifurcation were identified. Neck diameter was measured as the outer to outer diameter at the level of the renal arteries on the preoperative CT scan. The position and width of type IA endoleaks (gap between endograft and aortic wall) and the penetration depth and penetration angles of the EndoAnchor implants in both the primary and revision arms were measured. Because of the 3.5-mm total penetration length of the EndoAnchor implants, a gap of >2 mm between the endograft and aortic wall is beyond the recommended use for EndoAnchor implant deployment and could thereby result in maldeployment. Therefore, the eventual gap (≥ 2 mm) between the endograft and aortic wall was measured at the position of every EndoAnchor implant.

Endoleak measurements. The location where the endograft was not apposed to the aortic wall was defined as the endograft malapposition along the circumference of the proximal aortic neck. The endograft malapposition for patients with an endoleak was measured on preprocedural and postprocedural CT

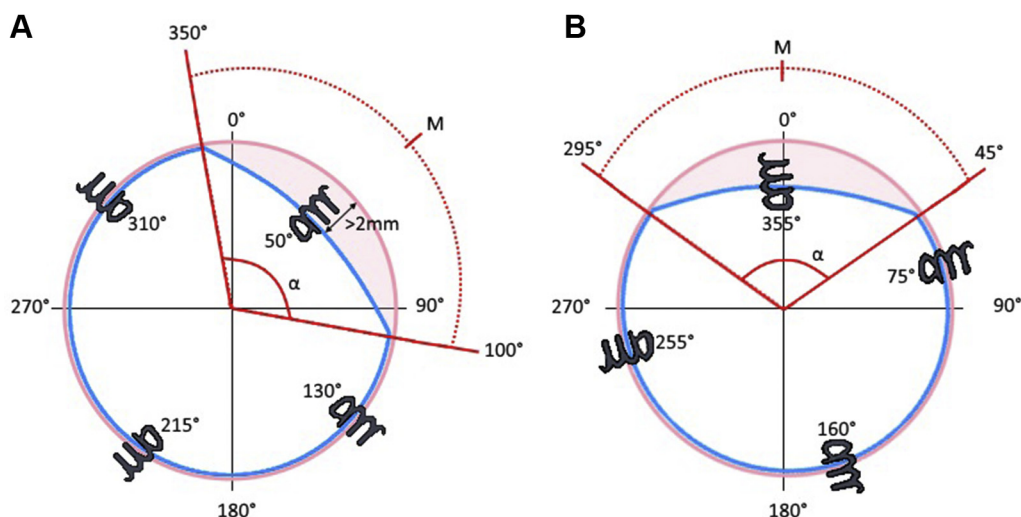


Fig 1. Schematic depiction in 360 degrees of the circumference and the normalization of the location of malapposition of EndoAnchor implants. **A**, The width (α in degrees) and the center of the malapposition zone (M). Notice that in this example, one of the EndoAnchor implants is deployed within the endoleak where there is a gap >2 mm; maldeployment due to exceeding the recommended use. The angle measurements (α) are performed on the slice perpendicular to the centerline. The width of the malapposition zone in this example is 110 degrees, and thus the center is 55 degrees. **B**, The malapposition zone is normalized such that the midpoint is located at 0 degrees. Therefore, the clock-face location of the EndoAnchor implants is also normalized to the center of the malapposition zone (ie, the clock-face EndoAnchor implant location minus 55 degrees).

scans for patients of the revision arm and on the postprocedural CT scans for patients in the primary arm. The circumference over which there was endograft malapposition was expressed as the clock-face range and width in degrees (Fig 1, A), normalized such that the center was translated to 0 degrees (Fig 1, B).⁵

EndoAnchor implant penetration. EndoAnchor implant penetration measurements were performed on the first postprocedural CT scan after EndoAnchor implant deployment. In a previous publication,⁵ penetration of the EndoAnchor implants was reviewed as good penetration when the EndoAnchor implant penetrated the aortic wall ≥ 2 mm, borderline penetration because of <2 mm of penetration or a gap between the endograft and aortic wall, or no penetration when there was no penetration into the aortic wall. Two experienced observers (S.G., K.N.) independently performed these measurements. A third reviewer's (J.P.d.V.) opinion was conclusive if there was a discrepancy in measurements. Maldeployment was investigated for each EndoAnchor implant and defined as EndoAnchor implants deployed above the fabric or in a gap >2 mm between the endograft and aortic wall (ie, endograft malapposition) due to thrombus >2 mm in the infrarenal neck or positioning of the EndoAnchor implant below the aortic neck (start of the aneurysm). Examples of properly deployed and maldeployed EndoAnchor implants are shown in Fig 2. Analysis of EndoAnchor implant penetration was performed for each EndoAnchor implant. They were subgrouped by whether they were implanted

within or outside the recommended use. Of note, one maldeployed EndoAnchor implant does not mean that all EndoAnchors are maldeployed in a patient. The position of the EndoAnchor implants was measured as a clock-face orientation (in degrees) on the orthogonal view, where 0 degrees was the 12-o'clock position on the aortic circumference (Fig 1, A). In subjects with a persistent type IA endoleak, the position of the EndoAnchor implants was translated according to the position of the endoleak, where 0 degrees was the center of the endoleak (Fig 1, B). The distribution of EndoAnchor implants with good, borderline, and no penetration in the successful and nonsuccessful cohorts was plotted over the circumference. In addition, the decrease in width of the endograft malapposition zone over the circumference was plotted for patients of the revision arm without procedural success.

EndoAnchor implant angle analysis. EndoAnchor implant penetration angles were determined as the orthogonal and longitudinal angles between the EndoAnchor implant and the aortic wall. Orthogonal angles were measured on the orthogonal view of the CLL with the angle tool in 3mensio (Fig 3, A). The angle was determined at the interface plane of the aortic wall and the EndoAnchor implant. The longitudinal angles were measured by placing two markers on the extremities of the EndoAnchor implants (Fig 3, B, blue dots) and two markers on the aortic wall parallel to the two markers of the extremities of the EndoAnchor implants (Fig 3, B, orange dots). Coordinates were exported to

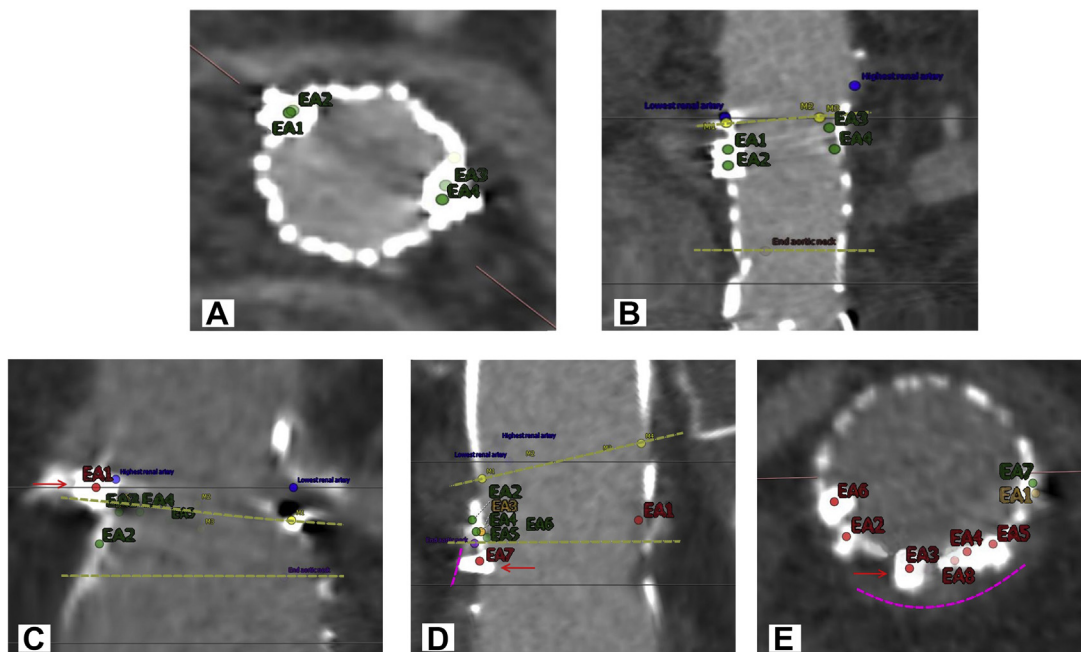


Fig 2. Examples of properly deployed (**A, B**) and maldeployed (**C-E**) EndoAnchor implants. **A** and **B**, EndoAnchor implants deployed within the apposition zone and penetrating the aortic wall at least 2 mm. **C**, EndoAnchor implant (EA1, red arrow) deployed above the fabric (yellow markers represent the endograft fabric markers, and the upper yellow dotted line represents the location of the top of the endograft fabric). **D**, EndoAnchor implant (EA7, red arrow) deployed below the apposition zone (lower yellow dotted line). This EndoAnchor implant furthermore does not penetrate the aortic wall (pink dotted line). **E**, EndoAnchor implant (EA3, red arrow) deployed within a >2-mm gap (aortic wall is the pink dotted line).

MATLAB 2017a (MathWorks, Natick, Mass) to calculate the directional vectors of the EndoAnchor implants and the directional vector of the aortic wall (Fig 3, B, blue and orange lines). The angle between the vectors was calculated for every EndoAnchor implant. To test the intra-observer and interobserver variability, the orthogonal and longitudinal angles of 80 EndoAnchor implants were measured by two experienced observers (J.J.M.V., S.G.).

Statistical analysis. Statistical analyses were performed with SPSS version 24 software (IBM Corp, Armonk, NY). *P* values were considered significant when two-tailed $\alpha < .05$. Normality of the data was tested with the Shapiro-Wilk test. All variables had a non-normal distribution; therefore, data were represented as median (IQR). Differences in continuous variables were tested with the Mann-Whitney *U* test and Wilcoxon signed rank test; categorical variables were calculated with the Fisher exact test. The intraclass correlation coefficient (ICC) was used to determine the intraobserver and interobserver agreement for the orthogonal and longitudinal angles of the EndoAnchor implants to the CLL. ICC values were categorized into levels of agreement: poor (0-0.20), fair (0.21-0.40), moderate (0.41-0.60), good (0.61-0.80), and perfect (0.81-1.00). Pearson correlation coefficient was used to calculate the correlation between neck diameter and longitudinal angles.

RESULTS

The analysis included a subcohort of 86 patients from ANCHOR treated for type IA endoleaks. Among these, 81.4% were male, and 61 (71%) and 25 (29%) patients were treated in the primary and revision arms of the registry, respectively. After treatment with EndoAnchor implants, 53 of the endoleaks resolved (62%) and 33 (38%) persisted through the 1-month CT angiography study. Median preoperative neck diameter was 26.5 mm (IQR, 24.2-28.8 mm).

Endoleak measurements. In the primary arm, 17 patients had a persistent type IA endoleak with a median width of the malapposition zone between endograft and aortic wall of 83 degrees (IQR, 75-120 degrees). The median preoperative width of the endograft malapposition zone of the 25 patients in the revision arm was 113 degrees (IQR, 98-143 degrees). Sixteen patients (64%) had a persistent type IA endoleak after EndoAnchor implant treatment in the revision arm. Of note, the decrease in width of malapposition zone was not significant in the cases with persisting endoleaks (preoperative: median, 113 degrees [IQR, 77-148 degrees]; postoperative: median, 102 degrees [IQR, 68-133 degrees]; *P* = .284).

EndoAnchor implant penetration. A total of 580 EndoAnchor implants were deployed in the 86 subjects, 332 and 248 EndoAnchor implants in the cohorts with

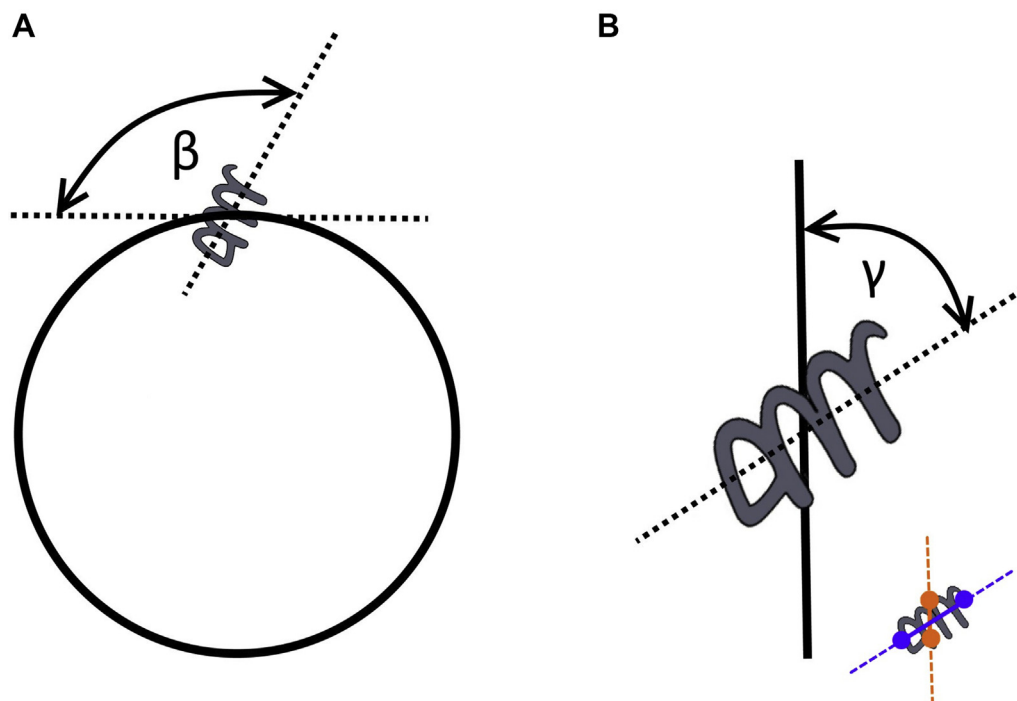


Fig 3. Schematic depiction of the angles between the EndoAnchor implant and aortic wall. **A**, Orthogonal angle (β) measurements performed with the 3mensio angle tool. **B**, The longitudinal angle (γ) was calculated as follows: markers were placed on the extremities of the EndoAnchor implant (blue dots) and parallel to the extremities of the EndoAnchor implant on the aortic wall (orange dots). The directional vectors were created for the EndoAnchor implant (blue line) and the aortic wall (orange line). The angle between the directional vectors was calculated.

and without procedural success, respectively. The median number of EndoAnchor implants was 6 (IQR, 4-8) per patient in the 53 patients with successful resolution of the type IA endoleak and 8 (IQR, 4-10) in the 33 patients with a persistent endoleak ($P = .060$). A total of seven (1%) EndoAnchor implants were deployed above the fabric and a total of 163 (28%) EndoAnchor implants were deployed in a ≥ 2 -mm gap between endograft and aortic wall.

Figs 4 to 6 represent the clock-face distribution of EndoAnchor implants. Each dot represents an EndoAnchor implant, and the color corresponds to one of the three groups of penetration (ie, good penetration, borderline penetration, or nonpenetration). The histogram corresponds to the percentage of EndoAnchor implants per penetration group over a range of 30 degrees.

Figs 4, A and 5, A show the clock-face distribution of all EndoAnchor implants in the procedural success and failure groups, respectively. Figs 4, B and 5, B show the distribution of only the EndoAnchor implants that were positioned within the recommended use and thus without maldeployment.

In Fig 4, B, three (1%) EndoAnchor implants were deployed above the fabric and a total of 60 (18%) EndoAnchor implants (18 [56%] borderline penetration and 42 [65%] nonpenetrating) were excluded from the cohort with procedural success because of a >2 -mm gap.

Four (2%) EndoAnchor implants were located above the fabric and a total of 103 (42%) EndoAnchor implants were deployed in an area with a gap ≥ 2 mm in the persistent type IA endoleak cohort: 25 (58%) borderline penetration and 78 (73%) nonpenetrating EndoAnchor implants (Fig 5, B). Of the 248 EndoAnchor implants, 110 (44.4%) were deployed in or near the endograft malapposition zone: 25 (23%) good penetration, 19 (17%) borderline penetration, and 66 (60%) nonpenetrating (Fig 5, A). After exclusion of EndoAnchor implants with maldeployment, only 25 good penetration (64%), 4 borderline penetration (10%), and 10 nonpenetrating (26%) EndoAnchor implants remain within this zone (Fig 5, B). This means that the majority of EndoAnchor implants deployed within the endograft malapposition zone were maldeployed (ie, 56 [51%] EndoAnchor implants with no penetration and 15 [17%] with borderline penetration).

In 33 patients of the successful group, a median of 1 [IQR, 1-3] EndoAnchor implant was maldeployed. In the 21 patients with a persistent type IA endoleak, a median of 4 [IQR, 3-6] EndoAnchor implants were maldeployed.

The amount of EndoAnchor implants with good, borderline, and no penetration was still significantly different between the procedural success and failure groups after exclusion of EndoAnchor implants with maldeployment (success: 235 [87.4%], 14 [5.2%], and 20

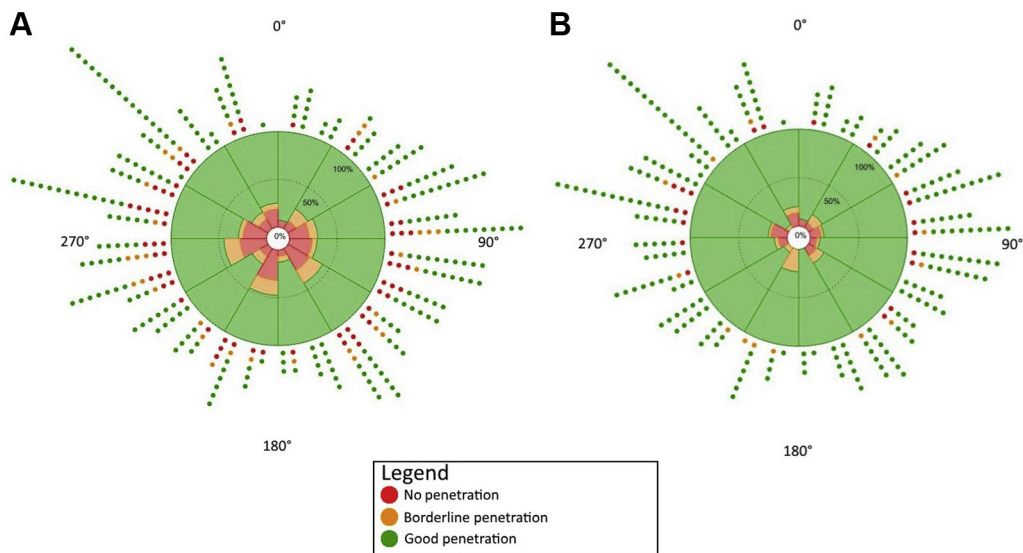


Fig 4. Graphical representation of the clock-face EndoAnchor implant distribution and penetration for patients with procedural success after treatment with EndoAnchor implants. Note that 0 degrees corresponds to the anterior position on the orthogonal view. **A**, EndoAnchor implants (n = 332) deployed in 53 patients that resulted in procedural success. **B**, EndoAnchor implants (n = 269) of the 53 patients with procedural success where the EndoAnchor implants with maldeployment were excluded.

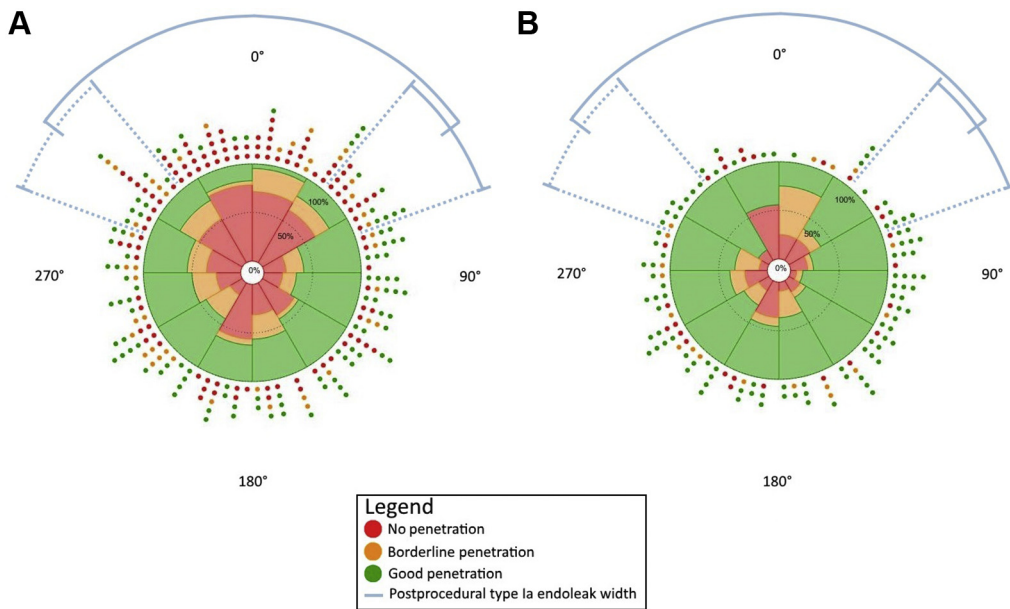


Fig 5. Graphical representation of the clock-face EndoAnchor implant distribution and penetration for patients with a persistent type IA endoleak after treatment with EndoAnchor implants. Note that 0 degrees represents the center of the malapposition zone (see also Fig 1, B). The blue lines represent the median (interquartile range [IQR]) of the malapposition zone. **A**, Persistent type IA endoleak after EndoAnchor implant deployment (n = 248) in 33 patients. **B**, Distribution of the EndoAnchor implants (n = 141) where EndoAnchor implants with maldeployment were excluded.

[7.4%]; type IA endoleak: 97 [68.8 %], 18 [12.8%] and 26 [18.4%]; $P < .001$).

Fig 6 shows the clock-face distribution of 135 EndoAnchor implants of the 16 revision arm patients with a persistent type IA endoleak due to malapposition of the endograft.

The endograft malapposition zone did not significantly decrease in width after EndoAnchor implant deployment. A total of 12 (50%) borderline penetration and 43 (75%) nonpenetrating EndoAnchor implants were deployed beyond recommended use. This accounts for 41% of the

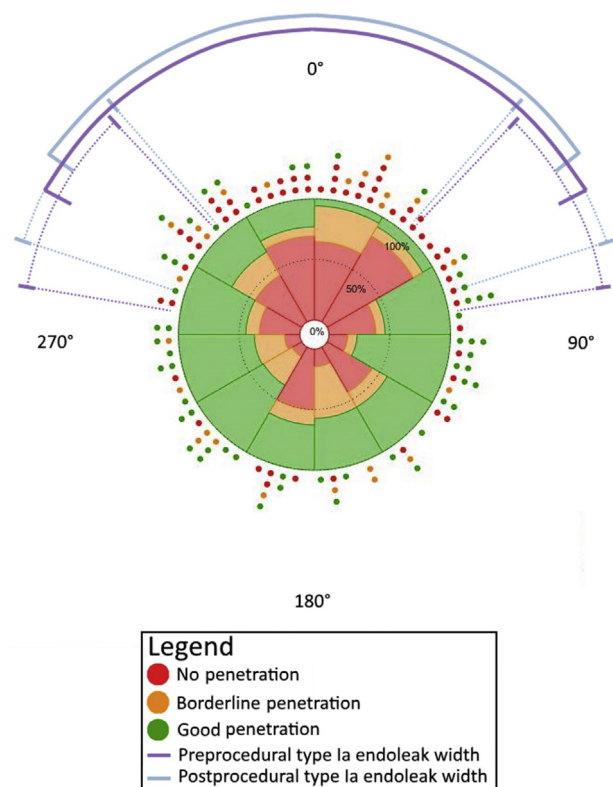


Fig 6. Sixteen patients treated for type IA endoleak after previous endograft implantation (revision procedures). The center of the endograft malapposition zone was normalized to 0 degrees. The median (interquartile range [IQR]) of the endograft malapposition zone is represented by the *solid and dotted purple and blue lines* for, respectively, the preprocedural and postprocedural malapposition zones. Postoperatively, the median width of endograft malapposition was decreased (*blue line*), although not significantly. A total of 135 EndoAnchor implants were deployed in this subgroup.

deployed EndoAnchor implants in this group of persistent type IA endoleak patients from the revision arm. Moreover, the majority of the excluded EndoAnchor implants were in or near the endograft malapposition zone.

EndoAnchor implant angle analysis. Intraobserver agreement was good for the orthogonal (0.799; 95% confidence interval [CI], 0.623-0.893) and longitudinal (0.659; 95% CI, 0.351-0.820) angle measurements. Interobserver agreement for the orthogonal and longitudinal angle measurements was perfect with an ICC of 0.881 (95% CI, 0.815-0.924) and 0.914 (95% CI, 0.866-0.945), respectively. **Fig 7** shows the distribution of orthogonal and longitudinal angles of each EndoAnchor implant. Ideally, EndoAnchor implants should be deployed perpendicular to the aortic wall, meaning a 90-degree orthogonal and longitudinal angle. The EndoAnchor implants with good penetration were more centered on the 90-degree orthogonal angle, whereas this angle for borderline penetration and nonpenetrating EndoAnchor implants

was more scattered. The distribution on the 90-degree orthogonal angle for the EndoAnchor implants with good penetration appears to be more consistent than the longitudinal angle, which was observed through all three penetration groups. Note that 43 (57%) and 126 (73%) of the borderline penetration and nonpenetrating EndoAnchor implants were beyond recommended use. After removal of these EndoAnchor implants, a clearer difference appears with regard to the orthogonal angle between the different EndoAnchor implant groups. The borderline penetration and nonpenetrating EndoAnchor implants were widely scattered, whereas the good penetration EndoAnchor implants are located close to the 90-degree orthogonal angle. No significant correlation was found between neck diameter and longitudinal angles ($R = 0.039$; $P = .361$).

DISCUSSION

This study characterized the distribution of deployed EndoAnchor implants over the circumferences of the aortic wall as well as penetration depth and angle of each EndoAnchor implant in a selected subcohort of ANCHOR patients. Almost 30% of all EndoAnchor implants did not penetrate the aortic wall and 13% had a borderline penetration. Of these EndoAnchor implants, 170 were deployed beyond recommended use, corresponding to 29% of all EndoAnchor implants deployed in this cohort. After exclusion of these maldeployed EndoAnchor implants, 87.4% vs 68.8% of the EndoAnchor implants had a good penetration in the cohorts with and without procedural success, respectively.

Maldeployment of EndoAnchor implants may be overcome by careful preoperative planning to identify the apposition zone and to prevent deployment in a >2-mm gap between the aortic wall and endograft. EndoAnchor implants are not designed to overcome gaps >2 mm, which will likely be the reason that the endograft malapposition zone was not significantly decreased in width after EndoAnchor deployment in the revision group. A large proportion of borderline penetration and nonpenetrating EndoAnchor implants were positioned within this zone. The amount of EndoAnchor implants within the endograft malapposition zone with maldeployment demonstrates the likelihood that the gap in this zone was mostly >2 mm. All EndoAnchor implants positioned beyond the recommended use were therefore not useful but serve as an improvement signal where technical success can be increased through better understanding of these indications and preplanning of the case. The reason for the presence of a gap could differ between EndoAnchor implants (eg, deployment within a type IA endoleak with a >2-mm width; a >2-mm-thick thrombus load; or low positioning of the EndoAnchor implant and thus deployment in the aneurysm sac, ie, >2-mm gap). Deployment of an EndoAnchor within thrombus may furthermore decrease the

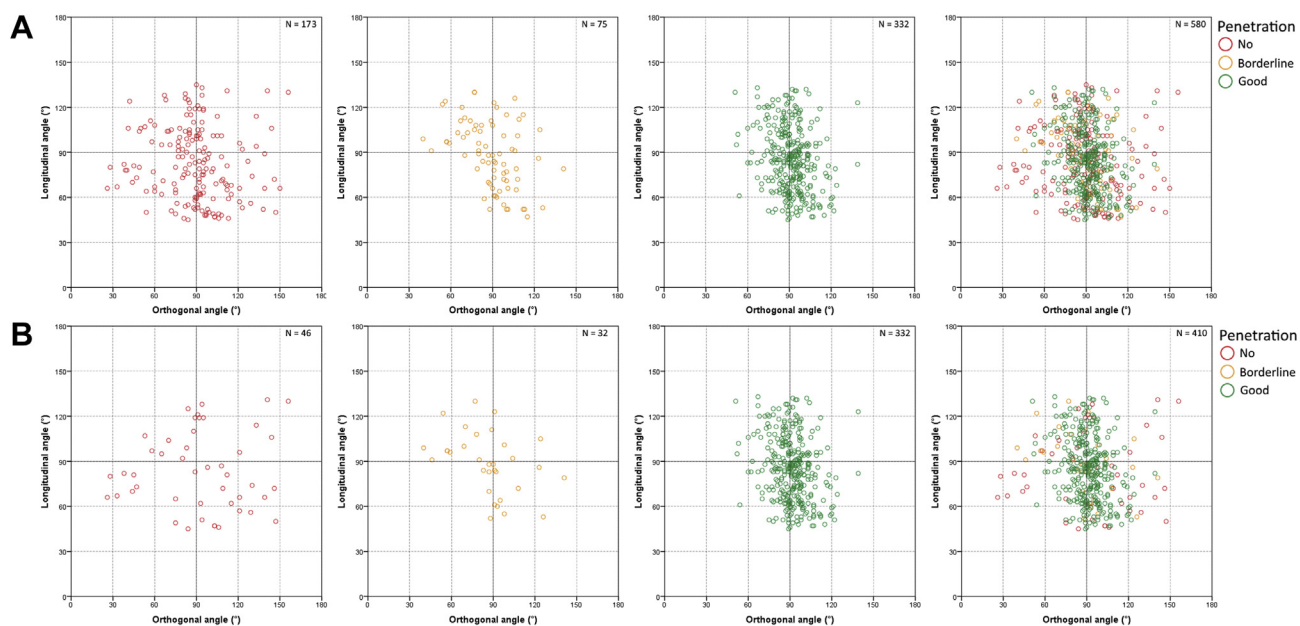


Fig 7. The distribution of EndoAnchor implants over the orthogonal (x-axis) and the longitudinal (y-axis) angles. **A**, The distribution of angles for all 580 EndoAnchor implants (ie, good penetration [green], borderline penetration [orange], and no penetration [red]). **B**, A similar distribution for the 410 EndoAnchor implants within the recommended use.

chance of ≥ 2 -mm penetration into the aortic wall (ie, good penetration), whereby adequate fixation may be inhibited. Moreover, EndoAnchor implants can encounter calcium, which can result in a fractured or nonpenetrating EndoAnchor implant (Fig 8). To overcome these problems, preoperative imaging needs careful evaluation. The clock-face locations and width of thrombus and calcium loads in the aortic neck can be calculated and translated to corresponding C-arm angles for optimal EndoAnchor implant positioning. EndoAnchor implants should be deployed in the preoperatively identified apposition zone, free from gaps and calcium load. Other reasons for EndoAnchor implant failure are mostly technical insufficiencies. First, optimal positioning of the C-arm (perpendicular to the endograft and Endoguide markers) is important throughout the intervention. During deployment of the EndoAnchor implants, the tip of the Endoguide should remain perpendicular to the fabric of the endograft.^{1,3,6,7} Two radiopaque markers (C-shaped and straight at, respectively, the distal tip and outer curve of the Endoguide) will aid the physician during deployment of the EndoAnchor implants. If the tip is positioned perpendicular to the aortic wall, the two markers will form a 90-degree angle. Hence, if the correct angle of the markers is created, the EndoAnchor implants will be deployed orthogonal to the aortic wall. Moreover, correct positioning of the C-arm perpendicular to the endograft fabric ensures that EndoAnchor implants will not be deployed above the endograft fabric. The EndoAnchor implants with good penetration were

predominantly deployed within the range of a 70- to 110-degree orthogonal angle, whereas the borderline penetration and nonpenetrating EndoAnchor implants were deployed at an orthogonal angle outside of this range. If the angle between the EndoAnchor implant and the aortic wall deviates greatly from the ideal 90 degrees, the length of the EndoAnchor implant that can penetrate the aortic wall will be limited, which may be the reason for borderline penetration or nonpenetration of the EndoAnchor implant.

The longitudinal angle is another technical challenge, and perfect positioning will work only if the size of the Endoguide is chosen on the basis of the aortic diameter. The Endoguide gets its stability from the contralateral aortic wall during deployment of the EndoAnchor. In case of an insufficiently small radius of the Endoguide, the guide cannot get its support from the opposite aortic wall and the tip of the guide will be unstable during deployment of the EndoAnchor. This will increase the risk for wiggling and maldeployment.³ Conversely, if the radius of the Endoguide is too large, the deflectable tip cannot be positioned perpendicular to the aortic wall and the risk for maldeployment will also increase. Our previous report⁵ demonstrated that the aortic neck diameter is an independent risk factor of good EndoAnchor penetration, which may have been of influence as well on the longitudinal angle. Fig 7 shows a larger deviation on the longitudinal angle for all good penetration, borderline penetration, and nonpenetrating EndoAnchor implants compared with the orthogonal angles. This implies that there is a greater technical

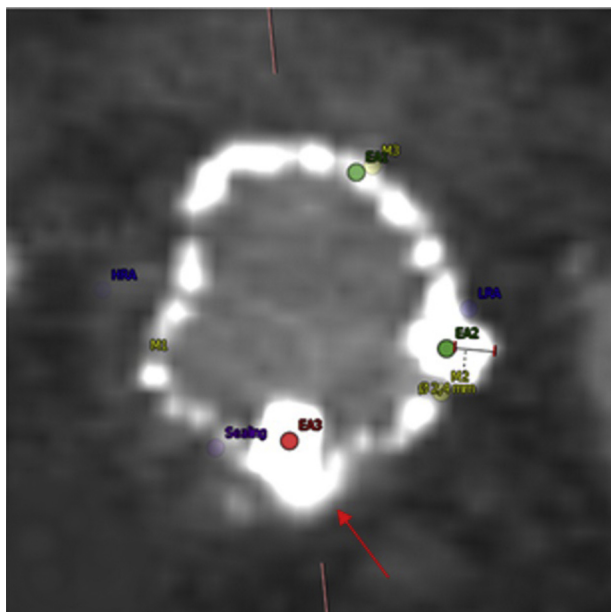


Fig 8. Perpendicular postoperative computed tomography (CT) image after implantation of an EndoAnchor in a highly calcified region. The figure shows a nonpenetrating EndoAnchor implant at the calcium load (red arrow). The blue labels represent the highest renal artery (HRA) and lowest renal artery (LRA). The yellow markers represent the markers of the endograft, whereas the purple marker points at the end of the proximal neck where sealing ends. Two green labels point at good penetrating EndoAnchor implants.

challenge in creating the correct longitudinal angle compared with the orthogonal angle.

The appropriate radius size of the Endoguide is also of importance to be able to apply sufficient pressure on the endograft (and aortic wall) during deployment of the EndoAnchor implants. Lack thereof may result in an EndoAnchor implant's sticking out into the aortic lumen, thereby having limited if any penetration into the aortic wall.

To overcome problems with gaps and angles, an increase in the length of EndoAnchor implants could be an option. However, the length of the EndoAnchor implant is designed to limit the risk of penetration of surrounding structures, such as the intestine or venous structures. Another limitation is that the EndoAnchor implant does not have the full function of a tension screw and therefore is unable to pull the aortic wall to the endograft on its own. Thus, sufficient pressure on the delivery guide is necessary to create adequate penetration and to ensure apposition of the endograft to the aortic wall.

Intraoperative assessment of the aortic wall and appreciation of penetration depth of EndoAnchor implants will increase successful use of EndoAnchor implants. In current practice, the physician must rely on haptic feedback of the guide to realize adequate pressure onto the aortic wall to deploy the EndoAnchor implants.

Intravascular ultrasound can visualize the aortic wall during EndoAnchor deployment, and this could be used to optimize the EndoAnchor's penetration and positioning. Alternatively, cone beam CT can be created after deployment of the EndoAnchor implants to assess the penetration of each individual EndoAnchor. Because the cone beam CT can be created intraoperatively, this can help decide whether more EndoAnchor implants should be deployed.

The costs of the Heli-FX EndoAnchor System as well as the reimbursement status differ per country. If EndoAnchor implants are correctly deployed and positioned, they can be successfully used to treat type IA endoleaks and, especially in case of small gutters, will be effective.⁵ This effectiveness is related to the amount of pressure that can be applied with the guide to push the endograft to the aortic wall. Importantly, the EndoAnchor implants will work sufficiently only when the endograft is pushed toward the aortic wall by the force of the applier. In other words, the EndoAnchor implants do not pull the aorta toward the endograft fabric. Longer EndoAnchor implants may not overcome this limitation and will increase the risk of penetration of adjacent structures like the caval vein or duodenum. Moreover, EndoAnchor implants can increase aortic wall apposition and prevent migration during follow-up.^{2,8,9} However, it is important to use the EndoAnchor implants in the same way as one would use a pledgeted suture (endovascular stitching). Thus, where sutures are used in case of a bleeding anastomosis, EndoAnchor implants can be used to resolve a type IA endoleak. However, EndoAnchor implants must be deployed at the location of the problem. If there is a malapposition zone, deployment of the EndoAnchor implants should start from the outer sides of the gap toward the center. This step by step reducing of the gap or endoleak may help overcome large sealing problems and may help ensure that the correct location of deployment is applied for the EndoAnchor implants. If endoleaks have >2-mm gaps, EndoAnchor implants alone may not provide the intended sealing, and additional devices should be considered.

Moreover, the studied patients were treated solely by EndoAnchor implants, and the results show that some of the patients might have benefited from the use of proximal extension cuffs or more complex revisions like chimney or fenestrated cuffs. This seems particularly true for the patients in the revision group.

Limitations of the study. EndoAnchor implant angle analysis could be challenging because of beam hardening artifacts from the metallic alloy the EndoAnchor is made of, even in high-quality CT scans. Especially in CT scans with greater slice thicknesses (1-3 mm), the extremities of the EndoAnchor implants were more difficult to identify. Moreover, 3mensio creates reconstructions of 1-mm slice thickness perpendicular to the CLL. The markers were placed on the orthogonal

view of these reconstructed slices. However, the extremities of the EndoAnchor implants could be located in between two reconstructed slices. If that was the case, markers were placed either above or below the intended location, whichever was closer to the extremity of the EndoAnchor implant. Even though this might have influenced the longitudinal angle, there was a nonsignificant difference between the measurements of both observers, and the level of agreement was perfect.

A hard cutoff value for each degree deviating from 90 degrees in the orthogonal or longitudinal axes on the increased risk for poor penetration was not determined because it is likely that a few degrees more or less will not make the difference between a good penetration, borderline penetration, or nonpenetrating EndoAnchor implant.

The presence of a learning curve must also be considered a possible reason for maldeployment of EndoAnchor implants; the data were derived from the worldwide ANCHOR registry, including experienced but also less experienced physicians (fewer than five patients treated with EndoAnchor implants before including patients in ANCHOR). Moreover, the current results are based on a subset of patients with strict inclusion and exclusion criteria and do not represent the entire ANCHOR cohort. Follow-up analysis could provide greater clarity as to the ongoing risk of endoleak persistence after EndoAnchor deployment.

CONCLUSIONS

In this subcohort of ANCHOR patients, almost 30% of the EndoAnchor implants had maldeployment, which may be prevented by careful preoperative planning and measured intraoperative deployment. If endoleaks are due to >2-mm gaps, EndoAnchor implants alone may not provide the intended sealing, and additional devices should be considered.

AUTHOR CONTRIBUTIONS

Conception and design: SG, KN, JV, KO, JPV
Analysis and interpretation: SG, KN, JV, KO, WJ, JP, CS, JPV
Data collection: SG, KN, JV

Writing the article: SG, KN

Critical revision of the article: SG, KN, JV, KO, WJ, JP, CS, JPV

Final approval of the article: SG, KN, JV, KO, WJ, JP, CS, JPV

Statistical analysis: SG, KN

Obtained funding: SG, KN, JPV

Overall responsibility: SG

SG and KN contributed equally to this article and share co-first authorship.

REFERENCES

1. De Vries JP, Van de Pavoordt HD, Jordan WD Jr. Rationale of EndoAnchors in abdominal aortic aneurysms with short or angulated necks. *J Cardiovasc Surg* 2014;55:103-7.
2. Avci M, Vos JA, Kolvenbach RR, Verhoeven EL, Perdikides T, Resch TA, et al. The use of endoanchors in repair EVAR cases to improve proximal endograft fixation. *J Cardiovasc Surg (Torino)* 2012;53:419-26.
3. De Vries JP, Jordan WD Jr. Improved fixation of abdominal and thoracic endografts with use of Endoanchors to overcome sealing issues. *Gefässchirurgie* 2014;19:212-9.
4. Melas N, Perdikides T, Saratzis A, Saratzis N, Kiskinis D, Deaton DH. Helical EndoStaples enhance endograft fixation in an experimental model using human cadaveric aortas. *J Vasc Surg* 2012;55:1726-33.
5. Coudeketting SR, Van Noort K, Ouriel K, Jordan WD Jr, Panneton JM, Slump CH, et al. Influence of aortic neck characteristics on successful aortic wall penetration of EndoAnchors in therapeutic use during endovascular aneurysm repair. *J Vasc Surg* 2018;68:1007-16.
6. Ongstad SB, Miller DF, Panneton JM. The use of EndoAnchors to rescue complicated TEVAR procedures. *J Cardiovasc Surg (Torino)* 2016;57:716-29.
7. De Vries JP, Ouriel K, Mehta M, Varnagy D, Moore WM Jr, Arko FR, et al. Analysis of EndoAnchors for endovascular aneurysm repair by indications for use. *J Vasc Surg* 2014;60:1460-7.
8. Jordan WD Jr, Mehta M, Ouriel K, Arko FR, Varnagy D, Joye J, et al. One-year results of the ANCHOR trial of EndoAnchors for the prevention and treatment of aortic neck complications after endovascular aneurysm repair. *Vascular* 2016;24:177-86.
9. Jordan WD Jr, Mehta M, Varnagy D, Moore WM Jr, Arko FR, Joye J, et al. Results of the ANCHOR prospective, multicenter registry of EndoAnchors for type Ia endoleaks and endograft migration in patients with challenging anatomy. *J Vasc Surg* 2014;60:885-92.e2.

Submitted May 3, 2018; accepted Sep 4, 2018.