

University of Groningen

ECCO-ESGAR Guideline for Diagnostic Assessment in IBD Part 1

European Crohn's and Colitis Organisation [ECCO] and the European Society of Gastrointestinal and Abdominal Radiology [ESGAR]

Published in:
Journal of Crohn's and Colitis

DOI:
[10.1093/ecco-jcc/jjy113](https://doi.org/10.1093/ecco-jcc/jjy113)

IMPORTANT NOTE: You are advised to consult the publisher's version (publisher's PDF) if you wish to cite from it. Please check the document version below.

Document Version
Publisher's PDF, also known as Version of record

Publication date:
2019

[Link to publication in University of Groningen/UMCG research database](#)

Citation for published version (APA):

European Crohn's and Colitis Organisation [ECCO] and the European Society of Gastrointestinal and Abdominal Radiology [ESGAR] (2019). ECCO-ESGAR Guideline for Diagnostic Assessment in IBD Part 1: Initial diagnosis, monitoring of known IBD, detection of complications. *Journal of Crohn's and Colitis*, 13(2), 144-164. <https://doi.org/10.1093/ecco-jcc/jjy113>

Copyright

Other than for strictly personal use, it is not permitted to download or to forward/distribute the text or part of it without the consent of the author(s) and/or copyright holder(s), unless the work is under an open content license (like Creative Commons).

The publication may also be distributed here under the terms of Article 25fa of the Dutch Copyright Act, indicated by the "Taverne" license. More information can be found on the University of Groningen website: <https://www.rug.nl/library/open-access/self-archiving-pure/taverne-amendment>.

Take-down policy

If you believe that this document breaches copyright please contact us providing details, and we will remove access to the work immediately and investigate your claim.

Downloaded from the University of Groningen/UMCG research database (Pure): <http://www.rug.nl/research/portal>. For technical reasons the number of authors shown on this cover page is limited to 10 maximum.



ECCO Guideline/Consensus Paper

ECCO-ESGAR Guideline for Diagnostic Assessment in IBD Part 1: Initial diagnosis, monitoring of known IBD, detection of complications

Christian Maaser,^a Andreas Sturm,^b Stephan R. Vavricka,^c Torsten Kucharzik,^d Gionata Fiorino,^e Vito Annese,^f Emma Calabrese,^g Daniel C. Baumgart,^h Dominik Bettenworth,ⁱ Paula Borralho Nunes,^{j,®} Johan Burisch,^{k,®} Fabiana Castiglione,^l Rami Eliakim,^m Pierre Ellul,ⁿ Yago González-Lama,^o Hannah Gordon,^p Steve Halligan,^q Konstantinos Katsanos,^r Uri Kopylov,^m Paulo G. Kotze,^s Eduards Krustiņš,^t Andrea Laghi,^u Jimmy K. Limdi,^v Florian Rieder,^w Jordi Rimola,^x Stuart A. Taylor,^y Damian Tolan,^z Patrick van Rhee, ^{aa} Bram Verstockt,^{bb,®} Jaap Stoker^{cc}; on behalf of the European Crohn's and Colitis Organisation [ECCO] and the European Society of Gastrointestinal and Abdominal Radiology [ESGAR]

^aOutpatients Department of Gastroenterology, Hospital Lüneburg, Lüneburg, Germany ^bDepartment of Gastroenterology, DRK Kliniken Berlin I Westend, Berlin, Germany ^cGastroenterology and Hepatology Center, Zurich, Switzerland ^dDepartment of Internal Medicine and Gastroenterology, Hospital Lüneburg, Lüneburg, Germany ^eDepartment of Gastroenterology, Humanitas Clinical and Research Institute, Milan, Italy ^fDepartment of Gastroenterology, Valiant Clinic & American Hospital, Dubai, UAE ^gDepartment of Systems Medicine, University of Rome, Tor Vergata, Italy ^hDivision of Gastroenterology, University of Alberta, Edmonton, AB, Canada ⁱDepartment of Medicine B, Gastroenterology and Hepatology, University Hospital Münster, Münster, Germany ^jDepartment of Anatomic Pathology, Hospital Cuf Descobertas; Faculdade de Medicina da Universidade de Lisboa, Lisbon, Portugal ^kDepartment of Gastroenterology, North Zealand University Hospital; Center for Clinical Research and Prevention, Bispebjerg and Frederiksberg Hospital, Frederiksberg, Denmark ^lDepartment of Clinical Medicine and Surgery, "Federico II" University of Naples, Naples, Italy ^mDepartment of Gastroenterology, Sheba Medical Center, Sackler School of Medicine, Tel Aviv, Israel ⁿDepartment of Medicine, Mater Dei Hospital, Msida, Malta ^oDepartment of Gastroenterology, University Hospital Puerta De Hierro, Majadahonda [Madrid], Spain ^pDepartment of Gastroenterology, Royal London Hospital, London, UK ^qCentre for Medical Imaging, University College London, London, UK ^rDepartment of Gastroenterology and Hepatology, University and Medical School of Ioannina, Ioannina, Greece ^sColorectal Surgery Unit, Catholic University of Paraná [PUCPR], Curitiba, Brazil ^tDepartment of Gastroenterology, Hepatology and Nutrition, Pauls Stradins Clinical University Hospital, Riga, Latvia ^uDepartment of Clinical and Surgical Translational Medicine, Sapienza University of Rome, Rome, Italy ^vDepartment of Gastroenterology, Pennine Acute Hospitals NHS Trust, Manchester; Manchester Academic Health Sciences Centre, University of Manchester, UK ^wDepartment of Gastroenterology, Hepatology & Nutrition, Digestive Diseases and Surgery Institute, Cleveland Clinic, Cleveland, OH, USA ^xDepartment of Radiology, Hospital Clínic Barcelona, Barcelona, Spain ^yCentre for Medical Imaging, University College London, London, UK ^zClinical Radiology, St James's University Hospital, Leeds, UK ^{aa}Department of Paediatric Gastroenterology, Hepatology and Nutrition, University Medical Center Groningen, Groningen, The Netherlands ^{bb}Department of Gastroenterology and Hepatology, University Hospitals Leuven and CHROMETA - Translational Research in Gastrointestinal Disorders,

KU Leuven, Leuven, Belgium ^aDepartment of Radiology and Nuclear Medicine, Academic Medical Center [AMC], University of Amsterdam, Amsterdam, The Netherlands

Corresponding author: Christian Maaser, gastroenterologist, Outpatients Department of Gastroenterology, Hospital Lüneburg, Lüneburg, Germany. Email: christian.maaser@klinikum-lueneburg.de

Introduction

This new diagnostic consensus guideline is a joint project of the European Crohn's and Colitis Organisation [ECCO] and the European Society of Gastrointestinal and Abdominal Radiology [ESGAR] that now merges the former ECCO-ESGAR Imaging Guideline and the former ECCO Endoscopy Guideline, also including laboratory parameters. It has been drafted by 30 ECCO and ESGAR members from 17 European countries. All the authors recognise the work of and are grateful to previous ECCO and ESGAR members who contributed to creating the earlier consensus guidelines on imaging and endoscopy.

The former guidelines have been condensed into this new diagnostic consensus guideline which consists of two papers: the first detailing assessment at initial diagnosis, to monitor treatment and for the detection of complications; the second dealing with the available scoring systems and general considerations regarding the different diagnostic tools.

The strategy to define consensus was similar to that previously described in other ECCO consensus guidelines [available at: www.ecco-ibd.eu]. Briefly, an open call for participants was made, with ECCO participants selected by the Guidelines' Committee of ECCO [known as GuiCom] on the basis of their publication record and a personal statement, and ESGAR participants nominated by ESGAR. The following working parties were established: diagnostics at initial diagnosis, diagnostics for monitoring treatment in patients with known IBD, diagnostics for the detection of complications, scores for IBD, and general principles and technical aspects.

Provisional guideline statements and supporting text were written following a comprehensive literature review, then refined following two voting rounds. The first voting round introduced a more comprehensive voting procedure, in which each guidelines participant voted on all statements by explicitly reviewing those statements together with their respective supporting text and references.

The second voting round included optional national representative participation of ECCO's 36 member countries and ESGAR's 28 member countries. The level of evidence was graded according to the Oxford Centre for Evidence-Based Medicine [www.cebm.net]. The ECCO statements were finalised by the authors at a face-to-face meeting in Barcelona in October 2017, and represent consensus with agreement of at least 80% of the present participants. Consensus statements are intended to be read in context with their qualifying comments, and not in isolation. The supporting text was then finalised under the direction of each working group leader [SV, TK, GF, VA, EC], before being integrated by the consensus leaders [CM, JS, AS].

Chapter 1: Initial diagnosis

Statement 1.1. ECCO-ESGAR Diagnostics GL [2018]

A single reference standard for the diagnosis of Crohn's disease [CD] or ulcerative colitis [UC] does not exist. The diagnosis of CD or UC is based on a combination of clinical, biochemical, stool, endoscopic, cross-sectional imaging, and histological investigations [EL5]

A single reference standard for the diagnosis of Crohn's disease [CD] or ulcerative colitis [UC] does not exist. At a minimum, the diagnosis

of CD or UC is based on a combination of clinical, biochemical, stool, endoscopic, and histological investigations. When CD is suspected, it may be necessary to visualise [radiologically] the small intestine. Infectious colitis, including *Clostridium difficile*, should be excluded.

Statement 1.2. ECCO-ESGAR Diagnostics GL [2018]

Genetic or serological testing is currently not recommended for routine diagnosis of CD or UC [EL3]

Statement 1.3. ECCO-ESGAR Diagnostics GL [2018]

On diagnosis, complementary investigations should focus on markers of disease activity [EL2], malnutrition, or malabsorption [EL5]. Immunisation status should be assessed. Consider screening for latent tuberculosis [EL5]

At diagnosis, every patient should have a biochemical assessment with full blood count, inflammatory markers (C-reactive protein [CRP]), electrolytes, liver enzymes, and a stool sample for microbiological analysis, including *C. difficile*.^{1,2} The full blood count may reveal thrombocytosis [due to an inflammatory response], anaemia, and leukocytosis. The presence of raised inflammatory markers [CRP] broadly correlates with clinical severity in CD¹ but less so in UC except in the case of acute severe colitis.² However, laboratory markers of chronic inflammation may be normal in both UC and CD.^{3,4} As raised CRP, leukocytosis, or both are not IBD-specific, their presence cannot differentiate IBD from infectious [or other causes of] colitis. Apart from biochemical evidence of malnutrition, hypoalbuminaemia can reflect severe inflammation; however this is not superior to CRP.⁴

Faecal calprotectin [FC], a neutrophil-derived protein, appears to be the most sensitive marker of intestinal inflammation in IBD. Other neutrophil-derived proteins are elastase, lysozyme, and lactoferrin.^{3,5-10} Calprotectin values correlate well with endoscopic indices of disease activity and are thus important in various clinical settings, including initial diagnosis, diagnosis of relapse, and response to treatment.¹¹⁻¹⁵

In the initial investigations of a patient with gastrointestinal symptoms and a raised stool marker of inflammation, an ileocolonoscopy should be performed. An exact cut-off value that distinguishes between IBD and functional bowel diseases does not exist.^{16,17} However, good diagnostic accuracy can potentially be obtained at a cut-off value of 150 µg/g, as recently suggested in a meta-analysis.¹⁸ However, FC lacks the specificity to discriminate between IBD and other causes of intestinal inflammation.⁷

During the diagnostic process of IBD, gastrointestinal infections should always be excluded.^{1,2} Loose stools for more than 6 weeks usually discriminate IBD-associated colitis from most cases of infectious diarrhoea.¹⁹ Stool specimens should be obtained to exclude common pathogens and specifically assayed for *C difficile* toxin. Additional tests may be tailored according to medical history, such as for those who have travelled abroad. This may include assessment for ova, cysts, and parasites.²⁰

Serological markers may be used to support a diagnosis, though the accuracy of the best available tests [pANCA and ASCAs] is rather limited and hence ineffective at differentiating colonic CD from UC.^{21,22} Similarly, the additional diagnostic value of antiglycan and antimicrobial antibodies, such as anti-OmpC and CBir1, is small.^{3,4,23,24} Likewise, although more than 250 IBD-associated susceptibility single nucleotide polymorphisms [SNPs] have been identified, genetic testing for common variants does not allow diagnosis of IBD.²⁵

Some infections are preventable, and the risk for severe infections during immunosuppression can be decreased or eliminated if the patient is adequately vaccinated. Vaccination is best given before initiating immunomodulatory therapy. The following should be assessed before vaccination: hepatitis B surface antibody, hepatitis B antigen, hepatitis B core antibody, hepatitis A IgG, measles serology, and varicella serology. Additional baseline tests recommended at diagnosis include hepatitis C serology, EpsteinBarr serology and human immunodeficiency virus serology, after appropriate counselling.²⁶

Statement 1.4. ECCO-ESGAR Diagnostics GL [2018]

[ECCO Anaemia Guideline: statement 1D in Dignass *et al.*] Diagnostic criteria for iron deficiency depend on the level of inflammation. In patients without clinical, endoscopic, or biochemical evidence of active disease, serum ferritin <30 µg/L is an appropriate criterion [EL2]. In the presence of inflammation, serum ferritin up to 100 µg/L may still be consistent with iron deficiency [EL4]

Statement 1.5. ECCO-ESGAR Diagnostics GL [2018]

[ECCO Anaemia Guideline: statement 1E in Dignass *et al.*] In the presence of biochemical or clinical evidence of inflammation, the diagnostic criteria for anaemia of chronic disease are serum ferritin >100 µg/L and transferrin saturation <20%. If the serum ferritin level is between 30 and 100 µg/L, a combination of true iron deficiency and anaemia of chronic disease is likely [EL2]

One of the most frequent complications of IBD is anaemia (haemoglobin [Hb] <13 g/dL for men and <12 g/dL for women), which may affect patients' quality of life and should hence be evaluated at initial diagnosis.^{27–29} In cases of documented anaemia, further workup should start from the evaluation of mean corpuscular volume [MCV]. Microcytic anaemia is usually the most common type of anaemia in IBD, which usually indicates iron deficiency anaemia.³⁰ Macrocytosis may indicate vitamin B12 or folate deficiency and is also commonly seen during thiopurine therapy, whereas normocytosis may suggest anaemia of chronic disease [ACD].³¹ The distinction between iron deficiency anaemia and ACD or a mixed picture of micro- and macrocytosis is important, as treatment is different between these conditions.

The diagnosis of iron deficiency depends on the level of inflammation. In patients without clinical, endoscopic, or biochemical evidence of active disease, the diagnosis is made when serum ferritin is <30 µg/L.^{32,33} In the presence of inflammation, serum ferritin up to 100 µg/L may still be compatible with iron deficiency.^{34,35} Other markers suggestive of iron deficiency anaemia are low mean corpuscular volume [MCV], raised red cell distribution width [RDW], microcytic hypochromic pencil red cells on blood film, low serum iron, raised total iron-binding capacity, and transferrin saturation of <16%.³⁶

Statement 1.6. ECCO-ESGAR Diagnostics GL [2018]

For suspected IBD, ileocolonoscopy with biopsies from inflamed and uninfamed segments are required to establish diagnosis [EL1], except in the case of acute severe colitis in which sigmoidoscopy may be sufficient [EL3]

Statement 1.7. ECCO-ESGAR Diagnostics GL [2018]

No endoscopic feature is specific for CD or UC. The most useful endoscopic features of UC are considered to be continuous and confluent colonic involvement with clear demarcation of inflammation and rectal involvement [EL2]. The most useful endoscopic features in CD are discontinuous lesions, presence of strictures and fistulae, and perianal involvement [EL2]

For a reliable diagnosis of UC and CD, ileocolonoscopy with a minimum of two biopsies from the inflamed regions should be obtained.^{37–40} Additional biopsies from uninfamed regions and every colonic segment [including the rectum, especially in UC] may be helpful in the diagnostic process and to diagnose microscopic pathology. The distinction of infectious colitis from IBD is usually characterised by preserved crypt architecture and acute inflammation.⁴¹ However, in very early disease the architecture can be preserved. Other differential diagnoses include segmental colitis associated with diverticulitis [SCAD] and ischaemic colitis.^{42–45}

Granulomas and focal crypt architectural abnormalities, in conjunction with focal or patchy chronic inflammation [defined by the presence of lymphocytes and plasma cells], or mucin preservation at active sites, are CD-related histological features. The patchy nature of the inflammation is only diagnostic in untreated adult patients.^{46–50} One single feature is not considered to be diagnostic, though there are no data available as to how many features must be present in an endoscopically derived biopsy before a firm diagnosis can be made.⁴⁰ On surgical samples, a diagnosis of CD should be made when at least three histological features suggestive of CD [segmental crypt architectural abnormalities and mucin depletion, mucin preservation at the active sites, and focal chronic inflammation without crypt atrophy] are present in the absence of granulomas, or when an epithelioid granuloma is present with one other feature.^{39,40}

Focal or diffuse basal plasmacytosis has been recognised as the earliest feature with the highest predictive value for UC diagnosis. This can be identified in 38% of patients within 2 weeks after symptom presentation. During this period, the distribution pattern of basal plasmacytosis is focal but may eventually change into a diffuse pattern throughout the disease course. Only about 20% of patients show crypt distortion within 2 weeks of the first symptoms of colitis. The distinction from infectious colitis is therefore a major concern. Widespread mucosal or crypt architectural distortion, mucosal atrophy, and an irregular or villous mucosal surface appear later, at least 4 weeks after presentation.^{41,51} Not all microscopic features found in UC are observed in early disease. A correct diagnosis of UC is reached in approximately 75% of cases where two or three features are present. However, the exact number of features needed for UC diagnosis has not been established.³⁷

Due to the increased risk of bowel perforation, complete ileocolonoscopy is not usually recommended in case of acute severe colitis.⁵² However, a study by Terheggen *et al.* demonstrated that there was no relationship between complication rate and disease activity.⁵³

Flexible sigmoidoscopy can be safely performed to establish the diagnosis of UC. Phosphate enema preparation before flexible sigmoidoscopy has been reported to be safe in this setting,⁵⁴ though it is generally advised to avoid purgatives, especially fleet enemas and oral sodium phosphate preparations.⁵⁵

Statement 1.8. ECCO-ESGAR Diagnostics GL [2018]

Patients with clinical suspicion of CD and with normal endoscopy should be considered for small bowel capsule endoscopy [SBCE] evaluation or cross-sectional imaging [EL2]. If stenotic disease is suspected, risk of retention should be assessed [EL2]

Small bowel capsule endoscopy [SBCE] is a sensitive tool to detect mucosal abnormalities in the small bowel. There are currently two validated indexes available, namely the Capsule Endoscopy Crohn's Disease Activity Index [CECDAI] and the Lewis Score, which assess the disease location and activity of small bowel involvement. Both will be discussed further in part 2. The diagnostic yield of SBCE is comparable to other modalities (MR enterography, small intestine contrast ultrasound [SICUS]), apart from proximal small bowel involvement for which SBCE seems superior.⁵⁶ As proximal small bowel involvement is associated with a higher risk of surgery,⁵⁷ this superior accuracy might have prognostic value.⁵⁶ Data from small, prospective cohorts suggest that the diagnostic yield of SBCE is highest in patients with suggestive CD symptoms and increased inflammatory markers,^{58,59} although this was not replicated in larger retrospective cohorts.^{60,61} However, the likelihood of positive diagnosis is very low in patients with suspected CD with FC <50 µg/g.⁶² Additionally, all patients with unclassified IBD at diagnosis could also be considered for SBCE.

Similarly, as normal imaging tests such as intestinal ultrasound [IUS] and MR enterography of the small bowel cannot entirely exclude small bowel involvement, CD patients with normal radiological tests can be considered for additional SBCE, for example in patients with clinical signs suspicious of small bowel Crohn's disease and elevated calprotectin and/or otherwise unexplained iron deficiency anaemia. Contraindications for SBCE include gastrointestinal obstruction, strictures, and swallowing disorders.⁶³⁻⁶⁵ The risk of capsule retention in patients with suspected CD without obstructive symptoms and without history of small bowel resection or known stenosis is low and comparable to that of obscure gastrointestinal [GI] bleeding.⁶⁶⁻⁶⁹ Data on retention rates in patients with CD varies from 2% to 13% in patients with established CD, to approximately 1.5% in patients with suspected CD.⁷⁰ If small bowel stenosis is not firmly excluded, a patency capsule can be used to confirm small bowel patency before performing SBCE. All patency capsules are dissolved within 72 h. SBCE is considered safe if the patency capsule is excreted before 30 h, an intact capsule is excreted after 30 h, or passage to the colon of an intact patency capsule has been radiologically confirmed.⁷¹ Yadav *et al.* demonstrated that the negative predictive value [NPV] for patency capsules and radiological tests were not significantly different.⁷² Thus, if either test is negative before SBCE, the patient will most likely pass the capsule without incident. Radiological tests have the advantage of eliminating false-positive results, as they do not depend on intestinal motility. However, cross-sectional imaging is significantly less accurate in the evaluation of functional small bowel patency, frequently overestimating the risk of obstruction. In a recent study evaluating the accuracy of MRI for prediction of patency capsule retention in patients with established small bowel CD, the sensitivity and specificity of MR enterography were 92.3% and 59%, respectively. Thus,

if the decision to administer SBCE was based on imaging and not on patency capsule results, at least 40% of the patients would not have undergone SBCE.⁵⁷ Questions about optimal bowel preparation, selection of patients, and the optimal reading protocol remain to be clarified⁷³ and are discussed in more detail later in part 2.

Statement 1.9. ECCO-ESGAR Diagnostics GL [2018]

Upper GI endoscopy is recommended in patients with CD with upper GI symptoms, but not for asymptomatic newly diagnosed adult IBD patients [EL5]

CD involving the upper GI tract [oesophagus, stomach, and duodenum] is almost invariably accompanied by small or large bowel involvement.⁷⁴⁻⁷⁶ Patients who have upper gastrointestinal symptoms such as nausea, dyspepsia, and vomiting will benefit from upper GI endoscopy.⁷⁷ Whether asymptomatic adult CD patients should routinely undergo oesophago-gastroduodenoscopy is still debated. However, a prospective registry reported a higher prevalence of upper GI involvement in asymptomatic CD patients than initially expected,⁷⁷ suggesting a place for a standard gastroscopy at CD diagnosis to correctly evaluate disease extent. When it is difficult to obtain a histological diagnosis of CD, upper GI endoscopy may support the diagnosis, as focal gastritis may be a feature of CD.⁷⁴ Finally, upper GI endoscopy is mandatory in patients with suspected concomitant coeliac disease.⁷⁸

The sensitivity and specificity of radiological imaging techniques in the assessment of upper GI CD are unclear, with publications limited to case reports and small series. Radiological assessment of patients should be reserved only for those patients with CD and upper GI symptoms in whom endoscopic assessment has failed or is incomplete. Radiological assessment of the upper GI tract should not form part of routine diagnostic workup.

Statement 1.10. ECCO-ESGAR Diagnostics GL [2018]

All newly diagnosed CD patients should undergo small bowel assessment [intestinal ultrasound, MR enterography and/or capsule endoscopy] [EL2]

The ileocaecal region is usually visualised adequately endoscopically. The proximal ileum and jejunum can be more difficult to assess. A study by Samuel *et al.* evaluated CD patients with computed tomography [CT] enterography and ileocolonoscopy. Among the group of patients with normal results from ileoscopy, 53.7% had active, small bowel CD. Ileoscopic examination can thus miss CD of the terminal ileum, as the disease can skip the distal ileum or may be confined to the intramural portion of the bowel wall and mesentery.⁷⁹

CT and MRI are both used to assess the small intestine. Both techniques can establish disease extent and activity based on wall thickness and increased intravenous contrast enhancement.⁸⁰ A direct comparison of CT and MRI for the diagnosis of a variety of small intestinal lesions demonstrates high sensitivity and specificity, similar for both techniques.⁸¹⁻⁸³ Due to the absence of radiation, MRI should be preferred over CT, particularly in young patients.⁸¹

A study by Messaris *et al.* demonstrated that routine use of MR enterography can alter the management of patients with ileal or ileocolonic CD. In this study, 64 [53%] of patients had additional medical management for active inflammation, and 16% underwent an operation for complicated CD or medical intractability. The intraoperative findings were consistent with the MRI diagnosis in all surgically treated patients.⁸⁴ Similarly, Mendoza *et al.* demonstrated

that MRI influenced a change in treatment [medical or surgical] in 83 [55.3%] patients. The change in management even affected those patients who were already diagnosed with ileal or ileocolonic CD.⁸⁵

A direct comparison of intestinal ultrasound [IUS] and MRI performed in 234 consecutive suspected CD patients showed a similar diagnostic accuracy in detecting small bowel CD. Sensitivity, specificity, positive predictive value [PPV], and NPV for CD diagnosis were 94%, 97%, 97%, and 94% for IUS and 96%, 94%, 94%, and 96% for MR enterography, respectively. IUS was less accurate than MR enterography in defining CD extent [$r = 0.69$], whereas the concordance in terms of CD location between the two procedures was high [$\kappa = 0.81$]. MR enterography also showed a fair concordance with IUS regarding strictures [$\kappa = 0.82$] and abscesses [$\kappa = 0.88$], with better detection of enteroenteric fistulas [$\kappa = 0.67$].⁸⁶

A UK multicentre trial of 284 newly diagnosed or suspected relapsed Crohn's disease patients showed that MRE had significantly greater sensitivity for small bowel disease extent [presence and location] compared with IUS [80% versus 70%, respectively]. MRE also had significantly greater specificity than IUS [95% versus 81%, respectively]. For detecting the presence of small bowel disease irrespective of location, IUS sensitivity was 92%, compared with 97% for MRE. Sensitivity for active small bowel [SB] disease was significantly greater for MRE than IUS (96% versus 90% [82 to 95]).⁸⁷

A review by Calabrese *et al.* reported that IUS had a 79.7% sensitivity and 96.7% specificity for the diagnosis of suspected CD, and an 89% sensitivity and 94.3% specificity in assessment of patients with known CD with lower accuracy for detecting proximal small bowel lesions. Administration of an oral contrast agent improved the sensitivity and specificity in determining CD lesions.⁸⁸

In a systematic review, the diagnostic yield of SBCE is comparable to MR enterography and IUS, apart from proximal small bowel involvement for which SBCE seems to be superior. The odds ratio [OR] for diagnosis via SBCE versus MR enterography was 0.56 (95% confidence interval [CI] 0.28–1.13; $p = 0.1$) and the OR for SBCE had superior diagnostic yield for proximal small bowel disease with an OR of 2.62 [95% CI 1.10–6.53; $p = 0.03$].⁵⁶

A range of factors, including local availability and expertise, determines the choice of small bowel imaging modality. For initial assessment and exclusion of CD, SBCE, IUS, MR enterography, and CT enterography are superior to small bowel follow-through [SBFT].^{83,89} Cross-sectional imaging of the small bowel should be performed in preference to SBCE where clinical symptoms indicate obstructive or stricturing small bowel CD.

Statement 1.11. ECCO-ESGAR Diagnostics GL [2018]

The presence of at least three small intestine ulcers in SBCE highly suggests a diagnosis of CD, provided the patient has not been using non-steroidal anti-inflammatory drugs [NSAIDs] for at least 1 month before the test [EL4]

Statement 1.12. ECCO-ESGAR Diagnostics GL [2018]

In patients with negative endoscopy and suspicion of CD on MRI or small bowel capsule endoscopy, device-assisted enteroscopy may be performed if diagnosis needs to be confirmed endoscopically and histologically [EL3]

Several small studies have evaluated the utility of SBCE for reclassification of patients with UC and with unclassified IBD, and reported varying reclassification rates. Although a normal SBCE cannot

exclude CD, the presence of small bowel pathology that is consistent with CD enables reclassification.^{90–95} In a study by Mow *et al.*, multiple ulcerations [≥ 3 ulcerations] were considered diagnostic for CD and were observed in 26% of cases.⁹⁰ Similar data have been found by Monteiro *et al.*; 25% of patients with unclassified IBD were found to have small bowel involvement consistent with CD. Still, 37% of patients remained IBD unclassified during further follow-up.⁹⁵

Statement 1.13. ECCO-ESGAR Diagnostics GL [2018]

Patients with unexplained perianal abscesses or complex fistulae should be investigated for CD [EL4]

Perianal manifestations result in fistula and abscess formation in 21% to 54% of CD patients^{96–99} and more frequently [up to 41%] in patients with isolated colonic involvement compared with isolated ileal disease [12%].⁹⁷ A thorough baseline clinical examination of the perianal area should be performed in all newly diagnosed patients at ileocolonoscopy, as symptoms can be initially very mild.

Diagnosis and classification of perianal disease are usually achieved via a combination of both clinical and imaging findings.¹⁰⁰ Fistulae can be considered 'simple' if they are low [of superficial or low intersphincteric or low transsphincteric origin], have a single external opening, and lack evidence of abscesses, rectovaginal fistulas, or anorectal strictures. 'Complex' fistulas are high [of high intersphincteric or high trans-sphincteric or extrasphincteric or suprasphincteric origin], may have multiple external openings, and can be associated with the presence of abscesses, rectovaginal fistulae, or anorectal strictures.¹⁰¹

A perianal abscess may be the first presentation of CD in a healthy individual.¹⁰² Patients with an unexplained fistula and suspicion of CD should therefore undergo ileocolonoscopy to assess mucosal inflammation in the ileum or colon that may indicate CD.¹⁰³ In case of a negative conventional workup including ileocolonoscopy, capsule endoscopy can provide an incremental diagnostic yield of 24%.¹⁰⁴

Proctosigmoidoscopy or ileocolonoscopy [if the proximal colon also needs evaluation] should be performed routinely in all patients with perianal CD to assess disease extent, severity of luminal inflammation, and presence of internal openings, and to exclude complications such as strictures and cancer.^{103,105} Proctitis is a known risk factor of persistent non-healing fistula tracts and increased colectomy rates,¹⁰⁶ and often indicates complex fistulae and associated complications such as abscesses.¹⁰⁰ Undiagnosed extensions and abscesses are major causes of recurrent disease after attempted surgical cure.¹⁰⁰

Chapter 2: Monitoring known IBD

2.1. Monitoring therapeutic success

Statement 2.1.1. ECCO-ESGAR Diagnostics GL [2018]

Response to treatment in active ulcerative colitis [UC] should be determined by a combination of clinical parameters, endoscopy, and laboratory markers such as C-reactive protein [CRP] and faecal calprotectin [EL1]

Statement 2.1.2. ECCO-ESGAR Diagnostics GL [2018]

In patients with UC who clinically respond to medical therapy, mucosal healing [MH] should be determined endoscopically or by faecal calprotectin [FC] approximately 3 to 6 months after treatment initiation [EL5]

Statement 2.1.3. ECCO-ESGAR Diagnostics GL [2018]

Endoscopic reassessment in UC should be considered in case of severe relapse, persistent disease activity, new unexplained symptoms, and before switch of therapy [EL5]. Sigmoidoscopy might be sufficient in most patients [EL5]

There is no gold standard in determination of therapeutic success in ulcerative colitis [UC]. For follow-up of active disease in UC, endoscopy remains the reference standard. As UC involves the mucosa continuously from the rectum, colonoscopy with biopsies is still the reference standard for assessment of disease extent. However, flexible sigmoidoscopy is adequate for assessment of disease activity in most patients.

Several studies determined the benefit of mucosal healing [MH] in patients with UC. In a prospective Norwegian cohort, MH was associated with reduced risk of colectomy in UC and lower inflammation at 5 years.¹⁰⁷ These findings could be confirmed by a recent meta-analysis.¹⁰⁸ In this meta-analysis, patients with MH had a pooled odds ratio of 4.50 for achieving long-term [after at least 52 weeks] clinical remission [95% confidence interval [CI] 2.12–9.52], 4.15 for remaining free of colectomy [95% CI 2.53–6.81], 8.40 for achieving long-term MH [95% CI 3.13–22.53], and 9.70 for achieving long-term corticosteroid-free clinical remission [95% CI 0.94–99.67], compared with patients without MH. In accordance with these findings, an international consensus panel recently recommended MH as an important therapeutic goal for UC.¹⁰⁹

There is no evidence-based consensus of when best to reassess disease activity after a change in therapy. However, in most induction studies MH has been determined approximately 2 to 3 months after starting treatment.¹¹⁰ Although this appears to be an appropriate time point to reassess, the exact timing will depend upon clinical necessity and the chosen therapy.

There is a growing need to replace invasive diagnostics by surrogate non-invasive markers. Blood parameters are convenient. However, C-reactive protein [CRP] has low sensitivity in determining active mucosal disease in UC, with serum levels frequently within normal limits even in active disease.¹¹¹ The exception is in patients with elevated CRP levels during disease flare, for whom CRP might be used as a suitable follow-up. A more accurate surrogate marker of MH is faecal calprotectin [FC]. There is a strong correlation between endoscopic inflammation and FC in UC. In a study with 52 patients, FC correlated with clinical Mayo score [$r = 0.63$; $p < 0.0001$].¹¹² This correlation was strengthened by adding the endoscopic subscore [$r = 0.90$; $p < 0.0001$]. The endoscopic subscore also correlated independently with FC [$r = 0.96$; $p < 0.0001$]. The use of FC as a surrogate marker for MH in UC has also been demonstrated in several other studies.^{113,114}

Another potential non-invasive alternative for monitoring active UC is intestinal ultrasound [IUS]. In four studies that assessed the diagnostic accuracy of IUS in a total of 74 patients, sensitivities ranged from 48% to 100% and specificities ranged from 82% to 90%. Current evidence indicates that the diagnostic accuracy of IUS in UC is also related to disease site, as sensitivity is high for sigmoid or descending colonic disease [reaching 97%]¹¹⁵ but low for rectal disease.¹¹⁶ The utility of IUS for assessing activity has been assessed in a study including 38 IBD patients [12 UC] and six controls.¹¹⁷ The mean colonic wall thickness was 3.2 mm in both Crohn's disease [CD] and UC, being higher in moderately [$n = 46$; $p < 0.001$] or severely inflamed bowels [$n = 20$; $p < 0.001$] compared with normal segments [$n = 58$]. There are only few studies that address the use of IUS for follow-up of patients with active UC under treatment. In a

recent study of 83 patients with moderate-to-severe UC, endoscopic and IUS severity were graded 0 to 3 at entry according to validated scores.¹¹⁶ Of the recruited patients, 74 patients who were clinically responsive to steroids were followed up with repeated colonoscopy and IUS at 3, 9, and 15 months from recruitment. A high and consistent concordance was demonstrated between endoscopic and IUS scores [weighted κ between 0.76 and 0.90]. Thus, IUS may be a potential alternative to endoscopy to assess response to treatment of severe UC.

As IUS has significant limitations in detecting rectal disease, proctitis cannot be assessed by IUS as an alternative to sigmoidoscopy. Whereas FC has been shown to be useful for follow-up of proctitis during treatment with mesalamine suppositories 8 weeks after treatment, the absolute levels of FC in ulcerative proctitis are low.¹¹⁸ Transrectal endosonography studies show that mucosal thickness correlates with endoscopic disease activity and a decline in bowel wall thickness, which can be determined a few weeks after treatment in patients with active UC.¹¹⁹

No study has compared the combination of different parameters such as IUS plus FC in active UC, even though it is conceivable that combinations might enhance sensitivity. MR colonography [MRC] can also assess inflammation with relatively high accuracy. In the largest series of 50 patients who underwent both MRC and endoscopy, the segmental simplified MRC index strongly correlated with the modified Baron score [$r = 0.81$, $p < 0.001$]. MRC was also able to detect endoscopic inflammation and severe lesions with high diagnostic accuracy [sensitivity 87% and 83%, specificity 88% and 82%, area under the curve 0.95 and 0.91, $p < 0.001$, respectively]. MRI may provide useful information on wall thickening, oedema, polyps, and extraluminal complications.^{120–122} MRI, especially when implemented with diffusion-weighted sequences, has high diagnostic accuracy in detecting active inflammation. Oussalah *et al.* investigated 35 patients with UC, and reported a sensitivity and specificity of 89.47% and 86.67%, respectively.¹²³ Moreover, the accuracy of the diffusion-weighted imaging hyperintensity for detecting colonic inflammation was greater in UC than in CD [$p = 0.004$].

Statement 2.1.4. ECCO-ESGAR Diagnostics GL [2018]

Clinical and biochemical response to treatment of Crohn's disease [CD] should be determined within 12 weeks following initiation of therapy [EL2]. Endoscopic or transmural response to therapy should be evaluated within 6 months following initiation of therapy [EL5]

Statement 2.1.5. ECCO-ESGAR Diagnostics GL [2018]

Endoscopic or cross-sectional reassessment in CD should be considered in cases of relapse, persistent disease activity, new unexplained symptoms, and prior to switch of therapy [EL5]

Mucosal healing

There is no reference standard for determining therapeutic success in CD. Clinical symptoms as scored by the CD Activity Index [CDAI] are not a reliable measure of the underlying inflammation. An increasing body of evidence suggests that MH may change the natural course of CD by decreasing relapse rates, hospitalisation rates, and the need for surgery.^{124–126}; as such, evaluation should be aimed at detecting this

endpoint, or at least at assessing a reliable surrogate marker of MH. MH can be directly visualised endoscopically. Cross-sectional imaging and non-invasive serological and faecal surrogate markers may however provide an indication, especially important when assessing parts of the bowel that are difficult to reach endoscopically.

The time interval of when to evaluate MH endoscopically can be inferred somewhat from trial data. However, studies have seldom been designed to directly evaluate the best point for reassessment and, as such, inferences regarding optimal timing for re-evaluation must be taken with care. Any recent change in therapy must also be considered. For example, it is recognised that the anti-integrin antibody vedolizumab takes longer than steroids or anti-TNFs for MH to occur. A sub-study of the SONIC trial demonstrated that MH along with steroid-free clinical remission at Week 26 was strongly predictive of steroid-free clinical remission at Week 50 [82%].¹²⁷ The EXTEND trial demonstrated that MH at 12 weeks correlated well with MH at 52 weeks.¹²⁶ Thus, it appears that 12 to 24 weeks is a sensible time scale for re-evaluation of MH.

The degree of mucosal inflammation may differ between segments of the digestive tract¹²⁸; the need for panenteric evaluation remains to be determined. In a retrospective analysis of the SONIC trial, CDAI scores and CRP values at baseline and at Week 26 were analysed from 188 CD patients who had evaluable ileocolonoscopy with evidence of mucosal ulceration at baseline.¹²⁹ Half of the patients treated with azathioprine or infliximab [or both] in clinical remission had endoscopic or CRP evidence [or both] of residual active CD, whereas other patients with endoscopic and CRP normalisation had persistent clinical symptoms. In a retrospective study of 201 patients with CD, the predictors of medium-term clinical efficacy and MH during adalimumab therapy were evaluated.¹³⁰ Clinical efficacy and normalised CRP at Week 12 were associated with medium-term clinical efficacy and mucosal healing during adalimumab therapy, whereas need for combined immunosuppression at induction and smoking status were predictors for non-response. Thus, correlation between CRP and MH is variable. Several studies indicate that FC correlates well with colonic inflammation in CD and might therefore be used as a surrogate marker.^{62,112} Importantly, although initial studies suggested that FC may be less sensitive in isolated small bowel disease, a recent meta-analysis demonstrated that the diagnostic yield of FC is significant for detection of active disease in the small bowel, with a negative predictive value [NPV] of 90% for the cut-off value of 50 µg/mL.⁶²

Transmural healing – Role of MRI, CT, and IUS

There is no reference standard for CD activity, and any kind of diagnostic modality [including endoscopy, MRI, laboratory parameters, or IUS] can only be used as a surrogate marker in this situation. CD is a transmural process; thus full-thickness bowel healing or remodelling could be important endpoints.

Various studies have assessed the value of cross-sectional imaging techniques for therapeutic monitoring in CD affecting the small and large bowel. These studies assessed IUS,^{131–136} CT,¹³⁷ or MRI.^{138–140}

The role of IUS as a non-invasive and inexpensive imaging modality for determining the treatment response of transmural inflammation in CD has been evaluated in different studies. The utility of IUS for assessing activity and drug response has been compared with colonoscopy,¹¹⁶ with high concordance [weighted κ between 0.76 and 0.90]. For example, a prospective study performed on 24 consecutive patients with CD used IUS to assess changes induced by anti-TNF therapy and its relationship with clinical and biological response.¹⁴¹ Parameters were measured 1 week before induction

treatment and 2 weeks thereafter. Anti-TNF therapy led to a significant reduction in bowel wall thickness [$p = 0.005$] and Doppler flow [$p = 0.02$], leading to the disappearance of IUS changes in 50% of the patients. However, sonographic normality was only achieved in five out of 17 patients [29%] with a clinical and biological response, and could not differentiate between those with and without clinical and biological response [$p = 0.27$]. A more recent prospective trial evaluated IUS features in patients with CD after treatment with biologics, using ileocolonoscopy as a reference standard.¹⁴² In this trial, normalisation of the IUS parameters could be observed in 62.8% of the patients, with a significant correlation compared with ileocolonoscopy [$\kappa = 0.76$; $p < 0.001$]. Some authors suggest that Contrast-enhanced ultrasound (CEUS) might be useful to determine treatment outcome shortly after initiating treatment with biologics.¹³³ In a study on 133 CD patients, transmural healing could be observed in approximately 25% of patients.¹³⁴ Most of the patients received anti-TNF therapy. In a paediatric CD study, 32 patients were included and followed up by IUS and ileocolonoscopy 9 to 12 months after treatment initiation. Patients with MH showed a significant decrease of bowel wall thickness and disease extension.¹³⁵ In a prospective multicentre longitudinal study of 51 patients with active CD, all patients underwent a clinical assessment and sonographic examination at baseline, 12 weeks after treatment initiation, and after 1 year of treatment.¹³⁶ Improvement at 52 weeks was more frequent in patients with improvement at the end of induction [12 weeks] compared with patients who did not improve [85% versus 28%; $p < 0.0001$]. The authors concluded that sonographic response after 12 weeks of therapy predicts 1-year sonographic response. A large multicentre trial including 243 patients from 50 centres in Germany has recently been conducted to determine the role of IUS for monitoring treatment response.¹³² In this trial, CD patients with an acute disease flare received anti-inflammatory treatment. Almost all sonographic parameters determined during IUS [including bowel wall thickness, vascularisation parameters, fibro-fatty proliferation] showed a highly significant decrease [$p < 0.001$ in all groups] at different sites. Interestingly, reduction of bowel wall thickness was more pronounced in the colon compared with the ileum. Improvement of ultrasound parameters correlated with laboratory parameters such as CRP.¹³² Based on current studies, IUS seems to be a valuable method to determine transmural healing in CD, with bowel wall thickness and vascularisation appearing to be the most relevant parameters.¹⁴³

The value of CT was assessed in a retrospective North American study on 63 infliximab-treated patients with CD.¹³⁷ Of 105 lesions, 21 [20%] were colonic. Poor-to-fair correlation was found between CT enterography features of response and improved clinical symptoms [κ 0.26], improved endoscopic appearance [κ 0.07], and reduction of CRP [κ 0.30]. When comparing responders [complete and partial] with non-responders, only the presence of the ‘comb sign’ on the index CT enterography was predictive of radiological response [$p = 0.024$]. Even though CT in principle might be a suitable method to determine disease activity in CD, it should be noted that CT, due to radiation safety, should not usually be used for monitoring disease activity if MRI or IUS is available.

In terms of responsiveness and reliability, different studies have shown that MRI has a high accuracy for monitoring therapeutic responses using endoscopy as a reference standard.^{138–140} In a recent study, 48 patients with ileocolonic CD were prospectively evaluated with MR enterography in comparison with ileocolonoscopy.¹³⁸ MR enterography determined ulcer healing with 90% accuracy and endoscopic remission with 83% accuracy. The mean CD Endoscopic Index Of Severity [CDEIS] and Magnetic Resonance Index Of Activity

[MaRIA] scores significantly changed at Week 12 in segments with ulcer healing, based on endoscopic examination [CDEIS, 21.28 ± 9.10 at baseline versus 2.73 ± 4.12 at 12 weeks; $p < 0.001$; and MaRIA, 18.86 ± 9.50 at baseline versus 8.73 ± 5.88 at 12 weeks; $p < 0.001$]. The authors concluded that the MaRIA score is a valid, responsive, and reliable index assessing response to therapy in patients with CD. In a retrospective study with 50 patients, MRI inflammation scores during anti-TNF therapy improved in 29 of 64 lesions [45.3%], remained unchanged in 18 of 64 lesions [28.1%], or deteriorated in 17 of 64 lesions [26.6%] over time. In the anti-TNF responder group, the mean intestinal inflammation score of all lesions improved from 5.19 to 3.12 [$p < 0.0001$]. The mean inflammation scores in stenotic lesions in anti-TNF responders also improved significantly, from 6.33 to 4.58 [$p = 0.01$]. In contrast, the mean inflammation scores did not change significantly [$5.55\text{--}5.92$; $p = 0.49$] in non-responders. Diagnostic accuracy of anti-TNF response on MRI was 68%.¹³⁹ The authors conclude that MRI can be used to guide the optimal use of TNF antagonists in daily clinical practice. In a prospective single-centre trial with 27 patients treated with anti-TNF [infliximab or adalimumab], the mean SES-CD and MaRIA scores significantly changed at Week 26 [SES-CD: 14.7 ± 8.9 at baseline versus 4.4 ± 4.6 at 26 weeks; $p < 0.001$; MaRIA: 41.1 ± 14.8 at baseline versus 32.8 ± 11.7 at 26 weeks; $p < 0.001$]. The overall MaRIA correlated with endoscopic score and with clinical activity [CDAI] both at baseline and at Week 26 [$p < 0.05$]. The authors conclude that the MaRIA has a good correlation with SES-CD, a high accuracy for prediction of endoscopic mucosal healing, and is a reliable indicator to monitor the use of TNF antagonists in patients with CD.¹⁴⁰

In a systematic review and analysis to identify MRE variables used to describe inflammation and damage wall enhancement, mucosal lesions and wall T2 hyperintensity were the most consistently useful for inflammation [most sensitivities >80% and specificities >90%].¹⁴⁴

In addition, in a retrospective analysis of 150 CD patients, having either had a pre- and post-therapy CTE or MRE radiological response to medical therapy was associated with significant reductions in long-term risk of hospitalisation, surgery, or corticosteroid usage among small bowel CD patients.¹⁴⁵

As MR enterography and IUS appear to be of similar value for monitoring transmural healing in CD during treatment, which imaging modality to use depends on local availability and expertise.

Video-capsule endoscopy

As endoscopic access of the small bowel is more difficult, response to treatment should either be determined by IUS or MR enterography or by capsule endoscopy. The superiority of small bowel capsule endoscopy [SBCE] compared with other imaging modalities to determine small bowel disease in CD has been described in different studies.¹⁴⁶

Recent clinical trials have evaluated the potential role of SBCE for assessment of MH in the small bowel.^{147–149} These trials used quantitative scores such as the Lewis Score¹⁵⁰ or the Capsule Endoscopy CD Activity Index [CECDAI], analogous to the application to ileocolonoscopy of the CDEIS or the simple endoscopic score for CD. In a case-control study, 40 patients with known or suspected CD were included and underwent SBCE.¹⁴⁷ When patients achieved clinical response [after at least 1 month of treatment] they underwent a second SBCE, with evaluation of the same parameters. The numbers (mean \pm standard error of the mean [SEM]) of large ulcers before and after treatment were 8.3 ± 1.4 and 5 ± 0.8 , respectively (mean difference 3.3 ± 1.2 , 95% confidence interval [CI] $0.8\text{--}5.9$; $p = 0.01$).

The other variables did not improve significantly. In another study, the CECDAI index was used to assess ileitis severity. All parameters were reassessed at Week 52. In total, 108 capsule procedures were performed on 43 patients. Based on the CECDAI, 39 patients [90%] exhibited active small bowel CD at baseline, with 28 patients [65%] undergoing assessment at 52 weeks. In total, 12 patients [42%] achieved complete MH and deep remission at the 52-week assessment [95% CI -0.62 to -0.22 ; $p < 0.0001$].¹⁴⁸ SBCE has a significant impact on disease management; in the largest retrospective series of patients with established CD that were evaluated with SBCE, a change in management was suggested in 52% of 187 patients.⁶⁰

Statement 2.1.6. ECCO-ESGAR Diagnostics GL [2018]

In the absence of credible evidence to support the best modality to assess response to treatment in upper GI disease of CD, endoscopy is recommended as the preferred method [EL5]

Data on imaging in upper GI CD and in particular on monitoring disease are sparse and sizeable series are unavailable, with essentially absent data for the stomach. Cross-sectional imaging may reveal ulcers or strictures in oesophageal CD, but superficial lesions are difficult to detect, underscoring the importance of endoscopy in the diagnosis of oesophageal CD. Endoscopy with tissue biopsy is useful to exclude other common oesophageal disorders. The most commonly described findings on endoscopy include aphthous ulcers, superficial erosions, and late-stage stricture development and cobblestoning of the mucosa.^{151,152} One study discussed the application of various methods to diagnose various inflammatory conditions of the oesophagus.¹⁵³

Although IUS and MRI seem to be feasible tools to determine disease activity of CD in the duodenum and stomach, there are no convincing data that prove their value in disease monitoring. Upper GI involvement should therefore be primarily monitored by the reference standard endoscopy.

Statement 2.1.7. ECCO-ESGAR Diagnostics GL [2018]

Extramural complications in CD [such as fistulae and abscesses] should be monitored by cross-sectional imaging, including intestinal ultrasound [IUS] [EL2] or MRI [EL2] [or both] in combination with clinical and laboratory parameters [EL5]

Whereas a variety of studies have shown good sensitivity and specificity of cross-sectional imaging to assess fistulae and abscesses, there are only few studies that address the follow-up of these extramural complications after treatment. The sensitivity of cross-sectional imaging modalities such as MRI, IUS, and CT to determine extramural complications has been shown to be high in a recent meta-analysis, with sensitivity between 84% and 93% and specificity between 90% and 93%, as discussed above.^{81,154} Although CT is accurate for follow-up of mural and extramural complications in CD patients, CT is not recommended for monitoring patients with active disease under treatment, due to radiation safety.¹⁵⁵ Although the dose can be reduced substantially with state-of-the-art low-radiation-dose CT scanners, the use of non-ionizing radiation techniques is preferable, considering the usually young age of these patients. Thus, CT should be used judiciously, ideally only in the emergency setting and if IUS and MRI are unavailable.

Statement 2.1.8. ECCO-ESGAR Diagnostics GL [2018]

Perianal CD should be reassessed by clinical evaluation in combination with endoscopic examination of the rectum plus MRI [EL1]. Transrectal ultrasonography [TRUS] in the absence of anal stenosis [EL1] or transperineal ultrasonography [TPUS] [EL2] might be used instead of MRI

Evaluation of perianal CD and fistula closure is primarily achieved with clinical evaluation. The definition of fistula healing varies in the literature and there is no consensus on when a first or definitive evaluation of fistula healing should be performed.¹⁵⁶ The Perianal Disease Activity Index [PDAI]¹⁵⁷ is a clinical scoring system that has been used and validated in clinical studies both at diagnosis and to measure treatment response. Fistula drainage assessment has been used in several clinical trials of medical therapy,¹⁵⁸⁻¹⁶⁰ but is very much investigator-dependent and has not been validated in large studies. A single retrospective study has evaluated the PDAI scoring system, where high scores predicted short-term surgical outcome, but this has not since been validated.¹⁶¹

MRI classifications of fistula severity have been proposed, such as the system published by Van Assche *et al.*¹⁶² Thus far, this system is of limited use outside clinical trials. MRI is increasingly used to assess fistula healing, particularly during medical therapies.¹⁶²⁻¹⁶⁴ Various MRI classifications have been proposed, including the Van Assche Score,¹⁶² which considers the number of fistulae, localisation, extensions, T2 hyperintensity, abscesses, and rectal involvement. Assessment of dynamic contrast enhancement has also been proposed as a means to monitor fistula activity.¹⁶⁵ It has been shown that fistulae may reopen after therapy cessation, and studies using MRI findings as a more stringent endpoint of deep fistula healing suggest that MRI^{162,164,166} and endo-anal ultrasound^{167,168} may be useful for identification of fistulae that show external closure but retain an internal fistula tract. This suggests that imaging assessment of deep healing is superior to simple clinical evaluation, although long-term comparative studies are lacking.

Despite the lack of relevant studies evaluating the role of MRI for the specific assessment of patients during and after therapy, several comparative studies have been performed evaluating ultrasound and MRI in perianal fistula diagnosis in CD. In most of these studies, MRI seems to be the method of choice. Schwartz *et al.* compared examination under anaesthesia [EUA], MRI, and transrectal ultrasonography [TRUS], and demonstrated a diagnostic accuracy of 91%, 87%, and 91%, respectively.¹⁶⁹ Buchanan *et al.* performed a large prospective clinical trial comparing preoperative digital rectal examination, endoscopic ultrasound, and body-coil MRI for the preoperative assessment of anal fistulae. According to their results, MRI was superior to both methods for abscess detection and accuracy in fistula classification [90% of patients correctly classified by MRI, 81% by TRUS, and 61% by EUA].¹⁷⁰ In a recent meta-analysis, the sensitivity of MRI and of TRUS to determine perianal CD was 87% for both imaging modalities, and specificity was 69% versus 43%, respectively.¹⁷¹ A recent consensus suggested a combination of different imaging modalities for diagnostic use during perianal CD.¹⁷²

MRI may therefore be slightly superior to TRUS for determining perianal disease activity. However, use of the adequate imaging modality also depends on local availability and expertise.

If MRI is not available and TRUS is either not available or unfeasible due to pain, transperineal ultrasonography [TPUS] is an alternative, although its sensitivity is lower than TRUS. In a recent study investigating 46 patients with perianal CD, 53 fistulae detected by

Statement 2.1.9. ECCO-ESGAR Diagnostics GL [2018]

Therapeutic drug monitoring might be beneficial in CD and UC in patients with non-response to thiopurines [EL3] or anti-TNF therapy [EL2]. Drug level monitoring is mandatory during treatment with calcineurin inhibitors [EL2]

TRUS were correctly classified by TPUS in 45 cases, reaching a sensitivity of 84.9%.¹⁷³

Primary non-response and secondary loss of response are common problems during anti-TNF therapy. Loss of response [LOR] to anti-TNF has been shown to be as high as 20% to 40% after the first year of treatment¹⁷⁴ and about 10% in the following years.

In a recent study on 247 patients, it was shown that therapeutic drug monitoring by measurement of anti-TNF trough levels and antidrug antibodies in IBD patients with secondary LOR may lead to therapeutic changes in more than 70% of patients.¹⁷⁵ Several studies have demonstrated that low trough levels and detectable antidrug antibodies are associated with LOR.¹⁷⁶⁻¹⁷⁸ In a recent meta-analysis of 22 trials with 3483 patients, it was shown that high infliximab trough levels correlate with good clinical response and low CRP levels.¹⁷⁹ Similar results have been shown for golimumab¹⁸⁰ and adalimumab.¹⁸¹ Even though the primary endpoint of the TAXIT trial [treatment guidance via infliximab trough level concentration measurements] was not achieved, it was shown that dose escalation in patients with sub-therapeutic levels improved clinical response.¹⁸² The optimal trough level concentration in this study was defined as 3–7 µg/mL. A cohort of 60 CD patients treated with adalimumab has been investigated retrospectively.¹⁸³ Higher adalimumab trough levels were significantly associated with MH [median 14.7 µg/mL in those with MH versus 3.4 µg/mL in those without; $p < 0.001$]. This study suggests that attaining MH alone or a combined outcome of clinical and endoscopic remission is more likely to occur in those patients who achieve an adalimumab trough level of at least 8.14 µg/mL.

In a recent study, primary non-response to anti-TNF therapy in patients with severe UC was associated with faecal loss of infliximab.¹⁸⁴ However, the optimal time points and cut-off levels for trough level measurements to determine primary non-response must still be determined.

Different studies have shown that measurement of thiopurine metabolites, such as 6-mercaptopurine [6-MMP] and 6-thioguanine [6-TGN], might be beneficial in patients with suboptimal response to thiopurines. In a recent study, determination of 6-TGN and 6-MMP levels identified patients with reduced compliance in 11% and raised 6-MMP levels in 10%. Treatment improvement could be achieved in 87% of patients after optimising thiopurine usage.¹⁸⁵

It is likely that as vedolizumab and ustekinumab drug monitoring becomes more easily available, this will also form part of management strategies when treating patients with these agents.

2.2. Monitoring clinically asymptomatic patients**Statement 2.2.1. ECCO-ESGAR Diagnostics GL [2018]**

In patients with IBD who have reached clinical and biochemical remission, monitoring is aimed at early recognition of a disease flare [EL5]. The interval of monitoring should be between 3 to 6 months depending upon duration of remission and current therapy [EL5]. Relapse can be detected with FC before clinical symptoms [EL2]

Figure 1 shows a simplified disease progression pathway in IBD from risk factors to irreversible intestinal fibrosis. The practicality of a given test for IBD monitoring decreases further downstream in the pathway, as the disease becomes more resistant to standard therapy. The ideal monitoring test is non-invasive, simple to conduct, and easily interpretable. Such a test should detect an imminent disease flare [often undetectable by symptom-based reporting alone] and make provision for proactive treatment optimisation [Table 1].

Faecal calprotectin

The utility of FC monitoring in patients with quiescent disease was evaluated in a recently published systematic review.¹⁸⁶ Electronic searches up to April 2016 identified six prospective studies [mostly in UC patients] that met the selection criteria. Since then, an additional five prospective studies in both UC and CD patients were published.^{118,187–190}

Two consecutively elevated FC levels were the best predictor for clinical relapse, but this was investigated systematically in only one study.¹⁹¹ In one of the more recently published studies, patients with both UC and CD provided faecal samples every third month and were prospectively followed until the first clinical relapse.¹⁸⁸ This study revealed that FC levels start rising approximately 3 months before a relapse becomes clinically apparent, and confirmed the observations of the aforementioned systematic review. These findings support the biological implausibility that a single FC measurement at baseline can predict the clinical course over a 12-month period, as suggested in a meta-analysis¹⁹² and more recently by Theede *et al.*¹⁹³

Currently, there is no consensus on the ideal cut-off point for FC monitoring. In clinical trials where response to a new treatment is monitored, a low cut-off point [e.g. 100 µg/g] is frequently used to demarcate the upper limit of the normal FC range. Conversely, in real-life studies, a higher cut-off point is advocated [e.g. 250 µg/g] as an action threshold for adjusting treatment.^{194–197} A prospective evaluation of a monitoring strategy is needed, namely a planned and organised system of repeated FC assessments and subsequent decisions about starting, modifying, or de-escalating therapy, as has been part of the recently published CALM study.¹⁹⁸

A general construct for FC-based disease monitoring in patients with IBD is shown in Figure 2, which illustrates the four phases of disease monitoring.^{199,200} Repeated FC measures are used to longitudinally track changes in a patient's condition over time. In phase I, IBD is suspected but is neither endoscopically confirmed nor treated. In phase II, induction therapy is introduced to achieve disease control, resulting in patient response. Phase III begins with disease remission with continuation of maintenance therapy. The goal of

monitoring in this phase is to detect deviations from the target range, indicating the start of phase IV. In phase IV, therapy is adjusted to re-establish disease control and bring FC levels back to the target range.

When the FC concentration is in the target range, the patient is reassured and advised to retest in 3 months. When the FC concentration is in the action range, the treatment plan is adjusted and re-testing is advised for the next month. In the uncertain range, a test interval of 1 month is advised before progressing to a treatment decision.

C-reactive protein

Serum CRP is an acute-phase reactant that has been used in clinical practice for many years as a general measure of inflammation. In a meta-analysis of cohort and case-control studies that compared the diagnostic accuracy of CRP [index test] with endoscopy [reference standard] in patients with symptomatic IBD, a CRP concentration of ≥5 mg/L appeared to have a high specificity for detecting endoscopic disease activity.¹¹¹ However, the sensitivity was very poor and a negative test does not exclude the presence of a flare. Almost two-thirds of the asymptomatic patients with normalised CRP still had active endoscopic lesions, and consequently an isolated fall in CRP was insufficient reassurance of endoscopic remission.²⁰¹ Repeated CRP measurements in the detection of early postoperative recurrence of CD,²⁰² or in the follow-up of small bowel CD,²⁰³ are inferior to repeated FC measurements.

Statement 2.2.2. ECCO-ESGAR Diagnostics GL [2018]

Asymptomatic patients with abnormal biochemical parameters may have an imminent disease flare. After excluding infection, endoscopic or cross-sectional imaging [or both] should be performed [EL5]

Capsule endoscopy

Recent prospective studies have shown that stool markers such as FC are useful in monitoring inflammation in the small bowel. Increased FC levels with negative findings on conventional endoscopy should trigger further investigations into the presence of active small bowel disease.²⁰⁴ Small bowel CD is in many cases located proximal to the terminal ileum and is therefore inaccessible to conventional ileocolonoscopy. In a considerable proportion of asymptomatic patients with CD, previously unknown new proximal involvement and progression to stricturing or penetrating disease were demonstrated with capsule endoscopy,⁶¹ leading to modifications in the original Montreal classification and consequently to treatment escalation.²⁰⁵ In a prospective

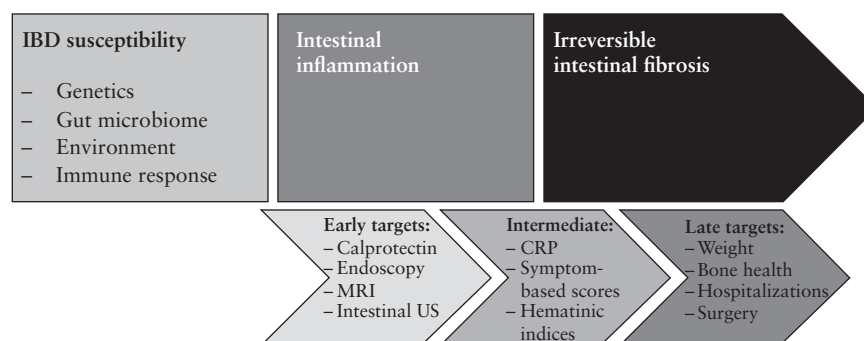


Figure 1. Targets along the disease progression pathway in IBD.

observational cohort of patients with asymptomatic or mildly active small bowel CD, tolerance and preference to MR enterography versus capsule endoscopy were compared. Pre-examination and procedural discomfort was perceived more favourable in capsule endoscopy. The superior tolerability of capsule endoscopy, along with diagnostic features, should be considered when choosing between these two modalities for long-term follow-up.²⁰⁵ A negative FC result in an asymptomatic CD patient should deter the clinician from using additional small bowel imaging techniques.²⁰⁴

MR enterography

MR enterography is not a suitable technique for early recognition of disease recurrence, since aphthoid ulcerations cannot be assessed. As disease severity progresses, MR enterography manifestations become more apparent. Several studies have evaluated the ability of MR enterography to quantify therapeutic response to immunosuppressive therapy, especially in children.²⁰⁶

Intestinal ultrasound

IUS is a non-invasive, widely available technique that does not use ionising radiation and is well accepted and tolerated by patients. Most parts of the large bowel [with the exception of the rectum] and major parts of the small bowel [with the exception of the proximal jejunum] can be visualised by IUS. The advantages of IUS include rapid evaluation of bowel wall thickness and direct visualisation of bowel vascularisation and motility.^{88,207,208} The role of this technique in monitoring patients with asymptomatic CD or UC is not yet clear. More is known about the role of IUS in monitoring response to treatment in CD patients. In a prospective trial that followed 234 CD patients with bowel wall alterations in the terminal ileum or in the colon, follow-up every 3 months showed significant improvements in nearly all ultrasound parameters.¹³² There is good concordance between ultrasound and MR enterography for disease location and activity, and fewer technical difficulties with IUS.²⁰⁹

Statement 2.2.3. ECCO-ESGAR Diagnostics GL [2018]

Before de-escalation or withdrawal of maintenance IBD therapy, it is necessary to assess disease activity using a combination of clinical and biochemical markers and endoscopic and/or cross-sectional imaging, balancing the risks and benefits of withdrawal [EL5]

In a recent meta-analysis of 18 studies, stopping immunomodulatory monotherapy after a period of remission was associated with approximately 75% of patients experiencing a relapse within 5 years after therapy discontinuation.²¹⁰ Approximately 50% of patients who discontinued anti-TNF therapy after combination therapy in this systematic review maintained remission 24 months later, but the proportion decreased over time.²¹⁰ Similar results have been reported in other meta-analyses.^{211,212} The factors that predict relapse after discontinuation of therapy remain controversial.

In a placebo-controlled study by the GETAID group, which included 83 patients in clinical remission under azathioprine, neither the presence of ulcerations nor a CDEIS >0 at ileocolonoscopy before azathioprine discontinuation was predictive of clinical relapse.²¹³ In contrast, in another GETAID trial, Louis *et al.* assessed the risk of clinical relapse after discontinuation of infliximab in 109 patients with CD who were in clinical remission under combined maintenance therapy with infliximab and an immunomodulatory agent.²¹⁴ In their multivariate analysis, the absence of MH was among the factors strongly associated with an increased risk of clinical relapse after infliximab withdrawal [hazard ratio 2.6]. In this study, immunosuppression with azathioprine or methotrexate was continued after infliximab withdrawal. In a recent meta-analysis, the relapse rate 1 year after discontinuation of anti-TNF therapy was 42%, which decreased to 26% when endoscopic remission was also required.²¹¹ Assessment of endoscopic activity in patients with quiescent CD is recommended before discontinuation of treatment is considered.

Table 1. Markers of disease activity for monitoring asymptomatic IBD patients.

	Validity [correlation with gold standard]	Responsiveness to changes in condition	Signal-to-noise ratio [ability to differentiate changes in condition from background variability]	Practicality
Endoscopy	Gold standard	Gold standard	Gold standard	Low Requires bowel preparation and general anaesthesia in children
Faecal calprotectin	Good	Good Rises quickly in case of relapse; falls rapidly with successful treatment	Moderate Risk of false-positive results	High Possible reluctance of patients for repeated stool collection
C-reactive protein	Moderate	Moderate Late position in disease progression pathway	Moderate Risk of false-positive results [acute infections and other inflammatory conditions] and false-negative results [normal CRP despite active disease]	High Quick result; but requires venepuncture
Capsule endoscopy	Good	Good	Moderate Potential over-interpretation of insignificant mucosal lesions	Moderate Requires bowel preparation, but is generally well tolerated
MR enterography	Moderate	Moderate Late position in disease progression pathway	Unknown	Moderate Requires oral preparation for bowel distention, and in children preparation through a nasoduodenal tube
Intestinal ultrasound	Unknown	Good	Unknown	High Non-invasive, widely available, and well tolerated

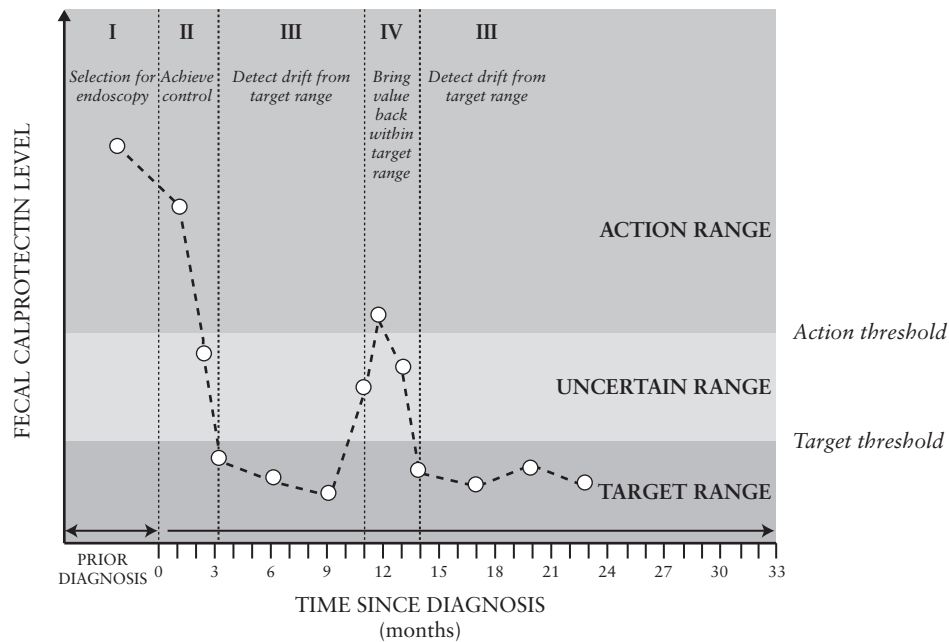


Figure 2. Conceptual model of FC-based monitoring in IBD patients [Copyright 2017 by the Wolters Kluwer Health, Inc. Used with permission].

2.3. Monitoring clinically symptomatic patients

Statement 2.3.1. ECCO-ESGAR Diagnostics GL [2018]

All patients with a suspected new flare of IBD should be investigated for infection, including exclusion of *Clostridium difficile* infection [EL3]

Bacterial infection and *Clostridium difficile* should be excluded in all patients. Diagnostic workup is recommended according to test availability and local practice. Available tests include glutamate dehydrogenase antigen and toxin A/B enzyme immunoassays, bacterial cultures, cytotoxicity assay, and nucleic acid amplification technology tests.

This is particularly important in patients with colonic disease where the diagnostic yield is higher; in one series of paediatric patients with UC [$n = 354$ stool tests], 1.8% of tests were positive for *Salmonella* serotype typhi and 13.6% were positive for *C. difficile* toxin.²¹⁵ Patients with CD have comparatively lower rates of *C. difficile* infection.²¹⁶

In UC, *C. difficile* is associated with poorer outcome, including increased colectomy rates²¹⁷ and increased postoperative complications^{218,219}; detection is thus of direct clinical relevance. Additional interrogation of faeces with polymerase chain reaction [PCR] should not be performed routinely as there is a high rate of detection of bacteria that may not be of clinical significance, even in healthy controls.²²⁰

Parasitic infections are found in about 12% of patients with UC who reside in endemic areas.²²¹ If travel history is suggestive, stool examination for ova cysts and parasites and *Strongyloides* serology should be performed before therapy is escalated. Local protocols regarding testing and transport of stool samples should be followed. Further guidance on management of opportunistic infection can be found in the second European evidence-based consensus on the prevention, diagnosis, and management of opportunistic infections in inflammatory bowel disease.²⁶

A recent meta-analysis revealed that cytomegalovirus [CMV] infection in IBD may be associated with longer disease duration, reduced efficacy of corticosteroid therapy, and increased

colectomy rate.²²² Corticosteroid and thiopurine exposure are associated with reactivation of latent CMV.²²³ However, tissue damage following exposure to immunomodulators is rare.²²⁴ Anti-TNF agents and cyclosporine also do not appear to be associated with adverse outcomes in CMV-positive patients.²²⁵ Therefore, the ECCO guidance on opportunistic infections recommends that testing for CMV should be reserved for steroid-resistant disease.²⁶

Statement 2.3.2. ECCO-ESGAR Diagnostics GL [2018]

Cytomegalovirus [CMV] should be tested in immunosuppressant-resistant UC as CMV is associated with adverse outcomes, including reduced efficacy of therapy and increased colectomy rates [EL3]

CMV disease is most commonly assessed via detection of CMV DNA through PCR or immunohistochemistry of tissue biopsies and blood. The second European evidence-based consensus on opportunistic infection in IBD provides more detailed information on the diagnosis and management of CMV infection.²⁶

Statement 2.3.3. ECCO-ESGAR Diagnostics GL [2018]

Colonoscopy is the modality of choice to assess disease activity of symptomatic colonic CD or UC [EL5]. Cross-sectional imaging is complementary to assess phenotype [EL2], and may be used as an alternative to evaluate disease activity. Sigmoidoscopy should be considered in UC if symptoms suggest an acute severe flare

Ileocolonoscopy provides direct mucosal visualisation of the colon and terminal ileum and allows histological assessment and therapeutic intervention. As such it is the gold standard investigation of large bowel disease.

If assessment of disease location or behaviour is not necessary, FC can be used to evaluate activity from the colon to the small bowel.^{62,204,226–229} Studies have shown good correlation [$r > 0.8$] with endoscopic disease activity in both CD and UC.^{230,231}

If acute severe UC is suspected, endoscopic evaluation should be limited to flexible sigmoidoscopy, as discussed previously in this guideline.

MR enterography^{232–237} of the colon, capsule endoscopy,^{238–240} and IUS¹¹⁵ can also be considered for assessment of disease extent and phenotype in individuals reluctant to undergo endoscopic evaluation. In a UK multicentre trial, IUS had superior sensitivity compared with MRE for colonic disease presence in newly diagnosed patients [67% versus 47%, respectively].⁸⁷

Statement 2.3.4. ECCO-ESGAR Diagnostics GL [2018]

Symptomatic small bowel disease can be investigated with MR enterography, IUS, and/or small bowel capsule endoscopy [SBCE] [EL2]

MR enterography, IUS, and SBCE are all sensitive and specific investigations of symptomatic small bowel disease. The decision on which investigation is ‘first line’ is based upon local availability and expertise.

MR enterography allows assessment of the small bowel without radiation exposure.²⁴¹ The presence of wall oedema, contraction frequency,²⁴² ulcers, and extramural signs such as fat stranding and lymphadenopathy, make MR enterography somewhat informative of whether the abnormalities detected are more inflammatory or fibrotic.^{242–245} However, it should be noted that no imaging modality can fully assess whether a stricture is inflammatory or fibrotic in nature. MR enterography is also safe and well tolerated in paediatric populations.^{246–248} A recent meta-analysis of 27 studies [19 included in pooled analysis] showed MRI to have a sensitivity of 0.88 [95% CI 0.86–0.91] and a specificity of 0.88 [95% CI 0.84–0.91].²⁴⁹ The studies included both MR with oral contrast solution [MR enterography] or contrast administered by nasojejunal tube insertion [MR enteroclysis]. MRI is perhaps superior to IUS in assessing disease extent⁸⁶ and leads to changes in clinical management following investigation²⁵⁰; MRI increases scores of disease location [L] and disease behaviour [B] of the Montreal classification in over 20% of patients.²⁵¹

MR enteroclysis is not significantly more sensitive or specific than MR enterography.²⁵² MR enteroclysis is also less well tolerated than MR enterography²⁵³ and requires minimal radiation exposure for fluoroscopic nasojejunal placement.²⁵⁴ Accordingly, MR enteroclysis is not routinely recommended.

IUS may be available immediately within the clinical setting; if this investigation is sufficient to confirm active disease it may preclude the need for further investigation. The sensitivity and specificity of IUS can be enhanced with contrast studies. Small intestine contrast ultrasound [SICUS] entails administering oral contrast and enables a greater rate of detection of small bowel lesions than by standard IUS,^{255,256} and in particular enables greater detection of strictures and associated dilatation. SICUS shows sensitivity and specificity comparable to MR enterography and CT enterography.^{257–259} In one study, SICUS was shown to be more sensitive in the proximal small bowel [92% versus 75%], similar within the proximal and mid ileum, and less specific within the terminal ileum.²⁶⁰ One study showed SICUS to be more sensitive and specific than CT enteroclysis.²⁶¹ The rates of detection of small bowel complications [such as strictures] are comparable to MR enterography.²⁵⁸ CEUS may facilitate differentiation between inflammatory and fibrotic strictures.²⁶² In the recently published METRIC trial, both MRE and IUS had a high sensitivity for detecting small bowel disease presence. However, the sensitivity of MRE for small bowel disease extent (80% [95% CI 72–86]) and presence [97%^{91–99}] were significantly greater than that of IUS [70%^{62–78} for disease extent, 92%^{84–96} for disease presence]: a 10% [95% CI 1–18; $p = 0.027$] difference for extent, and 5% [1–9; $p = 0.025$] difference for presence.⁸⁷

Most studies show the diagnostic accuracy of SBCE to be comparable to MR enterography, CT enterography, and IUS in CD,^{56,263–267} although a 2017 meta-analysis demonstrated superior detection of proximal small bowel disease compared with MR enterography (odds ratio [OR] 2.79, 95% CI 1.2–6.48).⁵⁶ This is in comparison with MR enterography, CT enterography, barium studies, and IUS.⁸⁹ Clinically, the use of SBCE is associated with earlier escalation of therapy.²⁶⁸ However, the benefits of this investigation are somewhat offset by a small risk of capsule retention; even with use of patency capsule in patients deemed to be at risk, the rates of capsule retention range from 1.5% to 2.1%.⁶⁰ The outcome of the retained capsule varies between studies; approximately 85% are asymptomatic and 15% result in partial or complete small bowel obstruction. The latter generally requires surgical management. The former can sometimes be retrieved with small bowel enteroscopy or managed conservatively.²⁶⁹ Routine use of a patency capsule has not been shown to reduce the risk of retention in the absence of risk factors. Patients who benefit from patency capsules include those with stricturing or penetrating disease phenotypes.²⁷⁰ Cost analyses suggest that SBCE is cost-effective²⁷¹ and frequently leads to changes in therapy.²⁷²

Barium studies, in particular barium follow-through, are still used in some centres for suspected active small bowel CD.^{273,274} However, sensitivity and specificity are less than those of MR enterography, IUS, or SBCE. Furthermore, radiation exposure also makes barium studies less appealing.²⁷⁵ This is particularly true in paediatric assessment.²⁷⁶ Accordingly, ECCO-ESGAR discourages barium studies unless local facilities preclude alternatives.

CT should largely be reserved for the emergency setting due to radiation exposure. However, low-radiation CT enterography yields results comparable to full-dose CT when evaluating CD. Accordingly, low-radiation CT enterography may be an alternative when local resources preclude alternatives or in older patients where radiation exposure is of less concern. When considering the efficacy of CT, the diagnostic yield of CT enterography is similar to that of MR enterography.^{80,277,278} Indeed, several studies comment that CT yields images of higher spatial resolution^{279–281} and that there is greater agreement between radiologists when interpreting CT.²⁷⁷ CT is often the only cross-sectional abdominal imaging modality available outside standard working hours, and as such is widely used in the emergency setting. CT has a high detection rate of complications, including perforation, strictures, and abscesses.²⁸¹

Studies of positron emission topography [PET] are limited. At present, PET does not appear to detect significantly more lesions than CT enterography²⁸² or MR enterography alone.²⁸³ Leukocyte scintigraphy has been shown to detect inflammatory lesions not otherwise shown prior to laparotomy. However, there is insufficient evidence to routinely include this test in clinical practice.²⁸⁴

Non-invasive evaluation of symptomatic IBD includes measurement of blood and stool inflammatory markers and measurement of parameters indicative of malabsorption. The use of non-invasive markers to assess disease activity is largely covered elsewhere. In brief, FC is a more sensitive marker of disease activity than haemoglobin, CRP, or albumin.^{285,286} In symptomatic disease, FC can be used to evaluate activity from the colon to the small bowel.^{62,204,226–229} Studies have shown good correlation [$r > 0.8$] with endoscopic disease activity in both CD and UC.^{230,231} One of the main drawbacks of indirect markers is their limited information on disease phenotype and potential complications.

Statement 2.3.5. ECCO-ESGAR Diagnostics GL [2018]

Balloon-assisted enteroscopy can be used for diagnostic evaluation or endoscopic intervention [or both] throughout the small bowel [EL3]

Balloon-assisted enteroscopy allows direct mucosal visualisation of the entire small bowel. Unlike other imaging modalities, balloon-assisted enteroscopy also enables the taking of biopsies, therapeutic intervention throughout the small bowel,²⁸⁷⁻²⁸⁹ and interventions to manage bleeding. One study showed a change in management in 75% of patients who underwent this investigation.²⁹⁰ However, this examination is time-consuming and requires patient sedation. The risk of perforation is 0.12% without therapeutic intervention but 1.74% with therapeutic intervention, the majority of which occurred after stricture dilatation.²⁹¹ Bleeding occurs in approximately 2.5%,²⁹² although one series demonstrated four out of six significant bleeds occurring following polypectomy.²⁹³ It is worth noting that real-world data on both the benefits and complications are skewed by selection bias, as at present this test is usually reserved for patients where other imaging modalities have been inconclusive or in scenarios when therapeutic intervention is a key aim.

Statement 2.3.6. ECCO-ESGAR Diagnostics GL [2018]

Malabsorption parameters should be assessed at regular intervals in all patients with IBD [EL5]

Nutritional deficiencies are frequently associated with symptomatic IBD. The reason for this is 2-fold. First, the discomfort and anorexia associated with disease flares preclude adequate intake. Second, inflammatory or fibrotic change to the bowel directly hinders absorption.

In all patients with IBD, weight should be recorded at each clinic review with the aim of early dietetic support when unintentional weight loss is noted. Anaemia is common and should be screened for in all IBD patients; this topic is covered in full in Chapter 1 of this guideline. Patients with symptoms suggestive of active disease should be screened for anaemia every 3 months. Initial screening should include complete blood count, ferritin, and CRP. There is no evidence on optimal screening intervals for any of the parameters used for malabsorption. Common practice in patients with small bowel disease or previous resection is to measure vitamin B12 and folic acid every 3 to 6 months. Judicious care must be taken when interpreting ferritin results in symptomatic patients; the ECCO anaemia guideline recommends ferritin values of up to 100 µg/L may still be consistent with iron deficiency in active disease, especially with a transferrin saturation of <20%. If low haemoglobin is confirmed, a more extensive workup should be undertaken as per the anaemia guideline.

Low albumin is common in active IBD, as it is an acute phase protein. Active IBD itself may lead to malabsorption, and low albumin in IBD may correlate with nutritional status. However, the use of albumin as a direct marker of malabsorption is tenuous. In a meta-analysis of 63 studies, albumin did not correlate with nutritional status in calorie-restricted but otherwise healthy individuals.²⁹⁴ Longitudinal follow-up of serum albumin in patients with anorexia nervosa and in healthy controls also failed to yield significant differences.²⁹⁵ As such, albumin is not an appropriate test for malabsorption and ECCO does not recommend albumin measurements for this reason.

Low vitamin D has been observed in between 16% to 95% of IBD patients, depending upon the study.^{296,297} Deficiency is associated with active disease, female gender, and non-Caucasian ethnicity, with one recent study suggesting higher prevalence in CD.²⁹⁸ A retrospective analysis has also linked low vitamin D with more frequent flares and lower quality-of-life scores.²⁹⁹ Unfortunately, prospective

follow-up after supplementation does not show a clear beneficial impact in disease course.³⁰⁰ Nevertheless, ECCO suggests measuring vitamin D in symptomatic patients, then re-evaluating after treatment to verify that levels are replete.

Other micronutrient deficiencies to be considered in IBD patients include vitamin K, selenium, vitamin A, vitamin C, zinc, vitamin B6, and vitamin B1.^{301,302} All patients with symptomatic IBD do not routinely require evaluation of all of the above. However, testing should be considered in patients with small bowel CD, in those who have undergone resection, and in those receiving nutritional supplementation [in particular parenteral nutrition] or if the specific clinical scenario lends suspicion to a deficiency [such as poor wound healing].

2.4. Imaging after surgery [including ileo-anal pouch]

Statement 2.4.1 ECCO-ESGAR Diagnostics GL [2018]

Ileocolonoscopy is the reference standard in the diagnosis of postoperative recurrence after ileocolonic resection. Endoscopy is recommended within the first 6 to 12 months after surgery [EL3]

Statement 2.4.2. ECCO-ESGAR Diagnostics GL [2018]

FC, IUS, MR enterography, and SBCE can be considered as non-invasive alternatives to detect postoperative recurrence, in particular after small bowel resection [EL2]

In the natural history of CD, intestinal resection is unavoidable in a significant proportion of patients. A majority of patients develop disease recurrence at or above the anastomosis, and endoscopic recurrence precedes the development of clinical symptoms. Data from endoscopic follow-up of patients after resection of ileocaecal disease have shown that in the absence of treatment, the postoperative endoscopic recurrence rate is approximately 65% to 90% within 12 months and 80% to 100% within 3 years of the operation.^{303,304} The rates of recurrence are also significant in patients after total proctocolectomy and permanent ileostomy. In a recent meta-analysis of 18 cohort studies, the risk of clinical recurrence was 28.0%, with a 5-year and 10-year median cumulative rate of 23.5%.³⁰⁵ Identification and treatment of early mucosal recurrence may therefore prevent clinical recurrence.

Ileocolonoscopy is the reference standard in the diagnosis of postoperative recurrence by defining the presence and severity of morphological recurrence. Data from endoscopic follow-up of patients after resection of ileocaecal disease have shown that in the absence of treatment, the postoperative recurrence rate is approximately 65% to 90% within 12 months.^{303,304} Ileocolonoscopy is therefore recommended within the first year after surgery where treatment decisions may be affected. The Rutgeert's score may be used for detailed description [see Chapter 4 of this guideline].

Non-invasive modalities may also be accurate and efficient in detection of postoperative recurrence.

FC can accurately identify postoperative recurrence.^{306,307} In a meta-analysis of 10 studies that evaluated the accuracy of FC for detection of endoscopic recurrence, the pooled sensitivity and specificity values for assessing suspected endoscopic recurrence were 0.82 and 0.61, respectively.³⁰⁸ In a more recent prospective study, FC levels >100 µg/g indicated endoscopic recurrence [defined as Rutgeert's

score ≥ 2] with 89% sensitivity and 58% specificity and an NPV of 91%; the authors suggested that colonoscopy could have been avoided in 47% of patients. In an additional prospective study from the GETAID group, FC levels >100 $\mu\text{g/g}$ were associated with a positive predictive value and NPV of 93% and 77%, respectively, for prediction of endoscopic recurrence.³⁰⁹

Several imaging modalities are available to reliably diagnose post-surgical recurrence, including IUS, small bowel follow-through, CT enteroclysis or CT enterography including virtual colonoscopy, MR enteroclysis or MR enterography, SBCE, and white blood cell scintigraphy.

Several authors have previously emphasised the value of IUS in postoperative follow-up, and confirmed the observation of bowel wall thickening as an indicator for recurrence.^{310–312} SICUS has shown an excellent correlation with the endoscopic Rutgeerts score [$r = 0.67$; $p = 0.0001$], reaching 87.5% accuracy for detecting CD recurrence.³¹³ SICUS is also considered to be superior to standard IUS in detecting postoperative CD recurrence after ileocaecal resection.³¹⁴ Bowel wall thickening was defined by thickness of >3.5 mm. SICUS prediction of recurrence was found to be correct in 100% of cases and confirmed by endoscopy.³¹⁴ In a recent retrospective series from Italy, the absolute incidence of new surgical intervention is 13% in patients with bowel thickness of 3 mm and 40% in patients with bowel thickness >6 mm.³¹⁵

CT enterography or CT enteroclysis are alternatives to endoscopy for assessing postoperative recurrence of CD activity.³¹⁶ In a prospective series that included 32 postoperative patients from China, a significant correlation between endoscopic and CT recurrence [$r = 0.782$; $p < 0.0001$] was demonstrated.³¹⁷ Due to false-negative findings, CT colonography has been tested for assessing the postoperative recurrence of CD with inconclusive results. However, CT colonography represents an alternative to conventional colonoscopy in non-compliant post-surgical patients with a rigid stenosis that does not allow passage of the endoscope.³¹⁸ However, due to concerns regarding cumulative radiation exposure, imaging modalities not associated with radiation [such as MR enterography or IUS] are preferable to CT enterography.

MR enterography may be an alternative to endoscopy as a diagnostic tool in postoperative recurrence evaluation in CD patients. Similar to the endoscopic Rutgeerts score for assessing postoperative recurrence, one study showed an objective evaluation using an MRI-based index of activity and severity for postoperative recurrence. This score achieved a high correlation with the endoscopic index, which allowed differentiation between mild and severe lesions³¹⁹ and prediction of the risk of clinical postoperative recurrence in CD patients.³²⁰

Although the Rutgeerts score has been used to evaluate the efficacy of several drugs, there is a lack of information on whether mural healing changes seen by cross-sectional imaging techniques are in parallel to endoscopic MH.

Capsule endoscopy can also be used to access postoperative recurrence.^{321,322} A fair correlation between the modalities [$r^2 = 0.54–0.64$; $p < 0.05$] was observed in a small pilot study that compared the Rutgeerts score calculated by capsule endoscopy and ileocolonoscopy.³²² An important advantage of capsule endoscopy is the ability to detect proximal small bowel recurrence. However, data on the use of capsule endoscopy for this indication are currently very limited, and patency capsule evaluation should be recommended before capsule endoscopy to minimize the risk of retention.

In a recent meta-analysis, MR enterography, IUS, and SBCE had excellent accuracy [area under the curve >0.9 for all modalities] for detection of endoscopic recurrence as defined by a Rutgeerts score ≥ 2 .³²³

Statement 2.4.3. ECCO-ESGAR Diagnostics GL [2018]

Endoscopy with biopsies should be performed in the assessment of pouch-related symptoms [EL2]

The ileo-anal pouch is a well-established option for patients who require surgery for chronic UC. Despite excellent functional results, the short-term and long-term outcome of ileal pouch with anal anastomosis [IPAA] are determined by the occurrence of complications. These may be directly related to the surgery or may occur over the long term. Immediate postoperative complications include leakage, abscess formation, pelvic sepsis, and fistula formation. More chronic disorders following IPAA are pouchitis, cuffitis, irritable pouch syndrome, pouch stricture, pouch sinus, afferent loop syndrome, or small bowel obstruction.³²⁴ Following surgery, up to 40% of patients have a single episode of pouchitis [a non-specific inflammatory condition at the ileal pouch reservoir]³²⁵ within 12 months, whereas 19% and 5% experience intermittent episodes and chronic pouchitis, respectively.^{326–328} The incidence of pouch failure is up to 7% at 3 years and 9% at 5 years.^{329,330}

Endoscopy plays a significant role in diagnosing and guiding therapy in patients with pouch complications.^{324,331–334} Importantly, the severity of symptoms does not always correlate with endoscopic or histological findings.^{335,336} Therefore, a cumulative clinical, endoscopic, and histological assessment is needed. Several diagnostic criteria are available and the most common in clinical use is the Pouch Disease Activity Index.³³⁷ Furthermore, it is valuable to classify the phenotype of pouchitis before initiating therapy, to provide guidance regarding treatment modalities and duration of treatment.³³⁸ In case of antibiotic-refractory pouchitis, endoscopic evaluation can facilitate exclusion of contributory factors such as ischaemic pouchitis and infections.³³⁹ Pouch endoscopy is essential in the diagnosis of CD of the pouch and prepouch ileitis.^{324,334,335}

FC levels are significantly elevated in cases of pouchitis. In a study that included 56 pouch patients, FC concentrations correlated closely with the objective pouchitis score, the Pouch Disease Activity Index, and endoscopic and histological inflammatory scores [Spearman rank test, p -values < 0.0001]; FC levels ≥ 92.5 $\mu\text{g/g}$ had a sensitivity of 90% and a specificity of 76.5% for detection of pouch inflammation.³⁴⁰ Other potential biomarkers of pouch inflammation, such as faecal matrix metalloprotease-9³⁴¹ and serum alpha-1 antitrypsin,³⁴² are also being evaluated but are currently not in routine clinical practice.

Chapter 3: Detection of complications

3.1. Detection of strictures

Statement 3.1.1. ECCO-ESGAR Diagnostics GL [2018]

Cross-sectional imaging should be used to detect small bowel strictures [EL2]. Due to radiation exposure with CT, the preferred methods are MRI and/or intestinal ultrasound [IUS]. No imaging technique is currently able to determine the degree of fibrosis [EL3]

Despite wide heterogeneity in the definitions for strictures, the accuracy of intestinal ultrasound [IUS], CT enterography, and MR enterography is high for diagnosis of stenosis affecting the small bowel.⁸¹ IUS is an accurate technique for detection of small bowel stenosis.

Based on pooled data using surgery as a reference standard, the sensitivity and specificity of IUS are 79% and 92%, respectively.⁸¹ Use of oral contrast agents, such as small intestine contrast ultrasound [SICUS], can improve the accuracy of IUS in detecting the presence and number of small bowel stenosis; sensitivity increased from 74% to 89% in one study.¹³¹ The sensitivity of CT enterography for stenosis detection was 92% and specificity was 100% when CT was compared with ileocolonoscopy.³⁴³⁻³⁴⁵ Studies using endoscopy and surgery as a reference standard reported a sensitivity of 85% and 90%, respectively, with a specificity of 100%.^{82,346} MRI studies with an adequate reference standard [endoscopy, surgery, or both] for diagnosis of stenosis showed a sensitivity of 89% and a specificity of 94%.⁸¹ The accuracy had a tendency to improve using enteroclysis [i.e. enteric contrast introduced via nasojejunal intubation rather than oral] as compared with enterography [sensitivity of 100% versus 86% and specificity of 100% versus 93%, respectively].²⁵³ Direct comparison of CT and MRI for diagnosis of stenosis indicated a similar sensitivity [85% versus 92%] and specificity [100% versus 90%].⁸² The use of luminal contrast and anti-peristaltic agents is recommended for CT enterography and MR enterography.³⁴⁷

Strictures in Crohn's disease [CD] are transmural and contain variable proportions of inflammatory and fibrotic tissue.³⁴⁸ Quantification of active inflammation versus fibrosis is challenging. With regards to current techniques used in clinical practice, no technique is sufficiently accurate to assess the degree of fibrosis in a stricture with adequate precision to guide clinical decisions. The stratified echo pattern of the different layers of the intestinal wall components of a stricture has been associated with collagen deposition, but this approach lacks consistency.³⁴⁹ On CT enterography, the presence of fibrosis was linked to stenotic lesions, but could not distinguish inflammation from fibrosis.³⁵⁰ Conventional-sequence MR enterography revealed conflicting results for fibrosis characterisation.^{351,352} Rimola *et al.* developed a technique using gadolinium enhancement between 70 s and 7 min on MR enterography. This approach was able to distinguish mild or moderate fibrosis from severe fibrosis irrespective of the degree of inflammation.³⁵³ This approach awaits external validation.

Although several novel imaging techniques have been proposed, data are limited, acquisition methods are unstandardised, and there is limited evidence to support external validity. These techniques include MR with dynamic contrast-enhanced technique,³⁵⁴ magnetisation-transfer MR,^{355,356} ultrasound elastography,^{357,358} or contrast-enhanced ultrasound [CEUS].^{359,360} While stenosis can be detected by endoscopy, most investigators use the ability to pass the endoscope as a measure of stenosis. The proportion of fibrosis cannot be evaluated precisely by biomarkers, endoscopy, or histology. There is no consistent approach regarding strategy for monitoring strictures over time or with which method.

Although not the preferred technique, ileocolonoscopy can be used for stricture diagnosis. The commonly used definition is a narrowing that cannot be passed with an endoscope.³⁶¹ An ileocolonoscopy is not necessary in all cases after a stricture has been detected on cross-sectional imaging, but should be considered if endoscopic therapy through endoscopic balloon dilatation is a valid therapeutic approach³⁶² and in case of colonic strictures when malignancy cannot be excluded.

Statement 3.1.2. ECCO-ESGAR Diagnostics GL [2018]

Any colonic stricture should be carefully surveyed due to risk of carcinoma [EL4]; surgery should be considered

Consistent with the observation that patients with ulcerative colitis [UC] and patients with colonic CD are at an increased risk of developing colorectal cancer [CRC],³⁶³⁻³⁶⁵ detection of a new colonic stricture should lead to a careful diagnostic workup to exclude malignancy. A recently published population-based study suggested that colonic strictures at diagnosis or during follow-up are associated with a 3.6% and 4.9% probability of CRC at 5 and 10 years, respectively.³⁶⁶ According to the ECCO evidence-based consensus for endoscopy in IBD, patients with strictures detected within 5 years should be considered 'high risk' and receive surveillance colonoscopy yearly. Malignancy is more frequent in the CD-affected colon and the incidence is comparable to UC.^{367,368} In a GETAID study, dysplasia or cancer was detected in 3.5% of patients with IBD who underwent surgery for colonic strictures.³⁶⁹ In addition, small bowel adenocarcinoma is rare but can be fatal if overlooked.³⁷⁰ The endoscopist should therefore have a low threshold for taking a biopsy before endoscopic balloon dilatation.³⁷⁰ In addition, the use of paediatric endoscopes with a smaller diameter may permit stricture traversal. Cross-sectional imaging should be considered as a complementary diagnostic modality. Currently, there is no method [including histology] that can definitively rule out malignancy in a patient with IBD and colonic strictures.

3.2. Detection of fistulae and abscesses

3.2.1. Detection of intra-abdominal fistulae and abscesses

Statement 3.2.1. ECCO-ESGAR Diagnostics GL [2018]

Cross-sectional imaging [IUS, MRI, and CT] can detect internal penetrating disease and intra-abdominal abscesses with varying accuracy [EL1]. MRI is preferable to ultrasound for deep-seated fistulae or abscesses or pelvic fistulae [EL4]

In a systematic review for the diagnosis of intra-abdominal fistulising lesions, cross-sectional imaging showed the following accuracy: for CT with surgery and endoscopy as reference standard, the sensitivity was 70% and specificity 97%; MRI with surgery or endoscopy as the reference standard showed a sensitivity of 76% and specificity of 96% for fistula diagnosis; IUS with surgery, barium studies, and colonoscopy as the reference standard showed a sensitivity of 74% and specificity of 95%.⁸¹ Oral contrast agents do not improve accuracy of IUS for detection of internal fistulae.¹³¹ If available, CT or MRI is preferable for detection of intra-abdominal or pelvic fistulae over ultrasound; MRI has the advantage of no radiation exposure.^{80,81} Cross-sectional imaging has a pivotal role in the assessment of penetrating complications of CD. In one study, there was no clinical fistula or abscess suspicion from pre-CT examination in half of patients with penetrating CD complications. Cross-sectional imaging changed management in more than three-quarters of these patients.³⁷¹ White blood cell scintigraphy is not indicated for diagnosis and characterisation of fistulae.

A systematic review revealed the following point estimates for diagnosis of abscesses: using surgery as a reference standard, IUS had a sensitivity of 84% and a specificity of 93%, which was dependent on disease location in CD.⁸¹ Detection of intra-abdominal abscesses via CT, with surgery as the reference standard, revealed a sensitivity of 86% and a specificity of 88%.³⁵⁰ One prospective study showed a sensitivity of 85% and specificity of 95% of CT for intra-abdominal abscesses.³⁷² CT and ultrasound showed an overall high and comparable accuracy in the detection of intra-abdominal abscesses, although CT showed a slightly greater positive predictive value than ultrasound.

CEUS has been shown to differentiate between an intra-abdominal phlegmon and abscess with high accuracy.³⁷³ The accuracy of MRI for abscess detection, using surgery as the reference standard, showed sensitivities ranging from 86% to 100% and specificities from 93% to 100%.^{352,374,375} A systematic review of these three studies showed a sensitivity of 86% and a specificity of 93% for MRI detection of abscesses.⁸¹ Endoscopy is not used for evaluation of internal penetrating disease, due to an inability to image extramural structures.

3.2.2 Detection of fistulae and abscesses

Statement 3.2.2. ECCO-ESGAR Diagnostics GL [2018]

MRI is the most accurate imaging modality for diagnosis and classification of perianal CD and is the recommended first-line test [EL1]. Transrectal ultrasonography [TRUS] is superior to clinical examination and is an alternative to MRI [EL2]. Combining any modality of MRI, examination under anaesthesia [EUA], or TRUS improves accuracy [EL2]

Statement 3.2.3. ECCO-ESGAR Diagnostics GL [2018]

Examination under anaesthesia [EUA] with drainage is recommended if a perianal abscess is suspected, and should not be postponed if pelvic imaging is not immediately available [EL2]

Statement 3.2.4. ECCO-ESGAR Diagnostics GL [2018]

Endoscopic evaluation of the rectum is essential to determine the most appropriate management strategy for perianal CD [EL2]

Three diagnostic tests are commonly used alone or in combination for the diagnosis and classification of perianal disease, namely examination under anaesthesia [EUA], MRI, or transrectal ultrasonography [TRUS]. Both TRUS [with and without hydrogen peroxide] and MRI can identify and classify fistulous tracts with a diagnostic accuracy for MRI ranging from 80% to 100% in most reported studies. The diagnostic accuracy of TRUS is more variable and ranges from 50% to 100%.^{165,170,376–385} MRI is the recommended first-line test, as TRUS is hindered by patient discomfort, cannot be performed in the presence of stenosis, and has a smaller field of view. EUA by an experienced surgeon has long been considered the reference standard for assessment of perianal CD. However, a prospective blinded study comparing EUA, MRI, and TRUS found diagnostic accuracies of 91%, 87%, and 91%, respectively, with 100% accuracy when any two of the tests were combined.¹⁶⁹ A larger prospective clinical trial compared preoperative digital rectal examination [33% sensitivity], TRUS [75% sensitivity], and body-coil MRI [85% sensitivity]. MRI may change management in patients with perianal CD by detecting an abscess not suspected clinically,^{376,386} and should therefore precede EUA unless there is a need for immediate drainage of sepsis. Although the use of EUA may be limited by luminal stenosis, dilatations during the procedure can be performed.

Undiagnosed fistula extensions and abscesses are major causes of recurrent disease after attempted surgical cure.³⁷⁷ Furthermore, full knowledge of the presence and extent of these secondary tracts is required for appropriate medical therapy, particularly with anti-TNF agents.¹⁶⁶ Accurate classification of perianal fistulae is thus essential before starting therapy. Two prospective studies evaluated

the effect of preoperative MRI on clinical outcome after surgical treatment for perianal fistulising disease.^{376,377} Both studies showed that MRI revealed additional and clinically relevant information to the surgeon performing EUA. A prospective comparison of modalities using a robust outcome-based reference standard found MRI superior to TRUS for fistula classification and detecting abscesses.¹⁷⁰ In general, MRI is preferred in CD, especially in recurrent or suspected complex disease.

Endoscopy can facilitate detection of perianal disease and has a role in assessing the degree of inflammation in the rectum, which may affect management.¹⁰⁵ Endoscopy has not been shown to be useful in monitoring perianal disease or assessing response to fistula therapy.

Transperineal ultrasound [TPUS] has been evaluated in small studies for the documentation of perianal disease and may have clinical utility.^{387,388}

3.3 Detection of pouch complications

Statement 3.3.1. ECCO-ESGAR Diagnostics GL [2018]

Cross-sectional imaging and endoscopy are complementary methods for assessing suspected structural complications after ileal pouch anal anastomosis [IPAA] [EL4]. Pouchography can be used additionally to assess functional disorders and other complications [EL3]

Inflammatory and non-inflammatory complications of the ileal pouch anal anastomosis [IPAA] are common and include strictures, abscesses, fistulae, and sinus tracts culminating in pouch failure in up to 9% of cases at 5 years.^{329,330,332,389} These complications can be immediately postoperative or long-term. In the cases of IPAA stenosis, fistulae, abscesses, and sinuses, EUA by an experienced IBD surgeon is important for diagnosis and timely treatment of most pathologies. The choice of diagnostic modality depends on the clinically suspected disorder, local expertise, and availability. Endoscopy is essential to obtain information on mucosal status and for diagnosis of intraluminal or anastomotic complications, such as strictures. Endoscopic balloon dilatation can be used to treat pouch stricture.^{390,391} For suspected extraluminal complications, such as abscesses, fistulae, or sinus tracts,^{392,393} pelvic CT, MRI, and TRUS or TPUS are sensitive methods that allow the identification and characterisation of septic problems¹⁷⁰; use of these modalities depends on local availability and experience level. Unfortunately, the proportion of fibrosis versus inflammation cannot be assessed precisely by any currently available diagnostic tool.^{394–396} Contrast pouchography can assist in assessment of pouch strictures, pouch fistulae, and leakage¹⁰⁰ but is only used in a limited number of centres. A correlation of pelvic CT, MRI, pouch endoscopy, and retrograde pouchography findings with clinical outcome revealed a reasonable accuracy for diagnosis of strictures, fistulae, sinuses, and pouch leaks, with all methods.³⁹⁷ CT had the lowest accuracy for small bowel strictures [74%]; MRI had the lowest accuracy for pouch sinuses [68%]. A combination of two imaging tests increased diagnostic accuracy to 100%. In the acute postoperative setting, complications of IPAA include anastomotic leaks and abscesses. Leaks from the tip of the J-pouch and the pouch-anal anastomosis often result in pelvic abscesses. Detection of anastomotic dehiscence after IPAA is possible using transanal ultrasound and TPUS, although pelvic CT or MRI scanning is usually required to outline the full extent of the complication and guide drainage.^{396,398} Complications of the pouch should be discussed in a multidisciplinary team setting to individualise management.

3.4 Detection of emergency complications

Statement 3.4.1. ECCO-ESGAR Diagnostics GL [2018]

In acute severe colitis, a plain abdominal radiograph is an acceptable first study to detect toxic megacolon. In selected cases, CT could be indicated as an initial method to screen for complications [EL3]

Diagnosis of toxic megacolon is usually made by clinical signs of systemic toxicity supported by imaging confirmation. Detection of transverse colonic dilatation >5.5 cm by means of plain abdominal X-ray is still the most established radiological definition of toxic megacolon.³⁹⁹ Some case series have shown that in patients with toxic megacolon, CT scan and IUS can be promising alternatives that provide additional information.^{400,401} A CT scan is an important tool for diagnosis of associated perforation or ascending pylephlebitis. A study observed that among 18 patients with toxic megacolon [four with underlying UC], CT scans revealed abdominal complications in four patients, missed clinically and on plain abdominal films.⁴⁰⁰ Larger clinical studies are warranted to assess the diagnostic benefit of cross-sectional radiological studies in the assessment of toxic megacolon.

Statement 3.4.2. ECCO-ESGAR Diagnostics GL [2018]

When a perforation is suspected, CT should be performed in all patients with acute abdominal pain and established diagnosis of IBD [EL2]

Spontaneous free perforation is a rare but serious event in CD, but can be more common in acute severe colitis. Spontaneous free perforation may result from severe inflammation or superimposed malignancy. It is estimated that approximately 1% to 2% of patients with CD will present with a free perforation initially or at some time over their disease course.^{402,403}

In IBD patients, intestinal perforation frequently presents as a peri-intestinal abscess that may be detected by cross-sectional imaging methods such as IUS, MRI, or CT. A systematic review showed that in this context the three techniques have a high accuracy for identification of fistulae, abscesses, and stenoses [sensitivities and specificities of 0.80], although IUS yields more false-positive results for abscesses.⁸¹

3.5. Detection of postoperative complications

Statement 3.5.1. ECCO-ESGAR Diagnostics GL [2018]

Acute postoperative complications in IBD patients [mainly anastomotic leaks and abscesses] should be initially investigated by CT [EL3]. Ultrasound may be an alternative first-line investigation, but should be followed by immediate CT, if negative or equivocal. [EL4]

Anastomotic leaks after intestinal surgery may be promptly diagnosed clinically, due to specific clinical presentation in the postoperative period. However, when anastomotic leaks are suspected in cases of atypical clinical manifestations, correct and rapid radiological diagnosis is necessary for successful management. Few studies have been designed to assess detection of these complications in CD,⁸¹ and most are derived from the surgical literature.^{404–406} A prospective database populated over a 10-year period showed that anastomotic leaks are frequently diagnosed late in the postoperative period and often after initial hospital discharge [median time 12.7 days, range

1–38].⁴⁰⁴ In this study, CT was the preferred imaging modality.⁴⁰⁴ In contrast, other studies showed that most postoperative CT features overlap between patients with or without clinically important anastomotic leaks, and that CT studies performed on patients shortly after abdominal surgery are not definitive. A negative CT does not exclude postoperative lower gastrointestinal tract leaks.^{405,406} A combination of CT, laboratory examinations, and clinical signs and symptoms will optimise diagnosis of such complications.

There is no evidence that the addition of intraluminal contrast is more sensitive for detection of anastomotic dehiscence in IBD, as peri-anastomotic located fluid-containing gas is the most prevalent sign of anastomotic insufficiency.⁴⁰⁶ Selected use of intraluminal contrast can be individualised according to physician preference.

3.6. Surveillance for colorectal cancer in IBD patients with colonic inflammation

Statement 3.6.1. ECCO-ESGAR Diagnostics GL [2018]

[ECCO UC Guideline: statement 8D in Magro F *et al.*] Screening colonoscopy should be offered 8 years after onset of symptoms to all patients to reassess disease extent and exclude dysplasia [EL5]

Statement 3.6.2. ECCO-ESGAR Diagnostics GL [2018]

[ECCO UC Guideline: statement 8E in Magro F *et al.*] When disease activity is limited to the rectum without evidence of previous or current endoscopic or microscopic inflammation [or both] proximal to the rectum, inclusion in a regular surveillance colonoscopy programme is not necessary [EL2]

Statement 3.6.3. ECCO-ESGAR Diagnostics GL [2018]

[ECCO UC Guideline: statement 8F in Magro F *et al.*] In patients with concurrent primary sclerosing cholangitis [PSC], annual surveillance colonoscopy should be performed following the diagnosis of PSC, irrespective of disease activity, extent, and duration [EL3]

Statement 3.6.4. ECCO-ESGAR Diagnostics GL [2018]

[ECCO UC Guideline: statement 8G in Magro F *et al.*] Ongoing surveillance should be performed in all patients apart from those with proctitis [EL3]. Patients with high-risk features [e.g. stricture or dysplasia detected within the past 5 years, PSC, extensive colitis with severe active inflammation] should have their next surveillance colonoscopy scheduled for 1 year [EL4]. Patients with intermediate risk factors should have their next surveillance scheduled for 2 to 3 years. Intermediate risk factors include extensive colitis with mild or moderate active inflammation, post-inflammatory polyps, or a family history of colorectal cancer [CRC] in a first-degree relative diagnosed at age 50 years and above [EL5]. Patients with neither intermediate nor high-risk features should have their next surveillance colonoscopy scheduled for 5 years [EL5]

Statement 3.6.5. ECCO-ESGAR Diagnostics GL [2018]

Colonoscopic surveillance is best performed when ulcerative colitis [UC] is in remission, because it is otherwise difficult to discriminate between dysplasia and inflammation on mucosal biopsies [EL5]

Statement 3.6.6. ECCO-ESGAR Diagnostics GL [2018]

Surveillance colonoscopy should take into account local expertise. Chromoendoscopy with targeted biopsies has been shown to increase dysplasia detection rate [EL2]. White-light endoscopy is less accurate. If white-light endoscopy is used, random biopsies [quadrantic biopsies every 10 cm] and targeted biopsies of any visible lesion should be performed [EL3]. High-definition endoscopy should be used if available [EL2]

Statement 3.6.7. ECCO-ESGAR Diagnostics GL [2018]

Where dysplasia of any grade is found without an associated endoscopically visible lesion, urgent repeat chromoendoscopy should be performed by an experienced endoscopist to determine whether a well-circumscribed lesion exists and to assess for synchronous dysplasia [EL5]. A patient with confirmed low-grade dysplasia detected in mucosa without an associated endoscopically visible lesion should undergo repeat chromoendoscopic colonoscopy with additional random biopsies within 3 months [EL5]

Statement 3.6.8. ECCO-ESGAR Diagnostics GL [2018]

[ECCO UC Guideline: statement 8K in Magro F *et al.*] Presence of low-grade or high-grade dysplasia should be confirmed by an independent gastrointestinal specialist pathologist [EL5]

Longstanding UC and CD with colonic inflammation are associated with an increased risk of CRC, with a variable estimate between studies.^{363–365} However, the risk of CRC seems to decline over time.^{407–409} Possible reasons are the emergence of effective surveillance strategies, better control of inflammation with drugs, and a modified approach to maintenance therapy or colectomy, as stated in previous guidelines.⁴¹⁰

On the basis of systematic endoscopic assessment, together with medical and family history of the patient, surveillance colonoscopy programmes have been developed to reduce CRC-associated morbidity and mortality.³⁶³ At the onset of these programmes, an initial screening colonoscopy is performed to reassess disease extent and confirm the absence of dysplastic lesions.³⁶³ The timing of surveillance colonoscopies should be based on the level of risk of the patient, as extensively discussed in the recent ECCO consensus³⁶³ [Table 2]. The suggested timeline for surveillance in Crohn's colitis, though scientific data are more limited, should be applied as for UC.

Good bowel preparation is essential for an efficient surveillance colonoscopy, since the quality of the preparation in UC patients significantly affects the lesion detection rate.⁴¹¹

A recent colitis surveillance study demonstrated that high-definition colonoscopy improves dysplasia detection in comparison with standard definition.^{363,412} Targeted biopsies have been shown to be not inferior to random biopsies for neoplasia detection rate per colonoscopy in a randomized controlled trial.^{363,413} Spraying dyes, such as methylene blue or indigo carmine,^{414–416} highlight subtle changes in the colonic mucosa architecture and can improve the detection rate of dysplasia.⁴¹⁷ There is abundant evidence from clinical trials and real-life studies that chromoendoscopy is superior to white-light endoscopy for dysplasia detection,^{418–426} independent of operator familiarity or from the availability of high-resolution endoscopy. Narrow-band imaging and endomicroscopy cannot currently be recommended for dysplasia screening in IBD.³⁶³

3.7. Diagnostic and monitoring techniques during pregnancy

Statement 3.7.1. ECCO-ESGAR Diagnostics GL [2018]

IUS and abdominal MRI without intravenous gadolinium are the safest techniques to examine pregnant women in whom IBD is known or suspected, regardless of the trimester [EL5]

Statement 3.7.2. ECCO-ESGAR Diagnostics GL [2018]

Endoscopy is generally considered to be safe in pregnancy; however, procedures should only be performed when there is a strong indication and clear clinical benefit [EL3]

Data are scarce concerning the medical imaging of pregnant women in whom IBD is known or suspected. Recent guidelines by the American College of Obstetricians and Gynecologists state that

Table 2. Timeline of endoscopic surveillance according to risk factors after screening colonoscopy.

Risk level	Risk factors	Surveillance
Lower risk	Extensive colitis with mild endoscopic or histological inflammation Colitis affecting <50% of the colon	Every 5 years
Intermediate risk	Extensive colitis with mild endoscopic or histological inflammation [or both] CRC in a first-degree relative older than 50 years	Every 2–3 years
Higher risk	Extensive colitis with moderate-to-severe endoscopic or histological inflammation [or both] CRC in a first-degree relative younger than 50 years History of PSC [included post-OLT] Stricture in past 5 years Dysplasia in the past 5 years in a patient who declines surgery	Yearly

CRC, colorectal cancer; PSC, primary sclerosing cholangitis; OLT, orthoptic liver transplantation.

ultrasound, MRI, CT, and nuclear medicine imaging techniques are theoretically safe if used prudently.⁴²⁷ The main concerns regarding these techniques are increased fetal temperature caused by application of high-frequency ultrasound, or a magnetic field and fetal radiation exposure, either via X-ray or radio-isotopes.

Ultrasound and MRI are the best choice for pregnant women, but application of either can theoretically increase the temperature of maternal and fetal tissues.^{428,429} The Food and Drug Administration limits the spatial-peak temporal average intensity of ultrasound transducers to 720 mW/cm².⁴²⁷ Ultrasound examination should be performed according to the 'as low as reasonably achievable' principle,⁴³⁰ accounting for exposure time related to the thermal index generated during the procedure [keeping this value <1].^{431,432} No specific data apply to IBD populations.

Regarding MRI, a recent retrospective survey of 1 424 105 deliveries from the province of Ontario compared those with first-trimester MRI [$n = 1737$] with no MRI [$n = 1 418 451$]. MRI did not confer additional risk of congenital anomalies, neoplasms, or vision or hearing loss. No additional risk of nephrogenic systemic fibrosis was found when gadolinium-enhanced MRI [$n = 397$] was compared with no MRI [$n = 1 418 451$]. Gadolinium-enhanced MRI at any time during pregnancy was associated with an increased risk of a broad set of rheumatological, inflammatory, or infiltrative skin conditions [adjusted hazard ratio 1.36; 95% CI 1.09–1.69] and for stillbirth or neonatal death [adjusted relative risk 3.70; 95% CI 1.55–0.85].⁴³³ Another retrospective study of 751 neonates exposed to 1.5T MRI in utero, compared with 10 042 unexposed neonates, found no difference between groups regarding birthweight or incidence of hearing impairment or deafness.⁴³⁴

Specific data on MRI in pregnant women with IBD are limited. Stern *et al.* reported nine pregnant women [seven with established CD] who underwent unenhanced MRI. Features typical of active CD were identified with their protocol [mural thickening ≥ 3 mm, ulcers, mural oedema, 'comb sign', phlegmon, abscesses, and fistulae]. MRI detected complications in four women and was sufficiently accurate to inform medical management.⁴³⁵ One case report described MR colonography used safely to examine a pregnant woman of 20 weeks gestational age with acute severe colitis, indicating conservative therapy that avoided colectomy.⁴³⁶ Another case report described a pregnant woman of 26 weeks gestational age who underwent unenhanced MRI to diagnose adhesions following ileo-anal pouch surgery, with no adverse events.⁴³⁷ Another case report did not reveal any safety concerns in a pregnant woman with fistulising CD.⁴³⁸

X-ray exposure is associated with an increased risk of congenital malformation^{439,440} and childhood cancer,⁴⁴¹ estimated at 6% per Gy.⁴⁴⁰ However, exposure at ≤ 50 mGy is considered safe at any trimester.⁴⁴⁰ In the absence of data for IBD patients, Hurwitz *et al.* showed that multidetector row CT to investigate suspected appendicitis conferred a dose of 1.52 to 1.68 cGy and 2 to 4 cGy at Months 0 and 3, respectively.⁴⁴² Unless potential risks are outweighed by clinical need, current data do not support the use of CT or any other X-ray technique. Due to the absence of specific data regarding use of radio-isotopes in pregnant women with suspected or diagnosed IBD, radio-isotopes should be avoided in this patient population.

Limited evidence exists regarding the utility and safety of endoscopy in pregnant women with IBD. Due to potential complications described in the recent ECCO pregnancy and reproduction consensus,⁴⁴³ endoscopy in pregnancy should be reserved for strong indications. To avoid vena cava compression, pregnant patients should be placed in the left pelvic tilt or left lateral position before, during, and after the endoscopic procedure. Close attention should be paid

to appropriate drug selection, using drugs appropriate for pregnancy and using the minimum dose possible to achieve the desired effect. Sedative drugs should be administered to provide patient comfort; over-sedation should be avoided.

3.8. Diagnostics for biliary extra-intestinal manifestations of IBD

Statement 3.8.1. ECCO-ESGAR Diagnostics GL [2018]

Ultrasound is the first-line non-invasive imaging procedure in the workup of elevated liver enzymes, cholestasis, or both [EL1]. Magnetic resonance cholangiopancreatography should be considered if ultrasound and serology are inconclusive [EL1]

Statement 3.8.2. ECCO-ESGAR Diagnostics GL [2018]

[ECCO-EIM Guidelines: statement 7B in M. Harbord *et al.*] If high-quality magnetic resonance cholangiography is normal in a patient with IBD and suspected PSC, an ultrasound-guided liver biopsy should be considered to diagnose small-duct PSC [EL2]

Statement 3.8.3. ECCO-ESGAR Diagnostics GL [2018]

[ECCO EIM Guidelines: statement 7H in M. Harbord *et al.*] There is no evidence-based follow up regimen proven to detect biliary neoplasia earlier in PSC. Annual ultrasonography to detect gallbladder mass lesions is recommended [EL4]. Additional imaging (MRI/MRC, CT, or endoscopic retrograde cholangiography [ERC]) should be performed without delay if cholangiocarcinoma is suspected [EL1]

Statement 3.8.4. ECCO-ESGAR Diagnostics GL [2018]

[ECCO EIM Guidelines: statement 7E in M. Harbord *et al.*] In PSC patients with clinical or radiological suspicion of significant strictures or cholangiocarcinoma, ERC is recommended to diagnose strictures that may be amenable to endoscopic dilatation [with or without stenting] and for brush cytology specimen evaluation [EL2]. Prophylactic antibiotic therapy is recommended [EL1]

The statements above have been included in this ECCO diagnostic guideline for completion of endoscopic or cross-sectional imaging diagnostics of extra-intestinal biliary involvement in patients with IBD. For detailed explanation and references, please refer to the ECCO EIM guideline.²⁴⁴

Conflict of Interest Statement

ECCO and ESGAR have diligently maintained a disclosure policy of potential conflicts of interests [CoI]. The conflict of interest declaration is based on a form used by the International Committee of Medical Journal Editors [ICMJE]. The CoI statement is not only stored at the ECCO Office and the editorial office of *JCC* but also is open to public scrutiny on the ECCO website [https://www.ecco-ibd.eu/about-ecco/ecco-disclosures.html] providing a comprehensive overview of potential conflicts of interest of authors.

The ECCO-ESGAR Consensus Guidelines are based on an international consensus process. Any treatment decisions are a matter for the individual clinician and should not be based exclusively on the content of the ECCO-ESGAR Consensus Guidelines. The European Crohn's and Colitis Organisation, the European Society of Gastrointestinal and Abdominal Radiology, and/or any of their staff members and/or any consensus contributor may not be held liable for any information published in good faith in the ECCO-ESGAR Consensus Guidelines.

Acknowledgments

Guidelines panel: Chairs: Andreas Sturm, Christian Maaser, and Jaap Stoker
Consultant pathologist expert: Paula Borralho Nunes

WG1 [Working group 1]: Initial diagnosis [or suspecting IBD], Imaging techniques in regard to location: Upper GI tract, Mid GI tract, Lower GI tract, Perianal disease

Leader – Stephan Vavricka

Member – Pierre Ellul

Member – Fabiana Castiglione

Y-ECCO – Bram Verstockt

ESGAR – Damian Tolan

WG2: Imaging techniques in regard to clinical situations: Monitoring therapeutic success [inclusive calpro], Monitoring clinically asymptomatic patients, Monitoring clinically symptomatic patients, Imaging after surgery including ileoanal pouch

Leader – Torsten Kucharzik

Member – Patrick van Rheenen

Member – Uri Kopylov

Y-ECCO – Hannah Gordon

ESGAR – Andrea Laghi

WG3: Detecting [suspected] complications [stricture, fistula, abscess, anastomotic insufficiency, toxic megacolon, perforation]: Endoscopic and non-medical, non-surgical interventions [stricture, abscess, bleeding], Cancer surveillance, Imaging during pregnancy

Leader – Gionata Fiorino

Member – Florian Rieder

Member – Paulo Gustavo Kotze

Member – Abraham Eliakim

Y-ECCO – Dominik Bettenworth

ESGAR – Steve Halligan

WG4: Endoscopic and clinical scoring systems in IBD: CDAI, CDEIS, Mayo-Score, Life quality indices, Cross-sectional imaging

Leader – Vito Anness

Member – Jimmy Limdi

Member – Konstantinos Katsanos

Y-ECCO – Eduards Krustiņš

ESGAR – Jordi Rimola

WG5: General principles and technical aspects of: endoscopy including enteroscopy, capsule endoscopy, ultrasound, CT, MRI, SBE/SBFT

Leader – Emma Calabrese

Member – Daniel Baumgart

Member – Yago González Lama

Y-ECCO – Johan Burisch

ESGAR – Stuart Andrew Taylor

ECCO and ESGAR National Representatives who participated in the Second Voting Round:

- Austria: Christoph Högenauer, Alexander Moschen
- Bosnia and Herzegovina: Ante Bogut
- Belgium: Bart Op de Beeck
- Croatia: Željko Krznarić, Brankica Mijandrušić-Sinčić
- Cyprus: Ioannis Kaimakliotis
- Czech Republic: Tomáš Douda, Vlastimil Valek
- Denmark: Signe Wildt, Soren Rafaelsen
- Estonia: Karin Kull, Benno Margus
- Finland: Pauliina Molander, Clas-Göran af Björkstén

- France: Arnaud Bourreille, Xavier Roblin, Jean- Pierre Tasu
- Germany: Britta Siegmund
- Greece: Ioannis Koutroubakis, Charikleia Triantopoulou
- Ireland: Garret Cullen
- Israel: Matti Waterman
- Italy: Ennio Biscaldi
- Lithuania: Gediminas Kiudelis
- Moldova: Svetlana Turcan
- Poland: Maria Klopocka, Małgorzata Śladek
- Portugal: Paula Ministro dos Santos
- Romania: Mihai Mircea Diculescu
- Russia: Alexander Potapov
- Spain: Javier Gisbert, Rosa Bouzas
- Sweden: Ann-Sofie Backman, Michael Eberhardson
- Switzerland: Dominik Weishaupt
- Trinidad & Tobago: Alexander Sinanan
- UK: Barney Hawthorne

Additional reviewers who participated in the Second Voting Round:

- Almer, Sven
- Biancone, Livia
- Bonifacio, Cristiana
- Civitelli, Fortunata
- Eder, Piotr
- Fernandes, Carlos
- Lopetuso, Loris
- Luglio, Gaetano
- Portela, Francisco
- Rizzello, Fernando
- Sahnan, Kapil
- Sieczkowska, Joanna

Reviewer, on behalf of GuiCom: Tim Raine

References

1. Gomollón F, Dignass A, Anness V, et al.; ECCO. Third^d European evidence-based consensus on the diagnosis and management of Crohn's disease 2016. Part 1: diagnosis and medical management. *J Crohns Colitis* 2017;**11**:3–25.
2. Magro F, et al. Third European evidence-based consensus on diagnosis and management of ulcerative colitis. Part 1: definitions, diagnosis, extra-intestinal manifestations, pregnancy, cancer surveillance, surgery, and ileo-anal pouch disorders. *J Crohns Colitis* 2017;**11**:649–70.
3. Vermeire S, Van Assche G, Rutgeerts P. Laboratory markers in IBD: useful, magic, or unnecessary toys? *Gut* 2006;**55**:426–31.
4. Vermeire S, Van Assche G, Rutgeerts P. The role of C-reactive protein as an inflammatory marker in gastrointestinal diseases. *Nat Clin Pract Gastroenterol Hepatol* 2005;**2**:580–6.
5. Plevy S. Do serological markers and cytokines determine the indeterminate? *J Clin Gastroenterol* 2004;**38**:S51–6.
6. Poullis A, Foster R, Northfield TC, Mendall MA. Review article: faecal markers in the assessment of activity in inflammatory bowel disease. *Aliment Pharmacol Ther* 2002;**16**:675–81.
7. Langhorst J, Elsenbruch S, Mueller T, et al. Comparison of 4 neutrophil-derived proteins in feces as indicators of disease activity in ulcerative colitis. *Inflamm Bowel Dis* 2005;**11**:1085–91.
8. Konikoff MR, Denson LA. Role of fecal calprotectin as a biomarker of intestinal inflammation in inflammatory bowel disease. *Inflamm Bowel Dis* 2006;**12**:S24–34.
9. Costa F, Mumolo MG, Bellini M, et al. Role of faecal calprotectin as non-invasive marker of intestinal inflammation. *Dig Liver Dis* 2003;**35**:642–7.
10. Kane SV, Sandborn WJ, Rufo PA, et al. Fecal lactoferrin is a sensitive and specific marker in identifying intestinal inflammation. *Am J Gastroenterol* 2003;**98**:1309–14.
11. Gisbert JP, Bermejo F, Pérez-Calle JL, et al. Fecal calprotectin and lactoferrin for the prediction of inflammatory bowel disease relapse. *Inflamm Bowel Dis* 2009;**15**:1190–8.

12. von Roon AC, Karamountzos L, Purkayastha S, *et al.* Diagnostic precision of fecal calprotectin for inflammatory bowel disease and colorectal malignancy. *Am J Gastroenterol* 2007;102:803–13.
13. Schoepfer AM, Beglinger C, Straumann A, Trummer M, Renzulli P, Seibold F. Ulcerative colitis: correlation of the Rachmilewitz endoscopic activity index with fecal calprotectin, clinical activity, C-reactive protein, and blood leukocytes. *Inflamm Bowel Dis* 2009;15:1851–8.
14. Schoepfer AM, Trummer M, Seeholzer P, Seibold-Schmid B, Seibold F. Discriminating IBD from IBS: comparison of the test performance of fecal markers, blood leukocytes, CRP, and IBD antibodies. *Inflamm Bowel Dis* 2008;14:32–9.
15. Vinding KK, Elsborg H, Thorkilgaard T, *et al.* Fecal calprotectin measured by patients at home using smartphones—a new clinical tool in monitoring patients with inflammatory bowel disease. *Inflamm Bowel Dis* 2016;22:336–44.
16. Lin JF, Chen JM, Zuo JH, *et al.* Meta-analysis: fecal calprotectin for assessment of inflammatory bowel disease activity. *Inflamm Bowel Dis* 2014;20:1407–15.
17. Menees SB, Powell C, Kurlander J, Goel A, Chey WD. A meta-analysis of the utility of C-reactive protein, erythrocyte sedimentation rate, fecal calprotectin, and fecal lactoferrin to exclude inflammatory bowel disease in adults with IBS. *Am J Gastroenterol* 2015;110:444–54.
18. Lozoya Angulo ME, de Las Heras Gómez I, Martínez Villanueva M, Noguera Velasco JA, Avilés Plaza F. Faecal calprotectin, a useful marker in discriminating between inflammatory bowel disease and functional gastrointestinal disorders. *Gastroenterol Hepatol* 2017;40:125–31.
19. Fine KD, Schiller LR. AGA technical review on the evaluation and management of chronic diarrhea. *Gastroenterology* 1999;116:1464–86.
20. Travis S, Jewell D. Ulcerative colitis: clinical presentation and diagnosis. In: Satsangi J, Sutherland L, editors. *Inflammatory Bowel Diseases*. London: Churchill Livingstone; 2003: 169–81.
21. Bossuyt X. Serologic markers in inflammatory bowel disease. *Clin Chem* 2006;52:171–81.
22. Reese GE, Constantinides VA, Simillis C, *et al.* Diagnostic precision of anti-*Saccharomyces cerevisiae* antibodies and perinuclear antineutrophil cytoplasmic antibodies in inflammatory bowel disease. *Am J Gastroenterol* 2006;101:2410–22.
23. Dubinsky MC, Kugathasan S, Mei L, *et al.*; Western Regional Pediatric IBD Research Alliance; Pediatric IBD Collaborative Research Group; Wisconsin Pediatric IBD Alliance. Increased immune reactivity predicts aggressive complicating Crohn's disease in children. *Clin Gastroenterol Hepatol* 2008;6:1105–11.
24. Ferrante M, Henckaerts L, Joossens M, *et al.* New serological markers in inflammatory bowel disease are associated with complicated disease behaviour. *Gut* 2007;56:1394–403.
25. Mirkov MU, Verstockt B, Cleyen I. Genetics of inflammatory bowel disease: beyond NOD2. *Lancet Gastroenterol Hepatol* 2017;2:224–34.
26. Rahier JF, Magro F, Abreu C, *et al.*; European Crohn's and Colitis Organisation [ECCO]. Second European evidence-based consensus on the prevention, diagnosis and management of opportunistic infections in inflammatory bowel disease. *J Crohns Colitis* 2014;8:443–68.
27. Pizzi LT, Weston CM, Goldfarb NI, *et al.* Impact of chronic conditions on quality of life in patients with inflammatory bowel disease. *Inflamm Bowel Dis* 2006;12:47–52.
28. Wells CW, Lewis S, Barton JR, Corbett S. Effects of changes in hemoglobin level on quality of life and cognitive function in inflammatory bowel disease patients. *Inflamm Bowel Dis* 2006;12:123–30.
29. World Health Organization. *Iron Deficiency Anemia Assessment, Prevention and Control. A Guide for Programme Managers*. Geneva: WHO; 2011.
30. Testa A, Rispo A, Romano M, *et al.* The burden of anaemia in patients with inflammatory bowel diseases. *Dig Liver Dis* 2016;48:267–70.
31. Dignass AU, Gasche C, Bettenworth D, *et al.*; European Crohn's and Colitis Organisation [ECCO]. European consensus on the diagnosis and management of iron deficiency and anaemia in inflammatory bowel diseases. *J Crohns Colitis* 2015;9:211–22.
32. Bergamaschi G, Di Sabatino A, Albertini R, *et al.* Prevalence and pathogenesis of anemia in inflammatory bowel disease. Influence of anti-tumor necrosis factor-alpha treatment. *Haematologica* 2010;95:199–205.
33. Goodhand JR, Kamperidis N, Rao A, *et al.* Prevalence and management of anemia in children, adolescents, and adults with inflammatory bowel disease. *Inflamm Bowel Dis* 2012;18:513–9.
34. Weiss G, Goodnough LT. Anemia of chronic disease. *N Engl J Med* 2005;352:1011–23.
35. Gasche C, Lomer MC, Cavill I, Weiss G. Iron, anaemia, and inflammatory bowel diseases. *Gut* 2004;53:1190–7.
36. Martin J, Radeke HH, Dignass A, Stein J. Current evaluation and management of anemia in patients with inflammatory bowel disease. *Expert Rev Gastroenterol Hepatol* 2017;11:19–32.
37. Bentley E, Jenkins D, Campbell F, Warren B. How could pathologists improve the initial diagnosis of colitis? Evidence from an international workshop. *J Clin Pathol* 2002;55:955–60.
38. Dejaco C, Oesterreicher C, Angelberger S, *et al.* Diagnosing colitis: a prospective study on essential parameters for reaching a diagnosis. *Endoscopy* 2003;35:1004–8.
39. Tanaka M, Riddell RH, Saito H, Soma Y, Hidaka H, Kudo H. Morphologic criteria applicable to biopsy specimens for effective distinction of inflammatory bowel disease from other forms of colitis and of Crohn's disease from ulcerative colitis. *Scand J Gastroenterol* 1999;34:55–67.
40. Tanaka M, Saito H, Fukuda S, Sasaki Y, Munakata A, Kudo H. Simple mucosal biopsy criteria differentiating among Crohn disease, ulcerative colitis, and other forms of colitis: measurement of validity. *Scand J Gastroenterol* 2000;35:281–6.
41. Langner C, Magro F, Driessen A, *et al.*; European Society of Pathology; European Crohn's and Colitis Foundation. The histopathological approach to inflammatory bowel disease: a practice guide. *Virchows Arch* 2014;464:511–27.
42. Tursi A, Inchingolo CD, Nenna R, *et al.* Pattern of mucosal tumor necrosis factor-alpha expression in segmental colitis associated with diverticula suggests a truly autonomous clinical entity. *Inflamm Bowel Dis* 2008;14:1315–7.
43. Lamps LW, Knapple WL. Diverticular disease-associated segmental colitis. *Clin Gastroenterol Hepatol* 2007;5:27–31.
44. Scowcroft CW, Sanowski RA, Kozarek RA. Colonoscopy in ischemic colitis. *Gastrointest Endosc* 1981;27:156–61.
45. Brandt LJ, Boley SJ. AGA technical review on intestinal ischemia. American Gastrointestinal Association. *Gastroenterology* 2000;118:954–68.
46. Bernstein CN, Shanahan F, Anton PA, Weinstein WM. Patchiness of mucosal inflammation in treated ulcerative colitis: a prospective study. *Gastrointest Endosc* 1995;42:232–7.
47. Geboes K. Pathology of inflammatory bowel diseases [IBD]: variability with time and treatment. *Colorectal Dis* 2001;3:2–12.
48. Markowitz J, Kahn E, Grancher K, Hyams J, Treem W, Daum F. Atypical rectosigmoid histology in children with newly diagnosed ulcerative colitis. *Am J Gastroenterol* 1993;88:2034–7.
49. Robert ME, Tang L, Hao LM, Reyes-Mugica M. Patterns of inflammation in mucosal biopsies of ulcerative colitis: perceived differences in pediatric populations are limited to children younger than 10 years. *Am J Surg Pathol* 2004;28:183–9.
50. Tanaka M, Riddell RH. The pathological diagnosis and differential diagnosis of Crohn's disease. *Hepatogastroenterology* 1990;37:18–31.
51. Magro F, Langner C, Driessen A, *et al.*; European Society of Pathology [ESP]; European Crohn's and Colitis Organisation [ECCO]. European consensus on the histopathology of inflammatory bowel disease. *J Crohns Colitis* 2013;7:827–51.
52. Navaneethan U, Kochhar G, Phull H, *et al.* Severe disease on endoscopy and steroid use increase the risk for bowel perforation during colonoscopy in inflammatory bowel disease patients. *J Crohns Colitis* 2012;6:470–5.
53. Terheggen G, Lanyi B, Schanz S, *et al.* Safety, feasibility, and tolerability of ileocolonoscopy in inflammatory bowel disease. *Endoscopy* 2008;40:656–63.

54. Record CO, Bramble MG, Lishman AH, Sandle GI. Flexible sigmoidoscopy in outpatients with suspected colonic disease. *Br Med J* 1981;283:1291–2.
55. Surawicz CM, Haggitt RC, Husseman M, McFarland LV. Mucosal biopsy diagnosis of colitis: acute self-limited colitis and idiopathic inflammatory bowel disease. *Gastroenterology* 1994;107:755–63.
56. Kopylov U, et al. Diagnostic yield of capsule endoscopy versus magnetic resonance enterography and small bowel contrast ultrasound in the evaluation of small bowel Crohn's disease: Systematic review and meta-analysis. *Dig Liver Dis* 2017;49:854–63.
57. Rozendorn N, Klang E, Lahat A, et al. Prediction of patency capsule retention in known Crohn's disease patients by using magnetic resonance imaging. *Gastrointest Endosc* 2016;83:182–7.
58. Katsinelos P, Fasoulas K, Beltsis A, et al. Diagnostic yield and clinical impact of wireless capsule endoscopy in patients with chronic abdominal pain with or without diarrhea: a Greek multicenter study. *Eur J Intern Med* 2011;22:e63–6.
59. De Bona M, Bellumat A, Cian E, Valiante F, Moschini A, De Boni M. Capsule endoscopy findings in patients with suspected Crohn's disease and biochemical markers of inflammation. *Dig Liver Dis* 2006;38:331–5.
60. Kopylov U, Nemeth A, Koulaouzidis A, et al. Small bowel capsule endoscopy in the management of established Crohn's disease: clinical impact, safety, and correlation with inflammatory biomarkers. *Inflamm Bowel Dis* 2015;21:93–100.
61. Kopylov U, Yablecovitch D, Lahat A, et al. Detection of small bowel mucosal healing and deep remission in patients with known small bowel Crohn's disease using biomarkers, capsule endoscopy, and imaging. *Am J Gastroenterol* 2015;110:1316–23.
62. Kopylov U, Yung DE, Engel T, et al. Fecal calprotectin for the prediction of small bowel Crohn's disease by capsule endoscopy: a systematic review and meta-analysis. *Eur J Gastroenterol Hepatol* 2016;28:1137–44.
63. Gölder SK, Schreyer AG, Endlicher E, et al. Comparison of capsule endoscopy and magnetic resonance [MR] enteroclysis in suspected small bowel disease. *Int J Colorectal Dis* 2006;21:97–104.
64. Triester SL, Leighton JA, Leontiadis GI, et al. A meta-analysis of the yield of capsule endoscopy compared to other diagnostic modalities in patients with non-stricturing small bowel Crohn's disease. *Am J Gastroenterol* 2006;101:954–64.
65. Van Weyenberg SJ, Bouman K, Jacobs MA, et al. Comparison of MR enteroclysis with video capsule endoscopy in the investigation of small-intestinal disease. *Abdom Imaging* 2013;38:42–51.
66. Postgate AJ, Burling D, Gupta A, Fitzpatrick A, Fraser C. Safety, reliability and limitations of the given patency capsule in patients at risk of capsule retention: a 3-year technical review. *Dig Dis Sci* 2008;53:2732–8.
67. Cheifetz AS, Kornbluth AA, Legnani P, et al. The risk of retention of the capsule endoscope in patients with known or suspected Crohn's disease. *Am J Gastroenterol* 2006;101:2218–22.
68. Liao Z, Gao R, Xu C, Li ZS. Indications and detection, completion, and retention rates of small bowel capsule endoscopy: a systematic review. *Gastrointest Endosc* 2010;71:280–6.
69. Höög CM, Bark LÅ, Arkani J, Gorsetman J, Broström O, Sjöqvist U. Capsule retentions and incomplete capsule endoscopy examinations: an analysis of 2300 examinations. *Gastroenterol Res Pract* 2012;2012:518718.
70. Nemeth A, Kopylov U, Koulaouzidis A, et al. Use of patency capsule in patients with established Crohn's disease. *Endoscopy* 2016;48:373–9.
71. Lewis BS. Expanding role of capsule endoscopy in inflammatory bowel disease. *World J Gastroenterol* 2008;14:4137–41.
72. Yadav A, Heigh RI, Hara AK, et al. Performance of the patency capsule compared with nonenteroclysis radiologic examinations in patients with known or suspected intestinal strictures. *Gastrointest Endosc* 2011;74:834–9.
73. Jensen MD, Brodersen JB, Kjeldsen J. Capsule endoscopy for the diagnosis and follow up of Crohn's disease: a comprehensive review of current status. *Ann Gastroenterol* 2017;30:168–78.
74. Rutgeerts P, Onette E, Vantrappen G, Geboes K, Broeckaert L, Talloen L. Crohn's disease of the stomach and duodenum: A clinical study with emphasis on the value of endoscopy and endoscopic biopsies. *Endoscopy* 1980;12:288–94.
75. Wagtmans MJ, van Hogezaand RA, Griffioen G, Verspaget HW, Lamers CB. Crohn's disease of the upper gastrointestinal tract. *Neth J Med* 1997;50:S2–7.
76. Witte AM, Veendaal RA, Van Hogezaand RA, Verspaget HW, Lamers CB. Crohn's disease of the upper gastrointestinal tract: the value of endoscopic examination. *Scand J Gastroenterol Suppl* 1998;225:100–5.
77. Annunziata ML, Caviglia R, Papparella LG, Cicala M. Upper gastrointestinal involvement of Crohn's disease: a prospective study on the role of upper endoscopy in the diagnostic work-up. *Dig Dis Sci* 2012;57:1618–23.
78. Casella G, D'Inca R, Oliva L, et al.; Italian Group IBD. Prevalence of celiac disease in inflammatory bowel diseases: an IG-IBD multicentre study. *Dig Liver Dis* 2010;42:175–8.
79. Samuel S, Bruining DH, Loftus EV Jr, et al. Endoscopic skipping of the distal terminal ileum in Crohn's disease can lead to negative results from ileocolonoscopy. *Clin Gastroenterol Hepatol* 2012;10:1253–9.
80. Qiu Y, Mao R, Chen BL, et al. Systematic review with meta-analysis: magnetic resonance enterography vs. computed tomography enterography for evaluating disease activity in small bowel Crohn's disease. *Aliment Pharmacol Ther* 2014;40:134–46.
81. Panés J, Bouzas R, Chaparro M, et al. Systematic review: the use of ultrasonography, computed tomography and magnetic resonance imaging for the diagnosis, assessment of activity and abdominal complications of Crohn's disease. *Aliment Pharmacol Ther* 2011;34:125–45.
82. Fiorino G, Bonifacio C, Peyrin-Biroulet L, et al. Prospective comparison of computed tomography enterography and magnetic resonance enterography for assessment of disease activity and complications in ileocolonic Crohn's disease. *Inflamm Bowel Dis* 2011;17:1073–80.
83. Puylaert CA, Tielbeek JA, Bipat S, Stoker J. Grading of Crohn's disease activity using CT, MRI, US and scintigraphy: a meta-analysis. *Eur Radiol* 2015;25:3295–313.
84. Messaris E, Chandolias N, Grand D, Pricolo V. Role of magnetic resonance enterography in the management of Crohn disease. *Arch Surg* 2010;145:471–5.
85. Mendoza JL, González-Lama Y, Taxonera C, et al. Using of magnetic resonance enterography in the management of Crohn's disease of the small intestine: first year of experience. *Rev Esp Enferm Dig* 2012;104:578–83.
86. Castiglione F, Mainenti PP, De Palma GD, et al. Noninvasive diagnosis of small bowel Crohn's disease: direct comparison of bowel sonography and magnetic resonance enterography. *Inflamm Bowel Dis* 2013;19:991–8.
87. Taylor SA, Mallett S, Bhatnagar G, et al.; METRIC study investigators. Diagnostic accuracy of magnetic resonance enterography and small bowel ultrasound for the extent and activity of newly diagnosed and relapsed Crohn's disease [METRIC]: a multicentre trial. *Lancet Gastroenterol Hepatol* 2018;3:548–58.
88. Calabrese E, Maaser C, Zorzi F, et al. Bowel ultrasonography in the management of Crohn's disease. A review with recommendations of an international panel of experts. *Inflamm Bowel Dis* 2016;22:1168–83.
89. Choi M, Lim S, Choi MG, Shim KN, Lee SH. Effectiveness of capsule endoscopy compared with other diagnostic modalities in patients with small bowel Crohn's disease: a meta-analysis. *Gut Liver* 2017;11:62–72.
90. Mow WS, Lo SK, Targan SR, et al. Initial experience with wireless capsule endoscopy in the diagnosis and management of inflammatory bowel disease. *Clin Gastroenterol Hepatol* 2004;2:31–40.
91. Mehdizadeh S, Chen G, Enayati PJ, et al. Diagnostic yield of capsule endoscopy in ulcerative colitis and inflammatory bowel disease of unclassified type [IBDU]. *Endoscopy* 2008;40:30–5.
92. Maunoury V, Savoye G, Bourreille A, et al. Value of wireless capsule endoscopy in patients with indeterminate colitis [inflammatory bowel disease type unclassified]. *Inflamm Bowel Dis* 2007;13:152–5.
93. Cohen SA, Gralnek IM, Ephrath H, et al. Capsule endoscopy may reclassify pediatric inflammatory bowel disease: a historical analysis. *J Pediatr Gastroenterol Nutr* 2008;47:31–6.
94. Higurashi T, Endo H, Yoneda M, et al. Capsule-endoscopic findings of ulcerative colitis patients. *Digestion* 2011;84:306–14.
95. Monteiro S, Dias de Castro F, Boal Carvalho P, et al. Essential role of small bowel capsule endoscopy in reclassification of colonic inflammatory bowel disease type unclassified. *World J Gastrointest Endosc* 2017;9:34–40.

96. Keighley MR, Allan RN. Current status and influence of operation on perianal Crohn's disease. *Int J Colorectal Dis* 1986;1:104–7.
97. Hellers G, Bergstrand O, Ewerth S, Holmström B. Occurrence and outcome after primary treatment of anal fistulae in Crohn's disease. *Gut* 1980;21:525–7.
98. Schwartz DA, Loftus EV Jr, Tremaine WJ, et al. The natural history of fistulizing Crohn's disease in Olmsted County, Minnesota. *Gastroenterology* 2002;122:875–80.
99. Tang LY, Rawsthorne P, Bernstein CN. Are perineal and luminal fistulas associated in Crohn's disease? A population-based study. *Clin Gastroenterol Hepatol* 2006;4:1130–4.
100. Panes J, Bouhnik Y, Reinisch W, et al. Imaging techniques for assessment of inflammatory bowel disease: joint ECCO and ESGAR evidence-based consensus guidelines. *J Crohns Colitis* 2013;7:556–85.
101. Sandborn WJ, Fazio VW, Feagan BG, Hanauer SB; American Gastroenterological Association Clinical Practice Committee. AGA technical review on perianal Crohn's disease. *Gastroenterology* 2003;125:1508–30.
102. Makowiec F, Jehle EC, Becker HD, Starlinger M. Perianal abscess in Crohn's disease. *Dis Colon Rectum* 1997;40:443–50.
103. Regueiro M. The role of endoscopy in the evaluation of fistulizing Crohn's disease. *Gastrointest Endosc Clin N Am* 2002;12:621–33.
104. Adler SN, Yoav M, Eitan S, Yehuda C, Eliakim R. Does capsule endoscopy have an added value in patients with perianal disease and a negative work up for Crohn's disease? *World J Gastrointest Endosc* 2012;4:185–8.
105. Gionchetti P, Dignass A, Danese S, et al.; ECCO. Third European evidence-based consensus on the diagnosis and management of Crohn's disease 2016. Part 2: Surgical management and special situations. *J Crohns Colitis* 2017;11:135–49.
106. Bell SJ, Williams AB, Wiesel P, Wilkinson K, Cohen RC, Kamm MA. The clinical course of fistulating Crohn's disease. *Aliment Pharmacol Ther* 2003;17:1145–51.
107. Frøslie KF, Jahnsen J, Moum BA, Vatn MH; IBSEN Group. Mucosal healing in inflammatory bowel disease: results from a Norwegian population-based cohort. *Gastroenterology* 2007;133:412–22.
108. Shah SC, Colombel JF, Sands BE, Narula N. Mucosal healing is associated with improved long-term outcomes of patients with ulcerative colitis: a systematic review and meta-analysis. *Clin Gastroenterol Hepatol* 2016;14:1245–55.e8.
109. Peyrin-Biroulet L, Sandborn W, Sands BE, et al. Selecting therapeutic targets in Inflammatory Bowel Disease [STRIDE]: determining therapeutic goals for treat-to-target. *Am J Gastroenterol* 2015;110:1324–38.
110. Cholakpranee A, Hazlewood GS, Kaplan GG, Peyrin-Biroulet L, Ananthakrishnan AN. Systematic review with meta-analysis: comparative efficacy of biologics for induction and maintenance of mucosal healing in Crohn's disease and ulcerative colitis controlled trials. *Aliment Pharmacol Ther* 2017;45:1291–302.
111. Mosli MH, Zou G, Garg SK, et al. C-reactive protein, fecal calprotectin, and stool lactoferrin for detection of endoscopic activity in symptomatic inflammatory bowel disease patients: a systematic review and meta-analysis. *Am J Gastroenterol* 2015;110:802–19; quiz 820.
112. Zittan E, Kelly OB, Kirsch R, et al. Low fecal calprotectin correlates with histological remission and mucosal healing in ulcerative colitis and colonic Crohn's disease. *Inflamm Bowel Dis* 2016;22:623–30.
113. Lee SH, Kim MJ, Chang K, et al. Fecal calprotectin predicts complete mucosal healing and better correlates with the ulcerative colitis endoscopic index of severity than with the Mayo endoscopic subscore in patients with ulcerative colitis. *BMC Gastroenterol* 2017;17:110.
114. Patel A, Panchal H, Dubinsky MC. Fecal calprotectin levels predict histological healing in ulcerative colitis. *Inflamm Bowel Dis* 2017;23:1600–4.
115. Parente F, Greco S, Molteni M, et al. Role of early ultrasound in detecting inflammatory intestinal disorders and identifying their anatomical location within the bowel. *Aliment Pharmacol Ther* 2003;18:1009–16.
116. Parente F, Molteni M, Marino B, et al. Are colonoscopy and bowel ultrasound useful for assessing response to short-term therapy and predicting disease outcome of moderate-to-severe forms of ulcerative colitis?: a prospective study. *Am J Gastroenterol* 2010;105:1150–7.
117. Bremner AR, Griffiths M, Argent JD, Fairhurst JJ, Beattie RM. Sonographic evaluation of inflammatory bowel disease: a prospective, blinded, comparative study. *Pediatr Radiol* 2006;36:947–53.
118. Yamamoto T, Shimoyama T, Matsumoto K. Consecutive monitoring of faecal calprotectin during mesalazine suppository therapy for active rectal inflammation in ulcerative colitis. *Aliment Pharmacol Ther* 2015;42:549–58.
119. Ellrichmann M, Wietzke-Braun P, Dhar S, et al. Endoscopic ultrasound of the colon for the differentiation of Crohn's disease and ulcerative colitis in comparison with healthy controls. *Aliment Pharmacol Ther* 2014;39:823–33.
120. Nozue T, Kobayashi A, Takagi Y, Okabe H, Hasegawa M. Assessment of disease activity and extent by magnetic resonance imaging in ulcerative colitis. *Pediatr Int* 2000;42:285–8.
121. Ajaj WM, Lauenstein TC, Pelster G, et al. Magnetic resonance colonography for the detection of inflammatory diseases of the large bowel: quantifying the inflammatory activity. *Gut* 2005;54:257–63.
122. Langhorst J, Kühle CA, Ajaj W, et al. MR colonography without bowel purgation for the assessment of inflammatory bowel diseases: diagnostic accuracy and patient acceptance. *Inflamm Bowel Dis* 2007;13:1001–8.
123. Oussalah A, Laurent V, Bruot O, et al. Diffusion-weighted magnetic resonance without bowel preparation for detecting colonic inflammation in inflammatory bowel disease. *Gut* 2010;59:1056–65.
124. Baert F, Moortgat L, Van Assche G, et al.; Belgian Inflammatory Bowel Disease Research Group; North-Holland Gut Club. Mucosal healing predicts sustained clinical remission in patients with early-stage Crohn's disease. *Gastroenterology* 2010;138:463–8; quiz e10–1.
125. Colombel JF, Sandborn WJ, Reinisch W, et al.; SONIC Study Group. Infliximab, azathioprine, or combination therapy for Crohn's disease. *N Engl J Med* 2010;362:1383–95.
126. Colombel JF, Rutgeerts PJ, Sandborn WJ, et al. Adalimumab induces deep remission in patients with Crohn's disease. *Clin Gastroenterol Hepatol* 2014;12:414–22.e5.
127. Colombel JF, Reinisch W, Mantzaris GJ, et al. Randomised clinical trial: deep remission in biologic and immunomodulator naïve patients with Crohn's disease a SONIC post hoc analysis. *Aliment Pharmacol Ther* 2015;41:734–46.
128. Carvalho PB, Rosa B, Cotter J. Mucosal healing in Crohn's disease are we reaching as far as possible with capsule endoscopy? *J Crohns Colitis* 2014;8:1566–7.
129. Peyrin-Biroulet L, Reinisch W, Colombel JF, et al. Clinical disease activity, C-reactive protein normalisation and mucosal healing in Crohn's disease in the SONIC trial. *Gut* 2014;63:88–95.
130. Kiss LS, Szamosi T, Molnar T, et al.; Hungarian IBD Study Group. Early clinical remission and normalisation of CRP are the strongest predictors of efficacy, mucosal healing and dose escalation during the first year of adalimumab therapy in Crohn's disease. *Aliment Pharmacol Ther* 2011;34:911–22.
131. Parente F, Greco S, Molteni M, et al. Oral contrast enhanced bowel ultrasonography in the assessment of small intestine Crohn's disease. A prospective comparison with conventional ultrasound, x ray studies, and ileocolonoscopy. *Gut* 2004;53:1652–7.
132. Kucharzik T, Wittig BM, Helwig U, et al.; TRUST study group. Use of intestinal ultrasound to monitor Crohn's disease activity. *Clin Gastroenterol Hepatol* 2017;15:535–42.e2.
133. Saevik F, Nylund K, Hausken T, Ødegaard S, Gilja OH. Bowel perfusion measured with dynamic contrast-enhanced ultrasound predicts treatment outcome in patients with Crohn's disease. *Inflamm Bowel Dis* 2014;20:2029–37.
134. Castiglione F, Testa A, Rea M, et al. Transmural healing evaluated by bowel sonography in patients with Crohn's disease on maintenance treatment with biologics. *Inflamm Bowel Dis* 2013;19:1928–34.
135. Civitelli F, Nuti F, Oliva S, et al. Looking beyond mucosal healing: effect of biologic therapy on transmural healing in pediatric Crohn's disease. *Inflamm Bowel Dis* 2016;22:2418–24.
136. Ripollés T, Paredes JM, Martínez-Pérez MJ, et al. Ultrasonographic changes at 12 weeks of anti-TNF drugs predict 1-year sonographic

- response and clinical outcome in Crohn's disease: a multicenter study. *Inflamm Bowel Dis* 2016;22:2465–73.
137. Bruining DH, Loftus EV Jr, Ehman EC, et al. Computed tomography enterography detects intestinal wall changes and effects of treatment in patients with Crohn's disease. *Clin Gastroenterol Hepatol* 2011;9:679–83.e1.
 138. Ordás I, Rimola J, Rodríguez S, et al. Accuracy of magnetic resonance enterography in assessing response to therapy and mucosal healing in patients with Crohn's disease. *Gastroenterology* 2014;146:374–82.e1.
 139. Tielbeek JA, Löwenberg M, Bipat S, et al. Serial magnetic resonance imaging for monitoring medical therapy effects in Crohn's disease. *Inflamm Bowel Dis* 2013;19:1943–50.
 140. Stoppino LP, Della Valle N, Rizzi S, et al. Magnetic resonance enterography changes after antibody to tumor necrosis factor [anti-TNF] alpha therapy in Crohn's disease: correlation with SES-CD and clinical-biological markers. *BMC Med Imaging* 2016;16:37.
 141. Paredes JM, Ripollés T, Cortés X, et al. Abdominal sonographic changes after antibody to tumor necrosis factor [anti-TNF] alpha therapy in Crohn's Disease. *Dig Dis Sci* 2010;55:404–10.
 142. Moreno N, Ripollés T, Paredes JM, et al. Usefulness of abdominal ultrasonography in the analysis of endoscopic activity in patients with Crohn's disease: changes following treatment with immunomodulators and/or anti-TNF antibodies. *J Crohns Colitis* 2014;8:1079–87.
 143. Ripollés T, Paredes Arquiola JM, Moreno-Osset E. Ultrasonography and transmural healing in Crohn's disease. *Clin Gastroenterol Hepatol* 2015;13:1549–51.
 144. Church PC, Turner D, Feldman BM, et al.; ImageKids Study Group. Systematic review with meta-analysis: magnetic resonance enterography signs for the detection of inflammation and intestinal damage in Crohn's disease. *Aliment Pharmacol Ther* 2015;41:153–66.
 145. Deepak P, Fletcher JG, Fidler JL, et al. Radiological response is associated with better long-term outcomes and is a potential treatment target in patients with small bowel Crohn's Disease. *Am J Gastroenterol* 2016;111:997–1006.
 146. Jensen MD, Nathan T, Rafaelsen SR, Kjeldsen J. Diagnostic accuracy of capsule endoscopy for small bowel Crohn's disease is superior to that of MR enterography or CT enterography. *Clin Gastroenterol Hepatol* 2011;9:124–9.
 147. Efthymiou A, Viazis N, Mantzaris G, et al. Does clinical response correlate with mucosal healing in patients with Crohn's disease of the small bowel? A prospective, case-series study using wireless capsule endoscopy. *Inflamm Bowel Dis* 2008;14:1542–7.
 148. Hall B, Holleran G, Chin JL, et al. A prospective 52-week mucosal healing assessment of small bowel Crohn's disease as detected by capsule endoscopy. *J Crohns Colitis* 2014;8:1601–9.
 149. Niv Y, Ilani S, Levi Z, et al. Validation of the Capsule Endoscopy Crohn's Disease Activity Index [CECDAI or Niv score]: a multicenter prospective study. *Endoscopy* 2012;44:21–6.
 150. Gralnek IM, Defranchis R, Seidman E, Leighton JA, Legnani P, Lewis BS. Development of a capsule endoscopy scoring index for small bowel mucosal inflammatory change. *Aliment Pharmacol Ther* 2008;27:146–54.
 151. Turner D, Griffiths AM. Esophageal, gastric, and duodenal manifestations of IBD and the role of upper endoscopy in IBD diagnosis. *Curr Gastroenterol Rep* 2007;9:475–8.
 152. Diaz L, Hernandez-Oquet RE, Deshpande AR, Moshiree B. Upper gastrointestinal involvement in Crohn disease: histopathologic and endoscopic findings. *South Med J* 2015;108:695–700.
 153. Attwood SE, Lamb CA. Eosinophilic oesophagitis and other non-reflux inflammatory conditions of the oesophagus: diagnostic imaging and management. *Best Pract Res Clin Gastroenterol* 2008;22:639–60.
 154. Horsthuis K, Bipat S, Stokkers PC, Stoker J. Magnetic resonance imaging for evaluation of disease activity in Crohn's disease: a systematic review. *Eur Radiol* 2009;19:1450–60.
 155. Desmond AN, O'Regan K, Curran C, et al. Crohn's disease: factors associated with exposure to high levels of diagnostic radiation. *Gut* 2008;57:1524–9.
 156. Sandborn WJ, Feagan BG, Hanauer SB, et al. A review of activity indices and efficacy endpoints for clinical trials of medical therapy in adults with Crohn's disease. *Gastroenterology* 2002;122:512–30.
 157. Irvine EJ. Usual therapy improves perianal Crohn's disease as measured by a new disease activity index. McMaster IBD Study Group. *J Clin Gastroenterol* 1995;20:27–32.
 158. Schoepfer AM, Vavricka SR, Binek J, et al.; Swiss IBDnet. Efficacy and safety of certolizumab pegol induction therapy in an unselected Crohn's disease population: results of the FACTS survey. *Inflamm Bowel Dis* 2010;16:933–8.
 159. Sands BE, Anderson FH, Bernstein CN, et al. Infliximab maintenance therapy for fistulizing Crohn's disease. *N Engl J Med* 2004;350:876–85.
 160. Sandborn WJ, Present DH, Isaacs KL, et al. Tacrolimus for the treatment of fistulas in patients with Crohn's disease: a randomized, placebo-controlled trial. *Gastroenterology* 2003;125:380–8.
 161. Pikarsky AJ, Gervaz P, Wexner SD. Perianal Crohn disease: a new scoring system to evaluate and predict outcome of surgical intervention. *Arch Surg* 2002;137:774–7; discussion 778.
 162. Van Assche G, Vanbeckevoort D, Bielen D, et al. Magnetic resonance imaging of the effects of infliximab on perianal fistulizing Crohn's disease. *Am J Gastroenterol* 2003;98:332–9.
 163. Karmiris K, Bielen D, Vanbeckevoort D, et al. Long-term monitoring of infliximab therapy for perianal fistulizing Crohn's disease by using magnetic resonance imaging. *Clin Gastroenterol Hepatol* 2011;9:130–6.
 164. Savoye-Collet C, Savoye G, Koning E, Dacher JN, Lerebours E. Fistulizing perianal Crohn's disease: contrast-enhanced magnetic resonance imaging assessment at 1 year on maintenance anti-TNF-alpha therapy. *Inflamm Bowel Dis* 2011;17:1751–8.
 165. Horsthuis K, Lavini C, Bipat S, Stokkers PC, Stoker J. Perianal Crohn disease: evaluation of dynamic contrast-enhanced MR imaging as an indicator of disease activity. *Radiology* 2009;251:380–7.
 166. Ng SC, Plamondon S, Gupta A, et al. Prospective evaluation of anti-tumor necrosis factor therapy guided by magnetic resonance imaging for Crohn's perineal fistulas. *Am J Gastroenterol* 2009;104:2973–86.
 167. Spradlin NM, Wise PE, Herline AJ, Muldoon RL, Rosen M, Schwartz DA. A randomized prospective trial of endoscopic ultrasound to guide combination medical and surgical treatment for Crohn's perianal fistulas. *Am J Gastroenterol* 2008;103:2527–35.
 168. Guidi L, Ratto C, Semeraro S, et al. Combined therapy with infliximab and seton drainage for perianal fistulizing Crohn's disease with anal endosonographic monitoring: a single-centre experience. *Tech Coloproctol* 2008;12:111–7.
 169. Schwartz DA, Wiersema MJ, Dudiak KM, et al. A comparison of endoscopic ultrasound, magnetic resonance imaging, and exam under anesthesia for evaluation of Crohn's perianal fistulas. *Gastroenterology* 2001;121:1064–72.
 170. Buchanan GN, Halligan S, Bartram CI, Williams AB, Tarroni D, Cohen CR. Clinical examination, endosonography, and MR imaging in preoperative assessment of fistula in ano: comparison with outcome-based reference standard. *Radiology* 2004;233:674–81.
 171. Siddiqui MR, Ashrafiyan H, Tozer P, et al. A diagnostic accuracy meta-analysis of endoanal ultrasound and MRI for perianal fistula assessment. *Dis Colon Rectum* 2012;55:576–85.
 172. Gece KB, Bemelman W, Kamm MA, et al.; World Gastroenterology Organization, International Organisation for Inflammatory Bowel Diseases IOIBD, European Society of Coloproctology, Robarts Clinical Trials. A global consensus on the classification, diagnosis and multidisciplinary treatment of perianal fistulizing Crohn's disease. *Gut* 2014;63:1381–92.
 173. Maconi G, Ardizzone S, Greco S, Radice E, Bezzio C, Bianchi Porro G. Transperineal ultrasound in the detection of perianal and rectovaginal fistulae in Crohn's disease. *Am J Gastroenterol* 2007;102:2214–9.
 174. Ben-Horin S, Chowers Y. Review article: loss of response to anti-TNF treatments in Crohn's disease. *Aliment Pharmacol Ther* 2011;33:987–95.
 175. Yanai H, Lichtenstein L, Assa A, et al. Levels of drug and antidrug antibodies are associated with outcome of interventions after loss of response

- to infliximab or adalimumab. *Clin Gastroenterol Hepatol* 2015;13:522–30.e2.
176. Ordás I, Mould DR, Feagan BG, Sandborn WJ. Anti-TNF monoclonal antibodies in inflammatory bowel disease: pharmacokinetics-based dosing paradigms. *Clin Pharmacol Ther* 2012;91:635–46.
 177. Vande Casteele N, Khanna R, Levesque BG, *et al.* The relationship between infliximab concentrations, antibodies to infliximab and disease activity in Crohn's disease. *Gut* 2015;64:1539–45.
 178. Radstake TR, Svenson M, Eijbsbouts AM, *et al.* Formation of antibodies against infliximab and adalimumab strongly correlates with functional drug levels and clinical responses in rheumatoid arthritis. *Ann Rheum Dis* 2009;68:1739–45.
 179. Moore C, Corbett G, Moss AC. Systematic review and meta-analysis: serum infliximab levels during maintenance therapy and outcomes in inflammatory bowel disease. *J Crohns Colitis* 2016;10:619–25.
 180. Harzallah I, Rigaij J, Williet N, Paul S, Roblin X. Golimumab pharmacokinetics in ulcerative colitis: a literature review. *Therap Adv Gastroenterol* 2017;10:89–100.
 181. Karmiris K, Painsaud G, Noman M, *et al.* Influence of trough serum levels and immunogenicity on long-term outcome of adalimumab therapy in Crohn's disease. *Gastroenterology* 2009;137:1628–40.
 182. Vande Casteele N, Ferrante M, Van Assche G, *et al.* Trough concentrations of infliximab guide dosing for patients with inflammatory bowel disease. *Gastroenterology* 2015;148:1320–9.e3.
 183. Zittan E, Kabakchiev B, Milgrom R, *et al.* Higher adalimumab drug levels are associated with mucosal healing in patients with Crohn's disease. *J Crohns Colitis* 2016;10:510–5.
 184. Brandse JF, van den Brink GR, Wildenberg ME, *et al.* Loss of infliximab into feces is associated with lack of response to therapy in patients with severe ulcerative colitis. *Gastroenterology* 2015;149:350–5.e2.
 185. Haines ML, Ajlouni Y, Irving PM, *et al.* Clinical usefulness of therapeutic drug monitoring of thiopurines in patients with inadequately controlled inflammatory bowel disease. *Inflamm Bowel Dis* 2011;17:1301–7.
 186. Heida A, Park KT, van Rheeën PF. Clinical utility of fecal calprotectin monitoring in asymptomatic patients with inflammatory bowel disease: a systematic review and practical guide. *Inflamm Bowel Dis* 2017;23:894–902.
 187. Yamamoto T, Shimoyama T, Umegae S, Matsumoto K. Serial monitoring of faecal calprotectin for the assessment of endoscopic recurrence in asymptomatic patients after ileocolonic resection for Crohn's disease: a long-term prospective study. *Therap Adv Gastroenterol* 2016;9:664–70.
 188. Zhulina Y, Cao Y, Amcoff K, Carlson M, Tysk C, Halfvarson J. The prognostic significance of faecal calprotectin in patients with inactive inflammatory bowel disease. *Aliment Pharmacol Ther* 2016;44:495–504.
 189. Langhorst J, Boone J, Lauche R, Rueffer A, Dobos G. Faecal lactoferrin, calprotectin, PMN-elasticase, CRP, and white blood cell count as indicators for mucosal healing and clinical course of disease in patients with mild to moderate ulcerative colitis: post hoc analysis of a prospective clinical trial. *J Crohns Colitis* 2016;10:786–94.
 190. Ferreira-Iglesias R, Barreiro-de Acosta M, Otero Santiago M, *et al.* Fecal calprotectin as predictor of relapse in patients with inflammatory bowel disease under maintenance infliximab therapy. *J Clin Gastroenterol* 2016;50:147–51.
 191. De Vos M, Dewit O, D'Haens G, *et al.*; on behalf of BIRD. Fast and sharp decrease in calprotectin predicts remission by infliximab in anti-TNF naïve patients with ulcerative colitis. *J Crohns Colitis* 2012;6:557–62.
 192. Mao R, Xiao YL, Gao X, *et al.* Fecal calprotectin in predicting relapse of inflammatory bowel diseases: a meta-analysis of prospective studies. *Inflamm Bowel Dis* 2012;18:1894–9.
 193. Theede K, Holck S, Ibsen P, Kallemose T, Nordgaard-Lassen I, Nielsen AM. Fecal calprotectin predicts relapse and histological mucosal healing in ulcerative colitis. *Inflamm Bowel Dis* 2016;22:1042–8.
 194. Lasson A, Öhman L, Stotzer PO, *et al.* Pharmacological intervention based on fecal calprotectin levels in patients with ulcerative colitis at high risk of a relapse: a prospective, randomized, controlled study. *United European Gastroenterol J* 2015;3:72–9.
 195. De Vos M, Louis EJ, Jahnsen J, *et al.* Consecutive fecal calprotectin measurements to predict relapse in patients with ulcerative colitis receiving infliximab maintenance therapy. *Inflamm Bowel Dis* 2013;19:2111–7.
 196. Diederer K, Hoekman DR, Leek A, *et al.* Raised faecal calprotectin is associated with subsequent symptomatic relapse, in children and adolescents with inflammatory bowel disease in clinical remission. *Aliment Pharmacol Ther* 2017;45:951–60.
 197. Du L, *et al.* Within-stool and within-day sample variability of fecal calprotectin in patients with inflammatory bowel disease: a prospective observational study. *J Clin Gastroenterol* 2018;52:235–40.
 198. Colombel JF, Panaccione R, Bossuyt P, *et al.* Effect of tight control management on Crohn's disease [CALM]: a multicentre, randomised, controlled phase 3 trial. *Lancet* 2018;390:2779–89.
 199. Glasziou P, Irwig L, Mant D. Monitoring in chronic disease: a rational approach. *BMJ* 2005;330:644–8.
 200. van Rheeën P. Do not read single calprotectin measurements in isolation when monitoring your patients with inflammatory bowel disease. *Inflamm Bowel Dis* 2014;20:1416–7.
 201. Zubin G, Peter L. Predicting endoscopic Crohn's disease activity before and after induction therapy in children: a comprehensive assessment of PCDAI, CRP, and fecal calprotectin. *Inflamm Bowel Dis* 2015;21:1386–91.
 202. Wright EK, Kamm MA, De Cruz P, *et al.* Comparison of fecal inflammatory markers in Crohn's disease. *Inflamm Bowel Dis* 2016;22:1086–94.
 203. Höög CM, Bark LÅ, Broström O, Sjöqvist U. Capsule endoscopic findings correlate with fecal calprotectin and C-reactive protein in patients with suspected small bowel Crohn's disease. *Scand J Gastroenterol* 2014;49:1084–90.
 204. Bar-Gil Shitrit A, Koslowsky B, Livoversusky DM, *et al.* A prospective study of fecal calprotectin and lactoferrin as predictors of small bowel Crohn's disease in patients undergoing capsule endoscopy. *Scand J Gastroenterol* 2017;52:328–33.
 205. Greener T, Klang E, Yablecovitch D, *et al.*; Israeli IBD Research Nucleus [IIRN]. The impact of magnetic resonance enterography and capsule endoscopy on the re-classification of disease in patients with known Crohn's disease: a prospective Israeli IBD Research Nucleus [IIRN] Study. *J Crohns Colitis* 2016;10:525–31.
 206. Yoon HM, Suh CH, Kim JR, *et al.* Diagnostic performance of magnetic resonance enterography for detection of active inflammation in children and adolescents with inflammatory bowel disease: a systematic review and diagnostic meta-analysis. *JAMA Pediatr* 2017;171:1208–16.
 207. Mocchi G, Migaletto V, Cabras F, *et al.* SICUS and CEUS imaging in Crohn's disease: an update. *J Ultrasound* 2017;20:1–9.
 208. Kucharzik T, Kannengiesser K, Petersen F. The use of ultrasound in inflammatory bowel disease. *Ann Gastroenterol* 2017;30:135–44.
 209. Barber JL, Maclachlan J, Planche K, *et al.* There is good agreement between MR enterography and bowel ultrasound with regards to disease location and activity in paediatric inflammatory bowel disease. *Clin Radiol* 2017;72:590–7.
 210. Torres J, Boyapati RK, Kennedy NA, Louis E, Colombel JF, Satsangi J. Systematic review of effects of withdrawal of immunomodulators or biologic agents from patients with inflammatory bowel disease. *Gastroenterology* 2015;149:1716–30.
 211. Gisbert JP, Marín AC, Chaparro M. The risk of relapse after anti-TNF discontinuation in inflammatory bowel disease: systematic review and meta-analysis. *Am J Gastroenterol* 2016;111:632–47.
 212. Kennedy NA, Warner B, Johnston EL, *et al.*; UK Anti-TNF Withdrawal Study Group. Relapse after withdrawal from anti-TNF therapy for inflammatory bowel disease: an observational study, plus systematic review and meta-analysis. *Aliment Pharmacol Ther* 2016;43:910–23.
 213. Lémann M, Mary JY, Colombel JF, *et al.*; Groupe D'Etude Thérapeutique des Affections Inflammatoires du Tube Digestif. A randomized, double-blind, controlled withdrawal trial in Crohn's disease patients in long-term remission on azathioprine. *Gastroenterology* 2005;128:1812–8.
 214. Louis E, Mary JY, Vernier-Massouille G, *et al.* Maintenance of remission among patients with Crohn's disease on antimetabolite therapy after infliximab therapy is stopped. *Gastroenterology* 2012;142:63–70.

215. Ihekweazu FD, Ajjarapu A, Kellermayer R. Diagnostic yield of routine enteropathogenic stool tests in pediatric ulcerative colitis. *Ann Clin Lab Sci* 2015;45:639–42.
216. Roy A, Lichtiger S. Clostridium difficile infection: a rarity in patients receiving chronic antibiotic treatment for Crohn's disease. *Inflamm Bowel Dis* 2016;22:648–53.
217. Navaneethan U, Mukewar S, Venkatesh PG, Lopez R, Shen B. Clostridium difficile infection is associated with worse long term outcome in patients with ulcerative colitis. *J Crohns Colitis* 2012;6:330–6.
218. Negrón ME, Barkema HW, Rioux K, et al. Clostridium difficile infection worsens the prognosis of ulcerative colitis. *Can J Gastroenterol Hepatol* 2014;28:373–80.
219. Negrón ME, Rezaie A, Barkema HW, et al. Ulcerative colitis patients with clostridium difficile are at increased risk of death, colectomy, and postoperative complications: a population-based inception cohort study. *Am J Gastroenterol* 2016;111:691–704.
220. Knösel T, Schewe C, Petersen N, Dietel M, Petersen I. Prevalence of infectious pathogens in Crohn's disease. *Pathol Res Pract* 2009;205:223–30.
221. Banerjee D, Deb R, Dar L, et al. High frequency of parasitic and viral stool pathogens in patients with active ulcerative colitis: report from a tropical country. *Scand J Gastroenterol* 2009;44:325–31.
222. Zhang WX, Ma CY, Zhang JG, et al. Effects of cytomegalovirus infection on the prognosis of inflammatory bowel disease patients. *Exp Ther Med* 2016;12:3287–93.
223. Shukla T, et al. Corticosteroids and thiopurines, but not tumor necrosis factor antagonists, are associated with cytomegalovirus reactivation in inflammatory bowel disease: a systematic review and meta-analysis. *J Clin Gastroenterol* 2017;51:394–401.
224. Kandiel A, Lashner B. Cytomegalovirus colitis complicating inflammatory bowel disease. *Am J Gastroenterol* 2006;101:2857–65.
225. Kopylov U, Papamichael K, Katsanos K, et al. Impact of infliximab and cyclosporine on the risk of colectomy in hospitalized patients with ulcerative colitis complicated by Cytomegalovirus A multicenter retrospective study. *Inflamm Bowel Dis* 2017;23:1605–13.
226. Jensen MD, Kjeldsen J, Nathan T. Fecal calprotectin is equally sensitive in Crohn's disease affecting the small bowel and colon. *Scand J Gastroenterol* 2011;46:694–700.
227. Arai T, Takeuchi K, Miyamura M, et al. Level of fecal calprotectin correlates with severe small bowel Crohn's disease, measured by balloon-assisted enteroscopy and computed tomography enterography. *Clin Gastroenterol Hepatol* 2017;15:56–62.
228. Egea Valenzuela J, Pereñíguez López A, Pérez Fernández V, Alberca de Las Parras F, Carballo Álvarez F. Fecal calprotectin and C-reactive protein are associated with positive findings in capsule endoscopy in suspected small bowel Crohn's disease. *Rev Esp Enferm Dig* 2016;108:394–400.
229. Costa F, Mumolo MG, Ceccarelli L, et al. Calprotectin is a stronger predictive marker of relapse in ulcerative colitis than in Crohn's disease. *Gut* 2005;54:364–8.
230. Moniuszko A, Głuszek S, Rydzewska G. Rapid fecal calprotectin test for prediction of mucosal inflammation in ulcerative colitis and Crohn disease: a prospective cohort study. *Pol Arch Intern Med* 2017;127:312–8.
231. Schoepfer AM, Beglinger C, Straumann A, et al. Fecal calprotectin correlates more closely with the Simple Endoscopic Score for Crohn's disease [SES-CD] than CRP, blood leukocytes, and the CDAI. *Am J Gastroenterol* 2010;105:162–9.
232. Narin B, Ajaj W, Göhde S, et al. Combined small and large bowel MR imaging in patients with Crohn's disease: a feasibility study. *Eur Radiol* 2004;14:1535–42.
233. Grand DJ, Kampalath V, Harris A, et al. MR enterography correlates highly with colonoscopy and histology for both distal ileal and colonic Crohn's disease in 310 patients. *Eur J Radiol* 2012;81:e763–9.
234. Narin B, Sungurlu F, Balci A, Arman A, Kurdas OO, Simsek M. Comparison of MR enteroclysis with colonoscopy in Crohn's disease—first locust bean gum study from Turkey. *Saudi J Gastroenterol* 2009;15:253–7.
235. Rimola J, Ordás I, Rodríguez S, Panés J. Colonic Crohn's disease: value of magnetic resonance colonography for detection and quantification of disease activity. *Abdom Imaging* 2010;35:422–7.
236. Röttgen R, Herzog H, Lopez-Häninnen E, Felix R. Bowel wall enhancement in magnetic resonance colonography for assessing activity in Crohn's disease. *Clin Imaging* 2006;30:27–31.
237. Hyun SB, Kitazume Y, Nagahori M, et al. Magnetic resonance enterocolonography is useful for simultaneous evaluation of small and large intestinal lesions in Crohn's disease. *Inflamm Bowel Dis* 2011;17:1063–72.
238. D'Haens G, Löwenberg M, Samaan MA, et al. Safety and feasibility of using the second-generation pillcam colon capsule to assess active colonic Crohn's disease. *Clin Gastroenterol Hepatol* 2015;13:1480–6.e3.
239. Negreanu L, Smarandache G, Mateescu RB. Role of capsule endoscopy Pillcam COLON 2 in patients with known or suspected Crohn's disease who refused colonoscopy or underwent incomplete colonoscopic exam: a case series. *Tech Coloproctol* 2014;18:277–83.
240. Shen B. Is it a prime time for small bowel colon video capsule endoscopy to cover both sides of the ileocecal valve in Crohn's disease? *Gastrointest Endosc* 2017;85:206–9.
241. Griffin N, Grant LA, Anderson S, Irving P, Sanderson J. Small bowel MR enterography: problem solving in Crohn's disease. *Insights Imaging* 2012;3:251–63.
242. Bickelhaupt S, Pazahr S, Chuck N, et al. Crohn's disease: small bowel motility impairment correlates with inflammatory-related markers C-reactive protein and calprotectin. *Neurogastroenterol Motil* 2013;25:467–73.
243. Fornasa F, Benassuti C, Benazzato L. Role of magnetic resonance enterography in differentiating between fibrotic and active inflammatory small bowel stenosis in patients with Crohn's disease. *J Clin Imaging Sci* 2011;1:35.
244. Giusti S, Faggioni L, Neri E, et al. Dynamic MRI of the small bowel: usefulness of quantitative contrast-enhancement parameters and time-signal intensity curves for differentiating between active and inactive Crohn's disease. *Abdom Imaging* 2010;35:646–53.
245. Hahnemann ML, Nensa F, Kinner S, et al. Quantitative assessment of small bowel motility in patients with Crohn's disease using dynamic MRI. *Neurogastroenterol Motil* 2015;27:841–8.
246. Iwańczak BM, Nienartowicz E, Krzesiek E. Assessment of magnetic resonance enterography in the diagnosis of small bowel diseases in children with Crohn's disease. *Adv Clin Exp Med* 2016;25:111–5.
247. Li XH, et al. Diffusion-weighted MRI enables to accurately grade inflammatory activity in patients of ileocolonic Crohn's disease: results from an observational study. *Inflamm Bowel Dis* 2017;23:244–53.
248. Li M, Dick A, Hassold N, et al. CAIPRINHA-accelerated T1w 3D-FLASH for small bowel MR imaging in pediatric patients with Crohn's disease: assessment of image quality and diagnostic performance. *World J Pediatr* 2016;12:455–62.
249. Ahmed O, Rodrigues DM, Nguyen GC. Magnetic resonance imaging of the small bowel in Crohn's disease: a systematic review and meta-analysis. *Can J Gastroenterol Hepatol* 2016;2016:7857352.
250. Cheriyan DG, Slattery E, McDermott S, et al. Impact of magnetic resonance enterography in the management of small bowel Crohn's disease. *Eur J Gastroenterol Hepatol* 2013;25:550–5.
251. Lang G, Schmiegel W, Nicolas V, Brechmann T. Impact of small bowel MRI in routine clinical practice on staging of Crohn's disease. *J Crohns Colitis* 2015;9:784–94.
252. Gourtsoyiannis NC, Grammatikakis J, Papamastorakis G, et al. Imaging of small intestinal Crohn's disease: comparison between MR enteroclysis and conventional enteroclysis. *Eur Radiol* 2006;16:1915–25.
253. Negaard A, Paulsen V, Sandvik L, et al. A prospective randomized comparison between two MRI studies of the small bowel in Crohn's disease, the oral contrast method and MR enteroclysis. *Eur Radiol* 2007;17:2294–301.
254. Negaard A, Sandvik L, Berstad AE, et al. MRI of the small bowel with oral contrast or nasojejunal intubation in Crohn's disease: randomized comparison of patient acceptance. *Scand J Gastroenterol* 2008;43:44–51.

255. Pallotta N, Civitelli F, Di Nardo G, *et al.* Small intestine contrast ultrasonography in pediatric Crohn's disease. *J Pediatr* 2013;163:778–84.e1.
256. Pallotta N, Vincoli G, Montesani C, *et al.* Small intestine contrast ultrasonography [SICUS] for the detection of small bowel complications in Crohn's disease: a prospective comparative study versus intraoperative findings. *Inflamm Bowel Dis* 2012;18:74–84.
257. Bhatnagar G, Von Stempel C, Halligan S, Taylor SA. Utility of MR enterography and ultrasound for the investigation of small bowel Crohn's disease. *J Magn Reson Imaging* 2017;45:1573–88.
258. Kumar S, Hakim A, Alexakis C, *et al.* Small intestinal contrast ultrasonography for the detection of small bowel complications in Crohn's disease: correlation with intraoperative findings and magnetic resonance enterography. *J Gastroenterol Hepatol* 2015;30:86–91.
259. Onali S, Calabrese E, Petruziello C, *et al.* Small intestine contrast ultrasonography versus computed tomography enteroclysis for assessing ileal Crohn's disease. *World J Gastroenterol* 2012;18:6088–95.
260. Aloï M, Di Nardo G, Romano G, *et al.* Magnetic resonance enterography, small-intestine contrast US, and capsule endoscopy to evaluate the small bowel in pediatric Crohn's disease: a prospective, blinded, comparison study. *Gastrointest Endosc* 2015;81:420–7.
261. Calabrese E, Zorzi F, Onali S, *et al.* Accuracy of small-intestine contrast ultrasonography, compared with computed tomography enteroclysis, in characterizing lesions in patients with Crohn's disease. *Clin Gastroenterol Hepatol* 2013;11:950–5.
262. Quaia E. Contrast-enhanced ultrasound of the small bowel in Crohn's disease. *Abdom Imaging* 2013;38:1005–13.
263. Dionisio PM, Gurudu SR, Leighton JA, *et al.* Capsule endoscopy has a significantly higher diagnostic yield in patients with suspected and established small bowel Crohn's disease: a meta-analysis. *Am J Gastroenterol* 2010;105:1240–8; quiz 1249.
264. Efthymiou A, Viazis N, Vlachogiannakos J, *et al.* Wireless capsule endoscopy versus enteroclysis in the diagnosis of small bowel Crohn's disease. *Eur J Gastroenterol Hepatol* 2009;21:866–71.
265. Flamant M, Trang C, Maillard O, *et al.* The prevalence and outcome of jejunal lesions visualized by small bowel capsule endoscopy in Crohn's disease. *Inflamm Bowel Dis* 2013;19:1390–6.
266. Gralnek IM, Leighton JA, Papatheofanis F. Evidence for capsule endoscopy in suspected small bowel Crohn's disease: an evaluation of intergrading system concordance. *J Insur Med* 2009;41:270–83.
267. O'Donnell S, Qasim A, Ryan BM, O'Connor HJ, Breslin N, O'Morain CA. The role of capsule endoscopy in small bowel Crohn's disease. *J Crohns Colitis* 2009;3:282–6.
268. Cotter J, Dias de Castro F, Moreira MJ, Rosa B. Tailoring Crohn's disease treatment: the impact of small bowel capsule endoscopy. *J Crohns Colitis* 2014;8:1610–5.
269. Cheon JH, Kim YS, Lee IS, *et al.*; Korean Gut Image Study Group. Can we predict spontaneous capsule passage after retention? A nationwide study to evaluate the incidence and clinical outcomes of capsule retention. *Endoscopy* 2007;39:1046–52.
270. Albuquerque A, Cardoso H, Marques M, *et al.* Predictive factors of small bowel patency in Crohn's disease patients. *Rev Esp Enferm Dig* 2016;108:65–70.
271. Dozsa C, Malbaski N, Borcsek B. Cost-effectiveness analysis of capsule endoscopy using for diagnosing small bowel Crohn's disease. *Value Health* 2015;18:A355.
272. Dussault C, Gower-Rousseau C, Salleron J, *et al.* Small bowel capsule endoscopy for management of Crohn's disease: a retrospective tertiary care centre experience. *Dig Liver Dis* 2013;45:558–61.
273. Bernstein CN, Greenberg H, Boulton I, Chubey S, Leblanc C, Ryner L. A prospective comparison study of MRI versus small bowel follow-through in recurrent Crohn's disease. *Am J Gastroenterol* 2005;100:2493–502.
274. Hafeez R, Greenhalgh R, Rajan J, *et al.* Use of small bowel imaging for the diagnosis and staging of Crohn's disease—a survey of current UK practice. *Br J Radiol* 2011;84:508–17.
275. Jaffe TA, Gaca AM, Delaney S, *et al.* Radiation doses from small bowel follow-through and abdominopelvic MDCT in Crohn's disease. *AJR Am J Roentgenol* 2007;189:1015–22.
276. Lai C, Zhou HC, Ma M, Zhang HX, Jia X. Comparison of magnetic resonance enterography, capsule endoscopy and gastrointestinal radiography of children with small bowel Crohn's disease. *Exp Ther Med* 2013;6:115–20.
277. Jensen MD, Ormstrup T, Vagn-Hansen C, Østergaard L, Rafaelsen SR. Interobserver and intermodality agreement for detection of small bowel Crohn's disease with MR enterography and CT enterography. *Inflamm Bowel Dis* 2011;17:1081–8.
278. Makó EK, Mester AR, Tarján Z, Karlinger K, Tóth G. Enteroclysis and spiral CT examination in diagnosis and evaluation of small bowel Crohn's disease. *Eur J Radiol* 2000;35:168–75.
279. Siddiki HA, Fidler JL, Fletcher JG, *et al.* Prospective comparison of state-of-the-art MR enterography and CT enterography in small bowel Crohn's disease. *AJR Am J Roentgenol* 2009;193:113–21.
280. Guidi L, Minordi LM, Semeraro S, *et al.* Clinical correlations of small bowel CT and contrast radiology findings in Crohn's disease. *Eur Rev Med Pharmacol Sci* 2004;8:215–7.
281. Greenup AJ, Bressler B, Rosenfeld G. Medical imaging in small bowel Crohn's disease-computer tomography enterography, magnetic resonance enterography, and ultrasound: "Which one is the best for what?". *Inflamm Bowel Dis* 2016;22:1246–61.
282. Ahmadi A, Li Q, Muller K, *et al.* Diagnostic value of noninvasive combined fluorine-18 labeled fluoro-2-deoxy-D-glucose positron emission tomography and computed tomography enterography in active Crohn's disease. *Inflamm Bowel Dis* 2010;16:974–81.
283. Pellino G, Nicolai E, Catalano OA, *et al.* PET/MR versus PET/CT imaging: impact on the clinical management of small bowel Crohn's disease. *J Crohns Colitis* 2016;10:277–85.
284. Almer S, Granerus G, Ström M, *et al.* Leukocyte scintigraphy compared to intraoperative small bowel enteroscopy and laparotomy findings in Crohn's disease. *Inflamm Bowel Dis* 2007;13:164–74.
285. Schoepfer AM, Beglinger C, Straumann A, *et al.* Fecal calprotectin more accurately reflects endoscopic activity of ulcerative colitis than the Lichtiger Index, C-reactive protein, platelets, hemoglobin, and blood leukocytes. *Inflamm Bowel Dis* 2013;19:332–41.
286. Sipponen T, Kärkkäinen P, Savilahti E, *et al.* Correlation of faecal calprotectin and lactoferrin with an endoscopic score for Crohn's disease and histological findings. *Aliment Pharmacol Ther* 2008;28:1221–9.
287. Jang HJ, Choi MH, Eun CS, *et al.* Clinical usefulness of double balloon enteroscopy in suspected Crohn's disease: the KASID multi-center trial. *Hepatogastroenterology* 2014;61:1292–6.
288. Keuchel M. Double balloon [push-and-pull] enteroscopy: breakthrough in the management of small intestinal strictures in Crohn's disease? *Eur J Gastroenterol Hepatol* 2007;19:523–5.
289. Seiderer J, Herrmann K, Diepolder H, *et al.* Double-balloon enteroscopy versus magnetic resonance enteroclysis in diagnosing suspected small bowel Crohn's disease: results of a pilot study. *Scand J Gastroenterol* 2007;42:1376–85.
290. Mensink PB, Groenen MJ, van Buuren HR, Kuipers EJ, van der Woude CJ. Double-balloon enteroscopy in Crohn's disease patients suspected of small bowel activity: findings and clinical impact. *J Gastroenterol* 2009;44:271–6.
291. Arulanandan A, Dulai PS, Singh S, Sandborn WJ, Kalmaz D. Systematic review: Safety of balloon assisted enteroscopy in Crohn's disease. *World J Gastroenterol* 2016;22:8999–9011.
292. Navaneethan U, Vargo JJ, Menon KV, Sanaka MR, Tsai CJ. Impact of balloon-assisted enteroscopy on the diagnosis and management of suspected and established small bowel Crohn's disease. *Endosc Int Open* 2014;2:E201–6.
293. Möschler O, May AD, Müller MK, Ell C; DBE-Studiengruppe Deutschland. [Complications in double-balloon-enteroscopy: results of the German DBE register]. *Z Gastroenterol* 2008;46:266–70.
294. Lee JL, Oh ES, Lee RW, Finucane TE. Serum albumin and prealbumin in calorically restricted, nondiseased individuals: a systematic review. *Am J Med* 2015;128:1023.e1–22.
295. Haluzík M, Kábrt J, Nedvídková J, Svobodová J, Kotlíková E, Papezová H. Relationship of serum leptin levels and selected nutritional parameters in patients with protein-caloric malnutrition. *Nutrition* 1999;15:829–33.

296. Ulitsky A, Ananthakrishnan AN, Naik A, et al. Vitamin D deficiency in patients with inflammatory bowel disease: association with disease activity and quality of life. *JPEN J Parenter Enteral Nutr* 2011;35:308–16.
297. Looker AC, Johnson CL, Lacher DA, Pfeiffer CM, Schleicher RL, Sempos CT. Vitamin D status: United States, 2001–2006. *NCHS Data Brief* 2011;1–8.
298. Zullo S, Jambaulikar G, Rustgi A, Quezada S, Cross RK. Risk factors for vitamin D deficiency and impact of repletion in a tertiary care inflammatory bowel disease population. *Dig Dis Sci* 2017;62:2072–8.
299. Castro FD, Magalhães J, Carvalho PB, Moreira MJ, Mota P, Cotter J. Lower levels of vitamin D correlate with clinical disease activity and quality of life in inflammatory bowel disease. *Arq Gastroenterol* 2015;52:260–5.
300. Narula N, Marshall JK. Management of inflammatory bowel disease with vitamin D: beyond bone health. *J Crohns Colitis* 2012;6:397–404.
301. Hwang C, Ross V, Mahadevan U. Micronutrient deficiencies in inflammatory bowel disease: from A to zinc. *Inflamm Bowel Dis* 2012;18:1961–81.
302. Weissshof R, Chermesh I. Micronutrient deficiencies in inflammatory bowel disease. *Curr Opin Clin Nutr Metab Care* 2015;18:576–81.
303. Rutgeerts P, Geboes K, Vantrappen G, Kerremans R, Coenegrachts JL, Coremans G. Natural history of recurrent Crohn's disease at the ileocolonic anastomosis after curative surgery. *Gut* 1984;25:665–72.
304. Rutgeerts P, Geboes K, Vantrappen G, Beyls J, Kerremans R, Hiele M. Predictability of the postoperative course of Crohn's disease. *Gastroenterology* 1990;99:956–63.
305. Fumery M, Dulai PS, Meirick P, et al. Systematic review with meta-analysis: recurrence of Crohn's disease after total colectomy with permanent ileostomy. *Aliment Pharmacol Ther* 2017;45:381–90.
306. Hukkinen M, Pakarinen MP, Merras-Salmio L, Koivusalo A, Rintala R, Kolho KL. Fecal calprotectin in the prediction of postoperative recurrence of Crohn's disease in children and adolescents. *J Pediatr Surg* 2016;51:1467–72.
307. Yamamoto T, Shiraki M, Bamba T, Umegae S, Matsumoto K. Faecal calprotectin and lactoferrin as markers for monitoring disease activity and predicting clinical recurrence in patients with Crohn's disease after ileocolonic resection: a prospective pilot study. *United European Gastroenterol J* 2013;1:368–74.
308. Qiu Y, Mao R, Chen BL, et al. Fecal calprotectin for evaluating postoperative recurrence of Crohn's disease: a meta-analysis of prospective studies. *Inflamm Bowel Dis* 2015;21:315–22.
309. Boschetti G, Laidet M, Moussata D, et al. Levels of fecal calprotectin are associated with the severity of postoperative endoscopic recurrence in asymptomatic patients with Crohn's disease. *Am J Gastroenterol* 2015;110:865–72.
310. Castiglione F, Bucci L, Pesce G, et al. Oral contrast-enhanced sonography for the diagnosis and grading of postsurgical recurrence of Crohn's disease. *Inflamm Bowel Dis* 2008;14:1240–5.
311. Castiglione F, de Sio I, Cozzolino A, et al. Bowel wall thickness at abdominal ultrasound and the one-year-risk of surgery in patients with Crohn's disease. *Am J Gastroenterol* 2004;99:1977–83.
312. Maconi G, Sampietro GM, Cristaldi M, et al. Preoperative characteristics and postoperative behavior of bowel wall on risk of recurrence after conservative surgery in Crohn's disease: a prospective study. *Ann Surg* 2001;233:345–52.
313. Calabrese E, Petruzzello C, Onali S, et al. Severity of postoperative recurrence in Crohn's disease: correlation between endoscopic and sonographic findings. *Inflamm Bowel Dis* 2009;15:1635–42.
314. Pallotta N, Giovannone M, Pezzotti P, et al. Ultrasonographic detection and assessment of the severity of Crohn's disease recurrence after ileal resection. *BMC Gastroenterol* 2010;10:69.
315. Cammarota T, Ribaldone DG, Resegotti A, et al. Role of bowel ultrasound as a predictor of surgical recurrence of Crohn's disease. *Scand J Gastroenterol* 2013;48:552–5.
316. Soyer P, Boudiaf M, Sirol M, et al. Suspected anastomotic recurrence of Crohn disease after ileocolic resection: evaluation with CT enteroclysis. *Radiology* 2010;254:755–64.
317. Mao R, Gao X, Zhu ZH, et al. CT enterography in evaluating postoperative recurrence of Crohn's disease after ileocolic resection: complementary role to endoscopy. *Inflamm Bowel Dis* 2013;19:977–82.
318. Biancone L, Fiori R, Tosti C, et al. Virtual colonoscopy compared with conventional colonoscopy for stricturing postoperative recurrence in Crohn's disease. *Inflamm Bowel Dis* 2003;9:343–50.
319. Sailer J, Peloschek P, Reinisch W, Vogelsang H, Turetschek K, Schima W. Anastomotic recurrence of Crohn's disease after ileocolic resection: comparison of MR enteroclysis with endoscopy. *Eur Radiol* 2008;18:2512–21.
320. Koilakou S, Sailer J, Peloschek P, et al. Endoscopy and MR enteroclysis: equivalent tools in predicting clinical recurrence in patients with Crohn's disease after ileocolic resection. *Inflamm Bowel Dis* 2010;16:198–203.
321. Kono T, Hida N, Nogami K, et al. Prospective postsurgical capsule endoscopy in patients with Crohn's disease. *World J Gastrointest Endosc* 2014;6:88–98.
322. Bourreille A, Jarry M, D'Halluin PN, et al. Wireless capsule endoscopy versus ileocolonoscopy for the diagnosis of postoperative recurrence of Crohn's disease: a prospective study. *Gut* 2006;55:978–83.
323. Yung DE, Har-Noy O, Tham YS, Ben-Horin S, Eliakim R, Koulaouzidis A, Kopylov U. Capsule endoscopy, magnetic resonance enterography and small bowel ultrasound for evaluation of postoperative recurrence in Crohn's disease: systematic review and meta-analysis. *Inflamm Bowel Dis* 2017;24(1):93–100.
324. Shen B, Fazio VW, Remzi FH, et al. Comprehensive evaluation of inflammatory and noninflammatory sequelae of ileal pouch-anal anastomoses. *Am J Gastroenterol* 2005;100:93–101.
325. Gionchetti P, Rizzello F, Helwig U, et al. Prophylaxis of pouchitis onset with probiotic therapy: a double-blind, placebo-controlled trial. *Gastroenterology* 2003;124:1202–9.
326. Hurst RD, Chung TP, Rubin M, Michelassi F. The implications of acute pouchitis on the long-term functional results after restorative proctocolectomy. *Inflamm Bowel Dis* 1998;4:280–4.
327. Madiba TE, Bartolo DC. Pouchitis following restorative proctocolectomy for ulcerative colitis: incidence and therapeutic outcome. *J R Coll Surg Edinb* 2001;46:334–7.
328. Mowschenson PM, Critchlow JF, Peppercorn MA. Ileoanal pouch operation: long-term outcome with or without diverting ileostomy. *Arch Surg* 2000;135:463–5; discussion 465–6.
329. Huetting WE, Buskens E, van der Tweel I, Gooszen HG, van Laarhoven CJ. Results and complications after ileal pouch anal anastomosis: a meta-analysis of 43 observational studies comprising 9,317 patients. *Dig Surg* 2005;22:69–79.
330. Fazio VW, Ziv Y, Church JM, et al. Ileal pouch-anal anastomoses complications and function in 1005 patients. *Ann Surg* 1995;222:120–7.
331. McLaughlin SD, Clark SK, Thomas-Gibson S, Tekkis PP, Ciclitira PJ, Nicholls RJ. Guide to endoscopy of the ileo-anal pouch following restorative proctocolectomy with ileal pouch-anal anastomosis; indications, technique, and management of common findings. *Inflamm Bowel Dis* 2009;15:1256–63.
332. Shen B, Fazio VW, Remzi FH, Lashner BA. Clinical approach to diseases of ileal pouch-anal anastomosis. *Am J Gastroenterol* 2005;100:2796–807.
333. Ghali P, Bitton A. The role of endoscopy in the evaluation of pouches and ostomies. *Gastrointest Endosc Clin N Am* 2002;12:605–19.
334. Shen B. Diagnosis and management of postoperative ileal pouch disorders. *Clin Colon Rectal Surg* 2010;23:259–68.
335. Shen B, Achkar JP, Lashner BA, et al. Endoscopic and histologic evaluation together with symptom assessment are required to diagnose pouchitis. *Gastroenterology* 2001;121:261–7.
336. Moskowitz RL, Shepherd NA, Nicholls RJ. An assessment of inflammation in the reservoir after restorative proctocolectomy with ileoanal ileal reservoir. *Int J Colorectal Dis* 1986;1:167–74.
337. Sandborn WJ, Tremaine WJ, Batts KP, Pemberton JH, Phillips SF. Pouchitis after ileal pouch-anal anastomosis: a pouchitis disease activity index. *Mayo Clin Proc* 1994;69:409–15.
338. Shen B, Remzi FH, Lavery IC, Lashner BA, Fazio VW. A proposed classification of ileal pouch disorders and associated complications after

- restorative proctocolectomy. *Clin Gastroenterol Hepatol* 2008;6:145–58; quiz 124.
339. Shen B, Plesec TP, Remer E, *et al.* Asymmetric endoscopic inflammation of the ileal pouch: a sign of ischemic pouchitis? *Inflamm Bowel Dis* 2010;16:836–46.
 340. Johnson MW, Maestranzi S, Duffy AM, *et al.* Faecal calprotectin: a noninvasive diagnostic tool and marker of severity in pouchitis. *Eur J Gastroenterol Hepatol* 2008;20:174–9.
 341. Farkas K, Bálint A, Bor R, *et al.* Faecal matrix metalloproteinase-9 is a more sensitive marker for diagnosing pouchitis than faecal calprotectin: results from a pilot study. *Expert Rev Gastroenterol Hepatol* 2015;9:387–92.
 342. Matalon S, Elad H, Brazowski E, Santo E, Tulchinsky H, Dotan I. Serum alpha-1 antitrypsin: a noninvasive marker of pouchitis. *Inflamm Bowel Dis* 2015;21:589–95.
 343. Colombel JF, Solem CA, Sandborn WJ, *et al.* Quantitative measurement and visual assessment of ileal Crohn's disease activity by computed tomography enterography: correlation with endoscopic severity and C reactive protein. *Gut* 2006;55:1561–7.
 344. Solem CA, Loftus EV Jr, Fletcher JG, *et al.* Small bowel imaging in Crohn's disease: a prospective, blinded, 4-way comparison trial. *Gastrointest Endosc* 2008;68:255–66.
 345. Voderholzer WA, Beinhöelzl J, Rogalla P, *et al.* Small bowel involvement in Crohn's disease: a prospective comparison of wireless capsule endoscopy and computed tomography enteroclysis. *Gut* 2005;54:369–73.
 346. Turetschek K, Schober E, Wunderbaldinger P, *et al.* Findings at helical CT-enteroclysis in symptomatic patients with Crohn disease: correlation with endoscopic and surgical findings. *J Comput Assist Tomogr* 2002;26:488–92.
 347. Parente F, Greco S, Molteni M, *et al.* Oral contrast enhanced bowel ultrasonography in the assessment of small intestine Crohn's disease. A prospective comparison with conventional ultrasound, x ray studies, and ileocolonoscopy. *Gut* 2004;53:1652–7.
 348. Rieder F, Fiocchi C, Rogler G. Mechanisms, management, and treatment of fibrosis in patients with inflammatory bowel diseases. *Gastroenterology* 2017;152:340–350.e6.
 349. Maconi G, Carsana L, Fociani P, *et al.* Small bowel stenosis in Crohn's disease: clinical, biochemical and ultrasonographic evaluation of histological features. *Aliment Pharmacol Ther* 2003;18:749–56.
 350. Chiorean MV, Sandrasegaran K, Saxena R, Maglinte DD, Nakeeb A, Johnson CS. Correlation of CT enteroclysis with surgical pathology in Crohn's disease. *Am J Gastroenterol* 2007;102:2541–50.
 351. Punwani S, Rodriguez-Justo M, Bainbridge A, *et al.* Mural inflammation in Crohn disease: location-matched histologic validation of MR imaging features. *Radiology* 2009;252:712–20.
 352. Zappa M, Stefanescu C, Cazals-Hatem D, *et al.* Which magnetic resonance imaging findings accurately evaluate inflammation in small bowel Crohn's disease? A retrospective comparison with surgical pathologic analysis. *Inflamm Bowel Dis* 2011;17:984–93.
 353. Rimola J, Planell N, Rodríguez S, *et al.* Characterization of inflammation and fibrosis in Crohn's disease lesions by magnetic resonance imaging. *Am J Gastroenterol* 2015;110:432–40.
 354. Tielbeek JA, Ziech ML, Li Z, *et al.* Evaluation of conventional, dynamic contrast enhanced and diffusion weighted MRI for quantitative Crohn's disease assessment with histopathology of surgical specimens. *Eur Radiol* 2014;24:619–29.
 355. Adler J, Swanson SD, Schmiedlin-Ren P, *et al.* Magnetization transfer helps detect intestinal fibrosis in an animal model of Crohn disease. *Radiology* 2011;259:127–35.
 356. Dillman JR, *et al.* Comparison of noncontrast MRI magnetization transfer and T2-weighted signal intensity ratios for detection of bowel wall fibrosis in a Crohn's disease animal model. *J Magn Reson Imaging* 2015;42:801–10.
 357. Dillman JR, Stidham RW, Higgins PD, Moons DS, Johnson LA, Rubin JM. US elastography-derived shear wave velocity helps distinguish acutely inflamed from fibrotic bowel in a Crohn disease animal model. *Radiology* 2013;267:757–66.
 358. Stidham RW, Xu J, Johnson LA, *et al.* Ultrasound elasticity imaging for detecting intestinal fibrosis and inflammation in rats and humans with Crohn's disease. *Gastroenterology* 2011;141:819–26.e1.
 359. Ripollés T, Rausell N, Paredes JM, Grau E, Martínez MJ, Vizuete J. Effectiveness of contrast-enhanced ultrasound for characterisation of intestinal inflammation in Crohn's disease: a comparison with surgical histopathology analysis. *J Crohns Colitis* 2013;7:120–8.
 360. Girlich C, Jung EM, Huber E, *et al.* Comparison between preoperative quantitative assessment of bowel wall vascularization by contrast-enhanced ultrasound and operative macroscopic findings and results of histopathological scoring in Crohn's disease. *Ultraschall Med* 2011;32:154–9.
 361. Sipponen T, Nuutinen H, Turunen U, Färkkilä M. Endoscopic evaluation of Crohn's disease activity: comparison of the CDEIS and the SES-CD. *Inflamm Bowel Dis* 2010;16:2131–6.
 362. Bettenworth D, Gustavsson A, Atreja A, *et al.* A pooled analysis of efficacy, safety, and long-term outcome of endoscopic balloon dilation therapy for patients with stricturing Crohn's disease. *Inflamm Bowel Dis* 2017;23:133–42.
 363. Magro F, *et al.* Third European evidence-based consensus on diagnosis and management of ulcerative colitis. Part 1: Definitions, diagnosis, extra-intestinal manifestations, pregnancy, cancer surveillance, surgery, and ileo-anal pouch disorders. *J Crohns Colitis* 2017;11:649–70.
 364. Eaden JA, Abrams KR, Mayberry JF. The risk of colorectal cancer in ulcerative colitis: a meta-analysis. *Gut* 2001;48:526–35.
 365. Jess T, Rungoe C, Peyrin-Biroulet L. Risk of colorectal cancer in patients with ulcerative colitis: a meta-analysis of population-based cohort studies. *Clin Gastroenterol Hepatol* 2012;10:639–45.
 366. Lovasz BD, Lakatos L, Golovics PA, *et al.* Risk of colorectal cancer in Crohn's disease patients with colonic involvement and stenosing disease in a population-based cohort from Hungary. *J Gastrointest Liver Dis* 2013;22:265–8.
 367. Friedman S, Rubin PH, Bodian C, Goldstein E, Harpaz N, Present DH. Screening and surveillance colonoscopy in chronic Crohn's colitis. *Gastroenterology* 2001;120:820–6.
 368. Yamazaki Y, Ribeiro MB, Sachar DB, Aufses AH Jr, Greenstein AJ. Malignant colorectal strictures in Crohn's disease. *Am J Gastroenterol* 1991;86:882–5.
 369. Fumery M, Pineton de Chambrun G, Stefanescu C, *et al.* Detection of dysplasia or cancer in 3.5% of patients with inflammatory bowel disease and colonic strictures. *Clin Gastroenterol Hepatol* 2015;13:1770–5.
 370. Rieder F, Latella G, Magro F, *et al.* European Crohn's and Colitis Organisation topical review on prediction, diagnosis and management of fibrostenosing Crohn's disease. *J Crohns Colitis* 2016;10:873–85.
 371. Booya F, Akram S, Fletcher JG, *et al.* CT enterography and fistulizing Crohn's disease: clinical benefit and radiographic findings. *Abdom Imaging* 2009;34:467–75.
 372. Maconi G, Sampietro GM, Parente F, *et al.* Contrast radiology, computed tomography and ultrasonography in detecting internal fistulas and intra-abdominal abscesses in Crohn's disease: a prospective comparative study. *Am J Gastroenterol* 2003;98:1545–55.
 373. Ripollés T, Martínez-Pérez MJ, Paredes JM, Vizuete J, García-Martínez E, Jiménez-Restrepo DH. Contrast-enhanced ultrasound in the differentiation between phlegmon and abscess in Crohn's disease and other abdominal conditions. *Eur J Radiol* 2013;82:e525–31.
 374. Lee SS, Kim AY, Yang SK, *et al.* Crohn disease of the small bowel: comparison of CT enterography, MR enterography, and small bowel follow-through as diagnostic techniques. *Radiology* 2009;251:751–61.
 375. Martínez MJ, Ripollés T, Paredes JM, Blanc E, Martí-Bonmatí L. Assessment of the extension and the inflammatory activity in Crohn's disease: comparison of ultrasound and MRI. *Abdom Imaging* 2009;34:141–8.
 376. Beets-Tan RG, Beets GL, van der Hoop AG, *et al.* Preoperative MR imaging of anal fistulas: Does it really help the surgeon? *Radiology* 2001;218:75–84.
 377. Buchanan G, Halligan S, Williams A, *et al.* Effect of MRI on clinical outcome of recurrent fistula-in-ano. *Lancet* 2002;360:1661–2.

378. Navarro-Luna A, García-Domingo MI, Rius-Macías J, Marco-Molina C. Ultrasound study of anal fistulas with hydrogen peroxide enhancement. *Dis Colon Rectum* 2004;47:108–14.
379. Sudol-Szopińska I, Jakubowski W, Szczepkowski M, Sarti D. Usefulness of hydrogen peroxide enhancement in diagnosis of anal and ano-vaginal fistulas. *Eur Radiol* 2003;13:1080–4.
380. Wedemeyer J, Kirchhoff T, Sellge G, et al. Transcutaneous perianal sonography: a sensitive method for the detection of perianal inflammatory lesions in Crohn's disease. *World J Gastroenterol* 2004;10:2859–63.
381. West RL, Dwarkasing S, Felt-Bersma RJ, et al. Hydrogen peroxide-enhanced three-dimensional endoanal ultrasonography and endoanal magnetic resonance imaging in evaluating perianal fistulas: agreement and patient preference. *Eur J Gastroenterol Hepatol* 2004;16:1319–24.
382. Schaefer O, Lohrmann C, Kreisel W, et al. Differentiation of perianal fistulas with digital subtraction magnetic resonance fistulography. *Inflamm Bowel Dis* 2005;11:383–7.
383. Fernández-Frías AM, Pérez-Vicente F, Arroyo A, et al. Is anal endosonography useful in the study of recurrent complex fistula-in-ano? *Rev Esp Enferm Dig* 2006;98:573–81.
384. Maier AG, Funovics MA, Kreuzer SH, et al. Evaluation of perianal sepsis: comparison of anal endosonography and magnetic resonance imaging. *J Magn Reson Imaging* 2001;14:254–60.
385. Reginelli A, Mandato Y, Cavaliere C, et al. Three-dimensional anal endosonography in depicting anal-canal anatomy. *Radiol Med* 2012;117:759–71.
386. Spencer JA, Chapple K, Wilson D, Ward J, Windsor AC, Ambrose NS. Outcome after surgery for perianal fistula: predictive value of MR imaging. *AJR Am J Roentgenol* 1998;171:403–6.
387. Wright EK, Novak KL, Lu C, Panaccione R, Ghosh S, Wilson SR. Transperineal ultrasonography in perianal Crohn disease: a valuable imaging modality. *Can J Gastroenterol Hepatol* 2015;29:445–7.
388. Maconi G, Tonolini M, Monteleone M, et al. Transperineal perineal ultrasound versus magnetic resonance imaging in the assessment of perianal Crohn's disease. *Inflamm Bowel Dis* 2013;19:2737–43.
389. Sandborn W. *Pouchitis: risk factors, frequency, natural history, classification and public health perspective. Trends in Inflammatory Bowel Disease 1996*. Lancaster, UK: Kluwer Academic Publishers; 1997:51–63.
390. Shen B, Fazio VW, Remzi FH, et al. Endoscopic balloon dilation of ileal pouch strictures. *Am J Gastroenterol* 2004;99:2340–7.
391. Shen B, Lian L, Kiran RP, et al. Efficacy and safety of endoscopic treatment of ileal pouch strictures. *Inflamm Bowel Dis* 2011;17:2527–35.
392. Nadgir RN, Soto JA, Dendrinis K, Lucey BC, Becker JM, Farraye FA. MRI of complicated pouchitis. *AJR Am J Roentgenol* 2006;187:W386–91.
393. Thoeni RF, Fell SC, Engelstad B, Schrock TB. Ileoanal pouches: comparison of CT, scintigraphy, and contrast enemas for diagnosing postsurgical complications. *AJR Am J Roentgenol* 1990;154:73–8.
394. McLaughlin SD, Clark SK, Thomas-Gibson S, Tekkis PP, Ciclitira PJ, Nicholls RJ. Guide to endoscopy of the ileo-anal pouch following restorative proctocolectomy with ileal pouch-anal anastomosis; indications, technique, and management of common findings. *Inflamm Bowel Dis* 2009;15:1256–63.
395. Sandborn WJ. Pouchitis following ileal pouch-anal anastomosis: definition, pathogenesis, and treatment. *Gastroenterology* 1994;107:1856–60.
396. Broder JC, Tkacz JN, Anderson SW, Soto JA, Gupta A. Ileal pouch-anal anastomosis surgery: imaging and intervention for post-operative complications. *Radiographics* 2010;30:221–33.
397. Tonolini M, Campari A, Bianco R. Ileal pouch and related complications: spectrum of imaging findings with emphasis on MRI. *Abdom Imaging* 2011;36:698–706.
398. Kirat HT, Kiran RP, Oncel M, Shen B, Fazio VW, Remzi FH. Management of leak from the tip of the "J" in ileal pouch-anal anastomosis. *Dis Colon Rectum* 2011;54:454–9.
399. Pola S, Patel D, Ramamoorthy S, et al. Strategies for the care of adults hospitalized for active ulcerative colitis. *Clin Gastroenterol Hepatol* 2012;10:1315–25.e4.
400. Imbricco M, Balthazar EJ. Toxic megacolon: role of CT in evaluation and detection of complications. *Clin Imaging* 2001;25:349–54.
401. Maconi G, Sampietro GM, Ardizzone S, et al. Ultrasonographic detection of toxic megacolon in inflammatory bowel diseases. *Dig Dis Sci* 2004;49:138–42.
402. Freeman HJ. Spontaneous free perforation of the small intestine in Crohn's disease. *Can J Gastroenterol* 2002;16:23–7.
403. Freeman HJ. Spontaneous free perforation of the small intestine in adults. *World J Gastroenterol* 2014;20:9990–7.
404. Hyman N, Manchester TL, Osler T, Burns B, Cataldo PA. Anastomotic leaks after intestinal anastomosis: it's later than you think. *Ann Surg* 2007;245:254–8.
405. Khoury W, Ben-Yehuda A, Ben-Haim M, Klausner JM, Szold O. Abdominal computed tomography for diagnosing postoperative lower gastrointestinal tract leaks. *J Gastrointest Surg* 2009;13:1454–8.
406. Power N, Atri M, Ryan S, Haddad R, Smith A. CT assessment of anastomotic bowel leak. *Clin Radiol* 2007;62:37–42.
407. Jess T, Horváth-Puhó E, Fallingborg J, Rasmussen HH, Jacobsen BA. Cancer risk in inflammatory bowel disease according to patient phenotype and treatment: a Danish population-based cohort study. *Am J Gastroenterol* 2013;108:1869–76.
408. Choi CH, Rutter MD, Askari A, et al. Forty-year analysis of colonoscopic surveillance program for neoplasia in ulcerative colitis: an updated overview. *Am J Gastroenterol* 2015;110:1022–34.
409. Selinger CP, Andrews JM, Titman A, et al.; Sydney IBD Cohort Study Group. Long-term follow-up reveals low incidence of colorectal cancer, but frequent need for resection, among Australian patients with inflammatory bowel disease. *Clin Gastroenterol Hepatol* 2014;12:644–50.
410. Annesse V, Daperno M, Rutter MD, et al.; European Crohn's and Colitis Organisation. European evidence-based consensus for endoscopy in inflammatory bowel disease. *J Crohns Colitis* 2013;7:982–1018.
411. Thomas-Gibson S, Rogers P, Cooper S, et al. Judgement of the quality of bowel preparation at screening flexible sigmoidoscopy is associated with variability in adenoma detection rates. *Endoscopy* 2006;38:456–60.
412. Subramanian V, Ramappa V, Telakis E, et al. Comparison of high definition with standard white light endoscopy for detection of dysplastic lesions during surveillance colonoscopy in patients with colonic inflammatory bowel disease. *Inflamm Bowel Dis* 2013;19:350–5.
413. Watanabe T, Ajioka Y, Mitsuyama K, et al. Comparison of targeted versus random biopsies for surveillance of ulcerative colitis-associated colorectal cancer. *Gastroenterology* 2016;151:1122–30.
414. Kiesslich R, Fritsch J, Holtmann M, et al. Methylene blue-aided chromoendoscopy for the detection of intraepithelial neoplasia and colon cancer in ulcerative colitis. *Gastroenterology* 2003;124:880–8.
415. Hurlstone DP, Sanders DS, Lobo AJ, McAlindon ME, Cross SS. Indigo carmine-assisted high-magnification chromoscopic colonoscopy for the detection and characterisation of intraepithelial neoplasia in ulcerative colitis: a prospective evaluation. *Endoscopy* 2005;37:1186–92.
416. Kiesslich R, Goetz M, Lammersdorf K, et al. Chromoscopy-guided endomicroscopy increases the diagnostic yield of intraepithelial neoplasia in ulcerative colitis. *Gastroenterology* 2007;132:874–82.
417. Hlavaty T, Huorka M, Koller T, et al. Colorectal cancer screening in patients with ulcerative and Crohn's colitis with use of colonoscopy, chromoendoscopy and confocal endomicroscopy. *Eur J Gastroenterol Hepatol* 2011;23:680–9.
418. Carballal S, et al. Real-life chromoendoscopy for neoplasia detection and characterisation in long-standing IBD. *Gut* 2018;67:70–8.
419. Marion JF, Wayne JD, Israel Y, et al.; Chromoendoscopy Study Group at Mount Sinai School of Medicine. Chromoendoscopy is more effective than standard colonoscopy in detecting dysplasia during long-term surveillance of patients with colitis. *Clin Gastroenterol Hepatol* 2016;14:713–9.
420. Subramanian V, Mannath J, Raganath K, Hawkey CJ. Meta-analysis: the diagnostic yield of chromoendoscopy for detecting dysplasia in patients with colonic inflammatory bowel disease. *Aliment Pharmacol Ther* 2011;33:304–12.
421. Wu L, Li P, Wu J, Cao Y, Gao F. The diagnostic accuracy of chromoendoscopy for dysplasia in ulcerative colitis: meta-analysis of six randomized controlled trials. *Colorectal Dis* 2012;14:416–20.

422. Dekker E, van den Broek FJ, Reitsma JB, *et al.* Narrow-band imaging compared with conventional colonoscopy for the detection of dysplasia in patients with longstanding ulcerative colitis. *Endoscopy* 2007;39:216–21.
423. Ignjatovic A, East JE, Subramanian V, *et al.* Narrow band imaging for detection of dysplasia in colitis: a randomized controlled trial. *Am J Gastroenterol* 2012;107:885–90.
424. Pellisé M, López-Cerón M, Rodríguez de Miguel C, *et al.* Narrow-band imaging as an alternative to chromoendoscopy for the detection of dysplasia in long-standing inflammatory bowel disease: a prospective, randomized, crossover study. *Gastrointest Endosc* 2011;74:840–8.
425. Günther U, Kusch D, Heller F, *et al.* Surveillance colonoscopy in patients with inflammatory bowel disease: comparison of random biopsy versus targeted biopsy protocols. *Int J Colorectal Dis* 2011;26:667–72.
426. van den Broek FJ, van Es JA, van Eeden S, *et al.* Pilot study of probe-based confocal laser endomicroscopy during colonoscopic surveillance of patients with longstanding ulcerative colitis. *Endoscopy* 2011;43:116–22.
427. Committee Opinion No. 656. Guidelines for diagnostic imaging during pregnancy and lactation. *Obstet Gynecol* 2016;127:e75–80.
428. Miller MW, Nyborg WL, Dewey WC, Edwards MJ, Abramowicz JS, Brayman AA. Hyperthermic teratogenicity, thermal dose and diagnostic ultrasound during pregnancy: implications of new standards on tissue heating. *Int J Hyperthermia* 2002;18:361–84.
429. Gowland PA, De Wilde J. Temperature increase in the fetus due to radio frequency exposure during magnetic resonance scanning. *Phys Med Biol* 2008;53:L15–8.
430. Fleishman AB, Notley HM, Wilkinson JM. Cost benefit analysis of radiological protection: a case study of remote after-loading in gynaecological radiotherapy. *Br J Radiol* 1983;56:737–44.
431. Bigelow TA, Church CC, Sandstrom K, *et al.* The thermal index: its strengths, weaknesses, and proposed improvements. *J Ultrasound Med* 2011;30:714–34.
432. Pooh RK, Maeda K, Kurjak A, *et al.* 3D/4D sonography any safety problem. *J Perinat Med* 2016;44:125–9.
433. Ray JG, Vermeulen MJ, Bharatha A, Montanera WJ, Park AL. Association between MRI exposure during pregnancy and fetal and childhood outcomes. *JAMA* 2016;316:952–61.
434. Strizek B, Jani JC, Mucyo E, *et al.* Safety of MR imaging at 1.5 T in fetuses: a retrospective case-control study of birth weights and the effects of acoustic noise. *Radiology* 2015;275:530–7.
435. Stern MD, Kopylov U, Ben-Horin S, Apter S, Amitai MM. Magnetic resonance enterography in pregnant women with Crohn's disease: case series and literature review. *BMC Gastroenterol* 2014;14:146.
436. Heetun ZS, Kavanagh D, Keegan D, *et al.* Magnetic resonance colonography for assessment of acute severe colitis in pregnancy. *Ir J Med Sci* 2014;183:147–8.
437. Witherspoon P, Chalmers AG, Sagar PM. Successful pregnancy after laparoscopic ileal pouch-anal anastomosis complicated by small bowel obstruction secondary to a single band adhesion. *Colorectal Dis* 2010;12:490–1.
438. Savoye G, Koning E, Savoye-Collet C, Tuech JJ, Lerebours E. Gastrointestinal: fistulae in Crohn's disease. *J Gastroenterol Hepatol* 2006;21:621.
439. Blot WJ, Miller RW. Mental retardation following in utero exposure to the atomic bombs of Hiroshima and Nagasaki. *Radiology* 1973;106:617–9.
440. Patel SJ, Reede DL, Katz DS, Subramaniam R, Amorosa JK. Imaging the pregnant patient for nonobstetric conditions: algorithms and radiation dose considerations. *Radiographics* 2007;27:1705–22.
441. Doll R, Wakeford R. Risk of childhood cancer from fetal irradiation. *Br J Radiol* 1997;70:130–9.
442. Hurwitz LM, Yoshizumi T, Reiman RE, *et al.* Radiation dose to the fetus from body MDCT during early gestation. *AJR Am J Roentgenol* 2006;186:871–6.
443. van der Woude CJ, Ardizzone S, Bengtson MB, *et al.* European Crohn's and Colitis Organisation. The second European evidenced-based consensus on reproduction and pregnancy in inflammatory bowel disease. *J Crohns Colitis* 2015;9:107–24.
444. Harbord M, Annese V, Vavricka SR, *et al.* The first European evidence-based consensus on extra-intestinal manifestations in inflammatory bowel disease. *J Crohns Colitis* 2016;10:239–54.