

University of Groningen

Angiogenesis in pediatric brain tumors

Sie, M.

IMPORTANT NOTE: You are advised to consult the publisher's version (publisher's PDF) if you wish to cite from it. Please check the document version below.

Document Version

Publisher's PDF, also known as Version of record

Publication date:

2013

[Link to publication in University of Groningen/UMCG research database](#)

Citation for published version (APA):

Sie, M. (2013). *Angiogenesis in pediatric brain tumors: therapeutic possibilities?* [Thesis fully internal (DIV), University of Groningen]. [S.n.].

Copyright

Other than for strictly personal use, it is not permitted to download or to forward/distribute the text or part of it without the consent of the author(s) and/or copyright holder(s), unless the work is under an open content license (like Creative Commons).

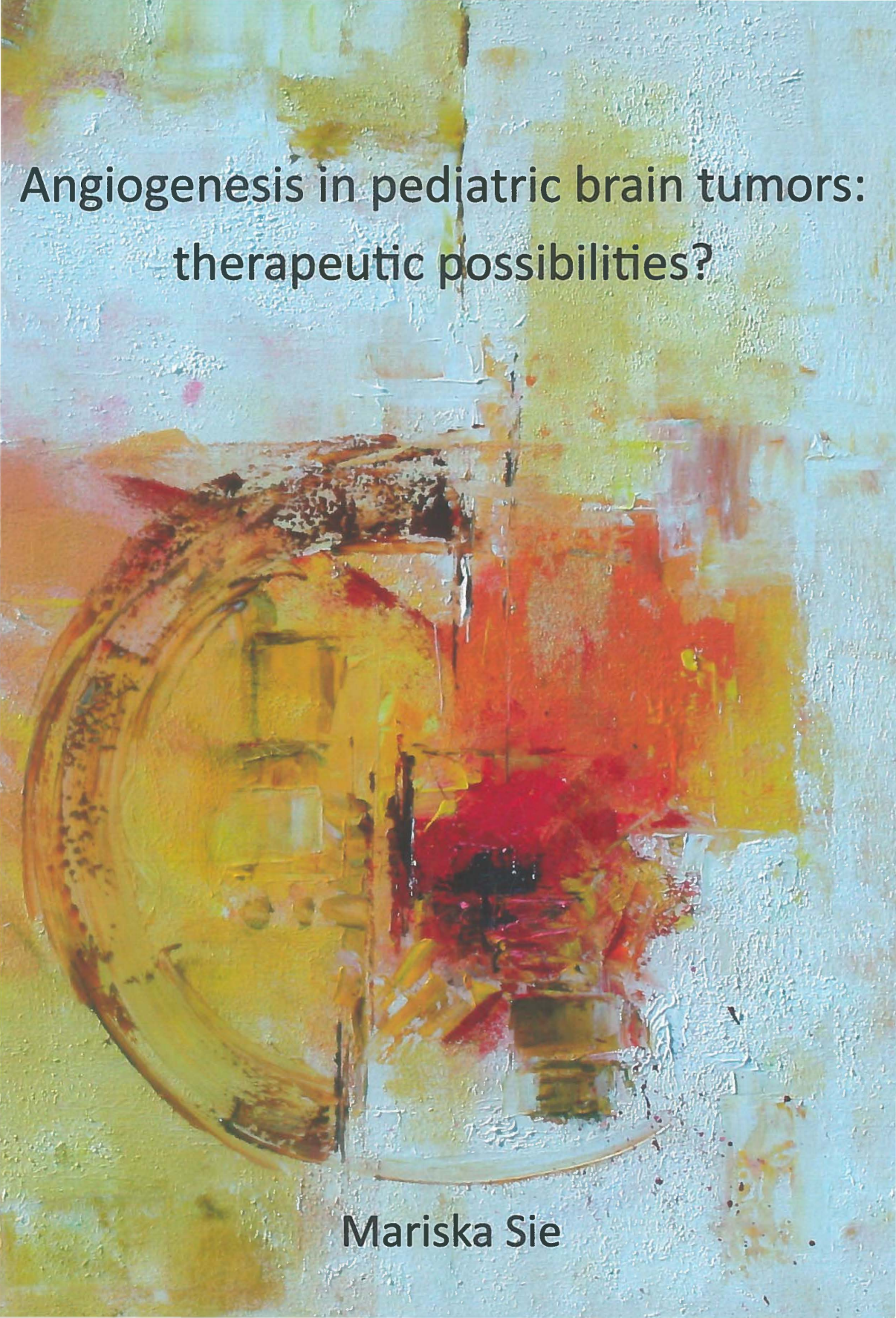
The publication may also be distributed here under the terms of Article 25fa of the Dutch Copyright Act, indicated by the "Taverne" license. More information can be found on the University of Groningen website: <https://www.rug.nl/library/open-access/self-archiving-pure/taverne-amendment>.

Take-down policy

If you believe that this document breaches copyright please contact us providing details, and we will remove access to the work immediately and investigate your claim.

Downloaded from the University of Groningen/UMCG research database (Pure): <http://www.rug.nl/research/portal>. For technical reasons the number of authors shown on this cover page is limited to 10 maximum.

Angiogenesis in pediatric brain tumors:
therapeutic possibilities?



Mariska Sie

Angiogenesis in pediatric brain tumors: therapeutic possibilities?

Mariska Sie

Angiogenesis in pediatric brain tumors: therapeutic possibilities?

Copyright © 2013 Mariska Sie, Groningen, the Netherlands.

All rights reserved. No part of this thesis may be reproduced, stored in a retrieval system, or transmitted in any form or by any means, without prior permission of the author.

ISBN	978-90-367-6414-8
Author	Mariska Sie
Cover	Convergence by Elizabeth Chapman © Elizabeth Chapman, Springfield, Missouri, USA
Print	Ipskamp Drukkers B.V., Enschede, the Netherlands

Financial support for the printing of this thesis is gratefully acknowledged and was provided by University of Groningen, University Medical Center Groningen (UMCG), Graduate School for Drug Exploration (GUIDE), Stichting Kinderoncologie Groningen (SKOG), Stichting STOPhersentumoren.nl, Greiner Bio-One B.V. (used material during research: polystyrene/polypropylene tubes, pipettes, pipette tips, analyser cups), and Roche Diagnostics Nederland B.V.

Stellingen


behorend bij het proefschrift

Angiogenesis in pediatric brain tumors: therapeutic possibilities?

1. De associatie tussen een hogere angiopoietine-1/angiopoietine-2 balans en langere overleving bij volwassen patiënten met een primair glioblastoom, suggereert mogelijkheden voor anti-angiogene therapie dat met name gericht is op vaatnormalisatie. (dit proefschrift)
2. Gezien het pilocytair astrocytoom en in mindere mate het ependymoom een cruciale overlap toont met het glioblastoom in tumorvasculatuur en het angiogene profiel kan anti-angiogene therapie mogelijk een belangrijke rol spelen in de behandeling van deze kinderhersentumoren. (dit proefschrift)
3. In laaggradige astrocytomen is het remmende effect van anti-VEGF op tumorgroei voornamelijk toe te schrijven aan de indirecte werking op het tumormilieu. (dit proefschrift)
4. Groeifactor gedreven tumor ontsnapingsmechanismen tijdens behandeling met receptor tyrosine kinase (RTK) remmers kunnen overwonnen worden door 'multi targeted' therapie in laaggradige astrocytomen en ependymomen. (dit proefschrift)
5. Preklinische *in vivo* en *ex vivo* modellen voor anti-angiogene therapie in kinderhersentumoren zullen geoptimaliseerd moeten worden om een rationele vertaling naar de kliniek te kunnen maken. (dit proefschrift)
6. The inquiry, knowledge and belief of truth is the sovereign good of human nature.
Francis Bacon
7. De vorm van een labjournaal zegt niets over de inhoud.
8. Hoewel de interesse voor een medisch specialisme ontwikkeld kan worden op basis van theoretische kennis, laat de kliniek je de voorkeur pas echt overkomen.
9. Het is mogelijk in een ander land een gevoel van thuiskomen te ervaren zonder dat je er ooit eerder bent geweest.
10. Je kunt alleen maar winnen als je niet bang bent te verliezen.
11. Hangmatten kun je leren.

Centrale	U
Medische	M
Bibliotheek	C
Groningen	G

Mariska Sie
11 september 2013





university of
 groningen

RIJKSUNIVERSITEIT GRONINGEN

**Angiogenesis in pediatric brain tumors:
 therapeutic possibilities?**

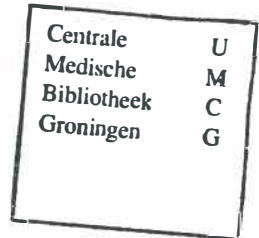
Proefschrift

ter verkrijging van het doctoraat in de
 Medische Wetenschappen
 aan de Rijksuniversiteit Groningen
 op gezag van de
 Rector Magnificus, dr. E. Sterken,
 in het openbaar te verdedigen op
 woensdag 11 september 2013
 om 16.15 uur

door

Mariska Sie

geboren op 18 december 1985
 te Groningen



Promotores: Prof. dr. E.S.J.M. de Bont
Prof. dr. W.A. Kamps

Copromotor: Dr. W.F.A. den Dunnen

Beoordelingscommissie: Prof. dr. R.G. Grundy
Prof. dr. J.M. Kros
Prof. dr. G. Molema



Een race tegen de klok die je toch nooit zal winnen.
De trui af willen hebben voor de wol op is.
Langzaam vlieg ik weg,
naar het land van onbezorgdheid.

Floortje Peneder, 1993

Paranimfen:

Marloes J.M. Gooden
Frank J.G. Scherpen


Contents

Chapter 1	General introduction and Scope of the thesis	9
Chapter 2	Anti-angiogenic therapy in pediatric brain tumors: an effective strategy? <i>Crit Rev Oncol Hematol; revision submitted</i>	17
Chapter 3	The angiopoietin 1/angiopoietin 2 balance as a prognostic marker in primary glioblastoma multiforme <i>J Neurosurg 2009; 110: 147-155</i>	45
Chapter 4	Tumor vessel biology in pediatric intracranial ependymoma <i>J Neurosurg Pediatrics 2010; 5: 335-341</i>	61
Chapter 5	Tumour vasculature and angiogenic profile of paediatric pilocytic astrocytoma; is it much different from glioblastoma? <i>Neuropath Appl Neurobiol 2010; 36: 636-647</i>	75
Chapter 6	Pro- and anti-angiogenic VEGF-A isoforms in pediatric pilocytic astrocytoma and adult glioblastoma: possibilities for anti-angiogenic therapy in pilocytic astrocytoma? <i>Cell Oncol 2012; 35: suppl 1 (abstract)</i>	93
Chapter 7	Less tumor engraftment after anti-VEGF therapy in pediatric low grade astrocytoma <i>Proceedings of the AACR 2013 (abstract)</i>	111
Chapter 8	Growth-factor-driven rescue to RTK inhibitors in pediatric low grade astrocytoma and ependymoma <i>Mol Cancer Res; manuscript submitted</i>	115
Chapter 9	Summary, general discussion and future perspectives	131
Chapter 10	Nederlandse samenvatting	139
Appendices	Dankwoord / Acknowledgements	147
	List of publications and Curriculum Vitae	153



Chapter 1

General introduction and Scope of the thesis



Introduction

Brain tumors account for approximately 1.4% of all cancers in adults and 2.3% of all cancer-related deaths. Contrary, in children, brain tumors are the most frequent solid tumors, accounting for nearly 20% of all childhood cancers and are the leading cause of cancer morbidity and mortality among children.¹ Brain tumors present particular difficult challenges, especially in children, in that they interfere with normal brain function and development which are essential for healthy ageing. Due to its localization, a brain tumor is one of the most challenging tumor types to treat. Given the high morbidity and mortality numbers despite intensive therapeutic options including neurosurgical resection, intensive chemotherapy and craniospinal radiotherapy, alternative treatment strategies are warranted. The concept that tumor growth and progression are angiogenesis-dependent, has resulted in the development of various strategies inhibiting angiogenesis as a therapeutic implication.²⁻⁶ However, in this research field, limited studies have been published about angiogenesis and tumor vasculature in pediatric brain tumors compared with adult solid tumors. In the present thesis we will focus particularly on the angiogenic profile in pediatric brain tumors. To study angiogenesis in various pediatric brain tumors it is compared to glioblastoma. Glioblastoma (WHO grade IV), the most frequent primary brain tumor in adults, is often seen as a model for studying angiogenesis.⁷

Glioblastoma

Glioblastomas, accounting for approximately 50% of all intrinsic brain tumors and 80% of malignant brain tumors,⁸ are among the most vascularized tumors. Despite the short duration of symptoms of less than 3 months in more than 50% of the patients, the tumors are often surprisingly large at the time of presentation. Glioblastoma occurs most often in the subcortical white matter of the cerebral hemispheres with a particularly typical fronto-temporal location. Tumor infiltration often extends into the adjacent cortex and through the corpus callosum into the contralateral hemisphere.⁷ Especially in children, glioblastoma of the basal ganglia, thalamus and brain stem (malignant brain stem glioma) can occur and is seen in 2-3% of the children diagnosed with a brain tumor (exact percentages are given in Figure 1). The overall survival is dramatically poor with median survival rates of 14 months reported in clinical trials,⁹ which could even be overestimated as they showed bias towards recruitment of younger adult patients and patients with high preoperative Karnofsky performance scores, which are both predictors of a more favorable clinical outcome.

Pediatric brain tumors

Low grade astrocytomas, including pilocytic astrocytoma (WHO grade I) and diffuse astrocytoma (WHO grade II), are the most frequent brain tumors in children (Figure 1). Pilocytic astrocytomas are relatively circumscribed, slowly growing, often cystic tumors, but highly vascular, as is evidenced by their contrast enhancement on magnetic resonance imaging (MRI).¹⁰ These tumors arise in most pediatric patients in the infratentorial region. The most common supratentorial site is the hypothalamus/optic pathways, followed by the thalamic/basal ganglia region.⁷

Diffuse astrocytomas (WHO grade II) are characterized by a high degree of cellular differentiation and slow growth, occurring throughout the central nervous system but preferentially located supratentorially. The intrinsic tendency of diffuse astrocytoma for malignant progression is rarely found in children.^{7, 11} Overall low grade astrocytomas have a good prognosis with 5-year overall survival rates of 80-90%. The 5-year survival rate for high grade astrocytomas including anaplastic astrocytomas (WHO grade III) ranges from merely 20-40% and is even worse for glioblastoma (5-15%).¹² Interestingly, although pediatric high grade astrocytoma may resemble adult glioblastoma on histopathological criteria, there are significant differences both clinically and within the molecular biology of the tumors.

The astrocytic tumors, are followed in frequency of occurrence by medulloblastomas (WHO grade IV) which are malignant, invasive embryonal tumors arising at least in 75% of the childhood cases in the vermis, and project into the fourth ventricle. Involvement of cerebellar hemispheres increases with the age of the patient.^{7, 13} Ependymomas (WHO grade I-III) represent the third most common pediatric brain tumors after astrocytomas and medulloblastomas. They most commonly develop in the fourth ventricle and in the spinal cord, followed by the lateral ventricles and the third ventricle, although supratentorial parenchymal ependymomas may occur outside the ventricular system.¹⁴ Histopathological grading of ependymomas according to the WHO classification (II-III) seems to be hardly reproducible, and not correlated with clinical outcome, especially in young children.¹⁵

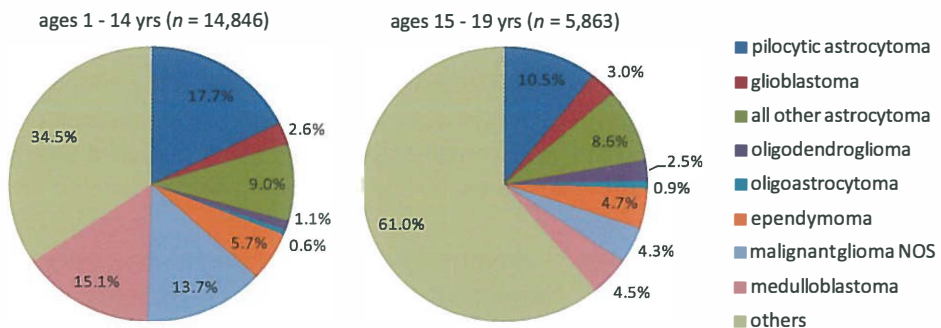


Figure 1. Distribution of childhood primary central nervous system tumors by histology.⁸

Angiogenesis and tumor vasculature

Angiogenesis, the formation of vessels from a pre-existing vasculature, is one of the main processes through which tumors acquire blood supply to establish a source of nutrients and oxygen and to eliminate cellular waste products. In addition, several other modes of vessel formation in tumors have been identified, including co-options of pre-existing vessels, the recruitment of endothelial progenitor cells, vessel splitting known as intussusceptions and vasculogenic mimicry which includes the formation of tube-like structures by tumor cells instead of endothelial cells.¹⁶⁻¹⁹ Crucial factors in the process of angiogenesis are *e.g.* angiopoietins (ANGPTs), regulating angiogenesis and vessel (in)stability by binding to the endothelial cell-specific receptor tyrosine kinase Tie2, and vascular endothelial growth factor (VEGF), promoting angiogenesis and cell survival.^{3, 19, 20}

Despite having an abundant number of vessels, tumors are mainly characterized by hypoxia, low pH and high interstitial fluid pressure due to an abnormal vasculature with immature and leaky vessels.¹⁹ This hostile tumor microenvironment can impede the transport and/or distribution of chemotherapeutics to the tumor and thereby sustaining tumor survival and even tumor growth.

Anti-angiogenic therapy

'Traditionally', anti-angiogenic therapy attempt to inhibit new vessel formation and/or to destroy existing vessels to starve the tumor from its nutrients. Interestingly, various other theories have been described. For example, anticipating on the previously described vascular abnormalities in tumors, anti-angiogenic therapy has been suggested as a strategy to normalize tumor vasculature by inhibiting pro-angiogenic factors like VEGF which is highly expressed in tumors, leading to improved blood supply with subsequently increased delivery of chemotherapy and oxygen for higher efficacy of radiation.^{21, 22} Furthermore angiogenic inhibitors targeting receptor tyrosine kinases, the so-called RTK inhibitors are not only effective through angiogenic pathways targeting the tumor indirectly, but also directly by inhibiting tumor cell growth.^{23, 24} However, in response to anti-angiogenic therapy tumor resistance or rescue mechanisms could rise, including upregulation of alternative angiogenic growth factors.^{25, 26}

Scope of the thesis

The research described in the present thesis aimed to analyze the angiogenic profile, tumor vasculature and growth-factor-driven rescue to receptor tyrosine kinase (RTK) inhibitors in pediatric brain tumors. By determining these aspects of tumor angiogenesis, more insight has been obtained into this mechanism, possibly resulting in the identification of a potential therapeutic window for anti-angiogenic therapy in pediatric brain tumors.

Up to now, numerous clinical studies of anti-angiogenic therapy in pediatric brain tumors have been described. **Chapter 2** reviewed these published studies and provided an overview of recently started clinical trials inhibiting angiogenesis in pediatric brain tumors. Moreover, response measuring and clinical monitoring of anti-angiogenic therapy will be evaluated. Based on pre-clinical results, clinical developments and future perspectives, this review discussed the question if anti-angiogenic therapy is an effective strategy in the treatment of children with brain tumors.

With this clinical point of view in mind, this thesis continued with analyses of more biological tumor characteristics in terms of the angiogenic profile and tumor vasculature in glioblastoma as prototype of angiogenesis in brain tumors. In **chapter 3**, the angiopoietin (ANGPT)1/ANGPT2 balance as an indicator for vessel stability was determined in the context of therapeutic outcome in 62 adult patients with primary glioblastoma. Moreover, microvessel density, turnover of both endothelial and tumor cells, and VEGF-A-D expression were evaluated in immunohistochemically stained tumor slides.

As glioblastomas are often seen as a model for studying angiogenesis, tumor tissue from the previous study was used as a comparable prototype to characterize the angiogenic profile and tumor vasculature in tumor tissue obtained from respectively 27 pediatric intracranial ependymoma (**chapter 4**) and 59 pilocytic astrocytoma patients (**chapter 5**). Besides the former aspects of studying tumor vessel biology in glioblastoma, both pediatric brain tumor studies enriched their methods with analyses of vessel maturity in terms of basement membrane and pericyte coverage. Furthermore, as in pilocytic astrocytoma two different methods were used to determine microvessel density, more insight was obtained into blood vessel architecture in these tumors.

Subsequently, as each VEGF isoform, arises through differential splicing of the VEGF-A gene, could contribute differently to the process of angiogenesis resulting in differences in blood vessel architecture, **chapter 6** aimed to further analyze various VEGF-A isoforms (VEGF-A_{121a-189a}) in correlation with tumor vessel morphology in pediatric pilocytic astrocytoma and adult glioblastoma. Interestingly, it has been suggested that anti-angiogenic VEGF-A isoforms (VEGF-A_{xxx}^b) contain binding domains for the vast majority of anti-VEGF-A antibodies, like bevacizumab, and therefore inhibiting the effect of these drugs in tumors expressing significant levels of VEGF-A_{xxx}^b.^{27,28} Tumors with relatively higher pro- than anti-angiogenic isoform expression will be probably more sensitive to anti-angiogenic therapy. Because of this possible clinical relevance, this study secondly aimed to determine VEGF-A_{xxx}^a : VEGF-A_{xxx}^b ratios in both pilocytic astrocytoma and glioblastoma.

In **chapter 7** and **chapter 8** anti-angiogenic therapies were analyzed in pediatric brain tumors with respectively anti-VEGF monoclonal antibodies and various receptor tyrosine kinase (RTK) inhibitors. By VEGF targeting the process of angiogenesis can be disrupted, effecting tumor growth indirectly. RTK inhibitors prevent receptor binding of growth factor ligands resulting not only in inhibition of angiogenic pathways, but also downstream survival signaling pathways, including the PI3K/Akt and MAPK/Erk pathways. As such, tumor cell growth can be attacked directly. However, inhibition of a specific RTK could trigger the tumor to upregulate RTK ligands, through autocrine tumor-cell production, paracrine contribution from tumor stroma or systemic production, eventually contributing to tumor resistance to the RTK inhibitor.²⁶

So in chapter 7 the anti-VEGF monoclonal antibodies, bevacizumab (Avastin®, anti human VEGF) and B20-4.1.1 (anti human and mouse VEGF) were studied on cell viability and proliferation level in pediatric low grade astrocytoma cell lines. Moreover an intracranial pediatric low grade astrocytoma xenograft mouse model was developed to determine *in vivo* effects. Chapter 8 aimed to investigate growth-factor-driven rescue to RTK inhibitors (sorafenib, dasatinib, canertinib, crizotinib) in pediatric low grade astrocytoma and ependymoma cell lines. Furthermore as a strategy to overcome tumor resistance multi targeted therapy will be evaluated.

Finally, in **chapter 9** the results of the research described in this thesis are summarized and discussed in a broader context with future perspectives about the possible therapeutic window for anti-angiogenic therapy in pediatric brain tumors.

References

1. Mueller S and Chang S. Pediatric brain tumors: current treatment strategies and future therapeutic approaches. *Neurotherapeutics*. 2009;6:570-586.
2. Folkman J. Tumor angiogenesis: therapeutic implications. *N Engl J Med*. 1971;285:1182-1186.
3. Dvorak HF. Vascular permeability factor/vascular endothelial growth factor: a critical cytokine in tumor angiogenesis and a potential target for diagnosis and therapy. *J Clin Oncol*. 2002;20:4368-4380.
4. Jain RK, di Tomaso E, Duda DG, Loeffler JS, Sorensen AG, Batchelor TT. Angiogenesis in brain tumours. *Nat Rev Neurosci*. 2007;8:610-622.
5. Ellis LM and Hicklin DJ. VEGF-targeted therapy: mechanisms of anti-tumour activity. *Nat Rev Cancer*. 2008;8:579-591.
6. Norden AD, Drappatz J, Wen PY. Antiangiogenic therapies for high-grade glioma. *Nat Rev Neurol*. 2009;5:610-620.
7. Louis DN, Ohgaki H, Wiestler OD, Cavenee WK. *Classification of Tumours of the Central Nervous System*. 4th ed. Lyon: IARC; 2007.
8. Dolecek TA, Propp JM, Stroup NE, Kruchko C. CBTRUS statistical report: Primary brain and central nervous system tumors diagnosed in the united states in 2005-2009. *Neuro Oncol*. 2012;14 Suppl 5: v1-49.
9. Stupp R, Mason WP, van den Bent MJ, et al. Radiotherapy plus concomitant and adjuvant temozolomide for glioblastoma. *N Engl J Med*. 2005;352:987-996.
10. Koeller KK and Rushing EJ. From the archives of the AFIP: pilocytic astrocytoma: radiologic-pathologic correlation. *Radiographics*. 2004;24:1693-1708.
11. Sarkar C, Ralte AM, Sharma MC, Mehta VS. Recurrent astrocytic tumours--a study of p53 immunoreactivity and malignant progression. *Br J Neurosurg*. 2002;16:335-342.
12. Pollack IF, Finkelstein SD, Woods J, et al. Expression of p53 and prognosis in children with malignant gliomas. *N Engl J Med*. 2002;346:420-427.
13. Koeller KK and Rushing EJ. From the archives of the AFIP: medulloblastoma: a comprehensive review with radiologic-pathologic correlation. *Radiographics*. 2003;23:1613-1637.
14. McGuire CS, Sainani KL, Fisher PG. Incidence patterns for ependymoma: a surveillance, epidemiology, and end results study. *J Neurosurg*. 2009;110:725-729.
15. Ellison DW, Kocak M, Figarella-Branger D, et al. Histopathological grading of pediatric ependymoma: Reproducibility and clinical relevance in european trial cohorts. *J Negat Results Biomed*. 2011;10:7.
16. Holash J, Maisonpierre PC, Compton D, et al. Vessel cooption, regression, and growth in tumors mediated by angiopoietins and VEGF. *Science*. 1999;284:1994-1998.
17. El Hallani S, Boisselier B, Peglion F, et al. A new alternative mechanism in glioblastoma vascularization: tubular vasculogenic mimicry. *Brain*. 2010;133:973-982.
18. Paulis YW, Soetekouw PM, Verheul HM, Tjan-Heijnen VC, Griffioen AW. Signalling pathways in vasculogenic mimicry. *Biochim Biophys Acta*. 2010;1806:18-28.
19. Jain RK. Molecular regulation of vessel maturation. *Nat Med*. 2003;9:685-693.
20. Scharpfenecker M, Fiedler U, Reiss Y, Augustin HG. The Tie-2 ligand angiopoietin-2 destabilizes quiescent endothelium through an internal autocrine loop mechanism. *J Cell Sci*. 2005;118:771-780.
21. Jain RK. Normalization of tumor vasculature: an emerging concept in antiangiogenic therapy. *Science*. 2005;307:58-62.
22. Fukumura D, Jain RK. Imaging angiogenesis and the microenvironment. *APMIS*. 2008;116:695-715.

23. Young A, Lou D, McCormick F. Oncogenic and wild-type ras play divergent roles in the regulation of mitogen-activated protein kinase signaling. *Cancer Discov.* 2013;3:112-123.
24. Christensen JG. A preclinical review of sunitinib, a multitargeted receptor tyrosine kinase inhibitor with anti-angiogenic and antitumour activities. *Ann Oncol.* 2007;18 Suppl 10:x3-10.
25. Bergers G and Hanahan D. Modes of resistance to anti-angiogenic therapy. *Nat Rev Cancer.* 2008;8:592-603.
26. Wilson TR, Fridlyand J, Yan Y, et al. Widespread potential for growth-factor-driven resistance to anticancer kinase inhibitors. *Nature.* 2012;487:505-509.
27. Harper SJ and Bates DO. VEGF-A splicing: the key to anti-angiogenic therapeutics? *Nat Rev Cancer.* 2008;8:880-887.
28. Varey AH, Rennel ES, Qiu Y, et al. VEGF 165 b, an antiangiogenic VEGF-A isoform, binds and inhibits bevacizumab treatment in experimental colorectal carcinoma: balance of pro- and antiangiogenic VEGF-A isoforms has implications for therapy. *Br J Cancer.* 2008;98:1366-1379.



Chapter 2

Anti-angiogenic therapy in pediatric brain tumors: an effective strategy?

Mariska Sie¹

Wilfred F.A. den Dunnen²

Eelco W. Hoving³

Eveline S.J.M. de Bont¹

¹ Department of Pediatrics, Beatrix Children's Hospital, Pediatric Oncology/Hematology division

² Department of Pathology and Medical Biology, Pathology division

³ Department of Neurosurgery

University Medical Center Groningen, University of Groningen, Groningen, the Netherlands

Crit Rev Oncol Hematol; revision submitted

Abstract

Brain tumors are still the leading cause of cancer morbidity and mortality among children, despite different therapeutic options including neurosurgery, chemotherapy and radiation. As angiogenesis is highly crucial in brain tumor growth and progression, numerous clinical trials evaluating diverse anti-angiogenic agents have been described. In the present review, we aimed to answer the question if anti-angiogenic therapy is an effective strategy in the treatment of children with brain tumors. Although some encouraging results have been published of anti-angiogenic therapy targeting vascular endothelial growth factor (VEGF)/VEGF receptor signaling or epidermal growth factor receptor (EGFR), still more insight is warranted to be highly conclusive about the efficacy of anti-angiogenic therapy with currently potential upcoming anti-angiogenic agents in pediatric brain tumors. However, given the need for new therapeutic strategies, multi targeted therapy with anti-angiogenic agents anticipating on possible tumor escape mechanisms could be effective in the future treatment of pediatric brain tumors.

Introduction

Brain tumors account for nearly 20% of all childhood cancers and are characterized by a large diversity of morphologic entities. The most common brain tumor subtype occurring in children and young adults is glioma, representing more than 50% of all tumors.¹ Gliomas are classified into low-grade glioma (LGG), including the most frequent occurring pilocytic astrocytoma (WHO grade I) and diffuse astrocytoma (WHO grade II) and high-grade glioma (HGG), including anaplastic astrocytoma (WHO grade III) and glioblastoma (WHO grade IV). WHO grade III tumors of oligodendroglial or mixed oligoastrocytic origin are less commonly found in children.² Tumor vascularity is associated with a higher WHO grade, except for pilocytic astrocytoma which are as grade I astrocytoma highly vascular tumors.²⁻⁴ Preferred sites of low-grade astrocytoma include the optic nerve, optic chiasm/hypothalamus, thalamus and basal ganglia, cerebral hemispheres, cerebellum and brain stem.² Overall these tumors have a good prognosis with 5-year overall survival rates of 80-90%. However, the 5-year survival rate for anaplastic astrocytomas ranges from merely 20-40% and is even worse for glioblastoma (5-15%).⁵ Diffuse intrinsic brain stem gliomas (DIPG) which are mainly grade III or IV astrocytomas have the most infaust prognosis.⁶ The overall survival of these children remains approximately 9 months, and most patients die from the disease within 2 years.⁷

Medulloblastoma, one of the embryonal brain tumor types, is the second most frequent tumor subtype after glioma. Peak occurrence is at 4 years of age with one third of the cases are present in the first years of life.^{2,6} Management of these very young patients remains challenging since the immature brain is particularly susceptible to the toxicity of current treatment options. Ependymoma is the third most common pediatric brain tumor subtype with a peak incidence between birth and 4 years of age. Ependymomas are classified into myxopapillary ependymoma (WHO grade I), grade II ependymoma (cellular, papillary, clear cell, tancytic) and anaplastic ependymoma (WHO grade III),² although clinical studies have failed to show a correlation between grade and clinical outcome.⁸ ⁹ 5-year overall survival was reported to be 57.1% in which infratentorial location was associated with better survival rates compared with supratentorially located tumors.¹⁰

Although the prognosis for pediatric patients with brain tumors has improved over the last few decades with diverse intensive therapeutic modalities as neurosurgery, chemotherapy and radiation, many brain tumors remain difficult to treat and are associated with a poor prognosis. The long term survival for children with DIPG has not even changed over the last decades. Overall brain tumors are still the leading cause of cancer morbidity and mortality among children. So to reduce this morbidity as well as mortality, alternative therapeutic strategies have been developed, extrapolating from adult studies, including anti-angiogenic therapy.

In 1971, Folkman firstly proposed that tumor growth is angiogenesis-dependent, and hence, blocking angiogenesis could be a strategy to arrest tumor growth.¹¹ This possibility stimulated an intensive search for pro- and anti-angiogenic molecules, resulting in the identification of crucial angiogenic factors including vascular endothelial growth factor (VEGF), epidermal growth factor receptor (EGFR) and platelet derived growth factor (PDGF). Later, various strategies inhibiting the process of angiogenesis were described, specific anti-angiogenic inhibitors were developed and tested in pre-clinical and clinical settings in adults and subsequently in children.

Nowadays, numerous clinical studies of anti-angiogenic therapy also in pediatric brain tumors have been described. In the present review an introduction in the process of angiogenesis and its mediators in pediatric brain tumors will be followed by a description of the general effects of and possible tumor resistance mechanisms to anti-angiogenic therapy. Next, we provide an overview of both published clinical pediatric brain tumor studies and recently started clinical trials inhibiting angiogenesis in different pediatric brain tumor subtypes. Moreover, we will evaluate clinical results and monitoring of anti-angiogenic therapy. Finally, the question if anti-angiogenic therapy is an effective strategy in the treatment of children with brain tumors and the future perspectives will be discussed.

Angiogenesis and its mediators in pediatric brain tumors

Vascularization of the brain begins during embryogenesis, continues into the post-natal period, and involves a tightly regulated process of vasculogenesis followed by angiogenesis.¹²⁻¹⁴ Angiogenesis is defined as blood vessel generation from pre-existing blood vessels, whereas vasculogenesis refers to in situ differentiation of undifferentiated precursor cells (angioblasts) to endothelial cells that assemble into a vascular labyrinth.^{15, 16} During adulthood most blood vessels remain quiescent and angiogenesis occurs only in the cycling ovary and in the placenta during pregnancy, and in physiological repair processes such as wound healing.^{17, 18} Angiogenesis is thought to be the result of a delicate balance between pro- and anti-angiogenic factors, including vascular endothelial growth factor (VEGF), angiopoietins (ANGPT), fibroblast growth factor (FGF), epidermal growth factor receptor (ErbB/HER) and platelet derived growth factor (PDGF).^{16, 19} Mitogens, such as VEGF, are activated to enhance endothelial cell migration and proliferation.²⁰ Endothelial cells migrate along newly deposited extracellular matrix tracts and form vessel sprouts. This process requires extracellular matrix dissolution facilitated by the presence of proteases such as matrix metalloproteinase (MMP). Subsequently, the occurring tube and basement membrane formation triggers further processes which involve pericyte recruitment by endothelial cells, and the eventual formation of a mature blood vessel.^{21, 22} Normal blood vessels are distributed at regular and closely spaced intervals having a highly organized blood flow. In the brain, astrocytes induce endothelial cell and pericyte differentiation, but it appears that pericytes migrate faster to capillary-like structures and cover the capillary-like structures more extensively than astrocytes, which provide the astrocyte end-feet that eventually invest the outer wall of the blood vessel.²³ The basement membrane exists between endothelial cells and astrocytes, and is functionally important in the brain in restricting extravasation of protein rich fluids and blood components into the parenchyma.²⁴ Interestingly, hypoxia is a key regulator of angiogenesis and affects the expression of crucial angiogenic factors.

Tumor angiogenesis has become widely accepted as the mechanism by which tumors induce the formation of new blood vessels from the pre-existing microvasculature. Both tumor growth and invasion are angiogenesis-dependent.²⁵ Angiogenesis has been extensively analyzed in glioblastoma, which is the most frequent intrinsic brain tumor in adults and is often seen as a model for studying angiogenesis. Much of the knowledge about angiogenesis and its mediators in brain tumors has been derived from this 'angiogenic prototype' and extrapolated to pediatric brain tumors. Relatively limited studies have been published about angiogenesis in pediatric brain tumors. In general, during tumorigenesis, tumor cells co-opt blood vessels of the surrounding brain until the limiting diffusion distance to a vessel has been reached and the tumor become hypoxic. In response to changes in the local milieu caused by tissue hypoxia, growth factor stimulation from both tumor and endothelial cells, metabolic and/or mechanical stress, genetic mutations and immune response, the so called 'angiogenic switch' (*i.e.* the balance between pro-angiogenic and anti-angiogenic molecules) is tipped towards a pro-angiogenic state.^{22, 26, 27}

The imbalance between pro- and anti-angiogenic factors results in abnormal blood vessels and immature tumor vasculature. In contrast to normal blood vessels, tumor vasculature is highly disorganized: the immature vessels are tortuous and dilated, vessel diameter varies extensively, pericyte coverage is incomplete, the basement membrane is abnormally thick or thin, there is excessive branching and shunting. Consequently, tumor blood flow is chaotic and variable and leads to hypoxic and acidic regions in tumors.^{26, 28} Moreover structural abnormalities of the endothelial lining form the basis for an increased microvascular permeability and loss of blood brain barrier function.²⁹ All these abnormalities in tumor vasculature could lower effectiveness of regular therapeutic strategies including chemotherapy and radiation. In pediatric brain tumors differences in vessel architecture have been found. In pediatric pilocytic astrocytoma and to a lesser extend in pediatric ependymoma overlapping tumor immaturity and instability was found compared with adult glioblastoma.^{3, 30}

One of the most extensively investigated angiogenic molecules is vascular endothelial growth factor (VEGF), which has been described as the key mediator of angiogenesis. The VEGF family currently comprises seven members: VEGF-A to VEGF-F (also known as FIGF) and placental growth factor (PIGF or PGF) of which VEGF-A is the best characterized VEGF member.^{20, 31} The VEGF-A gene consists of eight exons that give rise to various isoforms (VEGF-A₁₂₁₋₂₀₆) through differential splicing. All isoforms contain exon 1-5 and the terminal exon, exon 8, except for VEGF-A₁₄₈. The presence or absence of the heparin-binding domains encoded by exon 6 and 7 determines binding to the extracellular matrix and therefore these domains influence solubility. VEGF isoforms containing exon 6 (VEGF-A₁₄₅) or both exon 6 and 7 (VEGF-A₁₈₃, VEGF-A₁₈₉, and VEGF-A₂₀₆) are bound tightly to cell surface heparin-containing proteoglycans in the extracellular matrix,^{20, 32-34} whereas those lacking exon 6 (VEGF-A₁₆₅) or both exons 6 and 7 (VEGF-A₁₂₁) are moderately till highly diffusible.^{34, 35} The affinity of the VEGF isoforms to bind heparin has an overall effect on isoform spatial distribution; these variations determine whether blood vessel growth is organized and directed, or disordered.³⁴⁻³⁶ Longer isoforms like VEGF-A₁₈₉ are associated with more vessel maturity,³⁷ showing good levels of pericyte coverage, while VEGF-A₁₂₁ shows major defects in mural cell recruitment resulting in immature blood vessels that are fragile and leaky.³⁸

Besides these pro-angiogenic isoforms, it has been described that alternative 3' splice site selection in exon 8, could give different C-terminal sequences, resulting in the anti-angiogenic VEGF isoforms.³⁹⁻⁴¹ It is suggested that anti-angiogenic VEGF-A isoforms contain binding domains for the vast majority of anti-VEGF-A antibodies, and therefore inhibiting the effect of these drugs in tumors expressing significant levels of anti-angiogenic isoforms.⁴²⁻⁴⁴ The overlapping pro- and anti-angiogenic VEGF-A isoform ratio between pediatric pilocytic astrocytoma and adult glioblastoma could suggest possibilities for anti-angiogenic therapy not only in glioblastoma, but also in pilocytic astrocytoma.³⁷ Notably, the anti-angiogenic character of these VEGF isoforms have been questioned and more recently the pitfalls of interpreting VEGF expression patterns were highlighted, emphasizing the complexity of the VEGF-A isoform biology and carefulness of the interpretation of the results.^{45, 46}

VEGF-A expression can be induced by hypoxia and acidosis, but can also be regulated by multiple oncogenes and tumor-suppressor genes, hormones, cytokines and various signaling molecules, including nitric oxide and mitogen-activated protein kinases. Moreover, VEGF-A can be released from other cells and the extracellular matrix. VEGF-A mediates its effects by interacting with two high-affinity tyrosine kinase receptors (VEGFR-1 or Flt-1 and VEGFR-2 or KDR), in which VEGFR-2 is responsible for mediating microvascular permeability, endothelial cell migration, proliferation and anti-apoptotic effects, while VEGFR-1 may have an independent role in stimulating cell migration but may also dampen certain signaling pathways mediated by VEGFR-2 (Figure 1).^{31, 47} However, there are possible indications for VEGFR-1 induced tumor angiogenesis.⁴⁸ In pediatric brain tumors, VEGF-A is highly expressed and is thought to be partly responsible for the loss of the blood brain barrier during tumor growth. Neuropilins can also serve as a receptor for some members of the VEGF family and interact directly with VEGFRs, modulating angiogenesis (Figure 1).⁴⁹

Other critical angiogenic factors are the angiopoietins, Ang-1 (ANGPT1) and Ang-2 (ANGPT2) that bind to the endothelial cell-specific receptor tyrosine kinase Tie2 (TEK) and regulate angiogenesis (Figure 1). The working mechanism is still under debate. Initially, it was suggested that Ang-1 activates Tie2 to promote blood vessel maturation and stabilization. In contrast, Ang-2, which is highly expressed by tumor endothelial cells, is thought to inhibit Tie2 activity and destabilize blood vessels, thereby facilitating VEGF-dependent vessel growth. However, recent findings indicate that Ang-2 plays a protective rather than a destabilizing role in tumor endothelial cells by activating Tie2 instead of inhibiting.⁵⁰⁻⁵² Previous studies demonstrated different oligomeric or multimeric forms of the angiopoietins. It has been indicated that the higher oligomeric forms (at least tetramers) are needed for Ang-1-specific Tie2 binding and activation in endothelial cells.⁵³ The lower oligomerization state of Ang-2 seems to be crucial for the Ang-2-specific Tie2 redistribution, whereas multimeric structures of Ang-2 could induce responses similar to Ang-1.⁵⁴ These data should help to explain the versatile effects of Ang-2 in angiogenesis, acting as both agonist and antagonist of Tie2.

Yet another mediator in angiogenesis is fibroblast growth factor (FGF) of which 18 family members have been described (FGF1-FGF10 and FGF16-FGF23). FGF is a potent mitogen for cells of neuroectodermic and mesodermic origin, including endothelial cells, and stimulates angiogenesis by binding to FGF structurally related receptor tyrosine kinase receptors (FGFR1-5) (Figure 1).⁵⁵⁻⁵⁷ FGF in combination with VEGF acts synergistically on endothelial cell proliferation and migration.⁵⁸

Furthermore, epidermal growth factor receptor (ErbB/HER) and platelet derived growth factor (PDGF-A-D) may be involved in angiogenesis (Figure 1). The human ErbB family comprises four related receptors (EGFR/ErbB1/HER-1, ErbB2/HER-2/c-neu, ErbB3/HER-3 and ErbB4/HER-4) which are transmembrane glycoproteins containing an extracellular ligand binding domain and an intracellular receptor tyrosine kinase domain.⁵⁹ Dysregulation of ErbB/HER pathways by overexpression or constitutive activation can promote tumor processes including angiogenesis,⁵⁹ although the importance of EGFR promoting angiogenesis in different pediatric brain tumors is debatable.⁶⁰⁻⁶⁴ PDGF is a mitogen for multiple cells of mesenchymal and neuroectodermal origin that acts through the PDGF receptors (PDGFR α and β). PDGF-B can upregulate VEGF and exerts autocrine effects on endothelial and perivascular cells.⁶⁵ PDGFR α is overexpressed in pediatric high-grade brain stem glioma,⁶⁶ and the expression is significantly associated with malignant histology in pediatric glioma, but it does not represent an independent prognostic factor.⁶⁷

Effects of targeting angiogenesis

The inhibition of angiogenesis may affect tumor growth through several mechanisms. As the angiogenic profile is not quite similar in all pediatric brain tumors subtypes, different mechanisms will have a more or less important role depending on tumor type. Moreover, in some tumors angiogenesis-targeted therapy may act through parallel mechanisms. One such proposed mechanism is that of anti-angiogenesis where it simply inhibits the formation of new blood vessels. Inhibition of new vessel growth may occur with induction of endothelial cell apoptosis and blockade of incorporation of bone marrow-derived endothelial progenitor cells. However, there are no adequately powered clinical trials that showed really a decrease in tumor vessel count or microvessel density after anti-angiogenic therapy.⁶⁸

Anti-angiogenic therapy may also act by its direct effects on blood vessel function through vascular constriction or vascular normalization. Vascular constriction after anti-angiogenic therapy is probably due to decreases in production of the vasodilators nitric oxide and prostacyclin. It has been hypothesized that these vasodilators are chronically increased in tumor vessels owing to high levels of VEGF. Vasoconstriction decreases perfusion and could possibly lead to hypoxia and limited tumor growth.⁶⁸ Unfortunately this vasoconstriction is not limited to the tumor vasculature, as one of the most common adverse effects of angiogenesis-targeted therapy is hypertension, possibly resulting in posterior reversible encephalopathy syndrome (PRES), although the role of hypertension and changes in cerebral perfusion in the pathogenesis of PRES remains a matter of debate.⁶⁹

According to the vascular normalization theory, anti-angiogenic therapy could correct the balance between pro- and anti-angiogenic factors, thereby normalizing the abnormal tumor vasculature. Theoretically, this normalization of the tumor vascular network can lead to improved blood flow with subsequently increased delivery of chemotherapy and oxygen for higher efficacy of radiation.⁷⁰ However, although some studies described an increase in delivery of chemotherapy to tumors with anti-angiogenic therapy,^{71, 72} others didn't show any change in oxygenation/improved blood flow over time.⁷³

Furthermore, anti-angiogenic therapy could have effect on tumor cells suppressing similar and functional receptors as endothelial cells, like VEGFRs and neuropilins, to impair tumor growth directly. This mechanism could be more or less important in different pediatric brain tumors, as for example high-grade gliomas express VEGFR-2 on their tumor cells, and the expression of VEGFR-2 in pilocytic astrocytoma is particularly limited to the endothelial cells.⁷⁴ Another mechanism of anti-angiogenic therapy is by counteracting the effects of angiogenic factors induced by hypoxia. In tumors, stress conditions like hypoxia are present, resulting in high levels of angiogenic factors, in turn, contributing to tumor growth. However, expression of these angiogenic factors is also upregulated in reaction on genotoxic stress induced by chemotherapy and radiation. The proposed mechanism of action is neutralizing the adaptive stress responses of tumor cells to genotoxic stress by adding anti-angiogenic therapy to chemotherapy and radiation.^{68, 75}

(Overcome) resistance to anti-angiogenic therapy

Despite the benefits of anti-angiogenic treatments, tumor progression seems inevitable due to several mechanisms of acquired or adaptive resistance to anti-angiogenic therapy. Moreover, pre-existing non-responsiveness has been described as a second mode of tumor resistance. This last resistance mechanism is possibly attributable to intrinsic properties of tumor cells and angiogenic factor secretions prior to their exposure to anti-angiogenic therapy. Various strategies to overcome both types of resistance mechanisms have been hypothesized and are still under debate.

Resistance to anti-angiogenic therapy

One of the described acquired tumor resistance mechanisms includes activation and/or upregulation of alternative pro-angiogenic signaling pathways within the tumor than the goal targeted with the specific anti-angiogenic drug, such as FGF and ephrins during anti-VEGF therapy. Furthermore, anti-angiogenic therapy causing vessel regression and hypoxia could lead to recruitment of vascular progenitor cells and pro-angiogenic monocytes from the bone marrow that have the capacity to fuel tumors by eliciting new blood vessels. Another resistance mechanism suggests increased pericyte coverage of the tumor vasculature, serving to support the tumor's integrity and attenuate the necessity for angiogenic-mediated survival signaling. Alternatively, tumors can adopt an invasive phenotype, in which they co-opt existing cerebral vasculature. Some evidence supports a critical role for angiopoietins in this process.⁷⁵⁻⁷⁸

In sharp contrast with the vascular normalization theory purposed by Jain et al,^{16, 70} is the hypothesis that VEGF/VEGFR-targeted therapy could lead to its own resistance mechanism, which is still being discussed.⁷⁹⁻⁸¹ It was noted in preclinical models that VEGF-inhibition decreased permeability of the blood brain barrier, resulting in an impaired effect of chemotherapy, possibly due to restoration of the blood brain barrier and obstruction of chemo-distribution to tumor cells. However, despite visual normalization of the blood brain barrier by anti-VEGF other studies showed no limitation in intratumoral concentrations of chemotherapy.⁸²⁻⁸⁴ Up to now, these studies have only been performed in preclinical adult high-grade glioma models.

Other possible contributing resistance mechanisms included changes in the dominant VEGF isoforms (VEGF-A₁₂₁, VEGF-A₁₆₅ or VEGF-A₁₈₉) or in neuropilin 1 as a VEGFR co-receptor, and loss of endothelial cell VEGF dependence from downregulation of VEGFR-2.⁸⁵ Additional mechanisms for receptor tyrosine kinase inhibitors, could be under-dosing owing to increasingly rapid clearance of the inhibitor⁸⁶ and inhibitor inactivation by uptake and lysosomal sequestration in tumor cells.⁸⁷ Besides the acquired resistance mechanisms in which tumors develop the capability of regrowth or progression in the face of continued anti-angiogenic therapy, pre-existing or intrinsic resistance mechanisms have been determined. It has been suggested that some tumors have an inherent upregulation of multiple pro-angiogenic pathways or can mediate a pre-existing inflammatory state where the presence of a high proportion of pre-existing inflammatory cells confers a resistant phenotype to anti-angiogenic therapy.⁷⁶ Moreover tumor-surrogate blood vessel subtypes exhibit differential susceptibility to anti-angiogenic therapy, as recently formed, immature and unstable blood vessels are more sensitive than older and mature vessels.⁸⁸

Overcome resistance to anti-angiogenic therapy

To overcome resistance mechanisms different strategies have been described, including the addition of low-dose (metronomic) chemotherapy or radiation to anti-angiogenic treatment. However, the underlying mechanism of the added benefit is currently under debate. Anti-angiogenic therapy could lead to vascular normalization, resulting in increased delivery and efficacy of chemotherapy and possibly improved tumor oxygenation and radiosensitivity.⁷⁰ However, others suggest that hypoxia inducible factor (HIF)1 α blockade by chemotherapy could offset the hypoxic effects of vascular pruning when paired with an anti-angiogenic agent. Alternatively, radiotherapy sensitizes endothelial cells to anti-angiogenic therapy, suggesting that anti-angiogenic therapy should cause greater slowing of tumor growth when preceded by radiation than when followed by radiation.⁷⁸ The fact that abnormal/immature tumor vasculature is more vulnerable to anti-angiogenic therapy, therapeutic destabilization of tumor vessels should possibly be a potential approach for overcoming resistance to anti-angiogenic therapy. The inhibition of Notch signaling by blocking delta-like protein 4 (DLL4) stimulates the growth of abundant vascular structures but slows tumor growth in preclinical models because the vessels that are derived from endothelial hypersprouting are poorly functional and intratumoral hypoxia is increased.⁸⁹ The abnormal vasculature is more responsive to inhibition of VEGF signaling, and tumor growth is slowed even in some models that are usually unresponsive to VEGF inhibition. Theoretically, as single targeted angiogenic therapy could lead to upregulation of alternative angiogenic factors, multi targeted therapy should also overcome resistance to anti-angiogenic therapy.⁹⁰ Other methods to overcome resistance is inhibition of immune cell recruitment or processes that favor tumor progression, like the VEGF-inducible factors HIF1 α and insulin-like growth factor I (IGF1) or hypoxia increased c-Met (hepatocyt growth factor receptor, HGFR) which is associated with tumor invasiveness.⁷⁸

Clinical strategies in pediatric brain tumors

The first anti-angiogenic compounds described in pediatric brain tumors were interferon (INF) and thalidomide (Table 1). INFs are a family of glycoproteins with anti-proliferative, anti-viral, immunomodulating, and anti-angiogenic effects. INF- α and INF- β both function through inhibition of bFGF (Figure 1),⁹¹ while INF- γ has anti-angiogenic effect by enhanced secretion of anti-angiogenic chemokines.⁹² Standard chemotherapeutic agents, when modified by the frequency and dose administration, can also target angiogenesis. This approach is referred to as anti-angiogenic chemotherapy, low-dose chemotherapy, or metronomic chemotherapy.⁹³ Thalidomide acts as an inhibitor of VEGF and bFGF-mediated angiogenesis (Figure 1). Later, lenalidomide was introduced, a potent structural and functional thalidomide analog that demonstrates anti-angiogenic, proapoptotic, and anti-inflammatory activities in addition to its immunomodulatory effects. Anti-angiogenic agents targeting VEGF/VEGFR signaling and the ErbB family were evaluated next (Table 1, Figure 1). Currently, new agents like crizotinib inhibiting c-Met, ALK and RON (Figure 1) and dasatinib, an oral Src family, bcr-abl, PDGFR α , - β and c-kit TK inhibitor are under investigation (Table 2). In general, mainly pediatric patients with recurrent high-grade astrocytoma were included. Both the retrospective character of part of the studies and the absence of controlled case series makes it difficult to be conclusive about the efficacy of the clinical strategies in pediatric brain tumors.

Interferon

In 1991 the first phase I/II study was published in which children with recurrent or progressive brain tumors were treated with INF- β (Table 1).⁹⁴ Although promising results were shown, results in the following studies including combination treatment with INF and chemotherapy and/or radiation in newly diagnosed brain tumors were somewhat disappointing. INF- α showed no improvement in the 2-year survival in pediatric patients with diffuse intrinsic pontine glioma compared with a historic control population.⁹⁵ Moreover, INF- β in combination with radiation in brain stem glioma and INF- γ combined with low dose cyclophosphamide in high-grade glioma were not sufficient beneficially effective.^{96, 97} Even possible responses on a combination treatment with INF- β , chemotherapy and radiation in brain stem glioma were not convincing.^{98, 99} Overall, given the lack of efficacy and the potential side effects including hepatotoxicity, hematologic toxicity and neurotoxicity, it appears unlikely that interferons will have a future role in anti-angiogenic treatment in pediatric brain tumors.

Metronomic chemotherapy

Metronomic chemotherapy refers to the use of chemotherapy agents in low, frequent (often daily) rhythmic doses with minimal breaks that target endothelial rather than tumor cell proliferation. A number of agents have been used in metronomic schedules against pediatric brain tumors: etoposide, temozolomide, cyclophosphamide or topotecan are given alone or in combination in daily schedules.¹⁰⁰⁻¹⁰⁴ Low dose administration is less toxic compared with conventional or high dose chemotherapy. However, the optimal dosing for metronomic therapy has yet to be determined and may differ for each drug and tumor type.

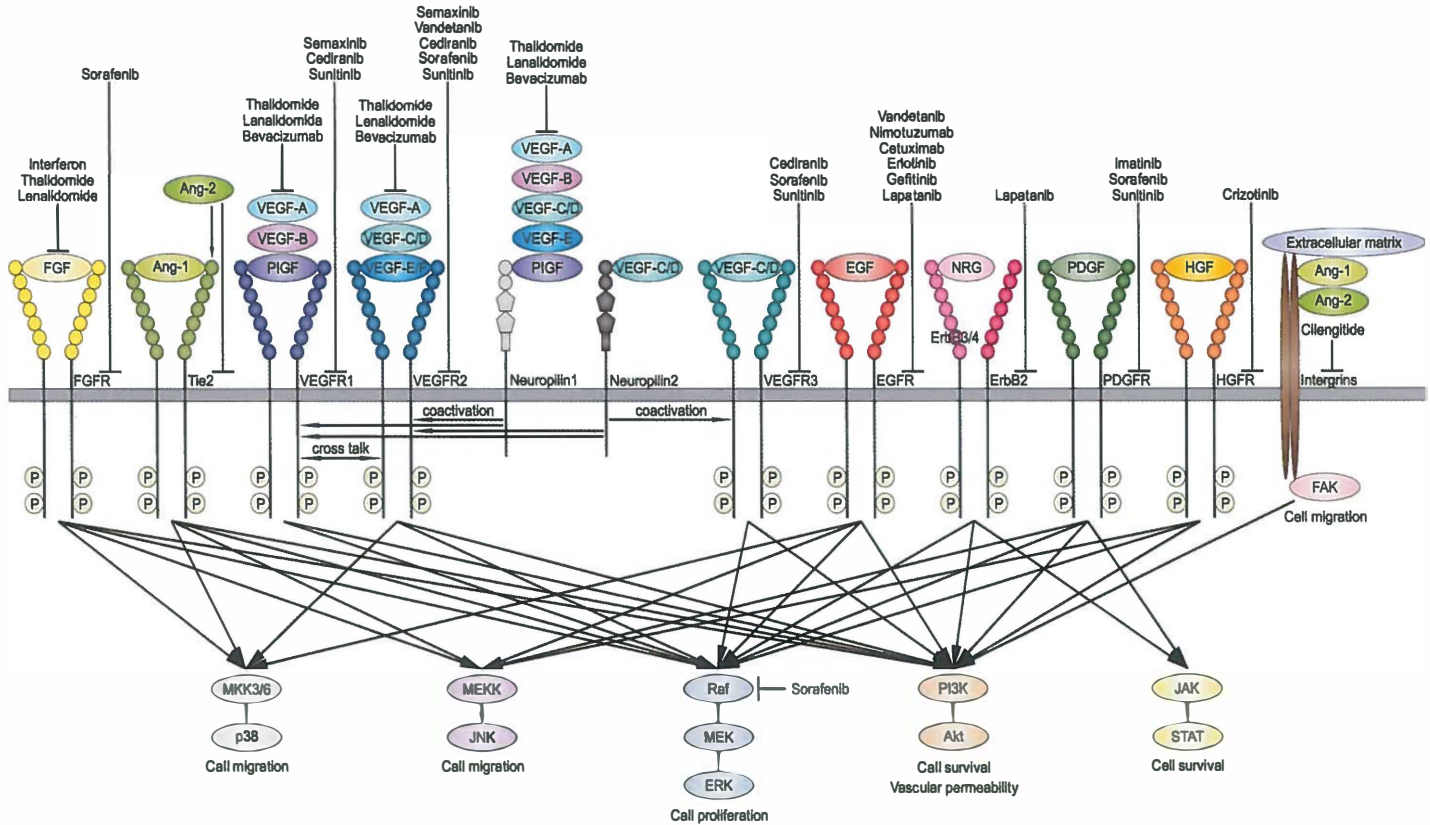


Figure 1. Schematic illustration showing numerous angiogenic mediators activating downstream pathways contributing to the process of tumor angiogenesis. Anti-angiogenic agents are included which are analyzed in published pediatric brain tumor clinical studies or in still ongoing clinical trials.

Up to now, beneficial findings of metronomic chemotherapy in pediatric brain tumors are limited to medulloblastoma which have been described in case report settings.^{101,103} Peyrl et al combined metronomic chemotherapy with the newer anti-angiogenic agent bevacizumab which seems also particularly beneficial in medulloblastoma.¹⁰⁴ At the moment, no clinical trial is ongoing studying metronomic chemotherapy in pediatric brain tumors.

Thalidomide and lenalidomide

The efficacy of thalidomide in pediatric brain tumors is doubtful. Although, a prospective study suggested a better outcome in children with diffuse intrinsic pontine gliomas treated with a combination of thalidomide, temozolomide and radiation, the authors compared the results with literature in which only radiotherapy was given.¹⁰⁵ So the therapeutic benefit could not be exclusively attributed to thalidomide. Also as tumor types varying from low to high-grade glioma were included, it is hard to be conclusive about the efficacy of thalidomide.¹⁰⁶ Thalidomide combined with radiation in newly diagnosed brain stem gliomas even failed to demonstrate any benefit with increased toxicity compared with historical use of radiation alone.¹⁰⁷ Given these moderate results, using thalidomide for future clinical strategies in pediatric brain tumors is not advisable. In contrast, lenalidomide seems to have effect in pediatric brain tumors. However, whether possible antitumor activity and toxicity were dose related has to be further analyzed.¹⁰⁸ Currently, two clinical trials analyzing lenalidomide are recruiting pediatric patients (Table 2).

Anti-VEGF monoclonal antibody and VEGFR tyrosine kinase inhibitors

Bevacizumab is a humanized immunoglobulin G1 monoclonal antibody that binds to and inhibits the activity of VEGF (Figure 1). Results of the efficacy of bevacizumab in clinical studies are various from objective radiographic response and clinical improvement in low-grade glioma¹⁰⁹ and prolonged progression free survival in medulloblastoma^{104, 110} till only minimal efficacy in high-grade glioma¹¹¹⁻¹¹³ and ependymoma¹¹⁴ (Table 1). Cessation of initial therapy resulted in tumor progression. However, more interestingly, despite previous exposure to bevacizumab, these patients showed clinical and/or radiographic improvement or stability with re-treatment.¹⁰⁹

As the majority of the patients was no part of prospective trials, the issue of selection bias raises. Moreover all published studies included recurrent brain tumors that most likely have multiple oncogenic mutations, making them resistant to hypoxia and less dependent on angiogenesis for survival. Since anti-angiogenic therapy is likely to work better in the setting of minimal tumor burden and earlier in the disease course of such patients, it might be worthwhile using bevacizumab at the time of initial diagnosis. In line with this theory and the possible trend of therapeutic benefit by anti-VEGF, bevacizumab is still under investigation and will probably have a future role in the treatment of pediatric brain tumors. The possible synergistic effect of bevacizumab and chemotherapy in pediatric brain tumors is still unclear. Remarkable is that bevacizumab was well tolerated in pediatric patients, sometimes even better than in adults. However, VEGF-targeted medications and dexamethasone are both associated with changes in blood pressure, possibly resulting in PRES, so close monitoring and management of hypertension is required.^{109, 115}

Besides bevacizumab as monoclonal VEGF antibody, small molecule tyrosine kinase inhibitors of the VEGF receptors, including semaxanib, vandetanib, cediranib, sorafenib and sunitinib were described in published studies (Table 1) or are still under research in ongoing studies (Table 2) (Figure 1).^{116,117} However, the clinical development of semaxanib has been halted in part due to the limited single-agent activity, as well as the significant toxicity related to the semaxanib dependent co-administration in the cremophor vehicle.¹¹⁶ In contrast, vandetanib, showed encouraging results¹¹⁷ and is continually being studied also in combination with other small molecule inhibitors like dasatinib (Table 2).

Anti-EGFR monoclonal antibodies and ErbB tyrosine kinase inhibitors

Two EGFR monoclonal antibodies including nimotuzumab and cetuximab, and three different ErbB tyrosine kinase inhibitors were evaluated in pediatric brain tumors (Table 1, Figure 1). Although modest activity was observed of nimotuzumab in resistant or relapsed high-grade glioma in particular DIPG, nimotuzumab combined with radiotherapy was not more efficacious than chemotherapy.¹¹⁸ The prospective study of Saurez et al was minor contributory to insights into nimotuzumab's efficacy due to a high heterogeneity of included tumors and variety of treatment regimens.¹¹⁹ Up to now, little is known about their efficacy as these agents were yet mainly analyzed in phase I studies. The only phase II study in which one of the EGFR tyrosine kinase inhibitors was tested, analyzed patients with newly diagnosed brain stem glioma and supratentorial malignant gliomas treated with gefitinib combined with radiotherapy (Table 1). Unfortunately, progression free survival and overall survival data were consistent with the generally disappointing therapeutic results observed for these tumors.¹²⁰

In general, the agents targeting the ErbB family showed to be well tolerated in children with brain tumors, also in combination with chemotherapy or radiotherapy.¹²¹⁻¹²⁴ The recommended dose was even higher in children compared with adults, mainly due to pharmacokinetic rather than pharmacodynamic particularities.^{123, 124} However, potentially life-threatening intratumoral hemorrhage remains a substantial risk,¹²⁵ comparable with VEGF-targeted therapy, so close monitoring is required during ErbB-targeted treatment. Because there is yet not much known about the efficacy of these agents in pediatric brain tumors and encouraging results about the crucial role of ErbB family members in the process of tumor angiogenesis have been described, currently numerous studies investigate ErbB targeting agents, given this therapeutic strategy a future perspective in the treatment of pediatric brain tumors. On the basis that lapatinib, an EGFR and ErbB2 tyrosine kinase inhibitor, may be synergistic with bevacizumab, a phase II trial of this combined strategy is currently being conducted in children with recurrent ependymoma (Table 2).

Table 1. Clinical studies of anti-angiogenic therapy in pediatric brain tumors

Drug	Target in angiogenesis	Combination therapy	Tumor type (no. patients)	Phase	Publication
Interferon- β (i.v.)	bFGF	-	Brain tumor (29)	I/II	Allen 1991 ⁹⁴
		ACNU, RT	BSG (16)		Wakabayashi 1992 ⁹⁸
Interferon- γ (i.v.)	bFGF, IL-8	RT	BSG (32)	I/II	Packer 1996 ⁹⁷
		Low dose CPM	HGG (40)		Wolff 2006 ⁹⁶
Interferon- α (i.v.)		MCNU, RT	BSG (15)	retro	Ohno 2009 ⁹⁹
Thalidomide (oral)	TNF- α , VEGF, bFGF, IL-8	RT	BSG, glioblastoma (13)	II	Turner 2007 ¹⁰⁷
Lenalidomide (CC5013) (oral)	TNF- α , VEGF, bFGF, IL-6	Carboplatin, vincristine, fluvastatin, RT	BSG (9)	II	López-Aguilar 2008 ¹⁴²
		TZM, RT	DIPG (17)	pros	Kim 2010 ¹⁰⁵
		-	Brain tumor (51)	I	Warren 2011 ¹⁰⁸
Bevacizumab (Avastin®) (i.v.)	VEGF	Metronomic anti-angiogenic therapy, RT	Brain tumor (30)	retro	Reismüller 2010 ¹¹⁵
		Irinotecan	HGG (12)	retro	Narayana 2010 ¹¹²
		Irinotecan	HGG, DIPG (31)	II	Gururangan 2010 ¹¹¹
		Irinotecan, TZM, CCNU	HGG (8)	retro	Parekh 2011 ¹¹³
		Irinotecan, TZM	Medulloblastoma (2)	CR	Aguilera 2011 ¹¹⁰
		<i>Thalidomide</i> , celecoxib, fenofibrate, etoposide, cyclophosphamide	Embryonal brain tumor (16)		Peyrl 2012 ¹⁰⁴
Semaxinib (SUS416) (i.v.)	VEGFR-1, -2	-	Ependymoma (15)	II	Gururangan 2012 ¹¹⁴
		Irinotecan	LGG (14)	retro	Hwang 2013 ¹⁰⁹
Vandetanib (oral)	VEGFR-2, EGFR	-	Brain tumor (excl BSG) (33)	I	Kieran 2009 ¹¹⁶
		RT	DIPG (21)	I	Broniscer 2010 ¹¹⁷
Nimotuzumab (i.v.)	EGFR	CT, RT	Brain tumor (22)	pros	Saurez 2009 ¹¹⁹
		-	HGG (47)	II	Bode 2012 ¹¹⁸
		RT	DIPG (42)	III	Bode 2012 ¹¹⁸
Cetuximab (i.v.)	EGFR	Irinotecan	Brain tumor (26)	I	Trippett 2009 ¹⁴³
Erlotinib (Tarceva®) (oral)	EGFR	TZM	Brain tumor (20)	I	Jakacki 2008 ¹²¹
		RT	HGG (23)	I	Broniscer 2009 ¹²²
		RT	Malignant brain tumor (51)	I	Geoerger 2011 ¹²³
Gefitinib (oral)	EGFR	RT	BSG, HGG (23)	I	Geyer 2010 ¹²⁵
		RT	DIPG (43)	II	Pollack 2011 ¹⁴⁴
Lapatinib (oral)	EGFR, ErbB2	Steroids	Malignant brain tumor (59)	I	Fouladi 2010 ¹⁴⁵
Imatinib (oral) (Gleevec®)	PDGFR α , bcr-abl, c-kit	-	PA (1)	CR	McLaughlin 2003 ¹⁴⁶
		RT	Glioma (84)	I	Pollack 2007 ¹²⁷
		- / CT	HCG (6)		Peyrl 2009 ¹²⁶
		-	Brain tumor (19)	II	Baruchel 2009 ¹²⁸
Cilengitide (i.v.)	α v β 3, α v β 5 integrins	-	Brain tumor (31)	I	MacDonald 2008 ¹²⁹

bFGF: basic fibroblast growth factor; RT: radiotherapy; BSG: brain stem glioma; CPM: cyclophosphamide; HGG: high-grade glioma; retro: retrospective; DIPG: diffuse intrinsic pontine glioma; TNF- α : tumor necrosis factor α ; VEGF: vascular endothelial growth factor; IL: interleukin; TZM: temozolomide; pros: prospective; LGG: low-grade glioma; CR: case report; VEGFR: vascular endothelial growth factor receptor; EGFR: epidermal growth factor receptor; CT: chemotherapy; PDGFR α : platelet derived growth factor receptor α ; PA: pilocytic astrocytoma; HCG: hypothalamic-chiasmatic glioma.

Table 2. Ongoing studies of anti-angiogenic therapy in pediatric brain tumors

Drug	Target in angiogenesis	Combination therapy	Tumor type	Phase	Estimated completion year
Thalidomide (oral)	TNF- α , VEGF, bFGF, IL-8	TZM	Brain tumor	II	Kieran (2010)
		Carboplatin, RT	BSG	II	Goldman (2007)
Lenalidomide (CC5013) (oral)	TNF- α , VEGF, bFGF, IL-6	RT	Brain tumor	I	Warren (2012)
		RT	DIPG, HGG	I	Warren (2016)
Bevacizumab (Avastin®) (i.v.)	VEGF	<i>Lapatinib</i>	Ependymoma	II	Rytting (2013)
		Irinotecan, TZM	Brain tumor	I	Stapleton (2013)
		Valproic acid, RT	HGG	II	Su (2014)
		Irinotecan	Medulloblastoma, PNET	II	Levy (2013)
		hydrochloride, TZM			
		RT, <i>Erlotinib</i> /TZM	DIPG	II	Kieran (2013)
		Vorinostat/TZM	HGG	II/III	Fouladi (2019)
		Thalidomide, celecoxib, fenofibrate acid, etoposide, cyclophosphamide	Medulloblastoma	II	Peyrl (2018)
Vandetanib (oral)	VEGFR-2, EGFR	RT	DIPG	I	Broniscer (2011)
		RT, <i>Dasatinib</i>	DIPG	I	Broniscer (2013)
Cediranib (AZD2171) (oral)	VEGFR-1, -2, -3	-	Brain tumor	I	Kieran (2012)
Sorafenib (oral)	VEGFR-2, -3, PDGFR β , Raf, c-kit, BRAF, FGFR-1	-	LGG	II	Karajannis (2014)
Sunitinib (SU11248) (oral)	VEGFR-1, -2, -3, PDGFR α , β , RET, c-kit, CSF-1R	-	Malignant glioma, ependymoma	II	Wetmore (-)
Nimotuzumab (i.v.)	EGFR	RT	DIPG	II	Epelman (2012)
		-	DIPG	II	Bouffet (2010)
Cetuximab (i.v.)	EGFR	External beam RT, Irinotecan	DIPG, HGG	II	Dunkel (2013)
Erlotinib (Tarceva®) (oral)	EGFR	(Versus Etoposide)	Ependymoma	II	APGD (2013)
		-	Ependymoma	II	APGD (2013)
		RT	Glioma	I/II	Broniscer (2015)
		RT	Malignant brain tumor, BSG, LGG	I	Hargrave (-)
		Rapamycin CT, (Erlotinib versus Etoposide)	Embryonal brain tumor, choroid plexus carcinoma, ependymoma, HGG	I	Packer (2017)
				-	Gajjar (2019)
Cilengitide (i.v.)	α v β 3, α v β 5 integrins	-	HGG	II	MacDonald (2011)
		RT	DIPG	I	Leblond (2015)
		TZM	Glioma	II	Kramm (2015)
Crizotinib (oral)	c-Met, ALK, RON	<i>Dasatinib</i>	DIPG, HGG	I	Broniscer (2015)

TNF- α : tumor necrosis factor α ; VEGF: vascular endothelial growth factor; bFGF: basic fibroblast growth factor; IL: interleukin; TZM: temozolomide; RT: radiotherapy; BSG: brain stem glioma; DIPG: diffuse intrinsic pontine glioma; HGG: high-grade glioma; VEGFR: vascular endothelial growth factor receptor; EGFR: epidermal growth factor receptor; PDGFR: platelet derived growth factor receptor; FGFR: fibroblast growth factor receptor; LGG: low-grade glioma; CSF-1R: colony stimulating factor 1 receptor; CT: chemotherapy; ALK: anaplastic lymphoma kinase; RON: recepteur d'origine nantais.

Remaining drugs

Imatinib mesylate disrupts PDGF/PDGFR autocrine and paracrine loops and inhibits bcr-abl and c-kit (Figure 1). The results of imatinib in pediatric brain tumors were disappointing, except for possible activity of imatinib in progressive hypothalamic-chiasmatic astrocytoma.¹²⁶ However, in a phase I trial it was suggested that imatinib may increase the risk of intratumoral hemorrhage,¹²⁷ and a phase II study failed to observe objective tumor response despite immunohistochemical target confirmation in pediatric brain tumor samples (Table 1).¹²⁸ One potential explanation for the lack of response was that, despite the possibility for partial blood brain barrier disruption, less than 5% of the corresponding imatinib plasma levels were found in the cerebrospinal fluid, perhaps due to poor penetration of the blood brain barrier. Rationally, as imatinib showed overall no convincing therapeutic beneficial effects in pediatric brain tumors, up to now, no clinical trials evaluating imatinib in pediatric brain tumors are ongoing.

Another, more promising anti-angiogenic agent is cilengitide, an antagonist of $\alpha v\beta 3$ and $\alpha v\beta 5$ integrins which are particularly important in angiogenesis through their ability to bind to arginine-glycine-aspartic acid amino acid sequences found on matrix proteins, allowing endothelial cells to attach to the extracellular matrix (Figure 1). Cilengitide inhibits tumor growth in a dose-dependent manner in *in vivo* medulloblastoma and glioblastoma models. MacDonald et al described the first phase I clinical trial in which cilengitide in children with refractory brain tumors was well tolerated (Table 1).¹²⁹ As the demonstrated responses were encouraging for preliminary evidence of activity of this agent against pediatric brain tumors, currently three cilengitide studies are ongoing (Table 2). Finally, new tyrosine kinase inhibitors are upcoming, like crizotinib inhibiting c-Met combined with dasatinib targeting Src in diffuse intrinsic glioma and high-grade glioma (Table 2). c-Met showed to be associated with tumor invasiveness as tumor escape mechanism during anti-angiogenic therapies. The importance of Src in pediatric brain tumors was previously determined with kinome profiling.¹³⁰ So, this combination treatment of crizotinib and dasatinib could be a promising strategy.

Response measuring and clinical monitoring

The evaluation of anti-angiogenic therapy in pediatric brain tumors relies on the overall survival as an ultimate gold standard or, more commonly in patients with recurrent disease, on clinical (neurologic) response, quality of life, progression free survival and the radiographic response rate. Symptom-based end points are subjective and are often influenced by factors not directly related to tumor burden. The tools to assess objectively and reproducibly quality of life in children are limited with a high interpatient variability. Unfortunately, up to now, no blood, urine or cerebrospinal fluid biomarkers have been identified that could reliably reflect response or predict response to anti-angiogenic agents in pediatric brain tumors. Moreover, even regular lumbar punctures are too invasive for routinely clinical use. To actually measure and monitor objective response to anti-angiogenic agents, radiologic assessment of tumor response will be more crucial during anti-angiogenic therapy.

However, in the radiologic measurement of objective tumor response to anti-angiogenic therapy difficulties have been raised, including the phenomenon termed 'pseudo-response'.¹³¹⁻¹³³ Pediatric brain tumors that display contrast enhancement on T1 weighted magnetic resonance imaging (MRI) do so as a consequence of contrast extravasation in abnormally leaky blood vessels.¹³³ Anti-angiogenic therapy can modify vascular permeability and interstitial pressure; restore the integrity of the blood brain barrier, thereby reducing contrast leakage from the vasculature and thus the extent and distribution of gadolinium extravasation. In these possible 'pseudo-response' cases it is questionable to which extent a reduction in contrast enhancement reflects true antitumor activity or may purely reflect vascular changes. If this effect reflects only vascular permeability, interruption of anti-angiogenic therapy may lead to a rebound resulting in an overestimation of tumor growth on MRI.¹³¹⁻¹³⁴ Moreover, low-grade astrocytomas (WHO grade II) for example are less contrast enhancing tumors in imaging and ependymoma may have varying degrees of contrast enhancement,^{2, 131} making it even more difficult to distinguish between tumor response or tumor progression. Furthermore increased T1 enhancement can also be induced by a variety of non-tumoral processes such as corticosteroid doses, seizure activity, post-surgical changes, ischemia, subacute radiation and radiation necrosis.¹³⁵⁻¹³⁸

To detect 'pseudo-response' and non-enhancing tumor progression, T2 and fluid-attenuated inversion recovery (FLAIR) MRI sequences have been recommended besides T1 weighted MRI. This combination of MRI sequences could also determine possible tumor escape mechanism during anti-angiogenic therapy in which a non-enhancing portion of tumor increased, suggestive of infiltrative tumor progression despite the continuing radiologic response of the enhancing lesions.¹³² However, measurement of T2-FLAIR signal is challenging and distinguishing tumor from radiation-related changes, edema, and even seizures remains difficult.

The use of volumetric assessment would possibly allow more accurate determination of the contrast-enhancing and nonenhancing volumes and overcome limitations of two-dimensional measurements of lesions surrounding a surgical cavity.¹³⁹ It has also been suggested that advanced MRI techniques such as perfusion, permeability, and diffusion imaging, magnetic resonance spectroscopy, and [18F]-fluorothymidine and amino acid positron emission tomography (PET) may allow differentiation of non-enhancing tumor from other causes of increased FLAIR signal or predict tumor response.¹³³ However these techniques require rigorous validation before they can be used in pediatric clinical trial setting.

Recently, the institution of the Response Assessment in Pediatric Neuro-Oncology (RAPNO) has been established to develop a consensus on the radiological assessment for clinical trials involving children with brain tumors, and better define response so that it reflects drug activity. Initially, response criteria for three tumor subtypes will be developed and subsequently validated in clinical trials: low-grade glioma, high-grade glioma and diffuse intrinsic pontine glioma, each with its own inherent radiographic features. Inclusion of advanced MRI techniques will be determined per tumor type. Eventually, a more personalized imaging approach based on tumor characteristics, treatment modality and clinical factors may be necessary to adequately define radiographic response in pediatric brain tumors.¹⁴⁰

Conclusions and future perspectives

The research field of tumor angiogenesis and anti-angiogenic therapy has undergone many crucial developments. More insight has been generated into the mechanism of angiogenesis and possible tumor escape mechanisms to anti-angiogenic treatment. New anti-angiogenic agents have been developed and replaced the relative older ones with low efficacy and significant toxicity levels. However, a substantial part of the generated knowledge has been derived from extensive research in adult glioblastoma, often seen as a model for studying angiogenesis. These insights have been extrapolated to pediatric brain tumors. It is questionable if the relatively limited studies in pediatric brain tumors and the extrapolation from adult glioblastoma are sufficient to make a rational translation into clinical trials in which pediatric patients are exposed to anti-angiogenic agents. Moreover, it has to be noted that inclusion of specific tumor subtypes including diffuse intrinsic pontine glioma in pediatric clinical trials is not only based on their expected susceptibility to anti-angiogenic therapy but also because of its fatal character despite intensive conventional therapies. Given the fact that many clinical trials in pediatric brain tumors are in the phase I setting and new agents are upcoming, we are still at the beginning of the development and optimization of anti-angiogenic therapy as an innovative clinical strategy. Up to now, some studies showed encouraging data of anti-angiogenic therapy in pediatric brain tumors, however results were partly generated in uncontrolled cases and not unambiguously presenting an anti-angiogenic strategy that significantly increases overall survival. So further research is definitely warranted in this field, especially focused on pediatric brain tumors.

Future therapeutic strategies will possibly combine anti-angiogenic agents with conventional treatment strategies like chemotherapy, as the possible synergistic effect is still unknown in pediatric brain tumors. However, multi targeted therapy with various potential anti-angiogenic agents could be of even more interest, anticipating on possible tumor escape mechanisms. These strategies could be especially suitable for children with an unresectable brain tumor, taking into account that introducing this strategy at initial diagnosis could be highly effective. Although potential anti-angiogenic agents are generally well tolerated in pediatric patients, strict clinical monitoring remains required which will be accompanied by radiologic challenges. In conclusion, because of the need for new therapeutic strategies in pediatric brain tumors as leading cause of cancer morbidity and mortality among children, multi targeted therapy with anti-angiogenic agents could have a future therapeutic role. There are also arguments for a personalized targeted therapy based on tumor marker analyses of recently derived pediatric brain tumor tissue.¹⁴¹ A step forward would be the discovery of biomarkers or tumor marker patterns, which will predict accurately the benefit of which drug.

References

1. Dolecek TA, Propp JM, Stroup NE, Kruchko C. CBTRUS statistical report: primary brain and central nervous system tumors diagnosed in the United States in 2005-2009. *Neuro Oncol* 2012;14 Suppl 5:v1-49.
2. Louis DN, Ohgaki H, Wiestler OD, Cavenee WK. *Classification of Tumours of the Central Nervous System*. 4th ed. Lyon: IARC; 2007.
3. Sie M, de Bont ES, Scherpen FJ, Hoving EW, den Dunnen WF. Tumour vasculature and angiogenic profile of paediatric pilocytic astrocytoma; is it much different from glioblastoma? *Neuropathol Appl Neurobiol*. 2010;36:636-647.
4. Bartels U, Hawkins C, Jing M, et al. Vascularity and angiogenesis as predictors of growth in optic pathway/hypothalamic gliomas. *J Neurosurg*. 2006;104:314-320.
5. Pollack IF, Finkelstein SD, Woods J, et al. Expression of p53 and prognosis in children with malignant gliomas. *N Engl J Med*. 2002;346:420-427.
6. Mueller S, Chang S. Pediatric brain tumors: Current treatment strategies and future therapeutic approaches. *Neurotherapeutics*. 2009;6:570-586.
7. Hargrave D, Bartels U, Bouffet E. Diffuse brainstem glioma in children: Critical review of clinical trials. *Lancet Oncol*. 2006;7:241-248.
8. Ross GW, Rubinstein LJ. Lack of histopathological correlation of malignant ependymomas with postoperative survival. *J Neurosurg*. 1989;70:31-36.
9. Ellison DW, Kocak M, Figarella-Branger D, et al. Histopathological grading of pediatric ependymoma: reproducibility and clinical relevance in European trial cohorts. *J Negat Results Biomed* 2011;10:7.
10. McGuire CS, Sainani KL, Fisher PG. Both location and age predict survival in ependymoma: A SEER study. *Pediatr Blood Cancer*. 2009;52:65-69.
11. Folkman J. Tumor angiogenesis: Therapeutic implications. *N Engl J Med*. 1971;285:1182-1186.
12. Mito T, Konomi H, Houdou S, Takashima S. Immunohistochemical study of the vasculature in the developing brain. *Pediatr Neurol*. 1991;7:18-22.
13. Breier G, Albrecht U, Sterrer S, Risau W. Expression of vascular endothelial growth factor during embryonic angiogenesis and endothelial cell differentiation. *Development*. 1992;114:521-532.
14. Ballabh P, Braun A, Nedergaard M. Anatomic analysis of blood vessels in germinal matrix, cerebral cortex, and white matter in developing infants. *Pediatr Res*. 2004;56:117-124.
15. Carmeliet P. Mechanisms of angiogenesis and arteriogenesis. *Nat Med*. 2000;6:389-395.
16. Jain RK. Molecular regulation of vessel maturation. *Nat Med*. 2003;9:685-693.
17. Carmeliet P. Angiogenesis in health and disease. *Nat Med*. 2003;9:653-660.
18. Reynolds LP, Killilea SD, Redmer DA. Angiogenesis in the female reproductive system. *FASEB J*. 1992;6:886-892.
19. Folkman J. Angiogenesis and apoptosis. *Semin Cancer Biol*. 2003;13:159-167.
20. Hoeben A, Landuyt B, Highley MS, Wildiers H, Van Oosterom AT, De Bruijn EA. Vascular endothelial growth factor and angiogenesis. *Pharmacol Rev*. 2004;56:549-580.
21. Bergers G, Benjamin LE. Tumorigenesis and the angiogenic switch. *Nat Rev Cancer*. 2003;3:401-410.
22. Holash J, Maisonpierre PC, Compton D, et al. Vessel cooption, regression, and growth in tumors mediated by angiopoietins and VEGF. *Science*. 1999;284:1994-1998.
23. Ramsauer M, Krause D, Dermietzel R. Angiogenesis of the blood-brain barrier in vitro and the function of cerebral pericytes. *FASEB J*. 2002;16:1274-1276.

24. Scholler K, Trinkl A, Klopotoski M, et al. Characterization of microvascular basal lamina damage and blood-brain barrier dysfunction following subarachnoid hemorrhage in rats. *Brain Res.* 2007;1142:237-246.
25. Ribatti D, Vacca A, Dammacco F. The role of the vascular phase in solid tumor growth: a historical review. *Neoplasia* 1999;1:293-302.
26. Carmeliet P, Jain RK. Angiogenesis in cancer and other diseases. *Nature* 2000;407:249-257.
27. Fagiani E, Christofori G. Angiopoietins in angiogenesis. *Cancer Lett.* 2013;328:18-26.
28. Fukumura D, Duda DG, Munn LL, Jain RK. Tumor microvasculature and microenvironment: Novel insights through intravital imaging in pre-clinical models. *Microcirculation.* 2010;17:206-225.
29. Vajkoczy P, Menger MD. Vascular microenvironment in gliomas. *Cancer Treat Res.* 2004;117:249-262.
30. Wagemakers M, Sie M, Hoving EW, Molema G, de Bont ES, den Dunnen WF. Tumor vessel biology in pediatric intracranial ependymoma. *J Neurosurg Pediatr.* 2010;5:335-341.
31. Dvorak HF. Vascular permeability factor/vascular endothelial growth factor: A critical cytokine in tumor angiogenesis and a potential target for diagnosis and therapy. *J Clin Oncol.* 2002;20:4368-4380.
32. Neufeld G, Cohen T, Gengrinovitch S, Poltorak Z. Vascular endothelial growth factor (VEGF) and its receptors. *FASEB J.* 1999;13:9-22.
33. Woolard J, Bevan HS, Harper SJ, Bates DO. Molecular diversity of VEGF-A as a regulator of its biological activity. *Microcirculation.* 2009;16:572-592.
34. Houck KA, Leung DW, Rowland AM, Winer J, Ferrara N. Dual regulation of vascular endothelial growth factor bioavailability by genetic and proteolytic mechanisms. *J Biol Chem.* 1992;267:26031-26037.
35. Park JE, Keller GA, Ferrara N. The vascular endothelial growth factor (VEGF) isoforms: Differential deposition into the subepithelial extracellular matrix and bioactivity of extracellular matrix-bound VEGF. *Mol Biol Cell.* 1993;4:1317-1326.
36. Kusters B, de Waal RM, Wesseling P, et al. Differential effects of vascular endothelial growth factor A isoforms in a mouse brain metastasis model of human melanoma. *Cancer Res.* 2003;63:5408-5413.
37. Sie M, den Dunnen WF, Scherpen FJ, Hoving EW, de Bont ES. Overlapping VEGF-A isoform ratios in pilocytic astrocytoma and glioblastoma. *Cell Oncol.* 2012;35(Suppl 1):Abstract PP78.
38. Tozer GM, Akerman S, Cross NA, et al. Blood vessel maturation and response to vascular-disrupting therapy in single vascular endothelial growth factor-A isoform-producing tumors. *Cancer Res.* 2008;68:2301-2311.
39. Bates DO, Cui TG, Doughty JM, et al. VEGF165b, an inhibitory splice variant of vascular endothelial growth factor, is down-regulated in renal cell carcinoma. *Cancer Res.* 2002;62:4123-4131.
40. Rennel ES, Varey AH, Churchill AJ, et al. VEGF(121)b, a new member of the VEGF(xxx)b family of VEGF-A splice isoforms, inhibits neovascularisation and tumour growth in vivo. *Br J Cancer.* 2009;101:1183-1193.
41. Miller-Kasprzak E, Jagodzinski PP. 5-aza-2'-deoxycytidine increases the expression of anti-angiogenic vascular endothelial growth factor 189b variant in human lung microvascular endothelial cells. *Biomed Pharmacother.* 2008;62:158-163.
42. Varey AH, Rennel ES, Qiu Y, et al. VEGF 165 b, an antiangiogenic VEGF-A isoform, binds and inhibits bevacizumab treatment in experimental colorectal carcinoma: Balance of pro- and antiangiogenic VEGF-A isoforms has implications for therapy. *Br J Cancer.* 2008;98:1366-1379.
43. Harper SJ, Bates DO. VEGF-A splicing: The key to anti-angiogenic therapeutics? *Nat Rev Cancer.* 2008;8:880-887.

44. Bates DO, Catalano PJ, Symonds KE, et al. Association between VEGF splice isoforms and progression-free survival in metastatic colorectal cancer patients treated with bevacizumab. *Clin Cancer Res.* 2012;18:6384-6391.
45. Catena R, Larzabal L, Larrayoz M, et al. VEGF121b and VEGF165b are weakly angiogenic isoforms of VEGF-A. *Mol Cancer* 2010;9:320.
46. Harris S, Craze M, Newton J, et al. Do anti-angiogenic VEGF (VEGFxxx) isoforms exist? A cautionary tale. *PLoS One.* 2012;7:e35231.
47. Hoeben A, Landuyt B, Highley MS, Wildiers H, Van Oosterom AT, De Bruijn EA. Vascular endothelial growth factor and angiogenesis. *Pharmacol Rev.* 2004;56:549-580.
48. Hiratsuka S, Nakao K, Nakamura K, Katsuki M, Maru Y, Shibuya M. Membrane fixation of vascular endothelial growth factor receptor 1 ligand-binding domain is important for vasculogenesis and angiogenesis in mice. *Mol Cell Biol.* 2005;25:346-354.
49. Staton CA. Class 3 semaphorins and their receptors in physiological and pathological angiogenesis. *Biochem Soc Trans.* 2011;39:1565-1570.
50. Koga K, Todaka T, Morioka M, et al. Expression of angiopoietin-2 in human glioma cells and its role for angiogenesis. *Cancer Res.* 2001;61:6248-6254.
51. Daly C, Eichten A, Castanaro C, et al. Angiopoietin-2 functions as a Tie2 agonist in tumor models, where it limits the effects of VEGF inhibition. *Cancer Res.* 2013;73:108-118.
52. Yuan HT, Khankin EV, Karumanchi SA, Parikh SM. Angiopoietin 2 is a partial agonist/antagonist of Tie2 signaling in the endothelium. *Mol Cell Biol.* 2009;29:2011-2022.
53. Davis S, Papadopoulos N, Aldrich TH, et al. Angiopoietins have distinct modular domains essential for receptor binding, dimerization and superclustering. *Nat Struct Biol.* 2003;10:38-44.
54. Pietila R, Natynki M, Tammela T, et al. Ligand oligomerization state controls Tie2 receptor trafficking and angiopoietin-2-specific responses. *J Cell Sci.* 2012;125:2212-2223.
55. Turner N, Grose R. Fibroblast growth factor signalling: From development to cancer. *Nat Rev Cancer.* 2010;10:116-129.
56. Beenken A, Mohammadi M. The FGF family: Biology, pathophysiology and therapy. *Nat Rev Drug Discov.* 2009;8:235-253.
57. Knights V, Cook SJ. De-regulated FGF receptors as therapeutic targets in cancer. *Pharmacol Ther.* 2010;125:105-117.
58. Asahara T, Bauters C, Zheng LP, et al. Synergistic effect of vascular endothelial growth factor and basic fibroblast growth factor on angiogenesis in vivo. *Circulation.* 1995;92:11365-71.
59. Lurje G, Lenz HJ. EGFR signaling and drug discovery. *Oncology.* 2009;77:400-410.
60. Pollack IF, Hamilton RL, James CD, Finkelstein SD, Burnham J, Yates AJ et al. Rarity of PTEN deletions and EGFR amplification in malignant gliomas of childhood: Results from the children's cancer group 945 cohort. *J Neurosurg.* 2006;105:418-424.
61. Khatua S, Peterson KM, Brown KM, et al. Overexpression of the EGFR/FKBP12/HIF-2alpha pathway identified in childhood astrocytomas by angiogenesis gene profiling. *Cancer Res.* 2003;63:1865-1870.
62. Bredel M, Pollack IF, Hamilton RL, James CD. Epidermal growth factor receptor expression and gene amplification in high-grade non-brainstem gliomas of childhood. *Clin Cancer Res.* 1999;5:1786-1792.
63. Gilbertson RJ, Hill DA, Hernan R, et al. ERBB1 is amplified and overexpressed in high-grade diffusely infiltrative pediatric brain stem glioma. *Clin Cancer Res.* 2003;9:3620-3624.
64. Gilbertson RJ. ERBB2 in pediatric cancer: Innocent until proven guilty. *Oncologist.* 2005;10:508-517.
65. Calzolari F, Malatesta P. Recent insights into PDGF-induced gliomagenesis. *Brain Pathol.* 2010;20:527-538.

66. Becher OJ, Hambardzumyan D, Walker TR, et al. Preclinical evaluation of radiation and perifosine in a genetically and histologically accurate model of brainstem glioma. *Cancer Res.* 2010;70:2548-2557.
67. Thorarinsdottir HK, Santi M, McCarter R, et al. Protein expression of platelet-derived growth factor receptor correlates with malignant histology and PTEN with survival in childhood gliomas. *Clin Cancer Res.* 2008;14:3386-3394.
68. Ellis LM, Hicklin DJ. VEGF-targeted therapy: Mechanisms of anti-tumour activity. *Nat Rev Cancer.* 2008;8:579-591.
69. Seet RC, Rabinstein AA. Clinical features and outcomes of posterior reversible encephalopathy syndrome following bevacizumab treatment. *QJM.* 2012;105:69-75.
70. Jain RK. Normalization of tumor vasculature: An emerging concept in antiangiogenic therapy. *Science.* 2005;307:58-62.
71. Dickson PV, Hamner JB, Sims TL, et al. Bevacizumab-induced transient remodeling of the vasculature in neuroblastoma xenografts results in improved delivery and efficacy of systemically administered chemotherapy. *Clin Cancer Res.* 2007;13:3942-3950.
72. Wildiers H, Guetens G, De Boeck G, et al. Effect of antivascular endothelial growth factor treatment on the intratumoral uptake of CPT-11. *Br J Cancer.* 2003;88:1979-1986.
73. Franco M, Man S, Chen L, et al. Targeted anti-vascular endothelial growth factor receptor-2 therapy leads to short-term and long-term impairment of vascular function and increase in tumor hypoxia. *Cancer Res.* 2006;66:3639-3648.
74. Sikkema AH, de Bont ES, Molema G, et al. Vascular endothelial growth factor receptor 2 (VEGFR-2) signalling activity in paediatric pilocytic astrocytoma is restricted to tumour endothelial cells. *Neuropathol Appl Neurobiol.* 2011;37:538-548.
75. Gaur P, Bose D, Samuel S, Ellis LM. Targeting tumor angiogenesis. *Semin Oncol.* 2009;36:S12-9.
76. Bergers G, Hanahan D. Modes of resistance to anti-angiogenic therapy. *Nat Rev Cancer.* 2008;8:592-603.
77. Norden AD, Drappatz J, Wen PY. Antiangiogenic therapies for high-grade glioma. *Nat Rev Neurol.* 2009;5:610-620.
78. Sennino B, McDonald DM. Controlling escape from angiogenesis inhibitors. *Nat Rev Cancer.* 2012;12:699-709.
79. Thompson EM, Frenkel EP, Neuwelt EA. The paradoxical effect of bevacizumab in the therapy of malignant gliomas. *Neurology.* 2011;76:87-93.
80. Ma J, Li S, Reed K, Guo P, Gallo JM. Pharmacodynamic-mediated effects of the angiogenesis inhibitor SU5416 on the tumor disposition of temozolomide in subcutaneous and intracerebral glioma xenograft models. *J Pharmacol Exp Ther.* 2003;305:833-839.
81. Ma J, Pulfer S, Li S, Chu J, Reed K, Gallo JM. Pharmacodynamic-mediated reduction of temozolomide tumor concentrations by the angiogenesis inhibitor TNP-470. *Cancer Res.* 2001;61:5491-5498.
82. Grossman R, Rudek MA, Brastianos H, et al. The impact of bevacizumab on temozolomide concentrations in intracranial U87 gliomas. *Cancer Chemother Pharmacol.* 2012;70:129-139.
83. Grossman R, Tyler B, Rudek MA, et al. Microdialysis measurement of intratumoral temozolomide concentration after cediranib, a pan-VEGF receptor tyrosine kinase inhibitor, in a U87 glioma model. *Cancer Chemother Pharmacol.* 2013;72:93-100.
84. Zhou Q, Gallo JM. Differential effect of sunitinib on the distribution of temozolomide in an orthotopic glioma model. *Neuro Oncol.* 2009;11:301-310.
85. Arao T, Matsumoto K, Furuta K, et al. Acquired drug resistance to vascular endothelial growth factor receptor 2 tyrosine kinase inhibitor in human vascular endothelial cells. *Anticancer Res.* 2011;31:2787-2796.

86. Arrondeau J, Mir O, Boudou-Rouquette P, et al. Sorafenib exposure decreases over time in patients with hepatocellular carcinoma. *Invest New Drugs*. 2012;30:2046-2049.
87. Gotink KJ, Broxterman HJ, Labots M, et al. Lysosomal sequestration of sunitinib: A novel mechanism of drug resistance. *Clin Cancer Res*. 2011;17:7337-7346.
88. Sitohy B, Nagy JA, Jaminet SC, Dvorak HF. Tumor-surrogate blood vessel subtypes exhibit differential susceptibility to anti-VEGF therapy. *Cancer Res*. 2011;71:7021-7028.
89. Thurston G, Noguera-Troise I, Yancopoulos GD. The delta paradox: DLL4 blockade leads to more tumour vessels but less tumour growth. *Nat Rev Cancer*. 2007;7:327-331.
90. Stommel JM, Kimmelman AC, Ying H, Nabioullin R, Ponugoti AH, Wiedemeyer R et al. Coactivation of receptor tyrosine kinases affects the response of tumor cells to targeted therapies. *Science*. 2007;318:287-290.
91. Singh RK, Gutman M, Bucana CD, Sanchez R, Llansa N, Fidler IJ. Interferons alpha and beta down-regulate the expression of basic fibroblast growth factor in human carcinomas. *Proc Natl Acad Sci U S A*. 1995;92:4562-4566.
92. Beatty G, Paterson Y. IFN-gamma-dependent inhibition of tumor angiogenesis by tumor-infiltrating CD4+ T cells requires tumor responsiveness to IFN-gamma. *J Immunol*. 2001;166:2276-2282.
93. Samuel DP, Wen PY, Kieran MW. Antiangiogenic (metronomic) chemotherapy for brain tumors: Current and future perspectives. *Expert Opin Investig Drugs*. 2009;18:973-983.
94. Allen J, Packer R, Bleyer A, Zeltzer P, Prados M, Nirenberg A. Recombinant interferon beta: A phase I-II trial in children with recurrent brain tumors. *J Clin Oncol*. 1991;9:783-788.
95. Warren K, Bent R, Wolters PL, et al. A phase 2 study of pegylated interferon alpha-2b (PEG-intron((R))) in children with diffuse intrinsic pontine glioma. *Cancer*. 2012;118:3607-3613.
96. Wolff JE, Wagner S, Reinert C, et al. Maintenance treatment with interferon-gamma and low-dose cyclophosphamide for pediatric high-grade glioma. *J Neurooncol*. 2006;79:315-321.
97. Packer RJ, Prados M, Phillips P, et al. Treatment of children with newly diagnosed brain stem gliomas with intravenous recombinant beta-interferon and hyperfractionated radiation therapy: A childrens cancer group phase I/II study. *Cancer*. 1996;77:2150-2156.
98. Wakabayashi T, Yoshida J, Mizuno M, Kito A, Sugita K. Effectiveness of interferon-beta, ACNU, and radiation therapy in pediatric patients with brainstem glioma. *Neurol Med Chir (Tokyo)*. 1992;32:942-946.
99. Ohno M, Natsume A, Fujii M, Ito M, Wakabayashi T. Interferon-beta, MCNU, and conventional radiotherapy for pediatric patients with brainstem glioma. *Pediatr Blood Cancer*. 2009;53:37-41.
100. Kieran MW, Turner CD, Rubin JB, et al. A feasibility trial of antiangiogenic (metronomic) chemotherapy in pediatric patients with recurrent or progressive cancer. *J Pediatr Hematol Oncol*. 2005;27:573-581.
101. Sterba J, Pavelka Z, Andre N, et al. Second complete remission of relapsed medulloblastoma induced by metronomic chemotherapy. *Pediatr Blood Cancer*. 2010;54:616-617.
102. Padovani L, Andre N, Gentet JC, et al. Reirradiation and concomitant metronomic temozolomide: An efficient combination for local control in medulloblastoma disease? *J Pediatr Hematol Oncol*. 2011;33:600-604.
103. Minturn JE, Janss AJ, Fisher PG, et al. A phase II study of metronomic oral topotecan for recurrent childhood brain tumors. *Pediatr Blood Cancer*. 2011;56:39-44.
104. Peyrl A, Chocholous M, Kieran MW, et al. Antiangiogenic metronomic therapy for children with recurrent embryonal brain tumors. *Pediatr Blood Cancer*. 2012;59:511-517.
105. Kim CY, Kim SK, Phi JH, et al. A prospective study of temozolomide plus thalidomide during and after radiation therapy for pediatric diffuse pontine gliomas: Preliminary results of the Korean Society for Pediatric Neuro-Oncology study. *J Neurooncol*. 2010;100:193-198.

106. Lopez-Aguilar E, Sepulveda-Vildosola AC, Betanzos-Cabrera Y, et al. Phase II study of metronomic chemotherapy with thalidomide, carboplatin-vincristine-fluvastatin in the treatment of brain stem tumors in children. *Arch Med Res.* 2008;39:655-662.
107. Turner CD, Chi S, Marcus KJ, et al. Phase II study of thalidomide and radiation in children with newly diagnosed brain stem gliomas and glioblastoma multiforme. *J Neurooncol.* 2007;82:95-101.
108. Warren KE, Goldman S, Pollack IF, et al. Phase I trial of lenalidomide in pediatric patients with recurrent, refractory, or progressive primary CNS tumors: Pediatric brain tumor consortium study PBTC-018. *J Clin Oncol.* 2011;29:324-329.
109. Hwang EI, Jakacki RI, Fisher MJ, et al. Long-term efficacy and toxicity of bevacizumab-based therapy in children with recurrent low-grade gliomas. *Pediatr Blood Cancer.* 2013;60:776-782.
110. Aguilera DG, Goldman S, Fangusaro J. Bevacizumab and irinotecan in the treatment of children with recurrent/refractory medulloblastoma. *Pediatr Blood Cancer.* 2011;56:491-494.
111. Gururangan S, Chi SN, Young Poussaint T, et al. Lack of efficacy of bevacizumab plus irinotecan in children with recurrent malignant glioma and diffuse brainstem glioma: A pediatric brain tumor consortium study. *J Clin Oncol.* 2010;28:3069-3075.
112. Narayana A, Kunnakatt S, Chacko-Mathew J, et al. Bevacizumab in recurrent high-grade pediatric gliomas. *Neuro Oncol.* 2010;12:985-990.
113. Parekh C, Jubran R, Erdreich-Epstein A, et al. Treatment of children with recurrent high grade gliomas with a bevacizumab containing regimen. *J Neurooncol.* 2011;103:673-680.
114. Gururangan S, Fangusaro J, Young Poussaint T, et al. Lack of efficacy of bevacizumab + irinotecan in cases of pediatric recurrent ependymoma—a pediatric brain tumor consortium study. *Neuro Oncol.* 2012;14:1404-1412.
115. Reismuller B, Azizi AA, Peyrl A, et al. Feasibility and tolerability of bevacizumab in children with primary CNS tumors. *Pediatr Blood Cancer.* 2010;54:681-686.
116. Kieran MW, Supko JG, Wallace D, et al. Phase I study of SU5416, a small molecule inhibitor of the vascular endothelial growth factor receptor (VEGFR) in refractory pediatric central nervous system tumors. *Pediatr Blood Cancer.* 2009;52:169-176.
117. Broniscer A, Baker JN, Tagen M, et al. Phase I study of vandetanib during and after radiotherapy in children with diffuse intrinsic pontine glioma. *J Clin Oncol.* 2010;28:4762-4768.
118. Bode U, Massimino M, Bach F, et al. Nimotuzumab treatment of malignant gliomas. *Expert Opin Biol Ther.* 2012;12:1649-1659.
119. Saurez G, Cabanas R, Zaldivar M, et al. Clinical experience with nimotuzumab in cuban pediatric patients with brain tumors, 2005 to 2007. *MEDICC Rev.* 2009;11:27-33.
120. Pollack IF, Stewart CF, Kocak M, et al. A phase II study of gefitinib and irradiation in children with newly diagnosed brainstem gliomas: A report from the pediatric brain tumor consortium. *Neuro Oncol.* 2011;13:290-297.
121. Jakacki RI, Hamilton M, Gilbertson RJ, et al. Pediatric phase I and pharmacokinetic study of erlotinib followed by the combination of erlotinib and temozolomide: A children's oncology group phase I consortium study. *J Clin Oncol.* 2008;26:4921-4927.
122. Broniscer A, Baker SJ, Stewart CF, et al. Phase I and pharmacokinetic studies of erlotinib administered concurrently with radiotherapy for children, adolescents, and young adults with high-grade glioma. *Clin Cancer Res.* 2009;15:701-707.
123. Georger B, Hargrave D, Thomas F, et al. Innovative therapies for children with cancer pediatric phase I study of erlotinib in brainstem glioma and relapsing/refractory brain tumors. *Neuro Oncol.* 2011;13:109-118.

124. White-Koning M, Civate E, Georger B, et al. Population analysis of erlotinib in adults and children reveals pharmacokinetic characteristics as the main factor explaining tolerance particularities in children. *Clin Cancer Res.* 2011;17:4862-4871.
125. Geyer JR, Stewart CF, Kocak M, et al. A phase I and biology study of gefitinib and radiation in children with newly diagnosed brain stem gliomas or supratentorial malignant gliomas. *Eur J Cancer.* 2010;46:3287-3293.
126. Peyrl A, Azizi A, Czech T, et al. Tumor stabilization under treatment with imatinib in progressive hypothalamic-chiasmatic glioma. *Pediatr Blood Cancer.* 2009;52:476-480.
127. Pollack IF, Jakacki RI, Blaney SM, et al. Phase I trial of imatinib in children with newly diagnosed brainstem and recurrent malignant gliomas: A pediatric brain tumor consortium report. *Neuro Oncol.* 2007;9:145-160.
128. Baruchel S, Sharp JR, Bartels U, et al. A canadian paediatric brain tumour consortium (CPBTC) phase II molecularly targeted study of imatinib in recurrent and refractory paediatric central nervous system tumours. *Eur J Cancer.* 2009;45:2352-2359.
129. MacDonald TJ, Stewart CF, Kocak M, et al. Phase I clinical trial of cilengitide in children with refractory brain tumors: Pediatric brain tumor consortium study PBTC-012. *J Clin Oncol.* 2008;26:919-924.
130. Sikkema AH, Diks SH, den Dunnen WF, et al. Kinome profiling in pediatric brain tumors as a new approach for target discovery. *Cancer Res.* 2009;69:5987-5995.
131. van den Bent MJ, Vogelbaum MA, Wen PY, Macdonald DR, Chang SM. End point assessment in gliomas: Novel treatments limit usefulness of classical macdonald's criteria. *J Clin Oncol.* 2009;27:2905-2908.
132. Brandes AA, Franceschi E, Gorlia T, et al. Appropriate end-points for right results in the age of antiangiogenic agents: Future options for phase II trials in patients with recurrent glioblastoma. *Eur J Cancer.* 2012;48:896-903.
133. Wen PY, Macdonald DR, Reardon DA, et al. Updated response assessment criteria for high-grade gliomas: Response assessment in neuro-oncology working group. *J Clin Oncol.* 2010;28:1963-1972.
134. Gallego Perez-Larraya J, Lahutte M, Petrirena G, et al. Response assessment in recurrent glioblastoma treated with irinotecan-bevacizumab: Comparative analysis of the macdonald, RECIST, RANO, and RECIST + F criteria. *Neuro Oncol.* 2012;14:667-673.
135. Watling CJ, Lee DH, Macdonald DR, Cairncross JG. Corticosteroid-induced magnetic resonance imaging changes in patients with recurrent malignant glioma. *J Clin Oncol.* 1994;12:1886-1889.
136. Henegar MM, Moran CJ, Silbergeld DL. Early postoperative magnetic resonance imaging following nonneoplastic cortical resection. *J Neurosurg.* 1996;84:174-179.
137. Kumar AJ, Leeds NE, Fuller GN, et al. Malignant gliomas: MR imaging spectrum of radiation therapy- and chemotherapy-induced necrosis of the brain after treatment. *Radiology.* 2000;217:377-384.
138. Ulmer S, Braga TA, Barker FG, 2nd, Lev MH, Gonzalez RG, Henson JW. Clinical and radiographic features of peritumoral infarction following resection of glioblastoma. *Neurology.* 2006;67:1668-1670.
139. Pichler J, Pachinger C, Pelz M, Kleiser R. MRI assessment of relapsed glioblastoma during treatment with bevacizumab: Volumetric measurement of enhanced and FLAIR lesions for evaluation of response and progression-A pilot study. *Eur J Radiol.* 2013;82:e240-e245.
140. Warren KE, Poussaint TY, Vezina G, et al. Challenges with defining response to antitumor agents in pediatric neuro-oncology: A report from the response assessment in pediatric neuro-oncology (RAPNO) working group. *Pediatr Blood Cancer.* 2013;60:1397-1401.
141. Wolff JE, Brown RE, Buryanek J, Pfister S, Vats TS, Rytting ME. Preliminary experience with personalized and targeted therapy for pediatric brain tumors. *Pediatr Blood Cancer.* 2012;59:27-33.

142. Lopez-Aguilar E, Sepulveda-Vildosola AC, Betanzos-Cabrera Y, et al. Phase II study of metronomic chemotherapy with thalidomide, carboplatin-vincristine-fluvastatin in the treatment of brain stem tumors in children. *Arch Med Res.* 2008;39:655-662.
143. Trippett TM, Herzog C, Whitlock JA, et al. Phase I and pharmacokinetic study of cetuximab and irinotecan in children with refractory solid tumors: A study of the pediatric oncology experimental therapeutic investigators' consortium. *J Clin Oncol.* 2009;27:5102-5108.
144. Pollack IF, Stewart CF, Kocak M, et al. A phase II study of gefitinib and irradiation in children with newly diagnosed brainstem gliomas: A report from the pediatric brain tumor consortium. *Neuro Oncol.* 2011;13:290-297.
145. Fouladi M, Stewart CF, Blaney SM, et al. Phase I trial of lapatinib in children with refractory CNS malignancies: A pediatric brain tumor consortium study. *J Clin Oncol.* 2010;28:4221-4227.
146. McLaughlin ME, Robson CD, Kieran MW, Jacks T, Pomeroy SL, Cameron S. Marked regression of metastatic pilocytic astrocytoma during treatment with imatinib mesylate (STI-571, gleevec): A case report and laboratory investigation. *J Pediatr Hematol Oncol.* 2003;25:644-648.



Chapter 3

The angiotensin 1/angiotensin 2 balance as a prognostic marker in primary glioblastoma multiforme

Mariska Sie^{1*}

Michiel Wagemakers^{2*}

Grietje Molema³

Jan Jakob A. Mooij²

Eveline S. J. M. de Bont¹

Wilfred F. A. den Dunnen⁴

*These authors contributed equally to this study

¹ Department of Pediatrics, Beatrix Children's Hospital, Pediatric Oncology/Hematology division

² Department of Neurosurgery

³ Department of Pathology and Medical Biology, Medical Biology division

⁴ Department of Pathology and Medical Biology, Pathology division

University Medical Center Groningen, University of Groningen, Groningen, the Netherlands

J Neurosurg 2009; 110: 147-155

Abstract

Object: In the present study, the authors analyzed the ANGPT1/ANGPT2 balance in the context of therapeutic outcome in 62 patients with primary glioblastomas multiforme (GBMs).

Methods: The tumor tissue used was obtained in adult patients who underwent neurosurgical debulking. Microvessel density was assessed by morphometric analysis. Double immunostaining for Ki 67/CD34 and cleaved caspase-3/CD34 was used to investigate the proliferation and apoptotic fraction of both endothelial and tumor cells. The expression of VEGFs (A-D) was evaluated on immunohistochemistry. To measure tumor vascular stabilization, the ANGPT1/ANGPT2 mRNA balance was determined using real-time reverse transcriptase polymerase chain reaction.

Results: Within the hypoxic perinecrotic tumor area, the apoptotic fraction of endothelial cells was positively correlated with VEGFA expression ($p < 0.001$). Higher levels of VEGFA correlated with greater proliferation of endothelial cells in the intermediate tumor area ($p = 0.031$). Vascular endothelial growth factor D was significantly more highly expressed within the perinecrotic tumor area compared with the intermediate tumor area ($p < 0.001$). Multivariate analysis showed a significant association between the ANGPT1/ANGPT2 balance and the survival time of patients with GBMs ($p = 0.035$).

Conclusions: The results of the present study suggest that the ANGPT1/ANGPT2 balance has prognostic value in patients with primary GBMs. The authors' findings support the need for further studies of the feasibility of antiangiogenic therapy in primary GBMs, with a special focus on the normalization of tumor vasculature.

Introduction

Glioblastoma multiforme is the most frequent and malignant brain tumor in adults, making up 12–15% of all intracranial neoplasms.¹⁻³ Despite combined modality treatment with neurosurgery, radiotherapy, and chemotherapy, the median patient survival is 14.6 months,⁴ underscoring the aggressive growth properties of GBM. Glioblastoma multiforme is characterized by endothelial cell proliferation and prominent vascularization^{2,5} resulting from a combination of vessel cooption and tumor angiogenesis.^{6,7}

Because angiogenesis is a key event in tumor growth and progression,^{6,7} understanding its molecular control has been the focus of many studies. Vascular endothelial growth factor (VEGF) and the angiopoietins (ANGPTs) are critically involved in angiogenesis.^{5,8-10} There are 7 members of the VEGF family, of which VEGFA, VEGFB, VEGFC, and VEGFD are of interest in the study of human tumors.¹⁰ Vascular endothelial growth factor A, induced by hypoxia, increases microvascular permeability, induces endothelial cell migration and division, promotes endothelial cell survival, prevents senescence, and induces angiogenesis.⁹ Little is known about the roles of VEGFB, VEGFC, and VEGFD in tumor angiogenesis. Vascular endothelial growth factor B promotes *in vivo* angiogenesis.¹¹ Vascular endothelial growth factor C and D are essential to the development of the lymphatic system and can also induce angiogenesis and increase vascular permeability.¹²

Angiopoietin 1 helps to maintain and stabilize mature vessels by acting as a maturation factor that promotes the recruitment of pericytes and smooth muscle cells to the developing vessel.¹³ The functions of ANGPT1 and VEGF may be complementary, with VEGF providing most mitogenic activity and ANGPT1 responsible for ensuring vascular stability.¹⁴ Angiopoietin 2 is the more dynamic protein of these, is expressed at sites of vascular remodeling, and acts as a competitive antagonist of ANGPT1. In the absence of VEGF, ANGPT2 destabilizes vessels via TEK dephosphorylation, ultimately leading to vessel regression. In the presence of VEGF, however, ANGPT2 facilitates angiogenesis.^{15,16} The authors of some studies have demonstrated that VEGF and angiopoietins are both markedly upregulated in the vast majority of human tumors, including gliomas.^{5,17} A shift in the balance between ANGPT1 and ANGPT2 in favor of ANGPT2 appears to correlate with tumor angiogenesis.⁵

In various tumors the production of proangiogenic factors, such as ANGPT2, leads to abnormal vessel structure and signs of vascular immaturity (such as that reflected by a reduction of pericyte coverage).^{15,18} By correcting the balance in these angiogenic factors, the immature vasculature in tumors can be normalized, leading to increased tumor perfusion, increased partial oxygen pressure, and a reduction in the interstitial pressure in the tumor. As a consequence, the efficacy of radiotherapy and chemotherapy may be increased.^{15,18}

Although authors of previous studies have explored the expression of VEGF, ANGPT1, and ANGPT2 in primary GBMs as separate features, in the present study we aimed to directly quantify the ANGPT1/ANGPT2 balance within these tumors. We analyzed MVD, proliferation and apoptotic fraction of endothelial and tumor cells, VEGF expression, and angiopoietin balance in the context of therapeutic outcome in patients with primary GBMs.

Methods

Patient population and baseline characteristics

From January 1998 to January 2003, 132 patients received a diagnosis of primary GBM (WHO grade IV astrocytoma) at our institution. Patients who underwent neurosurgical debulking were eligible for this study. Exclusion criteria included stereotactic biopsy (in 57 patients), secondary GBM (in 10), and mixed tumors containing zones with sarcomatous or oligodendroglial differentiation (in 3 patients). Finally, tumor tissues from 62 patients were included in this study.

The baseline patient characteristics included age at diagnosis, sex, preoperative tumor volume, period between start of symptoms and surgical debulking, degree of debulking as indicated by the surgical report, postoperative radiotherapy (up to a total of 60 Gy), and survival time. Age at diagnosis was defined as the patient's age on the date that the imaging study (MR imaging or CT) used to diagnose the tumor was obtained. Preoperative tumor volume was calculated as described by Kuijlen et al.¹⁹ The period between the start of symptoms and operation was defined as the time between the first manifestation of clinical symptoms, as registered by the referring neurologist, and the day of surgical debulking. The survival time was calculated as the period from the date of surgery until death.

Immunohistochemical staining

Deparaffinized GBM tissue was used to evaluate the proliferation and apoptotic fraction of both endothelial and tumor cells (4- μ m-thick tissue slices), and the expression of VEGFA, -B, -C, and -D (5- μ m-thick slices). This evaluation was performed based on double staining for Ki 67/CD34 and cleaved caspase-3/CD34, and single staining for VEGFA, -B, -C, and -D. For Ki 67/CD34 and cleaved caspase-3/CD34 staining, antigen retrieval was performed using 10 mM Tris/1 mM EDTA (pH 9) and 1 mM EDTA (pH 9), respectively, in a microwave at 700 W. Antigen retrieval for VEGFA staining was performed with 0.1 mM Tris/HCl (pH 9). For VEGFB, VEGFC, and VEGFD staining, 0.1 mM Tris/0.1 mM EDTA (pH 9) and subsequent microwave treatment at 400 W was used. Endogenous peroxidase and biotin were blocked using routine techniques.

The slides for Ki 67/CD34 staining were incubated with the first primary antibody, Ki 67 (Clone MIB-1; Dako) at room temperature for 1 hour, followed by application of the secondary antibody peroxidase-conjugated rabbit anti-mouse serum (Dako), and the tertiary antibody peroxidase-conjugated goat anti-rabbit serum (Dako), for 30 minutes each. For cleaved caspase-3/CD34 staining, sections were incubated with the primary antibody for cleaved caspase-3 (Asp175; Cell Signaling Technology) at room temperature for 1 hour. This was also followed by application of the same secondary and tertiary antibodies as used for the Ki 67/CD34 assay for 30 minutes each. The first primary antibodies were diluted 1/100 in 1% BSA/PBS. The secondary and tertiary antibodies were diluted 1/100 in 1% BSA/PBS with 1% AB serum. Color development was performed with 3,3'-diaminobenzidine (Sigma) for 10 minutes.

For Ki 67/CD34 staining, a blocking step with 0.1 M glycine/HCl (pH 2) was performed next for 45 minutes. Thereafter, the slides for both Ki 67/CD34 and cleaved caspase-3/CD34 were incubated with the second primary antibody CD34 (prediluted Clone Qbend10; Immunotech) at room temperature for 1 hour, followed by the application of secondary antibody alkaline phosphatase-conjugated goat anti-mouse (1/50 in 1% BSA/PBS with 1% AB serum; Dako) for 30 minutes, and subsequent staining with Fast Red (Sigma) for 20–30 minutes.

The slides for VEGF were incubated with the primary antibody VEGFA (sc-152), VEGFB (sc-13083), VEGFC (sc-9047) and VEGFD (sc-13085; Santa Cruz Biotechnology) for 60 minutes. Primary antibodies were diluted 1/50 in 1% BSA/PBS. Biotinylated peroxidase-conjugated goat anti-rabbit serum (1/300 in 1% BSA/PBS with 1% AB serum; Dako) was applied as the secondary antibody for 30 minutes, followed by the tertiary antibody peroxidaseconjugated StrepABComplex (Ko377, 1/100 in 1% BSA/PBS with 1% AB serum; Dako) for 30 minutes. The slides were subsequently stained with 3'3-diaminobenzidine (Sigma) for 10 minutes, followed by nuclear counterstaining with hematoxylin.

Histological evaluation

The slides were scanned for hot spots of blood vessels in both the perinecrotic and intermediate tumor area. The perinecrotic tumor area is a relatively hypoxic area directly adjacent to necrosis, showing increased expression of HIF-1 α .²⁰ The intermediate tumor area lies between the perinecrotic area and the tumor periphery, which contains the invasion front into the normal brain tissue. The intermediate tumor area showed no HIF-1 α expression and less VEGFA expression compared with the perinecrotic tumor area.

The MVD for both the perinecrotic and intermediate tumor area was assessed using the Chalkley point overlap morphometric technique.²¹ This method entails the use of an ocular grid with 25 random points. After the tumor was scanned to identify 10 hot spots per slide (5 in the perinecrotic and 5 in the intermediate area), the ocular grid was turned to maximize the overlap between points on the grid and the CD34-stained vessels. The number of overlapping points was counted for every hot spot. The MVD was obtained by calculating the mean of 5 hot spots per tumor area.

To determine the proliferation fraction of the endothelial and tumor cells in both the perinecrotic and intermediate tumor area, 5 hpfs in Ki 67/CD34-doublestained slides were evaluated at an objective magnification of 40. A minimum of 100 CD34+ endothelial cells were counted per slide, and the fraction of cells that stained for both CD34 and Ki 67 was recorded as the proliferation fraction of endothelial cells. Similarly, a minimum of 800 tumor cells was counted and the fraction of Ki 67+ tumor cells was determined. The same procedure was used with the cleaved caspase-3/CD34 slides to assess the apoptotic fraction of both endothelial and tumor cells.

Expression of VEGFA, -B, -C, and -D in both the perinecrotic and intermediate tumor areas was evaluated using a semiquantitative staining intensity score: no staining was scored as 0, low staining as 1, moderate as 2, and high intensity staining as 3. Normal brain parenchyma was used as a control for the staining procedure. All slides were evaluated by a neuropathologist who was blinded to patient data.

Real-time reverse transcriptase PCR and RNA isolation

Paraffin-embedded GBM tissue obtained in 62 patients was deparaffinized. Isolation of RNA was performed using the protocol described by Specht et al.,²² and RNA isolation was quantified using Nanodrop ND-1000 UV Spectrophotometer (NanoDrop Technologies). After this, the TURBO DNA-Free Kit (Ambion) was used to remove contaminating DNA from RNA preparations, and subsequently to remove the DNase and divalent cations from the sample; 1.5 μ l of 10 \times TURBO DNase Buffer and 1- μ l TURBO DNase (2 U/ μ l; Ambion) were added and the tube was incubated at 37°C for 30 minutes. Two microliters of DNase Inactivator Reagent (Ambion) was added next, and the tube was incubated at room temperature for 2 minutes with occasional mixing. The tube was centrifuged at 13,000 \times gravity at room temperature for 1 minute to make the DNase Inactivation Reagent into a pellet. After centrifuging, the supernatant containing the RNA was carefully transferred into a clean tube and the RNA content was again quantified using Nanodrop.

Synthesis of cDNA was performed as described previously.¹⁹ Real-time PCR was performed in triplicate with the TaqMan Universal PCR Master Mix (Applied Biosystems), using an ABI7900HT real-time sequence detection system in 384-well reaction plates. The following primers were used: ANGPT1 (Hs 00181613.m1), ANGPT2 (Hs 00169867.m1), and GAPDH (Hs 99999905.ml). The balance between ANGPT1 and ANGPT2 was calculated using the formula: $2^{\Delta Ct}$, in which ΔCt is the mean Ct value of ANGPT2 minus the mean Ct value of ANGPT1.

Statistical analysis

Statistical comparisons were made with the Student t-test if the data had a Gaussian distribution, and with the Mann-Whitney U-test if the data were not normally distributed. The nonparametric Spearman correlation test was used to compute correlations. The survival time was analyzed by the Kaplan-Meier method with use of log-rank statistics. Univariate and multivariate analyses were performed using the Cox proportional hazards model (SPSS 15.0 software). For all statistical analyses, a 2-tailed probability value < 0.05 was considered significant.

Results

Patient characteristics

All 62 patients had a Karnofsky Performance Scale scores ≥ 70 before debulking surgery. Radiotherapy was abrogated in 15 patients (24%) because of rapid postoperative deterioration (Karnofsky Performance Scale scores < 70); the remaining 47 patients (76%) received postoperative radiotherapy. No patient in this study received any form of chemotherapy because chemotherapy was not part of the standard treatment for GBMs in the Netherlands during the study period.

The mean patient age at diagnosis in the study group was 59 years (Table 1). Two-thirds (68%) of patients fell into the expected peak incidence age group of 45–70 years,² with a male preponderance of 69%. The median survival time was 253 days in the study group. As expected,¹ the median survival period in patients who did not receive postoperative radiotherapy was less than in those who did: 50 days versus 303 days.

No differences in the other patient characteristics were found between the groups with and without radiotherapy. Our study group was thus representative of the population of patients with primary GBMs.

Table 1. Summary of characteristics of 62 patients with GBMs*

Characteristic	Total (62 patients)	RT group (47 patients)	No RT group (15 patients)	P value
Mean age at diagnosis in yrs (95% CI)	59 (57–62)	59 (56–62)	60 (54–67)	ns
Male sex (%)	43 (69)	33 (70)	10 (67)	ns
Female sex (%)	19 (31)	14 (30)	5 (33)	ns
Median time to op in days (range)#	43 (7–211)	51 (7–211)	31 (14–122)	ns
Extent of resection, no. of patients (%)				
GTR	35 (57)	27 (57)	8 (53)	ns
Partial	17 (27)	13 (28)	4 (27)	ns
Not recorded	10 (16)	7 (15)	3 (20)	ns
Mean preop tumor vol in cm ³ (95% CI)	43 (37–49)	42 (36–48)	45 (29–61)	ns
Median survival in days (range)	253 (17–792)	303 (61–792)	50 (17–91)	< 0.001

* GTR: gross-total resection; NS: not significant; RT: radiotherapy.

Represents time period between symptom onset and surgery.

Distribution of MVD and proliferation/apoptotic fraction of endothelial and tumor cells

In all primary GBM tissue samples, vascular hot spots were found in both the perinecrotic and intermediate tumor areas (Figure 1). The intermediate tumor area showed a significantly higher MVD and proliferation fraction of tumor cells than the perinecrotic area (Table 2). The MVD of the intermediate tumor area did not correlate with the proliferation fraction of endothelial cells. Within the intermediate area, the proliferation fraction of tumor cells was negatively correlated with the MVD (Spearman $r = -0.325$, $p = 0.010$). The perinecrotic tumor area, a relatively hypoxic zone, showed a significantly higher apoptotic fraction of both endothelial and tumor cells. The morphometric data did not significantly correlate with the survival time of GBM patients.

Table 2. Morphometry within the perinecrotic and intermediate tumor area in 62 patients with primary GBMs*

Morphometry	Perinecrotic tumor area	Intermediate tumor area	P value
Mean MVD (95% CI)	4.6 (4.3–5.0)	5.4 (5.0–5.8)	0.007
Median PFEC (range)	6.8 (0.9–28.8)	9.5 (0.0–25.0)	ns
Median AFEC (range)	14.9 (0.2–67.6)	2.6 (0.0–12.5)	< 0.001
Median PFTC (range)	13.1 (3.3–48.8)	21.1 (3.9–72.6)	< 0.001
Median AFTC (range)	3.0 (0.2–30.6)	0.6 (0.0–7.8)	< 0.001

* AFEC: apoptotic fraction of endothelial cells; AFTC: apoptotic fraction of tumor cells; PFEC: proliferation fraction of endothelial cells; PFTC: proliferation fraction of tumor cells.

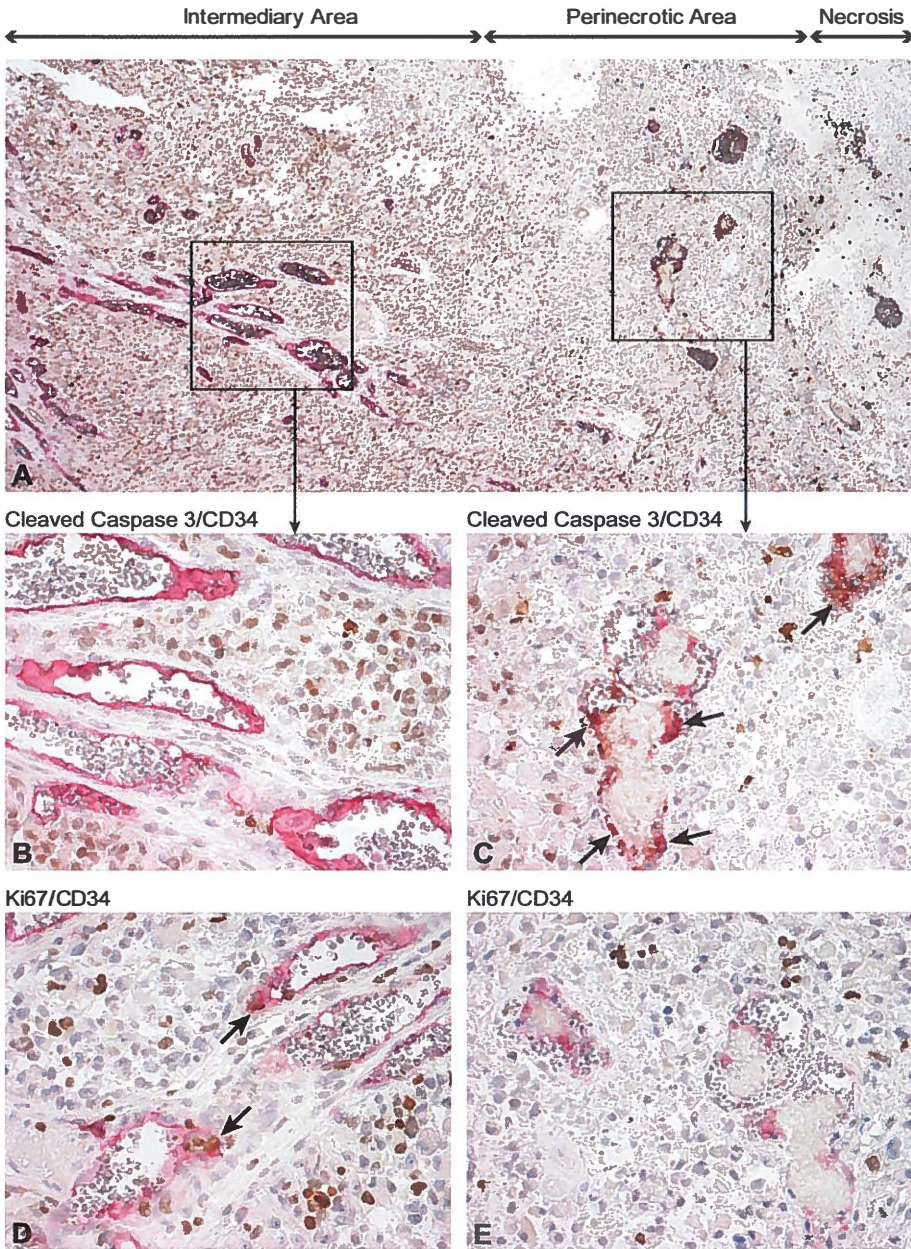


Figure 1. Photomicrographs of double-stained slides of a primary GBM. An overview of the different tumor areas with vascular hot spots in both the perinecrotic (right) and intermediary (left) tumor area is shown in A. Panels B and C respectively show details of vessels in the intermediary and perinecrotic tumor area, double-stained with cleaved caspase-3/CD34. Apoptotic endothelial cells are mostly observed in the perinecrotic tumor area (arrows in C). Panels D and E show details of vessels in the intermediary and perinecrotic tumor area, respectively, and are double-stained with Ki 67/CD34. Proliferating endothelial cells are mostly found in the intermediary tumor area (arrows in D). Original magnification $\times 100$ (A), and $\times 400$ (B-E).

Vascular endothelial growth factor expression

A significantly higher expression of VEGFA and VEGFD was found within the perinecrotic tumor area than in the intermediate tumor area (Figure 2). These data are consistent with the hypothesis that the production of VEGF is driven, at least in part, by hypoxia.^{6,7} Although this is known for VEGFA, it has not been described previously for VEGFD. For VEGFB and VEGFC no significant differences were found in expression between the perinecrotic and intermediate tumor areas.

Within the perinecrotic tumor area, a positive correlation was found between the apoptotic fraction of endothelial cells and the expression of VEGFA (Spearman $r = 0.485$, $p < 0.001$). In addition, a higher level of VEGFA expression was correlated with a higher proliferation fraction of endothelial cells within the intermediate tumor area (Spearman $r = 0.277$, $p = 0.031$). However, in the intermediate area, the expression of VEGFA was not significantly correlated with the MVD (Spearman $r = 0.251$, $p = 0.051$). Furthermore, no significant correlation was found between the expression of VEGF and the survival time of patients with GBMs.

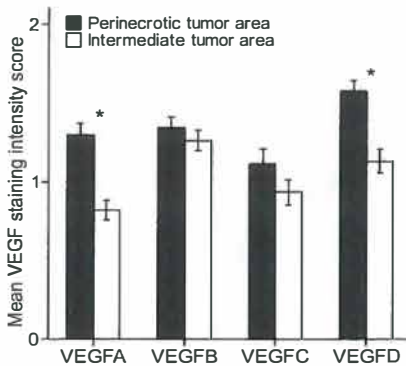


Figure 2. Bar graph showing the mean (\pm standard error) VEGFA, VEGFB, VEGFC, and VEGFD staining intensity score within the perinecrotic and intermediate tumor area in 61 patients with primary GBMs. The mean staining intensity score of VEGFA and VEGFD was 1.295 and 1.574 within the perinecrotic tumor area compared with 0.820 and 1.131 within the intermediate tumor area (* $p < 0.001$).

Angiopoietin 1/angiopoietin 2 balance

Expression of ANGPT1 and ANGPT2 could be determined in all primary GBM tissue samples, and the balance between them was calculated. The median ANGPT1/ANGPT2 balance was 0.268 (range 0.034–1.675) in the 62-patient study group and 0.289 (range 0.034–1.675) in the subgroup of 47 patients who underwent postoperative radiotherapy. The angiopoietin balance was positively correlated with the survival time of 62 patients with GBMs (Spearman $r = 0.322$, $p = 0.011$). Because patients who underwent radiotherapy had a significantly longer survival time than patients who did not, a subgroup analysis was indicated. The ANGPT1/ANGPT2 balance also significantly correlated with the survival time in patients who received radiotherapy (Figure 3).

Using the median ANGPT1/ANGPT2 balance of 0.289 as the cutoff in the radiotherapy subgroup, the median survival time in patients with an ANGPT1/ANGPT2 balance ≤ 0.289 was 253 days compared with 345 days in patients with an ANGPT1/ANGPT2 balance > 0.289 (Figure 4). Moreover, univariate analysis showed a significant association between the ANGPT1/ANGPT2 balance and the survival time in both the total study group and the subgroup that received postoperative radiotherapy (Table 3). Even corrected for known prognostic parameters in a multivariate analysis, the angiopoietin balance was still associated with the survival time of GBM patients.

Table 3. Univariate and multivariate analyses of data obtained in patients with primary GBMs*

Variable	Univariate analysis			Multivariate analysis		
	HR	95% CI	p value	HR	95% CI	P value
Entire study group (62 patients)						
Age at diagnosis	1.02	1.00–1.05	0.104	1.04	1.01–1.07	0.006
Sex	1.11	0.64–1.92	0.711	0.58	0.29–1.18	0.133
Preop tumor volume	1.01	0.99–1.02	0.298	1.01	0.99–1.02	0.519
Degree of debulking (GTR vs PR)	0.73	0.40–1.33	0.299	0.55	0.27–1.14	0.106
Radiotherapy	70.96	15.33–328.47	<0.001	73.32	13.85–388.13	<0.001
ANGPT1/ANGPT2 balance (≤0.268 vs >0.268)	1.86	1.11–3.10	0.018	1.99	1.05–3.76	0.035
RT group (47 patients)						
Age at diagnosis	1.03	1.00–1.06	0.080	1.06	1.02–1.10	0.002
Sex	1.12	0.59–2.12	0.732	0.57	0.25–1.29	0.177
Preop tumor volume	1.01	0.99–1.03	0.343	1.02	1.00–1.04	0.133
Degree of debulking (GTR vs PR)	0.66	0.33–1.33	0.245	0.53	0.24–1.17	0.116
ANGPT1/ANGPT2 balance (≤0.268 vs >0.268)	2.02	1.12–3.64	0.020	2.49	1.22–5.06	0.012

* HR: hazard ratio; RT: radiotherapy; GTR: gross-total resection; PR: partial resection

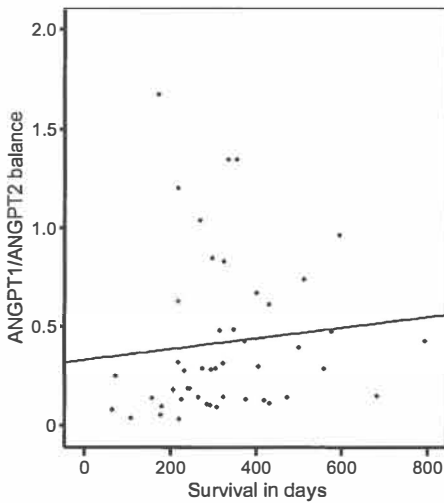


Figure 3. Scatterplot showing a positive correlation between the ANGPT1/ANGPT2 balance and the survival time in 47 patients with primary GBM and postoperative radiotherapy (Spearman $r = 0.317$, $p = 0.030$).

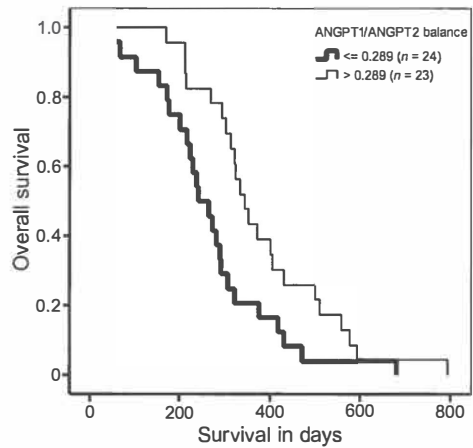


Figure 4. Kaplan-Meier curves of the overall survival of patients with primary GBM and postoperative radiotherapy (47 patients). Using the median ANGPT1/ANGPT2 balance of 0.289 as the cutoff, the median survival time in patients with an ANGPT1/ANGPT2 balance ≤ 0.289 was 253 days, and 345 days in patients with a higher ANGPT1/ANGPT2 balance ($p = 0.018$, log-rank test).

Discussion

We evaluated MVD, proliferation and apoptotic fraction of endothelial and tumor cells, VEGF expression, and ANGPT1/ANGPT2 balance in the context of therapeutic outcome in 62 patients with primary GBMs. Here, the ANGPT1/ANGPT2 balance was identified as a prognostic marker in patients with GBMs.

Of all the members of the VEGF protein family, VEGFA has been studied the most extensively. Our findings of increased staining of VEGFA within the perinecrotic area are consistent with the literature. This distribution within the tumor is explained by considering hypoxia as the primary trigger for the production of VEGFA. In the study by Holash et al.,²³ who investigated early vascularization of gliomas in a rat C6 model, hypoxia was the most specific signal that induced transcription of the VEGFA gene and stabilization of its mRNA. Although VEGFB, -C, and -D have been reported to be expressed in gliomas,²⁴⁻²⁷ a distribution similar to VEGFA was not seen. Currie et al.²⁸ found an association between VEGFD, HIF-1 α , and the HIF target gene DEC1 in primary human breast carcinomas. Although these findings support a role for hypoxia-induced VEGFD production, expression of VEGFD was not seen adjacent to areas of necrosis. In the present study, we show for the first time an increased staining intensity of VEGFD in the perinecrotic area.

Microvessel density is frequently used as a measure of angiogenic activity, so our finding that MVD does not correlate with either endothelial cell proliferation or VEGFA staining intensity seems counterintuitive. However, it has been proposed that MVD may depend more on the metabolic and mitotic activity of the tumor cells.²⁹ This concept is nicely illustrated by the negative correlation of MVD with tumor cell proliferation in the intermediate area, in absence of a correlation with endothelial cell proliferation and VEGF staining intensity. Few studies have analyzed the proliferation fraction of endothelial cells as a measure of angiogenic activity. Unlike MVD, however, the proliferation fraction of endothelial cells did correlate with VEGFA staining in the intermediate area. Analysis of the proliferation fraction of endothelial cells may very well be superior to MVD as a measure of angiogenic activity in tumors.^{29,30}

The angiopoietins are thought to actively control the initiation of tumor angiogenesis.³¹ Angiopoietin 1 and 2 ligate TEK, an endothelial cell transmembrane receptor; TEK is phosphorylated by ligation with ANGPT1, whereas ANGPT2 acts as a competitive antagonist. The exact roles of both angiopoietins are uncertain, and contradictory reports on pro- and antiangiogenic activity of both proteins can be found in the literature.³² Overall, it is clear that the presence of ANGPT1 leads to increased integration of the endothelial cells into their surroundings (adequate pericyte coverage), which is important for endothelial cell survival. Angiopoietin 2, however, destabilizes the vasculature and prepares the tumor endothelial cells to become responsive to proangiogenic factors such as VEGF. Consequently, in the presence of VEGF, sprouting angiogenesis can occur.

In line with this concept, overexpression of ANGPT2 in experimental tumors was found to lead to larger and heavier lesions.^{33,34} In preclinical models in astrocytomas, ANGPT2 has been identified as an early marker of tumor angiogenesis,^{35,36} and overexpression of ANGPT2 in intracranial tumors leads to enhanced infiltrative growth and increased angiogenesis in the areas of invasion.³⁷

The angiopoietin/TEK system has been studied previously in human astrocytomas.^{35, 36, 38, 39} Angiopoietin 1 mRNA is present in GBM tumor cells. Although the extent of expression varies locally, it can be seen throughout the tumor.^{35, 36, 39} Most studies have shown ANGPT2 expression to be restricted to the tumor endothelial cells. Angiopoietin 2 expression appears to be induced by the presence of tumor cells. This is illustrated by ANGPT2 expression by endothelial cells surrounded by infiltrating tumor cells at the invasive edge of the tumor. The role of ANGPT2 as an early marker of tumor angiogenesis as described in preclinical studies in a glioma model has been confirmed in human glioma samples.³⁶

Because ANGPT1 and ANGPT2 ligate the same receptor in competitive antagonism, the angiopoietin/TEK system is considered to function as a balance. Although the 2 angiopoietins are largely produced by different cells, the calculation of a direct ratio of the mRNA levels of both may reflect the general angiogenic activity of the tumor. We found that this ANGPT1/ANGPT2 balance was positively correlated with survival. Although this does not constitute a direct relationship between angiopoietin balance and survival, it does add to the evidence in support of the importance of the angiopoietin/TEK system in glioma growth and angiogenesis.

The concept of vessel normalization was introduced relatively recently into the field of angiogenesis.⁴⁰ Since the rise of angiogenesis research a few decades ago, attempts to use antiangiogenesis in the treatment of cancer have mainly focused on targeting the tumor vasculature for destruction and thereby starving the tumor or halting its growth. Vessel normalization, however, aims at reversing the changes that have occurred in the tumor vasculature during the process of vessel cooption or new vessel formation, thereby increasing the tumor's vulnerability to conventional therapies, such as radiation. The angiopoietins are strongly associated with the occurrence of these morphological and functional changes in the tumor vasculature and are thought to actively control the initiation of tumor angiogenesis.³¹ Therefore, our finding of a prognostic significance of the angiopoietin balance in a group of patients who underwent radiation therapy supports further attempts to study the feasibility of vessel normalization as part of the treatment of patients with GBMs.

Conclusions

To our knowledge, this is the first study that examines the ANGPT1/ANGPT2 balance instead of studying ANGPT1 and ANGPT2 as separate features in human brain tumors. In our multivariate analysis, we found a significant association between the ANGPT1/ANGPT2 balance and survival in primary GBM patients. Our findings support the initiation of further studies into the feasibility of antiangiogenic therapy in primary GBMs, especially when focused on the normalization of tumor vasculature.

Acknowledgements

The authors thank Dr. H. M. Boezen from the department of Epidemiology, University Medical Center Groningen, for her statistical advice.

This work was supported by a grant from Jan Kornelis de Cock Stichting (project code 514273).

References

1. DeAngelis LM. Brain tumors. *N Engl J Med.* 2001;344:114-123.
2. Louis DN, Ohgaki H, Wiestler OD, et al. The 2007 WHO classification of tumours of the central nervous system. *Acta Neuropathol.* 2007;114:97-109.
3. Ohgaki H and Kleihues P. Epidemiology and etiology of gliomas. *Acta Neuropathol.* 2005;109:93-108.
4. Stupp R, Mason WP, van den Bent MJ, et al. Radiotherapy plus concomitant and adjuvant temozolomide for glioblastoma. *N Engl J Med.* 2005;352:987-996.
5. Tait CR and Jones PF. Angiopoietins in tumours: the angiogenic switch. *J Pathol.* 2004;204:1-10.
6. Folkman J. How is blood vessel growth regulated in normal and neoplastic tissue? G.H.A. Clowes memorial Award lecture. *Cancer Res.* 1986;46:467-473.
7. Folkman J. What is the evidence that tumors are angiogenesis dependent? *J Natl Cancer Inst.* 1990;82:4-6.
8. Carmeliet P. VEGF as a key mediator of angiogenesis in cancer. *Oncology.* 2005;69 Suppl 3:4-10.
9. Dvorak HF. Vascular permeability factor/vascular endothelial growth factor: a critical cytokine in tumor angiogenesis and a potential target for diagnosis and therapy. *J Clin Oncol.* 2002;20:4368-4380.
10. Hoeben A, Landuyt B, Highley MS, Wildiers H, Van Oosterom AT, De Bruijn EA. Vascular endothelial growth factor and angiogenesis. *Pharmacol Rev.* 2004;56:549-580.
11. Silvestre JS, Tamarat R, Ebrahimi TG, et al. Vascular endothelial growth factor-B promotes in vivo angiogenesis. *Circ Res.* 2003;93:114-123.
12. Dvorak HF. Angiogenesis: update 2005. *J Thromb Haemost.* 2005;3:1835-1842.
13. Suri C, Jones PF, Patan S, et al. Requisite role of angiopoietin-1, a ligand for the TIE2 receptor, during embryonic angiogenesis. *Cell.* 1996;87:1171-1180.
14. Kaur B, Tan C, Brat DJ, Post DE, Van Meir EG. Genetic and hypoxic regulation of angiogenesis in gliomas. *J Neurooncol.* 2004;70:229-243.
15. Jain RK. Molecular regulation of vessel maturation. *Nat Med.* 2003;9:685-693.
16. Maisonpierre PC, Suri C, Jones PF, et al. Angiopoietin-2, a natural antagonist for Tie2 that disrupts in vivo angiogenesis. *Science.* 1997;277:55-60.
17. Ferrara N and Davis-Smyth T. The biology of vascular endothelial growth factor. *Endocr Rev.* 1997;18:4-25.
18. Jain RK, di Tomaso E, Duda DG, Loeffler JS, Sorensen AG, Batchelor TT. Angiogenesis in brain tumours. *Nat Rev Neurosci.* 2007;8:610-622.
19. Kuijlen JM, Mooij JJ, Platteel I, et al. TRAIL-receptor expression is an independent prognostic factor for survival in patients with a primary glioblastoma multiforme. *J Neurooncol.* 2006;78:161-171.
20. Zhong H, De Marzo AM, Laughner E, et al. Overexpression of hypoxia-inducible factor 1 α in common human cancers and their metastases. *Cancer Res.* 1999;59:5830-5835.
21. Vermeulen PB, Gasparini G, Fox SB, et al. Second international consensus on the methodology and criteria of evaluation of angiogenesis quantification in solid human tumours. *Eur J Cancer.* 2002;38:1564-1579.
22. Specht K, Richter T, Muller U, Walch A, Werner M, Hofler H. Quantitative gene expression analysis in microdissected archival formalin-fixed and paraffin-embedded tumor tissue. *Am J Pathol.* 2001;158:419-429.
23. Holash J, Wiegand SJ, Yancopoulos GD. New model of tumor angiogenesis: dynamic balance between vessel regression and growth mediated by angiopoietins and VEGF. *Oncogene.* 1999;18:5356-5362.

24. Debinski W, Slagle-Webb B, Achen MG, et al. VEGF-D is an X-linked/AP-1 regulated putative oncogene in human glioblastoma multiforme. *Mol Med.* 2001;7:598-608.
25. Gollmer JC, Ladoux A, Gioanni J, et al. Expression of vascular endothelial growth factor-b in human astrocytoma. *Neuro Oncol.* 2000;2:80-86.
26. Grau SJ, Trillsch F, Herms J, et al. Expression of VEGFR3 in glioma endothelium correlates with tumor grade. *J Neurooncol.* 2007;82:141-150.
27. Jenny B, Harrison JA, Baetens D, et al. Expression and localization of VEGF-C and VEGFR-3 in glioblastomas and haemangioblastomas. *J Pathol.* 2006;209:34-43.
28. Currie MJ, Hanrahan V, Gunningham SP, et al. Expression of vascular endothelial growth factor D is associated with hypoxia inducible factor (HIF-1alpha) and the HIF-1alpha target gene DEC1, but not lymph node metastasis in primary human breast carcinomas. *J Clin Pathol.* 2004;57:829-834.
29. Hlatky L, Hahnfeldt P, Folkman J. Clinical application of antiangiogenic therapy: microvessel density, what it does and doesn't tell us. *J Natl Cancer Inst.* 2002;94:883-893.
30. Eberhard A, Kahlert S, Goede V, Hemmerlein B, Plate KH, Augustin HG. Heterogeneity of angiogenesis and blood vessel maturation in human tumors: implications for antiangiogenic tumor therapies. *Cancer Res.* 2000;60:1388-1393.
31. Bach F, Uddin FJ, Burke D. Angiopoietins in malignancy. *Eur J Surg Oncol.* 2007;33:7-15.
32. Eklund L and Olsen BR. Tie receptors and their angiopoietin ligands are context-dependent regulators of vascular remodeling. *Exp Cell Res.* 2006;312:630-641.
33. Ahmad SA, Liu W, Jung YD, et al. The effects of angiopoietin-1 and -2 on tumor growth and angiogenesis in human colon cancer. *Cancer Res.* 2001;61:1255-1259.
34. Etoh T, Inoue H, Tanaka S, Barnard GF, Kitano S, Mori M. Angiopoietin-2 is related to tumor angiogenesis in gastric carcinoma: possible in vivo regulation via induction of proteases. *Cancer Res.* 2001;61:2145-2153.
35. Holash J, Maisonpierre PC, Compton D, et al. Vessel cooption, regression, and growth in tumors mediated by angiopoietins and VEGF. *Science.* 1999;284:1994-1998.
36. Zagzag D, Hooper A, Friedlander DR, et al. In situ expression of angiopoietins in astrocytomas identifies angiopoietin-2 as an early marker of tumor angiogenesis. *Exp Neurol.* 1999;159:391-400.
37. Hu B, Guo P, Fang Q, et al. Angiopoietin-2 induces human glioma invasion through the activation of matrix metalloproteinase-2. *Proc Natl Acad Sci U S A.* 2003;100:8904-8909.
38. Koga K, Todaka T, Morioka M, et al. Expression of angiopoietin-2 in human glioma cells and its role for angiogenesis. *Cancer Res.* 2001;61:6248-6254.
39. Stratmann A, Risau W, Plate KH. Cell type-specific expression of angiopoietin-1 and angiopoietin-2 suggests a role in glioblastoma angiogenesis. *Am J Pathol.* 1998;153:1459-1466.
40. Jain RK. Normalization of tumor vasculature: an emerging concept in antiangiogenic therapy. *Science.* 2005;307:58-62.



Chapter 4

Tumor vessel biology in pediatric intracranial ependymoma

Michiel Wagemakers¹

Mariska Sie³

Eelco W. Hoving¹

Grietje Molema²

Eveline S. J. M. de Bont³

Wilfred F. A. den Dunnen⁴

¹ Department of Neurosurgery

² Department of Pathology and Medical Biology, Medical Biology division

³ Department of Pediatrics, Beatrix Children's Hospital, Pediatric Oncology/Hematology division

⁴ Department of Pathology and Medical Biology, Pathology division
University Medical Center Groningen, University of Groningen, Groningen, the Netherlands

J Neurosurg Pediatrics 2010; 5: 335-341

Abstract

Object: This study aimed to characterize the pediatric intracranial ependymoma vasculature in terms of angiogenic activity and maturation status so as to provide indications for the applicability of vessel-targeted therapy in cases of pediatric intracranial ependymoma.

Methods: Tumor samples obtained in patients with ependymomas were immunohistochemically (double) stained for Ki 67/CD34, caspase 3a/CD34, vascular endothelial growth factor (VEGF)-A, -B, -C, -D, collagen Type IV, and smooth muscle actin to determine microvessel density, tumor and endothelial cell proliferation and apoptotic fraction, the relative expression of VEGF family members, and the coverage of the tumor endothelial cells by basal membrane and pericytes. Messenger RNA expression of angiopoietin-1 and -2 was analyzed by real-time reverse transcriptase polymerase chain reaction. These data were compared with those obtained in a glioblastoma series.

Results: Despite a low endothelial cell turnover, the microvessel density of ependymomas was similar to that of glioblastomas. In ependymomas the expression of VEGF-A was within the range of the variable expression in glioblastomas. The staining intensities of VEGF-B, -C, and -D in ependymomas were significantly lower ($p < 0.001$). The expression of angiopoietin-1 was higher in ependymomas than in glioblastomas ($p = 0.03$), whereas angiopoietin-2 expression was similar. The coverage of tumor endothelial cells with basal membrane and pericytes was more complete in ependymomas ($p = 0.009$ and $p = 0.022$, respectively).

Conclusions: The ependymoma vasculature is relatively mature and has little angiogenic activity compared with malignant gliomas. Therefore, the window for vessel normalization as a therapeutic aim might be considered small. However, the status of the tumor vasculature may not be a reliable predictor of treatment effect. Therefore, possible benefits of antiangiogenic treatment cannot be excluded beforehand in patients with ependymomas.

Introduction

Angiogenesis has been increasingly recognized as an important process in the outgrowth of solid tumors. Parameters related to tumor angiogenesis such as MVD and VEGF expression have been shown to be predictive of the prognosis in a host of tumors¹⁻⁴ and correlate with histological tumor grade in gliomas.^{5,6} Moreover, clinical trials of therapies aimed at the neovasculature have produced promising results.⁷ Glioblastomas have received special attention within the field of angiogenesis research because of their robust vasculature.^{8,9} The different aspects of the angiogenic process—that is, the initiation of angiogenesis, endothelial cell proliferation, and migration, extracellular matrix breakdown, and tube formation—have been extensively studied in glioblastomas. The angiogenic potential of glioblastomas has initiated investigations of vessel-targeted therapy and has motivated study groups worldwide to start trials on the feasibility of using antiangiogenic drugs in the treatment of glioblastomas.

Less is known about the neovasculature of other brain tumors. In pediatric ependymomas, in which the neovasculature is less prominent, only a handful of studies have analyzed aspects of the angiogenic process.¹⁰⁻¹⁴ The prognosis of pediatric ependymomas is limited. Despite developments of new surgical techniques, the introduction of conformal radiotherapy, and new chemotherapeutic strategies (for example, neoadjuvant chemotherapy), 5-year survival is approximately 57%.¹⁵ Because late recurrences are no exception, 10-year survival is even worse. Therefore, new therapeutic strategies are needed.

In the present study we aimed to characterize the neovasculature in a series of pediatric intracranial ependymomas. We quantified MVD, VEGF expression, and tumor and endothelial cell proliferation and apoptosis. Furthermore, the balance between the expression of Ang-1 and Ang-2 was analyzed, as this may be indicative of the angiogenic potential of tumors. These data were interpreted in the context of what is known about the neovasculature of glioblastomas that has been reported.¹⁶ As such, this study may provide a basis for further research into the possibilities of adding drugs with antiangiogenic activity to the treatment schedules of pediatric ependymoma.

Methods

Clinical data

Patients operated on between 1988 and 2004 were selected from the medical database of the University Medical Center Groningen and the national pathological database PALGA. Patients were included if 1) they were diagnosed with an intracranial ependymoma, 2) they were under 20 years of age, 3) there was access to clinical follow-up information, and 4) pre- and postoperative MR images were available. Cases involving spinal ependymomas were excluded. Tumor slides were reviewed to confirm the diagnosis, and, when available, tumor tissue samples were used for immunohistochemical analysis and real-time RT-PCR analysis. Table 1 summarizes the characteristics, treatment, and follow-up of the selected patients.

Data and analysis on glioblastoma vasculature were drawn from tissue samples of patients who underwent debulking surgery between 1998 and 2003 for a primary glioblastoma in the University Medical Center Groningen. These data have been previously reported.¹⁶

Table 1. Patients characteristics, treatment, and follow-up*

Parameters§	Total group	Yrs of age		Location	
		<3	>3	Infratentorial	Supratentorial
Patient					
No.	27	10	17	21	6
Age	4.2 (1.2–15.6)	2.0 (1.2–2.7)	6.4 (3.1–15.6)	3.7 (1.2–15.6)	4.6 (2.6–6.4)
Sex (M/F)	14/13	5/5	9/8	11/10	3/3
WHO Grade II/III	23/4	9/1	14/3	17/4	6/0
Treatment					
Biopsy	1	1	0	1	0
Resection	26	9	17	20	6
Partial	12	3	9	9	3
Gross-total	14	6	8	11	3
Radiotherapy	18	2†	16	13	5
Chemotherapy	6	4	2	4	2
Follow-up					
Follow-up (yrs)	9.5 (2.6–18.9)	8.8 (2.9–17.8)	9.5 (2.6–18.9)	7.8 (2.8–17.8)	12.6 (2.6–18.9)
Recurrence#	18 (27)	8 (10)	10 (17)	15 (21)	3 (6)
Time to recurrence (yrs)	1.3 (0–4.5)	1.3 (0–3.1)	1.2 (0–4.5)	1.3 (0–4.5)	1.1 (0–2.7)
5-yr PFS (%)	27.3	11.1	38.5	17.6	60
5-yr OS (%)	54.5	55.6	53.8	52.9	60
10-yr OS#	5 (13)	1 (5)	4 (8)	3 (9)	2 (4)

* OS: overall survival; PFS: progression-free survival.

§ All parameters are presented as median (range) unless stated otherwise.

† Patients received radiotherapy after reaching the age of 3 years.

Recurrences and 10-yr OS are presented in absolute numbers (total).

Immunohistochemistry

Tumor cell and endothelial cell proliferation and apoptosis, as well as the presence of VEGF protein, were evaluated by double-staining procedures for Ki 67/CD34 and caspase 3a/CD34, and by staining procedures for VEGF-A, -B, -C, and -D as described by Sie et al.¹⁶

The basal membrane and pericyte coverage of tumor vessels were evaluated by immunohistochemical staining for CD34, collagen Type IV, and SMA. Five-micrometer thick formalin-fixed, paraffin-embedded sections were cut and deparaffinized. For CD34 staining, antigen retrieval was performed with 0.1 M Tris/HCl (pH 9.5) in a microwave at 700 W. For collagen Type IV staining, antigen retrieval was performed using protein K 0.01% for 30 minutes. Endogenous peroxidase and biotin were blocked, and sections were incubated with the first primary antibody in PBS supplemented with 1% BSA for 1 hour at room temperature. This was followed by incubation with the secondary antibody in PBS supplemented with 1% BSA and 1% serum for 30 minutes. Endogenous peroxidase and biotin were blocked, and sections were incubated with the first primary antibody in PBS supplemented with 1% BSA for 1 hour at room temperature.

This was followed by incubation with the secondary antibody in PBS supplemented with 1% BSA and 1% serum for 30 minutes. Subsequently, sections were incubated with the third antibody for 30 minutes at room temperature in PBS supplemented with 1% BSA and 1% serum. Sections were then stained with 3,3'-diaminobenzidine (Sigma) for 10 minutes. Finally, nuclear counterstaining was performed with hematoxylin.

The primary antibodies used were SMA (m0851, DAKO), collagen Type IV (10760, Mp Biomedicals), and CD34 (Qbend10, Immunotech). The secondary antibody was rabbit anti-mouse (Rampo, DAKO, 1:100 dilution) for SMA, goat anti-rabbit (Garpo, DAKO, 1:100 dilution) for collagen Type IV, and alkaline phosphatase-conjugated goat anti-mouse (GAMAF, DAKO, 1:50 dilution) for CD34. The third antibody was goat anti-rabbit (Garpo, DAKO, 1:100 dilution) for SMA and rabbit anti-goat (Ragpo, DAKO, 1:100 dilution) for collagen Type IV and CD34.

Microvessel density, and tumor cell and endothelial cell proliferation and apoptosis

Microvessel density was quantified using the Chalkley point overlap morphometric technique.¹⁷ First, sections were scanned for vascular hot spots (magnification $\times 100$). The overlap of points on the Chalkley grid (Graticules, Ltd.) with endothelial cells or vessel lumen was counted in 5 hot spots per tissue section (magnification $\times 200$). The MVD was obtained by calculating the mean of these 5 hot spots.

The Ki 67/CD34 stained sections were evaluated for number and proliferation fraction of tumor cells and endothelial cells in 5 random high power fields (magnification $\times 400$). The same sequence was repeated with the caspase 3a/CD34 sections. From these the fractions of apoptotic tumor cells and apoptotic endothelial cells were calculated. In the glioblastoma data, which were used for comparison, a distinction was made between the perinecrotic areas and intermediate areas because of the heterogeneity within these tumors.⁵ The more homogeneous nature of the ependymomas precluded such a distinction. The data of both areas in glioblastomas were used to compare the tumor vessel characteristics of ependymomas and glioblastomas.

Evaluation of VEGF, collagen type IV, and SMA staining

Vascular endothelial growth factor staining and analysis were performed on the 14 tissue samples large enough to facilitate a representative assessment (roughly > 5 mm in diameter).

Vascular endothelial growth factor immunohistochemical staining was analyzed semiquantitatively. The intensity of the staining was scored using a subjective scoring system: 0 = no staining, 1 = slight staining, 2 = moderate staining, 3 = maximal staining.

The extent of coverage of the tumor vessels by a basal membrane and pericytes was analyzed by quantifying the vessels as recognized by immunohistochemical staining for either CD34, collagen IV, or SMA in 5 random areas per tumor. The number of vessels was recorded for every area (magnification $\times 200$). Vessel counts of collagen Type IV and SMA were subsequently divided by the CD34 vessel count to produce the percentage of tumor vessels that is covered by a basal membrane or pericytes, respectively. The analysis was performed on the samples of 16 ependymomas. For comparison, 10 glioblastomas were analyzed.

Isolation of RNA and real-time RT-PCR for Ang-1 and Ang-2

Paraffin-embedded tissue samples were deparaffinized. Isolation of RNA was performed using the RT-PCR protocol described by Specht et al.¹⁸ The RNA yield was quantified using Nanodrop (Nanodrop Technologies). To remove contaminating DNA from RNA preparations, the Ambion's TURBO DNA-free Kit was used according to the manufacturer's protocol and again RNA content was quantified using Nanodrop.

Synthesis of cDNA and real-time PCR was performed as previously described.²² The RT-PCR analysis of Ang-1 and Ang-2 was performed on tumors of which material of sufficient quality was available (8 samples). The RNA content per sample relative to glyceraldehyde 3-phosphate dehydrogenase was calculated using the formula $2^{-\Delta Ct}$, in which ΔCt is the Ct value of the RNA molecule under study minus the Ct value of glyceraldehyde 3-phosphate dehydrogenase. The balance between Ang-1 and Ang-2 per tumor (the angiopoietin balance) was calculated using the formula $2^{\Delta Ct}$, in which ΔCt is the Ct value of Ang-2 minus the Ct value of Ang-1. As such, a higher angiopoietin balance coincides with a higher relative expression of Ang-1.

Statistical analysis

Statistical analysis was performed using the Microsoft Excel XP and SPSS package 12.01. To evaluate differences between groups a Student t-test was used if data had a Gaussian distribution and a Mann-Whitney U-test for 2 independent variables was used if data were not normally distributed. Probability values < 0.05 were considered significant.

Results

Microvessel density

Mean MVD (\pm SD) of the ependymomas was 5.7 ± 1.7 (20 specimens), with a wide range of 3.3–7.9 (Table 2). Microvessel density did not significantly vary with age, sex, tumor grade, or tumor location. Although it is remarkable that all supratentorial tumors had an MVD exceeding 5, there was no significant difference between the infra- and supratentorial tumors.

The MVD of the pediatric ependymomas compared well with that of the intermediate area in the glioblastoma series and exceeded that of the relatively hypoxic, perinecrotic area of glioblastoma (Table 2).

Tumor and endothelial cell proliferation and apoptosis

There were no significant differences in tumor cell proliferation or apoptosis between the different tumor locations (infra- or supratentorial), age groups (under or over 3 years of age), or tumor WHO grades (II and III). The endothelial cell apoptotic and proliferating fractions did not differ among the age groups and WHO grades. The fraction of proliferating endothelial cells was significantly higher in infratentorial tumors than in supratentorial tumors ($p = 0.01$).

To put the turnover of tumor and endothelial cells in pediatric ependymoma in context, the proliferation and apoptosis data were compared with those in the glioblastoma series (Table 2).

Tumor cell proliferation and apoptosis were significantly higher in glioblastomas irrespective of the tumor area (Table 2, Figures 1). Endothelial cell proliferation in the intermediate area of the glioblastoma exceeded that of the ependymoma with borderline significance. The endothelial cell apoptosis of glioblastomas was significantly higher only in the perinecrotic area compared with ependymomas (Table 2).

Semiquantitative analysis of VEGF staining

All samples were positive for VEGF-A, albeit to a variable degree (Table 2). Staining for VEGF-B, -C, and -D was less intense and less uniform (with 13 of 14, 4 of 14, and 9 of 14 being positive, respectively). Vascular endothelial growth factor staining did not vary significantly with age group, location, or grade.

Vascular endothelial growth factor-A staining intensity in the ependymoma samples was similar to staining intensity of the perinecrotic area in our glioblastoma series (Table 2), whereas the staining intensity of the intermediate area in glioblastomas was clearly lower. Staining intensities of VEGF-B, -C, and -D in glioblastomas exceeded that of ependymomas irrespective of tumor area (Table 2, Figure 1). These differences in staining intensities were highly significant.

Angiopoietin-1/Angiopoietin-2 ratio

A relative high expression of the Ang-2 gene compared with Ang-1 is thought to promote tumor vessel instability. This instability determines the susceptibility of the tumor vessels to the proangiogenic stimulus of VEGF. We analyzed expression of the angiopoietin gene and calculated the ratio of Ang-1 and Ang-2. Whereas the expression of Ang-2 in ependymoma was similar to that in glioblastoma, the expression of Ang-1 in ependymoma exceeded that in glioblastoma significantly (Table 2). The calculated angiopoietin balance, with seemingly higher ratios in ependymoma compared with glioblastoma mainly due to differences in Ang-1 expression, did not reach significance (Table 2). Together, these data may be indicative of a vascular status in ependymoma that is less sensitive to the induction of angiogenic sprouting through VEGF compared with glioblastoma.

Basal membrane and pericyte coverage of tumor vessels

Vascular basal membrane and pericyte coverage were analyzed in 26 tumors (16 ependymoma and 10 glioblastoma). In comparison with glioblastoma, the coverage of tumor vessels by a basal membrane or pericytes was more extensive in ependymoma (Figure 2). Nevertheless, individual ependymomas did overlap with the glioblastoma group (Table 2). These results indicate that in general the vasculature of ependymomas has a higher maturation status, although individual ependymomas may contain immature vessels similar to glioblastomas.

Table 2. Tumor vessel parameters of ependymomas and glioblastoma*

Parameter	Ependymomas†	Glioblastomas‡	P value
MVD (Chalkley count)	5.74 (4.95–6.52)	P: 4.63 (4.26–5.00) I: 5.37 (4.98–5.76)	0.024 0.408
Tumor cell			
Proliferation	4.22 (0–49.9)	P: 13.10 (3.3–48.8) I: 21.05 (0.2–30.6)	<0.001 <0.001
Apoptosis	0.25 (0–6.9)	P: 3.00 (0.2–30.6) I: 0.60 (0–7.8)	<0.001 0.007
Endothelial cell			
Proliferation	3.45 (0–25.2)	P: 6.75 (0.9–28.8) I: 9.45 (0–25.0)	0.135 0.052
Apoptosis	2.78 (0–9.6)	P: 14.85 (0.2–67.6) I: 2.6 (0–12.5)	<0.001 0.282
VEGF			
A	1.25 (1.00–1.5)	P: 1.30 (1.14–1.45) I: 0.82 (0.69–0.95)	0.938 0.002
B	0.64 (0.47–0.82)	P: 1.34 (1.2–1.48) I: 1.26 (1.13–1.39)	<0.001 <0.001
C	0.14 (0.01–0.28)	P: 1.11 (0.93–1.30) I: 0.93 (0.77–1.10)	<0.001 <0.001
D	0.46 (0.23–0.70)	P: 1.57 (0.44–1.71) I: 1.13 (0.98–1.28)	<0.001 <0.001
Ang-1§	0.03 (0.001–0.36)	0.009 (0.001–0.24)	0.030
Ang-2§	0.04 (0.03–0.14)	0.03 (0.006–0.74)	0.097
Ang-1/Ang-2§	0.99 (0.03–3.04)	0.27 (0.03–1.67)	0.089
Basal membrane¶	0.72 (0.22–1.14)	0.31 (0.14–0.81)	0.009
Pericytes¶	0.20 (0.03–0.81)	0.11 (0.02–0.32)	0.022

* MVD, VEGF-A, -B, -C, and -D are presented as mean \pm SD; the other parameters are presented as median (range).

† Ependymoma: MVD, tumor cell and endothelial cell apoptosis (20 samples); tumor cell and endothelial cell proliferation (19); VEGF-A, -B, -C, and -D (14); Ang-1 and -2 (7); basal membrane and pericytes (16).

‡ The relative hypoxic perinecrotic (P) tumor area or the intermediate (I) tumor area; there were 62 samples for all parameters except basal membrane and pericytes (10 samples).

§ One ependymoma sample was disregarded as a result of outlier exclusion.

¶ Basal membrane and pericyte coverage of tumor vessels presented as the median number of tumor vessels staining for collagen Type IV or SMA, respectively, divided by the number of tumor vessels staining for CD34.

Discussion

Targeting the neovasculature of tumors is a promising addition to the current conventional treatments of cancer. A significant part of what is known about tumor vasculature and the process of angiogenesis has been analyzed in glioblastoma or glioblastoma models.^{8,9} In line with this, several clinical trials of antiangiogenic agents in patients with glioblastoma are ongoing. Less is known about the vasculature of other brain tumors. Pediatric ependymoma is a relatively rare tumor, and only a handful of studies have analyzed VEGF expression or MVD of this tumor.¹⁰⁻¹⁴

We studied several aspects of the ependymoma vasculature and compared the findings with data obtained in a glioblastoma series published previously. We found that ependymoma vasculature in general has a higher maturation status than glioblastoma vasculature, but that nevertheless a subset of ependymomas may contain immature vessels similar to glioblastomas.

The proliferation and apoptosis indices of tumor cells in glioblastomas were higher than in the ependymomas regardless of the tumor area. The tumor cell proliferation fraction of our ependymoma series was well within the range of 1–20.5 reported for ependymomas in the literature.^{19, 20} The fraction of apoptotic tumor cells is in agreement with the apoptotic index of 0.9 reported for ependymomas by Korshunov et al.¹¹ The differences in proliferation and apoptosis indices of endothelial cells between ependymoma and glioblastoma were less uniform. Whereas the Chalkley counts of both the ependymoma and the glioblastoma series were similar, proliferation and apoptosis indices of endothelial cells were not. Compared with ependymomas, proliferation of endothelial cells in glioblastomas was higher in the intermediate area, whereas apoptosis was higher in the perinecrotic area. These regional differences reflect the heterogeneity within glioblastomas and may be indicative of the influence of hypoxia on the angiogenic process. The hypoxic conditions within the tumor, which are known to contribute to the production of VEGF,²¹ may very well be of less importance in ependymoma, which has a more homogeneous architecture. Nonetheless, VEGF-A staining were of equal intensity in the 2 series. Although these results cannot be readily explained, alternative pathways of VEGF-A induction²¹ may account for these findings. In contrast to our findings, 2 studies reported that the VEGF expression in ependymomas either coincides with the presence of necrosis⁴ or is present mainly in areas of necrosis.¹⁴ These findings may actually suggest a hypoxic drive similar to that seen in glioblastoma. Vascular endothelial growth factor-B, -C, and -D stained with much less intensity in the ependymoma series than in the glioblastoma series. In a previous study, we showed that the pattern of expression of VEGF-D suggests a role for hypoxia in the induction of the production of this protein, similar to that of VEGF-A.¹⁶ The relative lack of VEGF-D shown here may therefore be illustrative of the absence of hypoxia as a driving force behind the production of VEGF in ependymoma.

The effect of VEGF-A on the initiation of angiogenesis depends in part on the angiopoietin/Tie-2 system.²² Tie-2, a membrane-bound endothelial cell restricted receptor, is ligated by Ang-1 leading to phosphorylation of the Tie-2 receptor and vessel stabilization and coverage with mural cells, constituting so-called mature vessels. In contrast, Ang-2 is a competitive antagonist of Ang-1 that induces vessel destabilization. These changes may, in the absence of sufficient survival factors such as VEGF, lead to endothelial cell apoptosis. On the other hand, if VEGF is available, proliferation and migration of endothelial cells can ensue. Angiopoietin-1 is expressed in tissues under physiological circumstances. Angiopoietin-2 expression is increased in pathological sites such as wound healing and tumors. In gliomas the onset of the expression of Ang-2 has been identified to be instrumental in the initiation of angiogenesis. It is contended that it is the balance between Ang-1 and -2 that determines the susceptibility of the vasculature to the proangiogenic stimulus of VEGF.²³ In that case the Ang-1 and -2 balance and the presence or absence of VEGF can be used as a measure of angiogenic potential.

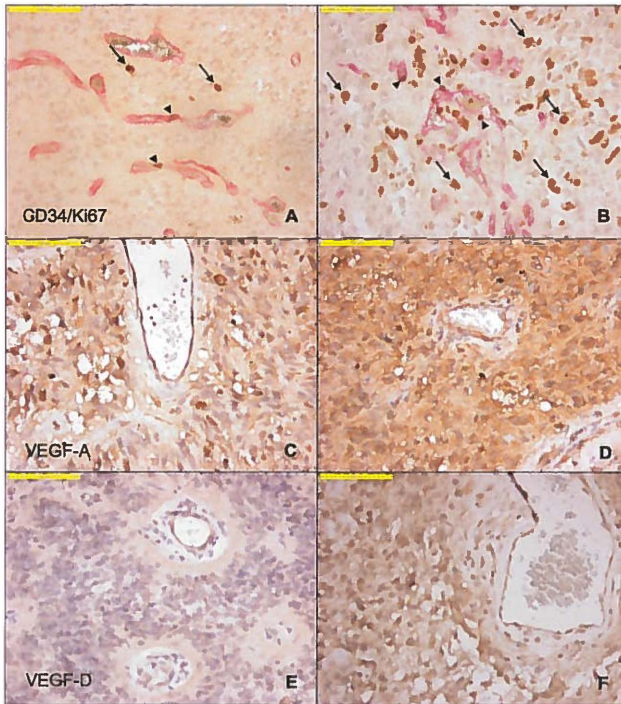


Figure 1. Immunohistochemical staining of ependymoma (A, C, and E) and glioblastoma (B, D, and F). Although the CD34/Ki 67 double staining of ependymoma (A) and glioblastoma (B) show similar MVDs, the number of proliferating tumor cells (*arrows*) and endothelial cells (*arrowheads*) is clearly higher in glioblastomas. Both ependymoma (C) and glioblastoma (D) show diffuse expression of VEGF-A, with intense staining of endothelial cells as well as tumor cells. Immunohistochemical staining for VEGF-D shows little to no staining in ependymoma (E), whereas staining in glioblastoma (F) is diffusely positive. Yellow bars represent 100 μ m.

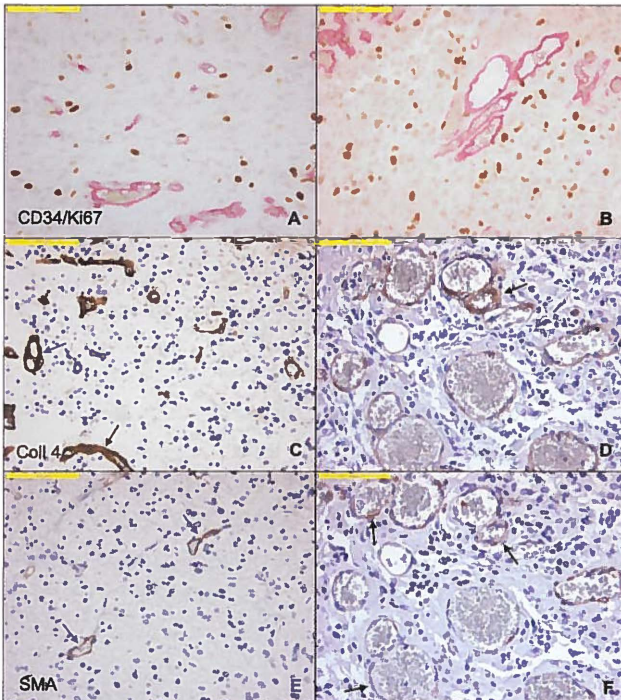


Figure 2. Immunohistochemical staining of ependymoma (A, C, and E) and glioblastoma (B, D, and F). Whereas the collagen Type IV (Coll 4) deposition of tumor vessels varies considerably in glioblastomas (D) from one vessel to the other (*arrow* indicates the only vessel in the photograph that is completely surrounded by a layer of collagen Type IV), collagen Type IV staining in ependymoma (C) is rather homogeneous and forms a thick layer around the vessels. Large and long vessels with multiple luminal areas (*arrows*) may appear as 2 or more separate structures on CD34 staining, which may account for the fact that collagen Type IV coverage of endothelial cells was less than 100% in ependymoma. In glioblastoma (F) SMA staining shows incomplete, heterogeneous, and scant coverage of tumor vessels with pericytes (*arrows*). In ependymoma (E), a subset of the microvessels shows SMA positivity. These vessels are more often than not completely surrounded by pericytes (*arrows*). Yellow bars represent 100 μ m.

In theory, one would expect to find highly angiogenic tumors such as glioblastomas to express high amounts of Ang-2 relative to Ang-1 compared with ependymomas. This was confirmed by our results. It is surprising, however, that this is brought about by a relatively higher expression of Ang-1 in the ependymoma series, whereas the expression of Ang-2 was similar.

Microvascular immaturity is associated with a relatively low pericyte coverage and aberrant basal membrane makeup.²⁴ As such, our data on pericyte and basal membrane coverage are in line with the findings of the angiopoietin balance. In ependymoma, the pericyte coverage of microvessels is in excess of that of glioblastoma. Similarly, the ependymoma series shows higher fractions of vessels that are surrounded by a basal membrane compared with the glioblastoma series.

Recently, antiangiogenesis studies in glioblastomas have shown some success in normalizing the vasculature as a means to sensitize the tumor to conventional treatment.^{25, 26} Moreover, clinical trials using bevacizumab in the treatment of recurrent glioblastoma have shown progression-free survival rates that compare favorably with historical controls.²⁷⁻²⁹ As we show here, the proangiogenic state of glioblastomas clearly supersedes that of ependymomas. In this context, ependymomas may not lend themselves very well to vessel-targeted therapy. However, these considerations are theoretical. In practice, at this time, the proangiogenic state of the tumor vasculature, as measured for instance by the angiopoietin balance, may not be a reliable predictor of the effect of antiangiogenesis treatment. Moreover, individual ependymomas show considerable overlap with the glioblastomas. Therefore, it is not impossible that the treatment of ependymomas or a subset of these tumors may benefit from antiangiogenesis as an addition to chemo- or radiotherapy.

Conclusions

Despite a lower proliferation fraction of endothelial cells in ependymomas compared with glioblastomas, the vascular density of both tumors is similar. The ependymoma vasculature, in general, has a higher maturation status than the glioblastoma vasculature, although these parameters show considerable overlap. Although successful vessel normalization through the use of antiangiogenic drugs may, in theory, be less likely in ependymomas than glioblastomas, any effect of such a therapy in ependymomas cannot be excluded beforehand. Because of the urgent need for additional therapeutic options in the treatment of pediatric intracranial ependymomas, further research into the feasibility of adding antiangiogenic drugs to the current treatment protocols is warranted.

Acknowledgements

This work was supported in part by grants from the Dutch Cancer Society (to M. Wagemakers and G. Molema) and the Jan Kornelis de Cock Stichting (project code 514273).

References

1. Bremnes RM, Camps C, Sirera R. Angiogenesis in non-small cell lung cancer: the prognostic impact of neoangiogenesis and the cytokines VEGF and bFGF in tumours and blood. *Lung Cancer*. 2006;51:143-158.
2. Ishigami SI, Aii S, Furutani M, et al. Predictive value of vascular endothelial growth factor (VEGF) in metastasis and prognosis of human colorectal cancer. *Br J Cancer*. 1998;78:1379-1384.
3. Vidal O, Soriano-Izquierdo A, Pera M, et al. Positive VEGF immunostaining independently predicts poor prognosis in curatively resected gastric cancer patients: results of a study assessing a panel of angiogenic markers. *J Gastrointest Surg*. 2008;12:1005-1014.
4. Weidner N. Tumor angiogenesis: review of current applications in tumor prognostication. *Semin Diagn Pathol*. 1993;10:302-313.
5. Samoto K, Ikezaki K, Ono M, et al. Expression of vascular endothelial growth factor and its possible relation with neovascularization in human brain tumors. *Cancer Res*. 1995;55:1189-1193.
6. Schmidt NO, Westphal M, Hagel C, et al. Levels of vascular endothelial growth factor, hepatocyte growth factor/scatter factor and basic fibroblast growth factor in human gliomas and their relation to angiogenesis. *Int J Cancer*. 1999;84:10-18.
7. Kerbel RS. Tumor angiogenesis. *N Engl J Med*. 2008;358:2039-2049.
8. Holash J, Maisonpierre PC, Compton D, et al. Vessel cooption, regression, and growth in tumors mediated by angiopoietins and VEGF. *Science*. 1999;284:1994-1998.
9. Jain RK, di Tomaso E, Duda DG, Loeffler JS, Sorensen AG, Batchelor TT. Angiogenesis in brain tumours. *Nat Rev Neurosci*. 2007;8:610-622.
10. Chan AS, Leung SY, Wong MP, et al. Expression of vascular endothelial growth factor and its receptors in the anaplastic progression of astrocytoma, oligodendroglioma, and ependymoma. *Am J Surg Pathol*. 1998;22:816-826.
11. Korshunov A, Golanov A, Timirgaz V. Immunohistochemical markers for prognosis of ependymal neoplasms. *J Neurooncol*. 2002;58:255-270.
12. Kurt E, Zheng PP, Hop WC, et al. Identification of relevant prognostic histopathologic features in 69 intracranial ependymomas, excluding myxopapillary ependymomas and subependymomas. *Cancer*. 2006;106:388-395.
13. Pietsch T, Valter MM, Wolf HK, et al. Expression and distribution of vascular endothelial growth factor protein in human brain tumors. *Acta Neuropathol*. 1997;93:109-117.
14. Preusser M, Wolfsberger S, Haberler C, et al. Vascularization and expression of hypoxia-related tissue factors in intracranial ependymoma and their impact on patient survival. *Acta Neuropathol*. 2005;109:211-216.
15. Hinsdale IL. Central Brain Tumor Registry of the United States: Statistical Report: Primary Brain Tumors in the United States, 2000-2004. Central Brain Tumor Registry of the United States. 2008;(<http://www.cbtrus.org/reports//2007-2008/2007report.pdf>) [Accessed November 18, 2009].
16. Sie M, Wagemakers M, Molema G, Mooij JJ, de Bont ES, den Dunnen WF. The angiopoietin 1/angiopoietin 2 balance as a prognostic marker in primary glioblastoma multiforme. *J Neurosurg*. 2009;110:147-155.
17. Vermeulen PB, Gasparini G, Fox SB, et al. Second international consensus on the methodology and criteria of evaluation of angiogenesis quantification in solid human tumours. *Eur J Cancer*. 2002;38:1564-1579.
18. Specht K, Richter T, Muller U, Walch A, Werner M, Hofler H. Quantitative gene expression analysis in microdissected archival formalin-fixed and paraffin-embedded tumor tissue. *Am J Pathol*. 2001;158:419-429.

19. Figarella-Branger D, Civatte M, Bouvier-Labit C, et al. Prognostic factors in intracranial ependymomas in children. *J Neurosurg.* 2000;93:605-613.
20. Wolfsberger S, Fischer I, Hoftberger R, et al. Ki-67 immunolabeling index is an accurate predictor of outcome in patients with intracranial ependymoma. *Am J Surg Pathol.* 2004;28:914-920.
21. Ferrara N. Molecular and biological properties of vascular endothelial growth factor. *J Mol Med (Berl).* 1999;77:527-543.
22. Reiss Y, Machein MR, Plate KH. The role of angiopoietins during angiogenesis in gliomas. *Brain Pathol.* 2005;15:311-317.
23. Tait CR and Jones PF. Angiopoietins in tumours: the angiogenic switch. *J Pathol.* 2004;204:1-10.
24. Jain RK. Normalization of tumor vasculature: an emerging concept in antiangiogenic therapy. *Science.* 2005;307:58-62.
25. Batchelor TT, Sorensen AG, di Tomaso E, et al. AZD2171, a pan-VEGF receptor tyrosine kinase inhibitor, normalizes tumor vasculature and alleviates edema in glioblastoma patients. *Cancer Cell.* 2007;11:83-95.
26. Pope WB, Lai A, Nghiemphu P, Mischel P, Cloughesy TF. MRI in patients with high-grade gliomas treated with bevacizumab and chemotherapy. *Neurology.* 2006;66:1258-1260.
27. Friedman HS, Prados MD, Wen PY, et al. Bevacizumab alone and in combination with irinotecan in recurrent glioblastoma. *J Clin Oncol.* 2009;27:4733-4740.
28. Kreisl TN, Kim L, Moore K, et al. Phase II trial of single-agent bevacizumab followed by bevacizumab plus irinotecan at tumor progression in recurrent glioblastoma. *J Clin Oncol.* 2009;27:740-745.
29. Vredenburgh JJ, Desjardins A, Herndon 2nd JE, et al. Phase II trial of bevacizumab and irinotecan in recurrent malignant glioma. *Clin Cancer Res.* 2007;13:1253-1259.





Chapter 5

Tumour vasculature and angiogenic profile of paediatric pilocytic astrocytoma; is it much different from glioblastoma?

Mariska Sie¹

Eveline S. J. M. de Bont¹

Frank J. G. Scherpen¹

Eelco W. Hoving³

Wilfred F. A. den Dunnen²

¹ Department of Pediatrics, Beatrix Children's Hospital, Pediatric Oncology/Hematology division

² Department of Pathology and Medical Biology, Pathology division

³ Department of Neurosurgery

University Medical Center Groningen, University of Groningen, Groningen, the Netherlands

Neuropath Appl Neurobiol 2010; 36: 636-647

Abstract

Aims: Pilocytic astrocytomas are the most frequent brain tumours in children. Because of their high vascularity, this study aimed to obtain insights into potential angiogenic related therapeutic targets in these tumours by characterization of the vasculature and the angiogenic profile. In this study 59 paediatric pilocytic astrocytomas were compared with 62 adult glioblastomas, as a prototype of tumour angiogenesis.

Methods: Microvessel density, vessel maturity in terms of basement membrane and pericyte coverage, and turnover of both endothelial and tumour cells, and vascular endothelial growth factor (VEGF) expression were evaluated in tumour tissue, immunohistochemically stained with, respectively, CD34, collagen IV, smooth muscle actin, Ki67/CD34, caspase-3/CD34 and VEGF(-A-D). As an indicator for vessel stability the angiopoietin (ANGPT)-1/ANGPT-2 balance was calculated using Real Time RT-PCR.

Results: Pilocytic astrocytoma and glioblastoma showed similar fractions of vessels covered with basement membrane and pericytes. Overlapping ANGPT-1/ANGPT-2 balance and VEGF-A expression were found. Pilocytic astrocytoma had fewer but wider vessels compared with glioblastoma. Turnover of endothelial and tumour cells were relatively lower in pilocytic astrocytoma. Within pilocytic astrocytoma, higher ANGPT-1/ANGPT-2 balance was correlated with fewer apoptotic endothelial cells. Lower numbers of vessels were correlated with higher VEGF-A expression.

Conclusions: Despite the fact that pilocytic astrocytoma showed a different vessel architecture compared with glioblastoma, a critical overlap in vessel immaturity/instability and the angiogenic profile was seen between both tumours. These findings suggest encouraging possibilities for targeting angiogenesis (for instance with anti-VEGF) as a therapeutic strategy in pilocytic astrocytoma.

Introduction

Pilocytic astrocytomas are grade I astrocytomas (WHO 2007), typically occurring in children and young adults, and representing the most frequent brain tumours in children.¹ Although pilocytic astrocytomas are highly vascular but generally circumscribed and slowly growing tumours, they may infiltrate into surrounding brain parenchyma and involve leptomeninges, causing diverse symptoms which also vary with tumour localization.^{1, 2} Gross total resection is considered the treatment of choice and cure will often be achieved in those patients.^{3, 4} For lesions in less favourable localizations, such as the diencephalic or thalamic regions, partial resection or biopsy only for histological diagnosis may be performed, possibly followed by postoperative chemotherapy and/or radiotherapy.⁵ Despite a 5-year survival of approximately 90%,⁶⁻⁸ morbidity can be serious, mainly because of the localization of the tumour (diencephalon and brain stem) and its subsequent chance of surgical morbidity and dismal effect of chemotherapy and/or radiation.⁹ So to reduce morbidity as well as mortality in children with pilocytic astrocytoma, new therapeutic modalities are needed. Because pilocytic astrocytomas are highly vascular, tumour vasculature or specific angiogenic factors could be potential therapeutic targets in these tumours.

Angiogenesis, formation of new vessels from preexisting ones, has been investigated as a target in cancer treatment for many years now, and has formed an effective and well-tolerated treatment in, for example, recurrent high grade astrocytomas.^{10, 11} Before tumour growth is obtained by angiogenesis, a subset of tumours initially grows by co-opting existing host vessels; tumour cells proliferate around existing blood vessels in the tissue. This co-opted host vasculature regresses, leading to a secondarily avascular tumour and massive tumour cell loss.¹² Next, under the influence of crucial factors such as vascular endothelial growth factor (VEGF) and angiopoietins the remaining tumour is 'rescued' by angiogenesis at the tumour margin, the so-called angiogenic switch.¹²⁻¹⁵ By targeting angiogenesis, resulting in disruption of blood supply and hypoxia, it is hypothesized that the tumour can be attacked indirectly.¹⁶ However, other theories may include anti-angiogenic therapy leading to vessel normalization for improved drug delivery and efficacy¹⁷ or resulting directly in suppression of tumour cells which express VEGF receptors.¹⁸

In theory, these possible effects of anti-angiogenic therapy could be more or less important in different tumours, depending on tumour vasculature and expression of angiogenic factors.¹⁹ As a consequence of an imbalance between pro- and anti-angiogenic factors, including VEGF and angiopoietins, various tumours are characterized by abnormal, immature vessels.^{20, 21} Those vessels have an abnormal endothelial-cell lining, detached pericytes, and a basement membrane that is abnormally thick or abnormally thin.¹⁷ Contrary to the extensively described angiogenic profile of high grade astrocytomas in adults, little is known about tumour vasculature and possible angiogenic activity in lowgrade paediatric astrocytomas, including pilocytic astrocytomas.

This study aimed to characterize tumour vasculature and the angiogenic profile of paediatric pilocytic astrocytoma to obtain insights into potential angiogenic related therapeutic targets in these tumours. We investigated microvessel density (MVD), vessel maturity and stability, and different angiogenic factors, including endothelial cell proliferation and VEGF expression. Vessel maturity and stability were analyzed in terms of basement membrane and pericytes coverage and the angiopoietin-1/angiopoietin-2 (ANGPT-1/ANGPT-2) balance using, respectively, morphometric techniques and Real Time RT-PCR. These data were interpreted in the context of previously described adult glioblastoma (WHO 2007, grade IV astrocytoma),^{22, 23} often seen as a model for studying angiogenesis.

Materials and methods

Patient and baseline characteristics

From November 1985 until March 2007, a total of 71 children (0–17 years of age) were histologically diagnosed with a pilocytic astrocytoma in our hospital. All patients underwent stereotactic biopsy, partial or gross total resection. Because the quantity and/or quality of tumour tissue from 12 patients were insufficient, tumour tissue of a final total of 59 pilocytic astrocytoma patients was included in this study, and evaluated in the context of tumour tissue of 62 adult patients with primary glioblastoma.²² Utilization of all human tissue was approved by the relevant institutional committees (University Medical Center Groningen).

Between the study population ($n = 59$) and the total pilocytic astrocytoma patient group ($n = 71$) no differences in baseline characteristics were found, including age at diagnosis, gender, tumour localization, neurosurgical procedure and possible post-operative chemotherapy and/or radiotherapy. 'Age at diagnosis' was defined as the patient's age at date of histological diagnosis. Tumour localization was divided into supratentorial, optic nerve, infratentorial and spinal cord. In addition, progression free survival (PFS), 5-year PFS and 5-year survival were evaluated. 'PFS' was defined as the time between operation and tumour progression as registered at magnetic resonance imaging (MRI) or computed tomography (CT). Tumour progression was described as the appearance of the tumour at MRI or CT after macroscopic total resection, as well as tumour progression assessed by imaging after stereotactic biopsy or partial resection. The baseline characteristics of glioblastoma patients have been described previously.²²

Evaluation of MVD

Two methods were used for MVD determination. First, the Chalkley point overlap morphometric technique in which double immunohistochemical stained slides for Ki67/CD34 (endothelial cell marker) were evaluated with the use of an objective of x20 and an ocular grid with 25 random points.²⁴ After the tumour was scanned to identify a maximum of five hot spots, the ocular grid was turned to maximize the overlap between points on the grid and the CD34 stained vessels. The number of overlapping points was counted for every hot spot. The Chalkley score for each slide was obtained by calculating the mean score of five hot spots.

Because in glioblastoma two important areas are distinguished, the perinecrotic and intermediate area, two Chalkley scores were assessed in this tumour.²² The second method was traditional counting of vessels (x200 magnification) in five randomized areas per slide, 30 min stained for CD34 with use of the NexES IHC Staining Module (Ventana Medical Systems, Tucson, AZ, USA). Antigen retrieval was performed at 98°C.

Morphometric analysis of vessel maturity

Vessel maturity was evaluated by calculating the fraction of tumour vessels that was covered with basement membrane or pericytes. So vessels were counted in, respectively, automatic stained slides as described above for collagen IV (main component of vascular basement membrane,²⁵ ICN Biochemicals, Costa Mesa, CA, USA, 1:800) and Smooth Muscle Actin (SMA, pericyte marker, Dako, Glostrup, Denmark, 1:100) at x200 magnification and next these numbers were divided by the CD34 vessel count. Five randomized areas were evaluated per tumour sample.²³ Moreover, these slides were analyzed by morphometry as described previously by Zhou et al.²⁶ Digital images [Leica DFC 420 C digital camera (Leica Microsystems, Heerbrugg, Switzerland) and Zeiss Axioskop model 451485 microscope (Carl Zeiss, Sydney, Australia)] were quantified for collagen IV and SMA at x200 magnification in six random areas per tumour sample. The pixel area of the positive staining was measured using Leica QWin software (Leica Imaging Systems, Cambridge, UK). The data were presented as the percentage of marker-positive surface area, which is calculated with the formula: marker-positive area x100/area of the optical field.

Genetic evaluation of vessel stability

As an indicator for vessel stability, gene expression of ANGPT-1 and ANGPT-2 was determined in deparaffinized tumour tissue using Real Time RT-PCR, followed by calculation of the balance between ANGPT-1 and -2 with the formula: $2^{\Delta Ct}$, in which ΔCt is the mean Cycle threshold (Ct) value of ANGPT-2 minus the mean Ct value of ANGPT-1.²² As such, a higher ANGPT-1/ANGPT-2 balance corresponds with relatively higher ANGPT-1 expression.

RNA-isolation was realized with use of the protocol described by Specht et al.,²⁷ and quantified using Nanodrop ND-1000 UV Spectrophotometer (NanoDrop Technologies, Wilmington, DE, USA). To remove contaminating DNA from RNA preparations and to subsequently remove the DNase and divalent cations from the sample, the TURBO DNA-free Kit (Applied Biosystems/Ambion, Austin, TX, USA) was used.²² Next, RNA was again quantified using Nanodrop. Synthesis of cDNA was performed as described previously.²⁸ Using TaqMan Universal PCR Master Mix (Applied Biosystems, Foster City, CA, USA) and the primers ANGPT-1 (Hs 00181613.m1), ANGPT-2 (Hs 00169867.m1), and GAPDH (Hs 99999905.m1), Real Time PCR was fulfilled in triplicate with an ABI7900HT Real Time sequence detection system in 384-well reaction plates.

Analysis of endothelial and tumour cell turnover and VEGF expression

Proliferation and apoptotic fractions of both endothelial and tumour cells were assessed in double-stained slides for, respectively, Ki67/CD34 and cleaved caspase-3/CD34 using an objective of x40 as described previously.²² In pilocytic astrocytoma three randomized high power fields (HPFs) were evaluated instead of five HPFs in glioblastoma, representing a more heterogeneous tumour. The expression of VEGF-A, -B, -C and -D was immunohistochemical determined using a semi-quantitative staining intensity score.²² No visible staining was scored as 0, low staining as 1, moderate as 2 and high intensity staining as 3. Evaluations of glioblastoma tissue were performed in both the perinecrotic and intermediate tumour area.²² During all these analyses of tumour tissue, investigators were blinded to the patient data.

Statistical analysis

PP-plots and the Shapiro-Wilk tests were used to evaluate if data had Gaussian distributions. Statistical comparisons were made with a Student's t-test if data had a Gaussian distribution and a Mann-Whitney U-test was used if data were not normally distributed. Comparisons between more than two groups were performed using anova if data were normally distributed and the Kruskal–Wallis test if data were ordinal and not normally distributed. The chi-square test was used for nominal (categorical) data. The nonparametric Spearman correlation test was used to compute correlations. For all statistical analyses, a two-tailed P-value of less than 0.05 was considered significant.

Results

Patient characteristics of the pilocytic astrocytoma study group

Median age at diagnosis in the study group of 59 patients was 7.2 years (Table 1). Children without tumour progression appeared to have a median age at diagnosis of 8.8 (range 0.2–16.6) years, while the median age of children with tumour progression was 5.3 years (range 0.8–14.1, $P = 0.023$). The choice of the type of neurosurgical procedure was dependent on tumour localization. When tumours were located centrally in the brain, such as thalamic tumours, only diagnostic biopsy was performed. Partial resection was mostly performed in pilocytic astrocytoma of the chiasm and hypothalamus, and gross total resection in infratentorial cerebellar tumours. As expected, a significant difference was found between the three neurosurgical procedures in the assessment of tumour progression: after stereotactic biopsy in all children tumour progression was seen, and after partial and gross total resection it was, respectively, 69% and 19% (chi-square $P < 0.001$). Five patients died due to tumour progression. Because of the heterogeneity in the study group concerning treatment and prognosis, no correlations of angiogenic data with outcome were studied.

Table 1. Baseline patient characteristics of the pilocytic astrocytoma study group ($n = 59$)

Characteristic	n (%)
Gender, male	37 (63)
Tumour localization	
Supratentorial	10 (17)
Optic nerve	18 (31)
Infratentorial	28 (47)
Spinal cord	3 (5)
Neurosurgery	
Stereotactic biopsy	2 (3)
Partial resection	29 (49)
Gross total resection	27 (46)
Missing data	1 (2)
Chemotherapy	6 (10)
Radiotherapy	3 (5)
Tumour progression	27 (46)
5-year progression free survival	(50)
Death	5 (8)
5-year survival	(90)
Characteristic	Median (range)
Age at diagnosis, years	7.2 (0.2–17.0)
Follow up, years	7.5 (0.1–21.5)
Progression free survival, years	2.2 (0.1–15.0)

Pilocytic astrocytoma showed fewer but wider vessels

As described previously, MVD was determined using (i) the Chalkley point overlap morphometric technique, as well as (ii) the traditional method of counting CD34 stained vessels. The results (Table 2) show that the Chalkley score was significantly higher in pilocytic astrocytoma. Interestingly, however, glioblastoma showed a higher number of blood vessels when using traditional vessel counting. In theory, the two techniques should be correlated. Indeed, in both pilocytic astrocytoma and the intermediate area in glioblastoma, a higher vessel counting was correlated with a higher Chalkley score (respectively $r: 0.348$, $P = 0.011$ and $r: 0.408$, $P = 0.001$). The Chalkley point overlap technique uses an ocular grid and the score depends on the maximum number of points lying in the lumen of blood vessels or on the CD34 stained endothelial cells. It is thus dependent not only on the number of blood vessels, but also on the diameter of these vessels. From these measurements it can be concluded that pilocytic astrocytoma had fewer but wider vessels than glioblastoma, which showed more vessels with a smaller diameter (Figure 1).

Cerebellar pilocytic astrocytomas ($n = 24$), known as highly vascularized tumours, showed a higher Chalkley score (median 8.6, range 2.4–15.8) compared with the other pilocytic astrocytomas ($n = 35$, median 6.7, range 3.0–12.4, $P = 0.012$), while the number of vessels was equal in all pilocytic astrocytoma ($P = 0.986$). These results reflect that cerebellar tumours have relatively wider blood vessels.

Table 2. Microvessel density (MVD), vessel stability, turnover of endothelial cells (EC) and tumour cells (TC), and vascular endothelial growth factor (VEGF) expression between pilocytic astrocytoma and glioblastoma

Parameter	Pilocytic astrocytoma (n = 59)	Glioblastoma (n = 62)*	P value
MVD			
Mean Chalkley score (95% CI)	7.6 (6.9–8.3)	P: 4.6 (4.3–5.0) I: 5.4 (5.0–5.8)	<0.001 <0.001
Median CD34 vessel count (range)	39.0 (16.0–104.0)	56.2 (17.0–126.4)	0.001
Vessel stability			
Median ANGPT-1/ANGPT-2 (range)	0.55 (0.05–11.63)	0.27 (0.03–1.67)	0.001
Turnover of EC			
Median PFEC (range)	1.9 (0.0–7.9)	P: 6.8 (0.9–28.8) I: 9.5 (0.0–25.0)	<0.001 <0.001
Median AFEC (range)	0.0 (0.0–2.2)	P: 14.9 (0.2–67.6) I: 2.6 (0.0–12.5)	<0.001 <0.001
Turnover of TC			
Median PFTC (range)	2.3 (0.0–9.2)	P: 13.1 (3.3–48.8) I: 21.1 (3.9–72.6)	<0.001 <0.001
Median APTC (range)	0.0 (0.0–0.5)	P: 3.0 (0.2–30.6) I: 0.6 (0.0–7.8)	<0.001 <0.001
Immunohistochemical VEGF expression			
Mean VEGF-A (95% CI)	1.26 (1.15–1.38)	P: 1.30 (1.14–1.45) I: 0.82 (0.69–0.95)	0.706 <0.001
Mean VEGF-B (95% CI)	0.97 (0.92–1.01)	P: 1.34 (1.20–1.48) I: 1.26 (1.13–1.39)	<0.001 <0.001
Mean VEGF-C (95% CI)	0.86 (0.77–0.95)	P: 1.11 (0.93–1.30) I: 0.93 (0.77–1.10)	0.021 0.547
Mean VEGF-D (95% CI)	1.02 (0.96–1.08)	P: 1.57 (0.44–1.71) I: 1.13 (0.98–1.28)	<0.001 0.141

*Perinecrotic area (P): relatively hypoxic area with HIF-1 α positively and VEGF-A up regulation; Intermediate area (I): normoxic tumour area with HIF-1 α negative.

PFEC: proliferation fraction of endothelial cells; AFEC: apoptotic fraction of endothelial cells; PFTC: proliferation fraction of tumour cells; APTC: apoptotic fraction of tumour cells; ANGPT: angiopoietin.

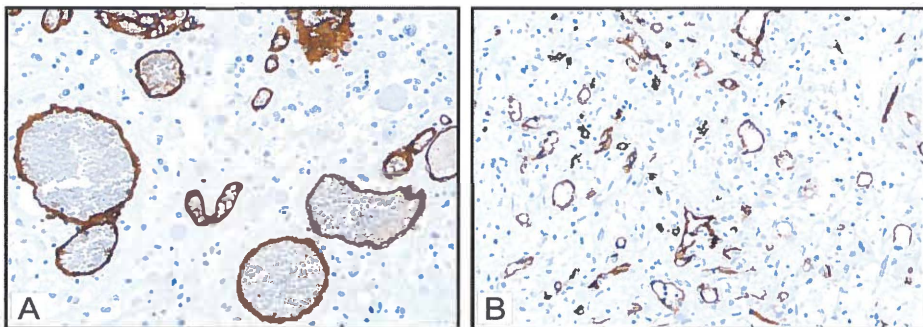


Figure 1. Photomicrographs of CD34-stained slides of pilocytic astrocytoma (A) and glioblastoma (B). Pilocytic astrocytoma showed fewer but wider vessels than glioblastoma, which showed more vessels with a smaller diameter. Original magnification: x200.

Overlap in vessel maturity and stability between pilocytic astrocytoma and glioblastoma

To investigate vessel maturity, we: (i) calculated the fraction of tumour vessels that was covered with basement membrane or pericytes; and (ii) used morphometry in which the surface area positive for collagen IV and SMA was assessed. Comparing pilocytic astrocytoma with glioblastoma, identical fractions of vessels covered with basement membrane and pericytes were found (Figure 2A). Moreover, although pilocytic astrocytoma showed statistically significant higher SMA percentages of positive surface area, clear overlap was seen between the two tumour types (Figure 2B). Interestingly, only in pilocytic astrocytoma was a positive correlation found between pericytes and basement membrane coverage, suggesting relatively less immaturity in these tumours ($r: 0.377$, $P = 0.005$). Furthermore, the pericytes coverage that may shape and control a uniform vessel diameter was positively correlated with the Chalkley score which partially depends on capillary diameter ($r: 0.590$, $P < 0.001$).

As described earlier, the ANGPT-1/ANGPT-2 balance measured with Real Time RT-PCR could also give an indication of vessel stability/maturity.²² It has been proposed that ANGPT-1 recruits pericytes and potentiates microvessel stability and maturation by supporting interactions between endothelial cells and pericytes.^{29–31} ANGPT-2, on the other hand, works as a destabilizing factor on blood vessels.^{32, 33} Strikingly, pilocytic astrocytomas located in the cerebellum ($n = 24$) showed a significantly lower ANGPT-1/ANGPT-2 balance (median 0.39, range 0.05–1.24) compared with the other pilocytic astrocytomas ($n = 35$, median 0.68, range 0.21–11.63, $P = 0.025$), reflecting relatively more unstable vessels in cerebellar pilocytic astrocytoma. Compared with glioblastoma, the total pilocytic astrocytoma group showed a higher ANGPT-1/ANGPT-2 balance (Table 2). However, the subgroup of cerebellar pilocytic astrocytomas did not show a significant difference with glioblastomas ($P = 0.450$). No significant correlation was detected between the ANGPT-1/ANGPT-2 balance and positive SMA surface area ($r: 0.106$; $P = 0.585$).

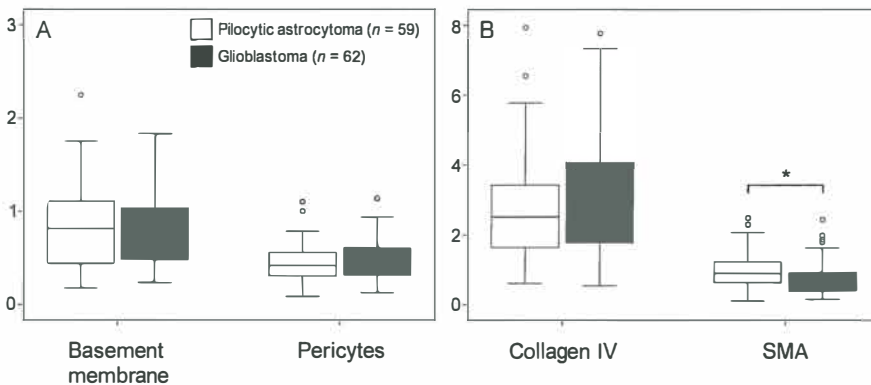


Figure 2. (A) Boxplots showing no difference between pilocytic astrocytoma and glioblastoma in fractions of vessels covered with basement membrane (collagen IV/CD34, $P = 0.928$) and pericytes (smooth muscle actin (SMA)/CD34, $P = 0.406$). (B) Boxplots showing the percentage positive surface area relative to the area of optical field, measured by morphometry software, between pilocytic astrocytoma and glioblastoma. Although pilocytic astrocytoma showed a statistically significant higher SMA positive surface area compared with glioblastoma (* $P = 0.016$), the boxplots show clearly an overlap in the results of the two tumour types.

Lower turnover of endothelial and tumour cells in pilocytic astrocytoma

The turnover of endothelial cells as parameter of angiogenic activity was significantly lower in pilocytic astrocytoma than in glioblastoma (Table 2). A similar difference was seen in the turnover of tumour cells. Within pilocytic astrocytoma, a higher ANGPT-1/ANGPT-2 balance, reflecting more vessel stability, was correlated with less apoptotic endothelial cells ($r: -0.480, P = 0.007$). No significance was found between a higher ANGPT-1/ANGPT-2 balance and less proliferating endothelial cells ($r: -0.103, P = 0.590$). Markedly, as characteristic for angiogenesis, more proliferating tumour cells were correlated with more proliferating endothelial cells within pilocytic astrocytoma ($r: 0.636, P < 0.001$). No differences were seen between the different tumour localizations.

Overlapping immunohistochemical VEGF expression between pilocytic astrocytoma and glioblastoma

The VEGF-A, which is induced by hypoxia, increases microvascular permeability, stimulates endothelial cell migration and division and induces angiogenesis.³⁴ Remarkable is the overlapping VEGF-A staining intensity scores between pilocytic astrocytoma and the hypoxic tumour area in glioblastoma (Table 2, Figure 3), suggesting a role for hypoxia induced VEGF expression in pilocytic astrocytoma. Consistent with this concept, lower numbers of vessels counted in CD34 stained pilocytic slides were correlated with higher expression of VEGF-A ($r: -0.434, P = 0.001$). Although no differences were found in VEGF expression between various tumour localizations, the coefficient of this correlation between the number of CD34 positive vessels and VEGF-A expression was stronger in cerebellar pilocytic astrocytomas ($n = 24, r: -0.436, P = 0.042$) which are mainly characterized by cyst formation compared with other tumour localizations ($n = 35, r: -0.424, P = 0.022$). In both pilocytic astrocytoma and the perinecrotic area in glioblastoma, VEGF-A expression was positively correlated with the fraction of vessels covered with pericytes (respectively $r: 0.317, P = 0.026$ and $r: 0.314, P = 0.023$).

In contrast to VEGF-A, the other members of the VEGF-family, including VEGF-B, -C and -D showed lower expression in pilocytic astrocytoma than in glioblastoma (Table 2, Figure 3), although (again) overlap between the two tumour types was observed.

Discussion

The present study demonstrated, besides differences in vessel architecture between pilocytic astrocytoma and glioblastoma, also a critical overlap in vessel immaturity/instability and angiogenic activity.

A fraction of the pilocytic astrocytomas showed a higher ANGPT-1/ANGPT-2 balance, stimulating vessel stability and leading to wider diameter blood vessels.^{35, 36} The ANGPT-1/Tie-2 system has been described as a potent regulator of the enlargement of blood vessel calibre. One of the key determinants in this mechanism is apelin, which is up-regulated under the activation of the Tie-2 receptor by ANGPT-1.^{37, 38} However, although cerebellar pilocytic astrocytoma showed the widest blood vessels, an interesting overlap with glioblastoma was found in the ANGPT-1/ANGPT-2 balance, demonstrating resemblance in vessel instability.

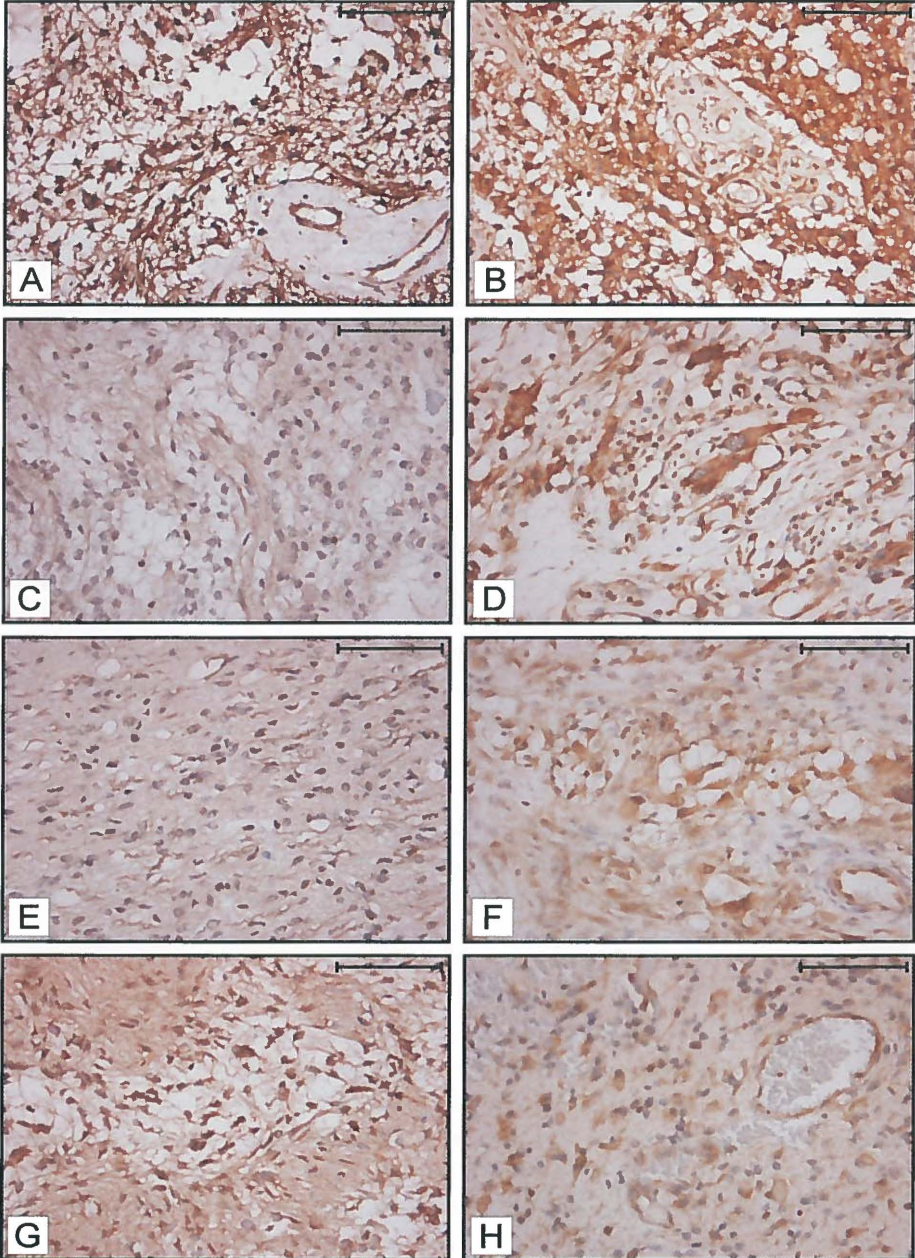


Figure 3. Photomicrographs of immunohistochemical stainings of pilocytic astrocytoma (A, C, E and G) and glioblastoma (B, D, F and H). Both pilocytic astrocytoma (A) and glioblastoma (B) show a relatively strong expression of vascular endothelial growth factor-A (VEGF-A) compared with the other growth factors (C-H). On average, the staining intensity of VEGF-B, -C and -D was stronger in glioblastomas than in pilocytic astrocytomas. Note that the tumour endothelium is also positive and could therefore be used as an intern control. The bars in the pictures represent 100 micro.

Indeed, besides ANGPT-1, also other factors including basic fibroblast growth factor and hypoxia could induce apelin expression and thereby increase vessel diameter.³⁷⁻³⁹ As cerebellar pilocytic astrocytomas are characterized by cyst formation resulting in intratumoral hypoxia, this could possibly lead to apelin induction and increased blood vessel diameter.

Besides wider vessels, pilocytic astrocytomas showed more regularly shaped vessels.⁴⁰ This observation was confirmed with a positive correlation between pericytes that control uniformity in vessel diameter⁴¹ and the Chalkley score partially depending on capillary diameter. ANGPT-2 seems to play a larger role in glioblastoma. It acts as an antagonist and inhibits ANGPT-1 induced phosphorylation of Tie-2 receptors in endothelial cells; as a result, ANGPT-2 initiates extensive angiogenesis resulting in pericyte drop-off and vascular destabilization.^{32, 33} The association between angiopoietins and blood vessel shape has not been described previously in glioma.

Analyzing vessel maturity in pilocytic astrocytoma, a positive correlation was found between pericytes and basement membrane coverage, suggesting a maturation step in which basement membrane is stimulated by pericyte recruitment in contrast to glioblastoma. However, this is only described for vasculogenesis, *de novo* formation of new blood vessels, but not for angiogenesis.⁴² Interestingly, according to the vessel fraction covered with pericytes which corresponds with the vessel maturation index,^{43,44} both tumours showed a surprisingly equal degree of vessel immaturity. Nevertheless, to give detailed information about the presence or absence of pericytes, a single pericyte marker like SMA, may not be sufficient.⁴¹

Notably, the pro-angiogenic VEGF-A was similarly expressed in pilocytic astrocytoma compared with the relatively hypoxic perinecrotic tumour area in glioblastoma and even scored higher than in the intermediate tumour area. The two different areas in glioblastoma are a result of its aggressive growth pattern. Although pilocytic astrocytomas are slowly growing tumours, areas of hyaline and cystic degradation have been distinguished due to tumour growth and increased tissue pressure and characterized by high VEGF expression.⁴⁵ Moreover, the present study showed a negative correlation between the number of CD34 positive vessels in pilocytic astrocytoma and VEGF-A expression. As cerebellar pilocytic astrocytomas are particularly cystic and highly vascular tumours, this correlation was found to be stronger in these tumours. These findings support a critical role for hypoxia induced VEGF expression in pilocytic astrocytoma.

The VEGF-A stimulates endothelial cell proliferation and migration, its role on pericytes however is less clear and different studies present conflicting results. It is suggested that VEGF ablates pericyte coverage of nascent vascular sprouts, leading to vessel destabilization,⁴⁶ while it is also shown that VEGF could promote the recruitment of pericytes, thereby contributing to the maturation of newly formed blood vessels.^{31, 47} This interaction between VEGF and pericytes was confirmed in the present study with a positive correlation between VEGF-A expression and the fraction of blood vessels covered with pericytes in both pilocytic astrocytoma and the perinecrotic area in glioblastoma. Furthermore, little is known about other members of the VEGF-family. In the present study, VEGF-B, -C and -D were expressed at relatively lower levels in pilocytic astrocytoma, although overlap between the two tumour types was observed. Within pilocytic astrocytoma, VEGF-B's probable function to stimulate angiogenesis^{48, 49} was confirmed with a positive correlation between proliferating tumour cells and VEGF-B expression.

In our opinion, this is the first study that has investigated various aspects of tumour vasculature in terms of vessel maturity status and stability and the angiogenic profile in pilocytic astrocytoma, using quantitative techniques like morphometry. This method in which overlapping SMA and collagen IV positive surface area were found, is a new technique, introduced by Zhou et al. in the evaluation of anti-angiogenic therapy in glioma xenografts²⁶ and never used before in comparisons between human tumour tissues.

While it is suggested that (i) low grade astrocytomas only show vessel co-option instead of angiogenesis; and (ii) increased angiogenesis is associated with a higher malignant brain tumour grade,^{15, 50} from our results it can be concluded that angiogenesis plays certainly a role in pilocytic astrocytoma. This is especially seen in overlapping VEGF-A expression between pilocytic astrocytoma and glioblastoma. Moreover, in high as well as low grade astrocytomas targeting the VEGF/VEGF receptor-2 (VEGFR-2) signalling pathway, which has been described recently, seems to be an effective therapeutic strategy.^{11, 51} However, for low grade astrocytoma, a selected patient group was treated; ten children with multiple recurrent low-grade gliomas (mostly diencephalic tumours) who had failed several treatment regimes, received a combination of bevacizumab and irinotecan. Two pilocytic astrocytomas were included.⁵¹

Besides selection bias, more importantly the possible synergistic effect of bevacizumab and chemotherapy is unclear and probably involves multiple mechanisms.¹⁹ In glioblastoma, for instance, it is thought that the efficacy seen with the combination of bevacizumab and irinotecan could be explained by an antitumour stem-cell effect of bevacizumab and anti-differentiated tumour cell effect of irinotecan.¹¹ In contrast to high grade gliomas which show increased VEGFR expression of tumour cells and surrounding tumour tissue, in pilocytic astrocytoma VEGFRs were confined to the endothelial cells.^{44, 52} So other response mechanisms are probably more important in pilocytic astrocytoma.

Because our study demonstrated clear overlap in vascular abnormality between pilocytic astrocytoma and glioblastoma, normalization of tumour vasculature by targeting VEGF could be a crucial mechanism. In theory, vessel normalization results in decreased interstitial pressure, more mature blood vessels, less hypoxia and increased delivery of chemotherapy to the tumour.¹⁷ Thus VEGF/VEGFR interaction could be an encouraging therapeutic target to control tumour growth and possibly reduce morbidity and mortality in children with pilocytic astrocytoma. However, different adaptive resistance mechanisms may arise in response to anti-angiogenic therapy, including up-regulation of alternative proangiogenic signalling pathways within the tumour.⁵³ For pilocytic astrocytoma, this is unclear and warrants further study. Moreover, possible toxicity related to angiogenic treatment strategies^{10, 54, 55} needs to be carefully taken into account. Nonetheless, although cerebellar pilocytic astrocytomas showed the most obvious signs of vessel instability, anti-angiogenic therapy could be in particular suitable/needed for pilocytic astrocytomas in surgically inaccessible sites or in cases involving large unresectable tumours.

Acknowledgements

This work was supported by a grant from Jan Kornelis de Cock Stichting (project code 09-58 to M. Sie).

References

1. Louis DN, Ohgaki H, Wiestler OD, Cavenee WK. Classification of Tumours of the Central Nervous System. 4th ed. Lyon: IARC; 2007.
2. Koeller KK and Rushing EJ. From the archives of the AFIP: pilocytic astrocytoma: radiologic-pathologic correlation. *Radiographics*. 2004;24:1693-1708.
3. Gajjar A, Sanford RA, Heideman R, et al. Low-grade astrocytoma: a decade of experience at St. Jude Children's Research Hospital. *J Clin Oncol*. 1997;15:2792-2799.
4. Sutton LN, Molloy PT, Sernyak H, et al. Long-term outcome of hypothalamic/chiasmatic astrocytomas in children treated with conservative surgery. *J Neurosurg*. 1995;83:583-589.
5. Ramina R, Neto MC, Meneses M, Arruda WO, Hunhevicz SC, Pedrozo AA. Management of deep-seated gliomas. *Crit Rev Neurosurg*. 1999;9:34-40.
6. Due-Tonnessen BJ, Helseth E, Scheie D, Skullerud K, Aamodt G, Lundar T. Long-term outcome after resection of benign cerebellar astrocytomas in children and young adults (0-19 years): report of 110 consecutive cases. *Pediatr Neurosurg*. 2002;37:71-80.
7. Fernandez C, Figarella-Branger D, Girard N, et al. Pilocytic astrocytomas in children: prognostic factors-a retrospective study of 80 cases. *Neurosurgery*. 2003;53:544-553.
8. Giannini C, Scheithauer BW, Burger PC, et al. Cellular proliferation in pilocytic and diffuse astrocytomas. *J Neuropathol Exp Neurol*. 1999;58:46-53.
9. Dirven CM, Mooij JJ, Molenaar WM. Cerebellar pilocytic astrocytoma: a treatment protocol based upon analysis of 73 cases and a review of the literature. *Childs Nerv Syst*. 1997;13:17-23.
10. Friedman HS, Prados MD, Wen PY, et al. Bevacizumab alone and in combination with irinotecan in recurrent glioblastoma. *J Clin Oncol*. 2009;27:4733-4740.
11. Vredenburgh JJ, Desjardins A, Herndon 2nd JE, et al. Bevacizumab plus irinotecan in recurrent glioblastoma multiforme. *J Clin Oncol*. 2007;25:4722-4729.
12. Holash J, Maisonpierre PC, Compton D, et al. Vessel cooption, regression, and growth in tumors mediated by angiopoietins and VEGF. *Science*. 1999;284:1994-1998.
13. Bach F, Uddin FJ, Burke D. Angiopoietins in malignancy. *Eur J Surg Oncol*. 2007;33:7-15.
14. Carmeliet P. VEGF as a key mediator of angiogenesis in cancer. *Oncology*. 2005;69 Suppl 3:4-10.
15. Tait CR and Jones PF. Angiopoietins in tumours: the angiogenic switch. *J Pathol*. 2004;204:1-10.
16. Folkman J. Tumor angiogenesis: therapeutic implications. *N Engl J Med*. 1971;285:1182-1186.
17. Jain RK. Molecular regulation of vessel maturation. *Nat Med*. 2003;9:685-693.
18. Wu Y, Zhong Z, Huber J, et al. Anti-vascular endothelial growth factor receptor-1 antagonist antibody as a therapeutic agent for cancer. *Clin Cancer Res*. 2006;12:6573-6584.
19. Ellis LM and Hicklin DJ. VEGF-targeted therapy: mechanisms of anti-tumour activity. *Nat Rev Cancer*. 2008;8:579-591.
20. Fukumura D and Jain RK. Tumor microvasculature and microenvironment: targets for anti-angiogenesis and normalization. *Microvasc Res*. 2007;74:72-84.
21. Jain RK. Normalization of tumor vasculature: an emerging concept in antiangiogenic therapy. *Science*. 2005;307:58-62.
22. Sie M, Wagemakers M, Molema G, Mooij JJ, de Bont ES, den Dunnen WF. The angiopoietin 1/angiopoietin 2 balance as a prognostic marker in primary glioblastoma multiforme. *J Neurosurg*. 2009;110:147-155.
23. Wagemakers M, Sie M, Hoving EW, Molema G, de Bont ES, den Dunnen WF. Tumor vessel biology in pediatric intracranial ependymoma. *J Neurosurg Pediatr*. 2010;5:335-341.

24. Vermeulen PB, Gasparini G, Fox SB, et al. Second international consensus on the methodology and criteria of evaluation of angiogenesis quantification in solid human tumours. *Eur J Cancer*. 2002;38:1564-1579.
25. Kalluri R. Basement membranes: structure, assembly and role in tumour angiogenesis. *Nat Rev Cancer*. 2003;3:422-433.
26. Zhou Q, Guo P, Gallo JM. Impact of angiogenesis inhibition by sunitinib on tumor distribution of temozolomide. *Clin Cancer Res*. 2008;14:1540-1549.
27. Specht K, Richter T, Muller U, Walch A, Werner M, Hofler H. Quantitative gene expression analysis in microdissected archival formalin-fixed and paraffin-embedded tumor tissue. *Am J Pathol*. 2001;158:419-429.
28. Kuijlen JM, Mooij JJ, Platteel I, et al. TRAIL-receptor expression is an independent prognostic factor for survival in patients with a primary glioblastoma multiforme. *J Neurooncol*. 2006;78:161-171.
29. Sato TN, Tozawa Y, Deutsch U, et al. Distinct roles of the receptor tyrosine kinases Tie-1 and Tie-2 in blood vessel formation. *Nature*. 1995;376:70-74.
30. Suri C, Jones PF, Patan S, et al. Requisite role of angiopoietin-1, a ligand for the TIE2 receptor, during embryonic angiogenesis. *Cell*. 1996;87:1171-1180.
31. Wakui S, Yokoo K, Muto T, et al. Localization of Ang-1, -2, Tie-2, and VEGF expression at endothelial-pericyte interdigitation in rat angiogenesis. *Lab Invest*. 2006;86:1172-1184.
32. Maisonpierre PC, Suri C, Jones PF, et al. Angiopoietin-2, a natural antagonist for Tie2 that disrupts in vivo angiogenesis. *Science*. 1997;277:55-60.
33. Scharpfenecker M, Fiedler U, Reiss Y, Augustin HG. The Tie-2 ligand angiopoietin-2 destabilizes quiescent endothelium through an internal autocrine loop mechanism. *J Cell Sci*. 2005;118:771-780.
34. Dvorak HF. Vascular permeability factor/vascular endothelial growth factor: a critical cytokine in tumor angiogenesis and a potential target for diagnosis and therapy. *J Clin Oncol*. 2002;20:4368-4380.
35. Cho CH, Kim KE, Byun J, et al. Long-term and sustained COMP-Ang1 induces long-lasting vascular enlargement and enhanced blood flow. *Circ Res*. 2005;97:86-94.
36. Thurston G, Wang Q, Baffert F, et al. Angiopoietin 1 causes vessel enlargement, without angiogenic sprouting, during a critical developmental period. *Development*. 2005;132:3317-3326.
37. Kidoya H, Ueno M, Yamada Y, et al. Spatial and temporal role of the apelin/APJ system in the caliber size regulation of blood vessels during angiogenesis. *EMBO J*. 2008;27:522-534.
38. Takakura N and Kidoya H. Maturation of blood vessels by haematopoietic stem cells and progenitor cells: involvement of apelin/APJ and angiopoietin/Tie2 interactions in vessel caliber size regulation. *Thromb Haemost*. 2009;101:999-1005.
39. Eyries M, Siegfried G, Ciumas M, et al. Hypoxia-induced apelin expression regulates endothelial cell proliferation and regenerative angiogenesis. *Circ Res*. 2008;103:432-440.
40. Grunstein J, Masbad JJ, Hickey R, Giordano F, Johnson RS. Isoforms of vascular endothelial growth factor act in a coordinate fashion To recruit and expand tumor vasculature. *Mol Cell Biol*. 2000;20:7282-7291.
41. Gerhardt H and Betsholtz C. Endothelial-pericyte interactions in angiogenesis. *Cell Tissue Res*. 2003;314:15-23.
42. Stratman AN, Malotte KM, Mahan RD, Davis MJ, Davis GE. Pericyte recruitment during vasculogenic tube assembly stimulates endothelial basement membrane matrix formation. *Blood*. 2009;114:5091-5101.
43. Benjamin LE, Golijanin D, Itin A, Pode D, Keshet E. Selective ablation of immature blood vessels in established human tumors follows vascular endothelial growth factor withdrawal. *J Clin Invest*. 1999;103:159-165.

44. Gesundheit B, Klement G, Senger C, et al. Differences in vasculature between pilocytic and anaplastic astrocytomas of childhood. *Med Pediatr Oncol*. 2003;41:516-526.
45. Leung SY, Chan AS, Wong MP, Yuen ST, Cheung N, Chung LP. Expression of vascular endothelial growth factor and its receptors in pilocytic astrocytoma. *Am J Surg Pathol*. 1997;21:941-950.
46. Greenberg JJ, Shields DJ, Barillas SG, et al. A role for VEGF as a negative regulator of pericyte function and vessel maturation. *Nature*. 2008;456:809-813.
47. Yamagishi S, Yonekura H, Yamamoto Y, et al. Vascular endothelial growth factor acts as a pericyte mitogen under hypoxic conditions. *Lab Invest*. 1999;79:501-509.
48. Salven P, Lymboussaki A, Heikkilä P, et al. Vascular endothelial growth factors VEGF-B and VEGF-C are expressed in human tumors. *Am J Pathol*. 1998;153:103-108.
49. Silvestre JS, Tamarat R, Ebrahimian TG, et al. Vascular endothelial growth factor-B promotes in vivo angiogenesis. *Circ Res*. 2003;93:114-123.
50. Fischer I, Gagner JP, Law M, Newcomb EW, Zagzag D. Angiogenesis in gliomas: biology and molecular pathophysiology. *Brain Pathol*. 2005;15:297-310.
51. Packer RJ, Jakacki R, Horn M, et al. Objective response of multiply recurrent low-grade gliomas to bevacizumab and irinotecan. *Pediatr Blood Cancer*. 2009;52:791-795.
52. Sikkema AH, de Bont ES, Molema G, et al. High-throughput assessment of the VEGFR2 kinase activity profile in pediatric brain tumor tissue. *AACR Annual Meeting*. 2010;Washington, DC, USA.
53. Bergers G and Hanahan D. Modes of resistance to anti-angiogenic therapy. *Nat Rev Cancer*. 2008;8:592-603.
54. Reismüller B, Azizi AA, Peyrl A, et al. Feasibility and tolerability of bevacizumab in children with primary CNS tumors. *Pediatr Blood Cancer*. 2010;54:681-686.
55. Vredenburgh JJ, Desjardins A, Herndon 2nd JE, et al. Phase II trial of bevacizumab and irinotecan in recurrent malignant glioma. *Clin Cancer Res*. 2007;13:1253-1259.



Chapter 6

Pro- and anti-angiogenic VEGF-A isoforms in pediatric pilocytic astrocytoma and adult glioblastoma: possibilities for anti-angiogenic therapy in pilocytic astrocytoma?

Mariska Sie¹

Wilfred F. A. den Dunnen²

Frank J. G. Scherpen¹

Eelco W. Hoving³

Eveline S. J. M. de Bont¹

¹ Department of Pediatrics, Beatrix Children's Hospital, Pediatric Oncology/Hematology division

² Department of Pathology and Medical Biology, Pathology division

³ Department of Neurosurgery

University Medical Center Groningen, University of Groningen, Groningen, the Netherlands

Cell Oncol 2012; 35: suppl 1 (abstract)

Abstract

Aims: The present study aimed to analyze VEGF-A isoforms in correlation with tumor vessel morphology in pediatric pilocytic astrocytoma and adult glioblastoma. Secondly, we aimed to determine the ratio between pro- (VEGF-A_{xxx}a) and anti-angiogenic (VEGF-A_{xxx}b) VEGF-A isoforms because VEGF-A_{xxx}b inhibits the effect of anti-VEGF-A antibodies like bevacizumab.

Methods: VEGF-A isoforms were analyzed in tumor tissue of 15 pilocytic astrocytoma and 12 glioblastoma patients using Real Time RT-PCR. Microvessel density and vessel maturity in terms of basement membrane and pericyte coverage were evaluated in immunohistochemically stained slides with CD34, collagen IV and smooth muscle actin respectively.

Results: All pro-angiogenic VEGF-A isoforms (VEGF-A_{121a-189a}) were lower expressed in pilocytic astrocytoma compared with glioblastoma. However, analyzing these isoforms relative to VEGF-A_{165a} as it is predominantly expressed in normal brain, no significant differences were found between both tumors. VEGF-A isoforms were not correlated with differences in vessel architecture between pilocytic astrocytoma and glioblastoma. Longer isoforms were associated with more vessel maturity. Strikingly, both tumors showed overlapping VEGF-A_{xxx}a : VEGF-A_{xxx}b ratios with relatively higher VEGF-A_{165a} and VEGF-A_{189a} expression.

Conclusions: The interplay between various VEGF-A isoforms does not seem to be the sole explanation for the different vessel architecture in pilocytic astrocytoma and glioblastoma. Interestingly, a high overlapping pro- and anti-angiogenic VEGF-A isoform ratio was found between both tumors, suggesting possibilities for anti-angiogenic therapy not only in glioblastoma, but also in pilocytic astrocytoma.

Introduction

Pilocytic astrocytomas (WHO grade I) are the most frequent pediatric brain tumors.¹ Despite different therapeutic options including neurosurgery, chemotherapy and radiotherapy, still 10% of the children with a pilocytic astrocytoma die due to tumor progression within 5 years.² Furthermore, morbidity can be serious, mainly because of the tumor localization (diencephalon, brain stem, optic pathway) and its subsequent chance of surgical morbidity and dismal effects of chemotherapy and/or radiation.²⁻⁴ New therapeutic strategies are warranted for these patients. Because pilocytic astrocytomas are highly vascular, anti-angiogenic therapy could be suitable and seems to be also an effective therapeutic option.⁵ Moreover, this possible suitability for targeting angiogenesis, was also suggested in our previous study, in which a critical overlap in the angiogenic profile and vessel immaturity/instability was found between pilocytic astrocytoma and the extensively described glioblastoma (WHO grade IV). However, the highly vascular pilocytic astrocytoma showed fewer but wider vessels compared with glioblastoma which contained more and smaller vessels.⁵ Various mechanisms, including the expression of vascular endothelial growth factor (VEGF) isoforms, could contribute to this difference in tumor vessel morphology. An increased insight in the tumor vasculature of pilocytic astrocytoma could result in a better understanding in new therapeutic strategies for these tumors, including anti-angiogenic therapy.

Angiogenesis, the development and remodeling of new blood vessels from an existing vasculature, is a fundamental regulatory process involved in tumor growth and progression.^{7,8} The most potent and dominant mediator in the mechanism of angiogenesis is VEGF-A which is up-regulated in several malignancies, including brain tumors.^{9,10} VEGF-A stimulates endothelial cell proliferation, migration, and increases microvascular permeability by activation of VEGF receptor 1 (VEGFR-1/flt-1) and VEGFR-2 (KDR/flk1).^{11,12} The VEGF-A gene consists of eight exons that give rise to various isoforms of *i.e.* 121, 145, 148, 165, 183 and 189 amino acids through differential splicing (Figure 1A). All isoforms contain exons 1-5 and the terminal exon, exon 8. The heparin-binding domain encoded by exon 6 and 7 determine binding to the extracellular matrix, and therefore isoforms containing exon 6 (VEGF-A₁₄₅) or both exon 6 and 7 (VEGF-A₁₈₃ and VEGF-A₁₈₉) are bound tightly to cell surface heparin-containing proteoglycans and the extracellular matrix, whereas those lacking the domain are diffusible.^{11,13-15} VEGF-A₁₆₅ which contains only one heparin-binding region encoded by exon 7, is moderately diffusible, and VEGF-A₁₂₁ which lacks the domain totally is highly diffusible (Figure 1B).^{15,16} This results in different contribution of the various isoforms to the process of tumor angiogenesis. The moderately diffusible VEGF-A₁₆₅ was the first VEGF isoform described and is widely considered to be a potent enhancer of vascular permeability and the predominant regulator of angiogenesis. VEGF-A₁₆₅ could fully rescue tumor growth.¹⁷ VEGF-A₁₆₅-induced tumor vasculature consists of irregularly dilated and leaky vessels.¹⁸ In contrast, the longer isoform VEGF-A₁₈₉ which binds to heparin-containing proteoglycans with high affinity contributes more to local blood vessel growth and tumor development in the tumor microenvironment resulting in a highly dense tumor vasculature with small microvessels.¹⁷⁻¹⁹ VEGF-A₁₈₉-induced microvessels penetrate deeply from the tumor rim to the tumor core and function better than VEGF-A₁₆₅-induced microvessels in maintaining the viability of tumors.¹⁹

The highly soluble isoform VEGF-A₁₂₁ functions especially at more distal sites of the tumor.¹⁹ However, conflicting results have been described about the potency of VEGF-A₁₂₁ to induce angiogenesis. It has been suggested that VEGF-A₁₂₁ only co-opts preexisting blood vessels and induces vasodilatation while some studies showed that VEGF₁₂₁ gave rise to much greater angiogenic activity than VEGF-A₁₆₅ or VEGF-A₁₈₉, and indeed increase angiogenesis.^{10, 18, 20-22} VEGF-A₁₂₁ show major defects in mural cell recruitment resulting in immature blood vessels that are fragile and leaky.²³ Important to notice is that these effects of the different VEGF-A isoforms have been studied in mouse models in which just one of the isoforms was overexpressed.^{17-19, 23} However in crude tumor tissue of course all various isoforms are present.

Besides the pro-angiogenic isoforms (VEGF-A_{xxx}a) as described above, alternative 3' splice site selection in exon 8, could also give different C-terminal sequences, resulting in the more recently described anti-angiogenic isoforms (VEGF-A_{xxx}b), where xxx denotes the amino acid number (Figure 1A).²⁴⁻²⁸ In many tumors, a switch is seen from a VEGF-A_{xxx}b-dominated milieu in normal tissue to a proliferative phenotype in which VEGF-A_{xxx}a isoforms dominate.^{24, 26, 29, 30} In addition, the balance of other angiogenic factors including angiopoietins is also disrupted in tumors, leading to abnormal and immature vessels with a chaotic endothelial-cell lining, detached pericytes, and an abnormally thick or thin basement membrane.³¹⁻³³

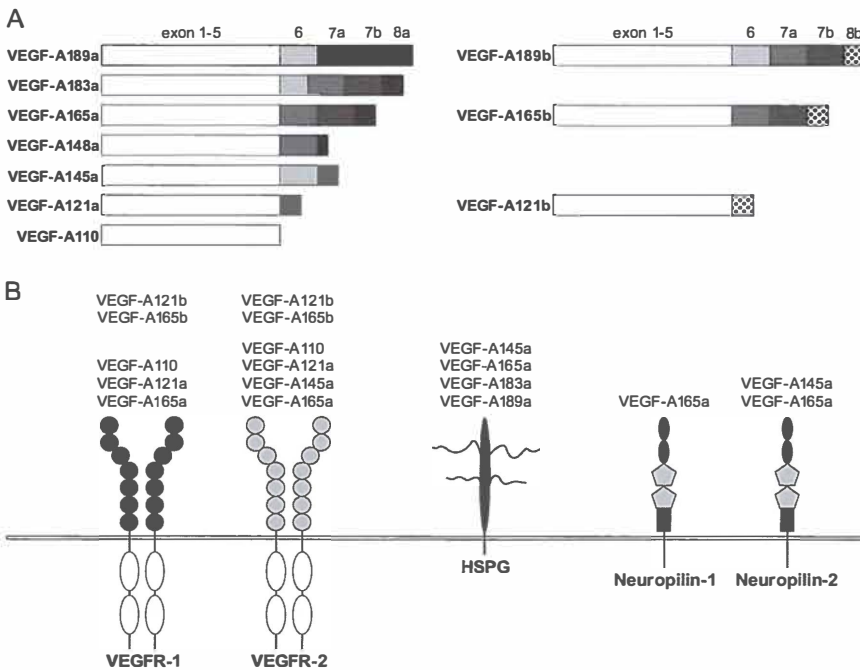


Figure 1. (A) Alternative splicing of the VEGF-A gene gives rise to multiple VEGF-A isoforms. An additional VEGF-A isoform of 110 amino acids results from proteolytic cleavage. Proximal splice-site selection in the terminal exon 8 leads to pro-angiogenic isoforms (VEGF-A_{xxx}a), whereas distal splice site selection gives rise to anti-angiogenic isoforms (VEGF-A_{xxx}b). **(B)** Interaction of pro- and anti-angiogenic VEGF-A isoforms with VEGF receptors (VEGFRs), heparin sulfate proteoglycans (HSPG) and neuropilin receptors.

As each isoform could contribute differently to the process of angiogenesis resulting in differences in blood vessel architecture, this study firstly aimed to analyze various VEGF-A isoforms in correlation with tumor vessel morphology in pediatric pilocytic astrocytoma and adult glioblastoma, as prototype of tumor angiogenesis. Interestingly, it is suggested that anti-angiogenic VEGF-A isoforms contain binding domains for the vast majority of anti-VEGF-A antibodies, including bevacizumab, and therefore inhibiting the effect of these drugs in tumors expressing significant levels of VEGF-A_{xxx}b. Tumors with relatively higher pro- than anti-angiogenic isoform expression will be probably more sensitive to anti-angiogenic therapy.^{30, 34} Because of this possible clinical relevance, we secondly aimed to determine VEGF-A_{xxx}a : VEGF-A_{xxx}b ratios in both tumor types.

Materials and Methods

Patient samples

Tumor tissue was obtained from 15 pediatric patients who were diagnosed with pilocytic astrocytoma in the period 1996-2006 (Table 1) and adults with glioblastoma in 2001-2003 ($n = 12$). Both patient groups were derived from a larger study group of respectively 59 and 62 patients.^{6, 35} However, we only included those patients with sufficient fresh frozen tumor tissue of high quality. Tissue material was histologically evaluated and graded according to WHO classification 2007.¹ Utilization of tumor tissue was approved by the relevant institutional committees (University Medical Center Groningen).

In the glioblastoma study group the median age at diagnosis using MRI or CT was 55.8 years (range 41.6 – 82.0) with a male predominance of 67%. Treatment included partial resection ($n = 5$) or gross total resection ($n = 6$). Nine patients received post-operative radiotherapy (up to a total of 60 Gy). None of the patients received any form of chemotherapy because chemotherapy was not part of the standard treatment for glioblastoma at that time in the Netherlands. The median overall survival time was 221 days with a range of 23 – 372 days. Because of the heterogeneity of both patient groups, no correlations were analyzed between clinical characteristics and biological tumor data.

Real Time RT-PCR of VEGF-A isoforms

Fresh frozen pilocytic astrocytoma ($n = 15$) and glioblastoma tissue ($n = 12$) was used for Real Time RT-PCR of different VEGF-A isoforms. RNA was isolated using RNeasy Mini Kit (Qiagen, Hilden, Germany), and quantified with the Nanodrop ND-1000 UV Spectrophotometer (NanoDrop Technologies, Wilmington, Delaware, USA). cDNA synthesis was performed using RevertAid first strand cDNA synthesis kit (Fermentas, Hanover, Maryland, USA) and again quantified. Real Time RT-PCR was performed in triplicate with SYBR Green Supermix (Bio-Rad Laboratories, Hercules, California, USA) using ABI7900 HT Real-Time sequence detection system in 384-well reaction plates (Applied Biosystems, Foster City, California, USA). Primers were designed with Clone Manager® and used as previously described (Table 2).^{27, 36}

As reference gene, β -actin (forward primer: GCTGTGCTACGTCGCCCTG, reverse: GGAGGAGCTGGAAGCAGCC) was used. TF-1 cells (acute myeloid leukemia cell line) were used as positive control for pro-angiogenic VEGF-A isoforms (VEGF-A_{xxx}a). This cell line was cultured in RPMI 1640 (Lonza) with 10% fetal bovine serum and 100 units/ml penicillin/streptomycin (PAA Laboratories). Fresh frozen healthy kidney tissue functioned as positive control for anti-angiogenic isoforms (VEGF-A_{xxx}b). The ratio between pro- and anti-angiogenic isoforms (VEGF-A_{xxx}a : VEGF-A_{xxx}b ratio) was calculated using the formula $2^{\Delta\text{Ct}}$, in which ΔCt was VEGF-A_{xxx}b ΔCt minus VEGF-A_{xxx}a ΔCt . So a higher VEGF-A_{xxx}a : VEGF-A_{xxx}b ratio corresponds with relatively higher VEGF-A_{xxx}a expression reflecting a more pro-angiogenic status.

Table 1. Patient characteristics of the pilocytic astrocytoma study group ($n = 15$)

Characteristic	<i>n</i> (%)
Gender, male	11 (73)
Tumour localization	
Supratentorial	3 (20)
Optic nerve	7 (47)
Infratentorial	5 (33)
Neurosurgery	
Partial resection	7 (47)
Gross total resection	8 (53)
Chemotherapy	1 (7)
Tumour progression	4 (27)
5-year progression free survival	(50)
Death	1 (7)
5-year survival	(83)
Characteristic	Median (range)
Age at diagnosis, years	11.1 (1.0 – 15.5)
Follow up, years	3.5 (1.1 – 10.8)
Progression free survival, years	3.6 (2.1 – 9.6)

Immunohistochemical analyses of MVD

Microvessel density (MVD) was determined using first the Chalkley point overlap morphometry technique and secondly traditional counting of blood vessels in paraffinic slides.³⁵ The first technique includes an evaluation of double immunohistochemical stained slides for Ki67/CD34 (endothelial cell marker) with the use of an ocular grid with 25 random points (x200 magnification). For each slide, five hot spots were analyzed by turning the ocular grid to maximize the number of overlapping points on the grid and the CD34 stained vessels. Next the mean score per slide was calculated representing the Chalkley score.

For glioblastoma two scores were assessed, both for the perinecrotic and intermediate area. Counting of blood vessels (x200 magnification) was performed in five randomized areas per slide, which were 30 min stained for CD34 with use of the NexES IHC Staining Module (Ventana Medical Systems, Tucson, AZ, USA). Antigen retrieval was performed at 98°C. As described previously, a higher Chalkley score corresponds with larger blood vessels, while CD34 vessel counting represents the number of vessels.⁶

Morphometric evaluation of vessel maturity

Vessel maturity was evaluated by two methods. In collagen IV and Smooth Muscle Actin (SMA) stained slides the fraction of tumor vessels that was covered with respectively basement membrane or pericytes was calculated in five randomized areas per tumor sample (x200 magnification). Furthermore, morphometry was used to analyze the percentage of marker-positive surface area of collagen IV and SMA in six random areas per tumor sample (x200 magnification), with use of the formula: marker-positive area x100/area of the optical field.⁶

During all these analyses of tumor tissue, investigators were blinded to the patient data. Because analyses of the tumor vasculature and different aspects of the angiogenic profile have been performed previously,^{6, 35} we presented the data in correlation with the expression of the diverse VEGF-A isoforms. Results from this subgroup correspond with those derived from the larger, original study group.

Table 2. Primers used for Real Time RT-PCR of VEGF-A isoforms

Isoform	Primer sequence (5'-3')	Product size (bp)
VEGF-A ₁₂₁ a	Forward: GCGGATCAAACCTCACCAAG Reverse: TCGGCTTGTCACATTTTCTTG	116
VEGF-A ₁₂₁ b	Forward: GAAAATCTCTCACCAGGAAA Reverse: CTGGATTAAGGACTGTTCTG	100
VEGF-A ₁₄₅ a	Forward: GAATGCAGACCAAGAAAGATAGAG Reverse: TCGGCTTGTCACATACGCTCC	124
VEGF-A ₁₄₈ a	Forward: GACAAGAAAATCCCTGTGG Reverse: TCGGCTTGTCACATCTTGCAAC	120
VEGF-A ₁₆₅ a	Forward: GAGCAAGACAAGAAAATCCC Reverse: CCTCGGCTTGTCACATCTG	163
VEGF-A ₁₆₅ b	Forward: GAGCAAGACAAGAAAATCCC Reverse: GTGAGAGATCTGCAAGTACG	156
VEGF-A ₁₈₃ a	Forward: GAGATGAGCTTCTACAGCAC Reverse: GGCCACAGGGACGGGATT	134
VEGF-A ₁₈₉ a	Forward: TCCTGGAGCGTTCCTGTG Reverse: CCTCGGCTTGTCACATCTG	158
VEGF-A ₁₈₉ b	Forward: TCCTGGAGCGTTCCTGTG Reverse: GTGAGAGATCTGCAAGTACG	152

Statistical analyses

Statistical analyses were performed with IBM SPSS Statistics 19 software. Because the data had no Gaussian distribution, a Mann-Whitney U-test was used for comparisons between the pilocytic and glioblastoma study group. The nonparametric Spearman correlation test was used to analyze correlations between angiogenic data. For all analyses, a two-tailed P-value of less than 0.05 was considered statistically significant.

Results

Overlapping expression of pro-angiogenic VEGF-A isoforms in pilocytic astrocytoma and glioblastoma

Analyzing the pro-angiogenic VEGF-A isoforms, an overall lower expression level was seen in pilocytic astrocytoma compared with glioblastoma (Figure 2), suggesting possible lower angiogenic activity in pilocytic astrocytoma. However, studying the expression of the various pro-angiogenic isoforms relative to VEGF-A_{165a} as it is predominantly produced in normal cells and tissues under physiological conditions,^{37, 38} interestingly no significant differences were found between both tumors (Figure 3). Pilocytic astrocytoma and glioblastoma both seem to show relatively higher expression of the freely diffusible isoform VEGF-A_{121a} and the longer isoform VEGF-A_{189a} (Figure 2 and 3). In theory, the relative higher expression of these two isoforms would lead to a mixture of large, immature and small, more mature blood vessels.^{19, 23}

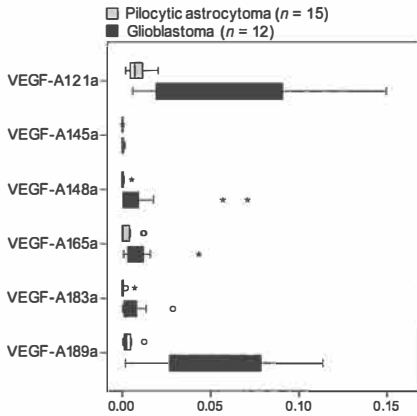


Figure 2. Boxplots showing lower gene expression of various pro-angiogenic VEGF-A isoforms in pilocytic astrocytoma compared with glioblastoma (VEGF-A_{121a}: P < 0.001, VEGF-A_{145a}: P = 0.004, VEGF-A_{148a}: P = 0.004, VEGF-A_{165a}: P = 0.001, VEGF-A_{183a}: P = 0.002, VEGF-A_{189a}: P < 0.001).

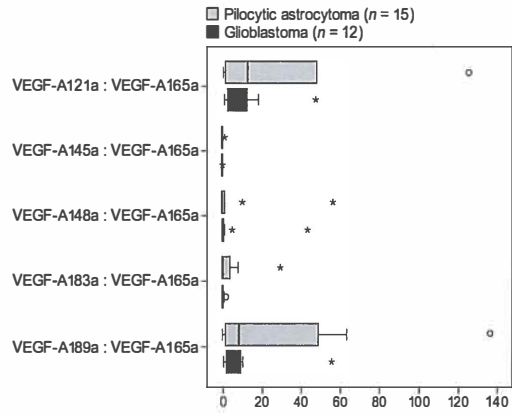


Figure 3. Boxplots showing various pro-angiogenic VEGF-A isoforms relative to VEGF-A_{165a} in pilocytic astrocytoma compared with glioblastoma (VEGF-A_{121a}: P = 0.399; VEGF-A_{145a}: P = 0.905; VEGF-A_{148a}: P = 0.067; VEGF-A_{183a}: P = 0.427; VEGF-A_{189a}: P = 0.614).

Pro-angiogenic VEGF-A isoforms versus vessel architecture in pilocytic astrocytoma and glioblastoma

As described previously, each pro-angiogenic VEGF-A isoform contributes in a unique way to the process of tumor angiogenesis, resulting in differences in vessel architecture. In line with this hypothesis, it has been expected that VEGF-A₁₂₁a and VEGF-A₁₆₅a gives rise to the more dilatated blood vessels in pilocytic astrocytoma, while in glioblastoma VEGF-A₁₈₉a contributes to their characteristic tumor vasculature with a high number of smaller and tortuous vessels. However, in both pilocytic astrocytoma and glioblastoma no significant correlations were found between VEGF-A isoform expression and vessel architecture. Indeed, VEGF-A isoforms do not seem to be the only determining factor in differences in vessel architecture between pilocytic astrocytoma and glioblastoma (Figure 4).

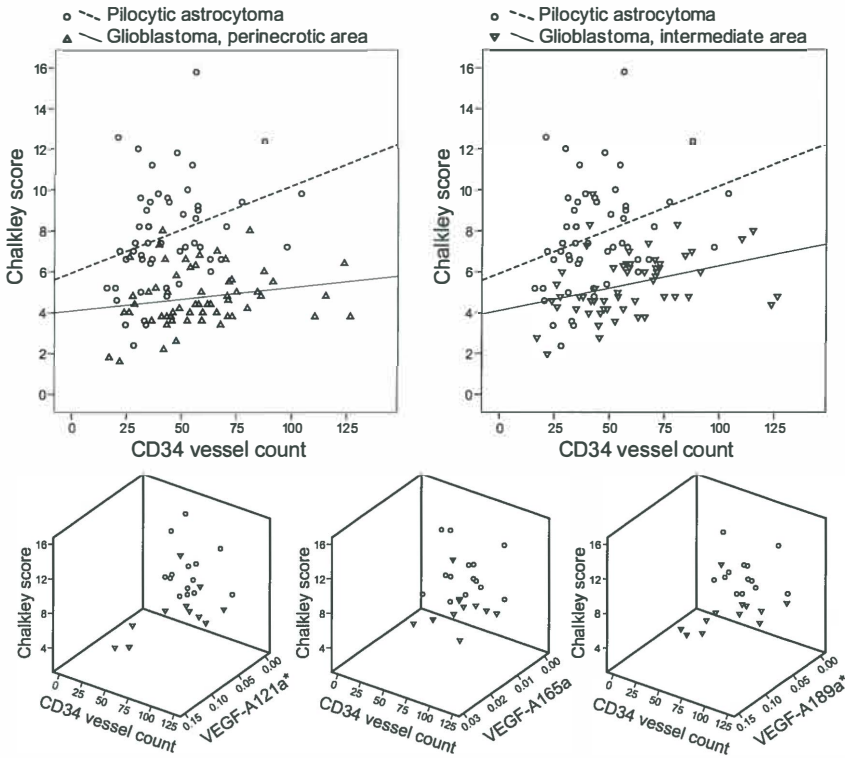


Figure 4. Scatterplots showing that differences in vessel architecture between pilocytic astrocytoma and glioblastoma do not seem to be only determined by expression of pro-angiogenic VEGF-A isoforms. *Exclusion of extreme value (VEGF-A₁₂₁a : 0.78 and VEGF-A₁₈₉a : 0.59).

Correlation between larger isoforms and more blood vessel maturity

Although pro-angiogenic VEGF-A isoforms were not correlated with vessel architecture, in both pilocytic astrocytoma and glioblastoma a clear correlation was seen between larger isoforms which are cell- and extracellular matrix-associated due to moderate heparin-surface glycoprotein interactions and a more mature vasculature.²³ In pilocytic astrocytoma, a positive correlation was found between VEGF-A₁₈₃a, VEGF-A₁₈₉a and the fraction of vessels covered with pericytes, as marker of vessel maturity ($r: 0.714, P = 0.006$; $r: 0.621, P = 0.024$). Taking pilocytic astrocytoma and glioblastoma together in the analyses, as both tumors showed a critical overlap in vessel (im) maturity,⁶ VEGF-A₁₈₉a was also positively correlated with vessels covered with pericytes ($r: 0.526, P = 0.010$).

Overlapping pro- and anti-angiogenic VEGF-A isoform ratios in pilocytic astrocytoma and glioblastoma

A higher VEGF-A_{xxx}a : VEGF-A_{xxx}b ratio corresponds with relatively higher VEGF-A_{xxx}a expression, showing a more pro-angiogenic status. In normal tissue, anti-angiogenic isoforms are dominantly expressed, while in many tumors, a switch is seen towards a dominated pro-angiogenic isoform milieu.^{24, 26, 29} Surprisingly, in both pilocytic astrocytoma and glioblastoma the median VEGF-A₁₂₁ ratio was lower than 1 (Figure 5), possibly reflecting less VEGF-A₁₂₁a expression compared with VEGF-A₁₂₁b. The other ratios showed, as expected, relatively more expression of the pro-angiogenic isoforms of VEGF-A₁₆₅ and VEGF-A₁₈₉. Notably, the ratios between pro- and anti-angiogenic VEGF-A isoforms did not differ significantly between pilocytic astrocytoma and glioblastoma (Figure 5). Especially the VEGF-A₁₆₅a : VEGF-A₁₆₅b and VEGF-A₁₈₉a : VEGF-A₁₈₉b ratios are of crucial interest as it is hypothesized that tumors with relatively more VEGF-A_{xxx}a expression compared with VEGF-A_{xxx}b will be more sensitive to anti-angiogenic therapy. In the present study we provide clues that this might be the case in glioblastoma as well as pilocytic astrocytoma. It is suggested that tumors expressing significant levels of VEGF-A_{xxx}b will be less responsive to VEGF-A antibodies, including bevacizumab, because VEGF-A_{xxx}b inhibits the effect of this anti-VEGF-A antibody.^{30, 34}

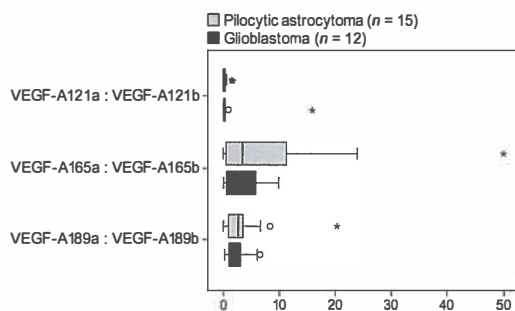


Figure 5. Overlapping VEGF-A isoform ratios between pilocytic astrocytoma and glioblastoma (VEGF-A₁₂₁a : VEGF-A₁₂₁b, $P = 0.829$; VEGF-A₁₆₅a : VEGF-A₁₆₅b, $P = 0.486$, VEGF-A₁₈₉a : VEGF-A₁₈₉b, $P = 0.456$).

Discussion

The present study showed relatively overlapping VEGF-A isoform expression between pediatric pilocytic astrocytoma and adult glioblastoma. VEGF-A isoforms do not seem to be the only determining factor in differences in vessel architecture between pilocytic astrocytoma and glioblastoma, but do correlate with vessel maturity, as longer isoforms were positively correlated with more vessel maturity in both tumors. Furthermore this study distinguished in the expression of VEGF-A isoforms between pro- and anti-angiogenic isoforms which has not been investigated previously in these tumors. Interestingly, a clear overlap was demonstrated between pilocytic astrocytoma and glioblastoma in the pro- and anti-angiogenic VEGF-A isoform ratios with relatively high VEGF-A₁₆₅a and VEGF-A₁₈₉a expression, suggesting possibilities for anti-angiogenic therapy not only in glioblastoma, but also in pilocytic astrocytoma.

So pilocytic astrocytoma seems to be more similar to the extensively studied glioblastoma, as probably has been thought. Firstly, analyses of the different pro-angiogenic VEGF-A isoforms (VEGF-A₁₂₁a, _{145'} _{148'} _{183'} _{189'}) relative to VEGF-A₁₆₅a as it is predominantly expressed in brain under normal physiological conditions,³⁸ showed no significant differences between both pilocytic astrocytoma and glioblastoma. These findings correspond with the observations in our previous study in which pilocytic astrocytoma showed overlapping VEGF-A expression with glioblastoma using immunohistochemistry.⁶ While under normal physiological conditions only low levels of VEGF-A₁₂₁a are observed in brain,³⁸ both pilocytic astrocytoma and glioblastoma showed relatively high VEGF-A₁₂₁a expression, suggesting a shift from VEGF-A₁₆₅a toward VEGF-A₁₂₁a as has been also described in prostate cancer.³⁹ VEGF-A₁₂₁a is also upregulated in colon cancer, where it is hypothesized to play an important role in this proliferative, angiogenic process due to its bioavailability.¹⁴ Furthermore it has been discussed whether during malignant progression an angiogenic switch favoring the shorter diffusible isoforms occurs, for example in lung cancer.⁴⁰ Our study does not support this hypothesis for brain tumors as both low and high grade glioma showed high VEGF-A₁₂₁a expression, followed by relatively high expression of VEGF-A₁₈₉a, one of the longer isoforms.

The relatively high expression of these two isoforms was not associated with characteristics in tumor vessel architecture. The present study showed that the interplay between the various VEGF-A isoforms does not seem to be the sole explanation for differences in vessel architecture between pilocytic astrocytoma with dilatated blood vessels and glioblastoma with their highly dense tumor vasculature and small microvessels. In both tumors no significant correlation were found as has been showed in previous studies in which just one of the isoforms was overexpressed. These mouse models give insight into the specific isoform induced tumor vasculature.^{17-19, 23} However, the influence of possible interactions between diverse isoforms on the vessel architecture is less clear, and plays probably a role in the present study.

Nevertheless, the VEGF-A isoforms are only one of the mechanisms that could influence vessel architecture, besides for example the angiotensin/Tie-2 system which has been described as a potent regulator of blood vessel enlargement.^{41,42} Remarkable in clinical practice is the overlapping signal intensity of gadolinium-based dynamic contrast-enhanced MRI between the low grade pilocytic astrocytoma and glioblastoma. As it has been described that the signal intensity is both dependent on vessel density and vessel caliber,^{43,44} the wide blood vessels in pilocytic astrocytoma probably contribute to this high intensity while in glioblastoma it seems to be due to their higher number of smaller vessels.

Another finding in which pilocytic astrocytoma showed their similarity with glioblastoma, has been showed by a positive correlation between longer VEGF-A isoforms and vessel maturity in both tumors. The affinity of the VEGF isoforms to bind heparin has an overall effect on isoform spatial distribution; these variations then determine whether blood-vessel growth is organized and directed, or disordered.^{15, 16, 18} VEGF-A₁₈₉a for example is associated with a much more mature vasculature, showing good levels of pericyte coverage and less hemorrhage, while VEGF-A₁₂₁a show major defects in mural cell recruitment resulting in immature blood vessels that are fragile and leaky.²³ In line with literature, the longer isoforms VEGF-A₁₈₃a and VEGF-A₁₈₉a were positively correlated with the fraction of vessel covered with pericytes. The protein product of VEGF-A₁₈₃a is six amino acids shorter than VEGF-A₁₈₉a as a consequence of an alternative splicing event within exon 6a.⁴⁵

Furthermore, in both pilocytic astrocytoma and glioblastoma VEGF-A₁₂₁a was highly expressed, however surprisingly the anti-angiogenic isoform VEGF-A₁₂₁b expression exceeded the expression of the pro-angiogenic isoform. For VEGF-A₁₆₅ and VEGF-A₁₈₉ relatively higher expression of the pro-angiogenic isoforms were found in both tumors, although the ratio was variable with some patients having no excess of VEGF-A_{xxx}a and others with high excess of VEGF-A_{xxx}a, a previously described phenomenon in colon cancer.³⁰ Overall, the effect of a shift from anti-angiogenic VEGF isoform expression under normal physiological conditions to pro-angiogenic expression in cancer is due to a combination of reduced VEGF-A_{xxx}b expression and increased VEGF-A_{xxx}a expression.^{24, 26, 29, 30} The anti-angiogenic isoforms VEGF-A₁₂₁b and VEGF-A₁₆₅b bind even as VEGF-A₁₂₁a and VEGF-A₁₆₅a, to the conventional VEGFRs (Figure 1B), however resulting in inhibition of the process of angiogenesis.^{26, 29, 46} So, the replacement of the terminal six amino acids with those coded by exon 8b is of crucial importance in converting the dominant pro-angiogenic growth factor into a positively anti-angiogenic molecule. Interestingly, while equal binding affinity is seen between VEGF-A_{xxx}a and VEGF-A_{xxx}b to VEGFR-2,^{26, 29} VEGF-A_{xxx}b is not simply a classical competitive inhibitor. VEGF-A₁₆₅b for example does stimulate the phosphorylation of VEGFR-2 but qualitatively in a unique way; VEGF-A₁₆₅b is considerably poorer than VEGF-A₁₆₅a in inducing phosphorylation of the angiogenic positive regulatory site in VEGFR-2.^{29, 47} Moreover contrary to VEGF-A₁₆₅a, the anti-angiogenic isoform is unable to bind the co-receptor neuropilin, contributing to the lack of angiogenic properties of VEGF-A₁₆₅b.⁴⁷

Similarly, VEGF-A₁₂₁b and VEGF-A₁₈₉b are expected to prevent angiogenesis, although VEGF-A₁₂₁ binds VEGFRs with lower receptor affinity than that of VEGF-A₁₆₅¹⁴ and the VEGF-A₁₈₉ isoform does not bind VEGFRs at all, but is available for cleavage by plasmin and subsequent release in the soluble form, VEGF-A₁₁₀ which binds VEGFRs.^{15,48} However, Catena et al suggested a weak angiogenic instead of anti-angiogenic function of VEGF-A₁₂₁b, showing in VEGF-A₁₂₁b-overexpressing tumors a significant increase in angiogenesis compared with controls and VEGF-A₁₆₅b-overexpressing tumors.⁴⁹ Furthermore, the observations that VEGF-A₁₂₁b seems to act as a survival factor for endothelial cells²⁶ and the present study demonstrating a relatively high VEGF-A₁₂₁b expression compared with VEGF-A₁₂₁a in both pilocytic astrocytoma and glioblastoma, emphasized the complexity of the VEGF-A isoform biology and the carefulness of the interpretation of the results. Finally, of particular interest is that the balance between pro- and anti-angiogenic isoforms seems to affect the sensitivity of tumors to anti-angiogenic drugs including bevacizumab. It was demonstrated that VEGF-A₁₆₅b binds to bevacizumab with similar affinity as VEGF-A₁₆₅a, and inhibits the bevacizumab effect on tumor growth. No effect of bevacizumab was seen in tumors expressing predominantly VEGF-A₁₆₅b.^{30,34} As we showed a crucial overlap in relatively more VEGF-A₁₆₅a and VEGF-A₁₈₉a expression between pilocytic astrocytoma and glioblastoma and as encouraging results were described with bevacizumab in glioblastoma,⁵⁰ pilocytic astrocytoma could also be suitable for anti-angiogenic therapy. In theory, especially patients with unresectable tumors and a high VEGF-A_{xxx}a : VEGF-A_{xxx}b ratio could possible benefit of bevacizumab. As such, morbidity and mortality in children with pilocytic astrocytoma could be reduced. In the future, combining multiple anti-angiogenic strategies will be of increasingly importance.

Acknowledgements

This work was supported by a grant from Jan Kornelis de Cock Stichting (project code 09-58 to M. Sie).

References

1. Louis DN, Ohgaki H, Wiestler OD, Cavenee WK. Classification of tumours of the central nervous system. 4th ed. Lyon: IARC; 2007.
2. Fernandez C, Figarella-Branger D, Girard N, et al. Pilocytic astrocytomas in children: prognostic factors - a retrospective study of 80 cases. *Neurosurgery*. 2003;53:544-553.
3. Dirven CM, Mooij JJ, Molenaar WM. Cerebellar pilocytic astrocytoma: a treatment protocol based upon analysis of 73 cases and a review of the literature. *Childs Nerv Syst*. 1997;13:17-23.
4. Kestle J, Townsend JJ, Brockmeyer DL, Walker ML. Juvenile pilocytic astrocytoma of the brainstem in children. *J Neurosurg*. 2004;101:1-6.
5. Packer RJ, Jakacki R, Horn M, et al. Objective response of multiply recurrent low-grade gliomas to bevacizumab and irinotecan. *Pediatr Blood Cancer*. 2009;52:791-795.
6. Sie M, de Bont ES, Scherpen FJ, Hoving EW, den Dunnen WF. Tumour vasculature and angiogenic profile of paediatric pilocytic astrocytoma; is it much different from glioblastoma? *Neuropathol Appl Neurobiol*. 2010;36:636-647.
7. Carmeliet P and Jain RK. Angiogenesis in cancer and other diseases. *Nature*. 2000;407:249-257.
8. Dvorak HF. Angiogenesis: update 2005. *J Thromb Haemost*. 2005;3:1835-1842.
9. Jain RK, di Tomaso E, Duda DG, Loeffler JS, Sorensen AG, Batchelor TT. Angiogenesis in brain tumours. *Nat Rev Neurosci*. 2007;8:610-622.
10. Sonoda Y, Kanamori M, Deen DF, Cheng SY, Berger MS, Pieper RO. Overexpression of vascular endothelial growth factor isoforms drives oxygenation and growth but not progression to glioblastoma multiforme in a human model of gliomagenesis. *Cancer Res*. 2003;63:1962-1968.
11. Hoeben A, Landuyt B, Highley MS, Wildiers H, Van Oosterom AT, De Bruijn EA. Vascular endothelial growth factor and angiogenesis. *Pharmacol Rev*. 2004;56:549-580.
12. Dvorak HF. Vascular permeability factor/vascular endothelial growth factor: a critical cytokine in tumor angiogenesis and a potential target for diagnosis and therapy. *J Clin Oncol*. 2002;20:4368-4380.
13. Neufeld G, Cohen T, Gengrinovitch S, Poltorak Z. Vascular endothelial growth factor (VEGF) and its receptors. *FASEB J*. 1999;13:9-22.
14. Woolard J, Bevan HS, Harper SJ, Bates DO. Molecular diversity of VEGF-A as a regulator of its biological activity. *Microcirculation*. 2009;16:572-592.
15. Houck KA, Leung DW, Rowland AM, Winer J, Ferrara N. Dual regulation of vascular endothelial growth factor bioavailability by genetic and proteolytic mechanisms. *J Biol Chem*. 1992;267:26031-26037.
16. Park JE, Keller GA, Ferrara N. The vascular endothelial growth factor (VEGF) isoforms: differential deposition into the subepithelial extracellular matrix and bioactivity of extracellular matrix-bound VEGF. *Mol Biol Cell*. 1993;4:1317-1326.
17. Grunstein J, Masbad JJ, Hickey R, Giordano F, Johnson RS. Isoforms of vascular endothelial growth factor act in a coordinate fashion to recruit and expand tumor vasculature. *Mol Cell Biol*. 2000;20:7282-7291.
18. Kusters B, de Waal RM, Wesseling P, et al. Differential effects of vascular endothelial growth factor A isoforms in a mouse brain metastasis model of human melanoma. *Cancer Res*. 2003;63:5408-5413.
19. Yuan A, Lin CY, Chou CH, et al. Functional and structural characteristics of tumor angiogenesis in lung cancers overexpressing different VEGF isoforms assessed by DCE- and SSCE-MRI. *PLoS One*. 2011;6:e16062.
20. Guo P, Xu L, Pan S, et al. Vascular endothelial growth factor isoforms display distinct activities in promoting tumor angiogenesis at different anatomic sites. *Cancer Res*. 2001;61:8569-8577.

21. Ruhrberg C, Gerhardt H, Golding M, et al. Spatially restricted patterning cues provided by heparin-binding VEGF-A control blood vessel branching morphogenesis. *Genes Dev.* 2002;16:2684-2698.
22. Zhang HT, Scott PA, Morbidelli L, et al. The 121 amino acid isoform of vascular endothelial growth factor is more strongly tumorigenic than other splice variants in vivo. *Br J Cancer.* 2000;83:63-68.
23. Tozer GM, Akerman S, Cross NA, et al. Blood vessel maturation and response to vascular-disrupting therapy in single vascular endothelial growth factor-A isoform-producing tumors. *Cancer Res.* 2008;68:2301-2311.
24. Bates DO, Cui TG, Doughty JM, et al. VEGF165b, an inhibitory splice variant of vascular endothelial growth factor, is down-regulated in renal cell carcinoma. *Cancer Res.* 2002;62:4123-4131.
25. Cui TG, Foster RR, Saleem M, et al. Differentiated human podocytes endogenously express an inhibitory isoform of vascular endothelial growth factor (VEGF165b) mRNA and protein. *Am J Physiol Renal Physiol.* 2004;286:F767-73.
26. Rennel ES, Varey AH, Churchill AJ, et al. VEGF(121)b, a new member of the VEGF(xxx)b family of VEGF-A splice isoforms, inhibits neovascularisation and tumour growth in vivo. *Br J Cancer.* 2009;101:1183-1193.
27. Miller-Kasprzak E and Jagodzinski PP. 5-Aza-2'-deoxycytidine increases the expression of anti-angiogenic vascular endothelial growth factor 189b variant in human lung microvascular endothelial cells. *Biomed Pharmacother.* 2008;62:158-163.
28. Perrin RM, Konopatskaya O, Qiu Y, Harper S, Bates DO, Churchill AJ. Diabetic retinopathy is associated with a switch in splicing from anti- to pro-angiogenic isoforms of vascular endothelial growth factor. *Diabetologia.* 2005;48:2422-2427.
29. Woolard J, Wang WY, Bevan HS, et al. VEGF165b, an inhibitory vascular endothelial growth factor splice variant: mechanism of action, in vivo effect on angiogenesis and endogenous protein expression. *Cancer Res.* 2004;64:7822-7835.
30. Varey AH, Rennel ES, Qiu Y, et al. VEGF 165 b, an antiangiogenic VEGF-A isoform, binds and inhibits bevacizumab treatment in experimental colorectal carcinoma: balance of pro- and antiangiogenic VEGF-A isoforms has implications for therapy. *Br J Cancer.* 2008;98:1366-1379.
31. Jain RK. Molecular regulation of vessel maturation. *Nat Med.* 2003;9:685-693.
32. Fukumura D, Duda DG, Munn LL, Jain RK. Tumor microvasculature and microenvironment: novel insights through intravital imaging in pre-clinical models. *Microcirculation.* 2010;17:206-225.
33. Wagemakers M, Sie M, Hoving EW, Molema G, de Bont ES, den Dunnen WF. Tumor vessel biology in pediatric intracranial ependymoma. *J Neurosurg Pediatr.* 2010;5:335-341.
34. Harper SJ and Bates DO. VEGF-A splicing: the key to anti-angiogenic therapeutics? *Nat Rev Cancer.* 2008;8:880-887.
35. Sie M, Wagemakers M, Molema G, Mooij JJ, de Bont ES, den Dunnen WF. The angiopoietin 1/angiopoietin 2 balance as a prognostic marker in primary glioblastoma multiforme. *J Neurosurg.* 2009;110:147-155.
36. Kruizinga RC, de Jonge HJ, Kampen KR, Walenkamp AM, de Bont ES. Vascular Endothelial Growth Factor A isoform mRNA expression in pediatric acute myeloid leukemia. *Pediatr Blood Cancer.* 2011;56:294-297.
37. Ferrara N, Houck KA, Jakeman LB, Winer J, Leung DW. The vascular endothelial growth factor family of polypeptides. *J Cell Biochem.* 1991;47:211-218.
38. Bacic M, Edwards NA, Merrill MJ. Differential expression of vascular endothelial growth factor (vascular permeability factor) forms in rat tissues. *Growth Factors.* 1995;12:11-15.
39. Catena R, Muniz-Medina V, Moralejo B, et al. Increased expression of VEGF121/VEGF165-189 ratio results in a significant enhancement of human prostate tumor angiogenesis. *Int J Cancer.* 2007;120:2096-2109.

40. Zygalki E, Tsaroucha EG, Kaklamanis L, Lianidou ES. Quantitative real-time reverse transcription PCR study of the expression of vascular endothelial growth factor (VEGF) splice variants and VEGF receptors (VEGFR-1 and VEGFR-2) in non small cell lung cancer. *Clin Chem*. 2007;53:1433-1439.
41. Cho CH, Kim KE, Byun J, et al. Long-term and sustained COMP-Ang1 induces long-lasting vascular enlargement and enhanced blood flow. *Circ Res*. 2005;97:86-94.
42. Thurston G, Wang Q, Baffert F, et al. Angiopoietin 1 causes vessel enlargement, without angiogenic sprouting, during a critical developmental period. *Development*. 2005;132:3317-3326.
43. Veeravagu A, Hou LC, Hsu AR, et al. The temporal correlation of dynamic contrast-enhanced magnetic resonance imaging with tumor angiogenesis in a murine glioblastoma model. *Neurol Res*. 2008;30:952-959.
44. Barbier EL, Lamalle L, Decorsp M. Methodology of brain perfusion imaging. *J Magn Reson Imaging*. 2001;13:496-520.
45. Jingjing L, Xue Y, Agarwal N, Roque RS. Human Muller cells express VEGF183, a novel spliced variant of vascular endothelial growth factor. *Invest Ophthalmol Vis Sci*. 1999;40:752-759.
46. Cebe Suarez S, Pieren M, Cariolato L, et al. A VEGF-A splice variant defective for heparan sulfate and neuropilin-1 binding shows attenuated signaling through VEGFR-2. *Cell Mol Life Sci*. 2006;63:2067-2077.
47. Kawamura H, Li X, Harper SJ, Bates DO, Claesson-Welsh L. Vascular endothelial growth factor (VEGF)-A165b is a weak in vitro agonist for VEGF receptor-2 due to lack of coreceptor binding and deficient regulation of kinase activity. *Cancer Res*. 2008;68:4683-4692.
48. Keyt BA, Berleau LT, Nguyen HV, et al. The carboxyl-terminal domain (111-165) of vascular endothelial growth factor is critical for its mitogenic potency. *J Biol Chem*. 1996;271:7788-7795.
49. Catena R, Larzabal L, Larrayoz M, et al. VEGF121b and VEGF165b are weakly angiogenic isoforms of VEGF-A. *Mol Cancer*. 2010;9:320.
50. Vredenburgh JJ, Desjardins A, Herndon JE, 2nd, et al. Bevacizumab plus irinotecan in recurrent glioblastoma multiforme. *J Clin Oncol*. 2007;25:4722-4729.



Chapter 7

Less tumor engraftment after anti-VEGF therapy in pediatric low grade astrocytoma

Mariska Sie¹

Arend H. Sikkema¹

Frank J.G. Scherpen¹

Arja ter Elst¹

Kim R. Kampen¹

Eelco W. Hoving³

Wilfred F.A. den Dunnen²

Eveline S.J.M. de Bont¹

¹ Department of Pediatrics, Beatrix Children's Hospital, Pediatric Oncology/Hematology division

² Department of Pathology and Medical Biology, Pathology division

³ Department of Neurosurgery

University Medical Center Groningen, University of Groningen, Groningen, the Netherlands

Proceedings of the AACR 2013 (abstract)

Pediatric low grade astrocytoma mouse models

Up to now, two spontaneous low grade astrocytoma mouse models have been described. The first *in vivo* model was developed based on the neurofibromatosis-1 associated optic glioma in young children.¹ So a genetically engineered mouse model of neurofibromatosis-1 was developed in which optic low grade glioma arise.² Secondly, a mouse model was developed in which a BRAF kinase domain was activated to induce pilocytic astrocytoma.³ Besides these induced murine tumor models, no pediatric low grade astrocytoma xenograft mouse model have been described. To further investigate the possible therapeutic window for anti-angiogenic therapy in pediatric low grade astrocytoma, we performed the following study which is published in abstract form.

Abstract

Introduction: Low grade astrocytomas are the most frequent brain tumors in children. Although some children benefit from traditional treatments including neurosurgery, chemotherapy and radiotherapy, still children die due to tumor progression. Furthermore, morbidity can be serious. So new therapeutic strategies are warranted for these patients. Vascular endothelial growth factor (VEGF), the most critical angiogenic factor may be a potential therapeutic target. The present study aimed to analyze the effect of VEGF inhibition *in vitro* and *in vivo* in pediatric low grade astrocytoma. **Materials and methods:** Three different pediatric low grade astrocytoma cell lines were used: Res-186 (WHO grade I astrocytoma), Res-259 and UW-467 (WHO grade II astrocytoma). Effects *in vitro* of the anti-VEGF monoclonal antibodies, bevacizumab (Avastin®, anti human VEGF) and B20-4.1.1 (anti human and mouse VEGF) were studied using a WST-1 cell viability assay and a cell proliferation assay with BRDU. Furthermore an intracranial pediatric low grade astrocytoma mouse model was developed in which Res-259 cells were orthotopically implanted in NOD-scid IL2Rg^{null} mice. After 6 weeks treatment intraperitoneal twice weekly with bevacizumab 15 mg/kg, B20-4.1.1 5 mg/kg or phosphate buffered saline as control group, mice were euthanized and tumor engraftment was studied in brain slides using Aperio's imagescope viewer.

Results: As expected, no effects were seen of anti-VEGF on pediatric low grade astrocytoma cell viability and cell proliferation. However *in vivo* results showed less tumor engraftment in bevacizumab ($n = 10$, 70%) and B20-4.1.1 ($n = 9$, 44%) treated mice compared with the control group ($n = 10$) in which in all mice tumor engraftment was observed. In contrast with bevacizumab which did not show significantly lower tumor mass compared with control ($P = 0.062$), in B20-4.1.1 treated mice significantly lower tumor mass was determined ($P = 0.001$).

Conclusion(s): This study showed less tumor engraftment after anti-VEGF therapy in a newly developed pediatric low grade astrocytoma mouse model. In these tumors anti-VEGF seems to work especially on tumor microenvironment. Suggesting that anti-VEGF could have a potential role in the therapeutic strategy for children with low grade astrocytoma, thoughtfulness on possible tumor escape mechanisms that may arise will be crucial.

Acknowledgements

This work was supported by a grant from Jan Kornelis de Cock Stichting (project code 11-66 to M. Sie) and the Ubbo Emmius Foundation-Junior Scientific Masterclass (UEF-JSM) Van der Meer-Boerema Stichting Talent Grant (project code UEF008 to M. Sie).

References

1. Listernick R, Ferner RE, Liu GT, Gutmann DH. Optic pathway gliomas in neurofibromatosis-1: controversies and recommendations. *Ann Neurol* 2007;61:189-198.
2. Hegedus B, Banerjee D, Yeh TH, et al. Preclinical cancer therapy in a mouse model of neurofibromatosis-1 optic glioma. *Cancer Res* 2008;68:1520-1528.
3. Gronych J, Korshunov A, Bageritz J, et al. An activated mutant BRAF kinase domain is sufficient to induce pilocytic astrocytoma in mice. *J Clin Invest* 2011;121:1344-1348.



Chapter 8

Growth-factor-driven rescue to RTK inhibitors in pediatric low grade astrocytoma and ependymoma

Mariska Sie¹

Wilfred F.A. den Dunnen²

Harm Jan Lourens¹

Tiny G.J. Meeuwssen-de Boer¹

Frank J.G. Scherpen¹

Kim R. Kampen¹

Eelco W. Hoving³

Eveline S.J.M. de Bont¹

¹ Department of Pediatrics, Beatrix Children's Hospital, Pediatric Oncology/Hematology division

² Department of Pathology and Medical Biology, Pathology division

³ Department of Neurosurgery

University Medical Center Groningen, University of Groningen, Groningen, the Netherlands

Mol Cancer Res; manuscript submitted

Abstract

It has been shown that single targeted kinase inhibition failed due to tumor resistance mechanisms. The present study will extend our previous observations that vascular endothelial growth receptor (VEGFR) 2, platelet derived growth factor receptor (PDGFR) β , Src, the epidermal growth factor receptor (ErbB) family, and hepatocyte growth factor receptor (HGFR/cMet) are potential drugable targets in low grade astrocytoma and ependymoma with investigations concerning growth-factor-driven resistance. This rescue mechanism was investigated in pediatric low grade astrocytoma and ependymoma cell lines treated with receptor tyrosine kinase (RTK) inhibitors *e.g.* sorafenib, dasatinib, canertinib and crizotinib. In the present study, flow cytometry analyses were performed showing high expression of VEGFR-1, fibroblast growth factor receptor (FGFR) 1, ErbB-1, HGFR and recepteur d'origine nantais (RON) and their respective inhibitors showed induced decrease of tumor cell viability, measured with WST-1 cell viability assays. EGF, HGF and FGF, which are normally expressed in brain (tumor) tissue, showed to be effective rescue inducing growth factors resulting in increased cell survival especially during treatment with dasatinib or sorafenib. Growth-factor-driven rescue was less prominent when canertinib or crizotinib were used. Rescue was underscored by activating downstream Akt and/or Erk phosphorylation. Combination treatment showed to be able to overcome the growth-factor-driven resistance. In conclusion, our study highlights the extensive importance of environmentally present growth factors in developing resistance mechanisms towards RTK inhibitors. It is of great interest to anticipate upon these results for the design of new therapeutic trials with RTK inhibitors in pediatric low grade astrocytoma and ependymoma.

Introduction

Low grade astrocytomas (WHO grade I-II) are the most frequent brain tumors in children. Ependymoma (WHO grade II-III) accounts for 6-12% of all pediatric brain tumors and is the fourth most common brain tumor in children.¹ Although the 5-year survival of patients with pilocytic astrocytoma is around 90%, morbidity can be serious mainly because of the tumor localization and the change of surgical morbidity.^{2, 3} Moreover, despite developments in neurosurgery, chemotherapy and radiation, the 5-year survival of pediatric ependymoma is approximately 57%.⁴ Therefore, a search for new targeted therapies has started. With kinome profiling we previously identified vascular endothelial growth factor receptor 2 (VEGFR-2), platelet derived growth factor receptor β (PDGFR β), Src, the epidermal growth factor receptor family (ErbB1-4), and hepatocyte growth factor receptor (HGFR/cMet) as potential drugable targets in these brain tumors.⁵ Potential interesting inhibitors for these targets are sorafenib, dasatinib, canertinib and crizotinib respectively (Figure 1). Today, still very limited data is published about the clinical use of inhibitors targeting these receptor tyrosine kinases (RTKs) in pediatric brain tumors, and even less is known in low grade astrocytoma and ependymoma.

Although in chronic myeloid leukemia, single kinase targeted therapy, for oncogenic activated BCR/ Abl has proven successful,⁶ more recent trials failed to show prolonged responses. The first results of single receptor tyrosine kinase targeted tumor therapies are disappointing. It is thought that tumor progression is the net result of signaling through various protein kinase mediated networks driving tumor cell proliferation and survival. The signaling networks can be reflected by oncogenic mutations, silencing tumor suppressor mutations, epigenetic changes and stromal interaction, such as angiogenesis. Important growth factors that can bind RTKs in brain tumors mediating tumor cell survival include VEGF, EGF, HGF, FGF and PDGF. Altogether these changes result in specific signaling profiles which promote tumor cell growth (Figure 1).

It has been shown that single targeted kinase inhibition failed due to tumor resistance mechanisms through alternate routes of kinase pathway activation. For example, RTK upregulation has been observed following targeted inhibition of selective kinases. This kinome reprogramming circumvents inhibition of proto-oncogenic kinases as for instance described for oncogenic RAS.⁷ Furthermore, inhibition of specific RTKs could trigger the tumor to upregulate RTK ligands, through autocrine tumor-cell production, paracrine contribution from tumor stroma or systemic production, eventually contributing to tumor resistance to the RTK inhibitor with a similar signaling output as shown recently by Wilson in oncogenic mutated cell lines.⁸ The present study will extend our previous observations that VEGFR-2, PDGFR β , Src, ErbB family, and HGFR/cMet are potential drugable targets in low grade astrocytoma and ependymoma, with investigations concerning growth-factor-driven resistance in pediatric low grade astrocytoma and ependymoma treated with RTK inhibitors *e.g.* sorafenib, dasatinib, canertinib and crizotinib.

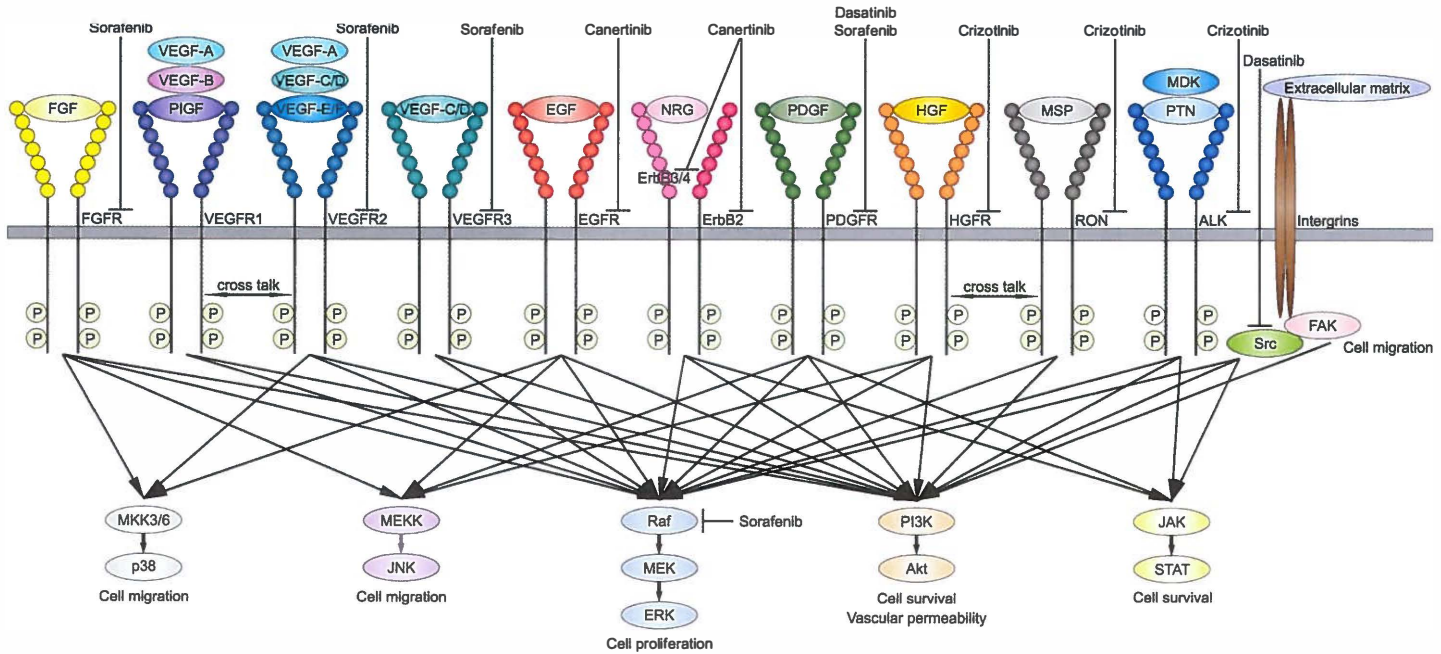


Figure 1. Schematic illustration showing important growth factors in brain tumors that can bind RTKs activating downstream pathways which contributes to tumor cell survival. These potential drugable targets can be inhibited by e.g. sorafenib, dasatinib, canertinib and crizotinib.

Materials and methods

Cell culture

Three pediatric low grade astrocytoma cell lines (WHO grade I: Res-186, grade II: Res-259 and UW-467) and one ependymoma cell line were evaluated (Res-196; Dr. Michael S. Bobola, Seattle Children's Hospital Research Institute, USA).⁹ All cell lines were cultured in DMEM/F12 (Life Technologies, Carlsbad, CA, USA) containing 5% fetal calf serum (FCS). Cell cultures contained 100 units/ml penicillin and 100 ul/ml streptomycin (PAA Laboratories, Les Mureaux, France).

Flow cytometry analyses

Cells were blocked by PBS 1% BSA (Bovine Serum Albumin, Sigma Aldrich, St Louis, MO, USA), and stained with anti-VEGFR-1 (Sigma Aldrich), anti-VEGFR-2-PE (Sigma Aldrich), anti-VEGFR-3-APC (R&D Systems, Minneapolis, MN, USA), anti-EGFR (Abcam, Cambridge, UK), anti-ErbB2-PE (R&D Systems), anti-ErbB3-APC (R&D Systems), anti-ErbB4 (R&D Systems), anti-HGFR/cMet-FITC (R&D Systems), anti-RON-APC (R&D Systems), anti-FGFR-1 (Cell Signaling, Danvers, MA, USA), anti-FGFR-2 (R&D Systems), anti-PDGFR α -biotin (BD Biosciences, San Jose, CA, USA), anti-PDGFR β -PE (BD Biosciences). Primary FGFR-2, ErbB4 antibodies were visualized using a Rabbit anti-Mouse PE-conjugated secondary antibody (Dako Cytomation, Glostrup, Denmark), and FGFR-1 with a FITC-conjugated Swine anti-Rabbit secondary antibody (Dako Cytomation). Primary EGFR was visualized using Alexa Fluor 488 conjugated anti-Rat secondary antibody (Cell Signaling) and PDGFR α antibody was visualized using streptavidin FITC (BD Biosciences). IgG-FITC/PE/APC and secondary antibodies were used as negative (isotype) controls. Expression was analyzed using LSRII (BD FACS DIVA software, BD Biosciences). The data was eventually developed using FlowJo software (Tree Star Inc., Ashland, OR, USA). Expression levels above 5% were considered as actual membrane protein expression, reaching above isotype controls.

Cell viability assays

WST-1 colorimetric viability assays were performed following the protocol described by the manufacturer (Roche, Basel, Switzerland). Cells were seeded in 96-wells plates at a density of 15 x 10³ per well in medium (1% FCS) and after adhesion treated with sorafenib (0 – 8 μ M), dasatinib (0 – 1000 nM), canertinib (0 – 10 μ M) or crizotinib (0 – 12 μ M) for 48h. Sorafenib, dasatinib, canertinib and crizotinib (LC laboratories, Woburn MA, USA) were dissolved in sterile dimethyl sulfoxide (DMSO) and stored at -20 °C. Growth factors including VEGF-A, EGF human, HGF human, FGF basic, PDGF-AB (all 100 ng/ml, Life Technologies) were added 1h after incubation by the inhibitor. After addition of the WST-1 cell survival reagent the absorbance was measured at 450 nm in a microplate reader (Bio-Rad Laboratories, Hercules, CA, USA). In every assay, per inhibitor, each concentration contains equal concentrations of DMSO. For each concentration 6 replicates were included. Similar conditions were maintained for different combination treatments.

Western blot analyses

1 x 10⁶ cells were seeded in T25 flasks in 5 ml DMEM-F12 containing 1% FCS to which after adhesion sorafenib 8 μ M, dasatinib 1 μ M, canertinib 8 μ M or crizotinib 9 μ M was added. In the combination treatments, the second inhibitor was added at a lower concentration: sorafenib 2 μ M, canertinib 4 μ M or crizotinib 3 μ M. After 1h, growth factors including VEGF-A, EGF, HGF, FGF or PDGF (all 100 ng/ml, Life Technologies) were added for another 1h. Cells were lysed in laemmli sample buffer (Bio-Rad Laboratories). Proteins were separated by sodium dodecyl sulfate-polyacrylamide gel electrophoresis (SDS-PAGE), and transported to nitrocellulose membranes. First, the membranes were incubated overnight with monoclonal primary antibodies for phospho-Erk (pErk) and total Erk (tErk), pAkt and tAkt, actin (Cell Signaling), followed by 1 hour incubation with HRP conjugated secondary antibodies (Dako Cytomation). Protein bands were visualized by chemiluminescence, on an x-ray film. Actin was used as loading control.

Results

EGF, HGF and FGF driven rescue to various RTK inhibitors

Pediatric low grade astrocytoma and ependymoma cell lines showed high expression of VEGFR-1, FGFR-1, EGFR, HGFR and RON (Figure 2A). Their respective inhibitors showed inhibitor induced decrease of tumor cell viability (Figure 2B). Effect of canertinib and crizotinib was also confirmed on RTK phosphorylation level studied with western blotting (data not shown). Interestingly, by addition of various growth factors, which are normally expressed in brain (tumor) tissue, inhibition by sorafenib, canertinib and crizotinib could be rescued partially, and even completely in dasatinib treated tumor cells (Figure 3). Especially EGF, HGF and FGF showed a strong rescue potential. Expression levels of the RTKs were not correlated with growth-factor-driven rescue in terms of increase in LC50. Eventually, as HGF was capable to induce rescue during canertinib and EGF during crizotinib, a combined treatment of these inhibitors could be promising in pediatric low grade astrocytoma and ependymoma (see below).

Growth factors overcome RTK-inhibited-phosphorylation of downstream targets

Before studying the possibilities of combined RTK inhibitors to overcome resistance, we assessed growth-factor-driven rescue on RTK-inhibited-phosphorylation of downstream targets to validate the previous rescue results on cell viability level. Analyses of the PI3K/Akt and MAPK/Erk downstream pathways, as the most commonly used survival signaling pathways by RTKs (Figure 1), indeed underscored EGF and HGF driven rescue during sorafenib and dasatinib treatment which resulted in phosphorylation of Akt and Erk (Figure 4A, B). HGF-driven rescue, positively effecting cell viability during canertinib, was also confirmed with overcoming the RTK-inhibited-phosphorylation of downstream targets. As intern negative control no Akt or Erk phosphorylation was found with FGF or PDGF during sorafenib, EGF during canertinib, and HGF during crizotinib treatment (Figure 4A, C, D).

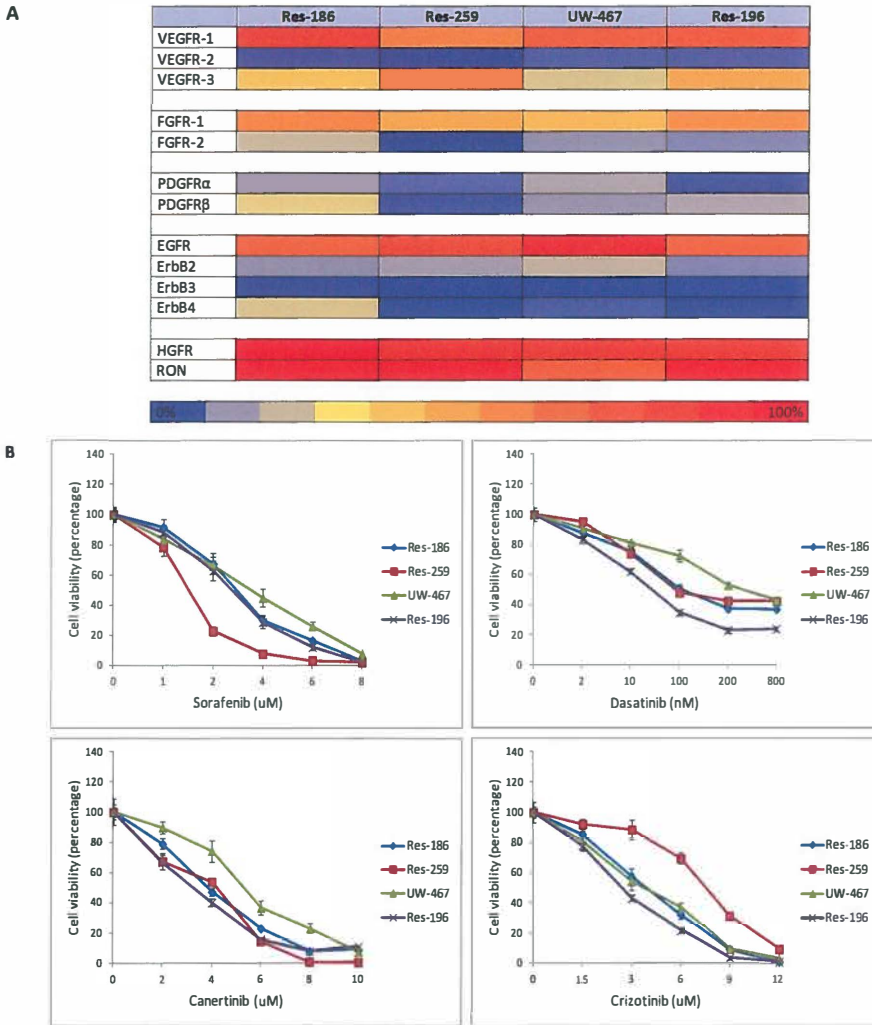


Figure 2. (A) Heat map showing expression levels in percentages of numerous growth factor receptors using flow cytometry analyses in pediatric low grade astrocytoma (Res-186, Res-259, UW-467) and ependymoma (Res-196) cell lines. (B) Cell viability assays demonstrating the effect of sorafenib, dasatinib, canertinib and crizotinib on pediatric low grade astrocytoma (Res-186, Res-259, UW-467) and ependymoma (Res-196) cell lines after 48h. Corresponding results in proliferation and apoptotic assays were found (data not shown).

A

Inhibitor	Cell line	VEGF-A	EGF	HGF	FGF basic	PDGF-AB
Sorafenib Raf, VEGFR 2, -3 PDGFRβ, c-Kit BRAF, FGFR-1	Res-186		35%	25%		
	Res-259		28%	35%		
	UW-467		36%	53%		
	Res-196		24%	11%		6%
Dasatinib Src, BCR/Abi PDGFRα, -β, c-Kit	Res-186		157%			
	Res-259		CR	CR	CR	
	UW-467		CR	CR	CR	
	Res-196					
Canertinib Pan-ErbB	Res-186			10%		
	Res-259				15%	
	UW-467					
	Res-196			15%		
Crizotinib cMet, ALK, RON	Res-186					
	Res-259					
	UW-467					
	Res-196		23%			

B

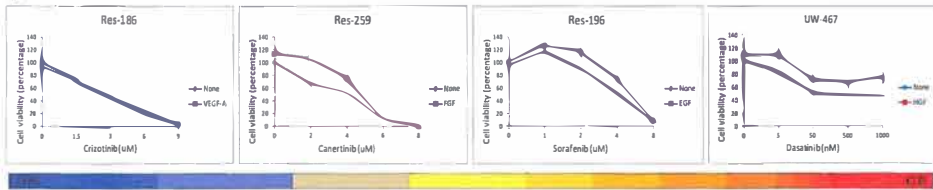


Figure 3. (A) Heat map showing the effect of growth factors on pediatric low grade astrocytoma and ependymoma cells treated with different TKIs. Percentages represent significant increase in LC50 of cells treated with inhibitor plus growth factor compared with inhibitor-treated cells only (purple squares, no rescue; yellow/orange, partial rescue; red squares, complete rescue). As an intern negative control no growth-factor-driven rescue was found of the particular RTK ligand of which the receptor is inhibited. **(B)** Cell viability assays demonstrating the diversity of growth factors on TKI-treated cells.

Discrepancies between growth-factor-driven rescue on cell viability level and downstream phosphorylation status

Notably, is the apparent discrepancy of HGF-driven phosphorylation by Akt and Erk without increased cell viability during canertinib in Res-259 cells, because there was HGF-driven rescue observed on cell viability level however at a lower dose, before the LC50. Also, in dasatinib treated Res-186 cells, HGF was unable to rescue cells at cell viability level despite the expression of the RTK and observed phosphorylation of Akt and Erk (Figure 4). This could possibly be explained by the various downstream targets of dasatinib with the consequence that activation of Akt and Erk is insufficient for cell viability rescue. Vice versa, FGF-driven rescue was not confirmed with Akt or Erk phosphorylation possibly due to involvement of other downstream pathways (Figure 1), that were not evaluated in this study.

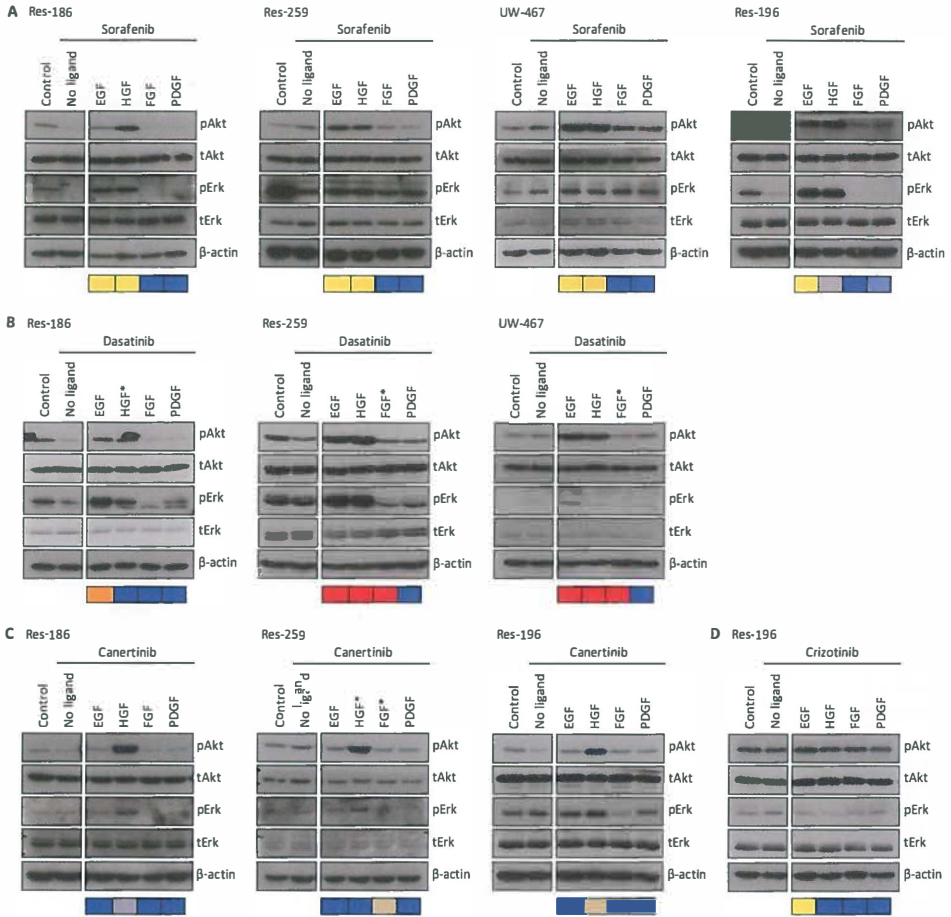


Figure 4. Immunoblots showing effects of growth factors (100 ng/ml) on Akt and Erk phosphorylation (p) after sorafenib (A), dasatinib (B), canertinib (C), crizotinib (D) in pediatric low grade astrocytoma and ependymoma cells (2h). Growth-factor-driven rescue on cell viability as given in Figure 3 is indicated underneath the blots: purple squares, no rescue; yellow/orange squares, partial rescue; red squares, complete rescue. * Discrepancies between growth-factor-driven rescue on cell viability level and downstream phosphorylation status.

Combined RTK treatment can overcome growth-factor-driven rescue

Interestingly, EGF-driven rescue during sorafenib and HGF- and FGF-driven rescue during canertinib could be overcome by combining specific TK inhibitors. So by addition of canertinib to sorafenib treatment, EGF-driven rescue could be overcome and tumor cell survival was disrupted. In turn, sorafenib can overcome FGF-driven rescue during canertinib treatment (Figure 5). Actually as rescue by different growth factors was found in sorafenib, including both EGF and HGF, more than one RTK would have to be added. However, canertinib seems therapeutically more attractive showing less growth-factor-driven rescue, and was indeed successfully combined with sorafenib or crizotinib in both ependymoma and low grade astrocytoma cells.

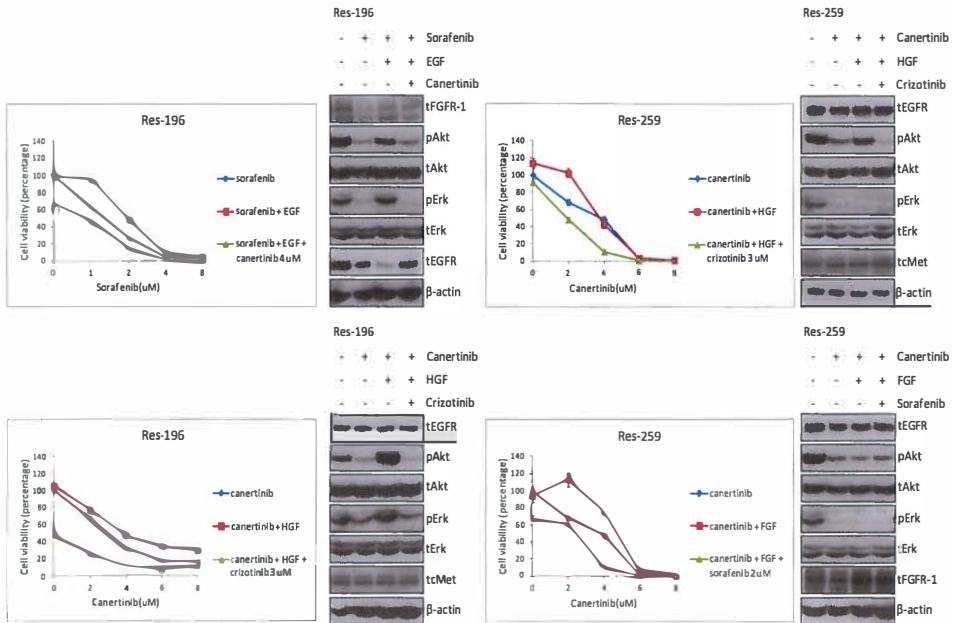


Figure 5. Cell viability assays demonstrating additional effects of combination treatment in pediatric low grade astrocytoma (Res-259) and ependymoma (Res-196) compared with single treatment (48h). Immunoblots showing effects of growth factors (100 ng/ml) on RTK, Akt and Erk phosphorylation (p) in pediatric low grade astrocytoma and ependymoma cells (2h).

Discussion

The present study showed growth-factor-driven rescue to various RTK inhibitors in pediatric low grade astrocytoma and ependymoma cell lines. Previously, we described several potential interesting drugable therapeutic targets upon kinome profiling *e.g.* VEGFR-2, PDGFR β , Src, ErbB family members, and HGFR/cMet.⁵ Drugs such as sorafenib, dasatinib, canertinib and crizotinib respectively were used to inhibit these targets. *In vitro* cell viability decreased upon the single use of one of these inhibitors as expected. In normal developing brain and therefore, also in brain tumors several growth factors including VEGF, EGF, HGF, FGF and PDGF, are commonly expressed.¹⁰⁻¹⁷ Interestingly, the growth factor receptors are found often to be present on low grade astrocytoma and ependymoma cells.

Therefore, the present study investigated the rescue of ligand exposure to these RTK inhibitors. EGF and HGF showed to be effective rescue inducing growth factors in these resistance mechanisms acting via their RTKs resulting in increased cell survival and down-stream signaling. Combination treatment showed enhanced decrease in cell viability although growth factors were present. In ependymoma cells the combination of canertinib and crizotinib showed the best potential strategy, whereas in low grade astrocytoma cells the combination of both canertinib and crizotinib or canertinib and sorafenib demonstrated the best results. These findings highlight the potential growth factor induced cross talk in RTKs that are co-expressed on these low grade astrocytoma and ependymoma cells.

This is the first study to describe a RTK profile in relation to ligand exposure in low grade astrocytoma. In pediatric ependymoma a positive correlation between higher coexpression of ErbB2 and ErbB4 and tumor proliferative activity has been described.¹⁸ Furthermore, ligand-dependent activation of ErbB receptor-signaling in cultured ependymoma cells resulted in Akt phosphorylation and cellular proliferation that was significantly blocked in a dose-dependent manner using WAY-177820, an inhibitor of ErbB2 tyrosine kinase activity.¹⁸ The present study showed especially EGFR expression compared with the other ErbB family members. Moreover, EGF was shown to be a potential ligand to overcome resistance during other RTK inhibitors in both low grade astrocytoma and ependymoma. The rescue by growth factors is in line with previous reports in other tumor types. Particularly, HGF/cMet-induced resistance to RTK inhibitors is observed in diverse tumor types, including adult glioblastoma.¹⁹ Further, PDGF upregulation in reaction to VEGFR inhibition and increased FGF/FGFR signaling during BRAF or EGFR inhibition may potentially contribute to tumor resistance.²⁰⁻²³ Recently, tumor-cell-secreted VEGF has been demonstrated as one of the growth-factor-driven rescue mechanisms through activation of VEGFR-2 and the PI3K/Akt pathway.²⁴ As VEGFR-2 expression is in pediatric low grade astrocytoma and ependymoma mainly limited to endothelial cells,²⁵ we expect that VEGF will be able to enhance tumor growth only indirectly by inducing angiogenesis. This study underscores the previous result because the cell viability did not differ. Until now, mainly pediatric high grade astrocytomas and just a few ependymomas were included into phase I studies analyzing erlotinib, an ErbB1/EGFR TK inhibitor as a single agent and in combination with chemotherapy or radiation.²⁶⁻²⁸ Erlotinib was well tolerated in children, as were other ErbB family inhibitors including gefitinib and lapatinib.²⁶⁻³⁰ The only published phase II study showed no increase in progression free survival or overall survival with gefitinib and radiation in malignant pediatric brain tumors.³⁰ Currently, erlotinib is under investigation in pediatric low grade astrocytoma and ependymoma in phase I and II trials respectively. As the ErbB TK family comprises four members, canertinib, a new pan-ErbB TK inhibitor showing anti-proliferative and pro-apoptotic effects on tumor cells,³¹ could be more interesting. Up to now, canertinib has not been investigated in pre- or clinical pediatric brain tumor studies. Sorafenib has been described in clinical trials, yet only restricted to adult brain tumors. Limited activity was reported of sorafenib in recurrent glioblastoma and in the first-line therapy for glioblastoma.³²⁻³⁴ In pediatric low grade astrocytoma, sorafenib is topically analyzed. Although this could be interesting as alterations affecting the BRAF oncogene represent the main genetic defects in pilocytic astrocytoma (WHO grade I),^{35,36} we showed growth-factor-driven rescue during sorafenib in pilocytic astrocytoma cells, suggesting less potential for single application of this RTK inhibitor. Dasatinib and crizotinib are recently introduced in pediatric brain tumor clinical trials which are still ongoing.

As especially EGFR and HGFR were highly expressed in pediatric brain tumor cells, these findings provide a rational explanation of the limited efficacy of single targeted treatment in clinical trials. Moreover the successful combination treatments to overcome these resistance mechanisms support the importance for multi targeted therapy in low grade astrocytoma and ependymoma. Although mutations are of great importance in tumorigenesis and tumor progression, specific RTK inhibitors often result in a heterogeneous clinical benefit in various clinical trials as mentioned above. Our study highlights the extensive importance of environmentally present growth factors in developing resistance mechanisms towards RTK inhibitors. It is of great importance to anticipate upon these results for the design of new therapeutic trials with RTK inhibitors.

Acknowledgements

This work was supported by a grant from Jan Kornelis de Cock Stichting (project code 13-75 to M. Sie).

References

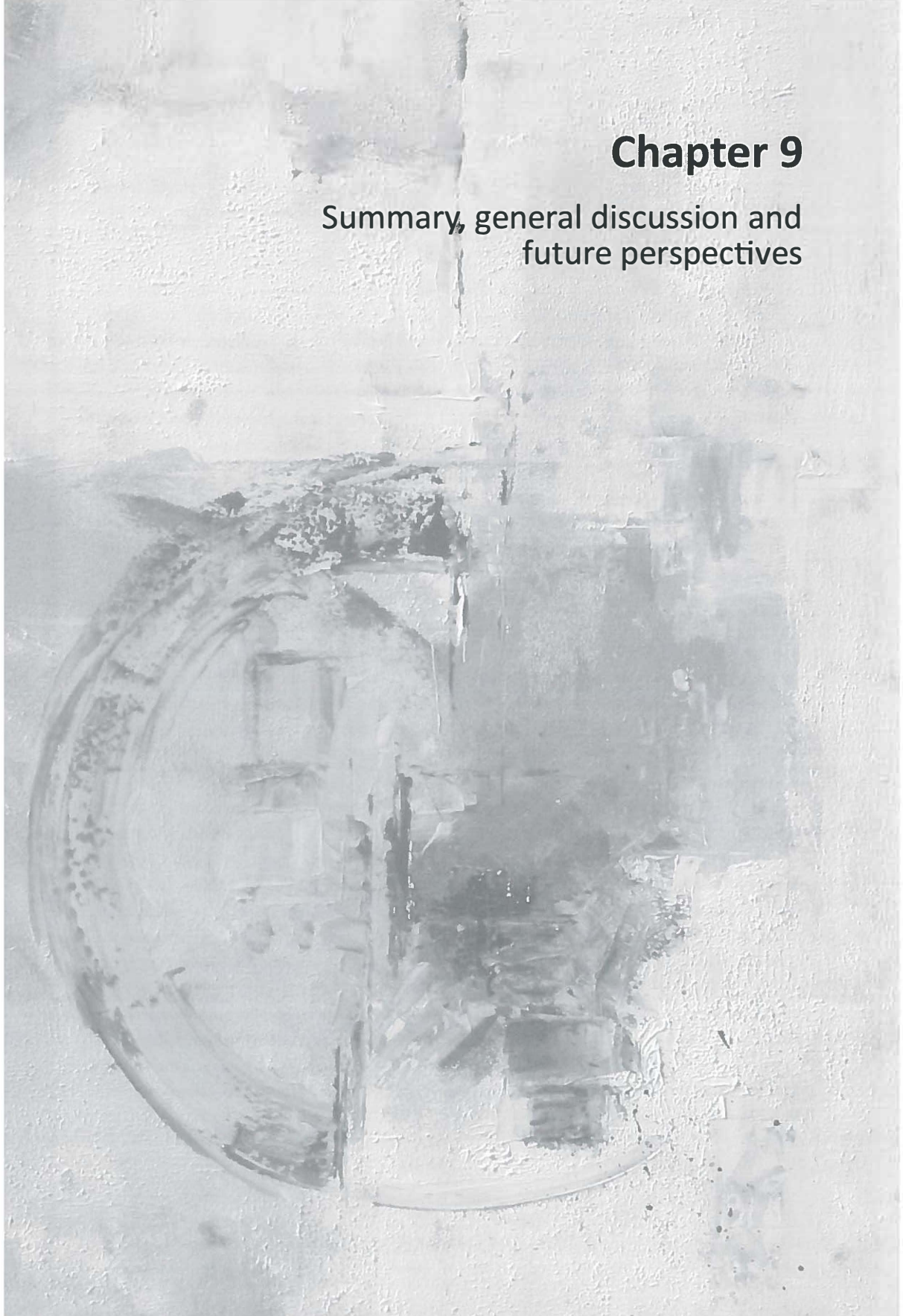
1. Louis DN, Ohgaki H, Wiestler OD, Cavenee WK. Classification of tumours of the central nervous system. 4th ed. Lyon: IARC; 2007.
2. Due-Tonnessen BJ, Helseth E, Scheie D, Skullerud K, Aamodt G, Lundar T. Long-term outcome after resection of benign cerebellar astrocytomas in children and young adults (0-19 years): report of 110 consecutive cases. *Pediatr Neurosurg* 2002;37:71-80.
3. Fernandez C, Figarella-Branger D, Girard N, et al. Pilocytic astrocytomas in children: prognostic factors-a retrospective study of 80 cases. *Neurosurgery* 2003;53:544-553
4. Shim KW, Kim DS, Choi JU. The history of ependymoma management. *Childs Nerv Syst* 2009;25:1167-1183.
5. Sikkema AH, Diks SH, den Dunnen WF, et al. Kinome profiling in pediatric brain tumors as a new approach for target discovery. *Cancer Res* 2009;69:5987-5995.
6. Maekawa T, Ashihara E, Kimura S. The Bcr-Abl tyrosine kinase inhibitor imatinib and promising new agents against Philadelphia chromosome-positive leukemias. *Int J Clin Oncol* 2007;12:327-340.
7. Young A, Lou D, McCormick F. Oncogenic and wild-type Ras play divergent roles in the regulation of mitogen-activated protein kinase signaling. *Cancer Discov* 2013;3:112-123.
8. Wilson TR, Fridlyand J, Yan Y, et al. Widespread potential for growth-factor-driven resistance to anticancer kinase inhibitors. *Nature* 2012;487:505-509.
9. Bobola MS, Silber JR, Ellenbogen RG, Geyer JR, Blank A, Goff RD. O6-methylguanine-DNA methyltransferase, O6-benzylguanine, and resistance to clinical alkylators in pediatric primary brain tumor cell lines. *Clin Cancer Res* 2005;11:2747-2755.
10. Lafuente JV, Ortuzar N, Bengoetxea H, Bulnes S, Argandona EG. Vascular endothelial growth factor and other angioglioneurins: key molecules in brain development and restoration. *Int Rev Neurobiol* 2012;102:317-346.
11. Namba H, Zheng Y, Abe Y, Nawa H. Epidermal growth factor administered in the periphery influences excitatory synaptic inputs onto midbrain dopaminergic neurons in postnatal mice. *Neuroscience* 2009;158:1731-1741.
12. Rosser AE, Tyers P, Dunnett SB. The morphological development of neurons derived from EGF- and FGF-2-driven human CNS precursors depends on their site of integration in the neonatal rat brain. *Eur J Neurosci* 2000;12:2405-2413.
13. Achim CL, Katyal S, Wiley CA, et al. Expression of HGF and cMet in the developing and adult brain. *Brain Res Dev Brain Res* 1997;102:299-303.
14. Thewke DP and Seeds NW. The expression of mRNAs for hepatocyte growth factor/scatter factor, its receptor c-met, and one of its activators tissue-type plasminogen activator show a systematic relationship in the developing and adult cerebral cortex and hippocampus. *Brain Res* 1999;821:356-367.
15. Gremo F and Presta M. Role of fibroblast growth factor-2 in human brain: a focus on development. *Int J Dev Neurosci* 2000;18:271-279.
16. Valenzuela CF, Kazlauskas A, Weiner JL. Roles of platelet-derived growth factor in the developing and mature nervous systems. *Brain Res Brain Res Rev* 1997;24:77-89.
17. Jain RK, di Tomaso E, Duda DG, Loeffler JS, Sorensen AG, Batchelor TT. Angiogenesis in brain tumours. *Nat Rev Neurosci* 2007;8:610-622.
18. Gilbertson RJ, Bentley L, Hernan R, et al. ERBB receptor signaling promotes ependymoma cell proliferation and represents a potential novel therapeutic target for this disease. *Clin Cancer Res* 2002;8:3054-3064.
19. Jun HJ, Acquaviva J, Chi D, et al. Acquired MET expression confers resistance to EGFR inhibition in a mouse model of glioblastoma multiforme. *Oncogene* 2012;31:3039-3050.

20. Ho AL, Vasudeva SD, Lae M, et al. PDGF receptor alpha is an alternative mediator of rapamycin-induced Akt activation: implications for combination targeted therapy of synovial sarcoma. *Cancer Res* 2012;72:4515-4525.
21. di Tomaso E, Snuderl M, Kamoun WS, et al. Glioblastoma recurrence after cediranib therapy in patients: lack of "rebound" revascularization as mode of escape. *Cancer Res* 2011;71:19-28.
22. Ware KE, Marshall ME, Heasley LR, et al. Rapidly acquired resistance to EGFR tyrosine kinase inhibitors in NSCLC cell lines through de-repression of FGFR2 and FGFR3 expression. *PLoS One* 2010;5:e14117.
23. Yadav V, Zhang X, Liu J, et al. Reactivation of mitogen-activated protein kinase (MAPK) pathway by FGF receptor 3 (FGFR3)/Ras mediates resistance to vemurafenib in human B-RAF V600E mutant melanoma. *J Biol Chem* 2012;287:28087-28098.
24. Akiyama K, Ohga N, Hida Y, et al. Tumor endothelial cells acquire drug resistance by MDR1 up-regulation via VEGF signaling in tumor microenvironment. *Am J Pathol* 2012;180:1283-1293.
25. Sikkema AH, de Bont ES, Molema G, et al. Vascular endothelial growth factor receptor 2 (VEGFR-2) signalling activity in paediatric pilocytic astrocytoma is restricted to tumour endothelial cells. *Neuropathol Appl Neurobiol* 2011;37:538-548.
26. Jakacki RI, Hamilton M, Gilbertson RJ, et al. Pediatric phase I and pharmacokinetic study of erlotinib followed by the combination of erlotinib and temozolomide: a Children's Oncology Group Phase I Consortium Study. *J Clin Oncol* 2008;26:4921-4927.
27. Broniscer A, Baker SJ, Stewart CF, et al. Phase I and pharmacokinetic studies of erlotinib administered concurrently with radiotherapy for children, adolescents, and young adults with high-grade glioma. *Clin Cancer Res* 2009;15:701-707.
28. Geoerger B, Hargrave D, Thomas F, et al. Innovative Therapies for Children with Cancer pediatric phase I study of erlotinib in brainstem glioma and relapsing/refractory brain tumors. *Neuro Oncol* 2011;13:109-118.
29. Geyer JR, Stewart CF, Kocak M, et al. A phase I and biology study of gefitinib and radiation in children with newly diagnosed brain stem gliomas or supratentorial malignant gliomas. *Eur J Cancer* 2010;46:3287-3293.
30. Pollack IF, Stewart CF, Kocak M, et al. A phase II study of gefitinib and irradiation in children with newly diagnosed brainstem gliomas: a report from the Pediatric Brain Tumor Consortium. *Neuro Oncol* 2011;13:290-297.
31. Slichenmyer WJ, Elliott WL, Fry DW. CI-1033, a pan-erbB tyrosine kinase inhibitor. *Semin Oncol* 2001;28:80-85.
32. Lee EQ, Kuhn J, Lamborn KR, et al. Phase I/II study of sorafenib in combination with temsirolimus for recurrent glioblastoma or gliosarcoma: North American Brain Tumor Consortium study 05-02. *Neuro Oncol* 2012;14:1511-1518.
33. Hainsworth JD, Ervin T, Friedman E, et al. Concurrent radiotherapy and temozolomide followed by temozolomide and sorafenib in the first-line treatment of patients with glioblastoma multiforme. *Cancer* 2010;116:3663-3669.
34. Reardon DA, Vredenburgh JJ, Desjardins A, et al. Effect of CYP3A-inducing anti-epileptics on sorafenib exposure: results of a phase II study of sorafenib plus daily temozolomide in adults with recurrent glioblastoma. *J Neurooncol* 2011;101:57-66.
35. Gronych J, Korshunov A, Bageritz J, et al. An activated mutant BRAF kinase domain is sufficient to induce pilocytic astrocytoma in mice. *J Clin Invest* 2011;121:1344-1348.
36. Rodriguez FJ, Lim KS, Bowers D, Eberhart CG. Pathological and molecular advances in pediatric low-grade astrocytoma. *Annu Rev Pathol* 2013;8:361-379.



Chapter 9

Summary, general discussion and
future perspectives



Summary

Brain tumors are the most frequent pediatric tumors and are still the leading cause of cancer morbidity and mortality among children, despite different therapeutic modalities including neurosurgery, chemotherapy and radiation. As angiogenesis plays a crucial role in tumor growth and progression, anti-angiogenic therapy could be suitable in pediatric brain tumors. To obtain insight into the possible therapeutic window for anti-angiogenic therapy in these tumors, the research described in the present thesis analyzed the angiogenic profile, tumor vasculature and growth-factor-driven rescue to angiogenic inhibitors in pediatric brain tumors in the context of adult glioblastoma, as the commonly used model for angiogenesis in brain tumors. Started with a clinical point of view on anti-angiogenic therapy in pediatric brain tumors, more biological tumor characteristics were evaluated in (pediatric) brain tumor tissue, followed by analyses of growth-factor-driven rescue to receptor tyrosine kinase (RTK) inhibitors in pediatric brain tumor cell lines.

In **chapter 2** published clinical trials of anti-angiogenic therapy in pediatric brain tumors were reviewed and an overview of recently started clinical trials was provided. As many of these clinical trials were in the phase I setting and new agents are upcoming, it seems that we are still at the beginning of the development and optimization of anti-angiogenic therapy in pediatric brain tumors. Although some encouraging results have been described of agents targeting VEGF/VEGFR signaling or the ErbB family, results were not convincing in the presentation of an anti-angiogenic strategy that significantly increases overall survival in pediatric brain tumor patients. This could be due to possible tumor escape mechanisms, including growth-factor-driven tumor resistance. Theoretically, this resistance mechanism could be overcome by multi targeted therapy. Overall, more insight is required to be highly conclusive about the efficacy of anti-angiogenic therapy with currently upcoming potential anti-angiogenic agents in pediatric brain tumors.

Chapter 3 evaluated aspects of the angiogenic profile and tumor vasculature in the context of therapeutic outcome in 62 adult patients with primary glioblastoma as prototype of angiogenesis in brain tumors. Microvessel density, turnover of endothelial and tumor cells, and VEGF-A-D expression were analyzed in tumor slides immunohistochemically stained with respectively Ki67/CD34, cleaved caspase-3/CD34, and VEGF-A-D. The ANGPT-1/ANGPT-2 balance as indicator for vessel stability was determined using Real Time RT-PCR. As VEGF-D was higher expressed in the relatively hypoxic perinecrotic tumor area, a possible role for hypoxia driven VEGF-D was suggested, comparable to VEGF-A. Interestingly, the ANGPT-1/ANGPT-2 balance was identified as a prognostic marker in primary glioblastoma. Angiopoietins are strongly associated with morphological and functional changes in tumor vasculature and are crucial in the process of tumor angiogenesis.¹⁻³ So the prognostic finding of the ANGPT-1/ANGPT-2 balance supported the need for further studies into the feasibility of anti-angiogenic therapy in primary glioblastoma, with a special focus on the normalization of tumor vasculature.

In the context of glioblastoma, often seen as a prototype for tumor angiogenesis, in **chapter 4** the angiogenic profile and tumor vasculature including vessel maturity status was investigated in 27 pediatric intracranial ependymomas (WHO grade II-III). Despite a low endothelial cell turnover in ependymomas, microvessel density and VEGF-A expression were similar to glioblastomas. The ependymoma vasculature, in general, showed more vessel maturity in terms of basement membrane and pericyte coverage than glioblastoma, although these parameters were overlapping. In theory, in ependymoma vessel normalization through anti-angiogenic agents may be less successful than in glioblastomas. However, as individual ependymomas showed considerable overlap with glioblastoma, ependymomas or a subset of these tumors may benefit from anti-angiogenic therapy as an addition to chemo- or radiotherapy.

Pediatric pilocytic astrocytomas (WHO grade I) showed besides differences in vessel architecture, a surprisingly critical overlap in vessel immaturity/instability and the angiogenic profile with glioblastoma (**chapter 5**). Moreover, a high overlapping pro- and anti-angiogenic VEGF-A isoform ratio was found between both tumors (**chapter 6**), suggesting encouraging possibilities for targeting angiogenesis as a therapeutic strategy, not only in glioblastoma, but also in pilocytic astrocytoma. Differences in vessel architecture could not be exclusively attributed to the VEGF-A isoforms.

Subsequently, **chapter 7** showed less tumor engraftment after anti-VEGF therapy in a newly developed pediatric low grade astrocytoma mouse model. In pediatric low grade astrocytoma VEGFR-2 expression is mainly limited to endothelial cells.⁴ So as expected no effects of anti-VEGF were observed on tumor cell viability and proliferation level whereas anti-VEGF seems to work especially on tumor microenvironment. Suggesting again that anti-angiogenic therapy could have a potential role in the therapeutic strategy for children with low grade astrocytoma. Clinical trials did not show that consequent positive results for anti-angiogenic therapy. Recently, some studies described tumor resistance or rescue mechanisms when specific targets are inhibited.

These tumor escape mechanisms have been described not only in VEGF targeted therapies but also during different RTK inhibitors which target both angiogenic and oncogenic pathways.⁵ These resistance mechanisms may include alternate routes of kinase pathway activation through kinome reprogramming or upregulation of other RTK and/or their ligands eventually contributing to tumor rescue to the RTK inhibitor with a similar signaling output.^{6,7} RTK ligands such as VEGF, EGF, HGF and PDGF are normally expressed in neuronal development and are expected to be present in the tumor microenvironment. Possibly due to these resistance mechanisms, clinical trials evaluating RTKs show disappointing results with single targeted therapy as reviewed in chapter 2.

Chapter 8 showed growth-factor-driven rescue of mainly EGF, HGF and FGF to RTK inhibitors (sorafenib, dasatinib, canertinib, crizotinib) in pediatric low grade astrocytoma and ependymoma cell lines. These results were found on cell viability level as well as phosphorylation level of downstream targets. These findings highlight the potential signal cross talk in RTKs that are co-expressed on these low grade astrocytoma and ependymoma cells. As the growth-factor-driven rescue could be overcome by addition of the relevant RTK inhibitor, this study is in line with chapter 2 preferring multi targeted therapy in pediatric brain tumors.

General discussion and future perspectives

The angiogenic profile and tumor vasculature in pediatric brain tumors have been analyzed in the context of the highly vascular adult glioblastoma as prototype of angiogenesis. As pediatric intracranial ependymoma and in more extent pilocytic astrocytoma showed a crucial overlap in the angiogenic profile and vessel immaturity/instability with glioblastoma, anti-angiogenic therapy achieving vessel normalization could be a suitable therapeutic strategy in combination with chemotherapy not only in glioblastoma but also in these pediatric brain tumors. However this thesis also highlights a tumor resistance mechanism, including growth-factor-driven rescue, that may arise in response to anti-angiogenic therapy. These tumor resistance mechanisms can be present during different angiogenic strategies, like anti-VEGF therapy to purpose vessel normalization but also during receptor tyrosine kinase (RTK) inhibition targeting both angiogenic and oncogenic pathways.

As results in clinical trials evaluating anti-angiogenic therapy in pediatric brain tumors were not convincingly presenting an angiogenic treatment that significantly increases overall survival, this indeed could possibly be due to growth-factor-driven rescue as one of the tumor escape mechanisms. Concurrently, we showed that growth-factor-driven rescue could be overcome by addition of the relevant RTK inhibitor. To further increase insight into these mechanisms and to test potential angiogenic agents, preclinical analyses *in vivo* or alternative *in ovo* and *ex vivo* models are highly needed. As such, translation of angiogenic agents into clinical trials will be more rational. Moreover by inclusion of a preclinical model simultaneously with a clinical trial, this model can be further optimized. Eventually, a potential preclinical model can be used in future clinical trials to perform prior analyses of tumor tissue derived from stereotactic biopsy, predicting tumor response and identifying the pediatric patients who will respond among the included trial patients.

Pediatric low grade astrocytoma mouse models

Up to now, two spontaneous low grade astrocytoma mouse models have been described: a genetically engineered mouse model of neurofibromatosis-1 developing optic low grade glioma and a mouse model in which a BRAF kinase domain was activated to induce pilocytic astrocytoma.⁸ However a xenograft model with human tumor cells may be relevant too for preclinical testing of potential anti-angiogenic agents. So in addition, we started a pediatric low grade astrocytoma xenograft mouse model, in which Res-259 cells (WHO grade II) were orthotopically implanted in NOD-scid IL2Rg^{null} mice. Due to the inconsistently shaped tumor engraftment varying from a massive tumor bulk to tumor engraftment around the brain, analyses of the tumor vasculature including vessel (im)maturity or possible tumor escape mechanisms like upregulation of alternative angiogenic factors or increased invasiveness could not be performed. Moreover, anti-angiogenic response monitoring of radiolabeled bevacizumab using positron emission tomography (PET) was not feasible due to small tumor size. The intracranial tumors were highly 2 mm in diameter while PET visualized subcutaneous tumors can reach diameters of 8 mm.¹⁰ Although preliminary results were derived, this *in vivo* model warrants optimization before it can be used for further drug testing.

***In ovo* and *ex vivo* models**

An *in ovo* brain tumor model for studying angiogenesis is the chorioallantoic membrane (CAM) of the chicken embryo on which glioblastoma cells were deposited, resulting in tumor growth.^{11,12} It has been suggested that tumor protein expression in the CAM model is comparable to that of an *in vivo* model. Effect of anti-angiogenic agents can be demonstrated on tumor growth and blood vessel development.^{12,13} Especially the possibility to analyze different aspects of the vasculature, including vessel growth and vessel architecture such as vascular density and branching points makes the CAM an elegant model to study angiogenesis. Up to now the CAM model has not yet been used to analyze anti-angiogenic agents in pediatric brain tumors.

More recently, an *ex vivo* 3D brain tumor model has been published in which adult and pediatric glioblastoma cells were cultured till aggregates using a 3D rotary cell culture system (RCCS), originally developed by the National Aeronautics and Space Administration (NASA).^{14,15} This study demonstrated that these 3D RCCS cultures had profound effects on the genetic, epigenetic and metabolic profiles of the cultured glioblastoma cells, suggesting an intermediate phenotype between that of 2D cultures and primary tumors. The macroscopic RCCS aggregates recapitulated the heterogeneous morphology of glioblastoma with a distinct proliferating rim, necrotic core and oxygen tension gradient, allowing drug testing in a more relevant *ex vivo* system. As pediatric low grade astrocytoma cells (Res-186: WHO grade I and Res-259: WHO grade II) could be successfully cultured in this 3D system (personal collaboration), our data can be enriched by this method. Moreover, the RCCS makes it possible to analyze other modes of vessel formation in tumors, including vasculogenic mimicry in which a proportion of RCCS brain tumor aggregates exhibit a vasculogenic phenotype and angiogenic gene expression profile in the absence of any form of co-culture. In addition, the RCCS can be used as a system for maintaining viable explants of primary tumor directly from neurosurgery. This in combination with increased experiences culturing primary brain tumor cells may allow target discovery analyses and drug testing to predict tumor response in the particular patient.

In relatively little time, analyses in both *in ovo* and *ex vivo* models could be performed, as the CAM model takes 1-2 weeks and aggregates in the RCCS can be analyzed within 3 weeks compared with 6 weeks in the *in vivo* mouse model. These models could present an easier and less expensive alternative for *in vivo* models, reducing the use of animals. Ideally, a preclinical model should be as close as possible to the patient's situation to give the best chances to be successful in clinical trials, so taking also crucial aspects into account including the microenvironment and the presence of either an intact or leaky blood brain barrier that could influence the delivery of targeted therapy to brain tumors. A mouse model seems to be more representative for the human situation including brain microenvironment and a systemic blood flow. However the environmental cells are murine and as the low grade astrocytoma cells could only result in tumor engraftment in immune compromised mice, the systemic factor is limited. In the RCCS it is possible to include environmental cells, however if glioblastoma cells were co-cultured with endothelial cells, the aggregates showed less tumor characteristics.¹⁴

Conclusions

Today, brain tumors are still the leading cause of cancer morbidity and mortality among children. As angiogenesis is highly crucial in tumor growth and progression, this mechanism has been extensively investigated and different anti-angiogenic therapies have been developed. However these studies are limited in pediatric brain tumors. So the present thesis obtained to increase insight into the angiogenic profile, tumor vasculature and growth-factor-driven resistance to angiogenic inhibitors in pediatric brain tumors. This thesis suggested a therapeutic window for anti-angiogenic therapy in these tumors at the one site and at the other site highlighted the possible tumor escape mechanisms that can arise in response to anti-angiogenic therapy. To further increase insight into these mechanisms and to test potential angiogenic agents, preclinical analyses in *ex vivo* and *in vivo* models need to be optimized, making translation into clinical trials more rational. It is advisable to include a preclinical model simultaneously with a clinical trial to contribute to its optimization and in future clinical trial function as a predictive tumor response model. At the end, more individualized anti-angiogenic therapy will be a worthwhile future perspective in pediatric brain tumors.

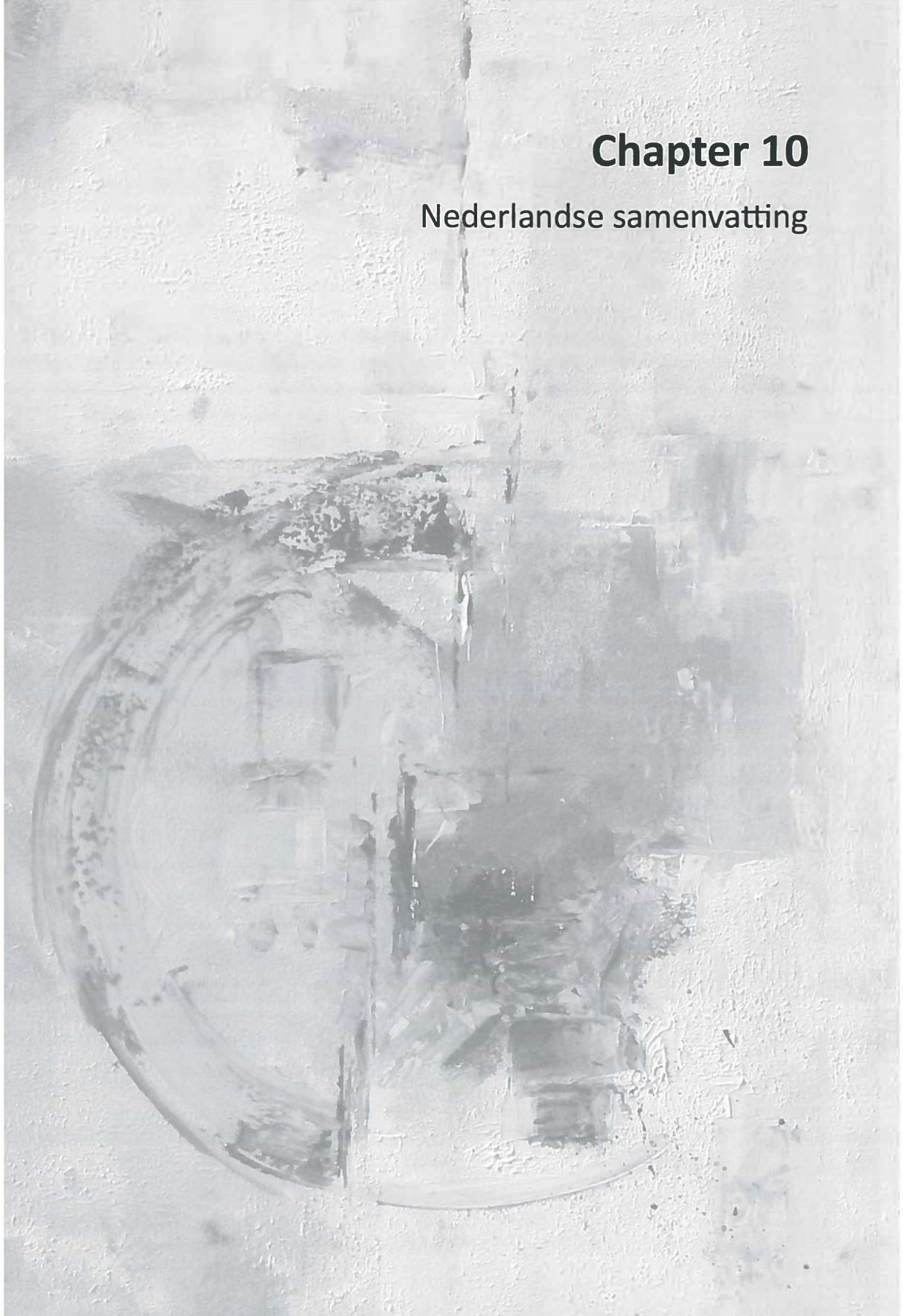
References

1. Thomas M and Augustin HG. The role of the Angiopoietins in vascular morphogenesis. *Angiogenesis*. 2009;12:125-137.
2. Jain RK. Molecular regulation of vessel maturation. *Nat Med*. 2003;9:685-693.
3. Koga K, Todaka T, Morioka M, et al. Expression of angiopoietin-2 in human glioma cells and its role for angiogenesis. *Cancer Res*. 2001;61:6248-6254.
4. Sikkema AH, de Bont ES, Molema G, et al. Vascular endothelial growth factor receptor 2 (VEGFR-2) signalling activity in paediatric pilocytic astrocytoma is restricted to tumour endothelial cells. *Neuropathol Appl Neurobiol*. 2011;37:538-548.
5. Stommel JM, Kimmelman AC, Ying H, et al. Coactivation of receptor tyrosine kinases affects the response of tumor cells to targeted therapies. *Science*. 2007;318:287-290.
6. Wilson TR, Fridlyand J, Yan Y, et al. Widespread potential for growth-factor-driven resistance to anticancer kinase inhibitors. *Nature*. 2012;487:505-509.
7. Duncan JS, Whittle MC, Nakamura K, et al. Dynamic reprogramming of the kinome in response to targeted MEK inhibition in triple-negative breast cancer. *Cell*. 2012;149:307-321.
8. Hegedus B, Banerjee D, Yeh TH, et al. Preclinical cancer therapy in a mouse model of neurofibromatosis-1 optic glioma. *Cancer Res*. 2008;68:1520-1528.
9. Gronych J, Korshunov A, Bageritz J, et al. An activated mutant BRAF kinase domain is sufficient to induce pilocytic astrocytoma in mice. *J Clin Invest*. 2011;121:1344-1348.
10. Nagengast WB, de Vries EG, Hospers GA, et al. In vivo VEGF imaging with radiolabeled bevacizumab in a human ovarian tumor xenograft. *J Nucl Med*. 2007;48:1313-1319.
11. Strojnik T, Kavalari R, Barone TA, Plunkett RJ. Experimental model and immunohistochemical comparison of U87 human glioblastoma cell xenografts on the chicken chorioallantoic membrane and in rat brains. *Anticancer Res*. 2010;30:4851-4860.
12. Grodzik M, Sawosz E, Wierzbicki M, et al. Nanoparticles of carbon allotropes inhibit glioblastoma multiforme angiogenesis in ovo. *Int J Nanomedicine*. 2011;6:3041-3048.
13. Nowak-Sliwinska P, Weiss A, van Beijnum JR, et al. Angiostatic kinase inhibitors to sustain photodynamic angio-occlusion. *J Cell Mol Med*. 2012;16:1553-1562.
14. Smith SJ, Wilson M, Ward JH, et al. Recapitulation of tumor heterogeneity and molecular signatures in a 3D brain cancer model with decreased sensitivity to histone deacetylase inhibition. *PLoS One*. 2012;7:e52335.
15. Lei XH, Ning LN, Cao YJ, et al. NASA-approved rotary bioreactor enhances proliferation of human epidermal stem cells and supports formation of 3D epidermis-like structure. *PLoS One*. 2011;6:e26603.



Chapter 10

Nederlandse samenvatting

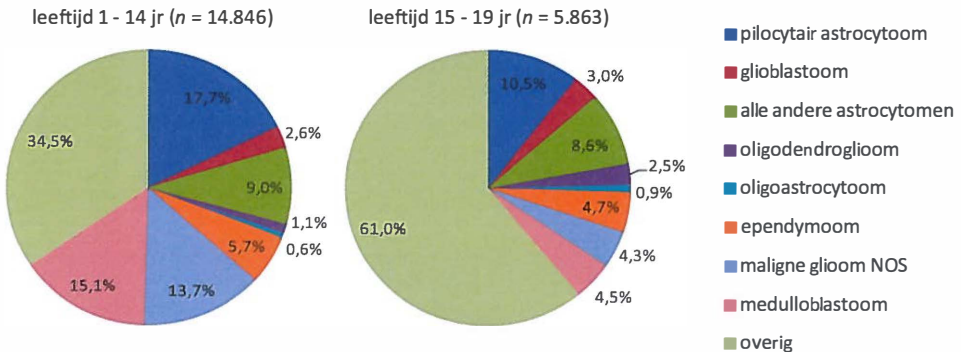


Hersentumoren

Elk jaar wordt in Nederland bij circa 1200 mensen een hersentumor vastgesteld. Hersentumoren beslaan 1,4% van alle soorten kanker bij volwassenen en zijn verantwoordelijk voor 2,3% van de sterftegevallen door kanker. Bij kinderen daarentegen zijn hersentumoren de meeste voorkomende tumoren en ondanks vele behandelingsmogelijkheden vormen hersentumoren nog steeds de grootste doodsoorzaak op de kinderleeftijd door kanker. Bovendien kan ernstige morbiditeit optreden, vooral bij ongunstige tumorlokalisaties met een aanzienlijke kans op chirurgische morbiditeit en nadelige effecten van chemotherapie en bestraling. Zo kunnen neurologische en endocriene restverschijnselen optreden en kan een gestoorde persoonlijke en sociaal-emotionele ontwikkeling plaatsvinden. Op deze wijze kunnen de kinderen die genezen van een hersentumor moeilijkheden ondervinden op maatschappelijk vlak waardoor gezond ouder worden bemoeilijkt wordt. Nieuwe behandelingsstrategieën zijn dus nodig om zowel mortaliteit als morbiditeit terug te dringen en daarmee 'healthy ageing' te bevorderen.

Aangezien angiogenese, oftewel bloedvatnieuwvorming, cruciaal is voor tumorgroei en -progressie, zou remming van angiogenese een geschikte therapie kunnen zijn. Echter in het betreffende onderzoeksveld zijn slechts een beperkt aantal studies gepubliceerd over angiogenese en tumorvasculatuur in kinderhersentumoren ten opzichte van volwassen hersentumoren. Om inzicht te krijgen in de therapeutische mogelijkheden van het remmen van angiogenese in kinderhersentumoren, wordt in dit proefschrift specifiek onderzoek gedaan naar het angiogene profiel in kinderhersentumoren. Analyses van kinderhersentumoren worden vergeleken met het angiogene profiel in het glioblastoom (WHO graad IV), de meest voorkomende hersentumor bij volwassenen. Glioblastomen zijn een van de meest vaatrijke tumoren en worden daarom ook wel gezien als een model voor de bestudering van angiogenese.

Op de kinderleeftijd komen laaggradige astrocytomen, waaronder het pilocytair astrocytoom (WHO graad I) en het diffuse astrocytoom (WHO graad II), het meeste voor, gevolgd door het medulloblastoom (WHO graad IV) en het ependymoom (WHO graad I-III) (Figuur 1).



Figuur 1. Histologische verdeling van tumoren van het centrale zenuwstelsel op de kinderleeftijd.

Angiogenese en anti-angiogene therapie

Angiogenese is van essentieel belang voor de bloedvoorziening van tumoren waarbij voedingsstoffen aangevoerd worden en afvalstoffen die gedurende de tumorgroei ontstaan, uitgescheiden kunnen worden. Cruciale factoren in het proces van angiogenese zijn onder andere angiopoietine (ANGPT) en vasculair endotheel groeifactor (VEGF) die via binding aan specifieke tyrosine kinase receptoren, respectievelijk Tie2 en VEGF receptor, angiogenese kunnen reguleren. Ondanks het feit dat tumoren veel bloedvaten bevatten, worden tumoren vaak gekenmerkt door een relatief laag zuurstofgehalte (hypoxie), een zuur milieu en verhoogde interstitiële druk dat te wijten is aan een abnormaal vaatbed met onrijpe en lekke bloedvaten. Deze abnormale tumorvasculatuur kan het transport en/of de verdeling van chemotherapeutica naar en in de tumor negatief beïnvloeden waardoor de tumor zich ondanks de behandeling kan handhaven of zelfs groei kan vertonen.

Oorspronkelijk werd gedacht dat anti-angiogene therapie zou leiden tot remming van nieuwe bloedvatvorming en/of vernietiging van de reeds bestaande vaten waardoor toevoer van voedingsstoffen naar de tumor voorkomen kon worden. In de loop van de tijd zijn ook andere theorieën beschreven over de mogelijke werking van anti-angiogene therapie. Eén van de theorieën gaat in op de eerder beschreven vaatabnormaliteiten in tumoren. Er wordt gesuggereerd dat in tumoren het abnormale vaatbed te wijten is aan een disbalans tussen pro- en anti-angiogene factoren in het voordeel van de pro-angiogene factoren, waaronder VEGF. Door remming van bijvoorbeeld VEGF met anti-angiogene therapie kan de balans hersteld worden, resulterend in vaatnormalisatie met een verbeterde bloedstroom. Op deze wijze kan chemotherapie de tumor beter bereiken en zal radiotherapie in effectiviteit toenemen doordat er sprake is van een hoger zuurstofgehalte in de tumor. Daarnaast wordt beschreven dat anti-angiogene therapie die specifieke receptor tyrosine kinases remmen, de zogenoemde RTK remmers, niet alleen effectief zijn via angiogene routes om de tumor indirect te bestrijden, maar ook direct gericht zijn op de remming van tumorcelgroei. Echter, als reactie op anti-angiogene therapie kunnen tumor resistentiemechanismen optreden waarbij bijvoorbeeld andere groeifactoren hoger tot expressie komen of tumoren een meer invasief karakter laten zien. Bovendien kunnen tumoren via alternatieve routes ontsnappen aan de gegeven therapie.

Samenvatting

Het proefschrift geeft inzicht in de mogelijke therapeutische geschiktheid van anti-angiogene therapie in kinderhersentumoren. Het onderzoek dat in dit proefschrift wordt beschreven, analyseert het angiogene profiel, de tumorvasculatuur en groeifactor gedreven tumor ontsnappingsmechanismen aan receptor tyrosine kinase (RTK) remmers in kinderhersentumoren.

Voordat wordt ingegaan op de biologische aspecten van angiogenese in kinderhersentumoren, geeft **hoofdstuk 2** een overzicht van reeds gepubliceerde klinische studies over anti-angiogene therapie in kinderhersentumoren en recent gestarte klinische trials. Omdat veel van deze klinische trials nog fase I studies betreffen en nieuwe anti-angiogene middelen in opkomst zijn, lijkt het alsof we nog steeds aan het begin staan van de ontwikkeling en optimalisering van anti-angiogene therapie in kinderhersentumoren.

Hoewel soms veelbelovende resultaten worden beschreven van middelen die VEGF/VEGF receptor signalering remmen of gericht zijn op de ErbB familie, blijven overtuigende resultaten van een anti-angiogene strategie die de overleving van kinderen met een hersentumor significant verbeterd uit. Een verklaring hiervoor zouden mogelijke tumor ontsnappingsmechanismen kunnen zijn, zoals groeifactor gedreven tumorresistentie. Theoretisch zou een dergelijke tumorresistentie overtroffen kunnen worden met een behandeling gericht op verschillende groeifactoren en/of receptoren, oftewel 'multi targeted' therapie. Om daadwerkelijk conclusief te zijn over de effectiviteit van anti-angiogene therapie in kinderhersentumoren is meer onderzoek nodig in de therapeutische werkingsmechanismen en mogelijke tumor ontsnappingsmechanismen zeker met de nu opkomende potentiële anti-angiogene middelen.

Hoofdstuk 3 evalueert aspecten van het angiogene profiel en de tumorvasculatuur gerelateerd aan de overleving in 62 volwassen patiënten met een primair glioblastoom als een angiogenese model in hersentumoren. Vaatdichtheid, turnover van endotheel- en tumorcellen en VEGF-A-D expressie werden geanalyseerd in tumorcoupes die immunohistochemisch gekleurd waren met respectievelijk Ki67/CD34, cleaved caspase-3/CD34 en VEGF-A-D. De ANGPT1/ANGPT2 balans als maat voor vaatstabiliteit werd bepaald met behulp van Real Time RT-PCR. Aangezien VEGF-D hoger tot expressie kwam in het relatief zuurstofarme perinecrotische tumorgebied werd er een mogelijke rol gesuggereerd voor hypoxie geïnduceerde VEGF-D expressie, evenals VEGF-A dat hoger tot expressie komt door hypoxie. Een interessante bevinding was dat de angiopoietine balans werd geïdentificeerd als een prognostische marker in primaire glioblastomen. Angiopoietines zijn sterk geassocieerd met morfologische en functionele veranderingen in de tumorvasculatuur en zijn cruciaal in het proces van tumorangiogenese. De prognostische bevinding van de ANGPT1/ANGPT2 balans steunt de noodzaak voor verder onderzoek naar de geschiktheid van anti-angiogene therapie in primaire glioblastomen, met speciale aandacht voor vaatnormalisatie van de tumorvasculatuur.

In de context van glioblastomen, vaak gezien als een prototype van tumorangiogenese, werd in **hoofdstuk 4** het angiogene profiel en de tumorvasculatuur met vaatmaturiteitsstatus bestudeerd in 27 intracranieële ependymomen bij kinderen (WHO graad II-III). Ondanks een lage turnover van endotheelcellen in ependymomen waren vaatdichtheid en VEGF-A expressie gelijkwaardig aan glioblastomen. Over het algemeen liet de ependymoom vasculatuur minder vaatmaturiteit zien in termen van basaalmembraan- en pericytenbedekking vergeleken met glioblastomen, hoewel deze parameters wel overlappend waren. In ependymomen zal vaatnormalisatie door anti-angiogene middelen mogelijk minder succesvol zijn dan in glioblastomen. Echter gezien individuele ependymomen wel een aanzienlijke overlap vertoonden met glioblastomen, zouden patiënten met een ependymoom of een subgroep van de patiënten mogelijk wel voordeel hebben van anti-angiogene therapie als een toevoeging op chemo- of radiotherapie.

Pilocytaire astrocytomen bij kinderen (WHO graad I) lieten naast verschillen in vaatarchitectuur, een verrassend essentiële overlap zien in vaatimmaturiteit/-instabiliteit en het angiogene profiel met glioblastomen (**hoofdstuk 5**). Verdere analyse van VEGF isovormen die het proces van angiogenese dusdanig kunnen beïnvloeden met verschillen in vaatarchitectuur tot gevolg, vond plaats in **hoofdstuk 6**. Daarbij werden zowel pro- als anti-angiogene isovormen bestudeerd, waarbij gesuggereerd wordt dat de anti-angiogene isovormen kunnen binden aan anti-angiogene middelen, waaronder bevacizumab (anti-VEGF) en daarmee het effect van dergelijke middelen kunnen remmen. Tumoren met een relatief hoge expressie van pro-angiogene isovormen ten opzichte van anti-angiogene factoren zijn mogelijk gevoeliger voor anti-angiogene therapie. Uit hoofdstuk 6 bleek dat het verschil in vaatarchitectuur tussen pilocytaire astrocytomen en glioblastomen niet alleen toegeschreven kon worden aan de expressie van de verschillende VEGF-A isovormen. In lijn met hoofdstuk 5 werd een opmerkelijk overlappende pro- en anti-angiogene VEGF-A isovorm ratio gevonden tussen beide tumoren in het voordeel van de pro-angiogene isovormen. Deze resultaten geven aan dat er mogelijkheden zijn voor het remmen van angiogenese als therapeutische strategie, niet alleen in glioblastomen, maar ook in pilocytaire astrocytomen.

Tevens liet **hoofdstuk 7** minder tumorgroei zien na behandeling met anti-VEGF in een nieuw ontwikkeld laaggradig astrocytoom muismodel. Omdat in laaggradige astrocytomen, VEGF receptor 2 vooral tot expressie komt in endotheelcellen en niet in tumorcellen werd naar verwachting geen direct effect gezien van anti-VEGF op tumorceloverleving of -proliferatie. Aangezien wel effect werd gemeten in het diermodel lijkt de omgeving van de tumor van groot belang te zijn bij de effectiviteit van anti-VEGF in laaggradige astrocytomen. Ook deze studie suggereert weer dat anti-angiogene therapie een potentiële rol zou kunnen vervullen in de therapeutische strategie voor kinderen met een laaggradig astrocytoom. Klinische trials lieten echter geen eenduidig positief resultaat zien van anti-angiogene therapie. Recente studies beschrijven mogelijke tumor ontsnappingsmechanismen die kunnen optreden indien specifieke angiogene factoren worden geremd.

Deze tumor ontsnappingsmechanismen worden niet alleen beschreven tijdens remming van VEGF maar ook tijdens verschillende receptor tyrosine kinase (RTK) remmers die zowel angiogene als oncogene routes remmen. Dergelijke resistentiemechanismen kunnen alternatieve routes includeren van kinase pathway activatie door kinoom reprogrammering of upregulatie van andere receptor tyrosine kinases of hun liganden wat uiteindelijk kan bijdragen aan tumor resistentie tegen RTK remmers met eenzelfde signaaloutput. RTK liganden zoals VEGF, epidermale groeifactor (EGF), hepatocyttaire groeifactor (HGF) en fibroblast groeifactor (FGF) komen tot expressie in de normale neuronale ontwikkeling en worden verwacht aanwezig te zijn in het tumormilieue. De betreffende resistentiemechanismen zouden een mogelijke verklaring kunnen zijn waarom teleurstellende resultaten worden gezien bij 'single targeted' behandelingen zoals beschreven in hoofdstuk 2.

Hoofdstuk 8 laat groeifactor gedreven tumorresistentie zien van vooral EGF, HGF en FGF bij gebruik van RTK remmers (sorafenib, dasatinib, canertinib, crizotinib) in laaggradige astrocytome- en ependymoomcellijnen. Deze resultaten worden zowel gevonden op het niveau van tumorceloverleving als op fosforylatieniveau van downstream targets. De bevindingen benadrukken de potentiële signaal cross talk in RTKs die tot co-expressie komen in deze laaggradige astrocytome- en ependymoomcellijnen. Groeifactor gedreven tumorresistentie kon overtroffen worden met toevoeging van de relevante RTK remmer. Dit pleit voor 'multi targeted' therapie in kinderhersentumoren wat overeenkomt met de bevindingen uit hoofdstuk 2.

Conclusies en toekomstperspectieven

Vandaag de dag vormen hersentumoren nog steeds de nummer één doodsoorzaak bij kinderen met kanker. Omdat angiogenese van groot belang is bij tumorgroei en progressie, is dit mechanisme uitvoerig onderzocht en zijn verschillende anti-angiogene therapieën ontwikkeld. Echter zijn deze studies in kinderen slechts beperkt. Dit proefschrift vergroot het inzicht in het angiogene profiel, de tumorvasculatuur en groeifactor gedreven tumorresistentie bij angiogene remmers in laaggradige astrocytomen en ependymomen. Enerzijds suggereert dit proefschrift een therapeutische geschiktheid voor anti-angiogene therapie in deze tumoren maar anderzijds wordt ook de keerzijde benadrukt, namelijk de mogelijke tumor ontsnappingmechanismen die kunnen optreden als reactie op anti-angiogene therapie. Om het inzicht verder te vergroten in deze mechanismen en om potentiële angiogene middelen te testen, zijn goede preklinische analyses nodig ter optimalisatie, waardoor de vertaling naar klinische trials meer rationeel kan plaatsvinden. Gestreefd zou moeten worden naar een situatie waarin preklinische modellen simultaan lopen met een klinische trial zodat het preklinische model geoptimaliseerd kan worden en mogelijk in toekomstige klinische trials een voorspellende rol kan vervullen. Uiteindelijk zal in de toekomst een meer geïndividualiseerde anti-angiogene therapie zeer waardevol zijn in de behandeling van kinderhersentumoren.



The background is a light, textured surface, possibly paper or canvas, with a subtle, circular, abstract pattern in the lower-left quadrant. The pattern consists of concentric, irregular lines and shapes, rendered in a slightly darker shade than the background. The overall appearance is that of a textured, monochromatic artwork.

Dankwoord / Acknowledgements

Dankwoord

Al heel lang geleden wist ik zeker dat ik arts wilde worden. Tijdens de studie geneeskunde werd de mogelijkheid geboden de artsopleiding te combineren met het verrichten van wetenschappelijk onderzoek, een combinatie die mij zeer aansprak. De periode waarin kliniek en onderzoek elkaar afwisselden heb ik als zeer boeiend en leerzaam ervaren. Voor mij zou het ultieme zijn om als arts de geneeskunde verder te helpen en een patiënt een verbeterde behandeling te kunnen bieden waar we zelf onderzoek naar hebben gedaan. Een toekomstperspectief waarin samenwerking van groot belang zal zijn, net als dat het geval was in de afgelopen jaren. Dit proefschrift was er zeker niet gekomen zonder een belangrijk aantal personen. Een aantal hiervan zou ik in het bijzonder willen noemen.

Alvorens hier specifiek op in te gaan, zou ik de patiënten en ouders van patiënten willen bedanken voor hun toestemming en medewerking in het onderzoek. Zonder hen zou het onderzoek onmogelijk zijn geweest.

Beste prof. dr. De Bont, beste Eveline, heel hartelijk dank voor jouw enthousiaste en kritische begeleiding tijdens het onderzoek. In al die jaren heb ik ontzettend veel van je geleerd en ben ik je dankbaar dat je mij de ruimte en het vertrouwen hebt gegeven om mij te kunnen ontwikkelen binnen het onderzoek en mij allerlei kansen hebt geboden op het gebied van samenwerking. Je strakke bewaking van kwaliteit en het goed kunnen doorpakken, zeker op het laatst in de afronding van dit proefschrift heb ik zeer gewaardeerd.

Beste dr. Den Dunnen, beste Wilfred, ik ben ontzettend blij dat we samen met Eveline als team dit promotietraject zijn ingegaan. Jouw ideeën, literatuurkennis en histologische perspectief waar je mij mee liet kennismaken hebben een belangrijke bijdrage geleverd aan dit proefschrift. Hier ben ik je zeer dankbaar voor, evenals de verschillende technieken die je mij hebt geleerd. Ik heb veel waardering voor je betrokken en open houding, snelle reacties en relativerend vermogen.

Beste prof. dr. Kamps, beste Willem, hartelijk dank voor de mogelijkheid die u mij heeft gegeven onderzoek te verrichten binnen de kinderoncologie.

De leden van de leescommissie, prof. dr. R.G. Grundy, prof. dr. J.M. Kros en prof. dr. G. Molema zou ik graag willen bedanken voor het beoordelen van het manuscript van dit proefschrift.

Prof. dr. Grundy, dear Richard Grundy, thank you very much for participating in the reading committee. It is a great honour for me that you are willing to come over to Groningen to be part of the committee at the defence. Moreover, I would like to thank you very much for giving me the opportunity to learn about the techniques you use in your laboratory and for getting insight into your clinical meetings. Dr. Ruman Rahman, Stuart Smith and off course all other lab members, thank you for sharing your expertise and giving me a warm welcome and nice stay in Nottingham.

De samenwerking met de afdeling Neurochirurgie heb ik zeer gewaardeerd. Beste dr. Hoving, hartelijk dank voor uw betrokkenheid en klinische blik op de manuscripten. Beste Michiel Wagemakers, het is alweer een tijdje geleden, maar hartelijk dank voor de leuke en geslaagde samenwerking in het begintraject. Ik hoop in de kliniek nog veel van jullie te mogen leren. Daarnaast zou ik de andere co-auteurs willen bedanken, waaronder prof. dr. Mooij en prof. dr. Molema voor de kritische inbreng.

De Junior Scientific Masterclass zou ik willen bedanken voor de mogelijkheid het MD/PhD traject te kunnen volgen waarbij de studie geneeskunde gecombineerd wordt met wetenschappelijk onderzoek. Tevens zou ik verschillende stichtingen willen bedanken die mij financieel hebben gesteund tijdens het onderzoek, waaronder de Jan Kornelis de Cock Stichting, het Ubbo Emmius Fonds, de Van der Meer-Boerema Stichting, de Stichting Kinderoncologie Groningen (SKOG) en het Groninger Universiteitsfonds.

De labcollega's van de Kinderoncologie wil ik graag bedanken voor de zeer plezierige samenwerking. Arja, heel hartelijk dank voor je hulp bij de experimenten in het CDP en natuurlijk voor alle gezelligheid tussendoor. Het congres met z'n drieën samen met Kim was zeer geslaagd! Kim, Harm Jan en Tiny, ontzettend bedankt voor jullie praktische hulp en technische adviezen, vooral bij de laatste loodjes van het proefschrift. Het laatste manuscript is dan ook een echte teamprestatie! Heel hartelijk dank voor de leuke tijd op het lab en daarbuiten.

Tevens wil ik mijn kamergenootjes door de jaren heen bedanken: Naomi, Erik, Henk-Marijn, Ellen, Lindy, Sanne, Roeliene, Waldrik en Ronald. Het was heel fijn om van alles te kunnen bespreken op wetenschappelijk gebied, elkaar te kunnen helpen en ondersteunen, maar zeker ook ter ontspanning gezellig met elkaar te kunnen kletsen. Naomi, wij hebben vele onderzoeksuurtjes samen doorgebracht. Bedankt voor de nodige reflectie en alle gezelligheid! Erik, naast kamergenootjes waren wij ook CDP-genootjes, bedankt voor de prettige samenwerking. Ellen, bedankt voor de leuke en gezellige tijd tijdens de AACR meeting en in Washington DC. Sander, Hasan, Alida, Berber, Dicky, Jenny, Neeltje, Bart en Hendrik ook bedankt voor de samenwerking.

Frank, zonder jou was dit proefschrift er niet geweest! Jij hebt mij geduldig wegwijs gemaakt op het lab en meerdere technieken geleerd waar ik je zeer dankbaar voor ben. Jouw betrokken en ontspannen houding samen met jouw kritische benadering van de experimenten heb ik zeer gewaardeerd. Ik ben blij dat ik gedurende het grootste deel van mijn onderzoekstraject met jou heb mogen samenwerken. Super leuk dat je mijn paranimf bent!

Daarnaast zijn er collega's van de Kinderoncologie buiten het lab die ik graag zou willen bedanken. Carolina Homs, jij bent zeer belangrijk geweest voor de logistieke zaken binnen het onderzoekstraject. Ik wil je hartelijk danken voor je bereidwilligheid en adequate hulp. Ook zou ik dr. Sabine Plasschaert en dr. Wim Tissing willen bedanken voor de inbreng en expertise binnen de onderzoeksbesprekingen.

Tevens zou ik de (oud)collega's van de Hematologie willen bedanken voor de gezellige tijd op het Multidisciplinaire Oncologie Lab. Annelies, Annet, Bart-Jan, Burcu, Djoke, Edo, Fiona, Francesco, Gerwin, Hein, Hendrik, Henny, Ingrid, Jeanet, Jenny, JJ, Karen, Lieke, Lina, Marcel, Marco, Marjan, Marta, Matthieu, Monika, Niccoló, Pallavi, Patrick, Rikst Nynke, Sandra O, Sandra R, Sarah, Susan, Szabolcs, Vincent bedankt voor de leuke samenwerking en de gezelligheid ernaast.

Ook de collega's van de Medische en Gynaecologische Oncologie zou ik willen bedanken voor de prettige samenwerking op het lab, de gezelligheid tijdens de borrels, labdagen en AACR meetings. Hetty, als 'lab-mama', in het bijzonder bedankt. Marcel, Marloes, Silke en Vincent wil ik graag bedanken als 'Los Sombreros'-commissiegenootjes voor de leuke tijd tijdens het organiseren van borrels en de labdag.

De collega's van de Pathologie, waarbij ik onder andere heb samengewerkt met Bea, Edwin, Hans, Inge, Marian en Tineke, zou ik willen bedanken voor de uitleg van verschillende technieken en de hulp die mij werd geboden tijdens experimenten.

De medewerkers van het CDP zou ik willen bedanken voor het faciliteren van de experimenten en de logistieke ondersteuning. Daarnaast zou ik dr. Sjef Copray en Annebet van der Meulen willen bedanken voor het aanleren van operatietechnieken en de plezierige samenwerking in het CDP.

Prof. dr. Groen, graag zou ik u willen bedanken voor de mogelijkheid die mij is geboden mijn semi-arts stage bij de Neurochirurgie te lopen en vervolgens als ANIOS op de afdeling te mogen werken. Daarbij heb ik zeer veel waardering voor de prettige werksfeer waarvoor ik mijn collega's zou willen bedanken en met wie ik hoop nog veel te mogen samenwerken.

Cass, Esther, Grace, Marieke en Sylvette, als teamgenootjes wil ik jullie bedanken voor de leuke tijd op en naast de tennisbaan met de gezellige zondagen en fijne ontspanning tussendoor. Laten we er samen nog heel wat gezelligheid aan vastplakken!

Elbrich, bedankt voor alle leuke en gezellige momenten die we hopelijk nog lang kunnen voortzetten! Jorien, Leonie, Paulien, Merette, Saskia en Sophie, inmiddels zijn we al heel wat belevenissen rijker, ik ben blij dat we al zo lang vriendinnen zijn!

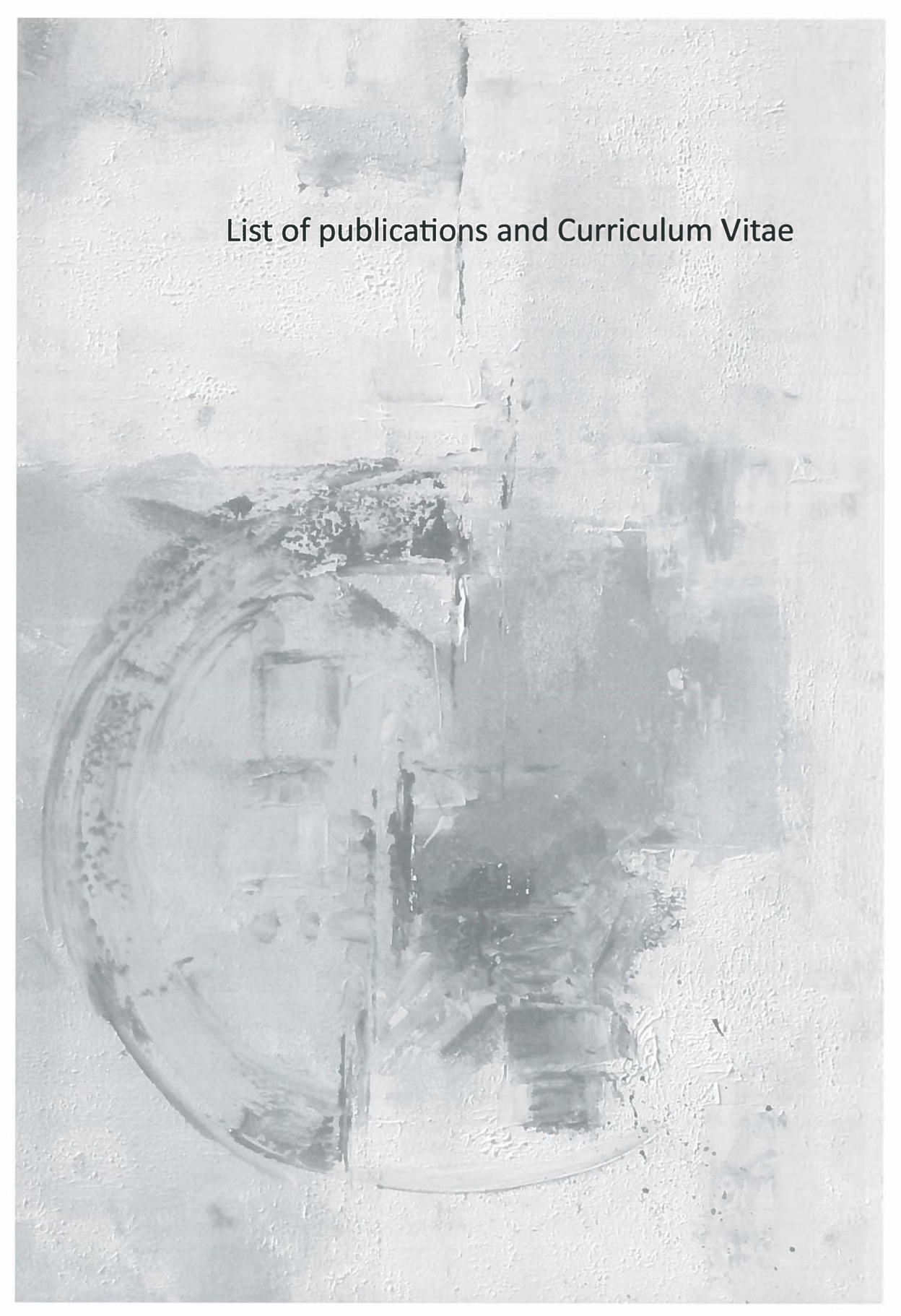
Anne, Carolien en Marloes, heel erg bedankt voor de geweldig leuke tijd die we tot nu toe samen hebben gehad, van wintersport tot jungletochten en van salsacursussen tot snorkelen met schildpadden! Maar ook het even samen op de bank hangen, heb ik altijd heel gezellig gevonden! Ook Germ, Martijn B, Martijn S, Nick en Rutger bedankt voor alle gezelligheid. Hopelijk kunnen we er met z'n allen nog heel wat leuke ervaringen aan toevoegen. Marloes, eerst mocht ik als trotse paranimf naast jou staan, hopelijk zijn de rollen nu omgedraaid. Echt super leuk dat je mijn paranimf bent!

Coen, Gonny, Sebastiaan, Stanzi en Julius, heel hartelijk dank voor alle belangstelling, grote gastvrijheid en een warm welkom binnen jullie gezin.

Mijn familie, lieve mam en pap, ik ben zo blij met jullie en ik ben jullie ongelooflijk dankbaar voor alles wat jullie voor mij hebben gedaan! Ik heb het geluk gehad onbezorgd te mogen opgroeien waarin mij alle kansen werden geboden. Ik hou heel veel van jullie! Lieve Edward en Linda, lieve Richard en Bibian, Lotus en May-Lin, bedankt voor jullie steun en betrokkenheid. Ik ben ontzettend blij dat we familie zijn en ben super trots op jullie!

Allerliefste Matthias, ik ben echt heel gelukkig samen met jou en wil je bedanken voor alles. Jouw bijdrage aan dit proefschrift is groter dan je wellicht zal denken, heel veel dank hiervoor. Ik hou heel veel van je!





List of publications and Curriculum Vitae

List of publications

Articles

Sie M, den Dunnen WFA, Lourens HJ, Meeuwse-de Boer TGJ, Scherpen FJG, Kampen KR, Hoving EW, de Bont ESJM. Growth-factor-driven rescue in pediatric low grade astrocytoma and ependymoma. *Mol Cancer Res*; manuscript submitted.

Sie M, den Dunnen WFA, Hoving EW, de Bont ESJM. Anti-angiogenic therapy in pediatric brain tumors: an effective strategy? *Crit Rev Oncol Hematol* 2013; revision submitted.

Sie M, de Bont ESJM, Scherpen FJG, Hoving EW, den Dunnen WFA. Tumor vasculature and angiogenic profile of paediatric pilocytic astrocytoma; is it much different from glioblastoma? *Neuropathol Appl Neurobiol* 2010; 36: 636-647.

Wagemakers M, Sie M, Hoving EW, Molema G, de Bont ESJM, den Dunnen WFA. Tumor vessel biology in pediatric intracranial ependymoma. *J Neurosurg Pediatrics* 2010; 5: 335-341.

Sie M*, Wagemakers M*, Molema G, Mooij JJA, de Bont ESJM, den Dunnen WFA. The angiopoietin 1/angiopoietin 2 balance as a prognostic marker in primary glioblastoma multiforme. *J Neurosurg* 2009; 110: 147-155.

* These authors contributed equally.

Presentations at international meetings

104th Annual Meeting, American Association for Cancer Research, 2013, Washington, DC, USA. 'Less tumor engraftment after anti-VEGF therapy in pediatric low grade astrocytoma.' Proceedings of the AACR 2013. (*poster presentation*)

Cell Symposia: Angiogenesis, metabolic regulation, and cancer biology in association with VIB, 2012, Leuven, Belgium. 'Overlapping VEGF-A isoform ratios in pilocytic astrocytoma and glioblastoma.' (*poster presentation*)

103rd Annual Meeting, American Association for Cancer Research, 2012, Chicago, IL, USA. 'Overlapping high pro- and anti-angiogenic VEGF-A isoform ratio between pediatric pilocytic astrocytoma and adult glioblastoma suggests possibilities for anti-angiogenic therapy in pilocytic astrocytoma.' Proceedings of the AACR 2012. (*poster presentation*)

International Society for Cellular Oncology Congress, 2012, Palma de Mallorca, Spain. 'VEGF-A isoforms in pilocytic astrocytoma and glioblastoma.' *Cellular Oncology* 2012; 35: suppl 1. (*poster presentation*)

14th International Symposium on Pediatric Neuro-Oncology, 2010, Vienna, Austria. 'Tumor vasculature and angiogenic profile of pediatric pilocytic astrocytoma; is it much different from glioblastoma?' *Neuro-Oncology* 2010; 12: ii1–ii134. (*oral presentation*)

101st Annual Meeting, American Association for Cancer Research, 2010, Washington, DC, USA. 'Tumor vasculature and angiogenic profile of pediatric pilocytic astrocytoma.' *Proceedings of the AACR 2010*. (*poster presentation*)

15th International Student Congress of Medical Sciences, 2008, Groningen, The Netherlands. 'The angiopoietin-1/angiopoietin-2 balance as a prognostic marker in primary glioblastoma multiforme.' (*oral presentation*)

Grants

Jan Kornelis de Cock Stichting Grant 2013. Anti-angiogenic therapy in pediatric brain tumors.

Ubbo Emmius Fonds-Junior Scientific Masterclass (UEF-JSM) Van der Meer-Boerema Stichting Talent Grant 2011. Angiogenesis in pediatric brain tumors.

Jan Kornelis de Cock Stichting Grant 2011. The effect of VEGF/VEGF-receptor targeting on pediatric low grade astrocytoma *in vivo*.

Jan Kornelis de Cock Stichting Grant 2009. Angiogenesis in pilocytic astrocytoma.

Curriculum Vitae

Mariska Sie werd geboren op 18 december 1985 te Groningen. Na het behalen van het VWO-diploma aan het H.N. Werkmancollege te Groningen in 2004, startte zij met de studie Geneeskunde aan de Rijksuniversiteit Groningen. In het tweede jaar van de studie Geneeskunde nam zij deel aan diverse extracurriculaire programmaonderdelen van de Junior Scientific Masterclass. Aansluitend startte zij als derdejaarsstudent in 2006 met het verrichten van wetenschappelijk onderzoek bij de afdeling Kinderoncologie en Pathologie onder begeleiding van prof. dr. E.S.J.M. de Bont en dr. W.F.A. den Dunnen in samenwerking met M. Wagemakers en prof. dr. J.J.A. Mooij van de afdeling Neurochirurgie van het Universitair Medisch Centrum Groningen (UMCG).

In 2009 begon zij met het MD/PhD traject waarbij wetenschappelijk onderzoek onder begeleiding van prof. dr. E.S.J.M. de Bont en dr. W.F.A. den Dunnen gecombineerd werd met coschappen, hetgeen uiteindelijk resulteerde in dit proefschrift. Voor een korte onderzoeksstage ging zij in 2012 naar het Children's Brain Tumour Research Centre, University of Nottingham (United Kingdom) en werd begeleid door prof. dr. R.G. Grundy, dr. R. Rahman en S.J. Smith.

Tijdens haar studie is zij actief geweest in de Jaarvertegenwoordiging van het 2e en 3e jaar van de geneeskundestudievereniging Panacea. Tevens was zij als docent tutor 3 jaar verbonden aan de Faculteit der Medische Wetenschappen van de Rijksuniversiteit Groningen.

In de masterfase van haar studie liep zij de junior coschappen in het UMCG. De senior coschappen werden voltooid in de Isala Klinieken te Zwolle, het Diaconessenhuis Meppel, het Ziekenhuis Bethesda te Hogeveen en bij de Stichting Regionale GezondheidsDienst te Paramaribo en Lelydorp (Suriname). Zij sloot haar studie af met een semi-arts stage bij de afdeling Keel Neus Oor Heelkunde onder begeleiding van dr. R.A. Feijen en bij de afdeling Neurochirurgie onder begeleiding van prof. dr. R.J.M. Groen in het UMCG. In 2012 ontving zij de artsenbul en in 2013 startte zij als ANIOS bij de afdeling Neurochirurgie van het UMCG.

