

University of Groningen

Bone-borne surgically assisted rapid maxillary expansion

Huizinga, Martin P.; Meulstee, Jene W.; Dijkstra, Pieter U.; Schepers, Rutger H.; Jansma, Johan

Published in:
Journal of Cranio-Maxillofacial Surgery

DOI:
[10.1016/j.jcms.2018.05.021](https://doi.org/10.1016/j.jcms.2018.05.021)

IMPORTANT NOTE: You are advised to consult the publisher's version (publisher's PDF) if you wish to cite from it. Please check the document version below.

Document Version
Publisher's PDF, also known as Version of record

Publication date:
2018

[Link to publication in University of Groningen/UMCG research database](#)

Citation for published version (APA):

Huizinga, M. P., Meulstee, J. W., Dijkstra, P. U., Schepers, R. H., & Jansma, J. (2018). Bone-borne surgically assisted rapid maxillary expansion: A retrospective three-dimensional evaluation of the asymmetry in expansion. *Journal of Cranio-Maxillofacial Surgery*, 46(8), 1329-1335. <https://doi.org/10.1016/j.jcms.2018.05.021>

Copyright

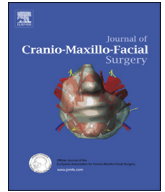Other than for strictly personal use, it is not permitted to download or to forward/distribute the text or part of it without the consent of the author(s) and/or copyright holder(s), unless the work is under an open content license (like Creative Commons).

The publication may also be distributed here under the terms of Article 25fa of the Dutch Copyright Act, indicated by the "Taverne" license. More information can be found on the University of Groningen website: <https://www.rug.nl/library/open-access/self-archiving-pure/taverne-amendment>.

Take-down policy

If you believe that this document breaches copyright please contact us providing details, and we will remove access to the work immediately and investigate your claim.

Downloaded from the University of Groningen/UMCG research database (Pure): <http://www.rug.nl/research/portal>. For technical reasons the number of authors shown on this cover page is limited to 10 maximum.



Bone-borne surgically assisted rapid maxillary expansion: A retrospective three-dimensional evaluation of the asymmetry in expansion



Martin P. Huizinga^{*}, Jene W. Meulstee, Pieter U. Dijkstra, Rutger H. Schepers, Johan Jansma

Department of Oral and Maxillofacial Surgery, (Head: Prof. F.K.L. Spijkervet, DMD, PhD), University Medical Center Groningen, Hanzeplein 1, P.O. Box 30.001, 9700RB, Groningen, The Netherlands

ARTICLE INFO

Article history:

Paper received 30 July 2017

Accepted 7 May 2018

Available online 12 May 2018

Keywords:

Surgically assisted rapid maxillary expansion

Asymmetrical expansion

Bone-borne distractor

Maxillary osteotomy

Imaging, three-dimensional

Palatal expansion technique

ABSTRACT

Purpose: Asymmetrical expansion occurs in patients treated with Surgically Assisted Rapid Maxillary Expansion (SARME). In the clinical setting, this asymmetrical expansion is seen in multiple directions. However, the frequency, actual directions and amount of asymmetry are unclear. Hence, the aim of this study was to analyze the directions and amount of asymmetrical lateral expansion in non-syndromic patients with transversal maxillary hypoplasia on employing bone-borne transpalatal distraction by means of SARME. Treatment involved corticotomies of all four bony supports, including pterygomaxillary disjunction.

Materials and methods: A retrospective case series was formed from patients treated with SARME. Pre- and postdistraction Cone Beam Computed Tomography scans were superimposed. A reference frame was created to analyze lateral expansion asymmetries in five directions.

Results: Clinical relevant asymmetries (>3.0 mm) in at least one of the investigated directions occurred in 55% of the patients. Lateral expansion asymmetries occurred mostly in the inferior-anterior part between the left and right segment and asymmetry in total expansion was noted between the anterior and posterior part of the maxilla.

Conclusion: This study confirms the clinical suspicion that using SARME with a bone-borne distractor and pterygomaxillary disjunction to treat non-syndromic patients with transversal maxillary hypoplasia, results in regular asymmetrical lateral expansion.

© 2018 European Association for Cranio-Maxillo-Facial Surgery. Published by Elsevier Ltd. All rights reserved.

1. Introduction

Skeletally mature patients with functional or aesthetic problems due to transversal hypoplasia of the maxilla can be treated with a combined surgical-orthodontic treatment modality called surgically assisted rapid maxillary expansion (SARME). SARME is indicated in patients with transverse maxillary hypoplasia, inadequate occlusion and a synostosed midpalatal suture. The age to perform SARME is generally considered 14 years and older, although large interindividual variation is seen in midpalatal suture closing in relation to age (Mommaerts, 1999; Koudstaal et al., 2005;

Haghanifar et al., 2017). SARME is applied to release the areas of bony resistance of the maxilla in order to prevent adverse skeletal and dental effects (e.g. alveolar bending, tooth tipping and periodontal membrane compression) during expansion and is combined with pre- and postsurgical orthodontic treatment (Mommaerts, 1999). The treatment results in an increase in transversal maxillary dimension, nasal cavity width and arch perimeter, providing adequate dental arch space for dentition alignment and space for the tongue (Pinto et al., 2001; Matteini and Mommaerts, 2001; Koudstaal et al., 2005; Lagravère et al., 2006; Asscherickx et al., 2016). SARME can be aided by a tooth-borne or a bone-borne transpalatal distractor (TPD). The advantages of a bone-borne palatal distractor have been theorized and weakly proved. The advantages include the following: the forces act directly on the bone at the mechanically desired level; overexpansion is not required; and it prevents dental side effects such as tipping of

^{*} Corresponding author. Afdeling Mondziekten, Kaak- en Aangezichts chirurgie, Hanzeplein 1, P.O. Box 30.001, 9700RB, Groningen, The Netherlands. Fax: +31 50 361 28 31.

E-mail address: mphuizinga@gmail.com (M.P. Huizinga).

anchor teeth and periodontal defects (Koudstaal et al., 2005, 2009a, 2009b; Verstraaten et al., 2010; Nada et al., 2012). Both tooth-borne and bone-borne distractors are well-accepted treatment modalities and have advantages and disadvantages relative to one another. The short- and long-term treatment outcomes have been evaluated extensively as well as the adverse dental effects (Koudstaal et al., 2005, 2009b; Lagravère et al., 2006; Landes et al., 2009; Verstraaten et al., 2010; Nada et al., 2012; Vilani et al., 2012; Asscherickx et al., 2016).

Many surgical procedures exist for mobilising the maxilla, but their use, especially regarding whether or not to dissect the pterygoid plates from the maxilla, vary (Mommaerts, 1999; Pinto et al., 2001; Laudemann et al., 2009; Verstraaten et al., 2010). SARME is a safe treatment with mostly minor problems that can usually be resolved easily (Neyt et al., 2002; Verlinden et al., 2011; Williams et al., 2012).

Clinical asymmetrical expansion was observed on applying SARME. However, the frequency, direction and amount of asymmetry have not yet been quantified, and the predictability of the outcomes of SARME is questioned. The international literature mentions that transversal asymmetrical results occur (Koudstaal et al., 2005, 2009b; Rameiri et al., 2005; Verstraaten et al., 2010; Kober et al., 2011; Verlinden et al., 2011). However, only a few studies focused primarily on the symmetry in maxillary expansion after applying SARME with a bone-borne distractor and pterygomaxillary disjunction (PMD) (Ramieri et al., 2005; Landes et al., 2009; Nada et al., 2012). Quantifying the occurrence, degree and direction of asymmetrical expansion may help clinicians to plan further treatment and to manage patients' treatment expectations. Furthermore, it could aid in suitably modifying the surgical and distraction protocol and orthodontic treatment following distraction.

The aim of this study was to analyze asymmetry in lateral expansion in non-syndromic patients with transversal maxillary hypoplasia undergoing bone-borne transpalatal distraction using SARME, with corticotomies of all four bony supports including pterygomaxillary disjunction. Three-dimensional (3D) analyses of voxel-based superimposed cone beam computed tomography (CBCT) scans of the maxilla were used.

2. Materials and Methods

2.1. Study design and sample

A retrospective case series was formed. The study sample consisted entirely of non-syndromic patients aged ≥ 14 years. They were referred by an orthodontist to the department of Oral and Maxillofacial Surgery at the University Medical Center Groningen (UMCG), Groningen, The Netherlands, between February 2009 and January 2016 for bilateral transpalatal distraction using SARME because of transversal maxillary hypoplasia. Patients were excluded if they failed to go through the activation period or when one of the CBCT scans was inadequate for our newly designed evaluation method.

2.2. Surgical treatment

One experienced oral and maxillofacial surgeon (J.J.) operated on all the patients using the same surgical protocol. All four areas of resistance to lateral forces were mobilised. Bilateral corticotomies were made with a round bur; the piriform aperture passed the zygomatic buttress to the pterygomaxillary junction. The maxilla was detached from the pterygoid process, split midline and mobilised with an osteotome without a full downgraft. The nasal septum was not released from its palatal base, and the

anterior nasal spine was left intact. A bone-borne TPD (Classic or All-in-one, Surgi-Tec, Sint-Denijs-Westrem, Belgium) was placed and fixed as cranially as possible on the palate at, preferably, the level of the second premolar and first molar. After a latency period of 5–7 days, the patients had to activate the distractor once or twice a day (0.33–0.66 mm) until adequate expansion was reached according to the referring orthodontist and treating surgeon. No overexpansion was performed. The distractor was subsequently locked with a blocking screw for a consolidation period of 3 months, during which orthodontic treatment was initiated. Orthodontic treatment commenced no sooner than 6 weeks after the start of the consolidation period. Subsequently, the TPD was removed under local anaesthesia and a second CBCT scan was taken immediately thereafter. Details regarding the treatment protocol and patient characteristics were retrieved from the patient records.

2.3. Image processing and measurements

During the study period, CBCT scans were taken using the i-CAT CBCT (i-CAT, Imaging Sciences International, Hatfield, PA, USA) at 120 kV, 0.3 mm voxel size.

A 3D reconstruction was made of the predistraction and postdistraction CBCT scans using the Maxilim software (Medicim, Mechelen, Belgium) (Fig. 1A). The grey values of the CBCT scans were superimposed using a voxel-based registration method (Fig. 1B). The anterior cranial base and both zygomatic arches were crucial for image-based registration because these landmarks provide accurate and reproducible results, as they are not influenced by treatment (Nada et al., 2011; Magnusson et al., 2012).

The Blender software (Blender Foundation, Amsterdam, the Netherlands) was used to process the generated images of the maxilla further, whereby all skeletal structures, except for the maxilla, were removed (Fig. 1C). A reference frame was then created of both the pre- and postdistraction maxilla (Fig. 2).

A horizontal base-plane was designed at the height of the cement–bone junction between the central incisors to the anterior side of the left and right second molars. Parallel planes were made at 2.5 mm, 6.0 mm and 8.5 mm cranially. Vertical planes were located at the anterior and distal side of the first molars and central incisors, also at the cement–bone junction. This frame was used to locate six corresponding surface areas on both scans to measure the expansion and to determine the asymmetries (Fig. 3).

Subsequently, the rest of the maxillary surface was removed to retain the six corresponding surface areas on both scans, making the lateral expansion visible. Surface based mapping was performed with Matlab software (Mathworks, Natick, MA, USA) using the iterative closest point algorithm (Zhang, 1994). The surface areas of the predistraction maxilla were mapped onto the corresponding surface areas of the postdistraction maxilla. The lateral displacement, perpendicular to the vertical plane of the reference frame, between the corresponding surface areas, was calculated in millimeters (mm). This procedure provided the outcome data of the absolute lateral expansion of the left and right maxillary segments of the surface areas.

Two observers (M.H. and J.M.) image processed half of the study sample each. They created the reference frames to analyze the inter-observer reliability and assessed all six surface areas in three randomly chosen patients independently.

Five independent experienced orthodontists were consulted. They decided that an expansion difference of more than 3.0 mm was clinically relevant. The consensus of the orthodontists was that smaller differences could be compensated by postdistraction orthodontic treatment.

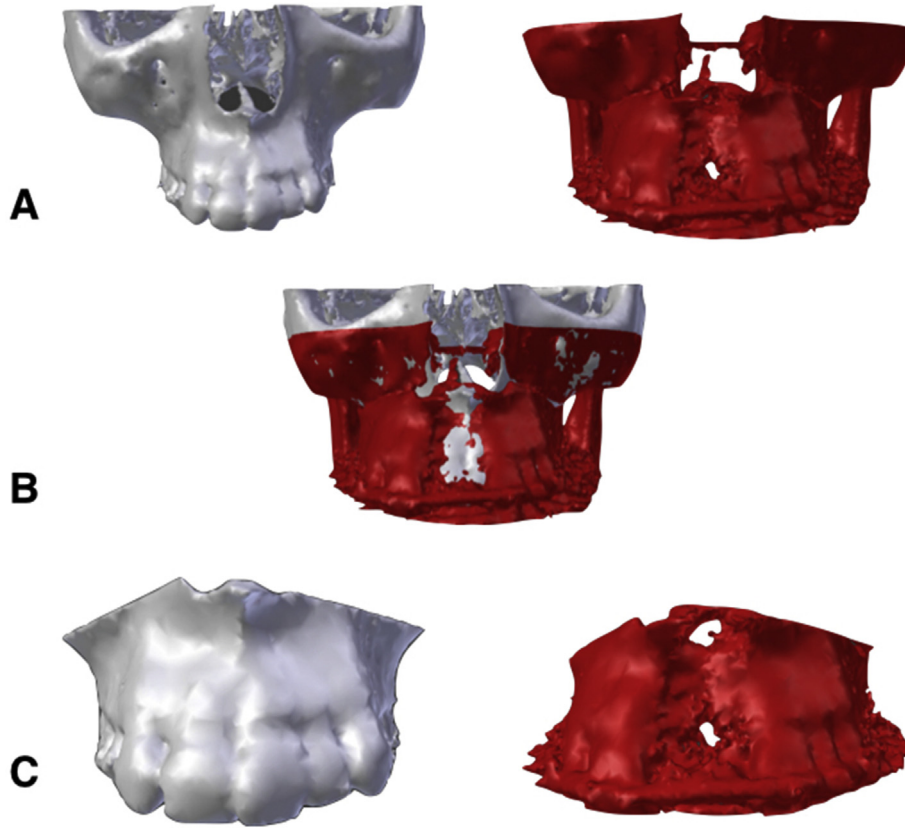


Fig. 1. Three-dimensional (3D) reconstruction of the maxilla. (A) 3D reconstruction of the predistracted (white) and postdistracted (red) cone beam computed tomography (CBCT) scans. (B) Superimposition of both CBCT scans. (C) Pre- and postdistracted maxilla.

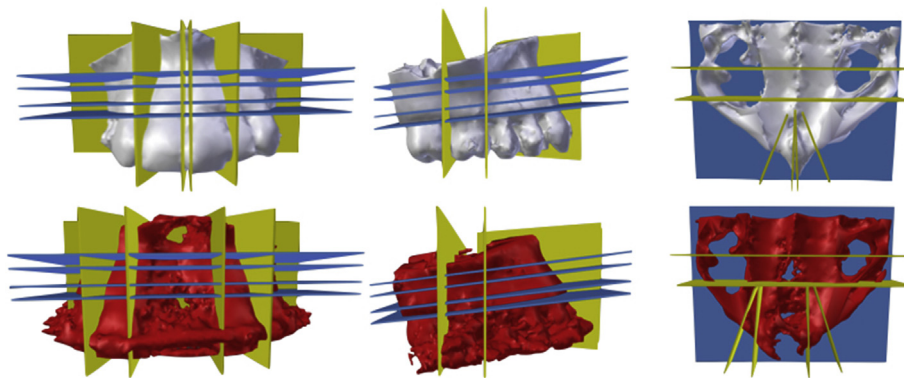


Fig. 2. Positioning of the reference frame on predistracted (white) and postdistracted (red) maxilla; frontal, side and cranial views.

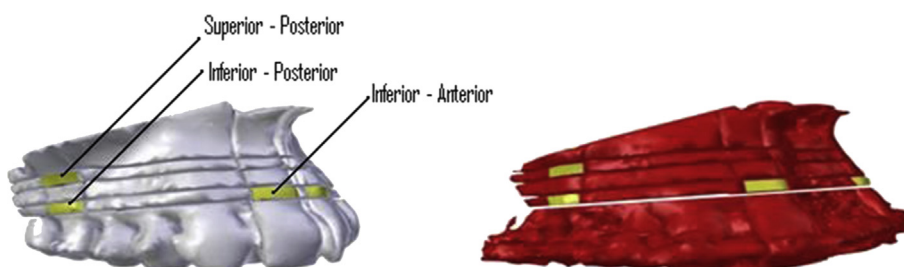


Fig. 3. Corresponding surface areas on predistracted (white) and postdistracted (red) maxilla; diagonal right view.

2.4. Statistical analysis

Differences in lateral expansion between right and left maxillary segments were calculated in three ways: 1) anterior, at the level of the central incisor; 2) posterior, at the level of the first molar inferiorly; and 3) posterior, at the level of the first molar superiorly (Fig. 3). The results of the left side were subtracted from those of the right side; hence positive values indicate a larger expansion of the right maxillary segment.

Differences in lateral expansion between the anterior and posterior aspect of the maxilla were also calculated. The total expansion of both sides at the level of the first molars was subtracted from the total expansion at the level of the incisors. Positive values indicated larger expansion anteriorly.

Finally, expansion asymmetry between the inferior and superior aspect of the maxilla at the level of the first molar was calculated in the same manner. The total expansion of both sides superiorly was subtracted from the total expansion inferiorly. Positive values indicated a larger expansion of the caudal part of the maxilla.

The number of outcome variables in which a clinically relevant asymmetry (>3.0 mm) had occurred was calculated per patient. In addition, the number of outcome variables with an asymmetry of >1.0 mm and >5.0 mm were calculated (see Results). Silverstein and Quinn (1997) state that discrepancies of less than 5.0 mm can be camouflaged by orthopedic forces alone. Asymmetry between the left and right segment was also expressed as a percentage of the total expansion.

Asymmetries might be explained by patient characteristics or particularities during treatment. Associations between these variables and asymmetries were analyzed using the Spearman two-tailed rank correlation or a Mann–Whitney U test ($\alpha = 0.05$). Differences in expansion between the five different sites were analyzed using Friedman's two-way analysis of variance. Analyses were performed in SPSS Statistics 22 (IBM Corporation, Armonk, NY, USA).

To assess interobserver reliability, a paired t-test was performed, and limits of agreement and an intra-class correlation coefficient (ICC; one-way random model, absolute agreement) were calculated.

3. Results

3.1. Patient population

A total of 40 patients were referred for transpalatal distraction. Of those, 20 patients were excluded: one patient was treated with a tooth-borne distractor; two patients underwent intentional unilateral expansion of the maxilla and thus fell outside the scope of this study; no pre- and/or postdistraction CBCT scans were available for nine patients; and, of the final eight patients, one or both of the CBCT scans was not suitable for the described image processing method, because the field of view was too small, the scan quality was unsuitable for superimposition, or the orthodontic brackets caused too much scattering (Fig. 4).

The selected 20 patients (8 female, 12 male) had a median age of 24.5 years (interquartile range: 19.0; 29.8). Each patient achieved the clinically required amount of expansion. Table 1 shows the patient and treatment characteristics (Table 1).

3.2. Treatment characteristics

The same surgical technique was applied to all patients; no differences in treatment protocol were noted in the patient records. No surgical complications occurred. The size of the used distractor differed between patients, depending on the available transversal space on the palate (Table 1). In one patient, the distractor was

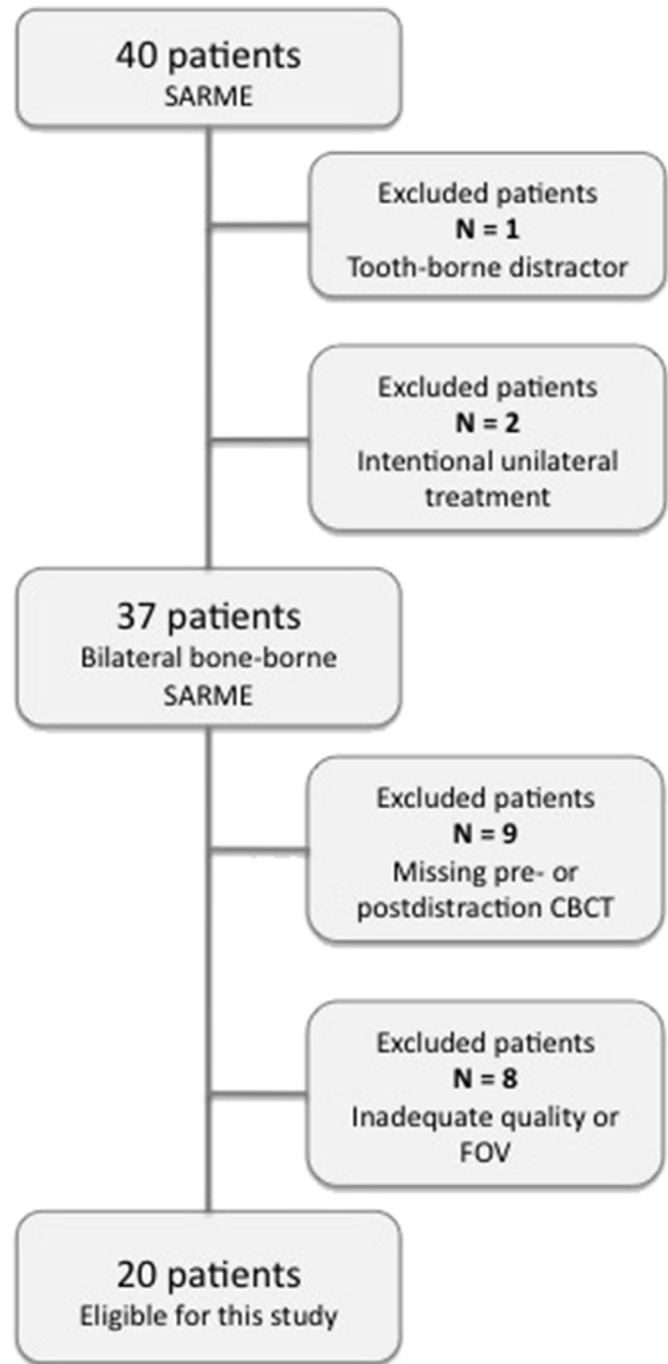


Fig. 4. Flowchart of patient inclusion and exclusion.

removed at the end of the activation period because of recurrent palatal bleedings, but sufficient expansion was achieved. The distractor was replaced with an orthodontic transpalatal arch-bar. This patient's second CBCT scan was performed 4 weeks after removal of the distractor. Furthermore, some minor irregularities, such as spontaneous rewinding of the distractor during expansion, were noted. These irregularities were all instantly corrected.

Fifteen patients subsequently underwent a pre-planned Le Fort 1 osteotomy after the SARME treatment, mostly as part of a bimaxillary osteotomy. Despite some of the patients' clinically experienced asymmetrical expansion, none of them needed unforeseen additional corrective orthognathic surgery of the maxilla

Table 1
Patient treatment characteristics (n = 20).

Characteristic	n	%
Female sex	8	40%
TPD size		
2.0	6	30%
2.5	10	50%
3.0	4	20%
	Median	IQR
Age	25	(19; 30)
Latency ^a	6	(6; 7)
Activation ^a	15	(13; 24)
Consolidation ^a	84	(70; 94)
Inferior Anterior ^b	4.6	(3.3; 7.3)
Inferior Posterior ^b	5.0	(3.7; 7.4)
Superior Posterior ^b	3.4	(2.5; 5.4)

TPD, transpalatal distractor; IQR, interquartile range.

^a Phase, number of days.^b Total expansion (mm).

due to asymmetrical expansion. In all other cases, asymmetries could be corrected by orthodontic treatment.

3.3. Asymmetrical expansion

Median differences in lateral expansion are shown in Table 2. Asymmetric distinctions were made between the right and left maxillary segments.

Clinical relevant asymmetries (>3.0 mm) were found in 11 patients (55%). Asymmetry was found as follows: six patients in one of the five directions; three patients in two directions; one patient in three directions; and one patient in four directions. None of the patients had an asymmetry in all five directions. Asymmetries were not significantly different among the five directions ($p < 0.083$).

Five patients had an asymmetry of >5.0 mm in one or two directions. The direction of asymmetry differed between these patients. In one patient, the left segment remained stationary while the right segment expanded >5.0 mm. In another patient, the left segment remained stationary only in the anterior part. In the third patient, the expansion was larger in the posterior part (>18.0 m) and the expansion in the anterior (>7.0 mm) was normal. This is in contrast to the fourth patient, who experienced a large expansion in the anterior (>14.0 m) because of excessive expansion in the inferior–anterior of the right segment. Normal expansion occurred in the fifth patient in the posterior part (>5.0 mm), while the inferior–anterior expansion was only 1.4 mm.

3.4. Correlations

The size of the distractor correlated inversely with inferior–anterior asymmetry ($\rho = -0.537$, $p = 0.015$) and with

inferior–posterior asymmetry ($\rho = -0.452$, $p = 0.045$). The size of the distractor was not correlated with the total expansion of these outcomes ($\rho = -0.220$, $p = 0.352$ and $\rho = 0.016$, $p = 0.945$ respectively). No associations were found between age, crowding of the maxillary incisors or anterior or posterior open bite.

3.5. Interobserver reliability

The mean difference between the two observers was 0.12 mm (SD: 0.42, 95% CI: -0.02 to 0.26). Limits of agreement were -0.70 and 0.94. This indicates that the difference between the observers was <1.0 mm. The ICC was 0.996 (95% CI: 0.991 to 0.998).

4. Discussion

Clinically relevant asymmetric expansion (>3.0 mm) occurred in at least one direction in 55% of the patients. This was observed most often at the level of the incisors and between the anterior and posterior part of the maxilla. The asymmetry was about one-half of the total expansion at the level of the incisors, about one-fifth between the anterior and posterior part of the maxilla and, regarding cranial-caudal expansion, asymmetry was about one-sixth at the level of the molars. Minor maxillary tipping occurred in all patients. There was no statistically significant difference among the five parameters measured.

In addition, when considering an asymmetrical cut-off point of >1.0 mm, 19 patients had asymmetries in one or more directions. However, the clinical relevance of an asymmetry of less than 3.0 mm was deemed to be small in the opinion of the orthodontists. When considering an asymmetrical cut-off point of >5.0 mm (Silverstein and Quinn, 1997), 25% of the patients still had an asymmetry in one or two directions. Most of these were in the axial plane, comparable to a cut-off point of 3.0 mm.

Only the distractor size was associated with asymmetry.

4.1. Anterior–posterior asymmetry

The position of the distractor and pterygomaxillary disjunction seems to be a key factor in parallel lateral expansion (Pinto et al., 2001; Matteini and Mommaerts, 2001; Laudemann et al., 2009; Nada et al., 2012). Despite a recent systematic review (Hamed Sangsari et al., 2016), there is some consensus that placing the distractor not further anterior than at the level of the first molar and performing PMD will indeed yield parallel expansion in the axial plane (Ramieri et al., 2005; Koudstaal et al., 2005; Verstraaten et al., 2010).

Placing the distractor in the second premolar and first molar region was dependent on available intra-oral space. The exact location of the distractor was not retrievable. Installing the distractor in a slightly more anterior position in our patients could

Table 2
Median differences (mm) and 25th and 75th percentiles in lateral expansion.

	Median	25th percentile	75th percentile	>1.0 mm n (%)	>3.0 mm n (%)	>5.0 mm n (%)	Difference in expansion as a percentage of the total expansion Mean (SD)/Med [IQR]
Δ Inferior–anterior ^a	0.36	-1.42	3.29	14 (70)	6 (30)	2 (10)	48.8 (29.0)/45.0 [21.0 to 74.5]
Δ Inferior–posterior ^a	-0.03	-0.54	1.74	9 (45)	4 (20)	1 (5)	24.1 (25.4)/14.3 [2.9 to 47.4]
Δ Superior–posterior ^a	0.10	-0.45	1.46	8 (40)	3 (15)	0 (0)	29.0 (26.1)/26.6 [5.6 to 45.7]
Δ Anterior vs. posterior ^b	-0.53	-1.40	1.13	12 (60)	6 (30)	4 (20)	
Δ Caudal vs. cranial ^c	1.51	0.69	1.93	15 (75)	0 (0)	0 (0)	

Med, median; IQR, interquartile range; SD, standard deviation.

Positive values indicate greater expansion.

^a Of the right maxillary segment.^b Of the anterior part of the maxilla.^c Of the caudal part of the maxilla.

explain excessive anterior expansion. However, in three out of the six patients with an anterior–posterior asymmetry of >3.0 mm (and two out of four with >5.0 mm asymmetry) the posterior part of the maxilla expanded more than the anterior. This is in contrast to findings in a previous study (Landes et al., 2009).

PMD was performed in all our patients, regardless of their age. Excessive decline in lateral width from anterior to posterior was not seen in our younger patients (<20 years) as described in a previous study (Laudemann et al., 2009).

It is likely that differences in the amount of resistance of the surrounding soft tissues had a substantial influence on the differences in expansion between the various parts of the maxilla (Koudstaal et al., 2009a, 2009b). In all patients, the maxilla was considered to be well mobilized during surgery. The degree of maxillary mobilization probably has no influence on the occurrence of asymmetry (Koudstaal et al., 2009a).

4.2. Left–right asymmetry

Only one study describes the asymmetry between the left and right maxillary segments in patients with a bone-borne distractor with PMD (Nada et al., 2012). The investigators found an asymmetry in posterior lateral expansion of >1.5 mm in 17.6% of their patients treated with bone-borne distractors. In a post hoc analysis, we calculated the percentage of patients who had an asymmetry of >1.5 mm in posterior lateral expansion. In our study, 7 out of 20 patients (35%) had asymmetry in the inferior–posterior and superior–posterior direction of >1.5 mm. However, a study by Nada et al. (2012) found that the mean total expansion in the posterior, being the expansion of the left and right maxillary segment combined, was 3.6 mm. An asymmetry of 1.5 mm is 41.7% of this mean total posterior lateral expansion. This is considerably more than 29.9% of the mean total posterior expansion in the inferior–posterior direction in our study. Nada et al. do not give the actual size of the asymmetries larger than 1.5 mm; this, together with a different expansion rate and apparently more anterior placement of the distractor, makes comparison difficult. In our study, most asymmetries occurred between the left and right segment in the anterior aspect of the maxilla. Half of our patients (10 out of 20) had an asymmetry of >1.5 mm and 30% had an asymmetry of >3.0 mm in this direction. Based on both studies, it can be concluded that left–right asymmetry occurs fairly regularly, especially at the level of the incisors.

Apart from the above-mentioned differences in resistance of the surrounding soft tissues and placement of the distractor on the axial axis, the orientation of the distractor in the transversal plane might also play a role. A narrow and high palatal vault can make it technically difficult to symmetrically align the distractor between the left and right palatal walls. Transversal asymmetry may occur when the direction of the forces exerted by the distractor is oblique (Ramieri et al., 2005).

4.3. Inferior–superior asymmetry

More lateral expansion occurred inferiorly than superiorly in all patients, at the level of the first molar. However, the asymmetries were small. Previous studies also showed some tipping of the segments in bone-borne SARME, comparable to tooth-borne SARME (Matteini and Mommaerts, 2001; Koudstaal et al., 2009a; Verstraaten et al., 2010; Nada et al., 2012). Theoretically, placing the distractor parallel to the center of resistance should give a symmetrical horizontal expansion. Segmental tipping can be decreased by placing the distractor as cranially against the roof of the palatal vault as possible (Pinto et al., 2001).

In our study, it was not possible to differentiate between tipping of the maxillary segments, alveolar bending and tipping of the teeth because the surface areas were two-dimensional areas created at the outer surface of the alveolar process. The movement of the underlying structures could not be visualized.

4.4. Strengths, Limitations and Future Research

This study used CBCT scans taken directly after removal of the distractor at the end of the consolidation period, and we report on the asymmetries of the surgical part of the combined orthodontic–surgical procedure. Long-term stability was not a focus of this study.

With the surface areas for measurement projected on the buccal cortex of the dentition, orthodontic treatment that is executed during the consolidation period could have had an influence on the outcome. However, due to the timing of the start of orthodontic treatment, approximately halfway through the consolidation period, and the small interquartile range of the consolidation period, major orthodontic influence is not expected. In future research, the second CBCT scan should preferably be taken directly at the end of the expansion period before the start of any post-operative orthodontic treatment, provided that scattering of the distractor does not hamper the placement of the surface areas for measurement. Also new surface areas for measurements that are not related to the dentition should be considered.

This was a retrospective study design; hence no standardized protocol existed for the CBCT scanning. The CBCT scans used for evaluation purposes have to be of good quality, and the field of view has to be adequate. In our study, 17 of a total of 40 patients could not be included due to inadequate CBCT scans, which made superimposition impossible. The CBCT scanner had a voxel size of 0.3 mm; the mean interobserver difference of 0.12 mm is within one voxel and adequate for this study. To increase interobserver difference, nowadays a CBCT scanner with a higher resolution could be used. A standardised scan protocol could have greatly improved the study sample and should be used in future prospective studies.

In contrast to a previous study (Falter et al., 2013), no additional or adjustment of pre-planned secondary corrective surgery due to asymmetrical expansion was necessary in our population, probably because follow-up orthognathic surgery was already part of the initial treatment plans.

Considering the above-mentioned factors contributing to asymmetrical expansion, it seems that careful positioning of the distractor is essential in minimizing these asymmetries. Time and effort should be expended to orient the distractor to the roof of the palatal vault at the level of the first molar parallel to the midline and palate. Nevertheless, a subsequent Le Fort 1 osteotomy to compensate for any asymmetries should be taken into consideration in the preoperative treatment planning and be discussed with the patient.

A suggestion for future research would be to conduct a prospective study with a clear uniform protocol for surgery, distraction, consolidation, orthodontic treatment timing, CBCT scanning and three-dimensional evaluation.

5. Conclusion

This study confirms the clinical suspicion of regular asymmetrical lateral expansion in patients with transversal maxillary hypoplasia treated using SARME with pterygomaxillary disjunction and a bone-borne distractor. Lateral expansion asymmetry occurs in all directions, particularly at the level of the incisors between the left and right maxillary segments and between the anterior and posterior parts of the maxilla.

Time and effort should be expended to orient the distractor to the roof of the palatal vault at the level of the first molar parallel to the midline and palate. The necessity for corrective orthognathic surgery following SARME should be taken into account and discussed with the patient during treatment planning.

Funding

This research did not receive a specific grant from funding agencies in the public, commercial, or not-for-profit sectors.

Conflicts of interest

The authors declare that they have no conflict of interest with regard to this work.

References

- Asscherickx K, Govaerts E, Aerts J, Vannet vande B: Maxillary changes with bone-borne surgically assisted rapid palatal expansion: a prospective study. *Am J Orthod Dentofacial Orthop* 149: 374–383, 2016
- Falter B, Schepers S, Vrielinck L, Lambrechts I, Politis C: Predicted versus executed surgical orthognathic treatment. *J Craniomaxillofac Surg* 41: 547–551, 2013
- Haghanifar S, Mahmoudi S, Foroughi R, Poorsatter Bejeh Mir A, Mesgarani A, Bijani A: Assessment of midpalatal suture ossification using cone-beam computed tomography. *Electron Physician* 9: 4035–4041, 2017
- Hamedi Sangsari A, Sadr-Eshkevari P, Al-Dam A, Friedrich RE, Freymiller E, Rashad A: Surgically assisted rapid palatamaxillary expansion with or without pterygomaxillary disjunction: a systematic review and meta-analysis. *J Oral Maxillofac Surg* 74: 338–348, 2016
- Kober C, Kannenberg S, Frank B, Al-Hakim G, Parvin A, Landes C, et al: Computer-assisted pre- and postoperative evaluation of surgically assisted rapid maxillary expansion. *Int J Comput Dent* 14: 233–241, 2011
- Koudstaal MJ, Poort LJ, van der Wal KGH, Wolvius EB, Prahm-Andersen B, Schulten AJM: Surgically assisted rapid maxillary expansion (SARME): a review of the literature. *Int J Oral Maxillofac Surg* 34: 709–714, 2005
- Koudstaal MJ, Smeets JBJ, Kleinrensink GJ, Schulten AJM, van der Wal KGH: Relapse and stability of surgically assisted rapid maxillary expansion: an anatomic biomechanical study. *J Oral Maxillofac Surg* 67: 10–14, 2009a
- Koudstaal MJ, Wolvius EB, Schulten AJM, Hop WCJ, van der Wal KGH: Stability, tipping and relapse of bone-borne versus tooth-borne surgically assisted rapid maxillary expansion; a prospective randomized patient trial. *Int J Oral Maxillofac Surg* 38: 308–315, 2009b
- Lagravère MO, Major PW, Flores-Mir C: Dental and skeletal changes following surgical assisted rapid maxillary expansion. *Int J Oral Maxillofac Surg* 35: 481–487, 2006
- Landes CA, Laudemann K, Schübel F, Petruchin O, Mack M, Kopp S, et al: Comparison of tooth- and bone-borne devices in surgically assisted rapid maxillary expansion by three-dimensional computed tomography monitoring: transverse dental and skeletal maxillary expansion, segmental inclination, dental tipping, and vestibular bone resorption. *J Craniofac Surg* 20: 1132–1141, 2009
- Laudemann K, Petruchin O, Mack MG, Kopp S, Sader R, Landes CA: Evaluation of surgically assisted rapid maxillary expansion with or without pterygomaxillary disjunction based upon preoperative and post-expansion 3D computed tomography data. *Oral Maxillofac Surg* 13: 159–169, 2009
- Magnusson A, Bjerklind K, Kim H, Nilsson P, Marcusson A: Three-dimensional assessment of transverse skeletal changes after surgically assisted rapid maxillary expansion and orthodontic treatment: a prospective computerized tomography study. *Am J Orthod Dentofacial Orthop* 142: 825–833, 2012
- Matteini C, Mommaerts MY: Posterior transpalatal distraction with pterygoid disjunction: a short-term model study. *Am J Orthod Dentofacial Orthop* 120: 498–502, 2001
- Mommaerts MY: Transpalatal distraction as a method of maxillary expansion. *Br J Oral Maxillofac Surg* 37: 268–272, 1999
- Nada RM, Maal TJJ, Breuning KH, Bergé SJ, Mostafa YA, Kuijpers-Jagtman AM: Accuracy and reproducibility of voxel based superimposition of cone beam computed tomography models on the anterior cranial base and the zygomatic arches. *PLoS One* 6: 1–8, 2011
- Nada RM, Fudalej PS, Maal TJJ, Bergé SJ, Mostafa YA, Kuijpers-Jagtman AM: Three-dimensional prospective evaluation of tooth-borne and bone-borne surgically assisted rapid maxillary expansion. *J Cranio Maxill Surg* 40: 757–762, 2012
- Neyt NMF, Mommaerts MY, Abeloos JVS, Clercq de CAS, Neyt LF: Problems, obstacles and complications with transpalatal distraction in non-congenital deformities. *J Craniomaxillofac Surg* 30: 139–143, 2002
- Pinto PX, Mommaerts MY, Wreakes G, Jacobs WVGJA: Immediate postexpansion changes following the use of the transpalatal distractor. *J Oral Maxillofac Surg* 59: 994–1000, 2001
- Ramieri GA, Spada MC, Austa M, Bianchi SD, Berrone S: Transverse maxillary distraction with a bone-anchored appliance: dento-periodontal effects and clinical and radiological results. *Int J Oral Maxillofac Surg* 34: 357–363, 2005
- Silverstein K, Quinn PD: Surgically-assisted rapid palatal expansion for management of transverse maxillary deficiency. *J Oral Maxillofac Surg* 55: 725–727, 1997
- Verlinden CRA, Gooris PG, Becking AG: Complications in transpalatal distraction osteogenesis: a retrospective clinical study. *J Oral Maxillofac Surg* 69: 899–905, 2011
- Verstraeten J, Kuijpers-Jagtman AM, Mommaerts MY, Bergé SJ, Nada RM, Schols JGJH: A systematic review of the effects of bone-borne surgical assisted rapid maxillary expansion. *J Cranio Maxill Surg* 38: 166–174, 2010
- Vilani GNL, Mattos CT, Oliveira Ruellas de AC, Maia LC: Long-term dental and skeletal changes in patients submitted to surgically assisted rapid maxillary expansion: a meta-analysis. *Oral Surg Oral Med Oral Pathol Oral Radiol* 114: 689–697, 2012
- Williams BJD, Currimbhoy S, Silva A, O’Ryan FS: Complications following surgically assisted rapid maxillary expansion: a retrospective cohort study. *J Oral Maxillofac Surg* 70: 2394–2402, 2012
- Zhang Z: Iterative point matching for registration of free-form curves and surfaces. *Int J Comput Vis* 13: 119–152, 1994