

University of Groningen

## Wilson's Disease in Children

Socha, Piotr; Janczyk, Wojciech; Dhawan, Anil; Baumann, Ulrich; D'Antiga, Lorenzo; Tanner, Stuart; Iorio, Raffaele; Vajro, Pietro; Houwen, Roderick; Fischler, Björn

*Published in:*  
Journal of Pediatric Gastroenterology and Nutrition

*DOI:*  
[10.1097/MPG.0000000000001787](https://doi.org/10.1097/MPG.0000000000001787)

**IMPORTANT NOTE: You are advised to consult the publisher's version (publisher's PDF) if you wish to cite from it. Please check the document version below.**

*Document Version*  
Publisher's PDF, also known as Version of record

*Publication date:*  
2018

[Link to publication in University of Groningen/UMCG research database](#)

### *Citation for published version (APA):*

Socha, P., Janczyk, W., Dhawan, A., Baumann, U., D'Antiga, L., Tanner, S., Iorio, R., Vajro, P., Houwen, R., Fischler, B., Dezsofi, A., Hadzic, N., Hierro, L., Jahnel, J., McLin, V., Nobili, V., Smets, F., Verkade, H. J., & Debray, D. (2018). Wilson's Disease in Children: A Position Paper by the Hepatology Committee of the European Society for Paediatric Gastroenterology, Hepatology and Nutrition. *Journal of Pediatric Gastroenterology and Nutrition*, 66(2), 334-344. <https://doi.org/10.1097/MPG.0000000000001787>

### **Copyright**

Other than for strictly personal use, it is not permitted to download or to forward/distribute the text or part of it without the consent of the author(s) and/or copyright holder(s), unless the work is under an open content license (like Creative Commons).

The publication may also be distributed here under the terms of Article 25fa of the Dutch Copyright Act, indicated by the "Taverne" license. More information can be found on the University of Groningen website: <https://www.rug.nl/library/open-access/self-archiving-pure/taverne-amendment>.

### **Take-down policy**

If you believe that this document breaches copyright please contact us providing details, and we will remove access to the work immediately and investigate your claim.

*Downloaded from the University of Groningen/UMCG research database (Pure): <http://www.rug.nl/research/portal>. For technical reasons the number of authors shown on this cover page is limited to 10 maximum.*

# Wilson's Disease in Children: A Position Paper by the Hepatology Committee of the European Society for Paediatric Gastroenterology, Hepatology and Nutrition

\*Piotr Socha, \*Wojciech Janczyk, †Anil Dhawan, ‡Ulrich Baumann, §Lorenzo D'Antiga, ||Stuart Tanner, ¶Raffaele Iorio, #Pietro Vajro, \*\*Roderick Houwen, ††Björn Fischler, ‡‡Antal Dezsofi, §§Nedim Hadzic, ||||Loreto Hierro, ¶¶Jörg Jahnel, ###Valérie McLin, \*\*\*Valerio Nobili, †††Francoise Smets, ‡‡‡Henkjan J. Verkade, and §§§Dominique Debray

## ABSTRACT

**Background:** Clinical presentations of Wilson's disease (WD) in childhood ranges from asymptomatic liver disease to cirrhosis or acute liver failure, whereas neurological and psychiatric symptoms are rare. The basic diagnostic approach includes serum ceruloplasmin and 24-hour urinary copper excretion. Final diagnosis of WD can be established using a diagnostic scoring system based on symptoms, biochemical tests assessing copper metabolism, and molecular analysis of mutations in the *ATP7B* gene. Pharmacological treatment is life-long and aims at removal of copper excess by chelating agents as D-penicillamine, trientine, or inhibition of intestinal copper absorption with zinc salts. Acute liver failure often requires liver transplantation. This publication aims to provide recommendations for diagnosis, treatment, and follow-up of WD in children.

**Methods:** Questions addressing the diagnosis, treatment, and follow-up of WD in children were formulated by a core group of ESPGHAN members. A systematic literature search on WD using MEDLINE, EMBASE, Cochrane Database from 1990 to 2016 was performed focusing on prospective and retrospective studies in children. Quality of evidence was assessed according to the GRADE system. Expert opinion supported recommendations where the evidence was regarded as weak. The ESPGHAN core group and ESPGHAN Hepatology Committee members voted on each recommendation, using the nominal voting technique.

**Key Words:** children, diagnosis, hepatitis, liver, treatment, Wilson's disease

(*JPGN* 2018;66: 334–344)

Received April 23, 2017; accepted August 11, 2017.

From the \*Department of Gastroenterology, Hepatology, Nutritional Disorders and Pediatrics, The Children's Memorial Health Institute, Warsaw, Poland, the †Paediatric Liver GI and Nutrition Center, King's College Hospital, London, UK, the ‡Division of Paediatric Gastroenterology and Hepatology, Department of Paediatric Kidney, Liver and Metabolic Diseases, Hannover Medical School, Hannover, Germany, the §Paediatric Hepatology, Gastroenterology and Transplantation, Hospital Papa Giovanni XXIII, Bergamo, Italy, the ||Children's Hospital, Sheffield, UK, the ¶Department of Translational Medical Science, Section of Pediatrics, University of Naples Federico II, Naples, the #Dipartimento di Medicina e Chirurgia, University of Salerno, Fisciano SA, Italy, the \*\*Department of Paediatrics, Wilhelmina Children's Hospital, University Medical Center Utrecht, Utrecht, The Netherlands, the ††Department of Paediatrics, CLINTEC, Karolinska Institute, Karolinska University Hospital, Stockholm, Sweden, the ‡‡First Department of Paediatrics, Semmelweis University, Budapest, Hungary, the §§Paediatric Centre for Hepatology, Gastroenterology and Nutrition, King's College Hospital, London, UK, the ||||Paediatric Hepatology Service, Hospital Infantil Universitario "La Paz," Madrid, Spain, the ¶¶Department of Paediatrics and Adolescent Medicine, Medical University of Graz, Graz, Austria, the ###Paediatric Gastroenterology Unit, Department of Pediatrics, University

## What Is Known

- Guidelines on diagnosis and treatment of Wilson's disease concerning mainly adults.

## What Is New

- The most updated systematic review of literature related mainly to management of Wilson's disease in childhood.
- Specific criteria for diagnosis of Wilson's disease in children, including diagnosis in early childhood and screening.
- Recommendations on choice of therapy depending on age and severity of liver damage in children with Wilson's disease.

Hospitals Geneva, Geneva, Switzerland, the \*\*\*Hepatometabolic Unit, Bambino Gesù Children's Hospital, Rome, Italy, the †††Université Catholique de Louvain-IREC-Cliniques Universitaires Saint-Luc-Pediatric Gastroenterology and Hepatology Unit, Brussels, Belgium, the ‡‡‡Department of Paediatrics, University of Groningen, University Medical Center Groningen, Groningen, The Netherlands, and the §§§Paediatric Hepatology Unit, Centre National de Référence de la Maladie de Wilson, Hôpital Necker-APHP, Paris, France.

Address correspondence and reprint requests to Wojciech Janczyk, MD and Piotr Socha, MD, PhD, Department of Gastroenterology, Hepatology, Nutritional Disorders and Pediatrics, The Children's Memorial Health Institute, Al. Dzieci Polskich 20, 04-730 Warszawa, Poland (e-mail: w.janczyk@ipezd.pl, p.socha@ipezd.pl).

Drs Socha and Janczyk contributed equally to this article.

"ESPGHAN is not responsible for the practices of physicians and provides guidelines and position papers as indicators of best practice only. Diagnosis and treatment is at the discretion of physicians".

Copyright © 2017 by European Society for Pediatric Gastroenterology, Hepatology, and Nutrition and North American Society for Pediatric Gastroenterology, Hepatology, and Nutrition

DOI: 10.1097/MPG.0000000000001787

Wilson's disease (WD) is an autosomal recessive genetic disorder of copper metabolism with an estimated prevalence of approximately 1:30,000 (1). It is caused by mutations in the *ATP7B* gene encoding a copper transporting P-type ATPase required for copper excretion into the bile (2). This defect results in progressive toxic accumulation of copper in the liver that begins in infancy when copper-containing solids are introduced in the diet. With increasing copper overload over time, deposition of copper in other organs, such as the nervous system, corneas, kidneys, and heart, occurs usually during the second decade or later. If WD is not recognized and adequately treated, the progression of liver disease to cirrhosis and liver failure can be rapid or irreversible brain damage can occur. Diagnosis of WD is difficult in children because they are often asymptomatic and conventional criteria established for adults may not be appropriate (3,4).

The aim of this position paper was to recommend appropriate steps for diagnosis, treatment, and follow-up of children with WD.

## METHODS

A core group of ESPGHAN members (P.S., W.J., A.D., L.D.A., S.T., R.I., P.V., R.H.) formulated questions relevant for the diagnosis and treatment of WD in children, which were agreed by the ESPGHAN Hepatology Committee (B.F., A.D., N.H., L.H., J.J., V.M., V.N., F.S., H.V., U.B., D.D.). To approach these questions, systematic reviews, prospective, and retrospective cohort or controlled studies from 1986 to 2016 in children <18 years and adults if evidence in children was lacking were searched in

EMBASE, MEDLINE, Cochrane Database of Systematic Reviews, and Cochrane Central Register of Controlled Clinical Trials. The following key words, WD, symptoms, diagnosis, liver, ceruloplasmin, copper, treatment, penicillamine, zinc, trientine, and children, were used to identify relevant articles. Articles in languages other than English and French, animal studies, and abstracts presented only during conference proceedings were excluded.

Using the GRADE system (1 for strong recommendation; 2 for weak recommendation), the quality of evidence of each recommendation was graded as follows (5):

1. High (A): Further research is unlikely to change our confidence in the estimate of effect.
2. Moderate (B): Further research is likely to have impact on our confidence in the estimate of effect and may change the estimate.
3. Low (C) Any estimate of effect is very uncertain.

## Consensus Meeting and Voting

A first draft of the position paper was discussed with the ESPGHAN Hepatology Committee members. The core group and Hepatology Committee members voted on each recommendation, using the nominal voting technique. Expert opinion supported recommendations where the evidence was regarded as weak.

Recommendations were accepted if they received >75% positive votes and are presented in Table 1.

TABLE 1. Recommendations of the ESPGHAN Hepatology Committee

- 1 WD should be considered in the differential diagnosis of children older than 1 year presenting with any sign of liver disease ranging from asymptotically increased serum transaminases to cirrhosis with hepatosplenomegaly and ascites or ALF. **Grade 1A (level of agreement: 86%)**
- 2 WD should be ruled out in any teenager with unexplained cognitive, psychiatric, or movement disorder. **Grade 1A (96%)**
- 3 Diagnostic testing for WD in suspected patients should include liver function tests (serum transaminases, conjugated and total bilirubin; alkaline phosphatase and prothrombin time/INR), serum ceruloplasmin, and 24-hour urinary copper. **Grade 1A (96%)**
- 4 The Ferenci scoring system should be applied to children for diagnosis of WD. Mutation analysis of the *ATP7B* gene may facilitate the diagnosis. **Grade 1A (91%)**
- 5 Copper estimation in the liver tissue could be helpful in children where the diagnosis is uncertain. **Grade 1C (100%)**
- 6 Once WD diagnosis is confirmed in the proband, WD should be sought in first degree relatives including siblings, offspring, and parents by performing liver function tests, explorations of copper metabolism, and targeted molecular analysis. **Grade 1A (100%)**
- 7 Given its safety profile, zinc salts, preferably zinc acetate, could be used in presymptomatic children identified through family screening, or as maintenance therapy after de-coppering with chelators as long as serum transaminase levels remain normal. **Grade 2C (96%)**
- 8 Children with signs of significant liver disease, such as cirrhosis or abnormal INR, should be preferably treated with copper chelating agents. **Grade 2B (96%)**
- 9 Dietary restriction of copper-rich foods is advised until remission of symptoms and normalization of liver enzymes in children treated with copper chelating agents. **Grade 2C (82%)**
- 10 Children with ALF or decompensated liver cirrhosis should be transferred to and managed in pediatric liver transplantation centers. **Grade 1A (100%)**
- 11 Children with decompensated liver cirrhosis should be treated with a chelating agent or a combination of zinc salts and a chelating agent that may preclude the need for a liver transplantation. The King's Wilson index should be monitored for prognostic assessment and timely decision for LT. **Grade 2B (96%)**
- 12 Because liver transplantation corrects the enzymatic defect, chelating agents or zinc treatment is no longer required after transplantation. **Grade 1A (96%)**
- 13 All children should be closely followed-up during the first month following initiation of therapy, then every 1 to 3 months until remission, and every 3 to 6 months thereafter. **Grade 1C (100%)**
- 14 Monitoring includes physical examination, biochemical tests (ie, blood cell count, liver function tests, urea, creatinine, proteinuria), serum copper, and 24-hour urinary copper to assess efficacy, overdosage, or non-adherence to therapy and adverse events. **Grade 1C (96%)**
- 15 Evidence for non-adherence to zinc can be assessed by measuring serum zinc levels and/or urinary zinc/copper 24-hour excretion. **Grade 2B (91%)**
- 16 If increased transaminases remain or relapse despite treatment, poor compliance should be suspected. **Grade 2B (96%)**
- 17 The occurrence of penicillamine-related adverse events should prompt discontinuation and switching to trientine or zinc salts according to the severity of liver disease. **Grade 2B (100%)**

Voting results are indicated in brackets for each recommendation.

ALF = acute liver failure; LT = liver transplantation; WD = Wilson's disease.

## When Should Wilson's Disease Be Suspected in Children?

The accumulation of copper in diverse organs accounts for the wide range of clinical manifestations shown in Table 2. Most children present with liver disease (6) ranging from incidental finding of increased serum transaminases in otherwise asymptomatic children >1 year of age (7), acute hepatitis, hepatomegaly, hyperechogenic liver on ultrasound to acute liver failure (ALF) or cirrhosis (8–12). WD may present at any age between 3 and 74 years (average 13.2 years), but WD is rarely symptomatic before 5 years of age (13,14). In a pediatric series of 100 children from Bangladesh, chronic liver disease (76%), most often limited to increased serum transaminases, was the most common presenting feature (15). The finding of another possible cause of liver dysfunction, such as acute viral hepatitis A, nonalcoholic fatty liver disease or nonalcoholic steatohepatitis (16), and autoimmune hepatitis (AIH) should not exclude WD. Low-titer autoantibodies (mainly antinuclear antibodies) are commonly found in patients with WD (17), but cases of WD and concomitant AIH have been reported (17,18).

Although neurological/psychiatric symptoms usually develop in the second or third decade of life, they may occasionally be seen before 10 years of age (19–22) (Table 1) and have been reported in 4% to 6% of pediatric cases with hepatic onset (9,10,15). Mild cognitive impairment such as working memory and language difficulties, however, seems quite frequent (23). Kayser-Fleischer rings, caused by copper deposition on Descemet membrane, are usually not seen on slit lamp examination in children with asymptomatic or mild liver disease, but are almost always present in children with neurological involvement (11).

Acute hemolysis has been described as the initial presentation of WD, sometimes apparently precipitated by infection or drugs, and is prominent in fulminant WD. The prevalence of acute hemolysis was 6.9% in a recent retrospective study of 321 patients with WD with an average onset of 12.6 years (ranging from 7 to 20 years) (24). But, an earlier onset at 3 years of age has been reported (14). Several other extrahepatic manifestations have also been described in children, usually as case reports (Table 2).

Recommendations of the ESPGHAN Hepatology Committee are shown in Table 1.

TABLE 2. Clinical presentations of Wilson's disease in childhood

Clinical symptoms	Age at onset of symptoms	References
Hepatic	>2 y	(6–15,17,18)
Incidental finding of increased serum transaminases		
Acute hepatitis		
Hepatomegaly		
Fatty liver		
Acute liver failure with hemolysis		
Portal hypertension: esophageal varices, splenomegaly, low platelet count		
Decompensated cirrhosis with ascites		
Neurological and psychiatric	Usually >15 y Case reports 7–9 y	(20–22,25–28)
Dysarthria		
Dysphagia, excessive salivation		
Mood/behavior changes including depression, irritability		
Incoordination (eg, handwriting deterioration)		
Declining performance at school		
Resting and intention tremors		
Gait disturbance, dystonia, rigidity		
Mask-like face, risus sardonicus,		
Stroke-like symptoms		
Ophthalmic	>10 y	(10,28)
KF rings at slit lamp examination		
Haematological	> 7 years	(24)
Acute/chronic hemolytic anemia		
Other	Case reports, age cannot be defined	
Renal		(29)
Renal tubular dysfunction (Fanconi syndrome, tubular acidosis, aminoaciduria)		
Nephrolithiasis		
Nephrocalcinosis		
Cardiac		(30)
Cardiomyopathy, subclinical dysfunction		
Arrhythmia		
Endocrine		(31)
Hypoparathyroidism		
Other		
Pancreatitis		(32)
Skin lipomas		(33)
Skeletal		
Rickets/osteopenia/osteoporosis		(34–36)
Arthropathy		

KF = Kayser-Fleischer.

TABLE 3. Explorations of copper metabolism

	Normal values	High suspicion of WD
Serum ceruloplasmin	20–40 mg/dL	<10 mg/dL
24-Hour urinary copper excretion	<40 $\mu\text{g}$ (<0.65 $\mu\text{mol}$ )	>100 $\mu\text{g}$ (1.6 $\mu\text{mol}$ )
Liver copper content	<50 $\mu\text{g/g}$ dry weight	>250 $\mu\text{g/g}$ dry weight (>4 $\mu\text{mol/g}$ dry weight)

WD = Wilson's disease.

## Diagnostic Tests for Wilson's Disease in Children

The diagnosis of WD is usually straightforward in children with advanced liver disease, as the classical biochemical features of disturbed copper metabolism (Table 3) are usually present. Establishing a diagnosis of WD in young asymptomatic children with mild liver disease is, however, often challenging given that ceruloplasmin levels and urinary copper excretion may be normal, and Kayser-Fleischer rings absent.

### Liver Function Tests

In acute presentation of WD with liver failure, typical findings are total high bilirubin levels (>300  $\mu\text{mol/L}$ , >17.5 mg/dL) combined with relatively low serum transaminases levels (100–500 IU/L), low serum alkaline phosphatase level thought to result from zinc deficiency, and a low alkaline phosphatase (IU/L)—to—total bilirubin (mg/dL) ratio <1 (37,38). These findings are, however, not pathognomonic of WD.

### Ceruloplasmin

Ceruloplasmin is a copper-carrying protein that is bound to 90% of the circulating copper in normal individuals. Serum ceruloplasmin concentration is low in neonates, then gradually rises with age and peaks in mid childhood before declining slightly during puberty (39). The youngest age suitable for testing serum ceruloplasmin for the diagnosis of WD is 1 year. The concentration of ceruloplasmin is reduced <20 mg/dL in most patients with WD because of its impaired biosynthesis and the short half-life of the copper-free molecule apoceruloplasmin. Decreased levels of serum ceruloplasmin are, however, also found in approximately 20% of heterozygous carriers, patients with liver failure, malabsorption, glycosylation disorders, Menkes disease, protein caloric malnutrition, nephrotic syndrome, protein-losing enteropathy, acquired copper deficiency, and hereditary aceruloplasminemia (40–44). Two main studies aimed at evaluating the diagnostic accuracy of serum ceruloplasmin for the diagnosis of WD (40,44). The best WD diagnostic threshold of serum ceruloplasmin was <14 mg/dL (sensitivity 93% and specificity 100%) in a series of 57 WD adults and children with liver dysfunction and/or neurological deficits (40), and <20 mg/dL (sensitivity 95% and specificity 84.5%) in a series of 40 clinically asymptomatic children with elevated serum transaminases (44).

On the other hand, up to 20% of children and adults with WD may have normal serum ceruloplasmin levels, as reported in patients carrying bi-allelic missense mutations of the *ATP7B* gene (45,46). Ceruloplasmin levels may increase in patients with WD with histologically active chronic hepatitis, in pregnant women, or women on estrogens. In addition, misleadingly elevated serum levels may be seen when using the immunological-nephelometric assay which measures both ceruloplasmin and the biologically inactive apoform (45,46), the reason why the enzymatic assay measuring oxidase activity should be the preferred method (46).

## Total Serum Copper

Total serum copper (which includes non-ceruloplasmin-bound copper or “free copper” and copper incorporated in ceruloplasmin) is usually decreased in proportion to the decreased serum ceruloplasmin. However, in patients with WD with severe liver injury, serum copper may be within the normal range or markedly elevated in the setting of ALF due to the release of copper from liver tissue stores and the increase in free copper in the blood. The serum non-ceruloplasmin-bound copper concentration can be estimated from the serum copper and serum ceruloplasmin levels, but is dependent on the adequacy of the methods for measuring both serum copper and ceruloplasmin (3,4). Total serum copper has a poor diagnostic value but could be more valuable for monitoring of pharmacotherapy. Very low values may signal systemic copper depletion that can occur in some patients with prolonged treatment.

## Urinary Copper Excretion

In asymptomatic children or children with mild liver disease, urinary copper values are often normal. The reported optimal basal urinary copper diagnostic cut-off value is 40  $\mu\text{g}$  /24 hours (0.65  $\mu\text{mol}$ /24 hours) with a sensitivity of 78.9% and a specificity of 87.9% (44). The penicillamine challenge test (ie. 0.5 g D-penicillamine given at the beginning of the 24-hour urine collection and 12 hours later) is unreliable to rule out the diagnosis in asymptomatic children with a sensitivity of 12% and 46% at the established cut-off diagnostic value of 1575  $\mu\text{g}$ /24 hours (25  $\mu\text{mol}$ /24 hours) (44,47). Lowering the cut-off to 5 times the upper normal limit of basal-urinary copper excretion (200  $\mu\text{g}$ /24 hours; 3.2  $\mu\text{mol}$ /24 hours) increased the sensitivity to 88% respectively at the cost of considerable loss in specificity (24.1%) (44). Importantly, plastic or acid-washed glass containers should be used for urine collection to avoid contamination with copper.

## Mutation Analysis

More than 500 mutations within the *ATP7B* gene (locus 13q14.3) have been identified and most affected individuals are compound heterozygotes (48). Predominant mutations have been reported in specific populations, such as in Eastern Europe (H1069Q), Spain (Met645Arg), Sardinia (c-441 427del15), Japan (229insC, Arg778Leu), Costa Rica (Asp1279Ser), and China, Korea, and Taiwan (Arg778Leu) facilitating molecular diagnosis (49–53). Next-generation sequencing can identify both mutant alleles in 95% of affected subjects, but several limitations should be considered (54). First, molecular defects outside the coding regions and in adjacent intron/exon junctions of the gene and deletions can still be missed using these techniques. Second, their high-yield comes with the risk of identifying variants of unknown significance which pose diagnostic difficulties.

### Liver Biopsy and Liver Copper Content

In equivocal cases, measurement of liver copper content is recommended as the next step for diagnosis of WD. A copper content <250 µg/g dry weight (normal <50 µg/g dry weight) in non-cholestatic patients is considered diagnostic for WD in adult series. Lower concentrations are reported in up to 20% of patients with WD possibly related to sampling error because the distribution of copper in the liver is not homogeneous (3,4,11,55–58). The accuracy of liver copper measurement is improved with an adequately sized specimen (preferably >1 cm long, min. 0.5 cm) that should be placed on a small piece of paper for drying, and in a dry plastic copper-free container for atomic absorption analysis on fresh tissue. It has also been proposed that 2 liver biopsy passes be performed and that an entire core of the sample be used for copper determination (57,58). The most comprehensive study analyzed liver samples from 691 patients with various liver diseases, including 178 with WD (58). Mean liver copper content was significantly higher in patients with WD with liver dysfunction than in asymptomatic patients or patients with neurological dysfunction without signs of liver disease (*P* = 0.001). All patients with WD with liver dysfunction had liver copper levels more than 250 µg/g dry weight, but a high proportion (47.8%) of patients with primary biliary cirrhosis or primary sclerosing cholangitis also had liver copper values ≥250 µg/g dry weight.

There have been only a few studies evaluating the diagnostic accuracy of liver copper content in children with WD (44). Liver copper content is increased physiologically in early infancy up to 14 months of age (59), in healthy heterozygotes and in cases of chronic cholestatic diseases such as biliary atresia (60,61). Nicasastro et al (44) reported an increase in liver copper >250 µg/g dry weight in 28 of 30 WD children with mild liver disease (mean 813 µg/g dry weight). Among patients with WD, 2 children (7%) had liver copper level <75 µg/g dry weight, whereas 4 (6%) of 24 controls had liver copper levels >50 µg/g dry weight. Liver copper exceeded 250 µg/g of dry weight in 2 children with congenital disorders of glycosylation mimicking WD.

Liver histology alone cannot be used to establish the diagnosis of WD. The main features are nonspecific and include microvesicular and macrovesicular fatty deposition, Mallory

hyaline glycogen-containing vacuoles in the nuclei, portal fibrosis, and inflammation resembling AIH with interportal fibrous bridging or cirrhosis (62). Copper deposition may be demonstrable by rhodanine, orcein, or rubeanic acid staining but has limited diagnostic value: negative staining does not exclude increased liver copper content (62), whereas positive staining is seen in many liver diseases associated with impaired bile secretion (63).

### Scoring System

In 2001, an international consensus of experts proposed a scoring system to facilitate the diagnosis of WD (referred to as the Ferenci score), using the previously discussed biochemical parameters and molecular diagnostics. It was subsequently adopted for the EuroWilson database (Table 4) (64). The identification of only 1 disease-causing mutation appears adequate to confirm the diagnosis of WD only in the presence of definite clinical symptoms and biochemical signs of impaired copper metabolism. Otherwise in asymptomatic children, identification of 2 disease-causing mutations becomes necessary to confirm the diagnosis of WD with certainty (64,65). In children the Ferenci score provided a relatively good combination of sensitivity and specificity for the diagnosis of WD in children—98.14% and 96.59%, respectively in 1 study (66), and 90% and 91.6%, respectively in the other (44). In this latest study, considering 40 µg/24 hours instead of 100 µg/24 hours as the urinary copper excretion cut-off increased the sensitivity of the scoring system to 93% with no change in the specificity (44).

### Other Tests

Other tests are being used in some centers to improve diagnosis. These include the measurement of the incorporation of radiolabeled copper into ceruloplasmin which is impaired in WD (67), and the measurement of serum exchangeable copper (68,69). Exchangeable copper corresponds to the labile fraction of copper in the serum complexed to albumin and other peptides. Recently, relative exchangeable copper (namely exchangeable copper-to-total copper ratio) has been reported to provide 100% sensitivity and 100% specificity for the diagnosis of WD in adults with a cut off value of 15% and also showed promising results for family screening of

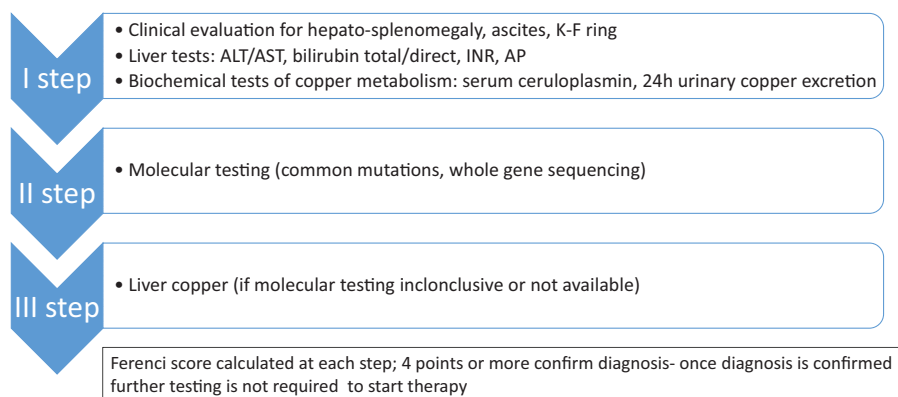
TABLE 4. Diagnostic score in Wilson’s disease, agreed at a consensus meeting (64)

Score	-1	0	1	2	4
Kayser-Fleischer rings		Absent		Present	
Neuropsychiatric symptoms suggestive of WD (or typical brain MRI)		Absent		Present	
Coombs negative hemolytic anemia + high serum copper		Absent	Present		
Urinary copper (in the absence of acute hepatitis)		Normal	1–2 × ULN	>2 × ULN, or normal but >5 × ULN 1 day after challenge with 2 × 0.5 g D-penicillamine	
Liver copper quantitative	Normal		<5 × ULN (<250 µg/g)	>5 × ULN (>250 µg/g)	
Rhodanine positive hepatocytes (only if quantitative Cu measurement is not available)		Absent	Present		
Serum ceruloplasmin (nephelometric assay)		>0.2 g/L	0.1–0.2 g/L	<0.1 g/L	
Disease-causing mutations detected		None	1		2

#### Assessment of the Wilson’s disease diagnostic score

0–1: Unlikely	2–3: Probable	4 or more: highly likely
---------------	---------------	--------------------------

MRI = magnetic resonance imaging; ULN = upper limit of normal; WD = Wilson’s disease.



**FIGURE 1.** Diagnostic approach to Wilson's disease. ALT = alanine aminotransferase; AP = alkaline phosphatase; AST = aspartate aminotransferase.

asymptomatic patients (68,70). Further studies are needed to evaluate its diagnostic accuracy in children with liver disease.

Recommendations of the ESPGHAN Hepatology Committee are shown in Table 1.

The diagnostic approach is illustrated in Figure 1.

### The Importance of Family Screening for Wilson's Disease

Genetic counseling is essential for families of patients with WD, and screening first-degree relatives is recommended by both European and American guidelines (3,4).

It is essential to screen siblings of any patient newly diagnosed with WD because the chance of being a homozygote and developing clinical disease is 25%. Assessment should include physical examination, serum ceruloplasmin, liver function tests, and molecular testing for ATP7B mutations or haplotype studies if not available. Newborn screening is not warranted and screening may be delayed until 1 to 2 years of age.

The occurrence of WD in 2 consecutive generations has been reported in apparently nonconsanguineous families suggesting a benefit for screening WD in offspring of an affected parent (71–74). Moreover, the risk of occurrence of WD in offspring is increased in consanguineous families and in specific populations with a high carrier frequency.

Finally, considering the possibility of late onset of WD, parents of a child newly diagnosed with WD should also be screened by performing liver tests, explorations of copper metabolism, and suitable genetic testing, as illustrated in a recently reported family (75).

### Treatment of Children With Wilson's Disease

Treatment is based on the removal of copper excess by chelating agents such as D-penicillamine, trientine, or by blocking the intestinal copper absorption with zinc salts. Dietary copper restriction does not prevent accumulation in WD, and there is a lack of evidence that it improves the outcome once chelators are initiated. However, avoiding copper-rich food (shellfish, nuts, chocolate, mushrooms, and organ meats) is advised until remission of symptoms and biochemical abnormalities (3). Treatment should be initiated upon diagnosis in presymptomatic children identified by family screening as soon as 2 to 3 years of age, promptly in symptomatic children to prevent progression of liver and/or neurological disease. High-quality evidence is lacking to estimate the optimal first-line treatment choice in WD. Treatment is life-long

and the monitoring of compliance and early detection of complications. Prognosis is excellent provided compliance to therapy is adequate.

### Treatment Options

*D-penicillamine* was introduced in 1956, and remains the standard treatment for WD. It chelates copper and favors its urinary excretion. Experimentally, *D-penicillamine* also has a copper “detoxifying” effect by inducing the endogenous hepatic metallothionein, a cytosolic metal-binding protein, which sequesters copper and thereby limiting damage to the liver.

*D-penicillamine* has been shown to efficiently prevent the progression of disease in asymptomatic children. This drug improved liver symptoms in more than 80% of symptomatic children within a mean time of 16 months (28), including those presenting with liver failure but no hepatic encephalopathy (76). Worsening of neurologic symptoms has, however, been reported (77,78).

Significant adverse effects are reported with the use of *D-penicillamine* resulting in drug withdrawal in up to 30% of cases in children or adults (3,12,28,79,80). Early adverse effects include sensitivity reactions characterized by fever and cutaneous eruptions, neutropenia or thrombocytopenia, lymphadenopathy, and proteinuria. Other adverse effects that may occur at any time in the medium- and long-term include a lupus-like syndrome characterized by hematuria, proteinuria, arthralgia, bone marrow toxicity with severe thrombocytopenia or aplasia, and skin changes related to *D-penicillamine*'s anticollagen effects such as *elastosis perforans serpiginosa*, *cutis laxa*, pemphigus, *lichen planus*, and aphthous stomatitis (81). Elevations in serum antinuclear antibodies are frequent, but there is no clear correlation with the development of immune-mediated diseases (82).

In children, the dose of *D-penicillamine* is usually increased progressively to 20 mg/kg/day given in 2 or 3 doses, with close follow-up for the occurrence of adverse events such as hypersensitivity and proteinuria, hematologic toxicity warranting immediate discontinuation and switching to trientine or zinc salts (83) (Table 5). As food inhibits the absorption of *D-penicillamine*, this drug should be administered 1 hour before or 2 hours after meals. There is lack of recent evidence as to pyridoxine deficiency in patients receiving *penicillamine*; hence, there has been variable personal practice in its supplementation. Moreover, pyridoxine intake is relatively high as many food products are supplemented with water-soluble vitamins.

*Trientine*, triethylene tetramine hydrochloride, was initially introduced in 1969 as a second-line chelating agent in patients with WD who developed adverse events related to *D-penicillamine* (84).

TABLE 5. Dosage and treatment monitoring

	Zinc salts	D-penicillamine	Trientine
Dosage in children	Zinc acetate, zinc sulphate Age >16 years and body weight >50 kg: 150 mg* day in 3 divided doses. Age 6–16 years and body weight <50 kg: 75 mg* day in 3 divided doses younger than 6 years of age: 50 mg* day in 2 divided doses	Starting dose: 150–300 mg/day, gradually increasing once a week up to 20 mg/kg/day given in 2 or 3 divided doses or 1000 mg (max 1500 mg) in young adults given in 2 or 4 divided doses. Maintenance dose: 10–20 mg/kg/day up to 750 mg–1000 mg/day in 2 divided doses	Starting dose: 20 mg/kg/day or 1000 mg (max 1500 mg) in young adults given in 2 or 3 divided doses. Maintenance dose: 900–1500 mg/day in 2 or 3 divided doses.
Administration	1 hour before meal or 2 hours after meal	1 hour before meal or 2 hours after meal	1 hour before meal or 3 hours after meal
Adequacy of treatment parameters	Urinary copper excretion: 30–75 µg (0.5–1.2 µmol/L) /24 hours on maintenance treatment Serum zinc level >125 µg/dL Urinary zinc >2 mg/24 h on maintenance treatment	Urinary copper excretion: 200–500 µg (3–8 µmol/L)/24 hours on maintenance treatment	Urinary copper excretion: 200–500 µg (3–8 µmol/L)/24 hours on maintenance treatment
Liver function improvement	Usually 2–6 months, ALT normalization within 1 year	Usually 2–6 months	Usually 2–6 months
Indication for a drug change	Persistent ALT >3× upper limit of normal and/or INR >1.5 Poor tolerance, for example, nausea, abdominal pain, gastric ulcerations	Poor tolerance or side effects, for example, hypersensitivity reactions, fever, neutropenia, thrombocytopenia, lymphadenopathy or proteinuria	Poor tolerance or side effects, for example, allergic reactions, arthralgia, sideroblastic anemia

ALT = alanine aminotransferase.

\* - elemental zinc.

There have been only rare reports of allergic reactions, arthralgias, muscle cramps, and sideroblastic anemia induced by trientine (85–87). Given its safety profile it is being increasingly used as first-line chelation therapy, although there is a lack of robust clinical studies evaluating the efficiency of trientine in treating WD compared to D-penicillamine. Similar efficacy of trientine compared to D-penicillamine was shown in 1 large study in WD adults with liver symptoms (88). First-line treatment with trientine was, however, associated with a higher risk of neurologic worsening of symptomatic neurologic patients compared to D-penicillamine. The only available pediatric study analyzed the efficacy of trientine as second-line therapy in 16 children with D-penicillamine intolerance or adverse events. Liver function normalized in the majority of children, but trientine did not improve accompanying neurological or psychiatric symptoms (86).

The recommended dose of trientine in children is 20 mg/kg/day in 2 to 3 divided doses. Recently, a small prospective pilot study in adults with WD has suggested that a once daily trientine regimen at a dose of 15 mg/kg provided good efficacy and safety but it should be further evaluated as maintenance therapy to improve compliance (89). Trientine also chelates iron, and therefore if iron supplementation is necessary, it should be administered at a different time of the day. The drug is best given 1 hour before or 2 to 3 hours after food for optimal absorption (Table 5). Trientine tablets must be kept refrigerated, which could be a problem for patients residing in or travelling to hot countries.

Zinc salts are being increasingly used as first-line therapy for the treatment of presymptomatic patients and for maintenance therapy after initial decoppering with a chelator, but the efficacy of zinc monotherapy in symptomatic patients with liver disease is still under debate (90–96). The postulated mode of action of zinc is the induction of metallothionein in enterocytes (97). Copper absorbed in the small intestine is thereby sequestered in enterocytes which at the end of their life cycle carry copper into the lumen. Zinc

also induces hepatocyte metallothionein, and as D-penicillamine may have copper detoxifying effect. Most studies evaluating the clinical efficacy of zinc when applied as first-line monotherapy in the various clinical presentations of WD showed that zinc had a better tolerance profile than penicillamine and could be safely used for treatment of presymptomatic children (90,92–94). Treatment failure was however reported in symptomatic children presenting with liver disease (79,91,95,96) and patients who relapsed on zinc improved after reintroduction of a chelating agent (91). Initiation of therapy with zinc salts presents also risk of neurological deterioration as is observed with other treatment modalities (91,98).

Different formulations of zinc salts are available: zinc sulfate, zinc acetate, and zinc gluconate. Gastrointestinal problems, such as nausea, vomiting, epigastric pain, gastric/duodenal mucosal ulceration, or erosion have been reported mainly with zinc sulfate, and may particularly alter the child's quality of life and lead to poor adherence (95,99). Gastrointestinal symptoms may resolve when switching formulation from zinc sulfate to zinc acetate. Anemia related to iron deficiency, isolated increase of serum amylase, and lipase levels (zinc containing enzymes) without clinical and radiological features of pancreatitis may also be observed.

The recommended dosage is 25 mg twice daily of elemental zinc in children younger than 5 years of age, 75 mg/day (if body weight <50 kg) or 150 mg/day (if body weight >50 kg) in 3 divided doses in children older than 5 years of age (3,92,94). Zinc should not be taken with food because it interferes with its absorption, and dietary copper restriction is not recommended because zinc blocks copper absorption from the intestinal track (Table 5).

### Treatment Strategy

Treatment should be individually tailored to the clinical condition of the child defined by the type and severity of organ involvement. A clinically relevant limitation in the long-term use of



D-penicillamine is the occurrence of severe adverse events. Lack of adherence and underdosage are the main risk factors for an unfavorable clinical course. To improve adherence to the life-long therapy, the treatment scheme should be as simple as possible.

Pediatric hepatologists vary in the approaches they use in the care for children with WD (100). In asymptomatic children or children with only mild liver symptoms, all available treatments have proven effective (28,86,90,92–94). In symptomatic patients with WD, current guidelines favor the use of chelating agents (D-penicillamine, trientine) as first-line therapy (3,4).

A sequential treatment in WD could be proposed based on the hypothesis that after a treatment phase with the more effective chelating agents, smaller dosage or alternative treatment with zinc in de-coppered patients may be sufficient to upkeep copper homeostasis. However, only limited data are available to decide when and under which conditions a patient can be switched to zinc maintenance therapy and vice versa.

Combination therapy using zinc in conjunction with a chelating agent (administered at widely spaced intervals during the day to avoid interference and given 1 hour before or 2 hours after meals) has a theoretical basis in both blocking copper uptake and eliminating excess copper, and thus may be synergistic effect. Reports have been limited to patients who present with decompensated chronic liver disease, and suggest a favorable outcome for combination therapy with D-penicillamine and zinc (8,76) or with trientine and zinc (79,101). Recommendations of the ESPGHAN Hepatology Committee are shown in Table 1.

### Indications for Liver Transplantation in Children With Wilson's Disease

Indications for liver transplantation (LT) are rare (<1%), including patients with ALF or those with progression of liver dysfunction to liver failure despite drug therapy (102). Excellent post-LT outcomes are reported (103,104). Actual patient survival rates were 87% at 5, 10, and 15 years in a French series of 75 adults and 46 children (median age: 14 years, range 7–17 years) transplanted between 1985 and 2009 for ALF (53%), decompensated cirrhosis (41%), or severe neurological disease (6%) (103). In another study analyzing the United Network for Organ Sharing database including 170 children with WD who underwent LT between 1987 and 2008, 1- and 5-year survival were 90.1% and 89%, respectively (104). In both studies, patients transplanted for end-stage chronic liver disease had better long-term survival than patients transplanted for ALF. Extracorporeal liver support systems as a bridge to LT may improve the outcome (105,106). Neurological and especially psychiatric involvement may show little improvement with transplantation but LT cannot be considered as a therapy for patients with severe neuropsychiatric involvement (107,108).

Children presenting with decompensated liver cirrhosis with liver failure but no hepatic encephalopathy can be often rescued with chelation treatment. Response to medical treatment may take time with improvement of prothrombin time after a minimum of 1 month and normalization within 3 months to 1 year or more (76). Close follow-up and monitoring of clinical status for hepatic encephalopathy, ascites, sepsis, and liver function tests is required in specialized LT units to timely listing the child on the transplant list, a decision that is extremely challenging. In 1986, Nazer et al (109) devised a scoring system to predict the outcome of patients including adults and children with hepatic decompensation in the setting of WD. In 2005, the score was re-examined in the pediatric population by Dhawan et al (8) who proposed a new scoring system (King's Wilson index [WI]) that had a better positive predictive value for mortality without transplantation (Table 6) (8,102). The

TABLE 6. Wilson's disease scoring system to predict the outcome of children with hepatic decompensation (King's Wilson index) by Dhawan et al (8)

Score	Bilirubin, μmol/L	INR	AST	Leukocytes, 10 <sup>9</sup> /L	Albumin, g/L
0	0–100	0–1.29	0–100	0–6.7	>45
1	101–150	1.3–1.6	101–150	6.8–8.3	34–44
2	151–200	1.7–1.9	151–200	8.4–10.3	25–33
3	201–300	2.0–2.4	201–300	10.4–15.3	21–24
4	>300	>2.5	>300	>15.3	0–20

AST = aspartate aminotransferase.

11 points and above - urgent listing for liver transplantation.

WI is reported to be 93% sensitive, 98% specific, with a positive predictive value of 93% (8). Although useful, the WI may, however, not be entirely accurate and continued investigation of predictors of outcome in WD is necessary.

Recommendations of the ESPGHAN Hepatology Committee are shown in Table 1.

### Monitoring Efficacy, Safety, and Compliance to Treatment

Treatment of WD should aim at normal physical examination and normal liver function tests. Patients must avoid alcohol consumption and potential hepatotoxic drug therapy.

Monitoring should be performed once a week at initiation of therapy, especially while increasing penicillamine dosages, every 1 to 3 months until remission and every 3 to 6 months afterwards. Nonadherence to therapy can lead to life-threatening deterioration and monitoring intervals should be shorter, especially in adolescents, in whom compliance is uncertain.

Monitoring includes physical examination (search for new WD symptoms or related to therapeutic adverse events of therapy) and liver function tests, which should normalize progressively within 3 to 12 months. Twenty-four-hour urinary copper excretion should increase after initiation of therapy with D-penicillamine or trientine, followed by a decrease once liver function tests return to normal indicating a reduction in the body load of copper. In general presymptomatic children excrete less copper than those with symptomatic disease. Urinary copper excretion should lie between 200 and 500 μg/24 hours during maintenance therapy with D-penicillamine or trientine. Monitoring of patients on zinc therapy must ensure a reduction in urinary copper excretion (initially <100 μg/24 h, and between 30 and 75 μg/24 h on maintenance therapy); low levels below 30 μg/24 h suggest zinc overdosage. In addition, serum zinc levels and urinary zinc excretion should be maintained above 125 μg/dL and 1.5 to 2 g/day, respectively; lower levels generally indicate poor compliance to therapy (110).

It is important to also monitor blood cell counts, and screen any therapeutic-related adverse events (such as proteinuria). Neutropenia and anemia may be due to failed iron mobilization, with transaminase elevation due to increased hepatic iron accompanied by increased ferritin indicating over treatment. Temporary discontinuation of therapy, with close observation, is warranted followed by reintroduction of therapy at a reduced dose (Table 5).

Yearly slit-lamp examination should document fading or disappearance in patients with Kayser-Fleischer (KF) rings if they are being adequately “decoppered.” Appearance of KF rings in patients with persisting abnormalities of liver function tests on maintenance therapy indicates noncompliance. Search for

appearance of changes at magnetic resonance imaging of the brain may be useful in patients noncompliant to therapy (111).

## Key Recommendations

Appropriate steps for diagnosis, treatment and follow-up of children with WD were discussed collectively between the core group and ESPGHAN hepatology members. An agreement was obtained on the recommendations shown in Table 1.

## REFERENCES

1. Reilly M, Daly L, Hutchinson M. An epidemiological study of Wilson's disease in the Republic of Ireland. *J Neurol Neurosurg Psychiatry* 1993;56:298–300.
2. Bandmann O, Weiss KH, Kaler SG. Wilson's disease and other neurological copper disorders. *Lancet Neurol* 2015;14:103–13.
3. Roberts EA, Schilsky ML. Diagnosis and treatment of Wilson disease: an update. *Hepatology* 2008;47:2089–111.
4. European Association for Study of Liver. Clinical practice guidelines: Wilson's disease. *J Hepatol* 2012;56:671–85.
5. Guyatt GH, Oxman AD, Schunemann HJ, et al. GRADE guidelines: a new series of articles in the Journal of Clinical Epidemiology. *J Clin Epidemiol* 2011;64:380–2.
6. Iorio R, D'Ambrosi M, Mazzarella G, et al. Early occurrence of hypertransaminasemia in a 13-month-old child with Wilson disease. *J Pediatr Gastroenterol Nutr* 2003;36:637–8.
7. Iorio R, Sepe A, Giannattasio A, et al. Hypertransaminasemia in childhood as a marker of genetic liver disorders. *J Gastroenterol* 2005;40:820–6.
8. Dhawan A, Taylor RM, Cheeseman P, et al. Wilson's disease in children: 37-year experience and revised King's score for liver transplantation. *Liver Transpl* 2005;11:441–8.
9. Iorio R, D'Ambrosi M, Marcellini M, et al. Serum transaminases in children with Wilson's disease. *J Pediatr Gastroenterol Nutr* 2004;39:331–6.
10. Sanchez-Albisua I, Garde T, Hierro L, et al. A high index of suspicion: the key to an early diagnosis of Wilson's disease in childhood. *J Pediatr Gastroenterol Nutr* 1999;28:186–90.
11. Merle U, Schaefer M, Ferenci P, et al. Clinical presentation, diagnosis and long-term outcome of Wilson's disease: a cohort study. *Gut* 2007;56:115–20.
12. Giacchino R, Marazzi MG, Barabino A, et al. Syndromic variability of Wilson's disease in children. Clinical study of 44 cases. *Ital J Gastroenterol Hepatol* 1997;29:155–61.
13. Lin LJ, Wang DX, Ding NN, et al. Comprehensive analysis on clinical features of Wilson's disease: an experience over 28 years with 133 cases. *Neurol Res* 2014;36:157–63.
14. Wilson DC, Phillips MJ, Cox DW, et al. Severe hepatic Wilson's disease in preschool-aged children. *J Pediatr* 2000;137:719–22.
15. Rukunuzzaman M. Wilson's disease in Bangladeshi children: analysis of 100 cases. *Pediatr Gastroenterol Hepatol Nutr* 2015;18:121–7.
16. Roberts EA, Yap J. Nonalcoholic fatty liver disease (NAFLD): approach in the adolescent patient. *Curr Treat Options Gastroenterol* 2006;9:423–31.
17. Yener S, Akarsu M, Karacanci C, et al. Wilson's disease with coexisting autoimmune hepatitis. *J Gastroenterol Hepatol* 2004;19:114–6.
18. Milkiewicz P, Saksena S, Hubscher SG, et al. Wilson's disease with superimposed autoimmune features: report of two cases and review. *J Gastroenterol Hepatol* 2000;15:570–4.
19. Machado A, Chien HF, Deguti MM, et al. Neurological manifestations in Wilson's disease: report of 119 cases. *Mov Disord* 2006;21:2192–6.
20. Abdel Ghaffar TY, Elsayed SM, Elnaghy S, et al. Phenotypic and genetic characterization of a cohort of pediatric Wilson disease patients. *BMC Pediatr* 2011;11:56.
21. Kalra V, Khurana D, Mittal R. Wilson's disease—early onset and lessons from a pediatric cohort in India. *Indian Pediatr* 2000;37:595–601.
22. Denning TR, Berrios GE. Wilson's disease: a longitudinal study of psychiatric symptoms. *Biol Psychiatry* 1990;28:255–65.
23. Favre E, Lion-Francois L, Canton M, et al. Cognitive abilities of children with neurological and liver forms of Wilson's disease. *J Pediatr Gastroenterol Nutr* 2017;64:436–9.
24. Walshe JM. The acute haemolytic syndrome in Wilson's disease—a review of 22 patients. *QJM* 2013;106:1003–8.
25. Pendlebury ST, Rothwell PM, Dalton A, et al. Stroke-like presentation of Wilson disease with homozygosity for a novel T766R mutation. *Neurology* 2004;63:1982–3.
26. Leinweber B, Moller JC, Scherag A, et al. Evaluation of the Unified Wilson's Disease Rating Scale (UWDRS) in German patients with treated Wilson's disease. *Mov Disord* 2008;23:54–62.
27. Ben-Pazi H, Jaworowski S, Shalev RS. Cognitive and psychiatric phenotypes of movement disorders in children: a systematic review. *Dev Med Child Neurol* 2011;53:1077–84.
28. Manolaki N, Nikolopoulou G, Daikos GL, et al. Wilson disease in children: analysis of 57 cases. *J Pediatr Gastroenterol Nutr* 2009;48:72–7.
29. Di Stefano V, Lionetti E, Rotolo N, et al. Hypercalciuria and nephrocalcinosis as early feature of Wilson disease onset: description of a pediatric case and literature review. *Hepat Mon* 2012;12:e6233.
30. Elkiran O, Karakurt C, Selimoglu A, et al. Subclinical diastolic dysfunction in children with Wilson's disease assessed by tissue Doppler echocardiography: a possible early predictor of cardiac involvement. *Acta Cardiol* 2013;68:181–7.
31. Fatima J, Karoli R, Jain V. Hypoparathyroidism in a case of Wilson's disease: rare association of a rare disorder. *Indian J Endocrinol Metab* 2013;17:361–2.
32. Weizman Z, Picard E, Barki Y, et al. Wilson's disease associated with pancreatitis. *J Pediatr Gastroenterol Nutr* 1988;7:931–3.
33. Schaefer M, Gotthardt DN, Didion C, et al. Increased prevalence of subcutaneous lipomas in patients with Wilson disease. *J Clin Gastroenterol* 2015;49:e61–3.
34. Quemeneur AS, Trocello JM, Ea HK, et al. Miscellaneous non-inflammatory musculoskeletal conditions. Musculoskeletal conditions associated with Wilson's disease. *Best Pract Res Clin Rheumatol* 2011;25:627–36.
35. Weiss KH, Van de Moortele M, Gotthardt DN, et al. Bone demineralisation in a large cohort of Wilson disease patients. *J Inherit Metab Dis* 2015;38:949–56.
36. Selimoglu MA, Ertekin V, Doneray H, et al. Bone mineral density of children with Wilson disease: efficacy of penicillamine and zinc therapy. *J Clin Gastroenterol* 2008;42:194–8.
37. Tissieres P, Chevret L, Debray D, et al. Fulminant Wilson's disease in children: appraisal of a critical diagnosis. *Pediatr Crit Care Med* 2003;4:338–43.
38. Sallie R, Katsiyiannakis L, Baldwin D, et al. Failure of simple biochemical indexes to reliably differentiate fulminant Wilson's disease from other causes of fulminant liver failure. *Hepatology* 1992;16:1206–11.
39. Kelly J, Raizman JE, Bevilacqua V, et al. Complex reference value distributions and partitioned reference intervals across the pediatric age range for 14 specialized biochemical markers in the CALIPER cohort of healthy community children and adolescents. *Clin Chim Acta* 2015;450:196–202.
40. Mak CM, Lam CW, Tam S. Diagnostic accuracy of serum ceruloplasmin in Wilson disease: determination of sensitivity and specificity by ROC curve analysis among ATP7B-genotyped subjects. *Clin Chem* 2008;54:1356–62.
41. Gitlin JD. Aceruloplasminemia. *Pediatr Res* 1998;44:271–6.
42. Mandato C, Brive L, Miura Y, et al. Cryptogenic liver disease in four children: a novel congenital disorder of glycosylation. *Pediatr Res* 2006;59:293–8.
43. Costa LS, Pegler SP, Lellis RF, et al. Menkes disease: importance of diagnosis with molecular analysis in the neonatal period. *Rev Assoc Med Bras (1992)* 2015;61:407–10.
44. Nicastro E, Ranucci G, Vajro P, et al. Re-evaluation of the diagnostic criteria for Wilson disease in children with mild liver disease. *Hepatology* 2010;52:1948–56.
45. Gromadzka G, Schmidt HH, Genschel J, et al. Frameshift and non-sense mutations in the gene for ATPase7B are associated with severe impairment of copper metabolism and with an early clinical manifestation of Wilson's disease. *Clin Genet* 2005;68:524–32.

46. Merle U, Eisenbach C, Weiss KH, et al. Serum ceruloplasmin oxidase activity is a sensitive and highly specific diagnostic marker for Wilson's disease. *J Hepatol* 2009;51:925–30.
47. Muller T, Koppikar S, Taylor RM, et al. Re-evaluation of the penicillamine challenge test in the diagnosis of Wilson's disease in children. *J Hepatol* 2007;47:270–6.
48. Kenney SM, Cox DW. Sequence variation database for the Wilson disease copper transporter, ATP7B. *Hum Mutat* 2007;28:1171–7.
49. Caca K, Ferenci P, Kuhn HJ, et al. High prevalence of the H1069Q mutation in East German patients with Wilson disease: rapid detection of mutations by limited sequencing and phenotype-genotype analysis. *J Hepatol* 2001;35:575–81.
50. Margarit E, Bach V, Gomez D, et al. Mutation analysis of Wilson disease in the Spanish population—identification of a prevalent substitution and eight novel mutations in the ATP7B gene. *Clin Genet* 2005;68:61–8.
51. Loudianos G, Dessi V, Lovicu M, et al. Molecular characterization of Wilson disease in the Sardinian population—evidence of a founder effect. *Hum Mutat* 1999;14:294–303.
52. Nanji MS, Nguyen VT, Kawasoe JH, et al. Haplotype and mutation analysis in Japanese patients with Wilson disease. *Am J Hum Genet* 1997;60:1423–9.
53. Wu Z, Wang N, Murong S, et al. Identification and analysis of mutations of the Wilson disease gene in Chinese population. *Chin Med J (Engl)* 2000;113:40–3.
54. Glenn TC. Field guide to next-generation DNA sequencers. *Mol Ecol Resour* 2011;11:759–69.
55. Ferenci P, Steindl-Munda P, Vogel W, et al. Diagnostic value of quantitative hepatic copper determination in patients with Wilson's disease. *Clin Gastroenterol Hepatol* 2005;3:811–8.
56. Gow PJ, Smallwood RA, Angus PW, et al. Diagnosis of Wilson's disease: an experience over three decades. *Gut* 2000;46:415–9.
57. Liggi M, Mais C, Demurtas M, et al. Uneven distribution of hepatic copper concentration and diagnostic value of double-sample biopsy in Wilson's disease. *Scand J Gastroenterol* 2013;48:1452–8.
58. Yang X, Tang XP, Zhang YH, et al. Prospective evaluation of the diagnostic accuracy of hepatic copper content, as determined using the entire core of a liver biopsy sample. *Hepatology* 2015;62:1731–41.
59. Araya M, Koletzko B, Uauy R. Copper deficiency and excess in infancy: developing a research agenda. *J Pediatr Gastroenterol Nutr* 2003;37:422–9.
60. Sato C, Koyama H, Satoh H, et al. Concentrations of copper and zinc in liver and serum samples in biliary atresia patients at different stages of traditional surgeries. *Tohoku J Exp Med* 2005;207:271–7.
61. Bayliss EA, Hambidge KM, Sokol RJ, et al. Hepatic concentrations of zinc, copper and manganese in infants with extrahepatic biliary atresia. *J Trace Elem Med Biol* 1995;9:40–3.
62. Johncilla M, Mitchell KA. Pathology of the liver in copper overload. *Semin Liver Dis* 2011;31:239–44.
63. Miyamura H, Nakanuma Y, Kono N. Survey of copper granules in liver biopsy specimens from various liver abnormalities other than Wilson's disease and biliary diseases. *Gastroenterol Jpn* 1988;23:633–8.
64. Ferenci P, Caca K, Loudianos G, et al. Diagnosis and phenotypic classification of Wilson disease. *Liver Int* 2003;23:139–42.
65. Caprai S, Loudianos G, Massei F, et al. Direct diagnosis of Wilson disease by molecular genetics. *J Pediatr* 2006;148:138–40.
66. Koppikar S, Dhawan A. Evaluation of the scoring system for the diagnosis of Wilson's disease in children. *Liver Int* 2005;25:680–1.
67. Lyon TD, Fell GS, Gaffney D, et al. Use of a stable copper isotope (<sup>65</sup>Cu) in the differential diagnosis of Wilson's disease. *Clin Sci (Lond)* 1995;88:727–32.
68. El Balkhi S, Trocello JM, Poupon J, et al. Relative exchangeable copper: a new highly sensitive and highly specific biomarker for Wilson's disease diagnosis. *Clin Chim Acta* 2011;412:2254–60.
69. El Balkhi S, Poupon J, Trocello JM, et al. Determination of ultrafiltrable and exchangeable copper in plasma: stability and reference values in healthy subjects. *Anal Bioanal Chem* 2009;394:1477–84.
70. Trocello JM, El Balkhi S, Woimant F, et al. Relative exchangeable copper: a promising tool for family screening in Wilson disease. *Mov Disord* 2014;29:558–62.
71. Firneisz G, Szonyi L, Ferenci P, et al. The other mutation is found: follow-up of an exceptional family with Wilson disease. *Am J Gastroenterol* 2004;99:2504–5.
72. Maier-Dobersberger T, Mannhalter C, Rack S, et al. Diagnosis of Wilson's disease in an asymptomatic sibling by DNA linkage analysis. *Gastroenterology* 1995;109:2015–8.
73. Dufernez F, Lachaux A, Chappuis P, et al. Wilson disease in offspring of affected patients: report of four French families. *Clin Res Hepatol Gastroenterol* 2013;37:240–5.
74. Dziezyc K, Gromadzka G, Czlonkowska A. Wilson's disease in consecutive generations of one family. *Parkinsonism Relat Disord* 2011;17:577–8.
75. Brunet AS, Marotte S, Guillaud O, et al. Familial screening in Wilson's disease: think at the previous generation! *J Hepatol* 2012;57:1394–5.
76. Santos Silva EE, Sarles J, Buts JP, et al. Successful medical treatment of severely decompensated Wilson disease. *J Pediatr* 1996;128:285–7.
77. Medici V, Trevisan CP, D'Inca R, et al. Diagnosis and management of Wilson's disease: results of a single center experience. *J Clin Gastroenterol* 2006;40:936–41.
78. Kalita J, Kumar V, Chandra S, et al. Worsening of Wilson disease following penicillamine therapy. *Eur Neurol* 2014;71:126–31.
79. Wiggelinkhuizen M, Tilanus ME, Bollen CW, et al. Systematic review: clinical efficacy of chelator agents and zinc in the initial treatment of Wilson disease. *Aliment Pharmacol Ther* 2009;29:947–58.
80. Czlonkowska A, Litwin T, Karlinski M, et al. D-penicillamine versus zinc sulfate as first-line therapy for Wilson's disease. *Eur J Neurol* 2014;21:599–606.
81. Ranucci G, Di Dato F, Leone F, et al. Penicillamine-induced elastosis perforans serpiginosa in Wilson's disease: is useful switching to zinc? *J Pediatr Gastroenterol Nutr* 2017;64:e72–3.
82. Seessle J, Gotthardt DN, Schafer M, et al. Concomitant immune-related events in Wilson disease: implications for monitoring chelator therapy. *J Inherit Metab Dis* 2016;39:125–30.
83. Brewer GJ, Yuzbasiyan-Gurkan V, Young AB. Treatment of Wilson's disease. *Semin Neurol* 1987;7:209–20.
84. Walshe JM. Treatment of Wilson's disease with trientine (triethylene tetramine) dihydrochloride. *Lancet* 1982;1:643–7.
85. Perry AR, Pagliuca A, Fitzsimons EJ, et al. Acquired sideroblastic anaemia induced by a copper-chelating agent. *Int J Hematol* 1996;64:69–72.
86. Taylor RM, Chen Y, Dhawan A. Triethylene tetramine dihydrochloride (trientine) in children with Wilson disease: experience at King's College Hospital and review of the literature. *Eur J Pediatr* 2009;168:1061–8.
87. Condamine L, Hermine O, Alvin P, et al. Acquired sideroblastic anaemia during treatment of Wilson's disease with triethylene tetramine dihydrochloride. *Br J Haematol* 1993;83:166–8.
88. Weiss KH, Thurik F, Gotthardt DN, et al. Efficacy and safety of oral chelators in treatment of patients with Wilson disease. *Clin Gastroenterol Hepatol* 2013;11:1028–35.
89. Ala A, Aliu E, Schilsky ML. Prospective pilot study of a single daily dosage of trientine for the treatment of Wilson disease. *Dig Dis Sci* 2015;60:1433–9.
90. Mizuochi T, Kimura A, Shimizu N, et al. Zinc monotherapy from time of diagnosis for young pediatric patients with presymptomatic Wilson disease. *J Pediatr Gastroenterol Nutr* 2011;53:365–7.
91. Weiss KH, Gotthardt DN, Klemm D, et al. Zinc monotherapy is not as effective as chelating agents in treatment of Wilson disease. *Gastroenterology* 2011;140:1189.e1–98.e1.
92. Ranucci G, Di Dato F, Spagnuolo MI, et al. Zinc monotherapy is effective in Wilson's disease patients with mild liver disease diagnosed in childhood: a retrospective study. *Orphanet J Rare Dis* 2014;9:41.
93. Abuduxikuer K, Wang JS. Zinc mono-therapy in pre-symptomatic Chinese children with Wilson disease: a single center, retrospective study. *PLoS One* 2014;9:e86168.
94. Marcellini M, Di Ciommo V, Callea F, et al. Treatment of Wilson's disease with zinc from the time of diagnosis in pediatric patients: a single-hospital, 10-year follow-up study. *J Lab Clin Med* 2005;145:139–43.
95. Santiago R, Gottrand F, Debray D, et al. Zinc therapy for Wilson disease in children in French pediatric centers. *J Pediatr Gastroenterol Nutr* 2015;61:613–8.

96. Linn FH, Houwen RH, Van Hattum J, et al. Long-term exclusive zinc monotherapy in symptomatic Wilson disease: experience in 17 patients. *Hepatology* 2009;50:1442–52.
97. Brewer GJ. Zinc therapy induction of intestinal metallothionein in Wilson's disease. *Am J Gastroenterol* 1999;94:301–2.
98. Litwin T, Dziezyc K, Karlinski M, et al. Early neurological worsening in patients with Wilson's disease. *J Neurol Sci* 2015;355:162–7.
99. Wiernicka A, Janczyk W, Dadalski M, et al. Gastrointestinal side effects in children with Wilson's disease treated with zinc sulphate. *World J Gastroenterol* 2013;19:4356–62.
100. Sturm E, Piersma FE, Tanner MS, et al. Controversies and variation in diagnosing and treating children with Wilson disease: results of an international survey. *J Pediatr Gastroenterol Nutr* 2016;63:82–7.
101. Askari FK, Greenson J, Dick RD, et al. Treatment of Wilson's disease with zinc. XVIII. Initial treatment of the hepatic decompensation presentation with trientine and zinc. *J Lab Clin Med* 2003;142:385–90.
102. Fischer RT, Soltys KA, Squires RH Jr et al. Prognostic scoring indices in Wilson disease: a case series and cautionary tale. *J Pediatr Gastroenterol Nutr* 2011;52:466–9.
103. Guillaud O, Dumortier J, Sobesky R, et al. Long term results of liver transplantation for Wilson's disease: experience in France. *J Hepatol* 2014;60:579–89.
104. Arnon R, Annunziato R, Schilsky M, et al. Liver transplantation for children with Wilson disease: comparison of outcomes between children and adults. *Clin Transplant* 2011;25:E52–60.
105. Nagata Y, Uto H, Hasuike S, et al. Bridging use of plasma exchange and continuous hemodiafiltration before living donor liver transplantation in fulminant Wilson's disease. *Intern Med* 2003;42:967–70.
106. Rustom N, Bost M, Cour-Andlauer F, et al. Effect of molecular adsorbents recirculating system treatment in children with acute liver failure caused by Wilson disease. *J Pediatr Gastroenterol Nutr* 2014;58:160–4.
107. Medici V, Mirante VG, Fassati LR, et al. Liver transplantation for Wilson's disease: the burden of neurological and psychiatric disorders. *Liver Transpl* 2005;11:1056–63.
108. Yagci MA, Tardu A, Karagul S, et al. Influence of liver transplantation on neuropsychiatric manifestations of Wilson disease. *Transplant Proc* 2015;47:1469–73.
109. Nazer H, Ede RJ, Mowat AP, et al. Wilson's disease: clinical presentation and use of prognostic index. *Gut* 1986;27:1377–81.
110. Brewer GJ, Yuzbasiyan-Gurkan V, Lee DY, et al. Treatment of Wilson's disease with zinc. VI. Initial treatment studies. *J Lab Clin Med* 1989;114:633–8.
111. Hermann W. Morphological and functional imaging in neurological and non-neurological Wilson's patients. *Ann N Y Acad Sci* 2014;1315:24–9.