

University of Groningen

Symptomatic Thoracic Nerve Root Herniation into an Extradural Arachnoid Cyst

Shanbhag, Nagesh C.; Duyff, Ruurd F.; Groen, Rob J. M.

Published in:
World neurosurgery

DOI:
[10.1016/J.WNEU.2017.07.105](https://doi.org/10.1016/J.WNEU.2017.07.105)

IMPORTANT NOTE: You are advised to consult the publisher's version (publisher's PDF) if you wish to cite from it. Please check the document version below.

Document Version
Publisher's PDF, also known as Version of record

Publication date:
2017

[Link to publication in University of Groningen/UMCG research database](#)

Citation for published version (APA):

Shanbhag, N. C., Duyff, R. F., & Groen, R. J. M. (2017). Symptomatic Thoracic Nerve Root Herniation into an Extradural Arachnoid Cyst: Case Report and Review of the Literature. *World neurosurgery*, 106, 1056.e5-1056.e8. <https://doi.org/10.1016/J.WNEU.2017.07.105>

Copyright

Other than for strictly personal use, it is not permitted to download or to forward/distribute the text or part of it without the consent of the author(s) and/or copyright holder(s), unless the work is under an open content license (like Creative Commons).

The publication may also be distributed here under the terms of Article 25fa of the Dutch Copyright Act, indicated by the "Taverne" license. More information can be found on the University of Groningen website: <https://www.rug.nl/library/open-access/self-archiving-pure/taverne-amendment>.

Take-down policy

If you believe that this document breaches copyright please contact us providing details, and we will remove access to the work immediately and investigate your claim.

Downloaded from the University of Groningen/UMCG research database (Pure): <http://www.rug.nl/research/portal>. For technical reasons the number of authors shown on this cover page is limited to 10 maximum.



Symptomatic Thoracic Nerve Root Herniation into an Extradural Arachnoid Cyst: Case Report and Review of the Literature

Nagesh C. Shanbhag^{1,2}, Ruurd F. Duyff³, Rob J.M. Groen⁴

Key words

- Extradural
- Herniation
- Radiculopathy
- Spinal arachnoid cyst
- Thoracic nerve root

Abbreviations and Acronyms

- CT:** Computed tomography
MRI: Magnetic resonance imaging
SEAC: Spinal extradural arachnoid cyst

From the ¹Department of Clinical Pharmacy & Pharmacology, University Medical Center Groningen, Groningen, The Netherlands; ²Department of Pharmacology and Molecular Therapeutics, Centre for Neuroscience and Regenerative Medicine, Uniformed Services University, Bethesda, Maryland, USA; ³Department of Neurology, Tjongerschans Hospital, Heerenveen, The Netherlands; and ⁴Department of Neurosurgery, University Medical Center Groningen, University of Groningen, Groningen, The Netherlands

To whom correspondence should be addressed:
 Rob J.M. Groen, M.D., Ph.D.
 [E-mail: r.j.m.groen@umcg.nl]

Citation: *World Neurosurg.* (2017) 106:1056.e5–1056.e8.
<http://dx.doi.org/10.1016/j.wneu.2017.07.105>

Journal homepage: www.WORLDNEUROSURGERY.org

Available online: www.sciencedirect.com

1878-8750/\$ - see front matter © 2017 Elsevier Inc. All rights reserved.

INTRODUCTION

Spinal extradural arachnoid cysts (SEACs) are rare lesions that result from the transdural protrusion/herniation of the arachnoid membrane into the spinal epidural space through a dural defect.¹ The expansion of the cyst in the extradural space can cause erosion of the bony structures and may result in the (symptomatic) compression of the neural structures (i.e., the spinal cord/cauda equina and/or spinal nerve roots). In this article, we report a unique case of a verified symptomatic thoracic nerve root herniation into an extradural arachnoid cyst through a lateral thoracic dural defect. The significance of the clinical diagnosis, proper imaging studies, and

■ **BACKGROUND:** Spinal extradural arachnoid cysts (SEACs) are relatively rare and usually asymptomatic. They preferentially are situated in the thoracic extradural space and almost always dorsal. SEACs may present with back pain and/or cord compression symptoms. Needle aspiration, needle fenestration, or open surgical resection/fenestration have been reported as treatment modalities.

■ **CASE DESCRIPTION:** We present a 35-year-old woman who complained of radiating pain from the right lower thoracic region of her back toward the right inguinal region, which was aggravated upon defecation and straining. Magnetic resonance imaging (MRI) revealed an extradural cyst located laterally at T11–T12 level on the right, with a nerve root herniation. During a T11–T12 hemilaminectomy, on resection of the cyst wall, a nerve root was noted to be herniating into the cyst cavity through a dural defect. The nerve root was released and repositioned intradurally, followed by direct suture of the dural tear. Histologic findings of the cyst wall confirmed an arachnoid cyst. Postoperative course was uneventful without complications. Postoperative MRI confirmed a complete resection of the cyst. Five years after surgery, the patient is asymptomatic with complete recovery.

■ **CONCLUSIONS:** Thoracic SEACs can present with radiating pain due to a transdural herniation of a thoracic nerve root into the cyst, potentially due to a mechanism of intermittent pressure gradients between the intradural and extradural spaces. MRI can prove beneficial in visualizing the nerve prolapsing into the cyst. Open resection of the cyst wall, reduction of the nerve root herniation, and subsequent direct closure of the dural tear led to complete recovery.

the surgical management are discussed, and we give a brief review of the cases reported in the literature with radiculopathy/limb pain due to a SEAC.

CASE REPORT

A previously healthy 35-year-old woman presented with complaints of intermitting excruciating pain radiating from the right lower thoracic part of her back toward the right inguinal region. This pain was aggravated during defecation and strenuous activities. She had an unremarkable medical history and denied any past vehicular accident or fall. One year before admission, her complaints had started with a shooting pain in both feet. This progressed to pain that concentrated over

her right lower leg approximately 6 months before admission. Also, she mentioned a subjective weakness in both legs, but neurologic examination was normal and sphincter functions were unaffected. Initial evaluation resulted in a suspicion of hip dysfunction and a referral was made to orthopedic surgery. However, no hip abnormalities were noted on this evaluation. Additional consultation with vascular surgery resulted in bilateral sclerotherapy for varicosities in both legs without resolution of any symptoms related to the chief complaint.

Although an initial magnetic resonance imaging (MRI) assessment performed in a different hospital revealed a thoracic cyst, it was considered insignificant. Nonetheless, as part of a second neurologic

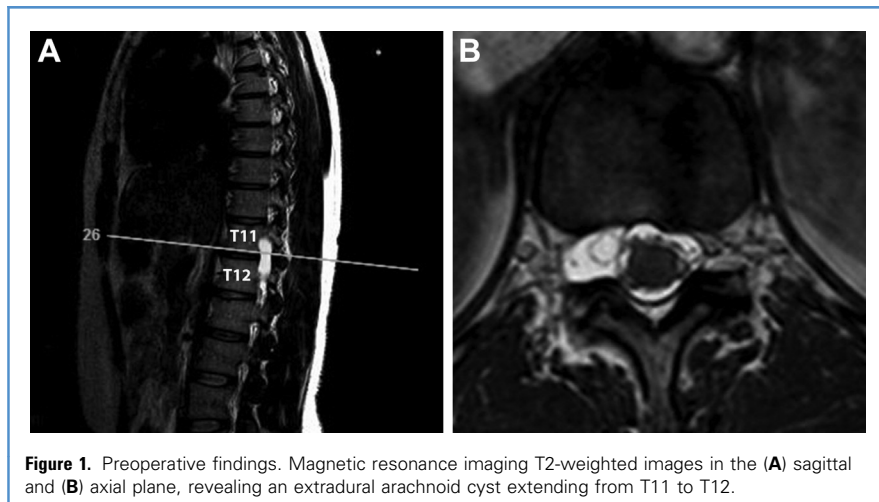


Figure 1. Preoperative findings. Magnetic resonance imaging T2-weighted images in the (A) sagittal and (B) axial plane, revealing an extradural arachnoid cyst extending from T11 to T12.

evaluation for persisting complaints of leg and groin pain on the right side and in the absence of any objective neurologic sign or symptom, MRI of the spine was performed. This revealed a widening of the neuroforamen by a cystic structure at the T11–T12 level on the right side (Figure 1A). Inside of the cyst, as visible on axial T2-weighted image, the looping of a part of a thoracic nerve root was evident (Figure 1B).

Based on the combination of intermittent radiating pain in the right groin and the peculiar nerve root looping observed on MRI, the transdural herniation of a lower thoracic nerve root into an extradural arachnoid cyst at T11–T12 on the right side was suspected. A right-sided T11–T12 hemilaminectomy with surgical exploration was performed, revealing a posterolateral extradural arachnoid cyst.

There was a small defect in the dura mater with a herniation of a loop of a thoracic nerve root (Figure 2A). This defect was then widened to bring the nerve root back inside the dural sac. A schematic representation of the herniated nerve root into the extradural arachnoid cyst is shown in Figure 2B. Subsequently, the dural defect was closed in a watertight fashion, and the cyst wall was resected completely. Histopathologic investigation confirmed the presence of a single layer of arachnoid cells lining collagenous tissue, which was consistent with an arachnoid cyst. Postoperative course was uneventful. The patient made a good recovery with complete relief of all symptoms. Complete resection of the cystic lesion was confirmed on MRI at 6 weeks postsurgery (Figure 3). Furthermore, at 5 years, the

postoperative course was uneventful without any complications, pain well controlled, and no gross neurologic deficits noted.

DISCUSSION

SEACs are rare arising as a diverticulum of the arachnoid prolapsing into the epidural space through a small defect of the dura mater.^{1–3} In most instances, the SEAC is located in the posterior or posterolateral region of the dural sac and only occasionally anterior or anterolateral.⁴ The cause of the dural defect is unclear, but both a congenital and a traumatic tear have been suggested.⁵ Abnormal development of arachnoid granulations, which typically are present on the dural sheath of spinal nerve roots, has also been mentioned.⁶ The exact mechanism that leads to the development of a SEAC is speculative. The pulsatile ejection of cerebrospinal fluid resulting in extradural expansion of the extruded arachnoid membrane or arachnoid diverticulum has been suggested.^{7,8} In case of a leak in the arachnoid, the arachnoid membrane might serve as a valve, preventing or hindering the cerebrospinal fluid to flow back intradurally. As a result, a gradual expansion of the arachnoid pouch occurs due to pressure-related erosion of the bony structures, resulting in the development of a cavity/bone defect in the spine.^{9,10}

Clinical symptoms may vary and depend on the size and location of the cyst. Compression symptoms of nerve roots, spinal cord, and/or cauda equina may occur.^{11–14} Our search of the literature revealed only 14 cases that clinically presented with radicular and/or limb pain as a major complaint. Patient characteristics are listed in Table 1. Although all patients complained of radiating pain, in only one case was the compromise of a nerve root into the arachnoid cyst confirmed during surgery.¹⁵ This included the identification of the L1 root herniating into the arachnoid cyst.¹⁵

Our present report is the first to present with a thoracic nerve root herniating into an extradural arachnoid cyst, visualized on the preoperative MRI and confirmed during surgical exploration. Like the case by Sangala et al.,¹⁵ our patient suffered exacerbation of radicular pains during

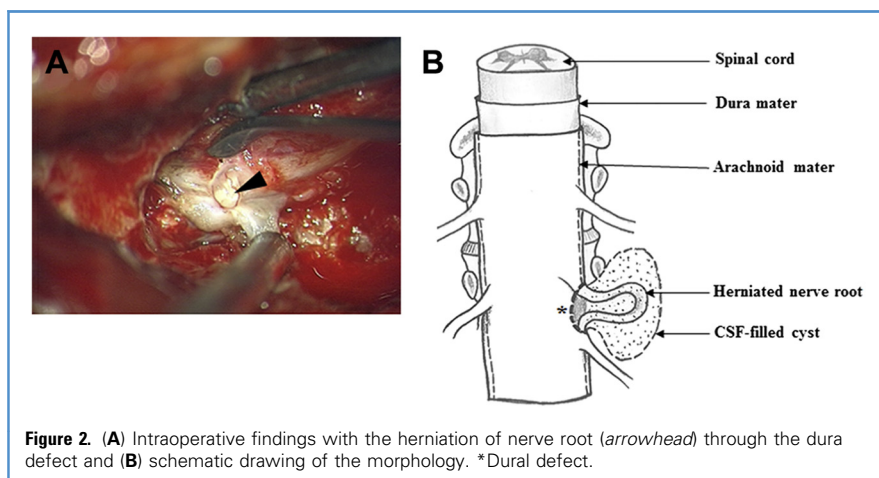


Figure 2. (A) Intraoperative findings with the herniation of nerve root (arrowhead) through the dura defect and (B) schematic drawing of the morphology. *Dural defect.

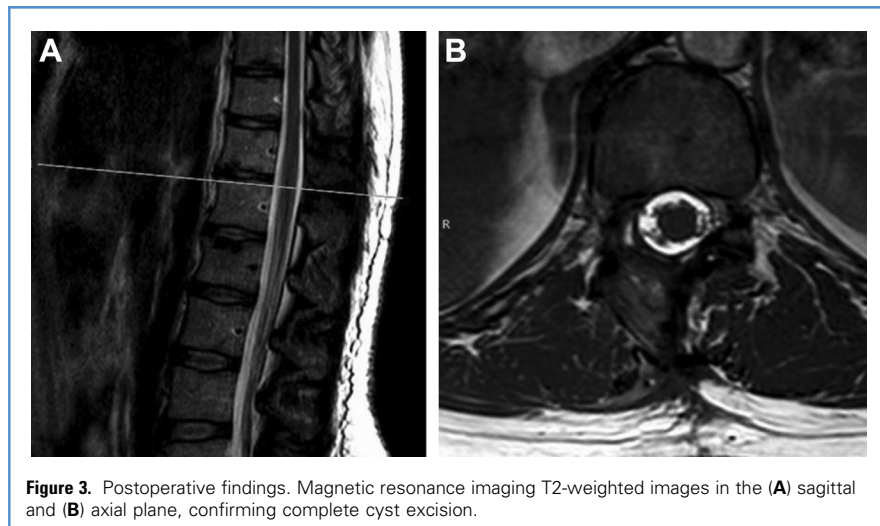


Figure 3. Postoperative findings. Magnetic resonance imaging T2-weighted images in the (A) sagittal and (B) axial plane, confirming complete cyst excision.

straining and exertion, which suggests a mechanism of intermittent pressure gradients between intradural and extradural spaces. This resulted in herniation or prolapse of the nerve root through the dural defect into the extradural arachnoid cyst, causing irradiating pain. Imaging tools such as MRI and computed tomography (CT) provide significant information related to cyst location, size, and its relationship to

adjacent tissues, which in combination with myelography can help to identify the site of communication between the cyst and thecal sac, although this communication may not be evident in all SEAC cases. Oh et al.⁸ performed MRI, MRI myelography, CT, and CT myelography, whereas Tokmak et al.⁴ reported only MRI T₁- and T₂-weighted sequences. In a series of 14 patients by Oh et al.,⁸ preoperative imaging revealed

the connection site between cyst and subarachnoid space in 8. During surgery, in all except one patient, a dural defect was found and repaired.¹⁶ Interestingly, Tokmak et al.⁴ did not mention any preoperative identification of the connection with imaging techniques, but during surgical exploration such a connection was identified (and closed) in 7 of 10 cases. Sangala et al.¹⁵ used CT myelography and intrathecal enhanced CT to localize the communication site.

We did not perform any additional imaging technique except MRI because of the fact that the T₂-weighted imaging already suggested the herniation of a nerve root into the extradural arachnoid cyst. As a noninvasive alternative for CT myelography, techniques such as kinematic and cine-MRI are advocated, to visualize the movement of fluid and the direction of flow, to detect the site of the (supposed) dural defect,^{2,17} and Miyamoto et al.¹⁸ demonstrated the usefulness of preoperative MRI myelography for this purpose.

Although several surgical procedures have been proposed for the treatment of SEACs, complete resection of the cyst using a (hemi)laminectomy or laminoplasty approach along with closure of the dural

Table 1. Summary of Case Reports About Thoracic and Lumbar Extradural Arachnoid Cysts Presenting with Radicular Signs/Symptoms

Study	Age, years, Sex	Level	Signs and Symptoms	Surgery	Root Herniation	Imaging Studies
Sangala et al., 2009 ¹⁵	18, F	T12–L1	Leg/back pain, L1 sensory and motor deficit	Dura repair	L1	MRI, CTm
Oh et al., 2012 ⁸	46, F	T11–L3	Leg/back pain, paraparesis	Cyst excision, dura repair	No	MRI, MRI, CTm
	26, F	T10–L1	Leg/back pain, monoparesis	Cyst excision, dura repair	No	MRI, MRI, CTm
	49, M	T11–L2	Leg/back pain, paraparesis	Cyst excision, dura repair	No	MRI, MRI, CTm
	25, M	T11–L2	Leg/back pain, L2/L3 sensory deficit	Cyst excision, dura repair	No	MRI, MRI, CTm
	44, F	T12–L1	Leg/back pain, L2/L3 sensory deficit	Cyst excision, dura repair	No	MRI, MRI, CTm
	61, F	T12–L2	Leg pain, paraparesis	Cyst excision, dura repair	No	MRI, MRI, CTm
	14, M	T10–L2	Leg pain, paraparesis	Cyst excision, dura repair	No	MRI, MRI, CTm
	21, F	T11–T12	Leg/back pain, L4/L5 sensory deficit	Cyst excision	No	MRI, MRI, CTm
Tokmak et al., 2015 ⁴	18, F	T5–T6	Radicular/back pain	Cyst resection	No	MRI
	52, M	T12–L1	Radicular pain	Partial cyst resection	No	MRI
	60, M	T7–T10	Radicular pain, paraparesis	Partial cyst resection	No	MRI
	63, M	T9	Radicular/back pain, paraparesis	Cyst resection	No	MRI
	67, F	T7–T11	Radicular/back pain, paraparesis	Cyst resection	No	MRI
Present case, 2017	35, F	T11–T12	Radicular/back pain	Cyst resection, dura repair	T11	MRI

F, female; T, thoracic; L, lumbar; MRI, magnetic resonance imaging; CTm, computed tomographic myelography; MRI, magnetic resonance imaging myelography; M, male.

defect is considered as the standard treatment.^{2,7,17} Recently, the “twist technique” as an alternative approach to the conventional repair procedure was proposed by Lee et al.¹⁶ Until now, only 2 cases with nerve root herniation into a SEAC have been reported. It seems that such a coincidence is exceptional in SEAC. The presence of radicular pain/limb pain as a dominant clinical symptom does not necessarily go together with nerve root herniation. In contrast, as is shown by Sangala et al.,¹⁵ preoperative imaging studies are unreliable to rule out such a condition before surgery. In that perspective, twisting of the wall without a thorough inspection of interior of the cyst would be hazardous and potentially harmful for a nerve root that is herniating into the cyst. Thorough exploration of the inner part of the arachnoid cyst seems to be the safest approach, followed by resection of the excess of the wall of the cyst, repositioning of the nerve root (if needed), and closure of the dural tear.

CONCLUSIONS

Transdural herniation of thoracic spinal nerve root into an arachnoid cyst can present as a radiculopathy, unlike those cases in which spinal cord and/or adjacent nerve root compression resulted due to a progressive cyst expansion. The nerve root herniation into the SEAC likely results from a mechanism of intermittent pressure gradients between the intradural and extradural compartments, which explains the typical presentation in current case. This is of surgical relevance, as it calls for thorough exploration of the cystic contents and direct closure of the dural tear

instead of twisting the arachnoid sac at its communicating stalk, as was proposed in a recent report. Consequently, this twisting leads to a risk of unintentional strangulation in those cases in which an unidentified nerve root is herniating into the SEAC.

REFERENCES

1. McCrum C, Williams B. Spinal extradural arachnoid pouches. Report of two cases. *J Neurosurg.* 1982;57:849-852.
2. Doita M, Nishida K, Miura J, Takada T, Kurosaka M, Fujii M. Kinematic magnetic resonance imaging of a thoracic spinal extradural arachnoid cyst: an alternative suggestion for exacerbation of symptoms during straining. *Spine.* 2003;28:E229-E233.
3. Kerr JM, Ukpeh H, Steinbok P. Spinal extradural arachnoid cyst presenting as recurrent abdominal pain. *Childs Nerv Syst.* 2015;31:965-969.
4. Tokmak M, Ozek E, Iplikcioglu AC. Spinal extradural arachnoid cysts: a series of 10 cases. *J Neurol Surg A Cent Eur Neurosurg.* 2015;76:348-352.
5. Honda E, Fujisawa H, Koyama T, Oshima Y, Sugita Y, Abe T. Symptomatic spinal arachnoid cyst triggered by seat belt injury—case report. *Neurol Med Chir.* 1998;38:168-172.
6. Teng P, Papatheodorou C. Spinal arachnoid diverticula. *Br J Radiol.* 1966;39:249-254.
7. Krings T, Lukas R, Reul J, Spetzger U, Spetzger U, Reinges MH, et al. Diagnostic and therapeutic management of spinal arachnoid cysts. *Acta Neurochir.* 2001;143:227-234 [discussion: 234-235].
8. Oh JK, Lee DY, Kim TY, Yi S, Ha Y, Kim KN, et al. Thoracolumbar extradural arachnoid cysts: a study of 14 consecutive cases. *Acta Neurochir.* 2012; 154:341-348.
9. Gortvai P. Extradural cysts of the spinal canal. *J Neurol Neurosurg Psychiatry.* 1963;26:223-230.
10. Rohrer DC, Burchiel KJ, Gruber DP. Intraspinous extradural meningeal cyst demonstrating ball-valve mechanism of formation. Case report. *J Neurosurg.* 1993;78:122-125.
11. Chang IC, Chou MC, Bell WR, Lin ZI. Spinal cord compression caused by extradural arachnoid cysts. Clinical examples and review. *Pediatr Neurosurg.* 2004;40:70-74.
12. Kumar K, Malik S, Schulte PA. Symptomatic spinal arachnoid cysts: report of two cases with review of the literature. *Spine.* 2003;28:E25-E29.
13. Liu H, Ishihara H, Kawaguchi Y, Abe Y, Otaya A, Sakurai S, et al. Large thoracolumbar extradural arachnoid cyst. *Orthopedics.* 2004;27:225-226.
14. Liu JK, Cole CD, Kan P, Schmidt MH. Spinal extradural arachnoid cysts: clinical, radiological, and surgical features. *Neurosurg Focus.* 2007;22:E6.
15. Sangala JR, Uribe JS, Park P, Martinez C, Vale FL. Nerve root prolapse into a spinal arachnoid cyst—an unusual cause of radiculopathy. *Clin Neurol Neurosurg.* 2009;111:460-464.
16. Lee SH, Shim HK, Eun SS. Twist technique for removal of spinal extradural arachnoid cyst: Technical note. *Eur Spine J.* 2014;23:1755-1760.
17. Neo M, Koyama T, Sakamoto T, Fujibayashi S, Nakamura T. Detection of a dural defect by cinematic magnetic resonance imaging and its selective closure as a treatment for a spinal extradural arachnoid cyst. *Spine.* 2004;29:E426-E430.
18. Miyamoto M, Kim K, Matsumoto R, Isobe M, Isu T. Utility of preoperative magnetic resonance imaging myelography for identifying dural defects in patients with spinal extradural arachnoid cysts: case report. *Neurosurgery.* 2006;59:E941.

Conflict of interest statement: The authors declare that the article content was composed in the absence of any commercial or financial relationships that could be construed as a potential conflict of interest.

Received 22 May 2017; accepted 17 July 2017

Citation: *World Neurosurg.* (2017) 106:1056.e5-1056.e8. <http://dx.doi.org/10.1016/j.wneu.2017.07.105>

Journal homepage: www.WORLDNEUROSURGERY.org

Available online: www.sciencedirect.com

1878-8750/\$ - see front matter © 2017 Elsevier Inc. All rights reserved.