



Case Report

J Liver Cancer 2023;23(1):206-212
pISSN 2288-8128 • eISSN 2383-5001
<https://doi.org/10.17998/jlc.2023.02.09>

A case of successful surgical treatment for peritoneal seeding of hepatocellular carcinoma after radiotherapy and atezolizumab plus bevacizumab combination treatment

Yuri Cho¹, Bo Hyun Kim¹, Tae Hyun Kim^{1,3}, Young Hwan Koh⁴, Joong-Won Park^{1,2}

¹Center for Liver and Pancreatobiliary Cancer, National Cancer Center, Goyang; ²Graduate School of Cancer Science and Policy, National Cancer Center, Goyang; ³Proton Therapy Center, National Cancer Center, Goyang; ⁴Department of Radiology, National Cancer Center Research Institute, Goyang, Korea

Peritoneal seeding of hepatocellular carcinoma (HCC) is incurable and has poor prognosis. A 68-year-old man underwent surgical resection for a 3.5 cm single nodular HCC at the tip of segment 3 and transarterial chemoembolization for a 1.5 cm-sized recurrent HCC at the tip of segment 6. 3 months later, an increasing 1 cm pelvic nodule on the rectovesical pouch warranted radiotherapy. Although it stabilized, a new 2.7 cm-sized peritoneal nodule in the right upper quadrant (RUQ) omentum appeared 3.5 years after radiotherapy. Hence, omental mass and small bowel mesentery mass excision were performed. 3 years later, recurrent peritoneal metastases in the RUQ omentum and rectovesical pouch progressed. 33 cycles of atezolizumab and bevacizumab treatment elicited stable disease response. Finally, laparoscopic left pelvic peritonectomy was performed without tumor recurrence. Herein, we present a case of HCC with peritoneal seeding that was successfully treated with surgery after radiotherapy and systemic therapy, leading to complete remission. (**J Liver Cancer 2023;23:206-212**)

Keywords: Hepatocellular carcinoma; Peritoneal seeding; Atezolizumab; Bevacizumab; Radiotherapy

Received Jan. 12, 2023
Revised Feb. 6, 2023
Accepted Feb. 9, 2023

INTRODUCTION

Peritoneal metastasis is a rare form of recurrence in hepatocellular carcinoma (HCC). Reports suggest that implantation of tumor cells by rupture of the primary tumor,¹ needle biopsy, or radiofrequency ablation (RFA)² may cause peritoneal dissemination of HCC. Peritoneal metastasis is a sign of

advanced HCC, and the treatment of choice is systemic therapy.³ Additionally, surgical resection has been reported to improve prognosis.⁴ Nakayama et al.⁵ reported that surgical resection is particularly beneficial for patients with less than four metastatic nodules, metachronous metastases, and an alpha-fetoprotein value <200 ng/mL. However, it is ambiguous whether peritoneal HCC metastases have the same biologic and prognostic value as other extrahepatic metastases: dissemination and growth of viable cells outside the liver.⁶⁻⁸ Peritoneal seeding is often studied in conjunction with other extrahepatic localizations.^{9,10} Aggressive tumor biology is often observed in patients with peritoneal localizations caused

Corresponding author: Joong-Won Park

Center for Liver and Pancreatobiliary Cancer, National Cancer Center, 323 Ilsan-ro, Ilsandong-gu, Goyang 10408, Korea
Tel: +82-31-920-1605; Fax: +82-31-920-2799
E-mail: jwpark@ncc.re.kr

by seeding following spontaneous rupture of HCC. Furthermore, there is a lack of research comparing treatments for the peritoneal seeding of HCC.

In this study, we present a novel case of peritoneal seeding in a patient with HCC who received radiotherapy and at-

ezolizumab plus bevacizumab combination treatment followed by successful surgical treatment for seeding nodules.

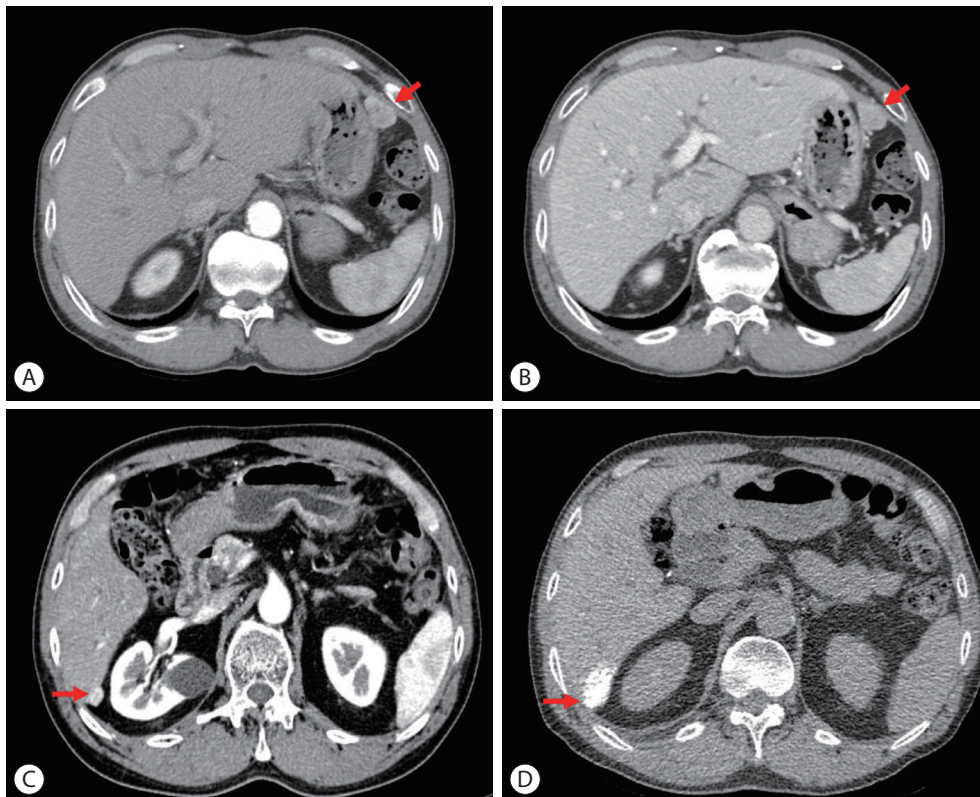


Figure 1. Initial and follow-up liver dynamic computed tomography (CT) imaging findings. (A) Arterial and (B) portal phase on July 2012, 3.5 cm single nodular hepatocellular carcinoma (HCC) on S3 (red arrow). (C) Arterial phase, before transarterial chemoembolization (TACE) on May 2014, 1.5 cm recurrent HCC on S6 (red arrow). (D) Lipiodol uptake (red arrow) on non-contrast CT after TACE on July 2014.

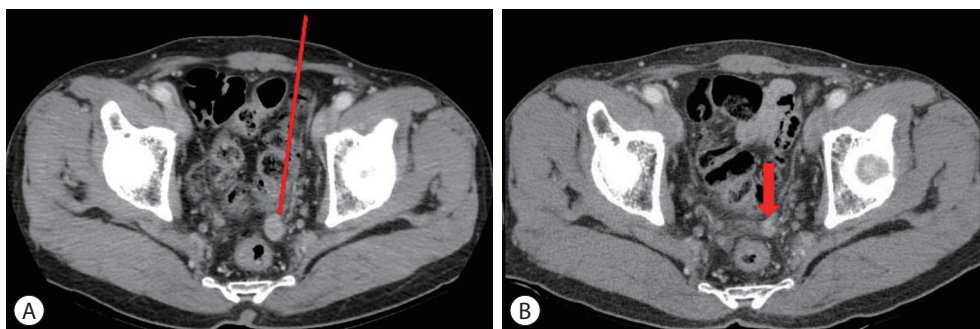


Figure 2. Follow-up liver dynamic computed tomography (CT) imaging findings before and after radiotherapy transarterial chemoembolization. (A) Liver dynamic CT, arterial phase, before radiotherapy on October 2014, 1 cm nodule on the rectovesical pouch (red arrow). (B) Liver dynamic CT, arterial phase, 5 mm nodule (red arrow) after radiotherapy on June 2015.

CASE REPORT

A 68-year-old man was initially diagnosed with a 3.5 cm single nodular HCC at the tip of segment 3 (Fig. 1A, B). The patient had alcoholic liver cirrhosis with Child-Pugh class A5 liver function. Surgical resection was performed for single nodular HCC. 16 months later, a 1.5 cm-sized single nodular HCC recurred at the tip of segment 6 (Fig. 1C). The patient's alpha-fetoprotein (AFP) level was 133.76 ng/mL, and the prothrombin induced by vitamin K absence (PIVKA-II) was 75 mAU/mL. The patient underwent conventional transarter-

rial chemoembolization for the recurrent tumor (Fig. 1D). Three months later, a 1 cm nodule increasing in size was observed on the rectovesical pouch (Fig. 2A). Radiation therapy for pelvic nodules was performed at a dose of 4,500 cGy in 10 fractions. Eight months after radiotherapy, the pelvic nodule size decreased to approximately 5 mm (Fig. 2B), and 2 years after radiotherapy, the pelvic nodule on the rectovesical pouch stabilized. However, a new 2.7 cm sized peritoneal nodule developed in the right upper quadrant omentum (Fig. 3A) 3.5 years after radiotherapy. Additionally, the size of the pelvic nodule on the rectovesical pouch had increased

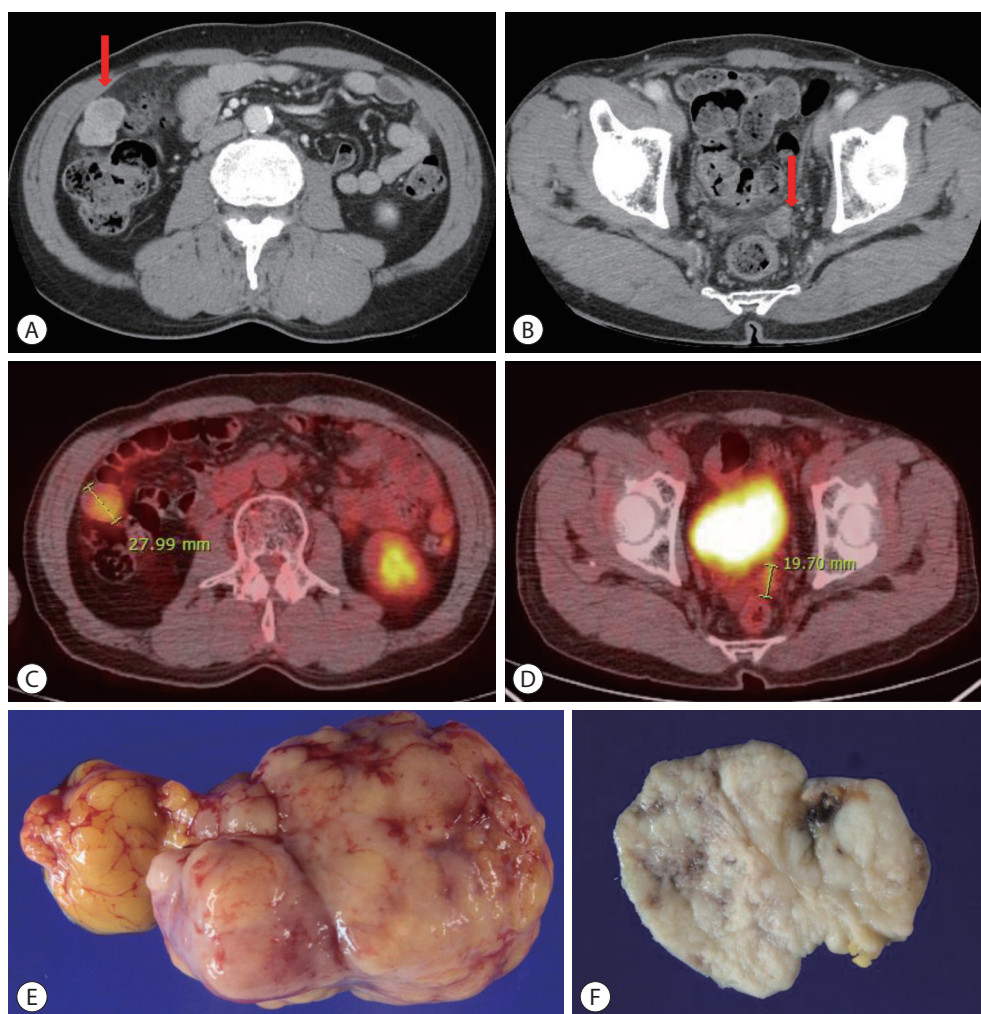


Figure 3. Follow-up liver dynamic computed tomography (CT) and positron emission tomography (PET)/CT imaging findings on May 2017: the progression of peritoneal metastases and omental metastatic mass of hepatocellular carcinoma after surgical resection on June 2017. (A) Liver dynamic CT, arterial phase, right upper quadrant area on abdominal cavity (red arrow). (B) Liver dynamic CT, arterial phase, rectovesical pouch (red arrow). (C) PET/CT, 2.8 cm sized nodule on right upper quadrant area on abdominal cavity. (D) PET/CT, 1.97 cm sized nodule on the rectovesical pouch. (E) Mass on right upper quadrant area on abdominal cavity. (F) Mass on the rectovesical pouch.

to 1.5 cm (Fig. 3B). The standard uptake value (SUV) of the 2.7 cm sized peritoneal nodule in the right upper quadrant omentum was 4.0 and the SUV of the rectovesical pouch was 3.1 upon ^{18}F -fluorodeoxyglucose positron emission tomography scan (Fig. 3C, D). AFP and PIVKA-II levels were 2.7 ng/mL, and 58 mAU/mL, respectively. Hence, omental and small bowel mesentery mass excision were performed to remove the pelvic nodules (Fig. 3E, F), and the histology of the resected nodules was compatible with metastatic HCC. Three years after surgical resection, recurrent peritoneal metastases in the right upper quadrant (RUQ) omentum (Fig. 4A) and the rectovesical pouch (Fig. 4B) were noted. The patient then started systemic therapy with atezolizumab and bevacizumab. After 15 cycles of atezolizumab and bevacizumab combination therapy, the peritoneal nodule on the RUQ omentum had decreased to 2 mm in size (Fig. 4C). However, the recur-

rent peritoneal metastatic nodule on the rectovesical pouch remained unchanged with a size of 4 cm (Fig. 4D). The patient received 33 cycles of atezolizumab and bevacizumab as systemic therapy. Finally, laparoscopic left pelvic peritonectomy was performed to remove the remaining pelvic nodule in the rectovesical pouch (Fig. 5). Histology revealed a clear cell neoplasm with necrosis, which was compatible with steatohepatic-type metastatic HCC. Six months after surgical treatment, there was no evidence of tumor recurrence in the peritoneum. The level of AFP was 2.1 ng/mL, and the PIVKA-II level was 31 AU/mL at the time of the final follow-up visit (Fig. 6).

DISCUSSION

Peritoneal recurrence is a rare form of HCC. According to

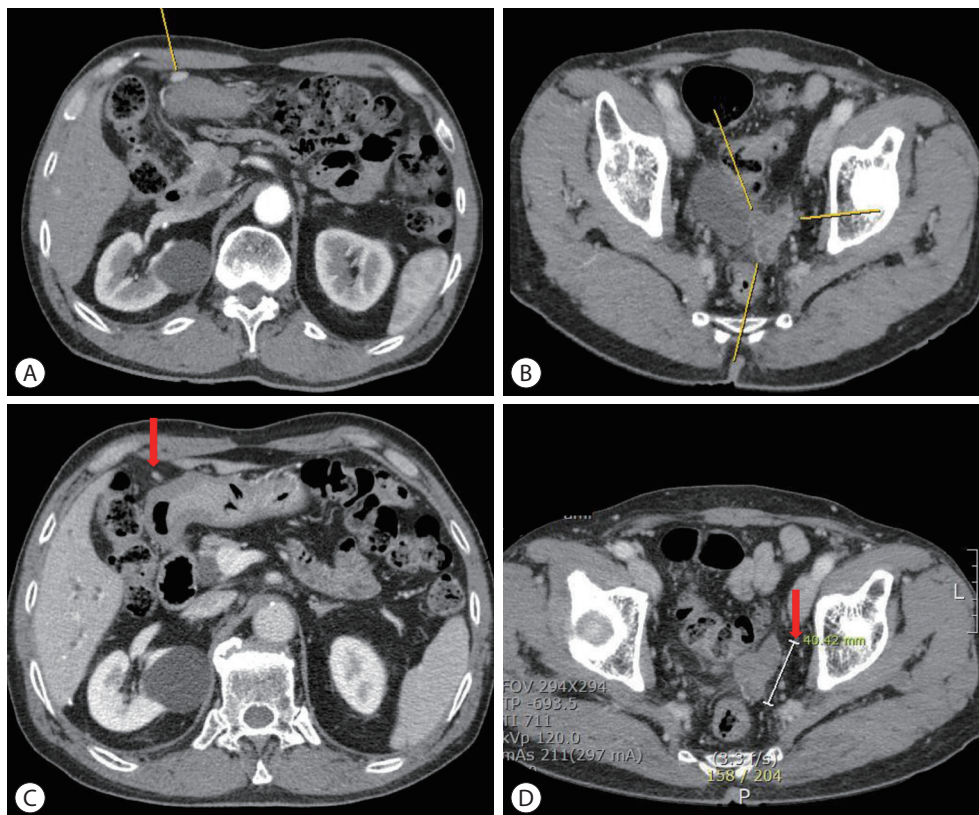


Figure 4. Follow-up liver dynamic computed tomography (CT) imaging findings before and after systemic therapy: the recurrence of peritoneal metastases. (A) Liver dynamic CT, arterial phase, right upper quadrant area on abdominal cavity (yellow line) on June 2020. (B) Liver dynamic CT, arterial phase, rectovesical pouch (yellow line) on June 2020. (C) Liver dynamic CT, arterial phase, right upper quadrant area on abdominal cavity (red arrow) on June 2021 after 33 cycles of atezolizumab and bevacizumab combination therapy. (D) Liver dynamic CT, arterial phase, rectovesical pouch (red arrow) on June 2021 after 33 cycles of atezolizumab and bevacizumab combination therapy.

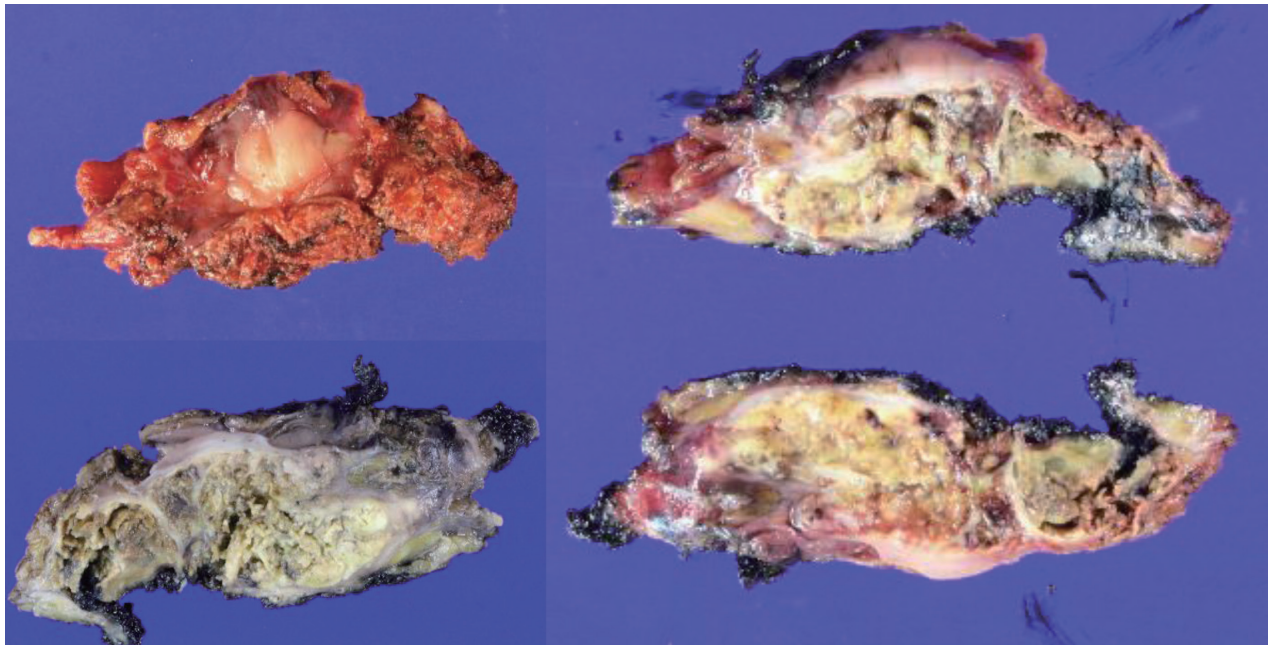


Figure 5. Omental metastatic mass of hepatocellular carcinoma after left pelvic peritonectomy on July 2022.

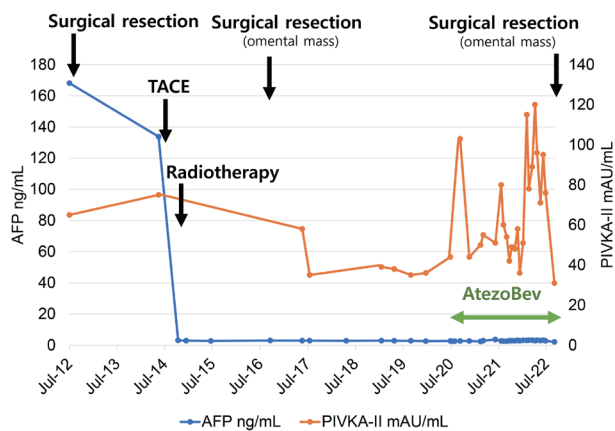


Figure 6. Clinical course of the patient with alpha-fetoprotein (AFP) and prothrombin induced by vitamin K absence (PIVKA-II). TACE, transarterial chemoembolization.

the report of the 22nd Nationwide Survey of Primary Liver Cancer in Japan (2012–2013),¹¹ of 7,494 resected HCC cases, only 28 (0.4%) had peritoneal dissemination. Implantation of tumor cells during needle biopsy, RFA, surgical resection, and tumor rupture are the main causes of peritoneal dissemination. However, research on treatment strategies for peritoneal HCC recurrence is severely lacking. While peritoneal seeding in other types of cancer is usually widespread and

not effectively managed with surgery, peritoneal metastasis of HCC is often localized. In fact, several reports have indicated that resection for peritoneal recurrence improves the prognosis of patients with HCC.^{12,13}

The mechanisms that drive peritoneal metastasis remain unclear. One theory is that exophytic HCC rupture in the peritoneal cavity contributes to metastasis. Several studies have revealed that ruptured HCC can lead to peritoneal seeding.^{7,14,15} However, in most patients, including this case, there is no evidence of overt HCC rupture. These patients probably had microscopic peritoneal metastases while the main tumors were treated. The diagnosis of HCC with peritoneal seeding after surgical resection was based on clinical suspicion. Rising serum AFP levels with no radiologic evidence of intrahepatic tumor recurrence suggest the possibility of extrahepatic recurrence.¹⁶ Typical radiologic manifestations of peritoneal seeding include peritoneal thickening with enhancing nodules, ascites, and omental cakes.¹⁷

A recent retrospective cohort study¹⁸ analyzed 11 patients with HCC peritoneal metastasis. Seven patients received systemic therapy with sorafenib, and four were treated with upfront peritonectomy followed by systemic therapy with sorafenib at recurrence. The median overall survival was 60

months for patients with peritoneal metastasis who were treated with immediate surgery, whereas the overall survival of the systemic therapy group was 11.8 months. Hence, this study highlights early surgical intervention as an effective strategy for peritoneal seeding in HCC.

In this case, when recurrence developed in the rectovesical pouch for the first time, radiotherapy was the first choice of treatment. Few reports have described the successful application of radiotherapy for the treatment of peritoneal seeding in patients with HCC. However, HCC is sensitive to radiotherapy. A recent case report from Japan also supports radiotherapy as a viable strategy for treating peritoneal seeding masses of HCC.¹⁹

In addition, recent advances in systemic therapy for HCC might play a key role in managing peritoneal metastasis. A recent case report from Japan suggested that peritoneal recurrence after surgical resection was effectively treated with first-line lenvatinib, second-line sorafenib, and third-line atezolizumab in addition to bevacizumab combination therapy.²⁰ The patient was treated with atezolizumab plus bevacizumab combination therapy again and maintained partial remission as an outpatient.

In conclusion, peritoneal seeding of HCC is rare and may occur synchronously or metachronously. We encountered a patient who successfully underwent curative surgical treatment for peritoneal seeding of HCC after radiotherapy and atezolizumab and bevacizumab combination treatment. However, further studies are needed to support the role of surgery combined with radiotherapy and systemic therapy for peritoneal seeding in HCC.

Conflicts of Interests

The authors have no conflicts of interest to disclose.

Ethics Statement

The Institutional Review Board of National Cancer Center waived the requirement for ethics approval and informed consent (IRB number: 2022-0536-0001).

Funding Statement

This research was supported by the National Research

Foundation of Korea grant funded by the Korea government (2021R1A2C4001401) and by a grant from the National Cancer Center, Korea (#2210420).

Data Availability

Data sharing not applicable to this article as no datasets were generated or analyzed for this case report.

ORCID

| | |
|----------------|---|
| Yuri Cho | https://orcid.org/0000-0002-4488-5352 |
| Bo Hyun Kim | https://orcid.org/0000-0001-8355-3126 |
| Tae Hyun Kim | https://orcid.org/0000-0001-8413-3385 |
| Young Hwan Koh | https://orcid.org/0000-0002-4598-6956 |
| Joong-Won Park | https://orcid.org/0000-0001-9972-0494 |

Authors Contributions

Conceptualization: JWP

Data curation: YC, BHK, JWP

Methodology: THK, YHK, JWP

Project administration: YC, JWP

Writing original draft: YC, JWP

Writing review & editing: YC, JWP

Approval of final manuscript: all authors

References

1. Hung MC, Wu HS, Lee YT, Hsu CH, Chou DA, Huang MH. Intra-peritoneal metastasis of hepatocellular carcinoma after spontaneous rupture: a case report. *World J Gastroenterol* 2008;14:3927-3931.
2. Lee SK, Song MJ. Drop metastasis from hepatocellular carcinoma after percutaneous radiofrequency ablation therapy. *Korean J Intern Med* 2017;32:943-944.
3. Korean Liver Cancer Association; National Cancer Center. 2022 KLCA-NCC Korea practice guidelines for the management of hepatocellular carcinoma. *Clin Mol Hepatol* 2022;28:583-705.
4. Portolani N, Baiocchi GL, Gheza F, Molfino S, Lomiento D, Giulini SM. Parietal and peritoneal localizations of hepatocellular carcinoma: is there a place for a curative surgery? *World J Surg Oncol* 2014;12:298.
5. Nakayama H, Takayama T, Makuuchi M, Yamasaki S, Kosuge T, Shimada K, et al. Resection of peritoneal metastases from hepatocellular carcinoma. *Hepatology* 1999;46:1049-1052.
6. Kirikoshi H, Saito S, Yoneda M, Fujita K, Mawatari H, Uchiyama T,

- et al. Outcomes and factors influencing survival in cirrhotic cases with spontaneous rupture of hepatocellular carcinoma: a multi-center study. *BMC Gastroenterol* 2009;9:29.
7. Sonoda T, Kanematsu T, Takenaka K, Sugimachi K. Ruptured hepatocellular carcinoma evokes risk of implanted metastases. *J Surg Oncol* 1989;41:183-186.
 8. Yeh CN, Chen MF. Resection of peritoneal implantation of hepatocellular carcinoma after hepatic resection: risk factors and prognostic analysis. *World J Surg* 2004;28:382-386.
 9. Lin CC, Liang HP, Lee HS, Huang GT, Yang PM, Ho MC, et al. Clinical manifestations and survival of hepatocellular carcinoma patients with peritoneal metastasis. *J Gastroenterol Hepatol* 2009;24:815-820.
 10. Belluco C, Petricoin EF, Mammano E, Facchiano F, Ross-Rucker S, Nitti D, et al. Serum proteomic analysis identifies a highly sensitive and specific discriminatory pattern in stage 1 breast cancer. *Ann Surg Oncol* 2007;14:2470-2476.
 11. Kudo M, Kitano M, Sakurai T, Nishida N. General rules for the clinical and pathological study of primary liver cancer, nationwide follow-up survey and clinical practice guidelines: the outstanding achievements of the Liver Cancer Study Group of Japan. *Dig Dis* 2015;33:765-770.
 12. Hai S, Okada T, Iimuro Y, Hirano T, Suzumura K, Fujimoto J. Successful laparoscopic extirpation of peritoneal dissemination after hepatectomy for ruptured hepatocellular carcinoma. *Asian J Endosc Surg* 2015;8:465-467.
 13. Kurachi K, Suzuki S, Yokoi Y, Okumura T, Inaba K, Igarashi T, et al. A 5-year survivor after resection of peritoneal metastases from pedunculated-type hepatocellular carcinoma. *J Gastroenterol* 2002;37:571-574.
 14. Lin CC, Chen CH, Tsang YM, Jan IS, Sheu JC. Diffuse intraperitoneal metastasis after spontaneous rupture of hepatocellular carcinoma. *J Formos Med Assoc* 2006;105:577-582.
 15. Kim SR, Ikawa H, Ando K, Mita K, Fuki S, Imoto S, et al. Small hepatocellular carcinoma presenting with massive metastasis in the peritoneum, mimicking sarcomatous tumor. *Hepatol Res* 2007;37:885-889.
 16. Yeh CN, Chen MF, Jeng LB. Resection of peritoneal implantation from hepatocellular carcinoma. *Ann Surg Oncol* 2002;9:863-868.
 17. Walkey MM, Friedman AC, Sohotra P, Radecki PD. CT manifestations of peritoneal carcinomatosis. *AJR Am J Roentgenol* 1988;150:1035-1041.
 18. Da Fonseca LG, Leonardi PC, Hashizume PH, Sansone F, Saud LR, Carrilho FJ, et al. A multidisciplinary approach to peritoneal metastasis from hepatocellular carcinoma: clinical features, management and outcomes. *Clin Exp Hepatol* 2022;8:42-48.
 19. Enomoto H, Fujiwara M, Kono H, Kako Y, Takahagi M, Taniguchi J, et al. Metastasis of hepatocellular carcinoma in the pouch of Douglas successfully treated by radiation therapy: a case report. *Life (Basel)* 2023;13:225.
 20. Katsura Y, Takeda Y, Ohmura Y, Sakamoto T, Shinke G, Katsuyama S, et al. A case of successful treatment of recurrent peritoneal dissemination of hepatocellular carcinoma with atezolizumab plus bevacizumab combination therapy. *Gan To Kagaku Ryoho* 2021;48:2027-2029.