

К.Ю. Литвин^{1*},
В.В. Маврутенков¹,
О.М. Якуніна¹,
З.О. Чыкарєнко¹,
О.О. Білокон¹,
М.О. Турчын²

GUILLAIN-BARRÉ SYNDROME AS AN EARLY COMPLICATION OF A NEW CORONAVIRUS INFECTION SARS-COV-2 (clinical case)

*Dnipro State Medical University*¹

V. Vernadskyi str., 9, Dnipro, 49044, Ukraine

Municipal non-profit enterprise "City Clinical Hospital No. 21 named after prof. E.G.Popkova" DCC²

Kanatna str., 17, Dnipro, 49000, Ukraine

*Дніпровський державний медичний університет*¹

вул. В. Вернадського, 9, Дніпро, Україна

*КНП «Міська клінічна лікарня № 21 ім. проф. Є.Г. Попкової» ДМР»*²

вул. Канатна, 17, Дніпро, 49000, Україна

**e-mail: k-lytvyn@ukr.net*

Цитування: *Медицинські перспективи*. 2022. Т. 27, № 3. С. 181-185

Cited: *Medicni perspektivi*. 2022;27(3):181-185

Key words: *Guillain-Barré syndrome, coronavirus infection, polyneuropathy*

Ключові слова: *синдром Гієна-Барре, коронавірусна інфекція, полінейропатія*

Abstract. *Guillain-Barré syndrome as an early complication of a new coronavirus infection SARS-CoV-2 (clinical case). Lytvyn K.Yu., Mavrutenkov V.V., Yakunina O.M., Chykarenko Z.O., Bilokon O.O., Turchyn M.O. The new strain of coronavirus SARS CoV-2 can affect any organ and system of the body. The pathogenesis of these lesions is due to both direct damage to body cells by the virus and the development of immunopathological reactions that can lead to demyelinating diseases of the nervous system. The article presents a clinical case of the development of Guillain-Barré syndrome associated with coronavirus disease in a 71-year-old man who developed after infection with a new strain of SARS CoV-2 virus. The man was hospitalized on the seventh day of the disease with complaints of unproductive cough, weakness, fever in the range of 37.5-38.7°C, shortness of breath during exercise. The clinical diagnosis was confirmed by the presence of SARS CoV-2 RNA in the nasopharyngeal secretion. According to digital radiography, the presence of interstitial pneumonia was determined. Against the background of treatment, the condition gradually improved and on the 14th day after the onset of the disease, a negative PCR result (SARS CoV-2 (-) RNA) was obtained. However, on the 16th day of hospital stay (23-24th days of the disease) he was diagnosed with polyneuropathy (Guillain-Barré syndrome), severe tetraparesis. Despite the therapy, the condition gradually deteriorated due to the progression of polyneuropathy. On the 9th day after the onset of neurological symptoms (25th days of illness), on the background of severe neurological deficits, the signs of respiratory and cardiovascular insufficiency developed, which led to the death of the patient. It has been shown that the course of Guillain-Barré syndrome, which developed after infection with a new strain of SARS CoV-2 virus, in this case has a severe course and lethal outcome of the disease. It is necessary to look for clinical predictors that would predict the occurrence of neurological complications in patients with coronavirus disease.*

Реферат. *Синдром Гієна-Барре як раннє ускладнення нової коронавірусної інфекції SARS-CoV-2 (клінічний випадок). Литвин К.Ю., Маврутенков В.В., Якуніна О.М., Чыкарєнко З.О., Білоконь О.О., Турчын М.О. Новий штам коронавірусу SARS CoV-2 здатний уражати будь-який орган та систему організму. Патогенез цих уражень зумовлений як прямим uszkodженням клітин організму вірусом, так і розвитком імунопатологічних реакцій, що можуть призвести до демієлінізуючих захворювань нервової системи. У статті наведено клінічний випадок розвитку синдрому Гієна-Барре, пов'язаного з коронавірусною хворобою, у чоловіка 71 року, який розвинувся після інфікування новим штамом вірусу SARS CoV-2. Чоловік потрапив до лікарні на сьому добу захворювання зі скаргами на непродуктивний кашель, слабкість, лихоманку в межах 37,5-38,7°C, задуху при фізичному навантаженні. Клінічний діагноз було підтверджено наявністю в секреті з носоглотки РНК SARS CoV-2. За даними цифрової рентгенографії визначена наявність інтерстиціальної пневмонії. На тлі лікування стан поступово покращився та на 14 день від початку захворювання був отриманий негативний результат ПЛР (РНК SARS CoV-2 (-)). Однак на 16 добу перебування в стаціонарі (23-24 доба захворювання) діагностовано полінейропатію (синдром Гієна-Барре), тяжкий тетрапарез. Незважаючи на терапію, що проводилась, стан поступово погіршувався через прогресування полінейропатії. На 9-ту добу від появи неврологічних симптомів (25 доба хвороби), на тлі тяжкого неврологічного дефіциту розвинулися явища*

дихальної та серцево-судинної недостатності, що призвело до загибелі хворого. Показано, що перебіг синдрому Г'єна-Барре, який розвинувся після інфікування новим штамом вірусу SARS CoV-2, у цьому випадку має тяжкий перебіг та летальний кінець хвороби. Потрібний пошук клінічних предикторів, які б дозволили спрогнозувати виникнення неврологічних ускладнень у пацієнтів з коронавірусною хворобою.

Guillain-Barré syndrome (GBS) is a set of clinical symptoms characterized by the development of acute inflammatory polyneuropathy, which is manifested by muscle weakness, moderate loss of distal sensitivity and self-limiting course. The disease was first described by the French neurologist J.B.O. Landry in 1859. The frequency of the syndrome is 1-2:100,000 population [4]. Men get sick more often than women in the ratio 1.1-1.7:1. GBS affects people aged from 2 months to 95 years, but, in general, with increasing age there is a tendency to increase: in people under 18 it is 0.8:100,000 population, and over the age of 60 years – 3.2:100,000. More often there are two peaks of morbidity: at the age of 15-35 years and 50-75 years [2, 3, 12].

There are many forms of this disease, but those that are most often diagnosed in medical practice are: 1) acute inflammatory demyelinating polyneuropathy (80% of all cases); 2) acute motor axonal neuropathy (10-15%); 3) acute motor-sensory axonal neuropathy (5-10%). All these forms are united by the clinical picture: the development of acute flaccid tetraparesis, with rapid (for less than 4 weeks) development of weakness of the muscles of the extremities and torso. Other forms of GBS (Miller Fischer syndrome, acute pandysautonomy, pharyngo-cervical-brachial form, facial diplegia, etc.) are rare (<1%).

The frequency of GBS subtypes varies from country to country. In Europe and North America, acute inflammatory demyelinating polyradiculopathy (polyneuropathy) accounts for 85-90% of cases, and in China and Japan – acute motor axonal neuropathy is more common [4]. Guillain-Barré syndrome is now the most common cause of acute peripheral paralysis in many countries around the world, including Ukraine. This nosology is included in the top seven priority research areas in world neurology and is included in the European list of orphan diseases [10, 12].

GBS is recognized as a post-infectious immune-mediated disease that affects peripheral nerves. In the anamnesis, patients with GBS often note a previous infection with *Campylobacter jejuni* (32% of cases, in China – up to 60%), with a lower frequency – Cytomegalovirus (15%), Epstein-Barr virus (10%), *Mycoplasma pneumoniae* (5%) [3].

In terms of the ability to be a trigger for the development of GBS, the most studied bacterium is *C. Jejuni* [11]. According to modern ideas, the ability of *C. Jejuni* to initiate an autoimmune process is due to the phenomenon of molecular mimicry. Immune

reactions directed against lipopolysaccharide antigens of the *C. jejuni* capsule lead to the formation of antibodies that cross-react with myelin GM1 gangliosides, resulting in immunological damage to the peripheral nervous system [5, 6].

In addition, provoking agents can be herpes simplex and shingles, influenza, Coxsackie, hepatitis B, as well as vaccination (against influenza, sometimes against rubella, mumps, measles, rabies), surgery and traumatic damage to peripheral nerves [11]. Cases of GBS at lymphoproliferative diseases, systemic lupus erythematosus, viral hepatitis E, hypothyroidism have been described in the medical literature [6]. It is possible that many of the identified infectious agents induce the production of antibodies that cross-react with certain myelin gangliosides and glycolipeptids in the peripheral nervous system [5]. Taking certain drugs may also precede the development of GBS [2].

In the world, during 2020-2021 there is a pandemic of coronavirus infection. Typical manifestations of coronavirus disease (COVID-19) are mostly respiratory. But as the pandemic grows, so is the number of reports of extrapulmonary presentation of COVID-19 both in outpatient practice and among hospitalized patients. The new strain of coronavirus SARS CoV-2 can affect any organ and system of the body. From the point of view of pathogenesis, neurological disorders in COVID-19 can be caused by "cytokine storm", hypoxemia, disorders of homeostasis (critical state encephalopathy), neurotropicity and neurovirulence of SARS-CoV-2 (isolated lesions of the cranial nerves and focal and diffuse damage of CNS), as well as the mixed influence of these factors. COVID-19 affects the course of chronic neurological diseases, especially those associated with neuroimmune disorders. All of the above mentioned determines the need for a multidisciplinary approach to the treatment of COVID-19 and its complications.

Genetic predisposition, death of oligodendrocytes, nerve cells and their processes, activation of microglia, cytokines (tumor necrosis factor alpha, IL4, IL10), auto-sensitized clones (CD4 +, Th1, Th17 of cellular immune response), molecular mimicry are significant factors of demyelination initiation in central and peripheral nervous system during infection and hospitalization [6]. The variety of mechanisms, the involvement of different structures determines the wide spectrum of clinical forms in the range: from leukoencephalopathy, encephalitis,

transverse myelitis to the main and atypical variants of Guillain-Barré syndrome [1, 7, 9, 13].

Observations on the development of GBS on the background of coronavirus disease are very few and indicate a significant range of terms of possible development of typical neurological manifestations: from 1 to 4 weeks after making the diagnosis of COVID-19. At the same time, there are isolated data on the development of GBS simultaneously with the manifestation of COVID-19, which determines the parainfectious nature of the disease. Therefore, there is reason to believe that possible factors in the development of GBS are the direct neuroinvasive effect of SARS CoV-2, namely the ability of the virus to affect angiotensin-converting enzyme neurons (ACE-2), or immunoinflammatory response with tissue damage due to high levels of inflammatory cytokines. (in particular interleukin-6 (IL-6)) [8, 13]. However, given the small number of existing observations, the analysis of each new case of GBS may be useful to broaden the understanding of the development of this syndrome in patients with COVID-19.

Objective – to analyze a rare clinical case of Guillain-Barré polyneuropathy due to SARS CoV-2 virus infection in order to improve the understanding of the pathogenesis and prevention of the development of this pathology.

MATERIALS AND METHODS OF RESEARCH

A clinical case of the development of Guillain-Barré syndrome associated with coronavirus disease in a 71-year-old man, who was treated from 26.01.2021 to 05.02.2021 at the "City Clinical Hospital No. 21 named after prof. E.G. Popkova" (infectious) is presented.

The patient did not use any new hardware research methods and new pharmacological drugs. The patient was acquainted with the amount of the planned study, the informed consent was obtained. Laboratory and instrumental methods of research are generally accepted, all drugs used in treatment are allowed for use. Throughout the observation period, the patient was provided with complete confidentiality of personal data. The Commission on Biomedical Ethics decided that the research conducted and described in the article should be considered as meeting the generally accepted standards of morality, requirements for the rights, interests and personal dignity of research participants. There is no risk for research subjects during the work

Male, 71 years old, Ukrainian, retired, resident of Dnipro, was hospitalized on the seventh day of the disease with complaints of unproductive cough, weakness, fever in the range of 37.5-38.7°C, shortness of breath during exercise. Objectively: The patient's condition is moderate, body temperature – 38.0°C, respiratory rate – 20/min, heart rate – 88/min,

blood pressure 130/65 mm Hg, skin of normal color, moderately moist, no rash or edema. In the lungs – there is crepitation on both sides, more in the lower lateral parts. Oxygen saturation (SpO₂) – 95-97%. Meningeal, focal symptoms were not detected.

Clinical diagnosis: Coronavirus disease, bilateral pneumonia. The diagnosis was confirmed by the presence of RNA of a new strain of SARS CoV-2 virus in the nasopharyngeal secretion by polymerase chain reaction (PCR). From the history: the patient's wife has a coronavirus infection. Life history: in 2015, a pacemaker was installed. Clinically, the disease was of the respiratory type – according to the digital radiograph, the presence of interstitial pneumonia was determined (Fig.). Oxygen support was not prescribed: oxygen saturation (SpO₂) was 95-97%. Laboratory indicators (on admission to the hospital):

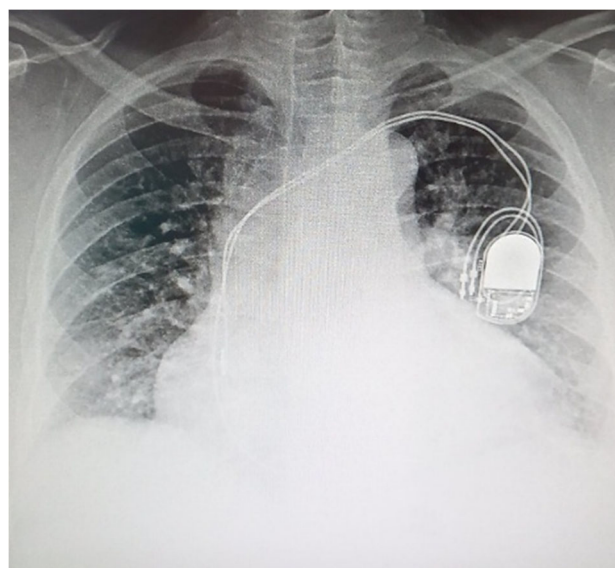
1. Complete blood count: erythrocytes $4.6 \cdot 10^{12}/L$; hemoglobin $141 \cdot 10^9/L$; platelets $345 \cdot 10^9/L$; erythrocyte sedimentation rate (ESR) 25 mm/hour; leukocytes $4.7 \cdot 10^9/L$; bands 5%; segments 60%; lymphocytes 30%; monocytes 3%, eosinophils 2%;

2. General analysis of urine was unremarkable;

3. Coagulogram: prothrombin time – 10.6 sec (decreased), prothrombin according to Quick – 108.7.8%, international normalizing ratio (INR) – 1.12 units, activated partial thromboplastin time (PTT) – 26.2 (decreased) sec, prothrombin index – 104%, fibrinogen – 6.6 g/L (increased);

4. Biochemical analysis of blood: bilirubin total- 16 $\mu\text{mol}/L$, bilirubin direct – 4 $\mu\text{mol}/L$, bilirubin indirect 12 $\mu\text{mol}/L$, ALT 0.4 $\mu\text{mol}/L$, urea 6.4 $\mu\text{mol}/L$, urea nitrogen 2.9 $\mu\text{mol}/L$, residual nitrogen 22.4 $\mu\text{mol}/L$, creatinine 96.6 $\mu\text{mol}/L$, glucose 3.6 mmol/L, C-reactive protein (CRP) was negative;

5. Radiograph of the thoracic cavity (Fig.).



Radiograph of the chest of the patient L.

The thorax radiograph shows bilateral infiltration of the lung tissue, more in the lower lobe on both sides. Also bilateral arrangement of inflammatory changes (numerous shadows of the "frosted glass" type of round shape and various sizes), which have a peripheral or basal location.

Treatment included: prevention of thrombotic complications ("activation", being in a proun position during prolonged sleep, wearing high compression stockings, rivaroxaban 15 mg/day); anti-inflammatory immunosuppressive therapy – dexamethasone 24 mg/day intravenously; adjuvant systemic antibacterial therapy: 3rd generation cephalosporins. With the treatment, the condition gradually improved, PCR investigation on day 14: SARS CoV-2 RNA was not detected, body temperature came back to normal. Due to the satisfactory condition of the patient, a discharge from the hospital was scheduled for further supervision of a family doctor, but on the 16th day of hospital stay (23-24th days disease) in the morning, when trying to get out of bed, the patient unexpectedly lost his balance and fell due to a sharp weakness in his legs. On examination: consciousness on the Glasgow scale 15 points, SpO₂ level – 96%, respiratory rate 18/min., blood pressure 135/90 mm Hg. At neurological examination there was a significant "neurological deficit" in the form of muscular hypotension of the lower and upper extremities while maintaining sensitivity, meningeal signs are negative. The patient was diagnosed with polyneuropathy (Guillain-Barré syndrome), tetraparesis, severe course.

Laboratory indicators at the time of detection of polyneuropathy:

1. Complete blood count showed appearance of leukocytosis: erythrocytes $5.0 \cdot 10^{12}/L$; hemoglobin $152 \cdot 10^9/L$; platelets $305 \cdot 10^9/L$; ESR 18 mm/hour; leukocytes $15.7 \cdot 10^9/L$; myelocytes 2%; young 2%; band neutrophils 5%; segments 76%; lymphocytes 8%; monocytes 7%;

2. Urinalysis remained normal;

3. Coagulogram: prothrombin time 13.3 sec, prothrombin according to Quick 91.8%, INR 1.12 units, aPTT 28.1 sec, prothrombin index 87%, fibrinogen 4.4 g/L;

4. Biochemical analysis of blood showed increased blood glucose to $9.4 \mu\text{mol}/L$, CRP remained negative.

Prescribed treatment: homologous human immunoglobulin at the rate of 1 g/kg per day intravenously,

for 5 days. For further treatment, the patient was transferred to the neurology department on the same day, where the administration of immunoglobulin was continued and methylprednisolone was prescribed in the regime of pulse therapy, prophylaxis of deep venous thrombosis (subcutaneous heparin). In the dynamics of the disease, the condition worsened due to the progression of polyneuropathy: myasthenia worsened, total areflexia developed. The patient was transmitted to intensive care unit. On the 9th day from the appearance of neurological symptoms, on the background of severe neurological deficit, the patient developed respiratory and cardiovascular failure, which led to death of the patient. An autopsy was not performed due to the categorical refusal of the relatives.

CONCLUSIONS

1. A new coronavirus infection caused by SARS CoV-2 virus may cause demyelinating diseases of the peripheral nervous system, in particular Guillain-Barré syndrome, and the number of neurological manifestations and complications should be expected to increase over time. The extrapulmonary manifestation of COVID-19 requires a multidisciplinary approach to treatment and its complications.

2. The course of Guillain-Barré syndrome, which developed after infection with a new strain of SARS CoV-2 virus, in this case has a severe course and an unfavorable outcome of the disease in the 2nd week after the onset of clinical manifestations.

3. In this case, there was no relationship between the severity of coronavirus disease (mild) and the occurrence, severity and consequences of Guillain-Barré syndrome.

Contributors:

Lytvyn K.Yu. – conceptualization, data curation, project administration;

Mavrutenkov V.V. – conceptualization, methodology, writing – review & editing;

Yakunina O.M. – investigation, validation, data curation;

Chykarenko Z.O. – Writing – review & editing;

Bilokon O.O. – visualization;

Turchyn M.O. – resources.

Funding. This research received no external funding.

Conflict of interests. The authors declare no conflict of interest.

REFERENCES

1. Alberti P, Beretta S, Piatti M, Karantzoulis A, Piatti ML, Santoro P. et al. Guillain-Barré syndrome related to COVID-19 infection. *Neurology*

Neuroimmunology Neuroinflammation. 2020;7(4). doi: <https://doi.org/10.1212/NXI.0000000000000741>

2. Chung A, Deimling M. Guillain-Barré Syndrome. *Pediatrics in review*. 2018;39(1):53-54. doi: <https://doi.org/10.1542/pir.2017-0189>
3. Doets AY, Verboon C, Van Den Berg B, Harbo T, Cornblath DR, Willison HJ, et al. Regional variation of Guillain-Barré syndrome. *Brain*. 2018;141(10):2866-77. Available from: <https://academic.oup.com/brain/article/141/10/2866/5104936?login=true>
4. Donofrio PD. Guillain-Barré Syndrome. *CONTINUUM: Lifelong Learning in Neurology*. 2017;23(5):1295-309. doi: <https://doi.org/10.1212/CON.0000000000000513>
5. Esposito S, Longo MR. Guillain-barré syndrome. *Autoimmunity reviews*. 2017;16(1):96-101. doi: <https://doi.org/10.1016/j.autrev.2016.09.022>
6. Mahecha MP, Ojeda E, Vega DA, Sarmiento-Monroy JC, et al. Guillain-Barré syndrome in Colombia: where do we stand now? *Immunologic research*. 2017;65(1):72-81. doi: <https://doi.org/10.1007/s12026-016-8816-8>
7. Padroni M, Mastrangelo V, Asioli GM, Pavolucci L, Abu-Rumeileh S, Piscaglia MG., et al. Guillain-Barré syndrome following COVID-19: new infection, old complication?. *Journal of neurology*. 2020;267(7):1877-9. doi: <https://doi.org/10.1007/s00415-020-09849-6>
8. Rahimi K. Guillain-Barre syndrome during COVID-19 pandemic: an overview of the reports. *Neurological Sciences*. 2020;41(11):3149-315. doi: <https://doi.org/10.1007/s10072-020-04693-y>
9. Sedaghat Z, Karimi N. Guillain Barre syndrome associated with COVID-19 infection: a case report. *Journal of Clinical Neuroscience*. 2020;76:233-5. doi: <https://doi.org/10.1016/j.jocn.2020.04.062>
10. Shahrizaila N, Lehmann HC, Kuwabara S. Guillain-Barré syndrome. *The Lancet*. 2021. doi: [https://doi.org/10.1016/S0140-6736\(21\)00517-1](https://doi.org/10.1016/S0140-6736(21)00517-1)
11. Sheikh KA. Guillain-Barré Syndrome. *CONTINUUM: Lifelong Learning in Neurology*. 2020;26(5):1184-204. doi: <https://doi.org/10.1212/CON.0000000000000929>
12. Willison HJ, Jacobs BC, van Doorn PA. Guillain-barre syndrome. *The Lancet*. 2016;388(N10045):717-27. doi: [https://doi.org/10.1016/S0140-6736\(16\)00339-1](https://doi.org/10.1016/S0140-6736(16)00339-1)
13. Zhao H, Shen D, Liu J, Chen S, Toscano G, Palmerini F, et al. Guillain-Barre syndrome associated with SARS-CoV-2 infection: causality or coincidence? *Lancet Neurol*. 2020;19(5):383-4. doi: [https://doi.org/10.1016/S1474-4422\(20\)30109-5](https://doi.org/10.1016/S1474-4422(20)30109-5)

Стаття надійшла до редакції
26.11.2021

