


CASE REPORT

Right ventricular postsystolic shortening: Resolution after opening a totally occluded right coronary artery

Sahrai Saeed¹  | Iman Karaji¹ | Kaia Skromme¹ | Anja Øksnes¹ | Terje H. Larsen^{1,2} | Øyvind Bleie¹

¹Department of Heart Disease, Haukeland University Hospital, Bergen, Norway

²Department of Biomedicine, University of Bergen, Bergen, Norway

Correspondence

Sahrai Saeed, Department of Heart Disease, Haukeland University Hospital, Bergen, Norway.

Email: sahrai_saeed@hotmail.com

Abstract

Acute myocardial ischemia induces reduced systolic shortening and causes post-systolic shortening (PSS). Right ventricular (RV) PSS in coronary artery disease has been less studied. We present here the case of a 51-year-old woman admitted with a non-ST segment elevation myocardial infarction and significant PSS in the RV free-wall segments on two-dimensional speckle tracking echocardiography, suggesting ongoing ischemia. A cardiac CT demonstrated occluded proximal right coronary artery with a low-attenuated/soft plaque, confirmed by coronary angiography which was treated by percutaneous coronary intervention. At 3-week follow-up, there was complete resolution of the RV-PSS, with a more synchronized pattern of maximum myocardial shortening at systole.

KEYWORDS

acute coronary syndrome, echocardiography, global longitudinal strain, left ventricular ejection fraction, right ventricular postsystolic shortening

1 | INTRODUCTION

Acute myocardial ischemia induces delayed postsystolic shortening (PSS) after the aortic valve closure (AVC), while the surrounding non-ischemic myocardial segments are already relaxing. The clinical significance and prognostic value of both left ventricular (LV) and right ventricular (RV) global longitudinal strain (GLS) and LV-PSS are well established in a number of conditions including coronary artery disease (CAD), systemic hypertension, stroke, cardiomyopathies and aortic stenosis.¹⁻⁴ However, to the best of our knowledge, there is no published data in the literature describing RV-PSS in patients with acute coronary syndrome, particularly in the setting of right coronary artery (RCA) occlusion.

2 | CASE REPORT

A 51-year-old woman presented with chest pain and dyspnea on exertion over the past few days. She was overweight, active smoker and had a history of CAD in her first-degree relatives. At presentation, there was no obvious signs of ischemia on ECG or wall motion abnormalities on echocardiography. RV (tricuspid annular plane systolic excursion = 27 mm) and LV systolic function (LV ejection fraction by biplane Simpson's method = 60%) was normal. The high sensitivity troponin T level was slightly elevated at 31 ng/L (normal <15 ng/L), which suggested a minor non-ST segment elevation myocardial infarction (NSTEMI). Cardiac computer tomography (CT) demonstrated an occluded proximal RCA (Figure 1A, arrow) with a low-attenuated/soft

This is an open access article under the terms of the [Creative Commons Attribution-NonCommercial-NoDerivs](https://creativecommons.org/licenses/by-nc-nd/4.0/) License, which permits use and distribution in any medium, provided the original work is properly cited, the use is non-commercial and no modifications or adaptations are made.

© 2022 The Authors. *Journal of Clinical Ultrasound* published by Wiley Periodicals LLC.

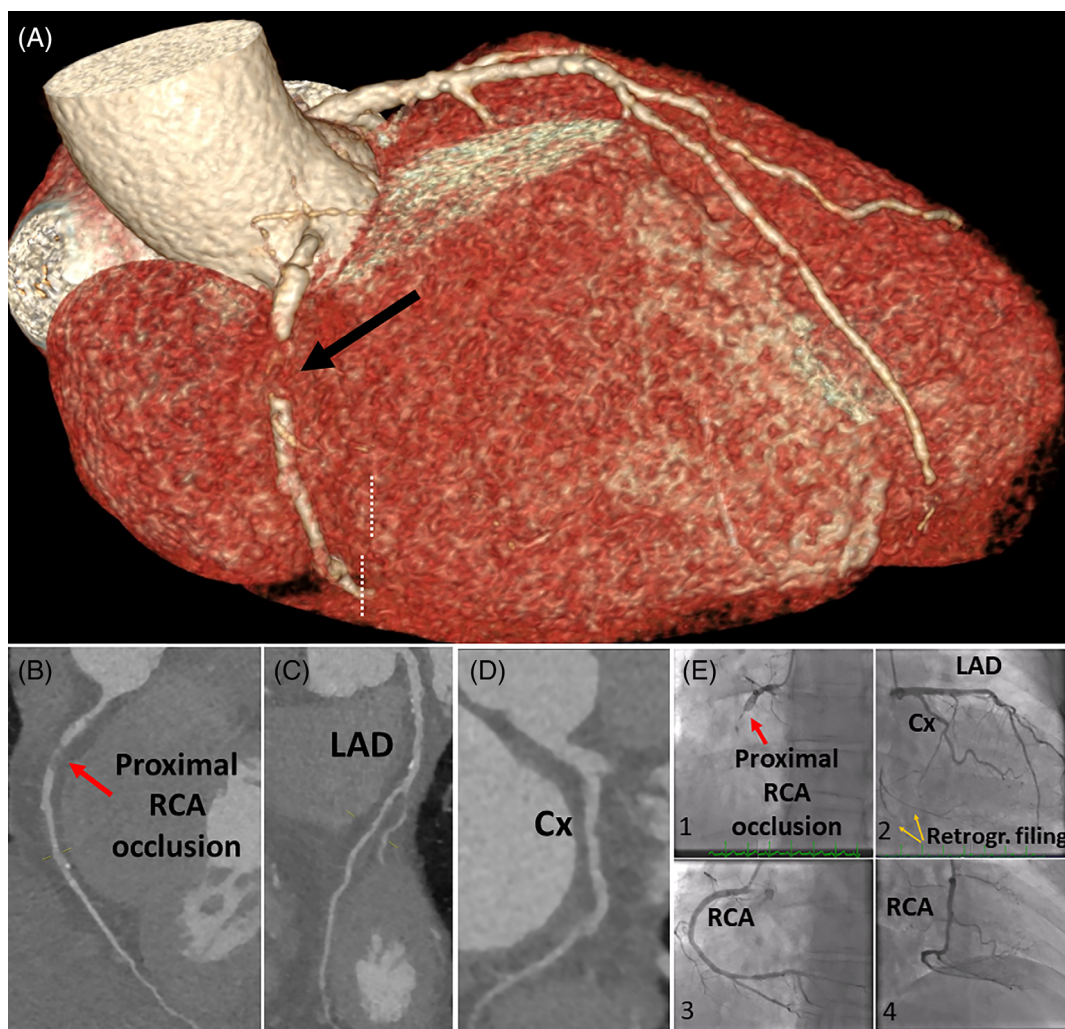


FIGURE 1 Cardiac computed tomography (CT) (A–D) and conventional angiography (E1–E4) images, showing occluded proximal RCA, treated with percutaneous coronary intervention (PCI) (E3 and E4). Cx, circumflex; LAD, left anterior descending; RCA, right coronary artery

plaque (Figure 1B, arrow), a stenosis more proximal in the RCA, and non-obstructive atherosclerotic lesions in the left anterior descending (LAD) (Figure 1C) and circumflex (Cx) (Figure 1D) arteries. Coronary calcium score was 119 Agatston units. Coronary angiography confirmed occluded proximal RCA (Figure 1E-1) and minimal non-obstructive disease in the LAD and Cx (Figure 1E-2). The RCA was treated with percutaneous coronary intervention (PCI) (1E-3 and E-4) followed by a transient blood pressure drop and bradycardia, which are not uncommon following revascularization of occluded RCA in the setting of acute myocardial infarction. In view of the clinical NSTEMI, normal LV ejection fraction without evidence of regional wall motion abnormalities, and an occluded RCA, LV and RV GLS and segmental strain curves were retrospectively analyzed. GLS was measured by two-dimensional speckle tracking echocardiography. End-systole was defined by aortic valve closure (AVC) using pulsed wave Doppler, which corresponded roughly with the end of T-wave on ECG (Figure 2, yellow vertical lines). Although LV-GLS was normal (-20% , Figure 2A), there was a clear postsystolic shortening (PSS) in the two basal segments of the inferior wall on apical 3-chamber view

(Figure 2B, red arrow). Similarly, RV-GLS was normal (-24.5% , Figure 2C) but significant PSS in all three segments of the RV free wall (Figure 2C, double arrows) was observed; i.e. approximately 80 ms delay in shortening following AVC (from peak systolic to peak global strain) in the basal and mid segments, and 120 ms in the apical free wall segment (Figure 2C). On the following day, the patient was discharged in a stable condition and with dual antiplatelet drugs and a statin. On a repeated echocardiogram at 3-week follow-up, LV ejection fraction and GLS remained unchanged (ejection fraction 62% and GLS -20%), with no signs of regional wall motion abnormalities (Figure 2D). However, global strain values on the apical 3-chamber view had now slightly improved (-21.5%) compared with the baseline (-19%) (Figure 2B), and PSS in the two basal segments of the LV inferior wall had almost reversed (Figure 2E). Interestingly, RV free wall strain further improved to -26% with a complete regression of PSS and a more synchronized pattern of maximum myocardial shortening at AVC (Figure 2F), which may indicate restoration of blood flow and reversal of ischemic impairment (stunning) of the RCA territory after PCI.

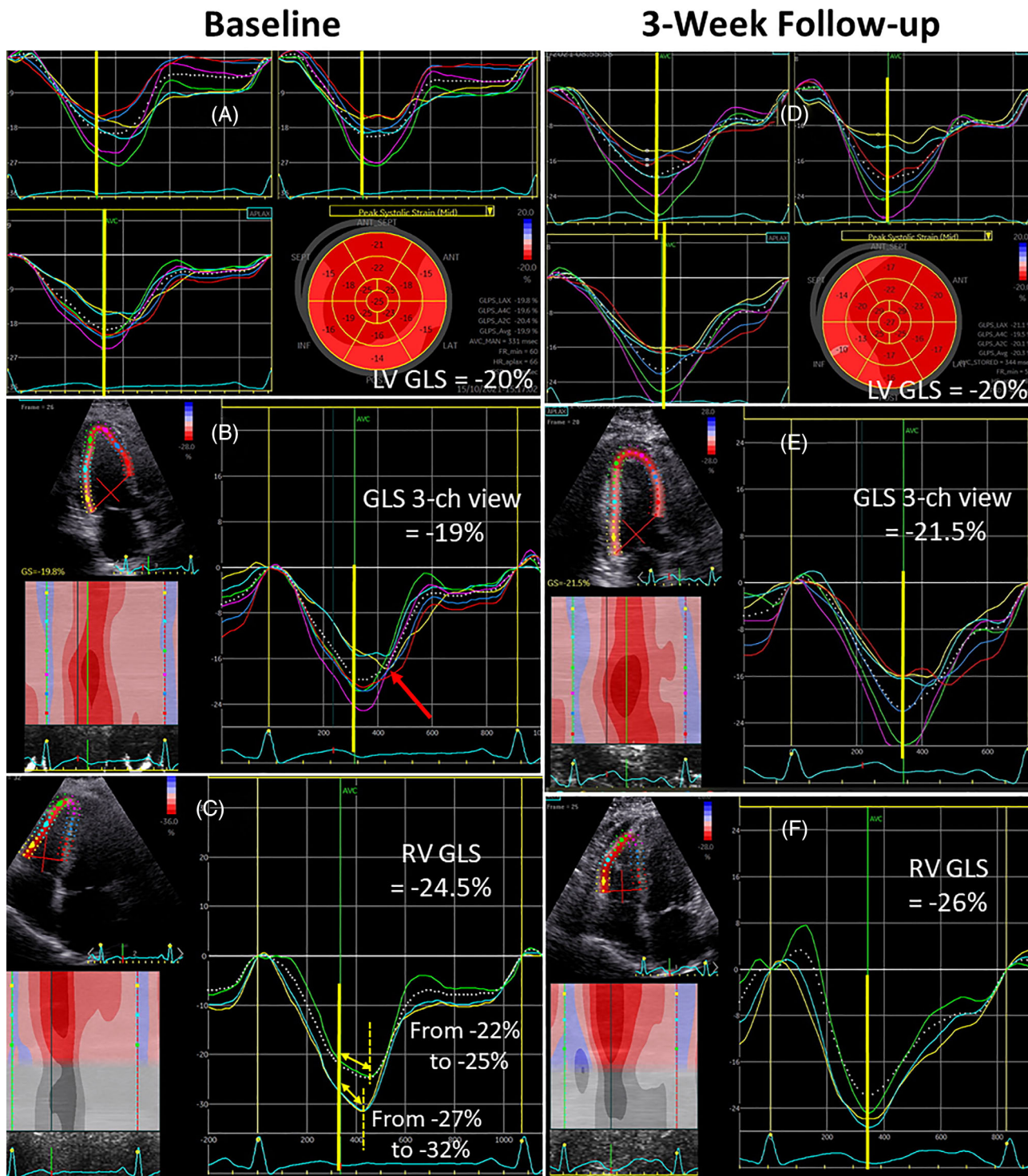


FIGURE 2 Two-dimensional speckle tracking echocardiography images, showing improvement (more negative values) of LV-GLS and regression of RV-GLS from baseline (A–C) to 3-week follow-up (D–F). GLS, global longitudinal strain; LV, left ventricular; RV, right ventricular

3 | DISCUSSION

Peak negative systolic strain is the maximum myocardial shortening at systole. The phenomenon of PSS is referred to as myocardial shortening after end-systole (AVC), and is a marker of regional myocardial dysfunction and delayed myocardial contraction. PSS does not contribute to the ejection of

blood but may inhibit diastolic filling.⁵ The mechanism of the appearance of PSS in an ischemic, but still viable segment was documented in an animal model by Skulstad et al. two decades ago.⁶ The authors demonstrated that PSS was an important feature of ischemic myocardium. However, when combined with dyskinesia, PSS seemed to be a nonspecific marker of severe ischemia. Here, we demonstrate RV-PSS in a patient with RCA

occlusion and ongoing ischemia, but normal LV ejection fraction and no signs of regional wall motion abnormalities. The reestablishment of coronary perfusion led to complete resolution of PSS at 3-week follow-up.

The novel finding of RV-PSS in our case report highlights the complimentary role of RV strain on two-dimensional speckle-tracking echocardiography to assess ongoing ischemia following a subacute RCA occlusion. RV-PSS is easy to assess by speckle-tracking echocardiography, and may be a useful marker of myocardial ischemia in patients with RCA-related myocardial infarction, particularly when the ECG does not show signs of acute ischemia and echocardiography demonstrates normal LV ejection fraction, regional wall motion, and RV and LV-GLS. The regression of RV-PSS as early as 3 weeks following successful PCI of the occluded RCA may indicate stunning of the myocardium and the potential benefit of restoring blood supply. Hence, RV-PSS in these patients may be a reliable marker of RV function recovery. Our case study is hypothesis generating and should encourage future prospective studies to investigate the clinical significance and prognostic value of RV-PSS.

CONFLICT OF INTEREST

The authors declare that they have no conflict of interest.

DATA AVAILABILITY STATEMENT

The data that support the findings of this study are available from the corresponding author upon reasonable request.

ORCID

Sahrai Saeed  <https://orcid.org/0000-0003-4041-5019>

REFERENCES

1. Eek C, Grenne B, Brunvand H, et al. Postsystolic shortening is a strong predictor of recovery of systolic function in patients with non-ST-elevation myocardial infarction. *Eur J Echocardiogr*. 2011;12:483-489.
2. Badano LP, Koliaas TJ, Muraru D, et al. Standardization of left atrial, right ventricular, and right atrial deformation imaging using 2-dimensional speckle-tracking echocardiography: a consensus document of the EACVI/ASE/industry task force to standardize deformation imaging. *Eur Heart J Cardiovasc Imaging*. 2018;19:591-600.
3. Morris DA, Krisper M, Nakatani S, et al. Normal range and usefulness of right ventricular systolic strain to detect subtle right ventricular systolic abnormalities in patients with heart failure: a multicentre study. *Eur Heart J Cardiovasc Imaging*. 2017;18:212-223.
4. Saeed S, Gerds E, Waje-Andreassen U, et al. Left ventricular myocardial dysfunction in young and middle-aged ischemic stroke patients: the Norwegian stroke in the young study. *J Hypertens*. 2019;37:538-545.
5. Brainin P, Biering-Sørensen SR, Møgelvang R, et al. Post-systolic shortening: normal values and association with validated echocardiographic and invasive measures of cardiac function. *Int J Cardiovasc Imaging*. 2019;35:327-337.
6. Skulstad H, Edvardsen T, Urheim S, et al. Postsystolic shortening in ischemic myocardium: active contraction or passive recoil? *Circulation*. 2002;106(6):718-724. doi:10.1161/01.cir.0000024102.55150.b6

How to cite this article: Saeed S, Karaji I, Skromme K, Øksnes A, Larsen TH, Bleie Ø. Right ventricular postsystolic shortening: Resolution after opening a totally occluded right coronary artery. *J Clin Ultrasound*. 2022;50(7):899-902. doi:10.1002/jcu.23251