



This is a repository copy of *Autoimmune manifestations in VEXAS: Opportunities for integration and pitfalls to interpretation.*

White Rose Research Online URL for this paper:

<https://eprints.whiterose.ac.uk/197929/>

Version: Published Version

---

**Article:**

Bruno, A. [orcid.org/0000-0001-8659-277X](https://orcid.org/0000-0001-8659-277X), Gurnari, C., Alexander, T. et al. (2 more authors) (2023) Autoimmune manifestations in VEXAS: Opportunities for integration and pitfalls to interpretation. *Journal of Allergy and Clinical Immunology*. ISSN 0091-6749

<https://doi.org/10.1016/j.jaci.2023.02.017>

---

**Reuse**

This article is distributed under the terms of the Creative Commons Attribution-NonCommercial-NoDerivs (CC BY-NC-ND) licence. This licence only allows you to download this work and share it with others as long as you credit the authors, but you can't change the article in any way or use it commercially. More information and the full terms of the licence here: <https://creativecommons.org/licenses/>

**Takedown**

If you consider content in White Rose Research Online to be in breach of UK law, please notify us by emailing [eprints@whiterose.ac.uk](mailto:eprints@whiterose.ac.uk) including the URL of the record and the reason for the withdrawal request.



[eprints@whiterose.ac.uk](mailto:eprints@whiterose.ac.uk)  
<https://eprints.whiterose.ac.uk/>

# Autoimmune manifestations in VEXAS: Opportunities for integration and pitfalls to interpretation

Alessandro Bruno, MD,<sup>a,\*</sup> Carmelo Gurnari, MD,<sup>b,c,\*</sup> Tobias Alexander, MD,<sup>d</sup> John A. Snowden, MD,<sup>e</sup> and Raffaella Greco, MD,<sup>a</sup> on behalf of Autoimmune Diseases Working Party of the European Society for Blood and Marrow Transplantation Milan and Rome, Italy; Cleveland, Ohio; Berlin, Germany; and Sheffield, United Kingdom

VEXAS (Vacuoles, E1 enzyme, X-linked, Autoinflammatory, Somatic) is a novel entity manifesting with a multiplicity of clinical features. Somatic mutations of the *UBA1* gene in hematopoietic stem cells constitute the genetic basis of VEXAS. As an X-linked disorder, most cases occur in men, classically developing symptoms during the fifth to sixth decade of life. Considering its multidisciplinary nature involving numerous branches of internal medicine, VEXAS has elicited a wide medical interest and several medical conditions have been associated with this disease. Even so, its recognition in everyday clinical practice is not necessarily straightforward. Close collaboration between different medical specialists is mandatory. Patients with VEXAS may manifest a range of features from manageable cytopenias to disabling and life-threatening autoimmune phenomena with limited responses to therapy, with the potential for progression to hematological malignancies. Diagnostic and treatment guidelines are exploratory and include a range of rheumatological and supportive care treatments. Allogeneic hematopoietic stem cell transplantation is potentially curative, but its risks are

significant and its position in the treatment algorithm is yet to be defined. Herein, we present the variegated manifestations of VEXAS, provide practice criteria for diagnostic testing of *UBA1*, and discuss potential treatment options, including allogeneic hematopoietic stem cell transplantation, current evidence, and future directions. (J Allergy Clin Immunol 2023;■■■:■■■-■■■.)

**Key words:** VEXAS, autoimmune manifestations, myelodysplastic syndrome, allogeneic hematopoietic stem cell transplant

## VEXAS: A NEW HEMATOINFLAMMATORY DISEASE

VEXAS, which is an acronym for Vacuoles, E1 enzyme, X-linked, Autoinflammatory, Somatic, constitutes a prototype of hematoinflammatory syndrome manifesting with autoimmune and hematopathologic features.<sup>1</sup> Patients develop inflammatory and hematologic symptoms, with clinical features that bridge rheumatological, dermatological, ophthalmological, respiratory, and hematological conditions. This complexity requires close collaboration between experienced hemato-oncologists and relevant disease specialists in diagnosis, management, and follow-up, which may ultimately involve transplant specialists. Early referral of patients is essential to optimize clinical outcomes and minimize risks.

Since its discovery,<sup>2</sup> numerous groups have progressively investigated the underlying genetics, pleomorphic clinical immune-related features, and potential treatment options. Although still much needs to be learned, herein we will provide an overview of pathogenesis, autoimmune manifestations, and potential treatment options.

Somatic mutations of the X-linked gene *UBA1* interfering with E1 enzyme activity constitute the genomic underpinnings of VEXAS.<sup>2</sup> These mutations occur classically in men at a median age of 50 to 60 years, whereas in the rare cases of VEXAS in women, the disorder shows a “pseudautosomal” character requiring somatic double hits (eg, Turner syndrome, acquired X deletions, or somatic X-skewing).<sup>3-6</sup> *UBA1* is expressed in 2 isoforms: *UBA1a* (starting at p.Met1), nuclear, and *UBA1b* (starting at p.Met41), cytoplasmic. The codon 41 represents a mutational hotspot where methionine is replaced by valine, threonine, or leucine, ultimately leading to a protein truncation.<sup>2</sup> Other rarer missense variants such as the p.Ser65Phe, and splice acceptor site mutations have also been described.<sup>7</sup> Both common missense and splice site variants are responsible for a decrease in the cytoplasmic level of UBA1 protein, whereas the rare p.Ser65Phe

From the <sup>a</sup>Unit of Hematology and Bone Marrow Transplantation, IRCCS San Raffaele Hospital, Vita-Salute San Raffaele University, Milan; <sup>b</sup>the Department of Translational Hematology and Oncology Research, Taussig Cancer Institute, Cleveland Clinic, Cleveland; <sup>c</sup>the Department of Biomedicine and Prevention, University of Rome Tor Vergata, Rome; <sup>d</sup>Charité - Universitätsmedizin Berlin, corporate member of Freie Universität Berlin, Humboldt-Universität zu Berlin, and Berlin Institute of Health, Department of Rheumatology and Clinical Immunology, Berlin; and <sup>e</sup>Sheffield Blood & Marrow Transplant and Cellular Therapy Programme, Department of Haematology, Sheffield Teaching Hospitals Foundation NHS Trust, Sheffield.

\*These authors contributed equally to this study.

This review was led and supported by the European Society for Blood and Marrow Transplantation (EBMT)-Autoimmune Diseases Working Party. The EBMT provided resources via the working party, data office, and registry. Other than EBMT support, there is no funding body supporting this review, commercial or otherwise.

Disclosure of potential conflict of interest: T. Alexander declares speaking honoraria from Amgen, Roche, and Pfizer, travel grants from Neovii, and study support from Amgen, Janssen-Cilag, and Miltenyi Biotec. J. A. Snowden declares advisory board membership from Medac. R. Greco discloses speaking honoraria from Biotest, Pfizer, Medac, and Magenta. The rest of the authors declare that they have no relevant conflicts of interest.

Received for publication December 21, 2022; revised February 10, 2023; accepted for publication February 16, 2023.

Corresponding author: Raffaella Greco, MD, Unit of Hematology and Bone Marrow Transplantation, IRCCS San Raffaele Hospital, via Olgettina 60, 20132, Milan, Italy. E-mail: [greco.raffaella@hsr.it](mailto:greco.raffaella@hsr.it). Or: Carmelo Gurnari, MD, Department of Biomedicine and Prevention, University of Rome Tor Vergata, 00133 Rome, Italy. E-mail: [carmelogurnari31@gmail.com](mailto:carmelogurnari31@gmail.com).

0091-6749

© 2023 The Authors. Published by Elsevier Inc. on behalf of the American Academy of Allergy, Asthma & Immunology. This is an open access article under the CC BY-NC-ND license (<http://creativecommons.org/licenses/by-nc-nd/4.0/>).

<https://doi.org/10.1016/j.jaci.2023.02.017>

**Abbreviations used**

AD:	Autoimmune disease
AZA:	Azacitidine
BM:	Bone marrow
GC:	Glucocorticoid
GF:	Graft failure
GvHD:	Graft-versus-host disease
HLH:	Hemophagocytic lymphohistiocytosis
HSCT:	Hematopoietic stem cell transplantation
JAK:	Janus kinase
MDS:	Myelodysplastic syndrome
NGS:	Next-generation sequencing
RIC:	Reduced-intensity conditioning
RTC:	Reduced-toxicity conditioning
VEXAS-RP:	VEXAS-relapsing polycondritis

variant appears to generate a temperature-dependent functional damage.<sup>8</sup> In particular, codon 41 mutations cause the translation of a truncated dysfunctional cytoplasmic protein (called *UBA1c* in the original Beck et al<sup>2</sup> report), starting at p.Met67. Of note is that *UBA1* mutations are not detected in mature lymphocytes, whereas they are present in hematopoietic stem and progenitor cells in the bone marrow (BM), thereby generating a condition of genetic mosaicism.<sup>2</sup> The mechanism for *UBA1-unmutated* lymphocytes selection is currently unknown, but because a significant part of the patients with VEXAS is lymphopenic, elimination of *UBA1-mutated* lymphocytes during their maturation process is likely.<sup>2</sup>

E1 enzyme is required for cellular ubiquitin signaling, which in VEXAS is globally altered by acquisition of somatic *UBA1* hits.<sup>9</sup> As a consequence, innate immune pathways are abnormally activated with hyperproduction of inflammatory cytokines such as TNF, IL-1, IL-6, IL-8, IFN- $\gamma$ -induced protein 10, and IFN- $\gamma$ , which have been demonstrated to be elevated in patients' sera, even during clinically quiescent periods, and in zebrafish models.<sup>2</sup> Such immune derangement is ultimately responsible for the variety of clinical manifestations.<sup>10</sup> In addition, despite occurring within the same genomic position, the type of amino acid substitution affects the cytoplasmic translation of *UBA1* in a heterogeneous fashion,<sup>11</sup> with p.Met41Val variant carriers showing 2-fold lower *UBA1* cytoplasmic levels compared with p.Met41Leu/Thr. Variances at a molecular level correlate with clinical outcomes, with the p.Met41Val genotype associated with decreased survival.<sup>11</sup>

## CLINICAL FEATURES OF VEXAS

### Autoimmune features

As discussed, patients with VEXAS present with various autoimmune manifestations.<sup>12,13</sup> Besides constitutional symptoms shared by many autoimmune/autoinflammatory conditions such as noninfectious fever and weight loss (present in up to two-third of cases), the skin is the most commonly involved organ, with a frequency achieving 90% and various types of manifestations.<sup>14</sup> In particular, patients with VEXAS can develop a neutrophilic dermatosis resembling Sweet syndrome as well as other histologically defined patterns (leukocytoclastic vasculitis and septal panniculitis).<sup>15</sup> Cases resembling classical Sweet syndrome have been demonstrated to harbor clonally restricted

*UBA1*-mutant cells in skin lesions, in addition to the BM.<sup>16</sup> Therefore, cutaneous manifestations of VEXAS may be clonal (directly caused by the actual *UBA1*-mutant clone) or paraclonal (resulting by the downstream effects of the inflammatory cytokines).<sup>15</sup>

The second most frequently involved organ is the lung.<sup>14</sup> Up to 70% of patients may present several pleuropulmonary disorders manifesting clinically with dyspnea and cough. In a study focusing on pulmonary complications, radiologic features included ground-glass opacities (87%), consolidations (49%), reticulation (38%), septal lines (51%), and pleural effusion (53%).<sup>17</sup> Although no differences were found in relation to the biology of the disease and outcomes, this study emphasized the need for a baseline and longitudinal pleuropulmonary assessment in VEXAS and showed good responses to treatment with glucocorticoids (GCs) with a low incidence of pulmonary fibrosis.<sup>17</sup>

Relapsing episodes of ear, nose, and peripheral joint chondritis are another common feature of VEXAS. In a study comparing VEXAS-relapsing polycondritis (VEXAS-RP) to idiopathic-relapsing polycondritis,<sup>18</sup> as expected, VEXAS cases were predominantly males (96% vs 30%;  $P < .001$ ), who were older at disease onset (66 vs 44 years;  $P < .001$ ) with a higher frequency of systemic features, including fever (60% vs 10%;  $P < .001$ ), skin lesions (82% vs 20%;  $P < .001$ ), ocular involvement (57% vs 28%;  $P = .01$ ), pulmonary infiltrates (46% vs 0%;  $P < .001$ ), and heart involvement (11% vs 0%;  $P = .0336$ ). The hyperinflammatory phenotype was also supported with higher median C-reactive protein levels in VEXAS compared with idiopathic cases (64 mg/L vs 10 mg/L;  $P < .001$ ).<sup>18</sup>

As in many other autoimmune conditions, ocular manifestations are also present (up to 40% of cases) and include uveitis, scleritis, episcleritis, and retinal vasculitis.<sup>14,18</sup> HLA-related mechanisms may explain the variable clinical picture of specific VEXAS manifestations, in a similar fashion to polymorphisms traditionally associated with autoimmune conditions (eg, HLA B27/B51 in Behçet syndrome).<sup>19</sup>

Besides cutaneous, pulmonary, and ocular manifestations, the gastrointestinal tract and the lymph nodes are involved at different rates.<sup>14</sup> Patients have also been reported with life-threatening complications, such as acute onset of chronic inflammatory demyelinating polyradiculoneuropathy and hemophagocytic lymphohistiocytosis (HLH).<sup>20,21</sup>

The clinicobiological presentation of VEXAS syndrome is therefore very heterogeneous. Raising the awareness of the rheumatological, dermatological, hematological, and other disease specialist communities should lead to earlier detection of VEXAS, resulting in better clinical management.

### Hematological features

The hallmark of VEXAS is the finding of BM vacuoles in hematopoietic precursors.<sup>22</sup> Although no specific threshold is set, the vacuolization of greater than or equal to 10% of myeloid precursors has been associated with a diagnosis of VEXAS with practically infallible sensitivity and specificity.<sup>23</sup> A study exploring the frequency of this cardinal diagnostic feature of VEXAS involved screening almost 12,000 BM specimens spanning 15 years at the Cleveland Clinic and confirmed that vacuolation of hematopoietic precursors is a relatively common feature shared by several conditions such as copper deficiency,<sup>24</sup> zinc toxicity, alcohol abuse, antibiotic treatment, and myelodysplastic syndrome (MDS).<sup>22,24</sup> However, other studies have reported

VEXAS cases with minimal BM changes, highlighting the limitations of using hematopathology alone.<sup>25</sup> Another hematological feature present in the totality of VEXAS cases is macrocytic anemia.<sup>26</sup> Other blood cell count alterations include lymphopenia, whereas thrombocytopenia and neutropenia are more common in cases with concomitant MDS.<sup>26</sup> The full spectrum of plasma cell dyscrasias ranging from monoclonal gammopathy of undetermined significance to multiple myeloma has also been described in association with VEXAS in up to 25% of cases.<sup>2,26</sup> The pathogenesis of such hematopathological manifestations seems multifactorial, probably being part mediated by the chronic hyperinflammation and in part by the transition to clonal hematological disease and neoplasia.<sup>9</sup>

In addition, patients with VEXAS show a high rate of thrombotic events, typically in the venous circulation.<sup>27</sup> The incidence of thromboembolism is reported to be as high as 55% in the different series with an increased likelihood for recurrence.<sup>27</sup> Thromboses are likely to be related to the chronic hypercytokinemia and resultant inflammation and endothelial dysfunction generated by the abnormal crosstalk between innate immune cells and platelets.<sup>28</sup> At present, these mechanisms are not fully elucidated, and patients are managed according to VEXAS-agnostic guidelines.<sup>29</sup> Specific attention is required in cases with concomitant lupus anticoagulant, which is present in up to half the patients and associated with recurrence of thrombotic events.<sup>2</sup>

MDS is the most frequent hematological neoplasm in VEXAS.<sup>30</sup> Current studies support transition to MDS happening with acquisition of mutations in classical myeloid genes belonging to the so-called DTA triad (*DNMT3A*, *TET2*, *ASXL1*), which are observed in the aging BM (age-related clonal hematopoiesis).<sup>31-34</sup> In this scenario, mechanisms of chronic inflammation may explain this molecular profile as in other rheumatological conditions (eg, gout) or acceleration of age-related clonal hematopoiesis/clonal hematopoiesis of indeterminate potential phenomena.<sup>35</sup> MDS associated with VEXAS display lower risk profiles according to the Revised International Prognostic Scoring System score ( $\leq 3.5$ ), normal karyotype at conventional cytogenetics analysis, and low blast counts.<sup>36,37</sup> Morphological dysplasia is typically present in 1 or more lineages as per the most common World Health Organization 2016 subtypes, MDS-multilineage dysplasia, and MDS with ring sideroblasts and unilineage dysplasia.<sup>37</sup> Other myeloid neoplasia subtypes (chronic myelomonocytic leukemia, primary myelofibrosis) have been also associated with VEXAS.<sup>16,38</sup> When present, MDS progression may negatively impact outcomes.<sup>14</sup>

In recent years, enhanced molecular genetic testing in hematological malignancies, predominantly by next-generation sequencing (NGS) technologies including *UBA1*, has led to earlier identification of patients with VEXAS. However, this requires patients to undergo testing with the appropriate NGS panel, usually a myeloid panel or a broader hemato-oncology panel, which importantly must include the *UBA1* gene. Outside of hematological testing (mainly of BM, but also of peripheral blood), this type of laboratory diagnostic investigation is unusual and other specialists are unlikely to be familiar with the process or interpretation of results. Close multidisciplinary working is essential.

### Prognostic factors

In an attempt to identify latent features linking pathobiological disease subgroups, the French VEXAS study group has recently

published the results of an unsupervised analysis on 116 patients.<sup>14</sup> The clustering identified 3 main groups: cluster 1 (47%) characterized by mild to moderate disease; cluster 2 (16%) with MDS association and higher mortality rates; and cluster 3 (37%) with constitutional manifestations, higher C-reactive protein levels, and less frequent chondritis. The identified clusters had diverse 5-year overall survival: 84% in cluster 1, 51% in cluster 2, and 90% in cluster 3. Most deaths were due to infection and MDS progression, and in this cohort the p.Met41Leu variant was associated with a better prognosis.<sup>14</sup> Similar conclusions were drawn in a recent study where the valine amino acid change and the need for transfusions were independent predictors for reduced survival, whereas the presence of ear chondritis was associated with a good prognosis.<sup>11</sup> Refractoriness to multiple lines of treatment, which is common in VEXAS, clearly contributes to morbidity and mortality. However, to date, the evidence base is heavily dependent on retrospective data analysis, with potential limitations and biases, and VEXAS intersects across multiple medical specialties and is thereby clinically managed in a highly variable fashion. To improve the putative poor prognosis of patients with VEXAS, it is important that patients benefit from early diagnosis, multidisciplinary management (pathologists, rheumatologists, hematologists, and others), sharing patients' care with coordinated clinical and laboratory follow-up.

### UBA1 TEST INDICATIONS: A GUIDE FOR THE PRACTICING CLINICIAN

As described above, VEXAS represents a challenging masquerade for the internal medicine community. The wide variety of presentations spanning from autoimmune/autoinflammatory manifestations involving skin, lungs, gastrointestinal tract, cytopenias, venous thromboembolism, and hematologic malignancies present challenges in recognition of clinical phenotypes. No clear diagnostic guidelines currently exist as to whom to candidate for *UBA1* gene testing, the clinical immune-related manifestations prompting testing, or the correct treatment algorithm. The possibility of an early diagnosis may also open therapeutic options useful in due course, such as hematopoietic stem cell transplantation (HSCT), the only curative treatment to date.<sup>39</sup>

Given the high rate overlap and variability of autoimmune and hematological features, and based on our review of the currently available literature, we have generated an evidence-based diagnostic scheme allocating VEXAS-associated characteristics into groups with different likelihood for the disease to support physicians assessing the suitability of *UBA1* testing (Table I and Fig 1).

### POTENTIAL TREATMENT OPTIONS IN PATIENTS NOT ELIGIBLE FOR HSCT

To date, the only potentially curative option for VEXAS syndrome is HSCT. Nonetheless, because of the disease demographics (late adulthood onset) and disease- and treatment-related organ dysfunctions, most patients will not be suitable candidates for allogeneic HSCT. However, most of the reports on treatment efficacy and tolerability are retrospective, including patients who were *post facto* diagnosed with VEXAS. Although various drugs have been explored, their benefit is yet to be defined in the context of VEXAS.

**TABLE I.** Features associated with VEXAS on the basis of literature review

VEXAS association	Demographics	Clinical features	Laboratory findings	BM findings (if available)
Very strong	Male sex Age >60 y	Noninfectious fever	Macrocytic anemia	MDS
		Weight loss	Elevated ESR and CRP	Vacuolization in myeloid precursors ≥10%
		Sweet syndrome–like skin lesions		
		Ground-glass pulmonary infiltrates		
		Chondritis (ear and nose)		
Strong	Age >50 y but ≤60 y	Tendinitis		
		Autoimmune symptoms with steroid dependency		
		Unprovoked venous thromboembolism	Lymphopenia	
		Chondritis (joints)	Elevated ferritin	
		Pulmonary involvement (consolidations, reticulation, pleural effusion)		
Possible	Age >40 y but ≤50 y Female sex (Turner syndrome or clonal X-skewing)	Erythematous rash		
		Transfusion dependency		
		Intestinal involvement	Thrombocytopenia	Plasma cell dyscrasias
		Ocular involvement	Monoclonal gammopathy	CMML
		Unspecified arthritis	Neutropenia	Myelofibrosis
		HLH, CIDP		
		Kidney, heart involvement		

Testing for *UBA1* mutation is warranted for patients with features very strongly associated with VEXAS or with strongly associated features if no other cause is identifiable. CIDP, Chronic idiopathic demyelinating polyneuropathy; CMML, chronic myelomonocytic leukemia; CRP, C-reactive protein; ESR, erythrocyte sedimentation rate.

### Targeting immune and inflammatory pathways

Inflammation in VEXAS is a consequence of defective protein ubiquitination generating a cascade of hyperinflammation.<sup>2</sup> GCs are the mainstay of treatment in inflammatory diseases, and the vast majority of patients with VEXAS have been and are treated with GCs as a first choice. Many reports have shown how GCs' dependency and refractoriness are common in VEXAS and how doses of more than 10 mg/d of prednisone are usually required to control symptoms.<sup>18</sup> Eventually, all patients will need additional drugs as GC-sparing agents or as further treatment, in most of the cases with short-term responses.

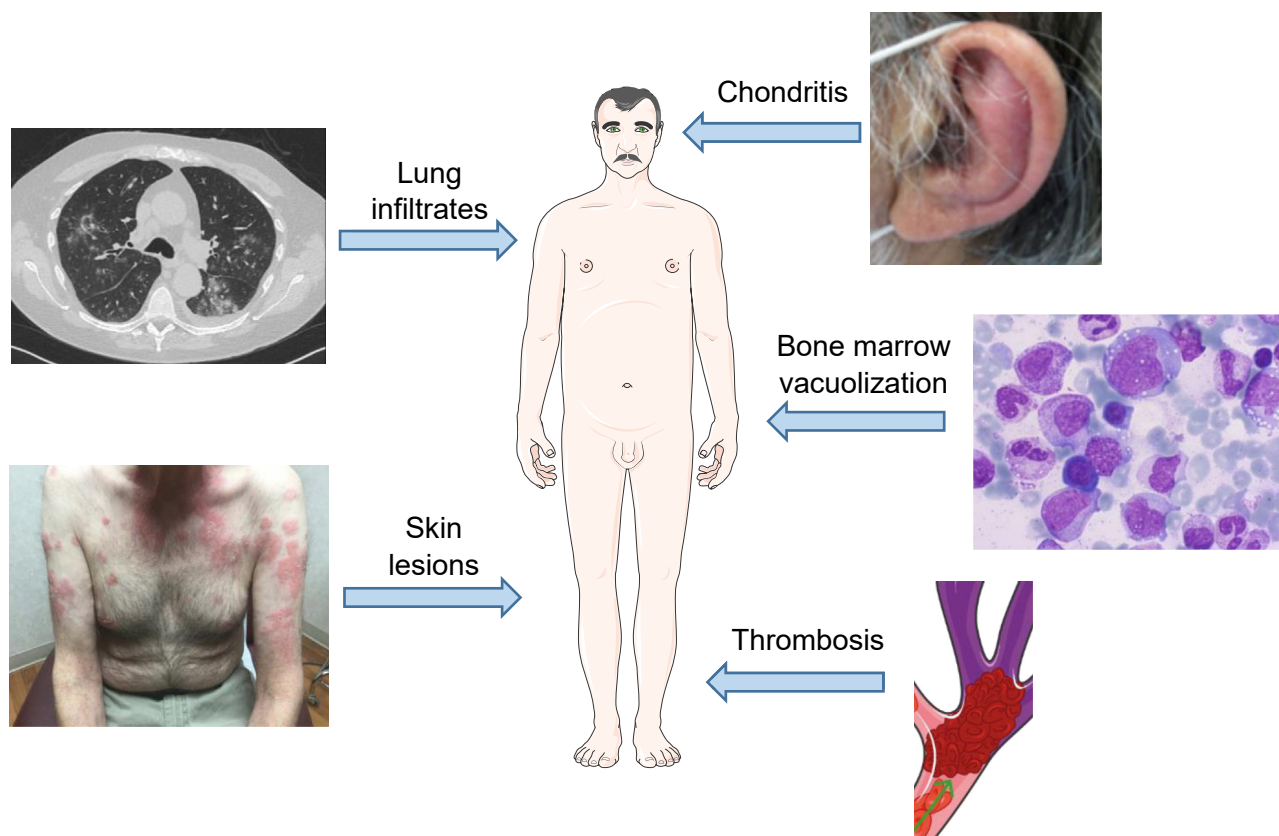
The previously cited comparison between patients with idiopathic-relapsing polychondritis and VEXAS-RP showed similar rates of GC dependency (62% vs 71%) albeit with much lower remission rate (90% vs 27%), shorter median duration of remission (24 vs 7 months), and longer median time to remission (19 vs 30 months) in patients with VEXAS.<sup>18</sup>

Small case series have reported on the efficacy of calcineurin inhibitors, other synthetic immunosuppressant (eg, methotrexate, mycophenolate, and azathioprine) or biological drugs (eg, tocilizumab, anakinra, and infliximab) in association with GCs. Patients reported so far have been treated following protocols for their initial diagnosis in a "VEXAS-agnostic" fashion, without specifically considering its inherent aggressive nature and possibly delaying the effective additional treatments. It is not currently known whether early use of combinatorial approaches with GCs may be useful in controlling clinical manifestations of VEXAS. In the original cohort by Beck et al,<sup>2</sup> the strategies used in combination with GCs were very heterogeneous, with methotrexate (76%), anti-IL-1 (52%), mycophenolate (44%), colchicine (40%), and tocilizumab (40%) as the most frequent. Notably, the vast majority of patients (80%) were treated with at least 3 therapeutic lines of different classes with generally poor responses. Another small case series by Poulter et al<sup>7</sup> showed

that among 8 patients, no one responded to methotrexate, azathioprine, cyclosporine, or mycophenolate. Analogous findings were described in a Dutch series of 12 patients diagnosed retrospectively with VEXAS who had been treated with multiple drugs, in particular anakinra (58%) and tocilizumab (50%). Most patients had at least a partial response, but with inevitable disease recurrence or intolerance that led to treatment discontinuation.<sup>13</sup> Tocilizumab was an effective treatment in 2 of 3 patients in a Japanese report on VEXAS-RP, even if follow-up was short (5-8 months), but high IL-6 blood levels did not seem to predict response.<sup>42</sup>

Janus kinase (JAK)/signal transducer and activator of transcription signaling activation is a common feature in inflammatory conditions, and also in VEXAS seems to play an important role. Therefore, JAK inhibitors have been used in VEXAS to target the downstream effects of hypercytokinemia. A recent retrospective multicenter study showed promising results for ruxolitinib, a JAK1/JAK2 inhibitor already widely used for various hematological conditions. Clinical response was obtained in 67% of 12 patients treated with ruxolitinib after 1 month, with efficacy improving over time (83% and 87% after 3 and 6 months of treatment, respectively), whereas other JAK inhibitors had inferior response rates. Median time to the next line of treatment was not reached in the ruxolitinib group, whereas it was just 3.3 months in the group treated with other JAK inhibitors. No significant predictors of ruxolitinib response were identified, and, despite the small numbers, a concomitant diagnosis of myeloid neoplasm did not seem to predict lower response rates. Moreover, probably due to reduction of inflammation, ruxolitinib improved cytopenias in responding patients.<sup>43</sup>

Although showing promising results, toxicities of immunosuppressive and biological drugs must be a special consideration in patients with VEXAS. High-dose GCs are poorly tolerated long-term, mainly due to cardiometabolic and infectious side



**FIG 1.** Main clinical and BM features of VEXAS: ear chondritis<sup>40</sup>; ground-glass pulmonary infiltrates; BM myeloid precursors vacuolization; Sweet syndrome–like skin lesions<sup>41</sup>; venous thrombosis.

effects. Tocilizumab may cause neutropenia, which may be present in VEXAS, because of incipient or overt MDS. Careful consideration needs the use of this drug in cases with gastrointestinal manifestation because rare perforation associated with tocilizumab has been reported.<sup>13</sup> Anakinra use in VEXAS has been instead associated with severe skin reaction at the injection site, for which the mechanism is unknown, but often leading to discontinuation.<sup>2,44</sup>

### Targeting the *UBA1*-mutant clone

Azacitidine (AZA) is a hypomethylating agent with a well-known efficacy in various hematologic malignancies, including MDS.<sup>45</sup> Several small case series reported on patients treated with AZA in the context of VEXAS-associated MDS. Data from the French VEXAS Registry showed 45% of 11 patients clinically responding to AZA, with best response observed between 4 and 6 treatment cycles. Three patients had erythroid response and 2 had platelet response according to IWG 2006 criteria.<sup>37</sup> Bourbon et al<sup>46</sup> reported on 4 patients with VEXAS-related MDS with a median time to the next treatment of 21.9 months for AZA, which was superior to both immunosuppressive and biological anticytokine drugs but inferior to ruxolitinib. Raaijmakers et al<sup>47</sup> presented 3 patients with VEXAS refractory to multiple lines eventually treated with AZA, all fulfilling the WHO 2016 diagnostic criteria for MDS at some point during their disease course. Two patients achieved a good clinical response, which lasted even after AZA withdrawal and allowed tapering of GCs. Of note is that

both patients responding to AZA had co-occurring *DNMT3A* mutations with high variant allele frequency, which decreased over time.<sup>47</sup> Even in non-VEXAS-associated MDS, it is still unclear whether and how *DNMT3A* mutational status influences response to AZA (besides R882 hotspot mutation<sup>48</sup>), and thus further data are necessary.<sup>48,49</sup> In a prospective phase II French trial of AZA in autoimmune/inflammatory disorders associated with MDS/chronic myelomonocytic leukemia, *UBA1* mutational status was retrospectively assessed. No differences were found in inflammatory symptoms or hematological response between *UBA1*-mutant and wild-type patients. In the VEXAS cases ( $n = 12$ ), 75% of patients had a significant reduction in symptoms after 6 cycles of treatment, which allowed steroid tapering. Hematological response was achieved in 59% of patients overall.<sup>36</sup>

The best treatment for patients with VEXAS not eligible for HSCT is yet to be defined, even by consensus. When inflammation is the main disease feature, high-dose GCs can achieve transient clinical responses, but severe toxicities limit their long-term use. Clinical relapse is typical during tapering of GCs. For the present, there is insufficient evidence to support the use of a specific immunosuppressive or biological drug as a GC-sparing agent either alone or in combinatorial strategies, even though most patients seem to respond temporarily to tocilizumab and anti-IL-1 drugs. Ruxolitinib is promising in quickly inducing a durable response that often allows tapering of GCs, but studies on larger cohorts for prolonged follow-up periods are warranted. In general, we suggest choosing among the available drugs according to the specific toxicity profile and patient's clinical picture and

needs (ie, avoiding tocilizumab in neutropenic patients, choosing early combination therapy in patients with cardiometabolic comorbidities to reduce GC dose, etc). Subcutaneous administration of anakinra should be avoided because of the risk of skin reaction. In patients with concomitant MDS or with cytopenias as the main disease feature, treatment with ruxolitinib or with agents targeting the *UBAI*-mutant clone such as AZA should be considered as a first choice.

### Supportive measures

Macrocytic anemia is common even in early stages of VEXAS. Transfusion threshold should be set on a case-by-case scenario, taking into consideration individual patients' symptoms and comorbidities. Iron chelation should be started as the transfusions burden increases and according to markers of iron overload to avoid organ damage.<sup>50</sup> Neutropenia and thrombocytopenia are late events, usually associated with progression to MDS or other myeloid neoplasms.<sup>51</sup> Currently there is no evidence to support the use of G-CSF and thrombopoietin mimetics in VEXAS-related cytopenias, while erythropoietin may be administered in the setting of anemia in low-risk MDS, although responses are often mediocre.<sup>50</sup>

Venous thromboembolism in VEXAS tends to recur even during anticoagulation treatment. Controlling inflammation is an important consideration to reduce venous thromboembolism risk.<sup>52</sup> All patients should be given thromboprophylaxis in high-risk situations (ie, prolonged hospitalization, reduced mobility), and individual modifiable risk factors for thrombosis should be kept under strict control. Whether to continue anticoagulation indefinitely or not should be individualized and judiciously evaluated alongside disease activity and in a tailored fashion.

Infectious complications are very common in patients with VEXAS due to the disease-associated immune-dysregulation, cytopenias, and immunosuppressive treatment. Differential diagnosis between VEXAS inflammatory flares and infections may be challenging (ie, in case of pulmonary infiltrates). Opportunistic infections are reported.<sup>44</sup> We suggest considering *Pneumocystis jirovecii* and Varicella-Zoster virus prophylaxis in every patient with VEXAS undergoing long-term GC treatment and/or immunosuppression. Other antibacterial and antifungal prophylaxis may be considered in patients with absolute neutropenia.<sup>53</sup>

### ALLOGENEIC HSCT IN VEXAS

Allogeneic HSCT is the only potentially curative treatment option for VEXAS. However, patients are often elderly, ineligible for the procedure from the point of diagnosis, or subsequently deteriorate to a point whereby they lose their fitness for HSCT. In the field of HSCT, new strategies are constantly evolving to reduce transplant-related mortality and toxicities and improve outcomes. Indeed, the refinement of HSCT platforms in the last decade enabled a higher fraction of frail patients to proceed to the procedure. However, given the heterogeneous clinical features of VEXAS, disease progression, and associated hematologic malignancies, the consideration of HSCT requires careful clinical acumen as to whom to candidate, timing, and optimal transplant strategies.<sup>39</sup>

Prospective studies are ongoing to assess HSCT effectiveness and safety in VEXAS both in the United States (NCT05027945) and in Europe by the Chronic Malignancies and Autoimmune

Disease working parties of the European Society for Blood and Marrow Transplantation.

### Summary of results for HSCT in autoimmune diseases and VEXAS

To date, several reports have shown the feasibility and efficacy of HSCT in autoimmune diseases (ADs). A recent European Society for Blood and Marrow Transplantation retrospective study showed a 67% complete remission rate in 64 patients with various AD diagnoses. Because the study was performed before VEXAS definition, patients' *UBAI* mutational status is unknown. However, genetic alterations were reported in some patients, suggesting that genetic background is currently underestimated in autoinflammatory/autoimmune diseases. Younger age, male sex, and transplantation received after 2009 were found to be significant predictors of better outcome.<sup>54</sup> Another Canadian study showed promising results in particular for Crohn disease (no relapse reported among 10 patients at 1-year follow-up after immunosuppression discontinuation), rheumatoid arthritis (2 relapses among 7 patients), and Behçet disease (no relapses among 3 patients). Other ADs included lupus and psoriasis, albeit with less impressive results. Interestingly, no association was found between AD relapse and reduced-intensity conditioning (RIC), use of anti-thymocyte globulin (ATG) in graft-versus-host disease (GvHD) prophylaxis, and persistence of mixed chimerism.<sup>55</sup>

Only small case reports and series of HSCT in VEXAS are available.<sup>38,56-58</sup> In a French series of 6 patients, 4 cases were transplanted for severe and refractory autoinflammatory manifestations, while 2 for concomitant hematologic neoplasms. Patients were relatively young, with only 1 older than 60 years. In all of them, VEXAS diagnosis was retrospective. Results were generally satisfactory, with 5 patients in complete remission after HSCT and 1 patient dying of transplant-related mortality (pneumonia).<sup>38</sup> An additional 4 patients have been reported in a UK experience. Three were diagnosed with VEXAS before HSCT, whereas in 1 case the diagnosis was retrospective and HSCT was performed because of a concomitant MDS. Patients underwent fludarabine-based RIC, with various donors. Outcomes were diverse, with 1 patient alive in remission, 1 patient alive but with severe quality-of-life reduction due to GvHD, and 2 patients dead.<sup>56</sup> Van Leeuwen-Kerkhoff et al<sup>57</sup> reported a case of a patient with severe steroid-dependent VEXAS and no associated MDS who underwent upfront TCR $\alpha\beta$ <sup>+</sup> and CD19<sup>+</sup> cell-depleted HSCT from an unrelated HLA-mismatched donor. Conditioning was myeloablative and included ATG, with mycophenolate and prednisolone as GvHD prophylaxis. Immunosuppression was tapered and then discontinued at 3.5 months from HSCT and no need for more treatment was reported at 9-month follow-up.<sup>57</sup> Recently, a first prospective case series of 5 patients was published. Indications for HSCT were severe and refractory inflammation, persistent cytopenias with transfusion dependency, and/or concomitant myeloid malignancy. An RIC approach with fludarabine and melphalan was used in all cases. All patients were alive in remission at various follow-up timings with no grade II to IV acute or chronic GvHD reported but with some cases showing infections, persistent cytopenias, and mixed chimerism.<sup>58</sup> Loschi et al<sup>59</sup> reported the case of a patient who underwent HSCT after a bridging treatment with ruxolitinib, with first evidence of clearance of *UBAI*-mutated clone posttransplant<sup>59</sup> (Table II).

**TABLE II.** Characteristics of patients with VEXAS who have undergone HSCT so far reported

Study	Age at HSCT (y)	Clinical features	Concomitant hematologic malignancy	Donor	Conditioning	GvHD prophylaxis	Complications	Outcome
Diarra et al <sup>58</sup>	46	Neutrophilic dermatosis, polyarteritis nodosa	Yes (MDS)	MUD 10/10	Fludarabine, busulfan, ATG	CSA, MMF	Chronic cutaneous GvHD, hepatic GvHD	CR at 32-mo FUP
	59	Neutrophilic dermatosis	Yes (myelofibrosis)	Related donor	Fludarabine, busulfan	CSA, MTX	Chronic cutaneous GvHD	CR at 67-mo FUP
	65	Neutrophilic dermatosis, polyarteritis nodosa, chondritis	Yes (MDS)	MUD 10/10	Fludarabine, busulfan	CSA, MTX, PT-Cy	<i>Escherichia coli</i> bacteremia, BK virus-related hemorrhagic cystitis, CMV replication, acute cutaneous GvHD grade I	CR at 38-mo FUP
	50	Neutrophilic dermatosis, chondritis, pulmonary involvement, deep vein thrombosis	Yes (MDS)	MUD 10/10	Fludarabine, busulfan, ATG	CSA, MTX	Bacterial catheter-related infection	CR at 3-mo FUP
	58	Chondritis, pulmonary involvement	Yes (MDS)	Related donor	Fludarabine, busulfan, thiotepa	CSA, MMF, PT-Cy	Bacterial catheter-related infection, acute gastrointestinal GvHD grade II, cutaneous GvHD grade I	CR at 5-mo FUP
	55	Chondritis	Yes (MDS, myelofibrosis)	MUD 10/10	Busulfan, cyclophosphamide, ATG	CSA, MTX	Bacterial catheter-related infection, fusariosis, acute gastrointestinal GvHD grade III	Death before evaluation (infection)
Al-Hakim et al <sup>56</sup>	51	Fever, weight loss, skin involvement, pulmonary involvement	Yes (MDS)	Haplo (son)	Fludarabine, busulfan, thiotepa	PT-Cy, tacrolimus, MMF	<i>Salmonella houtenae</i> in blood cultures, pseudomonas in sputum	Death at 11 d (infection)
	67	Fever, weight loss, skin involvement, pulmonary embolus	No	MUD	Fludarabine, melphalan, alemtuzumab	CSA	EBV reactivation, HLH, aseptic encephalitis, GvHD	Alive with Karnofsky 40% at 5-mo FUP
	61	Fever, weight loss, skin involvement, pulmonary involvement, tubular interstitial nephritis	No	Sibling	Fludarabine, treosulfan, alemtuzumab	CSA, MMF	Bacterial infection, <i>C difficile</i> , SARS-CoV-2, metabolic acidosis peritransplantation, myelitis and optic neuropathy	Death at 11 mo (infection)
	62	Fever, skin involvement, chondritis	Yes (MDS)	MUD	Fludarabine, busulfan, ATG	CSA	Grade 1 GvHD	CR at 40-mo FUP
Van Leeuwen-Kerkhoff et al <sup>57</sup>	51	Fever, weight loss, skin involvement, sinusitis, chondritis	No	MUD 9/10	Fludarabine, melphalan, thiotepa, ATG	Prednisone, MMF, depletion of TCR $\alpha\beta$ <sup>+</sup> and CD19 <sup>+</sup> cells	Viral enteritis, cytomegalovirus colitis	CR at 9-mo FUP
Mangaonkar et al <sup>58</sup>	63	Transfusion-dependent anemia, polychondritis	No	MUD	Fludarabine, melphalan	PT-Cy, tacrolimus, MMF	Bacteremia, encephalopathy / steroid withdrawal	CR at 16-mo FUP

(Continued)



TABLE II. (Continued)

Study	Age at HSCT (y)	Clinical features	Concomitant hematologic malignancy	Donor	Conditioning	GvHD prophylaxis	Complications	Outcome
	60	Refractory inflammation including vasculitis	No	Sibling	Fludarabine, melphalan	PT-Cy, tacrolimus, MMF	Drug-induced rash	CR at 13-mo FUP
	59	Refractory inflammation including polyarthritis	No	Sibling	Fludarabine, melphalan	Tacrolimus, MTX	Delayed count recovery, lactic acidosis peritransplantation	CR at 4-mo FUP
	74	Refractory inflammation	No	MUD	Fludarabine, melphalan	PT-Cy, tacrolimus, MMF	<i>C difficile</i> diarrhea, <i>E coli</i> infection, grade I acute skin GvHD	CR at 3-mo FUP
	49	Relapsing polychondritis	Yes (MDS)	MUD	Fludarabine, melphalan	PT-Cy, tacrolimus, MMF	Skin hypersensitivity reaction	CR at 9.5-mo FUP
Loschi et al <sup>59</sup>	70	Skin lesion, polychondritis, arthritis	Yes (MDS)	MUD	Fludarabine, busulfan	PT-Cy, CSA, MMF	Acute GvHD	CR at 4-mo FUP

ATG, Anti-thymocyte globulin; CMV, cytomegalovirus; CR, complete response; CSA, cyclosporine; FUP, follow-up; GvHD, graft-versus-host disease; MMF, mycophenolate; MTX, methotrexate; MUD, matched unrelated donor; PT-Cy, posttransplantation cyclophosphamide; SARS-CoV-2, severe acute respiratory syndrome coronavirus 2.

### Eligibility and indications

The definition of fitness for HSCT has enormously changed in the last decades. The only consideration of chronological age *per se* has been replaced by comprehensive geriatric and comorbidities evaluations, using tools such as instrumental activities of daily living<sup>60</sup> and HCT-CL.<sup>61</sup> During the last decade considerable clinical progress has been achieved, with less aggressive conditioning regimens, improved patient selection, better supportive care, and advances in GvHD prophylaxis, adapted to deliver personalized care for the elderly patient.<sup>62</sup>

Eligibility for HSCT should be determined by a complete assessment of the patient's comorbidities, organ function, infectious risk, personal motivation, and social support. In VEXAS, because of the common onset in late adulthood, disease-related organ damage (eg, lung infiltrates and thrombosis), and treatment side effects (eg, diabetes and infections), it is uncommon to find a candidate of ideal fitness. The decision to proceed to HSCT should be thereby taken not only by HSCT specialists but also by a multidisciplinary and experienced team, to properly assess HSCT risks and complications in more frail patients.

We believe that HSCT should be offered to all eligible patients with VEXAS and a concomitant diagnosis of hematologic malignancy, because of reported higher mortality rates.<sup>14</sup> For patients with VEXAS without a full diagnosis of hematological malignancy, the decision must be taken in a tailored fashion, taking into consideration the genomics (eg, p.Met41Val genotype), disease severity (eg, transfusion burden), relapse rate, and treatment response. It should be considered that disease and therapy-related complications may delay or prevent the feasibility of HSCT at a later stage, and that indolent disease evolution is uncommon but possible.

Currently it is unknown whether *UBA1*-mutation type, allele burden, or clinical and/or molecular remission impacts on HSCT outcome. Nevertheless, a bridging strategy to control symptoms and reduce pretransplantation complications seems reasonable. In this respect, ruxolitinib, because of its rapid effect, may be especially useful in patients with AD phenotypes, whereas AZA may be a good choice in patients with associated MDS.

Given these considerations, the search for a suitable hematopoietic stem cell donor should be started at the time of VEXAS diagnosis for every patient in which HSCT is not clearly contraindicated. Donor choice should follow the usual practice. The choice for the preferred hematopoietic stem cell source is still a matter of debate, depending also on multiple factors related to the patient and transplant characteristics. However, higher risk of chronic GvHD has been reported in peripheral blood-based approaches with elevated CD3<sup>+</sup> cell graft content.<sup>63</sup>

### Conditioning regimens and GvHD prophylaxis strategies

The choice of conditioning regimen in elderly/frail patients can be challenging. RIC and reduced-toxicity conditioning (RTC) regimens, which are mostly based on fludarabine associated with an alkylating agent at a reduced dose or total body irradiation, showed comparable efficacy with myeloablative conditioning in various settings, with better morbidity and toxicity profiles.<sup>64,65</sup> The role of nonmyeloablative conditioning in a disease with uncertain malignant potential such as VEXAS without MDS should be a matter of investigation, especially due to previously analyzed reports that seem not to correlate conditioning intensity with risk of relapse in ADs.<sup>53</sup> Treosulfan is an alkylating agent shown to improve overall survival rates in older patients with MDS and acute myeloid leukemia when compared with busulfan-based RIC, with an overall milder toxicity profile,<sup>66</sup> especially desirable in elderly patients.

GvHD prophylaxis is often based on the single-institution experience, but in most of the cases includes either posttransplantation cyclophosphamide and/or ATG. The use of one strategy versus the other does not seem to impact on relapse risk after HSCT.<sup>53</sup> The current US National Institutes of Health phase II trial uses posttransplantation cyclophosphamide with sirolimus and mycophenolate as GvHD prophylaxis.

A potentially useful platform that may be considered in VEXAS was originally developed for nonmalignant diseases,

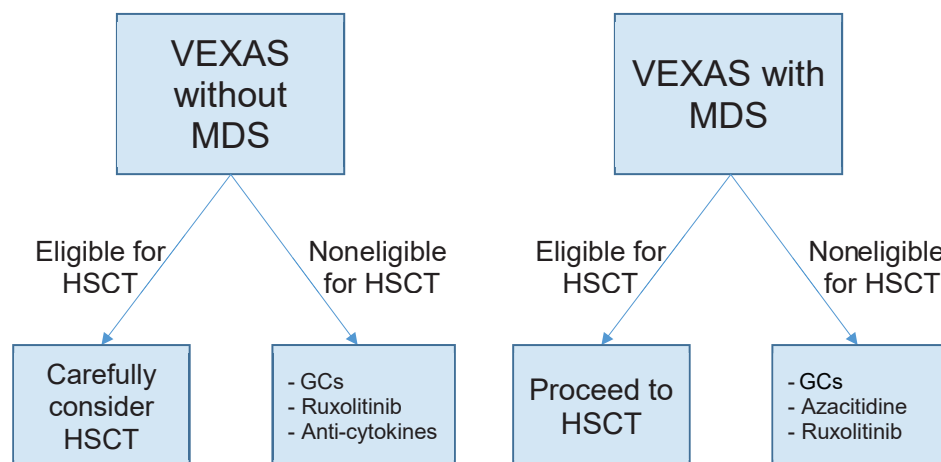


FIG 2. Treatment algorithm we propose for VEXAS according to current evidence.

such as thalassemia and severe aplastic anemia, at the Johns Hopkins University in Baltimore. It consists of nonmyeloablative conditioning and intensive GvHD prophylaxis with both post-transplantation cyclophosphamide and ATG and produced outstanding results (95% overall survival and 84% GvHD-free survival with haploidentical donors).<sup>67</sup> The successful HSCT of a VEXAS case from an HLA-mismatched unrelated donor with depletion of TCR $\alpha\beta^+$  and CD19 $^+$  cells and mycophenolate and prednisone as GvHD prophylaxis also opens other possibilities.<sup>57</sup>

### Disease-specific complications

Graft failure (GF) is defined as the failure to achieve hematological recovery at day +28 from HSCT in the absence of donor chimerism. HSCT in nonmalignant diseases, mainly due to lack of exposure to previous treatments, is at increased risk for GF. The use of RIC regimens and nonrelated donors further increases this risk. In the previously cited Johns Hopkins University platform, conditioning intensity for treatment-naïve patients with severe aplastic anemia had indeed to be escalated to reduce GF risk.<sup>67</sup> In the setting of VEXAS, especially for patients with uncontrollable disease, GF risk must be judiciously evaluated in a patient-by-patient fashion and balanced against the use of more intensive conditioning regimens.

VEXAS association with EBV-related HLH has already been discussed.<sup>21</sup> Incidence of HLH after HSCT<sup>68</sup> was reported to be up to 4.3%, with a mortality rate of 85.5%.<sup>69</sup> Close monitoring of patients with VEXAS undergoing HSCT for signs and symptoms of HLH (noninfectious fever, high ferritin blood levels, etc) is recommended, alongside EBV-DNA viral load, especially during periengraftment time so that treatment measures can be instituted without delay.

### CONCLUSIONS AND FUTURE PERSPECTIVES

Although the association between autoimmunity and myeloid malignancies is long recognized, VEXAS provides a genomic paradigm linking these areas and a basis for “cross-fertilization” of treatment approaches between specialties. Given the heterogeneity of clinical manifestations, with overlap of clinical and/or biological features of autoinflammation and hematological malignancies, VEXAS can be considered in the list of clinical

“masqueraders.” Close collaboration between transplant hematologists and relevant disease specialists in diagnosis, clinical management, and follow-up is essential.

The clinicobiological and genetic description of the VEXAS syndrome has been progressively refined on the basis of evolving literature. Molecular diagnosis is made by the confirmation of the *UBA1* gene. The discovery of VEXAS syndrome clearly illustrates the power of molecular diagnostics, including NGS panels, to identify the role of mutations in somatic diseases, which is arguably underestimated in autoinflammatory/autoimmune diseases at present. The suspicion of typical autoimmune manifestations should prompt an evaluation of underlying myeloid malignancies and assessment of somatic *UBA1* mutation according to broader hemato-oncology NGS panels and other sequencing technologies. For this reason, wide availability of *UBA1* and genetic testing and close collaboration of rheumatologists, hematologists, and other specialists, through multidisciplinary teams, are necessary to optimize the early diagnosis and subsequent management of VEXAS. On the basis of currently available evidence, sourced from PubMed searches of original observations and key reviews, coupled with expert opinion from international multidisciplinary team, we developed specific recommendations to early identify patients with features of VEXAS, such as described in Table I, which may further improve the connection between general practitioners or rheumatologists and hematologists.

Raising clinical awareness is of paramount importance for prompt diagnosis and institution of appropriate treatment. While waiting for prospective trials to report, treatments may range from conservative therapeutics (ruxolitinib, AZA) alone or, in carefully selected patients, as a bridge to HSCT. Although the evidence base for treatment recommendations is currently very limited, we have proposed a potential VEXAS treatment algorithm proposal in Fig 2.

Although data are still limited in HSCT, a proactive multidisciplinary treatment approach for all patients, including those who are elderly and frail, should be commenced from diagnosis, especially as risk of disease progression and treatment side effects may preclude further therapy if a “sequential” approach is followed. In cases with high disease burden and/or refractory symptoms and concomitant MDS, sequential conditioning strategies such as fludarabine-amsacrine-reduced intensity conditioning

(FLAMSA-RIC) may be also useful to quickly turn off the autoimmunity/autoinflammatory symptoms and proceed to HSCT even without achieving a full pretransplant disease control.<sup>70</sup> Challenges will inevitably arise from patients who present with uncontrollable and refractory autoimmune features, in whom individualized approaches are required to stabilize their condition before HSCT. Personalized conditioning regimens possibly adopting RIC or RTC strategies should be considered, although heterogeneity and small numbers in literature preclude the identification of a clear recommendation. We therefore believe that RIC and RTC approaches are necessary to make HSCT feasible in less fit patients, reducing the risk of transplant-related mortality in a setting with potentially low risk of malignant evolution, in which currently there is no evidence that an “anticlonal” immunologic effect is required to cure the disease. Clinical acumen with early recognition of highly suspicious cases, prompt diagnosis, and the establishment of a treatment program with a multidisciplinary team are key elements for a successful therapeutic strategy to minimize morbidity and mortality.

The development of international registries for rare diseases such as VEXAS is crucial to have more reliable data that may be helpful to better elucidate the disease’s pathophysiological mechanism and analyze treatment responses in large cohorts of patients, as well as providing a basis for prospective studies and consensus guidelines.<sup>71</sup>

## REFERENCES

- Hasserjian RP. This year’s best in hematology diagnosis: a new disease is discovered. *Hematologist* 2022;19.
- Beck DB, Ferrada MA, Sikora KA, Ombrello AK, Collins JC, Pei W, et al. Somatic mutations in UBA1 and severe adult-onset autoinflammatory disease. *N Engl J Med* 2020;383:2628-38.
- Barba T, Jamilloux Y, Durel CA, Bourbon E, Mestrallet F, Sujobert P, et al. VEXAS syndrome in a woman. *Rheumatology (Oxford)* 2021;60:E402-3.
- Tsuchida N, Kunishita Y, Uchiyama Y, Kirino Y, Enaka M, Yamaguchi Y, et al. Pathogenic UBA1 variants associated with VEXAS syndrome in Japanese patients with relapsing polyarthralgia. *Ann Rheum Dis* 2021;80:1057-61.
- Diarra A, Duployez N, Terriou L. Mutant UBA1 and severe adult-onset autoinflammatory disease. *N Engl J Med* 2021;384:2163-4.
- Stubbins RJ, McGinnis E, Johal B, Chen LYC, Wilson L, Cardona DO, et al. VEXAS syndrome in a female patient with constitutional 45,X (Turner syndrome). *Haematologica* 2022;107:1011-3.
- Poulter JA, Collins JC, Cargo C, de Tute RM, Evans P, Ospina Cardona D, et al. Novel somatic mutations in UBA1 as a cause of VEXAS syndrome. *Blood* 2021;137:3676-81.
- Poulter JA, Savic S. Genetics of somatic auto-inflammatory disorders. *Semin Hematol* 2021;58:212-7.
- Grayson PC, Patel BA, Young NS. VEXAS syndrome. *Blood* 2021;137:3591-4.
- Oganesyan A, Jachiet V, Chasset F, Hirsch P, Hage-Sleiman M, Fabiani B, et al. VEXAS syndrome: still expanding the clinical phenotype. *Rheumatology (Oxford)* 2021;60:E321-3.
- Ferrada MA, Savic S, Cardona DO, Collins JC, Alessi H, Gutierrez-Rodriguez F, et al. Translation of cytoplasmic UBA1 contributes to VEXAS syndrome pathogenesis. *Blood* 2022;140:1496-506.
- Sikora KA, Wells KV, Bolek EC, Jones AI, Grayson PC. Somatic mutations in rheumatological diseases: VEXAS syndrome and beyond. *Rheumatology (Oxford)* 2022;61:3149-60.
- van der Made CI, Potjewijd J, Hoogstins A, Willems HPJ, Kwakernaak AJ, de Sevaux RGL, et al. Adult-onset autoinflammation caused by somatic mutations in UBA1: a Dutch case series of patients with VEXAS. *J Allergy Clin Immunol* 2022;149:432-9.e4.
- Georgin-Lavialle S, Terrier B, Guedon AF, Heiblig M, Comont T, Lazaro E, et al. Further characterization of clinical and laboratory features in VEXAS syndrome: large-scale analysis of a multicentre case series of 116 French patients. *Br J Dermatol* 2022;186:564-74.
- Lacombe V, Beucher A, Urbanski G, le Corre Y, Cottin L, Croué A, et al. Distinction between clonal and paraclonal cutaneous involvements in VEXAS syndrome. *Exp Hematol Oncol* 2022;11:6.
- Gurnari C, Mannion P, Pandit I, Pagliuca S, Voso MT, Maciejewski JP, et al. UBA1 screening in Sweet syndrome with hematological neoplasms reveals a novel association between VEXAS and chronic myelomonocytic leukemia. *Hemisphere* 2022;6:e775.
- Borie R, Debray MP, Guedon AF, Mekinian A, Terriou L, Lacombe V, et al. Pleuropulmonary manifestations of VEXAS syndrome [published online ahead of print October 20, 2022]. *Chest*. <https://doi.org/10.1016/j.chest.2022.10.011>.
- Khitri MY, Guedon AF, Georgin-Lavialle S, Terrier B, Saadoun D, Segulier J, et al. Comparison between idiopathic and VEXAS-relapsing polyarthralgia: analysis of a French case series of 95 patients. *RMD Open* 2022;8:e002255.
- Lucchino B, Finucci A, Ghellere F, Bortolotti ME, Tedesco A, Lombardi S. Influence of HLA polymorphisms on clinical features of VEXAS syndrome: a potential epistatic mechanism. *Rheumatology (Oxford)* 2022;62:e7-8.
- Bert-Marcz C, Briantais A, Faucher B, Corazza G, Ebbo M, Attarian S, et al. Expanding the spectrum of VEXAS syndrome: association with acute-onset CIDP. *J Neurol Neurosurg Psychiatry* 2022;93:797-8.
- Kao RL, Jacobsen AA, Billington CJ, Yohe SL, Beckman AK, Vercellotti GM, et al. A case of VEXAS syndrome associated with EBV-associated hemophagocytic lymphohistiocytosis. *Blood Cells Mol Dis* 2022;93:102636.
- Gurnari C, Pagliuca S, Durkin L, Terkawi L, Awada H, Kongkiatkamon S, et al. Vacuolization of hematopoietic precursors: an enigma with multiple etiologies. *Blood* 2021;137:3685-9.
- Lacombe V, Prevost M, Bouvier A, Thépot S, Chabrun F, Kosmider O, et al. Vacuoles in neutrophil precursors in VEXAS syndrome: diagnostic performances and threshold. *Br J Haematol* 2021;195:286-9.
- Gurnari C, Rogers HJ. Copper deficiency. *N Engl J Med* 2021;385:640.
- Patel N, Dulau-Florea A, Calvo KR. Characteristic bone marrow findings in patients with UBA1 somatic mutations and VEXAS syndrome. *Semin Hematol* 2021;58:204-11.
- Ombrello AK, Patel BA, Wang W, Trick M, Ombrello AK, et al. Benign and malignant hematologic manifestations in patients with VEXAS syndrome due to somatic mutations in UBA1. *Blood Adv* 2021;5:3203-15.
- Groarke EM, Dulau-Florea AE, Kanthi Y. Thrombotic manifestations of VEXAS syndrome. *Semin Hematol* 2021;58:230-8.
- Patel BA, Ferrada MA, Grayson PC, Beck DB. VEXAS syndrome: an inflammatory and hematologic disease. *Semin Hematol* 2021;58:201-3.
- Heiblig M, Patel BA, Groarke EM, Bourbon E, Sujobert P. Toward a pathophysiology inspired treatment of VEXAS syndrome. *Semin Hematol* 2021;58:239-46.
- Templé M, Kosmider O. VEXAS syndrome: a novelty in MDS landscape. *Diagnosics (Basel)* 2022;12:1590.
- Voso MT, Gurnari C. Have we reached a molecular era in myelodysplastic syndromes? *Hematology* 2021;2021:418-27.
- Lötscher F, Seitz L, Simeunovic H, Sarbu AC, Porret NA, Feldmeyer L, et al. Case report: genetic double strike: VEXAS and TET2-positive myelodysplastic syndrome in a patient with long-standing refractory autoinflammatory disease. *Front Immunol* 2022;12:800149.
- Kusne Y, Fernandez J, Patnaik MM. Clonal hematopoiesis and VEXAS syndrome: survival of the fittest clones? *Semin Hematol* 2021;58:226-9.
- Hochman MJ, DeZern AE. Myelodysplastic syndrome and autoimmunity disorders: two sides of the same coin? *Lancet Haematol* 2022;9:e523-34.
- Agrawal M, Niroula A, Cunin P, McConkey M, Shkolnik V, Kim PG, et al. TET2-mutant clonal hematopoiesis and risk of gout. *Blood* 2022;140:1094-103.
- Mekinian A, Zhao LP, Chevret S, Desseaux K, Pascal L, Comont T, et al. A phase II prospective trial of azacitidine in steroid-dependent or refractory systemic autoimmune/inflammatory disorders and VEXAS syndrome associated with MDS and CMML. *Leukemia* 2022;36:2739-42.
- Comont T, Heiblig M, Rivière E, Terriou L, Rossignol J, Bouscary D, et al. Azacitidine for patients with Vacuoles, E1 Enzyme, X-linked, Autoinflammatory, Somatic syndrome (VEXAS) and myelodysplastic syndrome: data from the French VEXAS registry. *Br J Haematol* 2022;196:969-74.
- Diarra A, Duployez N, Fournier E, Preudhomme C, Coiteux V, Magro L, et al. Successful allogeneic hematopoietic stem cell transplantation in patients with VEXAS syndrome: a 2-center experience. *Blood Adv* 2022;6:998-1003.
- Gurnari C, McLornan DP. Update on VEXAS and role of allogeneic bone marrow transplant: considerations on behalf of the Chronic Malignancies Working Party of the EBMT. *Bone Marrow Transplant* 2022;57:1642-8.
- Matsumoto H, Fujita Y, Fukatsu M, Ikezoe T, Yokose K, Asano T, et al. Case report: coexistence of multiple myeloma and auricular chondritis in VEXAS syndrome. *Front Immunol* 2022;13:897722.
- Alhomida F, Beck DB, George TI, Shaffer A, Lebiecz-Odrobina D, Kovacsovic T, et al. Vacuoles, E1 enzyme, X-linked, autoinflammatory, somatic (VEXAS) syndrome—clinical presentation of a newly described somatic, autoinflammatory syndrome. *JAAD Case Rep* 2021;14:111.

42. Kirino Y, Takase-Minegishi K, Tsuchida N, Hirahara L, Kunishita Y, Yoshimi R, et al. Tocilizumab in VEXAS relapsing polyorchondritis: a single-center pilot study in Japan. *Ann Rheum Dis* 2021;80:1501-2.
43. Heiblig M, Ferrada MA, Koster MT, Barba T, Gerfaud-Valentin M, Mékinian A, et al. Ruxolitinib is more effective than other JAK inhibitors to treat VEXAS syndrome: a retrospective multicenter study. *Blood* 2022;140:927-31.
44. Staels F, Betrains A, Woei-A-Jin S, Boeckx N, Beckers M, Bervoets A, et al. Case report: VEXAS syndrome: from mild symptoms to life-threatening macrophage activation syndrome. *Front Immunol* 2021;12:678927.
45. Fenaux P, Platzbecker U, Ades L. How we manage adults with myelodysplastic syndrome. *Br J Haematol* 2020;189:1016-27.
46. Bourbon E, Heiblig M, Gerfaud Valentin M, Barba T, Durel CA, Lega JC, et al. Therapeutic options in VEXAS syndrome: insights from a retrospective series. *Blood* 2021;137:3682-4.
47. Raaijmakers MHGP, Hermans M, Aalbers A, Rijken M, Dalm VASH, van Daele P, et al. Azacitidine treatment for VEXAS syndrome. *Hemisphere* 2021;5:e661.
48. Falconi G, Fabiani E, Picciocchi A, Crisculo M, Fianchi L, Lindfors Rossi EL, et al. Somatic mutations as markers of outcome after azacitidine and allogeneic stem cell transplantation in higher-risk myelodysplastic syndromes. *Leukemia* 2019;33:785-90.
49. Scheller M, Ludwig AK, Göllner S, Rohde C, Krämer S, Stäble S, et al. Hotspot DNMT3A mutations in clonal hematopoiesis and acute myeloid leukemia sensitize cells to azacitidine via viral mimicry response. *Nat Cancer* 2021;2:527-44.
50. Fenaux P, Haase D, Santini V, Sanz GF, Platzbecker U, Mey U. Myelodysplastic syndromes: ESMO Clinical Practice Guidelines for diagnosis, treatment and follow-up†☆. *Ann Oncol* 2021;32:142-56.
51. Obiorah IE, Beck DB, Wang W, Ombrello A, Ferrada MA, Wu Z, et al. Myelodysplasia and bone marrow manifestations of somatic UBA1 mutated autoinflammatory disease. *Blood* 2020;136:20-1.
52. Oo TM, Koay J TJ, Lee SF, Lee SMS, Lim XR, Fan BE. Thrombosis in VEXAS syndrome. *J Thromb Thrombolysis* 2022;53:965-70.
53. Teh BW, Yeoh DK, Haeusler GM, Yannakou CK, Fleming S, Lindsay J, et al. Consensus guidelines for antifungal prophylaxis in haematological malignancy and haemopoietic stem cell transplantation, 2021. *Intern Med J* 2021;51:67-88.
54. Greco R, Labopin M, Badoglio M, Veys P, Silva JMF, Abinun M, et al. Allogeneic HSCT for autoimmune diseases: a retrospective study from the EBMT ADWP, IEWP, and PDWP Working Parties. *Front Immunol* 2019;10:1570.
55. Shifa I, Hazlewood GS, Durand C, Barr SG, Mydlarski PR, Beck PL, et al. Efficacy of allogeneic hematopoietic cell transplantation for autoimmune diseases. *Transplant Cell Ther* 2021;27:489.e1-9.
56. Al-Hakim A, Poulter JA, Mahmoud D, Rose AMS, Elcombe S, Lachmann H, et al. Allogeneic haematopoietic stem cell transplantation for VEXAS syndrome: UK experience. *Br J Haematol* 2022;199:777-81.
57. van Leeuwen-Kerkhoff N, de Witte MA, Heijstek MW, Leavis HL. Case report: up-front allogeneic stem cell transplantation in a patient with the VEXAS syndrome. *Br J Haematol* 2022;199:e12-5.
58. Mangaonkar AA, Langer KJ, Lasho TL, Finke C, Litzow MR, Hogan WJ, et al. Reduced intensity conditioning allogeneic hematopoietic stem cell transplantation in VEXAS syndrome: data from a prospective series of patients. *Am J Hematol* 2023;98:E28-31.
59. Loschi M, Roux C, Sudaka I, Ferrero-Vacher C, Marceau-Renaut A, Duployez N, et al. Allogeneic stem cell transplantation as a curative therapeutic approach for VEXAS syndrome: a case report. *Bone Marrow Transplant* 2022;57:315-8.
60. Bottari CL, Dassa C, Rainville CM, Dutil É. The IADL profile: development, content validity, intra- and interrater agreement. *Can J Occup Ther* 2010;77:90-100.
61. Sorror ML, Maris MB, Storb R, Baron F, Sandmaier BM, Maloney DG, et al. Hematopoietic cell transplantation (HCT)-specific comorbidity index: a new tool for risk assessment before allogeneic HCT. *Blood* 2005;106:2912-9.
62. Penack O, Peczynski C, Mohty M, Yakoub-Agha I, Styczynski J, Montoto S, et al. How much has allogeneic stem cell transplant-related mortality improved since the 1980s? A retrospective analysis from the EBMT. *Blood Adv* 2020;4:6283-90.
63. Mussetti A, de Philippis C, Carniti C, Bastos-Oreiro M, Gayoso J, Cieri N, et al. CD3+ graft cell count influence on chronic GVHD in haploidentical allogeneic transplantation using post-transplant cyclophosphamide. *Bone Marrow Transplant* 2018;53:1522-31.
64. Fasslirinner F, Schetelig J, Burchert A, Kramer M, Trenschele R, Hegenbart U, et al. Long-term efficacy of reduced-intensity versus myeloablative conditioning before allogeneic haemopoietic cell transplantation in patients with acute myeloid leukaemia in first complete remission: retrospective follow-up of an open-label, randomised phase 3 trial. *Lancet Haematol* 2018;5:e161-9.
65. Aoudjhane M, Labopin M, Gorin NC, Shimoni A, Ruutu T, Kolb HJ, et al. Comparative outcome of reduced intensity and myeloablative conditioning regimen in HLA identical sibling allogeneic haematopoietic stem cell transplantation for patients older than 50 years of age with acute myeloblastic leukaemia: a retrospective survey from the Acute Leukemia Working Party (ALWP) of the European group for Blood and Marrow Transplantation (EBMT). *Leukemia* 2005;19:2304-12.
66. Beelen DW, Stelljes M, Reményi P, Wagner-Drouet EM, Dreger P, Bethge W, et al. Treosulfan compared with reduced-intensity busulfan improves allogeneic hematopoietic cell transplantation outcomes of older acute myeloid leukemia and myelodysplastic syndrome patients: final analysis of a prospective randomized trial. *Am J Hematol* 2022;97:1023-34.
67. DeZern AE, Zahurak ML, Symons HJ, Cooke KR, Rosner GL, Gladstone DE, et al. Haploidentical BMT for severe aplastic anemia with intensive GVHD prophylaxis including posttransplant cyclophosphamide. *Blood Adv* 2020;4:1770-9.
68. Sandler RD, Tattersall RS, Schoemans H, Greco R, Badoglio M, Labopin M, et al. Diagnosis and management of secondary HLH/MAS following HSCT and CAR-T cell therapy in adults; a review of the literature and a survey of practice within EBMT centres on behalf of the Autoimmune Diseases Working Party (ADWP) and Transplant Complications Working Party (TCWP). *Front Immunol* 2020;11:524.
69. Kobayashi R, Tanaka J, Hashino S, Ota S, Torimoto Y, Kakinoki Y, et al. Etoposide-containing conditioning regimen reduces the occurrence of hemophagocytic lymphohistiocytosis after SCT. *Bone Marrow Transplant* 2014;49:254-7.
70. Owattanapanich W, Ungprasert P, Wais V, Kungwankiatichai S, Bunjes D, Kuchenbauer F. FLAMSA-RIC for stem cell transplantation in patients with acute myeloid leukemia and myelodysplastic syndromes: a systematic review and meta-analysis. *J Clin Med* 2019;8:1437.
71. Vitale A, Caggiano V, della Casa F, Hernández-Rodríguez J, Frassi M, Monti S, et al. Development and implementation of the AIDA International Registry for Patients With VEXAS syndrome. *Front Med (Lausanne)* 2022;9:926500.