



# Knee Extension Is Related to the Posteriorly Deviated Gravity Line to the Pelvis in Young Adults: Radiographic Analysis Using Low-Dose Biplanar X-ray

Jun Young Park<sup>1</sup>, Byung Woo Cho<sup>2</sup>, Hyuck Min Kwon<sup>3</sup>, Kwan Kyu Park<sup>3</sup>, and Woo-Suk Lee<sup>2</sup>

<sup>1</sup>Department of Orthopedic Surgery, Yongin Severance Hospital, Yonsei University College of Medicine, Yongin;

<sup>2</sup>Department of Orthopedic Surgery, Gangnam Severance Hospital, Yonsei University College of Medicine, Seoul;

<sup>3</sup>Department of Orthopedic Surgery, Severance Hospital, Yonsei University College of Medicine, Seoul, Korea.

**Purpose:** We sought to compare the radiographic parameters concerning the sagittal alignment of the standing whole-body skeletons between the knee extension group and control group using the low-dose biplanar X-ray system in a young adult population without knee pain, and to investigate the associated variables for the sagittal knee angle (sagKA) among the radiographic parameters of global sagittal alignment.

**Materials and Methods:** We reviewed whole-body standing sagittal radiographs of 124 young adults taken from December 2018 to May 2020 in a single institution. We compared the radiographic parameters concerning the lower extremity sagittal alignment and global sagittal alignment between the knee extension group and control group. The factors correlated with sagKA were evaluated using multiple linear regression analysis.

**Results:** The sagittal vertical axis (SVA), the horizontal offset between the gravity line (GL) and the posterior edge of S1 endplate (GL-S), and the horizontal offset between the GL and the hip center (GL-H) were  $-11.6 \pm 21.3$  mm,  $5.1 \pm 23.8$  mm, and  $-25.1 \pm 27.1$  mm in the knee extension group, respectively, which were significantly smaller than those in the control group. The C7 plumb line (C7PL) and GL were deviated posterior to the sacrum and the hip center in the knee extension group, with the mean sagKA of  $-5.6^\circ$  in young adults.

**Conclusion:** The GL-H using GL, not the SVA using C7PL, was a significant radiographic factor associated with the sagKA.

**Key Words:** Gravity line, whole body sagittal alignment, center of gravity, knee, low-dose biplanar X-ray

## INTRODUCTION

Since the human body is a chain-like structure connected lin-

**Received:** May 24, 2022 **Revised:** July 19, 2022

**Accepted:** August 14, 2022 **Published online:** September 13, 2022

**Corresponding author:** Woo-Suk Lee, MD, PhD, Department of Orthopaedic Surgery, Gangnam Severance Hospital, Yonsei University College of Medicine, 211 Eonju-ro, Gangnam-gu, Seoul 06273, Korea.

E-mail: wsleeos@yuhs.ac

This work was performed at the Department of Orthopaedic Surgery, Gangnam Severance Hospital, Yonsei University College of Medicine in Seoul, Republic of Korea in 2020.

•The authors have no potential conflicts of interest to disclose.

© Copyright: Yonsei University College of Medicine 2022

This is an Open Access article distributed under the terms of the Creative Commons Attribution Non-Commercial License (<https://creativecommons.org/licenses/by-nc/4.0>) which permits unrestricted non-commercial use, distribution, and reproduction in any medium, provided the original work is properly cited.

early from the skull to the ankle joint,<sup>1,2</sup> relationships between the centers of each segment and the body's center of gravity (CoG) is an important consideration for understanding sagittal balance. The gravity line (GL), which is an imaginary vertical line through the whole-body CoG, is located laterally from the center of acoustic meatus (CAM) and passes slightly behind the center of the femoral head.<sup>3-5</sup> Various recent studies have used horizontal offsets of each vertebra from the GL to describe the sagittal reference during a standing posture.<sup>5,6</sup> GL is considered as another important measure in understanding whole-body sagittal balance other than the C7 plumb line (C7PL), which is conventionally used in the absence of whole-body imaging modalities.<sup>7,8</sup>

Standing posture is a daily routine activity, but it is inherently unstable since the whole-body CoG exists about 1 m above the ankle joint and the base of support is somewhat narrow.<sup>2</sup>

Therefore, body configuration, including the position of joints and body segment, needs to be firmly regulated to effectively maintain the standing posture.<sup>9</sup> Genu recurvatum, which has been defined as hyperextension of the knees, can cause pain, instability, and limitation of range of motion with a poor functional prognosis.<sup>10</sup> In addition, genu recurvatum after total knee arthroplasty (TKA), which is widely implemented, causes postoperative instability, and is the most common cause of revision after TKA.<sup>11</sup> To date, few studies have been conducted on the quantitative relationship between the knee flexion-extension status and whole-body CoG. Due to the chain-like connection of the whole body during the static standing process, we assumed that the global sagittal balance expressed through the location of the GL or C7PL might be related to the sagittal knee angle (sagKA).

Our hypothesis was that there is a significant difference in the sagittal location of the CoG between the knee extension group with the sagKA less than  $-2^\circ$  and the control group, and that the sagKA is correlated with the C7PL and GL, which are radiographic parameters expressing the sagittal location of the CoG. We sought to compare the radiographic parameters concerning the sagittal alignment of the standing whole-body skeletons between the knee extension group and control group using the low-dose biplanar X-ray system in a young adult population without knee pain, and to investigate the associated variables for the sagKA among the radiographic parameters of global sagittal alignment.

## MATERIALS AND METHODS

### Study cohort selection

This study protocol was approved by the Institutional Review Board of our hospital (IRB # 3-2020-0401). We retrospectively reviewed whole-body sagittal radiographs of 898 subjects from December 2018 through May 2020 in a single institution (Fig. 1). The inclusion criteria were as follows: 1) age 18–40 years, 2) patients who visited our outpatient clinic for musculoskeletal pain, 3) patients who underwent whole-body biplanar radiography, and 4) visual analog scale score  $<3$  points. The exclusion criteria were as follows: 1) any symptoms in the knee suggestive of knee diseases; 2) prior history of trauma or surgery of the spine, pelvis, or lower extremities; 3) scoliosis with Cobb angle  $>20^\circ$ ; 4) neuromuscular disease; and 5) any radiographic anomaly of the transitional lumbosacral spine, such as L5 sacralization or L6 type in which the parameters of spinopelvic sagittal alignment could not be determined.

### Radiographic examination

All images were taken using the low-dose biplanar X-ray system, known as the EOS system (EOS imaging, Paris, France), which captures simultaneous biplanar images of the whole body without magnification and distortion and reduces exposure to radiation by 50%–80% compared to conventional full-length radiography.<sup>12</sup> All subjects underwent biplanar radiography in a direct standing posture (Fig. 2). Patients were instructed to stand comfortably without leaning back and forth, while maintaining a horizontal gaze and touching their cheek bones with fingers, according to a previously reported protocol.<sup>4</sup> Well-trained technicians who had more than 2 years of experience

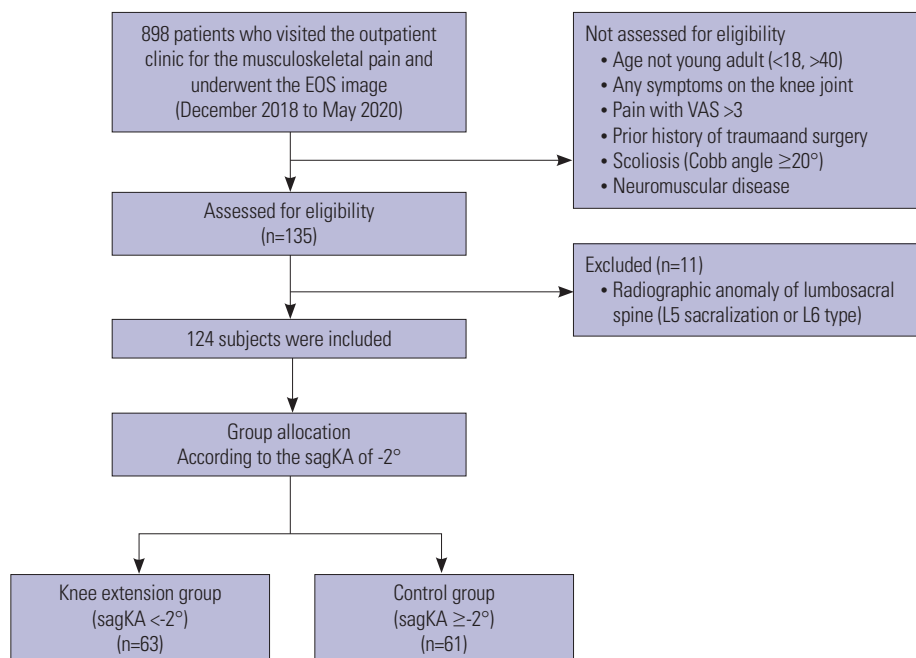
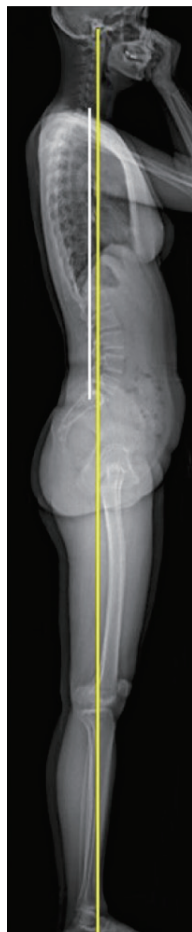

Fig. 1. Flowchart of patient inclusion. sagKA, sagittal knee angle; VAS, visual analog scale.

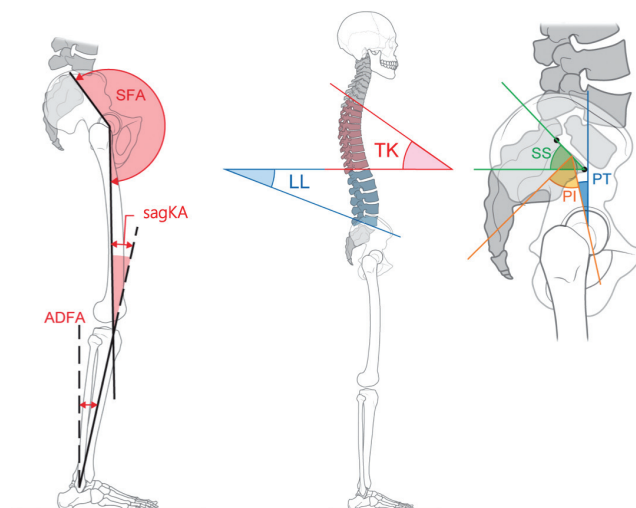


**Fig. 2.** EOS image in a static standing posture.

with the low-dose biplanar X-ray system performed the image capturing process.

### Radiographic measurement-lower extremity alignment

We measured the sagKA of the enrolled subjects, which was defined as the angle between the sagittal mechanical axis of the femur and tibia (Fig. 3). The sagittal mechanical axis of the femur was defined as the straight line between the hip center and knee center. The hip center was defined as the mid-point of the straight line connecting the centers of bilateral femoral heads, and the knee center was defined as the distal end of Blumensaat's line.<sup>13,14</sup> The sagittal mechanical axis of the tibia was defined as the line between the midpoint of tips of both intercondylar eminences and the ankle center. The ankle center was defined as the center of the tibial plafond.<sup>15</sup> We also measured the sacrofemoral angle (SFA) and ankle dorsiflexion angle (ADFA) for evaluating the degree of hip extension and ankle flexion. The SFA was defined as the angle formed by the line from the middle of S1 endplate to the hip center and the sagittal mechanical axis of the femur.<sup>12</sup> The angle between the sagittal mechanical axis of the tibia and the vertical line perpendicular to the ground was defined as the ADFA. As previously reported, the normative sagKA of healthy young adults is



**Fig. 3.** Definition of radiographic parameters of whole-body sagittal alignment. SFA, sacrofemoral angle; sagKA, sagittal knee angle; ADFA, ankle dorsiflexion angle; PI, pelvic incidence; SS, sacral slope; PT, pelvic tilt; TK, thoracic kyphosis; LL, lumbar lordosis.

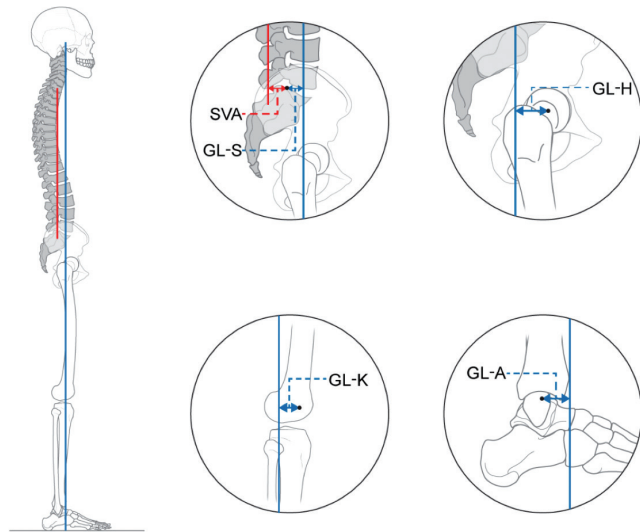
about 1°–2° in extension<sup>4,12</sup>; therefore, the subjects of our study cohort were allocated into two groups as follows: knee extension group with sagKA less than -2° and control group with sagKA greater than -2°. Positive values of the sagKA and ADFA indicated the status of knee flexion and ankle dorsiflexion, respectively.

### Radiographic measurement-standard spinopelvic alignment

Pelvic incidence (PI), sacral slope (SS), and pelvic tilt (PT) were measured based on the standard methods described in previous studies (Fig. 3).<sup>16</sup> Thoracic kyphosis (TK) was measured from the upper endplate of T4 to the superior endplate of T12, and lumbar lordosis (LL) was measured from the upper endplate of L1 to the endplate of S1, using the Cobb method.<sup>17</sup> The sagittal spinal posture of each subject was categorized according to the Roussouly classification based on the PI, SS, PT, and spinal sagittal alignments.<sup>18</sup>

### Radiographic measurement-global sagittal alignment

We measured the sagittal vertical axis (SVA) and horizontal offset between the GL and bony landmarks of lower extremities to assess and quantify the subjects' sagittal location of CoG in the static posture (Fig. 4). SVA was defined as the horizontal distance between the C7PL and the posterior edge of the sacral plate.<sup>19</sup> GL was defined as the vertical plumb line, which is perpendicular to the ground and passes through the CAM, according to the previous studies conducted using the force plate.<sup>3,5</sup> We measured four horizontal offsets between the GL and the posterior corner of the sacral plate, hip center, knee center, and ankle center, and designated each distance as GL-S, GL-H, GL-K, and GL-A, respectively. Positive values of the SVA and horizontal offset meant that the C7PL and GL were anterior to



**Fig. 4.** Definition of radiographic parameters concerning the sagittal location of the center of gravity. Sagittal vertical axis (SVA), horizontal offset between gravity line (GL) and posterior edge of S1 endplate (GL-S), horizontal offset between GL and hip center (GL-H), horizontal offset between GL and knee center (GL-K), and horizontal offset between GL and ankle center (GL-A). Red line indicates C7 plumb line and blue line indicates GL.

the bony landmarks to be measured.

**Evaluation of intrarater and interrater reliability**

Two orthopedic surgeons performed the radiographic measurement using sterEOS (EOS imaging) and Centricity (GE Health Care Products and Solutions, Chicago, IL, USA). Each rater measured all of the radiographic parameters for the second time, 2–3 weeks after the initial measurement, to evaluate the intrarater reliability. Each rater was blinded to others’ measurements during the period of evaluation for assessing interrater reliability. The degree of measurement reliability was assessed using intraclass correlation coefficients (ICC). The ICCs for intrarater and interrater reliabilities were all >0.9 for all radiographic parameters, which meant that all the radiographic measurements were reliable.

**Statistical analyses**

R software, version 3.6.3 (R Foundation for Statistical Computing, Vienna, Austria) was used for statistical analyses. All data are summarized as the means and standard deviations for continuous variables. Independent t-test and chi-squared test were used to compare the demographic and radiographic parameters between the knee extension group and control group. Univariate multiple linear regressions were performed to analyze the effect of independent variables on a dependent variable, and we selected the statistically significant independent variables in a stepwise manner with the alpha level set as 0.05. The dependent variable was the sagKA, and independent variables were age, sex, body mass index (BMI), SVA, GL-S, GL-H, GL-K, and GL-A. A *p*-value <0.05 was considered to indicate statistical

**Table 1.** Demographics of the Study Cohort (n=124)

Characteristics	Values
Age (yr)	29.4±6.3 (18–40)
Sex	
Male	58 (47)
Female	66 (53)
BMI (kg/m <sup>2</sup> )	22.6±3.3 (16.4–0.6)
PI (°)	46.6±9.5 (24–68)
SS (°)	37.1±7.9 (15–56)
PT (°)	9.5±7.5 (-6–26)
LL (°)	49.5±11.0 (14–73)
TK (°)	28.3±9.8 (-1–50)
Sagittal spinal posture	
Type 1	20 (16)
Type 2	21 (17)
Type 3	62 (50)
Type 4	21 (17)
Sagittal hip-knee-ankle angle	
Knee extension group	63 (51)
Control group	61 (49)

BMI, body mass index; PI, pelvic incidence; SS, sacral slope; PT, pelvic tilt; LL, lumbar lordosis; TK, thoracic kyphosis.

Data are presented as mean±standard deviation (range) or n (%). Sagittal spinal posture is categorized according to the Roussouly classification.

significance. We used G\*Power, version 3.1.9.6 (Heinrich-Heine-Universität Düsseldorf, Düsseldorf, Germany) to calculate the adequate sample size.<sup>20</sup> A total of 124 subjects were required to undergo linear multiple regression analysis using an alpha error of 0.05, power of 0.95, and effective size of 0.24; and hence, the sample size of our study cohort was acceptable.

**RESULTS**

**Baseline characteristics**

Overall, our study enrolled 124 subjects comprising 58 male and 66 female with a mean age of 29.4±6.3 years and a mean BMI of 22.6±3.3 kg/m<sup>2</sup> (Table 1). Sixty-three subjects (51%) were placed in the knee extension group and 61 (49%) in the control group according to our definition. Twenty subjects (16%) were classified as type 1, 21 (17%) as type 2, 62 (50%) as type 3, and 21 (17%) as type 4 according to the Roussouly classification.<sup>18</sup>

**Comparison of sagittal alignment parameters between two groups**

In the comparison of demographic data between the knee extension group and control group, the difference in age and BMI was not significant, but the proportion of women in the knee extension group was significantly higher than that in the control group (70% vs. 36%, *p*<0.001). There was a significant difference in the sagKA, SFA, and ADFA between the two groups. The mean sagKA was 1.7±2.8°, SFA was 192.2±7.5°, and ADFA was

3.3±1.8° in the control group, whereas the mean sagKA was -5.6±2.6°, SFA was 195.9±8.8°, and ADFA was -0.1±1.7° in the knee extension group.

Among the radiographic parameters of global sagittal alignment, the mean SVA in the knee extension group was -11.6±21.3 mm, which was significantly smaller than -1.3±25.1 mm in the control group. The mean GL-S, GL-H, and GL-A in the knee extension group were also significantly smaller than those of the control group (Table 2). The mean GL-S, GL-H, and GL-A were 5.1±23.8 mm, -25.1±27.1 mm, and 23.3±25.6 mm in the

knee extension group, and 18.9±29.8 mm, -11.7±27.1 mm, and 33.1±27.2 mm in the control group, respectively. The mean GL-K was 14.0±26.3 mm in the knee extension group and 0.2±25.6 mm in the control group, and a statistically significant difference was observed between the two values.

### Univariate linear regression analysis for the sagKA

Simple linear regression was performed to identify the association between the sagKA and independent variables. According to the results of the simple linear regression analysis, the sagKA was significantly decreased in older subjects, women, decreased SVA, decreased GL-S, decreased GL-H, increased GL-K, and decreased GL-A (Table 3). Multiple linear regression was conducted for factors that were significant in the univariate analysis (age, female sex, SVA, GL-S, GL-H, GL-K and GL-A). In the final model, the independent factors for sagKA were GL-H, GL-K, and GL-A. The extended knee was predicted by increased GL-K and decreased GL-H and GL-A (Table 3). According to our multiple linear regression equation, the knee tended to be extended with the sagKA decreased by 1.4° when the GL was deviated 1 cm posterior to the hip center.

**Table 2.** Comparison of Sagittal Alignment Parameters between the Knee Extension Group and Control Group

	Knee extension group (n=63)	Control group (n=61)	Total	p value
Demographic data				
Age (yr)	30.3±6.2	28.4±6.4	29.4±6.3	0.109
BMI (kg/m <sup>2</sup> )	22.1±3.0	23.1±3.4	22.6±3.3	0.078
Sex				
Male	19 (30)	39 (64)	58 (47)	<0.001
Female	44 (70)	22 (36)	66 (53)	<0.001
Lower extremity sagittal alignment (°)				
sagKA	-5.6±2.6	1.7±2.8	-2.0±4.5	<0.001
SFA	195.9±8.8	192.2±7.5	194.1±8.3	0.011
ADFA	-0.1±1.7	3.3±1.8	1.6±2.4	<0.001
Global sagittal alignment (mm)				
SVA	-11.6±21.3	-1.3±25.1	-6.5±23.7	0.015
GL-S	5.1±23.8	18.9±29.8	11.9±27.7	0.005
GL-H	-25.1±27.1	-11.7±27.1	-18.5±27.8	0.007
GL-K	14.0±26.3	0.2±25.6	7.2±26.8	0.004
GL-A	23.3±25.6	33.1±27.2	28.1±26.8	0.041

BMI, body mass index; sagKA, sagittal knee angle; SFA, sacrofemoral angle; ADFA, ankle dorsiflexion angle; SVA, sagittal vertical axis; GL, gravity line; GL-S, horizontal offset between GL and posterior edge of S1 endplate; GL-H, horizontal offset between GL and hip center; GL-K, horizontal offset between GL and knee center; GL-A, horizontal offset between GL and ankle center. Data are presented as mean±standard deviation or n (%).

## DISCUSSION

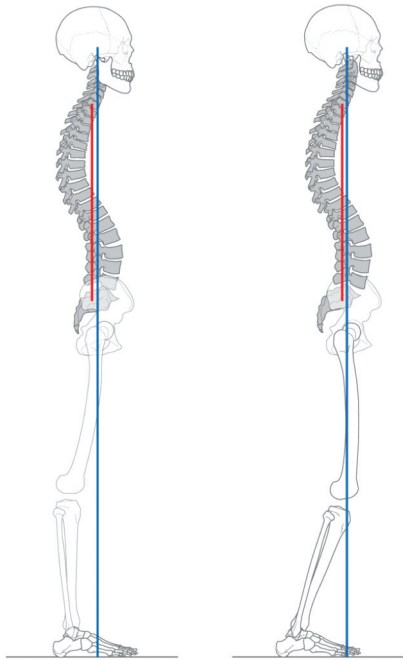
The pelvis is known to act as a hinge between the spine and hip to maintain balance during bipedalism.<sup>21</sup> Knee flexion is known to be a part of the compensation mechanism for maintaining proper balance and preventing the GL from shifting anterior to the body in the aging process.<sup>22</sup> However, little is known about whether there is a correlated or quantified relationship between the CoG and knee flexion-extension status in a young adult population. We investigated the relationship between the sagKA and the sagittal location of C7PL and GL in a standing posture through radiographic analysis using the low-dose biplanar X-ray system. We found that C7PL and GL were deviated posterior to the sacrum and the hip center in the

**Table 3.** Simple Linear Regression Analysis of Factors Correlated with sagKA

Variables	Simple regression			Multiple regression		
	B (95% CI)	β	p value	B (95% CI)	β	p value
Age	-0.15 (-0.28, -0.03)	-0.22	0.016			
Sex, female	-3.31 (-4.83, -1.79)	-0.36	<0.001			
BMI	0.16 (-0.09, 0.40)	0.11	0.214			
SVA	0.06 (0.03, 0.09)	0.31	<0.001			
GL-S	0.05 (0.02, 0.08)	0.31	<0.001			
GL-H	0.05 (0.02, 0.07)	0.29	0.001	0.14 (0.13, 0.15)	0.85	<0.001
GL-K	-0.06 (-0.09, -0.03)	-0.35	<0.001	-0.28 (-0.29, -0.27)	-1.64	<0.001
GL-A	0.03 (0.00, 0.06)	0.19	0.038	0.14 (0.13, 0.15)	0.82	<0.001

sagKA, sagittal knee angle; B, unstandardized regression coefficient; CI, confidence interval; β, standardized regression coefficient; BMI, body mass index; SVA, sagittal vertical axis; GL, gravity line; GL-S, horizontal offset between GL and posterior edge of S1 endplate; GL-H, horizontal offset between GL and hip center; GL-K, horizontal offset between GL and knee center; GL-A, horizontal offset between GL and ankle center. Adjusted R<sup>2</sup>=0.97.





**Fig. 5.** Schematic model representing the relationships between the knee and the center of gravity. The left is the knee extension model and the right is the control model. Red line indicates C7 plumb line and blue line indicates gravity line.

knee extension group with the sagKA less than  $-2^\circ$  (Fig. 5). In addition, the GL-H using GL, not the SVA using C7PL, was a significant radiographic factor that was associated with the sagKA.

According to the multiple linear regression analysis, predictive factors for the sagKA were GL-H, GL-K, and GL-A. However, the SVA was not included in the final model in our regression analysis, which means that the C7PL was found to be inadequate for the parameters of global sagittal alignment to determine the sagKA. Additionally, when the knee was extended, we determined that the GL-K and GL-A were clinically insignificant in the regression equation for predicting the sagKA.

The SVA and GL-S, which represent the location of C7PL and GL using the same bony landmark of the posterior edge of the sacral plate, have been widely used as the hypothetical CoG in whole-body sagittal radiographs.<sup>7</sup> The normal range of SVA is known to be from  $-12$  to  $1$  mm, and normally, the GL is approximately  $7$  mm ahead of the center of the sacral plate in asymptomatic adults under the age of  $40$  years.<sup>4-6,12</sup> In our results of  $124$  young adults, the mean SVA was  $-6.5$  mm, the GL was located  $11.9$  mm ahead of the posterior corner of the sacral plate, and the horizontal offset distance between the center and the posterior corner of the sacral plate was about  $10$  mm. Thus, the sagittal location of the C7PL and GL from the sacrum was not significantly out of the normal range, as suggested in the previously reported studies.

By analyzing the SVA, several studies reported that the deterioration of global sagittal alignment is strongly correlated with poor outcomes in patients with adult spinal deformity.<sup>23</sup> The

compensation mechanism in the knee segment is implemented in the form of knee flexion to avoid the anterior translation of the GL.<sup>1</sup> As such, lumbar kyphosis and knee flexion have a close relationship, and this phenomenon is known as “knee–spine syndrome.”<sup>24</sup> We clarified that the GL deviating posterior to the hip center causes knee extension through radiographic analysis of young adults without definite knee and spine pathology and global sagittal malalignment. We believe that our results may explain the mechanism of knee extension that could not be explained through the phenomenon of “knee–spine syndrome.”

In particular, elucidating the relationship between CoG and knee extension may provide basic help in understanding the sagittal knee biomechanics after TKA. Risk factors for the genu recurvatum after TKA include neuromuscular disorder, inflammatory arthritis, genu valgum, and preoperative genu recurvatum.<sup>25-27</sup> However, even though the extension gap was tightly adjusted during TKA in patients without the abovementioned risk factors, the de novo genu recurvatum was often observed during the postoperative period,<sup>11,28</sup> suggesting that there may be a new risk factor for postoperative recurvatum after TKA. Considering that decreased GL-H induced knee extension according to our study results, a follow-up study is needed to determine if a decrease in GL-H can be a risk factor for postoperative recurvatum after TKA.

The current study had several limitations. First, the anatomical characteristics of lower extremities may depend on the ethnicity of subjects. Since all of the subjects in the current study were Korean, care should be taken in applying our results directly to other cohorts. Second, our study lacked the evaluation of spinal pain and functional status for subjects using questionnaires, such as the Oswestry Disability Index and Scoliosis Research Society-22, due to its retrospective design. As a result, we might have included subjects with back pain or radiculopathy in our study cohort. Third, there were some disparities in determining the knee center to set the sagittal mechanical axis of the femur and tibia. Various methods have been used to define the mechanical axes of the femur and tibia in the sagittal plane.<sup>14</sup> In the pilot study of our cohort, when the mechanical axis of the femur was set using the midpoint of intercondylar eminences, the sagKA differed by about  $2^\circ$ . Fourth, the EOS system is an imaging modality with excellent reliability,<sup>29</sup> but we performed the radiographic analysis with only one radiograph for each patient. Hey, et al.<sup>30</sup> suggested that the radiographic parameters of whole-body sagittal alignment vary between serial images using serial EOS images. Finally, we did not use force plates in determining the location of the GL, but we positioned the GL by referring to a previously reported study conducted using force plates.<sup>3-5</sup>

We elucidated that C7PL and GL were deviated posterior to the sacrum and hip center in the knee extension group with the sagKA less than  $-2^\circ$  in young adults. According to our multiple regression analysis, knee extension could be predicted by decrease in GL-H. Although our study was limited in that it was a

retrospective radiographic study, we hope that our findings will help in understanding the relationships between CoG and the knee status of flexion and extension through the quantitative results of measurements on whole-body sagittal radiographs.

## ACKNOWLEDGEMENTS

The authors would like to thank Medical Illustration & Design, part of the Medical Research Support Services of Yonsei University College of Medicine, for all of the artistic support related to this work.

## AUTHOR CONTRIBUTIONS

**Conceptualization:** Woo-Suk Lee and Hyuck Min Kwon. **Data curation:** Hyuck Min Kwon and Jun Young Park. **Formal analysis:** Byung Woo Cho and Jun Young Park. **Investigation:** Kwan Kyu Park. **Methodology:** Byung Woo Cho and Jun Young Park. **Project administration:** Woo-Suk Lee. **Resources:** Kwan Kyu Park. **Software:** Hyuck Min Kwon and Byung Woo Cho. **Supervision:** Woo-Suk Lee. **Validation:** Kwan Kyu Park. **Visualization:** Jun Young Park. **Writing—original draft:** Jun Young Park. **Writing—review & editing:** Woo-Suk Lee. **Approval of final manuscript:** all authors.

## ORCID iDs

Jun Young Park <https://orcid.org/0000-0002-4713-4036>  
 Byung Woo Cho <https://orcid.org/0000-0002-7472-4103>  
 Hyuck Min Kwon <https://orcid.org/0000-0002-2924-280X>  
 Kwan Kyu Park <https://orcid.org/0000-0003-0514-3257>  
 Woo-Suk Lee <https://orcid.org/0000-0002-0798-1660>

## REFERENCES

1. Le Huec JC, Thompson W, Mohsinaly Y, Barrey C, Faundez A. Sagittal balance of the spine. *Eur Spine J* 2019;28:1889-905.
2. Ivanenko Y, Gurfinkel VS. Human postural control. *Front Neurosci* 2018;12:171.
3. Steffen JS, Obeid I, Aurouer N, Hauger O, Vital JM, Dubouset J, et al. 3D postural balance with regard to gravity line: an evaluation in the transversal plane on 93 patients and 23 asymptomatic volunteers. *Eur Spine J* 2010;19:760-7.
4. Hasegawa K, Okamoto M, Hatsushikano S, Shimoda H, Ono M, Watanabe K. Normative values of spino-pelvic sagittal alignment, balance, age, and health-related quality of life in a cohort of healthy adult subjects. *Eur Spine J* 2016;25:3675-86.
5. Hasegawa K, Okamoto M, Hatsushikano S, Shimoda H, Ono M, Homma T, et al. Standing sagittal alignment of the whole axial skeleton with reference to the gravity line in humans. *J Anat* 2017;230:619-30.
6. Hey HWD, Tan KA, Thadani VN, Liu GK, Wong HK. Characterization of sagittal spine alignment with reference to the gravity line and vertebral slopes: an analysis of different roussouly curves. *Spine (Phila Pa 1976)* 2020;45:E481-8.
7. Yagi M, Takeda K, Machida M, Asazuma T. Discordance of gravity line and C7PL in patient with adult spinal deformity--factors affecting the occiput-trunk sagittal discordance. *Spine J* 2015;15:213-21.
8. Kim YC, Lenke LG, Lee SJ, Gum JL, Wilartatsami S, Blanke KM. The cranial sagittal vertical axis (CrSVA) is a better radiographic measure to predict clinical outcomes in adult spinal deformity surgery than the C7 SVA: a monocentric study. *Eur Spine J* 2017;26:2167-75.
9. Di Giulio I, Baltzopoulos V. Attainment of quiet standing in humans: are the lower limb joints controlled relative to a misaligned postural reference? *Front Physiol* 2019;10:625.
10. Dean RS, Graden NR, Kahat DH, DePhillipo NN, LaPrade RF. Treatment for symptomatic genu recurvatum: a systematic review. *Orthop J Sports Med* 2020;8:2325967120944113.
11. Mortazavi SMJ, Razzaghoof M, Noori A, Okati A. Late-onset de novo genu recurvatum after primary total knee arthroplasty: a potential indication for isolated polyethylene exchange. *Arthroplast Today* 2020;6:492-5.
12. Jalai CM, Cruz DL, Diebo BG, Poorman G, Lafage R, Bess S, et al. Full-body analysis of age-adjusted alignment in adult spinal deformity patients and lower-limb compensation. *Spine (Phila Pa 1976)* 2017;42:653-61.
13. Brattström H. Patella alta in non-dislocating knee joints. *Acta Orthop Scand* 1970;41:578-88.
14. Chung BJ, Kang YG, Chang CB, Kim SJ, Kim TK. Differences between sagittal femoral mechanical and distal reference axes should be considered in navigated TKA. *Clin Orthop Relat Res* 2009;467:2403-13.
15. Han HS, Chang CB, Seong SC, Lee S, Lee MC. Evaluation of anatomic references for tibial sagittal alignment in total knee arthroplasty. *Knee Surg Sports Traumatol Arthrosc* 2008;16:373-7.
16. Legaye J, Duval-Beaupère G, Hecquet J, Marty C. Pelvic incidence: a fundamental pelvic parameter for three-dimensional regulation of spinal sagittal curves. *Eur Spine J* 1998;7:99-103.
17. Garbossa D, Pejrona M, Damilano M, Sansone V, Ducati A, Berjano P. Pelvic parameters and global spine balance for spine degenerative disease: the importance of containing for the well being of content. *Eur Spine J* 2014;23 Suppl 6:616-27.
18. Roussouly P, Gollogly S, Berthounaud E, Dimnet J. Classification of the normal variation in the sagittal alignment of the human lumbar spine and pelvis in the standing position. *Spine (Phila Pa 1976)* 2005;30:346-53.
19. Schwab FJ, Blondel B, Bess S, Hostin R, Shaffrey CI, Smith JS, et al. Radiographical spinopelvic parameters and disability in the setting of adult spinal deformity: a prospective multicenter analysis. *Spine (Phila Pa 1976)* 2013;38:E803-12.
20. Faul F, Erdfelder E, Buchner A, Lang AG. Statistical power analyses using G\*Power 3.1: tests for correlation and regression analyses. *Behav Res Methods* 2009;41:1149-60.
21. Pizones J, García-Rey E. Pelvic motion the key to understanding spine-hip interaction. *EFORT Open Rev* 2020;5:522-33.
22. Barrey C, Roussouly P, Le Huec JC, D'Acunzi G, Perrin G. Compensatory mechanisms contributing to keep the sagittal balance of the spine. *Eur Spine J* 2013;22 Suppl 6:S834-41.
23. Daubs MD, Lenke LG, Bridwell KH, Kim YJ, Hung M, Cheh G, et al. Does correction of preoperative coronal imbalance make a difference in outcomes of adult patients with deformity? *Spine (Phila Pa 1976)* 2013;38:476-83.
24. Murata Y, Takahashi K, Yamagata M, Hanaoka E, Moriya H. The knee-spine syndrome. Association between lumbar lordosis and extension of the knee. *J Bone Joint Surg Br* 2003;85:95-9.
25. Meding JB, Keating EM, Ritter MA, Faris PM, Berend ME. Genu recurvatum in total knee replacement. *Clin Orthop Relat Res* 2003;416:64-7.
26. Prasad A, Donovan R, Ramachandran M, Dawson-Bowling S, Millington S, Bhumbra R, et al. Outcome of total knee arthroplasty in patients with poliomyelitis: a systematic review. *EFORT Open Rev* 2018;3:358-62.
27. Seo SS, Kim CW, Lee CR, Seo JH, Kim DH, Kim OG. Outcomes of

- total knee arthroplasty in degenerative osteoarthritic knee with genu recurvatum. *Knee* 2018;25:167-76.
28. Erceg M, Rakić M. Genu recurvatum as a complication after total knee arthroplasty. *Acta Clin Croat* 2012;51:265-8.
29. Wade R, Yang H, McKenna C, Faria R, Gummerson N, Woolacott N. A systematic review of the clinical effectiveness of EOS 2D/3D X-ray imaging system. *Eur Spine J* 2013;22:296-304.
30. Hey HWD, Tan KLM, Moorthy V, Lau ET, Lau LL, Liu G, et al. Normal variation in sagittal spinal alignment parameters in adult patients: an EOS study using serial imaging. *Eur Spine J* 2018;27:578-84.