

Clinical and immunological study of Tofacitinib and Baricitinib in refractory Blau syndrome: case report and literature review

Carmen Álvarez-Reguera*¹, Diana Prieto-Peña*, Alba Herrero-Morant, Lara Sánchez-Bilbao, José Luis Martín-Varillas, Elena González-López, María Gutiérrez-Larrañaga, David San Segundo, Rosalía Demetrio-Pablo, Gonzalo Ocejo-Vinyals†, Miguel A. González-Gay†² and Ricardo Blanco†²

Abstract: Blau syndrome (BS) is an autoinflammatory disorder characterized by non-caseating granulomatous dermatitis, arthritis, and uveitis. We present a case of refractory and severe BS that was treated with the Janus kinase inhibitors (JAKINIBS), Tofacitinib (TOFA) and then Baricitinib (BARI). Our aim was to describe the clinical and immunological outcomes after treatment with JAKINIBS. Blood tests and serum samples were obtained during follow-up with TOFA and BARI. We assessed their effects on clinical outcomes, acute phase reactants, absolute lymphocyte counts (ALCs), lymphocyte subset counts, immunoglobulins, and cytokine levels. A review of the literature on the use of JAKINIBS for the treatment of uveitis and sarcoidosis was also conducted. TOFA led to a rapid and maintained disease control and a steroid-sparing effect. A decrease from baseline was observed in ALC, CD3+, CD4+, CD8+, and natural killer (NK) cell counts. B-cells were stable. Serum levels of interleukin (IL)-4 and tumor necrosis factor alpha (TNF- α) increased, whereas IL-2, IL-6, IL-10, and IL-17 maintained stable. TOFA was discontinued after 19 months due to significant lymphopenia. The initiation of BARI allowed maintaining adequate control of disease activity with an adequate safety profile. The literature review showed seven patients with uveitis and five with sarcoidosis treated with JAKINIBS. No cases of BS treated with JAKINIBS were found. We report the successful use of JAKINIBS in a patient with refractory and severe BS.

Keywords: Baricitinib, Blau syndrome, case report, Tofacitinib, uveitis

Received: 15 October 2021; revised manuscript accepted: 24 March 2022.

Introduction

Blau syndrome (BS) is an autoinflammatory disorder characterized by non-caseating granulomatous dermatitis, symmetric arthritis, and recurrent uveitis with childhood onset. It is associated with mutations in the *NOD2/CARD15* gene.¹⁻³ BS is inherited in an autosomal dominant pattern. When the same phenotype is presented without family history, it is also called Early Onset Sarcoidosis (EOS), but the term BS can be used for both inherited and sporadic forms.⁴⁻⁶

Eye involvement is usually the most severe and refractory manifestation of BS. Chronic granulomatous uveitis can evolve into cataract, high

intraocular pressure (IOP), and band keratopathy, frequently requiring surgery.^{3,7}

Non-steroidal anti-inflammatory drugs (NSAIDs), corticosteroids, and conventional immunosuppressive agents, such as methotrexate (MTX) and azathioprine (AZA), are initially used. More recently, biologic agents such as tumor necrosis factor alpha (TNF- α) blockers, interleukin (IL)-1, and IL-6 receptor inhibitors have demonstrated effectiveness in refractory cases.⁸⁻¹⁰

Tofacitinib (TOFA) and Baricitinib (BARI) are two Janus kinase inhibitors (JAKINIBS) that are approved for their use in several immune-mediated

Ther Adv Musculoskel Dis

2022, Vol. 14: 1–10

DOI: 10.1177/
1759720X221093211

© The Author(s), 2022.
Article reuse guidelines:
sagepub.com/journals-
permissions

Correspondence to:

Ricardo Blanco
Division of Rheumatology,
Hospital Universitario
Marqués de Valdecilla,
IDIVAL, Avda. Valdecilla
s/n., Santander ES-39008,
Spain.
rblancovela@gmail.com

Miguel A. González-Gay
Division of Rheumatology,
Hospital Universitario
Marqués de Valdecilla,
IDIVAL, Avda. Valdecilla
s/n., Santander ES-39008,
Spain.
miguelaggay@hotmail.
com

Carmen Álvarez-Reguera
Diana Prieto-Peña
Alba Herrero-Morant
Lara Sánchez-Bilbao
José Luis Martín-Varillas
Division of Rheumatology,
Hospital Universitario
Marqués de Valdecilla,
IDIVAL, Santander, Spain

Elena González-López
María Gutiérrez-Larrañaga
David San Segundo
Gonzalo Ocejo-Vinyals
Department of
Immunology, Hospital
Universitario Marqués
de Valdecilla, Santander,
Spain

Rosalía Demetrio-Pablo
Department of
Ophthalmology, Hospital
Universitario Marqués
de Valdecilla, Santander,
Spain

*Carmen Álvarez-Reguera and Diana Prieto-Peña share first authorship.

†Gonzalo Ocejo-Vinyals, Professor Miguel A. González-Gay, and Dr Ricardo Blanco share senior authorship.

inflammatory diseases (IMIDs) but not in granulomatous diseases. Janus kinases (JAK) may be involved in the pathogenesis of uveitis and sarcoidosis; however, there are only a few case reports published on the successful use of JAKINIBS.^{11–14}

We present a case of severe BS refractory to multiple lines of immunosuppressive therapy, treated with TOFA and then BARI. In addition, a literature review was performed on the use of JAKINIBS in uveitis and sarcoidosis.

Patients and methods

We present the case of a 25-year-old woman with BS followed by the Rheumatology and Ophthalmology unit of our hospital. At the age of 2 years old, she was initially diagnosed with Juvenile Idiopathic Arthritis (JIA) after presenting several episodes of polyarthritis. She was initially treated with acetylsalicylic acid that was discontinued due to drug-induced hepatitis. MTX (3.75 mg/week) and oral methylprednisolone (0.5 mg/kg/day) were then started. From the age of 4, she developed several episodes of bilateral anterior uveitis and required topical corticosteroids and cycloplegics. The ophthalmologic examination showed peripapillary granulomas and mild vitritis.

In addition to relapsing bilateral anterior uveitis, when she was 10 years old, she had a micropapular erythematous rash in groins and both feet. The skin biopsy revealed non-caseating granulomas. BS was then suspected, and genetic laboratory testing reported a mutation in *NOD2/CARD15* (*R334Q*) gene. This mutation was not found in her parents; therefore, she was diagnosed with EOS/ sporadic BS. Biological therapy was started due to refractory manifestations. She received etanercept, anakinra, and abatacept, but none of them were effective to induce remission of the disease.

At the age of 14 years old, she experienced an episode of bilateral panuveitis. Adalimumab (ADA; 40 mg every other week (EOW)) was prescribed. In the subsequent years, she developed other severe episodes of uveitis, IOP, and cataract in her right eye. IOP required surgery.

Five years later, she required intensified therapy with ADA (40 mg weekly) and oral MTX up to 20 mg weekly to control ocular, cutaneous, and articular manifestations. Despite good adherence to treatment, systemic and topical corticosteroids were frequently

required for recurrent episodes of anterior, posterior, and panuveitis (up to 3–4 per year).

At the age of 25 years old, in addition to erythematous rash (Figure 1(a)), the ophthalmologic examination showed cystoid macular edema in her left eye. The central foveal thickness measured by Optical Coherence Tomography (OCT) was 372 μm, and the best-corrected visual acuity in her left eye was 0.5/1. (Figure 1(c)).

Due to the persistence of inflammatory activity, and based on the rationale of JAK involvement in the pathogenesis of BS,¹¹ written informed consent to treatment was obtained, because TOFA is an off-label indication of BS. We followed the CARE (Case Report) guidelines for case report publication.¹⁵ All the patient details were de-identified, and the signed consent to publish was also provided from the patient. It was approved by the Local Clinical Research Ethics Committee (Name: Comité Ético de Investigación médica de Cantabria), approval number: 2020.437.

In addition to methylprednisolone 6 mg/day, TOFA at a standard dose of 5 mg twice daily was started. ADA and MTX were stopped. TOFA led to a rapid and sustained control of previously refractory clinical manifestations. Arthritis signs in both knees and wrists and erythematous plaques on chest and lower extremities disappeared 1 month after TOFA initiation. Macular edema and anterior uveitis signs improved from the first weeks of treatment and were not present at ophthalmological evaluation after 2 months. A progressive reduction in corticosteroids dose up to withdrawal was observed.

The patient was asymptomatic at cutaneous, ocular, and articular levels during TOFA therapy. She only experienced one relapse consisting of a micropapular rash in the infraumbilical area and flogotic signs in both wrists when TOFA was discontinued during a mild upper respiratory infection.

Nineteen months after TOFA onset, the dose was reduced to 5 mg/daily because of significant lymphopenia (700 cells/μl). Subsequently, the patient experienced clinical worsening consisting of arthritis of both wrists. TOFA was finally discontinued due to persistence of marked lymphopenia (500 cells/μl). Four weeks after TOFA discontinuation, an improvement in lymphocyte count to normal range levels was observed.

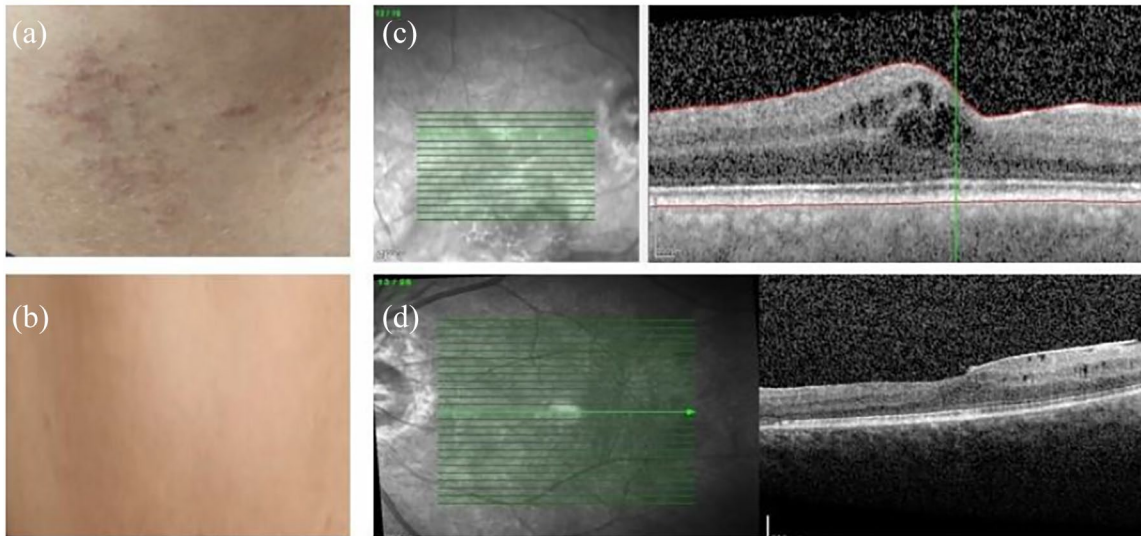


Figure 1. Skin rash before (a) after treatment with Tofacitinib (b). Optical coherence tomography of left eye showing cystoid macular edema before (c) and after treatment with Tofacitinib (d).

Due to BS worsening, ADA was restarted (40 mg EOW) while waiting for other therapeutic options. After 2 weeks of ADA, a new off-label treatment with BARI at a standard dose of 4 mg daily was started. Since then, cutaneous, ocular, and joint manifestations have remained stable.

Laboratory Immunological study

Blood tests and serum samples were obtained at baseline and at months 1 and 12 after TOFA onset and at baseline and month 4 after BARI onset. We assessed their effects on acute phase reactants, absolute lymphocyte counts (ALCs), lymphocyte subset counts, red blood cell count, platelet count, immunoglobulins, and cytokine levels.

Ethylenediaminetetraacetic acid (EDTA) peripheral blood samples were collected to analyze B- and T-lymphocytes subsets using flow cytometry in a Navios EX Flow Cytometer (Beckman Coulter, Barcelona, Spain). Monoclonal antibodies from Beckman Coulter were used to characterize T-, B-, and natural killer (NK) cells (available upon request).

IgG, IgM, IgA, and IgG subclasses were measured in serum samples by turbidimetry using the Optilite® analyzer (Binding Site, Barcelona, Spain).

Peripheral blood mononuclear cells (PBMCs) were isolated by using Ficoll-Paque gradient from

sodium heparin blood samples for the *in vitro* polyclonal activation. Peripheral Blood Mononuclear Cells (PBMCs) were seeded on 96-well plates at a final concentration of 0.5×10^6 cells/ μ l, cultured at 37°C in 5% CO₂ with supplemented Roswell Park Memorial Institute 1640 medium (R10), and stimulated with magnetic beads coated with anti-CD3 and anti-CD28 antibodies (Dynabeads®; Thermo Fisher Scientific, Madrid, Spain) in 1:1 cell:bead ratio. After 72 h, T-cell proliferation was analyzed measuring carboxyfluorescein succinimidyl ester (CFSE) by flow cytometry, and supernatants were collected and stored at -80°C until analysis.

In the serum and culture supernatant, IL-2, IL-4, IL-6, IL-10, IL-17A, and TNF- α levels were analyzed by using the Human High Sensitivity T-cell panel from Merck Millipore (Merck Life Science S.L.U., Madrid, Spain) in a Luminex 200 platform following manufacturer's instructions. The normal or abnormal levels of cytokines were established following two different criteria: the pretreatment levels of the patient and the levels of five healthy age and sex-matched controls.

Results

Laboratory Immunological study

Table 1 shows the laboratory test results throughout the follow-up of treatment with TOFA and BARI. A decrease from baseline in the ALC, CD3+, CD4+, and CD8+ cell counts was

Table 1. Complete laboratory and immunological test results throughout follow-up with TOFA and BARI therapy.

Laboratory parameters	TOFA Baseline	TOFA Month 1	TOFA Month 12	BARI Baseline	BARI Month 4	Normal range
Acute phase reactants						
CRP (mg/dl)	0.5	<0.4	<0.4	0.4	<0.4	<0.5
ESR (mm/1 h)	13	5	10	–	–	1–20
Lymphoid lineage cells						
Lymphocyte subsets (cells/ μ l)						
Lymphocytes/ μ l	3600	3100	900	1200	800	1200–5000
CD3	2907	2370	855	1017	564	404–2075
CD4	2146	1743	624	703	430	297–1698
CD8	799	542	220	267	116	43–437
CD19	545	614	136	182	124	55–472
NK (CD16/CD56)	211	103	120	185	110	82–596
T-cell subsets (cells/ μ l)						
CD4 Naïve	997	890	4	311	280	100–2300
CD4 Tregs	73	87	43	53	23	25–180
CD4 TCM	721	503	461	39	107	180–1100
CD4 TEM	404	335	59	123	41	13–220
CD4 TEMRA	23	15	0	1	1	0–68
CD8 Naïve	373	314	20	111	85	16–1000
CD8 TCM	227	49	146	39	6	40–640
CD8 TEM	172	140	53	96	21	40–60
CD8 TEMRA	27	38	2	20	4	25–280
B-cell subsets (%)						
B naïve	41.7	35.6	47.7	39.9	48	58–72.1
B unswitched	21.9	27.2	10	10.3	13	13.4–21.4
B switched	25.6	26	24.6	24.3	23.9	9.2–18.9
Myeloid lineage cells						
Neutrophils/ μ l	7100	7800	3500	3800	4300	3000–10,000
Red blood cell count $\times 10^6$ / μ l	4.07	4.01	3.87	3.89	3.85	4.00–5.40
Platelets/ μ l	198,000	236,000	205,000	208,000	275,000	150,000–450,000
Hemoglobin (g/dl)	13.2	13.2	12.3	12.9	12.4	12–15
Hematocrit (%)	38.5	38.2	37.7	37.9	36.9	34–46

TOFA was stopped at month 19 due to severe lymphopenia. BARI was started 6 weeks after TOFA withdrawal.

BARI, Baricitinib; CRP, C-reactive protein; ESR, erythrocyte sedimentation rate; NK, natural killer; TCM, Central Memory T-cells; TEM, Effector Memory T-cells; TEMRA, Effector Memory Recently Activated T-cells; TOFA, Tofacitinib; Tregs, regulatory T-cells.

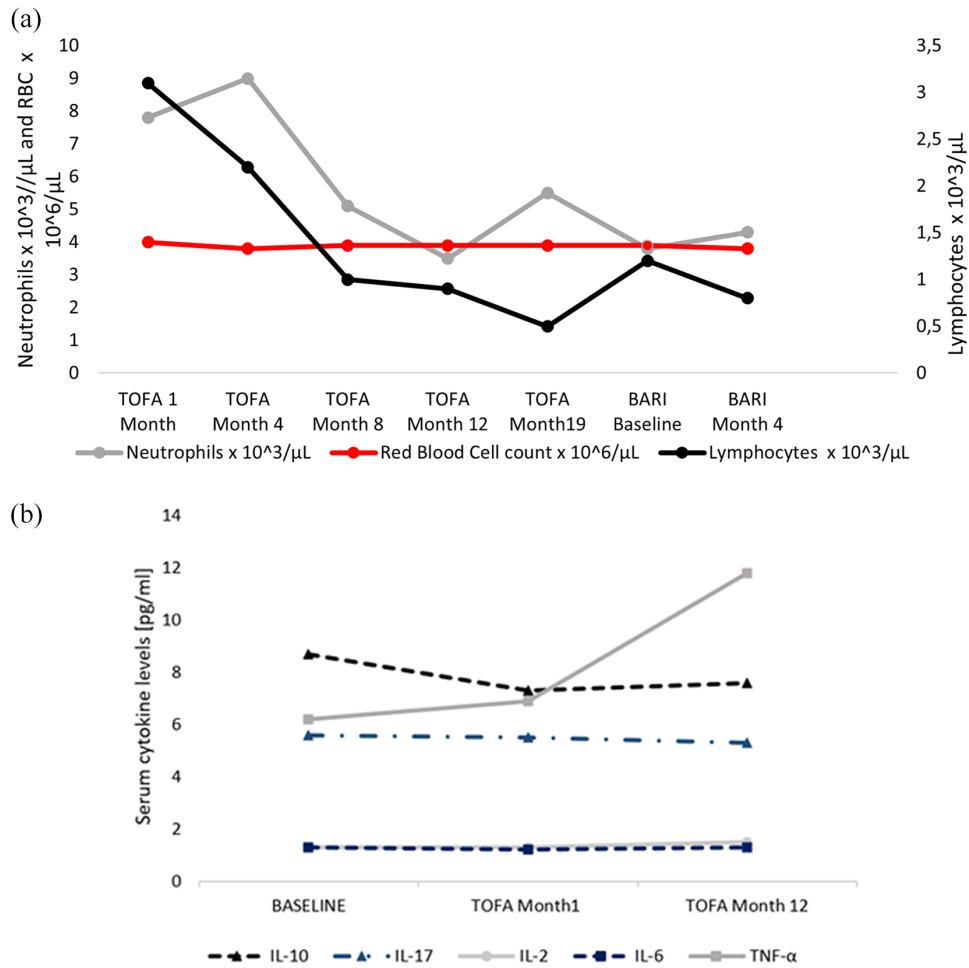


Figure 2. (a) Leukocytes, lymphocytes, and hemoglobin evolution through follow-up with Tofacitinib and Baricitinib therapy. (b) Cytokines evolution through follow-up with Tofacitinib.

progressively observed during follow-up with TOFA and during the first 4 months with BARI. The values of anti-CD3/28 (1 μl/500,000 cells) were normal [>0.7 (4×10^7 Dynabeads/ml)] before TOFA therapy and at 1 and 12 months after TOFA onset. They were assessed to evaluate the possible influence of JAKINIBS on the activation of T-lymphocytes through stimulation *via* the second signal (CD28). Both CD4 and CD8 Central Memory T-cells (TCM), Effector Memory T-cells (TEM), and Effector Memory Recently Activated T-cells (TEMRA) also suffered a progressive decrease after 12 months of treatment. The most remarkable change was observed in CD4+ and CD8+. Naïve cells showed a deep delayed reduction, falling under the normal range with TOFA.

Regarding the ALC, a drop to 500 cells/μl together with a clinical worsening forced to stop TOFA. Lymphocyte counts transiently increased during the 2 weeks of treatment with ADA and remained stable during BARI therapy. However, after 4 months of treatment with BARI, a new episode of lymphopenia (800 cells/μl) was observed (Figure 2(a)).

B-cell (CD19+) and NK cell counts remained within the reference range during follow-up. However, a mild decrease in cell count was observed. IgG, IgM, and IgA levels stayed within the reference range after 19 months of treatment with TOFA and 4 months of treatment with BARI. IgG levels increased (mainly IgG1 and IgG3), and IgM showed a small reduction.

Table 2. Review of the literature on uveitis treated with Janus kinase inhibitors.

Study (reference)	Center, country	Cases, n	Age, sex	Underlying disease	Janus kinase inhibitor	Uveitis pattern	Previous treatment	Evolution
Bauermann <i>et al.</i> ¹⁶	St. Franziskus Hospital, Muenster, Germany	1	22, female	Juvenile Idiopathic Arthritis	TOFA	Bilateral anterior uveitis, ME	MTX, ADA, RTX, GOL1, IFX, CsA, TCZ, MMF	Complete improvement
Paley <i>et al.</i> ¹⁷	Washington University, St. Louis, USA	1	45, female	Idiopathic	TOFA	Unilateral anterior uveitis, CME	MTX, LFN, AZA, MMF, ADA, IFX, CZP, FAIL	Complete improvement
Miserocchi <i>et al.</i> ¹⁸	G. Pini Center, Italy	4	9, female 1, female 2, female 10, male	Juvenile Idiopathic Arthritis	TOFA BARI BARI BARI	Bilateral, chronic panuveitis Bilateral, chronic panuveitis Bilateral, chronic panuveitis Unilateral, chronic panuveitis	IFX, ADA, LFN, ABA, RTX, TCZ MTX, ADA, IFX, RTX, ABA MTX, AZA, IFX, ADA, TCZ ETN, MTX, CsA, IFX, ADA, ABA, TCZ, RTX	Complete improvement Complete improvement Complete improvement Complete improvement
Dutta Majumder <i>et al.</i> ¹⁹	Apollo Hospital, Chennai, Tamil Nadu, India	1	26, female	Vogt-Koyanagi-Harada	TOFA	Bilateral	IVMP 1g/day × 5 days.	Complete improvement
Present study	Hospital Universitario Marqués de Valdecilla, Santander, Spain	1	25, female	Blau Syndrome	TOFA and BARI	Bilateral chronic panuveitis	MTX, ETN, ANA, ABA	Complete improvement

ABA, abatacept; ADA, adalimumab; ANA, anakinra; AZA, azathioprine; BARI, Baricitinib; CME, cystoid macular edema; CsA, cyclosporine A; CZP, certolizumab pegol; ETN, etanercept; FAIL, fluocinolone acetonide intravitreal implants; GOL1, golimumab; IFX, infliximab; IVMP, intravenous methylprednisolone; LFN, leflunomide; ME, macular edema; MMF, mycophenolate mofetil; MTX, methotrexate; RTX: rituximab; TCZ, tocilizumab; TOFA, Tofacitinib.

After 12 months of treatment with TOFA, IL-4 and TNF- α serum levels increased, whereas IL-2, IL-6, IL-10, and IL-17A did not modify their serum levels. Regarding cytokine levels after *in vitro* culture with anti-CD3/CD28 stimulation, IL-2 and IL-4 showed a marked reduction in their production, whereas IL-6, IL-10, IL-17A, and TNF- α levels increased in a significant way (Figure 2(b)).

Literature review

For literature review, a search was conducted in PubMed, Embase, and the Cochrane Library, from their inception to 31 July 2021, and conference proceedings from the four major rheumatology conferences. Original research articles on JAKINIBS in uveitis and sarcoidosis were included.

Table 2 summarizes the studies published on the use of JAKINIBS for the treatment of uveitis. Bauermann *et al.* were the first authors to describe

the successful use of TOFA in a case of severe refractory recurrent anterior uveitis and associated macular edema in an adult patient with JIA in 2018.¹⁶ In 2019, Paley *et al.*¹⁷ published the positive effect of TOFA in a case of idiopathic uveitis refractory to topical and local steroid injections and different disease-modifying antirheumatic drugs (DMARDs). The same group also reported a case of idiopathic scleritis remission using MTX and TOFA, achieving a steroid-sparing effect in both cases. A case series of four consecutive patients with long-term history of JIA and severe associated uveitis was published by Miserocchi *et al.*¹⁸ They observed a good response of ocular inflammation in all four cases. However, the articular disease did not respond adequately.

Dutta Majumder *et al.*¹⁹ reported a case of a young girl with exudative retinal detachment due to Vogt-Koyanagi-Harada disease that was steroid-resistant. One month after the initiation of TOFA, her visual acuity improved and fundus

Table 3. Review of the literature on sarcoidosis treated with Janus kinase inhibitors.

Study (reference)	Center, country	Cases	Age, sex	Sarcoidosis affection	Janus kinase inhibitor	Previous treatment	Evolution
Damsky <i>et al.</i> ¹¹	Yale School of Medicine, New Haven	4	48, female 34, male 68, female 66, female	Cutaneous Cutaneous Cutaneous Granuloma annulare	TOFA	HCQ, Minocycline, Tacrolimus, APR HCQ, ADA + MTX HCQ, Minocycline, MTX HCQ, PnbUVB, Doxycycline, CsA, 13-CRA	Complete improvement
Damsky <i>et al.</i> ²⁰	Yale School of Medicine, New Haven	1	60, female	Multiorgan	TOFA	Mycophenolate sodium, RTX, IVIG	Complete improvement
Levrault <i>et al.</i> ²¹	Universite Cote d'Azur, Nice, France	1	60, female	Refractory sarcoidosis-like systemic granulomatosis	RUXO	Antimicrobial therapy, HCQ, AZA, MMF, CP, MTX, TNF, interleukin 1b inhibitors	Complete improvement
Rotenberg <i>et al.</i> ²²	Avicenne Hospital, Bobigny, France	1	25, female	Multisystemic sarcoidosis	RUXO	MTX, AZA, LEF, INF, ADA	Complete improvement
Wei <i>et al.</i> ²³	University of Pennsylvania, Philadelphia	1	60, female	Cutaneous sarcoidosis Polycythemia	RUXO	Intralesional steroid injections, phlebotomies	Partial improvement

ADA, adalimumab; APR, apremilast; AZA, azathioprine; CP, cyclophosphamide; CsA, cyclosporine A; HCQ, hydroxychloroquine; INF, infliximab; IVIG, intravenous immunoglobulin; LEF, leflunomide; MMF, mycophenolate mofetil; MTX, methotrexate; PnbUVB: phototherapy (nbUVB); RTX, rituximab; RUXO, ruxolitinib; 13-CRA, isotretinoin; TNF, tumor necrosis factor; TOFA, Tofacitinib.

examination revealed resolution of exudative retinal detachment.

Regarding the usefulness of JAKINIBS for sarcoidosis, Damsky *et al.* were the first to describe the efficacy of TOFA in a patient with cutaneous sarcoidosis and afterward in multiorgan sarcoidosis.^{12,13,20} Other groups have published multiorgan and cutaneous sarcoidosis improvement after the initiation of ruxolitinib (RUXO), a JAK1 and JAK2 inhibitor¹² (Table 3). Other phase III trials are currently being conducted on cutaneous (NCT03910543) and systemic sarcoidosis (NCT03793439 and NCT02920710).

Discussion

To the best of our knowledge, we report for the first time the successful use of TOFA and then BARI in a patient with severe and refractory EOS/ sporadic BS. Remission was achieved with TOFA and was subsequently maintained with BARI when TOFA was discontinued due to severe lymphopenia.

As previously described, scarce evidence is available on the use of JAKINIBS in the treatment of uveitis and sarcoidosis. The reason for the use of

TOFA and BARI for treating our patient was based on the granulomatous nature of the disease. The activation of macrophages in the granuloma is considered to be dependent on CD4+ cells that secrete several cytokines such as IL-2 and TNF- α .^{3,24} JAK1 and JAK3 pathways are known to be constitutively active in sarcoidosis and other granulomatous diseases. TOFA inhibits JAK1, JAK3, and to a lesser extent JAK2, and BARI inhibits JAK1 and JAK2, thereby blocking the proinflammatory cytokine expression at sites of inflammation.²⁵

A dose-dependent mean decrease in ALCs was reported in TOFA-treated rheumatoid arthritis (RA) patients. This was also the case with our patient. Reductions in hemoglobin levels, hematocrit, and red blood cell counts could be explained by the inhibition of JAK2-dependent erythropoietin signaling.²⁶ Since lymphopenia has been associated with an increased risk of serious infections during TOFA treatment, evaluation of the ALC at baseline and monitoring every 3 months is recommended. Treatment with JAKINIBS should be interrupted if the ALC is 500 cells/ μ l.

TOFA partially and reversibly inhibits the signaling of IL-2, IL-4, IL-7, IL-9, and IL-15. These

cytokines are important for the development and proliferation of CD3+, CD19+, and NK cells. In RA patients treated with TOFA, a gradual decline to steady state of CD3+, CD4+, CD8+, and NK cell counts has been described. In contrast, CD19+ cell counts showed dose-dependent increases.²⁶ Cell-mediated immunity data suggest that TOFA does not significantly impair T-cell function. Noteworthy, CD4+ cell count did not fall below 200 cells/ μ l, which is known to be a risk factor for opportunistic infections.^{27,28}

Lymphopenia is a well-known analytical finding of TOFA. However, in both RA and atopic dermatitis, BARI has not been usually associated with a decrease in ALC. The decrease after 4 months of treatment with BARI could be due to lymphopenia associated with sarcoidosis or some other mechanism that is still unknown.

In patients with RA treated with TOFA, only slight decreases in serum IgG, IgM, and IgA levels are observed. This may be due to changes in disease activity rather than a direct effect on B-cell function.^{29,30} In fact, in the case of our patient, IgG levels increased (mainly IgG1, 3 and 4 subclasses), which could indicate that plasma cells resident in the bone marrow were not completely affected by the action of the treatment.

In conclusion, TOFA and then BARI were useful to achieve rapid and maintained clinical remission in a patient refractory to multiple lines of immunosuppressive therapy. Although these preliminary results are promising, further studies with larger series of patients and randomized clinical trials are needed to confirm our findings.

Author contribution(s)

Carmen Álvarez-Reguera: Formal analysis; Investigation; Methodology; Project administration; Supervision; Validation; Visualization; Writing – original draft; Writing – review & editing.

Diana Prieto-Peña: Investigation; Methodology; Supervision; Validation; Visualization; Writing – review & editing.

Alba Herrero-Morant: Investigation; Project administration; Supervision; Validation; Visualization; Writing – original draft; Writing – review & editing.

Lara Sánchez-Bilbao: Visualization; Writing – original draft; Writing – review & editing.

José Luis Martín-Varillas: Supervision; Visualization; Writing – original draft; Writing – review & editing.

Elena González-López: Investigation; Methodology; Supervision; Visualization; Writing – original draft; Writing – review & editing.

María Gutiérrez-Larrañaga: Formal analysis; Investigation; Methodology.

David San Segundo: Formal analysis; Investigation; Methodology.

Rosalía Demetrio-Pablo: Supervision; Validation; Visualization; Writing – review & editing.

Gonzalo Ocejo-Vinyals: Formal analysis; Investigation; Methodology; Supervision; Visualization; Writing – original draft; Writing – review & editing.

Miguel A. González-Gay: Conceptualization; Formal analysis; Investigation; Methodology; Project administration; Supervision; Validation; Writing – original draft; Writing – review & editing.

Ricardo Blanco: Conceptualization; Formal analysis; Investigation; Methodology; Resources; Supervision; Validation; Visualization; Writing – original draft; Writing – review & editing.

Conflict of interest statement

The authors declared the following potential conflicts of interest with respect to the research, authorship, and/or publication of this article: Professor Miguel A. González-Gay has received grants/research supports from Abbvie, MSD, Jansen, and Roche, and had consultation fees/participation in company sponsored speaker's bureau from Abbvie, Pfizer, Roche, Sanofi, and MSD. Dr Ricardo Blanco received grants/research supports from Abbvie, MSD, and Roche, and had consultation fees/participation in company sponsored speaker's bureau from Abbvie, Pfizer, Roche, Bristol-Myers, Janssen, Lilly, and MSD. Dr Carmen Álvarez-Reguera, Diana Prieto-Peña, Alba Herrero-Morant, Lara Sánchez-Bilbao, José Luis Martín-Varillas, Elena González-López, María Gutiérrez-Larrañaga, David San Segundo, Rosalía Demetrio-Pablo, and Gonzalo Ocejo-Vinyals have not declared financial disclosures.


Funding

The authors disclosed receipt of the following financial support for the research, authorship, and/or publication of this article: This work was

partially supported by Redes Temáticas de Investigación Cooperativa en Salud (RETICS) Program, RD16/0012 Red de Investigación en Inflamación y Enfermedades Reumáticas (RIER) from ISCIII from 'Instituto de Salud Carlos III' (ISCIII) (Spain).

ORCID iDs

Carmen Álvarez-Reguera  <https://orcid.org/0000-0003-4840-7961>

Miguel A. González-Gay  <https://orcid.org/0000-0002-7924-7406>

Ricardo Blanco  <https://orcid.org/0000-0003-2344-2285>

References

- Blau EB. Familial granulomatous arthritis, iritis, and rash. *J Pediatr* 1985; 107: 689–693.
- Chen J, Luo Y, Zhao M, *et al.* Effective treatment of TNF α inhibitors in Chinese patients with Blau syndrome. *Arthritis Res Ther* 2019; 21: 236.
- Wouters CH, Maes A, Foley KP, *et al.* Blau Syndrome, the prototypic auto-inflammatory granulomatous disease. *Pediatr Rheumatol Online J* 2014; 12: 33–39.
- van Duist MM, Albrecht M, Podswiadek M, *et al.* A new CARD15 mutation in Blau syndrome. *Eur J Hum Genet* 2005; 13: 742–747.
- Sfriso P, Caso F, Tognon S, *et al.* Blau syndrome, clinical and genetic aspects. *Autoimmun Rev* 2012; 12: 44–51.
- Kanazawa N, Okafuji I, Kambe N, *et al.* Early-onset sarcoidosis and CARD15 mutations with constitutive nuclear factor- κ B activation: common genetic etiology with Blau syndrome. *Blood* 2005; 105: 1195–1197.
- Kurokawa T, Kikuchi T, Ohta K, *et al.* Ocular manifestations in Blau syndrome associated with a CARD15/Nod2 mutation. *Ophthalmology* 2003; 110: 2040–2044.
- Jindal AK, Pilania RK, Suri D, *et al.* A young female with early onset arthritis, uveitis, hepatic, and renal granulomas: a clinical tryst with Blau syndrome over 20 years and case-based review. *Rheumatol Int* 2019; 41: 173–181.
- Lu L, Shen M, Jiang D, *et al.* Blau syndrome with good responses to Tocilizumab: a case report and focused literature review. *Semin Arthritis Rheum* 2018; 47: 727–731.
- Punzi L, Gava A, Galozzi P, *et al.* Blau syndrome. *Best Pract Res Clin Rheumatol* 2011; 25: 703–714.
- Damsky W, Thakral D, McGeary MK, *et al.* Janus kinase inhibition induces disease remission in cutaneous sarcoidosis and granuloma annulare. *J Am Acad Dermatol* 2020; 82: 612–621.
- Wang A, Singh K, Ibrahim W, *et al.* The promise of JAK inhibitors for treatment of sarcoidosis and other inflammatory disorders with macrophage activation: a review of the literature. *Yale J Biol Med* 2020; 93: 187–195.
- Damsky W, Thakral D, Emeagwali N, *et al.* Tofacitinib treatment and molecular analysis of cutaneous sarcoidosis. *N Engl J Med* 2018; 379: 2540–2546.
- Milman N, Andersen CB, Hansen A, *et al.* Favourable effect of TNF- α inhibitor (infliximab) on Blau syndrome in monozygotic twins with a de novo CARD15 mutation. *APMIS* 2006; 114: 912–919.
- Gagnier JJ, Kienle G, Altman DG, *et al.* The CARE guidelines: consensus-based clinical case reporting guideline development. *BMJ Case Rep* 2013; 2: 38–43.
- Bauermann P, Heiligenhaus A and Heinz C. Effect of Janus kinase inhibitor treatment on anterior uveitis and associated macular edema in an adult patient with juvenile idiopathic arthritis. *Ocul Immunol Inflamm* 2019; 27: 1232–1234.
- Paley MA, Karacal H, Rao PK, *et al.* Tofacitinib for refractory uveitis and scleritis. *Am J Ophthalmol Case Rep* 2019; 13: 53–55.
- Miserocchi E, Giuffrè C, Cornalba M, *et al.* JAK inhibitors in refractory juvenile idiopathic arthritis-associated uveitis. *Clin Rheumatol* 2020; 39: 847–851.
- Dutta Majumder P, Shah A and Kaushik V. Tofacitinib in Vogt-Koyanagi-Harada disease. *Indian J Ophthalmol* 2020; 68: 1938–1939.
- Damsky W, Young BD, Sloan B, *et al.* Treatment of multiorgan sarcoidosis with Tofacitinib. *ACR Open Rheumatol* 2020; 2: 106–109.
- Levrant M, Martis N, Viau P, *et al.* Refractory sarcoidosis-like systemic granulomatosis responding to ruxolitinib. *Ann Rheum Dis* 2019; 78: 1606–1607.
- Rotenberg C, Besnard V, Brillet P, *et al.* Dramatic response of refractory sarcoidosis under ruxolitinib in a patient with associated JAK2-mutated polycythemia. *Eur Respir J* 2018; 52: 1801482.
- Wei JJ, Kallenbach LR, Kreider M, *et al.* Resolution of cutaneous sarcoidosis after Janus kinase inhibitor therapy for concomitant polycythemia vera. *JAAD Case Rep* 2019; 5: 360–361.

24. Aróstegui JI, Arnal C, Merino R, *et al.* NOD2 gene-associated pediatric granulomatous arthritis: clinical diversity, novel and recurrent mutations, and evidence of clinical improvement with interleukin-1 blockade in a Spanish cohort. *Arthritis Rheum* 2007; 56: 3805–3813.
25. Hodge JA, Kawabata TT, Krishnaswami S, *et al.* The mechanism of action of Tofacitinib – an oral Janus kinase inhibitor for the treatment of rheumatoid arthritis. *Clin Exp Rheumatol* 2016; 34: 318–328.
26. Strober B, Buonanno M, Clark JD, *et al.* Effect of Tofacitinib, a Janus kinase inhibitor, on haematological parameters during 12 weeks of psoriasis treatment. *Br J Dermatol* 2013; 169: 992–999.
27. Winthrop KL, Korman N, Abramovits W, *et al.* T-cell-mediated immune response to pneumococcal conjugate vaccine (PCV-13) and tetanus toxoid vaccine in patients with moderate-to-severe psoriasis during Tofacitinib treatment. *J Am Acad Dermatol* 2018; 78: 1149–1155.
28. Valenzuela F, Papp KA, Pariser D, *et al.* Effects of Tofacitinib on lymphocyte sub-populations, CMV and EBV viral load in patients with plaque psoriasis. *BMC Dermatol* 2015; 15: 8.
29. Boyman O, Létourneau S, Krieg C, *et al.* Homeostatic proliferation and survival of naïve and memory T cells. *Eur J Immunol* 2009; 39: 2088–2094.
30. Boyman O, Krieg C, Homann D, *et al.* Homeostatic maintenance of T cells and natural killer cells. *Cell Mol Life Sci* 2012; 69: 1597–1608.

Visit SAGE journals online
[journals.sagepub.com/
home/tab](http://journals.sagepub.com/home/tab)

 SAGE journals