

# Primary percutaneous coronary intervention of great saphenous vein grafts in a patient with central and peripheral artery disease – how to approach?

**Luka Mitar<sup>1,\*</sup>,**  
**Zvonimir Ostojić<sup>1,2</sup>,**  
**Kristina Marić Bešić<sup>1,2</sup>,**  
**Joško Bulum<sup>1,2</sup>**

<sup>1</sup>School of Medicine,  
University of Zagreb, Zagreb,  
Croatia

<sup>2</sup>University Hospital Centre  
Zagreb, Zagreb, Croatia

**KEYWORDS:** ST elevation myocardial infarction, primary coronary intervention, great saphenous vein, thrombectomy, covered stents.

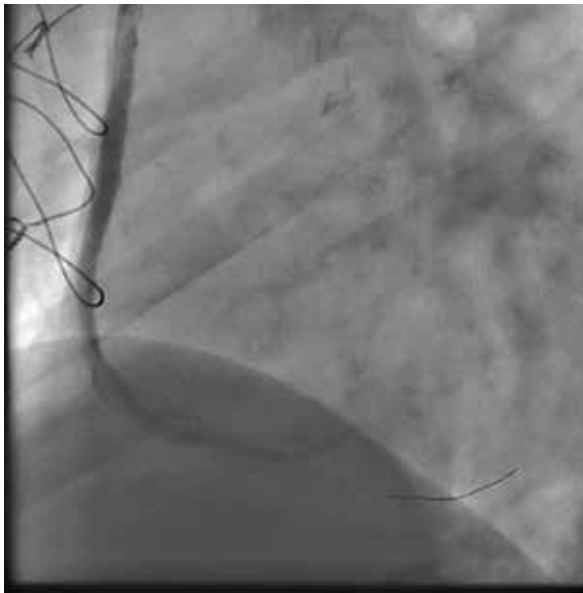**CITATION:** *Cardiol Croat.* 2023;18(3-4):63-4. | <https://doi.org/10.15836/ccar2023.63>

**\*ADDRESS FOR CORRESPONDENCE:** Luka Mitar, Medicinski fakultet, Šalata 3, HR-10000 Zagreb, Croatia. /  
Phone: +385-99-5738-982 / E-mail: [lukamitar25@gmail.com](mailto:lukamitar25@gmail.com)

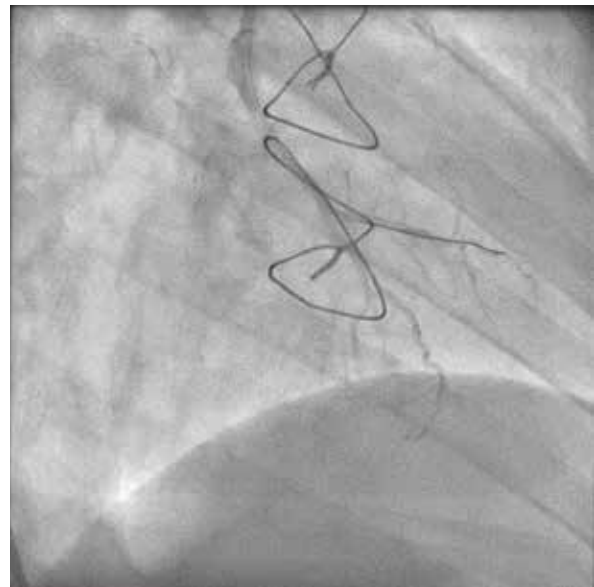
**ORCID:** Luka Mitar, <https://orcid.org/0000-0002-6765-2447> • Zvonimir Ostojić, <https://orcid.org/0000-0003-1762-9270>  
Kristina Marić Bešić, <https://orcid.org/0000-0002-4004-7271> • Joško Bulum, <https://orcid.org/0000-0002-1482-6503>

**Introduction:** Primary percutaneous coronary intervention (PCI) of great saphenous vein (VSM) graft remains a challenge due high thrombotic burden causing poor acute and long-term angiographic results<sup>1</sup>. Several strategies have been proposed for such cases, such as deferred stenting, covered stents and distal protection devices, all with unsatisfactory results.

**Case report:** 68-year-old male with multiple cardiovascular risk factors, known coronary artery disease (CAD) treated with PCI on left anterior descending artery (LAD) in 2007. and two VSM coronary-artery bypass grafts (CABG) on right coronary artery (RCA) and left circumflex artery (LCX) in 2008. has presented with inferior ST elevation myocardial infarction (STEMI) in 2016 due to thrombotic occlusion of VSM on RCA. Despite multiple successful thrombectomies, three covered stents (MGuard, all 3.5 mm) had to be implanted. Additionally, one 5.0 mm bare metal stent (BMS) has been implanted in severe stenosis proximal to the occlusion. During the entire intervention, two boluses of eptifibatid were given, with the final thrombolysis in myocardial infarction (TIMI 2)



**FIGURE 1.** The final result after primary percutaneous coronary intervention of vena saphena magna coronary artery bypass graft thrombosis on right coronary artery treated with 3 covered stents (MGuard, all 3.5 mm) and 1 bare metal stent (5.0 mm). Post procedure thrombolysis in myocardial infarction flow 2 was achieved.



**FIGURE 2.** The final result after primary percutaneous coronary intervention of vena saphena magna coronary artery bypass graft thrombosis on the second obtuse marginal artery after treatment with eptifibatid and thrombectomy followed with implantation of a drug-eluting stent (4.0 mm). Bypass attachment to the obtuse marginal artery was further dilatated with a 2.5 mm balloon due to immense distal embolization in the native arteries, yielding limited success.

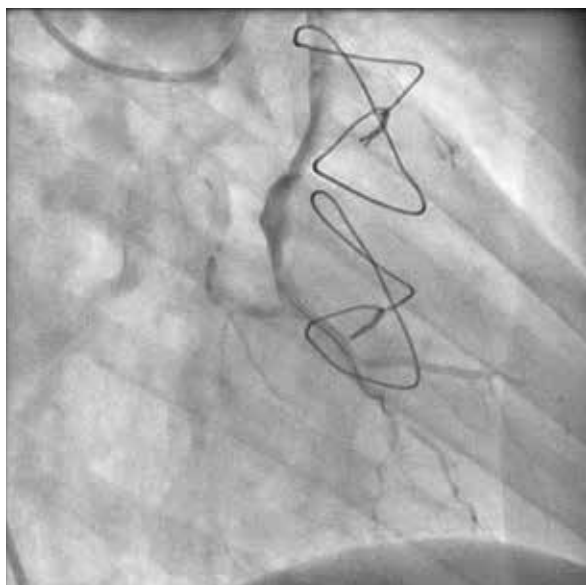
**RECEIVED:**  
February 17, 2023

**ACCEPTED:**  
February 22, 2023

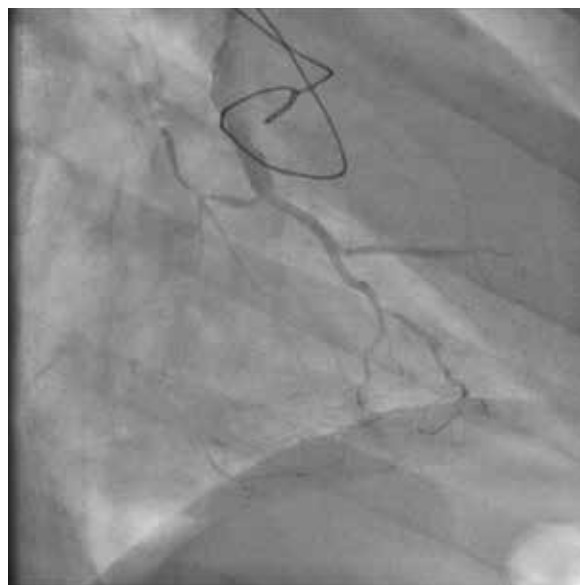

## Primary percutaneous coronary intervention of great saphenous vein grafts in a patient with central and peripheral artery disease – how to approach?

flow achieved (**Figure 1**). The LAD and VSM on second obtuse marginal artery (OM2) were patent, while LCX has been occluded. In 2020 the patient was treated for limb ischemia with combined surgical thrombectomy and percutaneous intervention. The patient again presents in 2022 with infero-postero-lateral STEMI. Emergent coronarography revealed occluded VSM on RCA and OM2, with patent LAD. The occlusion of VSM on RCA was tackled first without successfully recanalizing the artery after a few minutes. The PCI of VSM on OM2 immediately followed. After recanalization of the VSM, eptifibatide boluses were given, followed by thrombectomy, predilatation and one drug-eluting stent (DES) implantation (4.0 mm). Due to immense distal embolization in native arteries, VSM attachment on LCX has been dilatated with a 2.5 mm balloon with only modest success. The further intervention was deferred for the next day while the patient was placed on continuous eptifibatide infusion (**Figure 2**). The strategy resulted in modest flow improvement. On the second intervention, VSM attachment has again been dilated with a 3.0 mm balloon, and an additional 4.5 mm DES was implanted in stenosis proximal to the culprit lesion (**Figure 3**). Eptifibatide has been continued for additional 24 hours. At 3 months follow-up, the patient was free of symptoms, and coronarography revealed no signs of restenosis with better flow distally (**Figure 4**).



**FIGURE 3.** The final result of after 24 hours of eptifibatide infusion and additional dilation with a 3.0 mm balloon. Improved flow in native coronary arteries has been achieved.



**FIGURE 4.** Coronarography performed on 3 months follow-up revealed no signs of restenosis with better flow distally.

**Conclusion:** Although covered stents and deferred stenting provide satisfactory acute results after primary PCI of VSM, their long-term results remain uncertain.

### LITERATURE

1. Lee MS, Park SJ, Kandzari DE, Kirtane AJ, Fearon WF, Brilakis ES, et al. Saphenous vein graft intervention. *JACC Cardiovasc Interv.* 2011 Aug;4(8):831-43. <https://doi.org/10.1016/j.jcin.2011.05.014>