

Prompt Reversing the Neurologic and Cardiac Manifestations of Valproate Poisoning by Hemodialysis: A Case Report

Ahmad Nemati (MD)¹, Farkhonde Nikkhah (MD)², Mohammad Moshiri (MD)³, Hanie Salmani Izadi (MD)¹,
Leila Etemad

¹ Student Research Committee, Faculty of Medicine, Mashhad University of Medical Sciences, Mashhad, Iran.

² Medical Student, Mazandaran University of Medical Sciences, Mazandaran, Iran.

³ Assistant Professor, MD, PhD in Toxicology, Medical toxicology research center, faculty of Medicine. Mashhad University of Medical Sciences, Mashhad, Iran.

⁴ Assistant Professor, PhD in Toxicology, Pharmaceutical Research Center, Pharmaceutical Technology Institute, Mashhad University of Medical Sciences, Mashhad, Iran

ARTICLE INFO

Article type

Case report

Article history

Received: 23 Oct 2022

Revised: 10 Nov 2022

Accepted: 20 Dec 2022

Keywords

Hemodialysis

Valproate Poisoning

Cardiac Manifestations

Neurologic Manifestations

ABSTRACT

SV (sodium valproate) is an antiepileptic drug that is often prescribed for epilepsy, bipolar disorders, and migraine. We reported an SV intoxicated case that cardiac and neurologic abnormalities were promptly responded to hemodialysis (HD). She ingested a large amount of SV (150 pills of SV 200mg) for a suicide attempt. She was initially alert but her Glasgow coma scale (GCS) decreased to 6 thought 11 hours. However, valproate (>150mg/l) and ammonia serum (164µg/dL) levels were not excessively elevated. The serial electrocardiography (ECG) showed QT prolongation and a sign of sodium channel block such as dominant R wave in AVR lead and T-wave inversion in the precordial leads. She had low level of calcium and potassium serum levels. Supportive treatment, charcoal, and L-carnitine, were not effective and HD was started due to the resistant cardiac and neurologic symptoms. After a 3-hour HD session, decreased GCS, pathological ECG findings, and laboratory abnormalities dramatically disappeared. In conclusion, HD is an effective and rapid response treatment for Valproate-induced loss of consciousness and life-threatening cardiac abnormality.

Please cite this paper as:

Nemati A, Nikkhah F, Moshiri M, Salmani Izadi H, Prompt Reversing the Neurologic and Cardiac Manifestations of Valproate Poisoning by Hemodialysis: A Case Report. *Rev Clin Med.* 2022;9(4): 181-185.

Introduction

Sodium Valproate (SV) is used to treat complex partial seizures, simple and complex absence seizures, migraines, bipolar mania, and schizoaffective disorders. The mechanism of action of SV have included blockage of Voltage-gated-sodium-channel and increasing level of gamma-aminobutyric acid (GABA) in central nervous system (CNS)(1). There have been numerous reports of abuse with high dosage of SV for suicide attempts. SV toxicity

could be presented with vomiting, agitation, tremors and palpitation. It also can cause some life-threatening side effects such as hepatotoxicity, respiratory depression, encephalopathy, cerebral edema and cardiac arrhythmia. Laboratory findings may include metabolic acidosis, electrolyte abnormalities, hyperammonemia and abnormal liver function tests (1,2).

Initial treatment for the SV intoxicated patient

***Corresponding author:** Leila Etemad,
Pharmaceutical Research Center, Pharmaceutical Technology Institute,
Mashhad University of Medical Sciences, Mashhad, Iran
E-mail: Etemadl@mums.ac.ir
Tel: 09153161466

This is an Open Access article distributed under the terms of the Creative Commons Attribution License (<http://creativecommons.org/licenses/by/3.0>), which permits unrestricted use, distribution, and reproduction in any medium, provided the original work is properly cited.

is mainly supportive in the majority of cases. It includes maintenance of airway, O₂ therapy, intravenous fluid therapy, gastric lavage, multiple doses activated charcoal (MDAC) and administration of L-carnitine or naloxone. If the patient does not respond to the treatment or the level of consciousness is severely decreased, it is recommended to use hemodialysis (HD) (3,4). We reported an interesting case of SV intoxicated woman with electrocardiogram changes and severe encephalopathy that did not match by levels of serum ammonia and serum valproate. It performed treatment with HD and her neurologic and cardiac manifestations promptly responded to HD.

Case presentation

She was a 17-year-old woman who was brought to Emam Reza hospital's toxicology ward affiliated to Mashhad University of Medical Sciences (MUMS) after a suicide attempt with ingestion of 150 pills of Sodium Valproate 200mg in several swallows 2 hours ago. This was the first suicide attempt that she committed after arguing with her family. She has been diagnosed with bipolar disorder since 3 years ago and had been treated with SV and benzodiazepine. On presentation, she had complained of nausea and dizziness. On physical examination she was aggressive and agitated with a Glasgow coma scale (GCS) 14/15 because of not following commands. Other physical examinations were unremarkable except tachycardia.

Her vital sign included: heart rate= 120 beat /min, blood pressure=110/70 mmHg, respiratory rate= 18 cycle/min, temperature= 36.6°C and SpO₂ = 95%.

Initially, she received 2 mg of Midazolam to control her agitation. She was instructed "Nothing by mouth" except medication. She was also treated by maintenance intravenous fluids and electrolytes. She received 50 g activated charcoal and appropriate laxative that was repeated every 4 hours in half doses. Intravenously 40mg pantoprazole for stress ulcer prophylaxis was administered as well.

Due to history of SV intoxication, she received 3000 mg of oral L-carnitine. Unfortunately, intravenous L-carnitine was not available in Iran at that time. Her lab test results showed low serum calcium level (table 1) and mild hypokalemia with high normal serum sodium level.

On admission (2 hours after ingestion) Electrocardiography (ECG) showed sinus tachycardia, with prolonged corrected QT (QTc)= 500 ms, and dominant R (R/S=1) wave in AVR lead (figure 1). Due to low calcium level, 10g calcium gluconate was infused through 1 hour. Four hours later (6 hours after ingestion), her ECG revealed T-wave inversion in precordial leads and QTc =540ms. So, she received 2gr of magnesium sulfate intravenously and 20 mEq potassium was added to each liter of maintenance fluid to reduce the risk of torsade de pointes. However, the QTc prolongation (500ms) did not completely resolve. Her serum troponin I level was normal (table 1).

Table 1: Laboratory tests results of Valproate intoxicated woman referred to Emam Reza hospital's toxicology ward

tests	unite	Reference Value	Time After ingestion								
			4	10	12	17	30	37	45	52	
Ammonia	µg/dL	<82	62				164			35	
White Blood cell	10 ³ /µL	4.4-11.3	8.5								
PMN	%	45-73	61.6%								
Lymph	%	20-45	34.8%								
Haemoglobin	g/dl	12.3-15.3	12.3								
Haematocrit	%	36-45	39.2								
Platelet count	10 ³ /µL	150-450	222								
Sodium	mEq/L	135-145	146			145		144			147
Potassium	mEq/L	3.5-5.3	3.8			3.2		3.7			3.6
Calcium	Mg/dL	8.5-10.5	8.6			7.1		7.0			
Magnesium	Mg/dL	1.7-2.7	2.2			2.8		2.8			
Blood sugar	Mg/dL		80								
Urea	Mg/dL	17-45	12								
Creatinine	Mg/dL	0.6-1.3	0.8								
Aspartate transaminase	U/L	5-40	21.7								
Alanine Transaminase	U/L	5-40	11.6								
Alkaline Phosphatase	U/L	<258	98								
Total Bilirubin	Mg/dL	<1.1	0.3								
Direct Bilirubin	Mg/dL	<0.4	0.1								
C-reactive protein	Mg/L	0-6									
Troponin I	Pg/ml	< 17.5									
PT	Second	11-13	12.6								
INR		0.8-1.2	1.05								
PTT	Second	23-32	27								
PH		7.35-7.45	7.32					7.29			
PCO ₂	mmHg	35-45	47.7					36.8			

HCO ₃	mEq/L	22-28	24.7	18.0	28.5	24.5	25.3
Base Excess	Mmol/L	-2 to +2	-1.5	-7.5	6.6	1.1	4
Base buffer	Mmol/L		46.3	39.4	52.5	48.1	50.2
B-HCG			negative				
Amylase		<80			46		
Serum Acetaminophen	Mg/l			<10			
Serum salicylate level	Mg/l	100-300		ND			
Serum Valproate level	mg/l	50-125	>150		144		27
Serum Ethanol	Mg/dl	<10		<10			
Serum methanol	Mg/dl	<3		1.2			
Urine Cannabis				ND			
Urine Buprenorphine				ND			
Urine Methadone				ND			
Urine Morphine				ND			
Urine Tramadol				ND			
Urine cocaine				ND			
Urine amphetamine				ND			
Urine tricyclic antidepressant				ND			
Urine phenothiazine				ND			

Ethanol was detected by Enzyme assay Method , Methanol was evaluated by colorimetric method
PT= Prothrombin time , PTT= Partial Thromboplastin Time , ND= Not detected

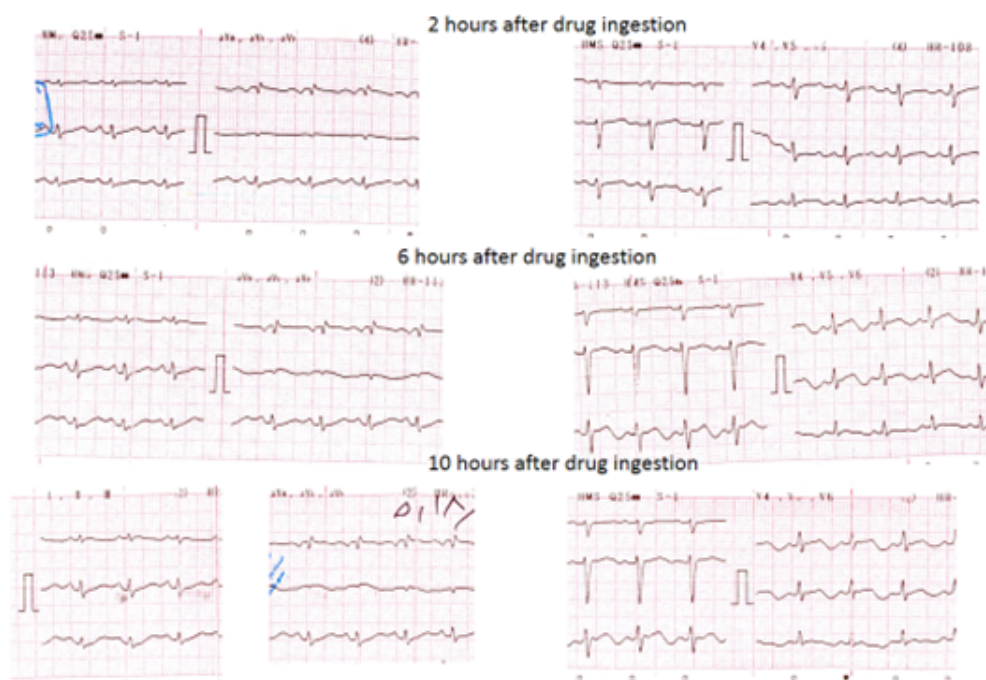


Figure 1: Electrocardiograms of Valproate intoxicated woman referred to Emam Reza hospital's toxicology ward

However, she was alert at presentation, the level of consciousness was reduced through 3 hours (5 hours after ingestion) and she became obtunded and she only responded to sternal rub. Her GCS decreased to 10/15. Administration of 2mg Naloxone intravenously could not change in the level of consciousness.

At 4 hours after ingestion, the Valproate serum level was > 150 mg/L (therapeutic range=100-150 mg/L) and serum ammonia level was 164 µg/dL. Approximately in 8 hours after admission, she didn't respond to sternal rub anymore and her GCS dropped to 6/15.

Therefore, the patient immediately performed tracheal intubation and mechanically ventilate, and she became candidate to hemodialysis (HD). In 11 hours after the presentation, she performed HD. HD was initiated with a dialysis machine (hemodialysis machine Gambro AK95) via an internal jugular venous catheter for 3 hours.

Dialysis was done with a dialysate flow rate of 500 ml/min and a blood flow rate of 250 ml/min. Also, 3-liter ultrafiltration was performed. During hemodialysis, she received 2500 units of heparin to reduce coagulation. Bicarbonate was used as a dialysate buffer. Dialysate sodium concentration

was 106 mEq/L. During HD, systolic blood pressure was above 92 mmHg. After 3 hours dialysis, dramatically her conscious raised. However, she was confused, she opened her eyes to speech and localized pain and her GCS raised to 12/15. The all ECG abnormality of patients was resolved as well. She was self-extubated.

After hemodialysis, chemistry abnormalities were resolved. The serum ammonia and valproate levels became normal. However, the. The patient had further monitoring toxicity evaluations and treatment in the toxicological department and oral L-carnitine and other supportive therapy were continued. After 3 days adequate clinical and paraclinical improvement was achieved completely. She was transferred to a psychiatric ward for further management and monitoring.

Discussion

We reported a valproate intoxication case that her neurologic and cardiac abnormalities were promptly obviated by HD. Decreasing level of consciousness and ECG abnormalities were progressing rapidly and were resistant to supportive treatment.

Valproate induced encephalopathy is not very common (14%) and one multicenter case series reported that very high concentrations of serum valproate (>850 microgram/ml) were associated with coma (5). Although, the current case had decreased level of consciousness with not too much elevated valproate serum (>150 microgram/ml) and ammonia concentrations (162 μ /dL). Similarly, a case was presented with a non-hyperammonemia encephalopathy(6).

Valproate induced encephalopathy could be related to some valproates metabolites that was not measured in the serum of the case (7). Also, acidosis, electrolyte abnormality, cardiac arrhythmia may cause altered consciousness (8). However, she had not sever abnormality.

In the current patient, ECG showed tachycardia, QT prolongation, T-wave inversion in precordial leads, and dominant R wave in AVR lead. Similarly, Tachycardia is a common sign in SV toxicity.

Also, massive overdose can cause tachyarrhythmia, heart block and QT prolongation (9). SV blocked the neuronal sodium channel through binding to the batrachotoxin-binding site (or adjacent area) on alpha subunits of Na⁺ channels.(10) However this binding is highly selective in therapeutic concentration, at toxic concentration the selectivity of SV to sodium channel reduces and sodium channels of cardiac tissue may be blocked, such as happened in the current cases (11).

The case reports showed QTc prolongation occurred in higher concentration (9) specially in concentration over 450mg/l which could induce

hypocalcemia(12). Although SV concentration of current patients 5 hours after ingestion was >150mg/L. She had low levels of calcium and potassium, as well. Her EKG showed QTC prolongation that was not resolved by correction of potassium and calcium and administration of magnesium. It was promptly responded to HD.

It is not clear whether this immediate response was due to the electrolyte disturbances correction by HD or some other factors. In our patient the recorded EKG after HD showed that all of the pathological changes were resolved. QT prolongation concomitant with electrolytes abnormalities were corrected completely after HD.

Similarly, a case reported that HD considered to be effective in correcting QT interval for 100 ms. Moreover, tachycardia was resolved after HD similar to a case report with atrial tachycardia that was treated by HD (9).

Some studies emphasized the role of L-carnitine and naloxone in some patients' recovery such as clinical symptoms and mental status (13,14). In current case administration of 2mg intravenous naloxone could not make any change in decreased level of GCS. L-carnitine administration, also, can reduce the level of ammonium and risk of encephalopathy. It is recommend to be administrated intravenously (3).

Intravenous L-carnitine is not available in Iran. Therefore, the patient received a single dose of 3g oral L-carnitine orally, without any changes in the patient's state of consciousness and the serum ammonia level as well, and she was deteriorated in next hours. Due to treatment resistance symptoms and decreasing consciousness, she had a HD for 3 hours in about 11 hours after presentation. Her cardiac, GCS and biochemical abnormalities responded dramatically to a single HD session. HD has an important effect in large valproate overdose and resistant to treatment (15). HD increases elimination of SV not bounded to protein from the blood and reduces the half-life to 2.5 hours (16,17).

Some authors suggest that intermittent HD or continuous renal replacement therapy (CRRT) can be used in SV intoxication until serum valproate level is reduced to 50 to 100 mg/L or exhibit the clinical improvement evidences such as normal hemodynamic status, improved mental status and normalizing acid-base and electrolyte abnormalities (3). However, clinical manifestations of the case were normalized after just a single HD session, the SV concentration was still upper than 100mg/l.

Conclusion

HD is an effective and rapid response treatment for Valproate-induced loss of consciousness and life-threatening cardiac abnormality.

References

1. Etemad L, Moshiri M, Moallem SA. Epilepsy drugs and effects on fetal development: Potential mechanisms. *J Res Med Sci*. 2012;17:876-881.
2. Vidaurre J, Gedela S, Yarosz S. Antiepileptic Drugs and Liver Disease. *Pediatr Neurol*. 2017;77:23-36.
3. Patel AR, Nagalli S. Valproate Toxicity [Updated 2021 Jul 26]. Available from: <https://www.ncbi.nlm.nih.gov/books/NBK560898/>. StatPearls [Internet]. Treasure Island (FL): StatPearls Publishing; 2021.
4. Ghannoum M, Laliberte M, Nolin TD, et al. Extracorporeal treatment for valproic acid poisoning: systematic review and recommendations from the EXTRIP workgroup. *Clin Toxicol (Phila)*. 2015;53:454-465.
5. Spiller HA, Krenzelok EP, Klein-Schwartz W, et al. Multicenter case series of valproic acid ingestion: serum concentrations and toxicity. *Journal of toxicology Clinical toxicology*. 2000;38:755-760.
6. Farooq O, Zunga PM, Dar MI, et al. Non-Hyperammonemic valproate encephalopathy. *Annals of neurosciences*. 2014;21:76-79.
7. Silva ME, Aires CC, Luis PB, et al. Valproic acid metabolism and its effects on mitochondrial fatty acid oxidation: a review. *J Inherit Metab Dis*. 2008;31:205-216.
8. Segura-Bruna N, Rodriguez-Campello A, Puente V, et al. Valproate-induced hyperammonemic encephalopathy. *Acta Neurol Scand*. 2006;114:1-7.
9. Ray S, Skellett S. Valproate toxicity in a child: two novel observations. *Clinical Toxicology*. 2013;51:60.
10. Rogawski MA, Loscher W, Rho JM. Mechanisms of Action of Antiseizure Drugs and the Ketogenic Diet. *Cold Spring Harb Perspect Med*. 2016;6.
11. Doyon S. Antiepileptics. In: Hoffman RS, Howland MA, Lewin NA, Nelson LS, Goldfrank LR, editors. *Goldfrank's Toxicologic Emergencies*, 10e. 10 ed: McGraw Hill; 2019. p. 770-783.
12. Kazim S, Mohindra R, Gosselin S, et al. QTc prolongation and valproate toxicity. *Clin Toxicol (Phila)*. 2013;51:193.
13. Wadzinski J, Franks R, Roane D, et al. Valproate-associated hyperammonemic encephalopathy. *Journal of the American Board of Family Medicine : JABFM*. 2007;20:499-502.
14. Alberto G, Erickson T, Popiel R, et al. Central nervous system manifestations of a valproic acid overdose responsive to naloxone. *Annals of emergency medicine*. 1989;18:889-891.
15. Nasa P, Sehwat D, Kansal S, et al. Effectiveness of hemodialysis in a case of severe valproate overdose. *Indian J Crit Care Med*. 2011;15:120-122.
16. Bunchman TE, Ferris ME. Management of toxic ingestions with the use of renal replacement therapy. *Pediatr Nephrol*. 2011;26:535-341.
17. Kane SL, Constantiner M, Staubus AE, et al. High-flux hemodialysis without hemoperfusion is effective in acute valproic acid overdose. *The Annals of pharmacotherapy*. 2000;34:1146-1151.