



A Rare Case of Paraneoplastic Syndrome *Nadir Bir Paraneoplastik Sendrom Olgu Sunumu*

• Tuğçe Akçadağ¹, • Muammer Korkmaz², • Yasemin Ünal³, • Özgür Tanrıverdi⁴, • Semai Bek¹, • Gülnihal Kutlu¹

¹Mugla Sitki Kocman University Faculty of Medicine, Department of Neurology, Mugla, Türkiye

²Mugla Training and Research Hospital, Clinic of Neurology, Mugla, Türkiye

³Bandırma Onyedli Eylul University Faculty of Medicine, Department of Neurology, Balıkesir, Türkiye

⁴Mugla Sitki Kocman University Faculty of Medicine, Department of Medical Oncology, Mugla, Türkiye

Keywords: Zic4 antibody, paraneoplastic, paraneoplastic syndrome, limbic encephalitis

Anahtar Kelimeler: Zic4 antikoru, paraneoplastik, paraneoplastik sendrom, limbik ensefalit

Dear editor,

Paraneoplastic neurological syndromes affect different parts of the nervous system and may present as limbic encephalitis, subacute cerebellar degeneration, and neuronopathies. Paraneoplastic neurological syndromes might occur months or even years before the apparent diagnosis of cancer. Detecting a tumor supports paraneoplastic disease, although antibodies cannot be found in every case (1).

Early diagnosis of rapidly progressive dementia and immediate treatment may positively affect the disease's prognosis. Although prion disease is the prototype of rapidly progressive dementia, vascular, infectious, metabolic, toxic, neoplastic, iatrogenic, neurodegenerative, vasculitic, systemic, and autoimmune etiologies can also cause be a cause (2).

The 77-year-old male discussed here was diagnosed with small cell lung cancer and adenocarcinoma. At his follow-up, he presented with progressive cognitive impairment and was positive for Zic4 antibodies. He was referred to our clinic with complaints of amnesia for 20 days, including confusion with telephone numbers and rooms of his house. He was diagnosed with prostate adenocarcinomas four years ago. Small cell lung cancer and bone metastasis four months ago. His neurological examination was normal except for his orientation in space and time. His routine

blood biochemistry tests were normal except for vitamin B12: 144 pg/ml (197–771 pg/ml). His electroencephalography record was within normal limits, as well as his brain magnetic resonance imaging (Figure 1). Protein 51.5 mg/dl (15–45 mg/dl), glucose 51 mg/dl (40–70 mg/dl). 164 leukocytes were found in his cerebrospinal fluid (CSF) microscopic examination. Percent of 96.4% these leukocytes were in mononuclear morphology. Ceftriaxone 2 x 2 g/day and acyclovir 3 x 750 mg/day treatment were initiated with a prediagnosis of encephalitis. His CSF polymerase chain reaction (PCR) panel (herpes simplex virus 1 and 2, mumps, varicella zoster, enterovirus, parechovirus) was negative. Zic4 antibody was positive in his serum paraneoplastic panel (Figure 2). On the 12th day, 1 g of intravenous methylprednisolone was started and continued daily for five days. After the steroid treatment, 125 g of intravenous immunoglobulin (IVIg) was administered over five days as the patient weighed only 62.5 kg. After the steroid and IVIg treatments, the patient was transferred to the oncology service for the treatment of his primary disease.

Paraneoplastic neurological syndromes manifest by the involvement of parts of the nervous system. Paraneoplastic syndromes may occur in patients diagnosed with cancer or as the first finding in patients not yet diagnosed with cancer (3).

Paraneoplastic syndromes may affect the peripheral nervous system as well as present as limbic encephalitis, subacute cerebellar

Address for Correspondence/Yazışma Adresi: Tuğçe Akçadağ MD, Mugla Sitki Kocman University Faculty of Medicine, Department of Neurology, Mugla, Türkiye

Phone: +90 537 794 00 22 E-mail: tugceakcadag@gmail.com ORCID: orcid.org/0000-0002-0608-4212

Received/Geliş Tarihi: 28.03.2022 **Accepted/Kabul Tarihi:** 31.07.2022

©Copyright 2023 by Turkish Neurological Society
Turkish Journal of Neurology published by Galenos Publishing House.

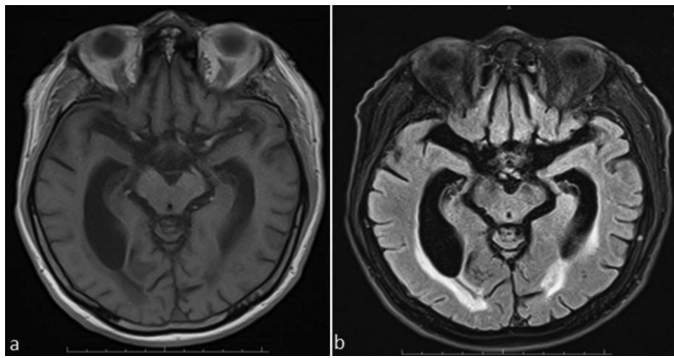


Figure 1. T1-weighted and fluid-attenuated inversion recovery brain magnetic resonance imaging were consistent with cortical atrophy and chronic gliotic changes

Antigen	Intensity	Degree	0	+	++	+++
Amphipysin (Amp)	2	0	■			
CV2 (CV2)	1	0	■			
PNMA2/Ta (Ma2/Ta)	2	0	■			
Ri (Ri)	3	0	■			
Yo (Yo)	1	0	■			
Hu (Hu)	1	0	■			
Recoverin (Rec)	2	0	■			
SOX1 (SOX1)	1	0	■			
Titin (Titin)	2	0	■			
Zic4 (Zic4)	13	+	■	■		
GAD65 (GAD65)	1	0	■			
Tr (DNER) (Tr)	2	0	■			
Kontrol (Co)	86	+++	■	■	■	■

Figure 2. The patient’s serum paraneoplastic panel was positive for Zic4 antibodies

degeneration, and brainstem encephalitis with central nervous system involvement. To diagnose paraneoplastic and autoimmune encephalitis, infections, metastasis, vascular causes, and the toxic effects of cancer treatment drugs should be excluded (3).

Zinc finger proteins are coded by *Zic* genes, which are expressed in the mature and developing central nervous system and play a part in cerebellar development (4). As the *Zic* proteins are associated with the development of the cerebellum, autoantibodies against these proteins cause major cerebellar effects (5). Given the role of *Zic* proteins in cerebellar development, antibodies against these proteins are expected to be found in patients with cerebellar dysfunction. Sabater et al. (5) reported that eight out of nine patients positive for isolated *Zic4* antibodies had cerebellar dysfunction only or predominantly, and one patient had a cognitive disorder. Salazar (4) also detected *Zic4* antibodies in addition to 14-3-3 antibodies in a case he reported with rapidly progressive dementia, stroke-like symptoms, and dysautonomia, who was diagnosed with possible Creutzfeldt Jakob disease. He also reported that a possible mechanism of rapid destruction in the central nervous system might be due to anti-*Zic4* antibodies (4).

Our case also had rapidly progressive cognitive impairment. After detecting lymphocytosis in the CSF, antibiotic and antiviral treatments were started for a possible infection. Our patient’s CSF was found to have 164 leukocytes per mm³. However, after the emergence of a negative CSF culture, negative PCR results, and the positive detection of *Zic4* antibodies, it was considered that the patient had non-infectious autoimmune encephalitis.

In the case of rapidly progressive dementia and cognitive decline, a diagnosis of autoimmune encephalitis should be considered a differential diagnosis (2). Cases of autoimmune encephalitis might present with cognitive decline, seizure-like activity, and newly emerging disorders of movement, gait, and balance (2). However, while *Zic4* antibodies in the *Zic* family have been reported as being mostly associated with small cell lung cancer, they might also be associated with other malignancies, such as B-cell lymphoma and neuroblastoma (4). Malignancy should be investigated in patients with rapidly developing cognitive problems, and the necessary tests and treatments should be planned with paraneoplastic syndromes in mind. All other etiological causes should be excluded before diagnosing paraneoplastic and autoimmune encephalitis.

Ethics

Informed Consent: Signed consent was obtained from the patient relative.

Peer-review: Externally peer-reviewed.

Authorship Contributions

Surgical and Medical Practices: T.A., M.K., Y.Ü., Ö.T., S.B., G.K., Concept: T.A., M.K., Y.Ü., Ö.T., S.B., G.K., Design: T.A., M.K., Y.Ü., Ö.T., S.B., G.K., Data Collection or Processing: T.A., M.K., Y.Ü., Ö.T., S.B., G.K., Analysis or Interpretation: T.A., M.K., Y.Ü., Ö.T., S.B., G.K., Literature Search: T.A., M.K., Y.Ü., Ö.T., S.B., G.K., Writing: T.A., M.K., Y.Ü., Ö.T., S.B., G.K.

Conflict of Interest: No conflict of interest was declared by the authors.

Financial Disclosure: The authors declared that this study received no financial support.

References

1. Canbaz Kabay S. Paraneoplastic syndromes. *Turkiye Klinikleri J Neurol-Special Topics* 2015;8:48-55.
2. Wesley SF, Ferguson D. Autoimmune encephalitis and rapidly progressive dementias. *Semin Neurol* 2019;39:283-292.
3. Aydın Ç, Çelik ŞY, İçöz S, et al. Prognostic factors in anti-neuronal antibody positive patients. *Arch Neuropsychiatry* 2018;55:189-194.
4. Salazar R. Atypical presentation of probable Creutzfeldt-Jakob disease associated with anti-*Zic4* antibody: Literature review of neuronal antibodies in Creutzfeldt-Jakob disease. *Clin Neurol Neurosurg* 2018;168:72-76.
5. Sabater L, Bataller L, Suárez-Calvet M, et al. ZIC Antibodies in paraneoplastic cerebellar degeneration and small cell lung cancer. *J Neuroimmunol* 2008;201-202:163-165.