

1-1-2014

Asymptomatic carotid stenosis identifying patients at high enough risk to warrant endarterectomy or stenting

J. David Spence
Western University, jdspence@uwo.ca

David Pelz
Robarts Research Institute

Frank J. Veith
Cleveland Clinic Foundation

Follow this and additional works at: <https://ir.lib.uwo.ca/medpub>

Citation of this paper:

Spence, J. David; Pelz, David; and Veith, Frank J., "Asymptomatic carotid stenosis identifying patients at high enough risk to warrant endarterectomy or stenting" (2014). *Department of Medicine Publications*. 240.

<https://ir.lib.uwo.ca/medpub/240>

Asymptomatic Carotid Stenosis Identifying Patients at High Enough Risk to Warrant Endarterectomy or Stenting

J. David Spence, MD, FRCPC; David Pelz, MD, FRCPC; Frank J. Veith, MD, FACS

See related article, p 702.

In this issue of *Stroke*, Hirt¹ reports that substantial progression of carotid stenosis predicted ipsilateral stroke or transient ischemic attack among patients randomized to medical therapy in the Asymptomatic Carotid Surgery Trial (ACST).² This might be regarded as another justification to perform carotid endarterectomy (CEA) or stenting (CAS) in some patients with asymptomatic carotid stenosis (ACS), and Hirt's article may help in the selection for invasive treatment of those ACS patients at highest risk of having a stroke.

However, the proportion of patients with progression by ≥ 2 grades (which carried a high enough risk to identify patients who might benefit from invasive intervention) was small. Among the 1469 patients in the study, there were events in only 50 (3.4%), among the 117 (8%) of patients with progression by ≥ 2 grades of stenosis. It must also be understood that the ACST trial was conducted before the widespread implementation of intensive medical therapy that has diminished the stroke risk picture markedly.

The current situation in the United States is deplorable: as many as 95% of CEA and CAS procedures are being performed in patients with asymptomatic stenoses,³ and most of these patients are more likely to be harmed than helped by these interventions. This is being justified on the basis of historical stroke risks in the ACST² and the Asymptomatic Carotid Surgery Trial.⁴ These risks no longer pertain. Three recent studies have shown that in the era of intensive medical therapy, the ipsilateral stroke risk of patients with ACS is now well below the risks of stenting or endarterectomy, even in the recent Carotid Revascularization Endarterectomy Versus Stenting Trial (CREST) trial.

A meta-analysis,⁵ a population-based study in Oxfordshire, UK,⁶ and a stroke prevention clinic study in Canada⁷ have all shown that with more intensive medical

therapy, the 2-year risk of ipsilateral stroke is now between 0.34% and 1%, well below that of CEA or CAS. In CREST, the procedural (30-day) risk of stroke or death for asymptomatic patients was 2.5% for stenting and 1.4% for endarterectomy; the 4-year risk was 4.5% with stenting and 2.7% with endarterectomy.⁸ The 2011 report of Wang et al³ documents in Medicare patients a 1-year risk of stroke or death of 16.7% for stenting and 11% for endarterectomy. It is now clear that stenting carries a higher risk of stroke than does CEA and a higher risk than that with intensive medical therapy. Some have objected that the risk is higher in patients with more severe stenosis, but Naylor has recently shown that this may not be the case.⁹

Interventionalists, who because they often do not consider advances in other therapies or changes in natural history, are indiscriminately stenting patients with ACS for what Henry Barnett calls the Mount Everest indication; when Mallory was asked why he climbed Mount Everest, he said "because it was there." CEA is often performed for the same reason. Indeed, there is an important misunderstanding on the part of many vascular specialists that contributes to this misguided and unnecessarily costly treatment.

Carotid endarterectomy and CAS are not about increasing blood flow to the brain; they are or should be about preventing emboli (Figures 1 and 2). The circle of Willis is remarkably effective at maintaining blood flow in the face of unilateral (or even bilateral) carotid stenosis. In the North American Symptomatic Carotid Endarterectomy Trial (NASCET), the risk of stroke declined among patients with near occlusion.¹⁰ In a total of 100 years of practice in stroke neurology or vascular intervention, we have seen >50 000 patients, but we can count on 2 hands the number who had convincing hemodynamic transient ischemic attacks. Spence et al have shown that in patients with asymptomatic stenosis, intensive medical therapy reduces the proportion of patients with microemboli on transcranial Doppler from 12.6% to 3.7% and reduces the 2-year risk of stroke or myocardial infarction to 1%. This is a much safer way to prevent emboli than either surgery or stenting.

CAS is being justified on the grounds that it causes fewer myocardial infarctions than does endarterectomy, but carotid procedures are not done to prevent myocardial infarction; they are done to prevent stroke. CAS, uniformly to date, causes more strokes than does CEA.¹¹⁻¹²

This widespread application of CAS and CEA to treat ACS is at best misguided and at worst unjustified. We are concerned that too many of these procedures are being done because of the remuneration for them.¹³

The opinions expressed in this article are not necessarily those of the editors or of the American Heart Association.

From the Stroke Prevention & Atherosclerosis Research Centre (J.D.S.), Robarts Research Institute and the Division of Neuroradiology (D.P.), Department of Medical Imaging, University of Western Ontario, London, Ontario, Canada; and the Division of Vascular Surgery (F.J.V.), Cleveland Clinic, Cleveland, OH, and New York University School of Medicine, New York, NY.

Correspondence to J. David Spence, MD, FRCPC, Stroke Prevention & Atherosclerosis Research Centre, Robarts Research Institute, University of Western Ontario, 1400 Western Road, London, Ontario, Canada N6G 2V2. E-mail dspence@robarts.ca; www.robarts.ca/sparc
(*Stroke*. 2014;45:655-657.)

© 2011 American Heart Association, Inc.

Stroke is available at <http://stroke.ahajournals.org>
DOI: 10.1161/STROKEAHA.111.626770

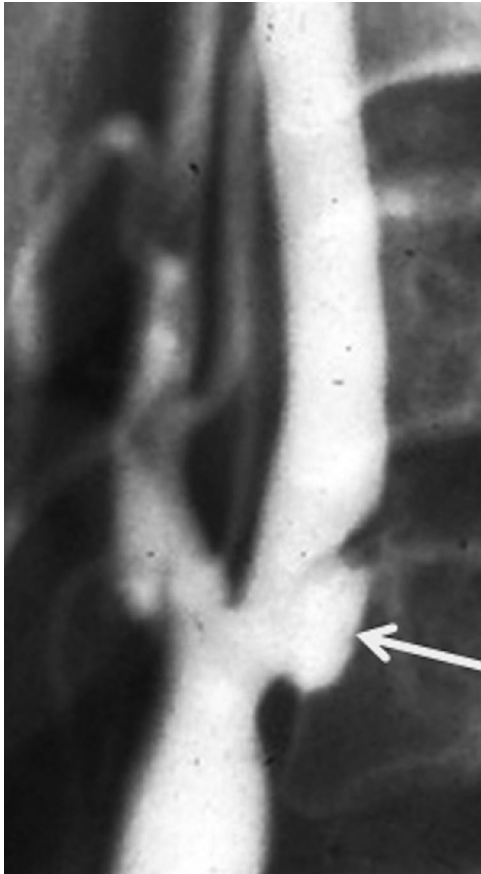


Figure 1. A large carotid ulcer. This was a stenotic plaque until the blood rushing past the stenosis, by the Bernoulli principle, created suction on the surface of the plaque and ripped off the cap, resulting in embolization to the brain.

The recent guidelines of the American Heart Association¹⁴ and other organizations suggest that the indications for CAS be extended to include low-risk patients. This may make a bad situation worse by opening the flood gates for increased use of CAS in patients with ACS when most of these patients are best treated with intensive medical therapy. The value of Hirt's report is that it describes a way to select ACS patients at higher risk for stroke so that they can be treated invasively and the

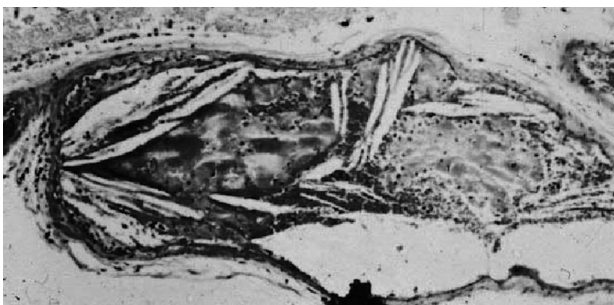

Figure 2. An embolus of atherosclerotic debris in a cerebral blood vessel. Emboli of atheroembolic debris laden with cholesterol crystals (the pointed slender white structures seen in this image) are not prevented by antiplatelet agents; they are prevented by endarterectomy. Stents with a fine mesh might prevent many such emboli, but open stents will not. Intensive medical therapy reduces microemboli detected on transcranial Doppler in patients with asymptomatic carotid stenosis.

much larger remaining group of ACS patients can be treated medically as is appropriate. However, whether high-risk ACS patients, when treated by current medical regimens, will derive additional benefit from invasive treatment still remains to be shown by appropriate randomized trials.

Finally, there are other ways to identify among ACS patients the few who might benefit from invasive intervention.¹⁵ Detection of microemboli,⁷⁻¹⁶⁻¹⁷ detection of ulceration on 3-dimensional ultrasound,¹⁸ and intraplaque hemorrhage on MRI¹⁹ are some approaches that may identify the approximately 10% of ACS patients who are most likely to benefit from CEA or CAS. Nicolaidis et al have suggested other approaches, combining clinical features such as diabetes and smoking with ultrasound features such as echolucent plaque, that may identify a somewhat larger proportion of ACS patients at high risk,²⁰ but their patients were enrolled before the implementation of intensive medical therapy. Most patients, approximately 90%, cannot benefit from such intervention. Thus, the current rush to intervene indiscriminately in ACS patients should be resisted by payers such as private insurance companies and by the Centers for Medicare and Medicaid. The vast majority of patients with asymptomatic carotid stenosis would be better served by intensive medical therapy than by either CAS or CEA.

Disclosures

None.

References

- Hirt LS. Progression rate and ipsilateral neurological events in asymptomatic carotid stenosis. *Stroke*. 2014;45:702–706.
- Halliday A, Mansfield A, Marro J, Peto C, Peto R, Potter J, et al. Prevention of disabling and fatal strokes by successful carotid endarterectomy in patients without recent neurological symptoms: randomised controlled trial. *Lancet*. 2004;363:1491–1502.
- Wang FW, Esterbrooks D, Kuo YF, Mooss A, Mohiuddin SM, Uretsky BF. Outcomes after carotid artery stenting and endarterectomy in the Medicare population. *Stroke*. 2011;42:2019–2025.
- Executive Committee for the Asymptomatic Carotid Atherosclerosis Study. Endarterectomy for asymptomatic carotid artery stenosis. *JAMA*. 1995;272:1421–1428.
- Abbott AL. Medical (nonsurgical) intervention alone is now best for prevention of stroke associated with asymptomatic severe carotid stenosis: results of a systematic review and analysis. *Stroke*. 2009;40:e573–e583.
- Marquardt L, Geraghty OC, Mehta Z, Rothwell PM. Low risk of ipsilateral stroke in patients with asymptomatic carotid stenosis on best medical treatment: a prospective, population-based study. *Stroke*. 2010;41:e11–e17.
- Spence JD, Coates V, Li H, Tamayo A, Munoz C, Hackam DG, et al. Effects of intensive medical therapy on microemboli and cardiovascular risk in asymptomatic carotid stenosis. *Arch Neurol*. 2010;67:180–186.
- Brott TG, Hobson RW II, Howard G, Roubin GS, Clark WM, Brooks W, et al. Stenting versus endarterectomy for treatment of carotid-artery stenosis. *N Engl J Med*. 2010;363:11–23.
- Naylor AR. What is the current status of invasive treatment of extracranial carotid artery disease? *Stroke*. 2011;42:2080–2085.
- Morgenstern LB, Fox AJ, Sharpe BL, Eliasziw M, Barnett HJ, Grotta JC. The risks and benefits of carotid endarterectomy in patients with near occlusion of the carotid artery. North American Symptomatic Carotid Endarterectomy Trial (NASCET) Group. *Neurology*. 1997;48:911–915.
- Rothwell PM. Carotid stenting: more risky than endarterectomy and often no better than medical treatment alone. *Lancet*. 2010;375:957–959.

12. Paraskevas KI, Mikhailidis DP, Veith FJ. Best medical treatment for a symptomatic carotid artery stenosis. *Lancet*. 2011;377:123–124.
13. Naylor AR, Gaines PA, Rothwell PM. Who benefits most from intervention for asymptomatic carotid stenosis: patients or professionals? *Eur J Vase Endovasc Surg*. 2009;37:625–632.
14. Goldstein LB, Bushnell CD, Adams RJ, Appel LJ, Braun LT, Chaturvedi S, et al. Guidelines for the primary prevention of stroke: a guideline for healthcare professionals from the American Heart Association/American Stroke Association. *Stroke*. 2011;42:517–584.
15. Spence JD. Cerebrovascular disease: identifying high-risk patients from carotid plaque composition. *Nat Rev Cardiol*. 2010;7:426–428.
16. Spence JD, Tamayo A, Lownie SP, Ng WP, Ferguson GG. Absence of microemboli on transcranial Doppler identifies low-risk patients with asymptomatic carotid stenosis. *Stroke*. 2005;36:2373–2378.
17. Markus HS, King A, Shipley M, Topakian R, Cullinane M, Reihill S, et al. Asymptomatic embolisation for prediction of stroke in the Asymptomatic Carotid Emboli Study (ACES): a prospective observational study. *Lancet Neurol*. 2010;9:663–671.
18. Madani A, Beletsky V, Tamayo A, Munoz C, Spence JD. High-risk asymptomatic carotid stenosis: ulceration on 3D ultrasound versus TCD microemboli. *Neurology*. In press.
19. Altaf N, Daniels L, Morgan PS, Auer D, MacSweeney ST, Moody AR, et al. Detection of intraplaque hemorrhage by magnetic resonance imaging in symptomatic patients with mild to moderate carotid stenosis predicts recurrent neurological events. *J Vase Surg*. 2008;47:337–342.
20. Nicolaiades AN, Kakkos SK, Kyriacou E, Griffin M, Sabetai M, Thomas DJ, et al. Asymptomatic internal carotid artery stenosis and cerebrovascular risk stratification. *J Vase Surg*. 2010;52:1486–1496.

KEY WORDS: asymptomatic carotid stenosis ■ carotid artery ■ carotid endarterectomy ■ endarterectomy ■ stenting