



## HEALTH SCIENCES

# The effects of metyrosine on ischemia-reperfusion-induced oxidative ovarian injury in rats: Biochemical and histopathological assessment

OMER E. YAPCA, GULSAH A. YILDIZ, RENAD MAMMADOV, NEZAHAT KURT, BETUL GUNDOGDU, YUSUF K. ARSLAN, HALIS SULEYMAN & NIHAL CETIN

**Abstract:** The aim of this study is to investigate the effect of metyrosine on ischemia-reperfusion (I/R) induced ovarian injury in rats in terms of biochemistry and histopathology. Rats were divided into: ovarian I/R (OIR), ovarian I/R+50 mg/kg metyrosine (OIRM) and sham (SG) operations. OIRM group received 50 mg/kg metyrosine one hour before the application of the anesthetic agent, OIR and SG group rats received equal amount of distilled water to be used as a solvent orally through cannula. Following the application of the anesthetic agent, ovaries of OIRM and OIR group rats were subjected to ischemia and reperfusion, each of which took two hours. This biochemical experiment findings revealed high levels of malondialdehyde (MDA) and cyclo-oxygenase-2 (COX-2) and low levels of total glutathione (tGSH), superoxide dismutase (SOD) and cyclo-oxygenase-1 (COX-1) in the ovarian tissue of OIR group, with significant histopathological injury. In metyrosine group, MDA and COX-2 levels were lower than the OIR group whereas tGSH, SOD and COX-1 levels were higher, with slighter histopathological injury. Our experimental findings indicate that metyrosine inhibits oxidative and pro-inflammatory damage associated with ovarian I/R in rats. These findings suggest that metyrosine could be useful in the treatment of ovarian injury associated with I/R.

**Key words:** cyclo-oxygenase enzyme, ischemia-reperfusion, metyrosine, ovarian tissues, rat.

## INTRODUCTION

In literature, ischemic injury is defined as the deoxygenation of the tissues and organs due to reduction or complete cut-off of the blood flow for several reasons (Parks & Granger 1986). Permanent ischemia leads to irreversible injury in ischemic cells (Newmeyer & Ferguson-Miller 2003). Therefore, the first intervention on the ischemic tissue would be to achieve reperfusion. But paradoxically, reperfusion of the ischemic tissue leads to a more significant injury in tissue than the ischemia-induced injury (Zimmerman & Granger 1992). These ROSs, which are known

to be the mediators of reperfusion, oxidize cellular membrane lipids and generates toxic substances such as the malondialdehyde (MDA) from lipids (Del Maestro 1980). Another mechanism of ischemia-reperfusion (I/R) injury is the activation of phospholipase A2 with the increased intra-cellular calcium in ischemic period. Phospholipase A2 increases the production of arachidonic acid among the membrane phospholipids. In tissue I/R, the cyclooxygenase-2 (COX-2) enzyme is activated and reveals pro-inflammatory prostaglandins and free oxygen radicals from arachidonic acid

(Yapca et al. 2013). While the increased xanthine oxidase turns hypoxanthine into xanthine with the achievement of re-oxygenation in reperfusion, it leads to excessive free oxygen radical (ROS) generation (Lindsay et al. 1990). In clinical terms, ovarian I/R is a pathological situation that comes out following the detorsion applied on ovaries that have been torsioned for some reason (Huang et al. 2017). These data suggest that anti-oxidant and anti-inflammatory drugs could be useful in the treatment of ovarian I/R injury.

In this study, investigation of the protective effect of metyrosine, which is a tyrosine enzyme inhibitor drug participating in catecholamine synthesis was aimed (Nasrallah et al. 1977). There are several studies reporting the anti-oxidant activity of metyrosine (Yigiter et al. 2012). Metyrosine is reported to be protective to the gastric tissue against indomethacin and ethanol damage and to develop an anti-inflammatory effect by inhibiting the cyclo-oxygenase-2 enzyme (Albayrak et al. 2010). Anti-ulcerous, anti-oxidant and anti-inflammatory effects of metyrosine indicate that it could protect the ovarian tissue against I/R injury. We could not find any study in the literature search the investigation the effect of methyrosine on ovarian I/R injury. Therefore, the aim of this study is to conduct a biochemical and histological assessment of the effect of metyrosine in IR-induced ovarian injury in rats.

## **MATERIALS AND METHODS**

### **Animals**

Experimental animals were supplied from the Medical Experimental Study and Research Center of Ataturk University. A total of 24 albino Wistar female rats, weights of which varied from 280 to 295 grams, were randomly selected and assigned into group. Animals were kept and fed at ambient temperature (22°C) before the

experimental study. Animal experiments were performed in accordance with the National Guidelines for the Use and Care of Laboratory Animals and were approved by the local animal ethics committee of Ataturk University, Erzurum, Turkey (Ethics Committee Number: 252 Dated: 27.12.2018).

### **Chemical substances**

The thiopental sodium to be used in the experiment was supplied from I.E. Ulagay (Turkey), meperidine was supplied from Liba Laboratories (Turkey) and metyrosine was supplied from Sigma Chemical (Munich, Germany).

### **Experimental groups**

Rats were divided into groups to undergo ovarian ischemic reperfusion (OIR), ovarian ischemic reperfusion+50 mg/kg metyrosine (OIRM) and a healthy group to undergo sham operation (SG).

### **Surgical and pharmacologic operations**

Surgical operations were performed under sterile conditions in a suitable laboratory environment. Rats were anesthetized with thiopental sodium 25 mg/kg intraperitoneally (i.p.). As a pain-killer, 20 mg/kg meperidine was administered via intraperitoneal injection. The time of immobility of the animals in the supine position is considered as the appropriate anesthesia time for surgery (Nayki et al. 2016). In this research, this duration was estimated as 1,5-2 minutes. Prior to the application of the anesthetic agent, OIRM group (n=8) received 50 mg/kg metyrosine orally (metyrosine was dissolved in water) through a catheter. OIR (n=8) and SG (n=8) group rats received equal amounts of distilled water to be used as a solvent in the same way. Following anesthesia, a 2-2,5cm-long vertical incision was performed on pelvic cavity of all rat groups to reach their ovaries. Then, vascular clips were applied to the lower

part of the ovaries (the part where the uterus is connected to the ovary) to provide ischemia for two hours (ischemia was not applied to the ovaries of SG group). At the end of this process, the vascular clips were removed to provide reperfusion for two hours. Following reperfusion, the rats were killed by high-dose anesthetic agent and their ovaries were excised (Nayki et al. 2016). The excised ovarian tissues were then subjected to biochemical and histopathological assessment.

## Biochemical analyses

### **Malondialdehyde (MDA) analysis**

MDA measurements were based on the method used by Ohkawa et al. (1979), involving spectrophotometrical measurement of absorbance of the pink-colored complex formed by thiobarbituric acid (TBA) and MDA. The serum/tissue-homogenate sample (0.1 mL) was added to a solution containing 0.2 mL of 80 g/L sodium dodecyl sulfate, 1.5 mL of 200 g/L acetic acid, 1.5 mL of 8 g/L 2-thiobarbiturate, and 0.3 mL distilled water. The mixture was incubated at 95 °C for 1 h. Upon cooling, 5 mL of n-butanol:pyridine (15:1) was added. The mixture was vortexed for 1 min and centrifuged for 30 min at 4000 rpm. The absorbance of the supernatant was measured at 532 nm. The standard curve was obtained by using 1,1,3,3-tetramethoxypropane (Ohkawa et al. 1979).

### **Total Glutathione (tGSH) analysis**

The amount of GSH in the total homogenate was measured according to the method of Sedlak and Lindsay with some modifications (Sedlak & Lindsay 1968). The sample was weighed and homogenized in 2 mL of 50 mmol/L Tris-HCl buffer containing 20 mmol/L EDTA and 0.2 mmol/L sucrose at pH 7.5. The homogenate was immediately precipitated with 0.1 mL of

25% trichloroacetic acid, and the precipitate was removed after centrifugation at 4200 rpm for 40 min at 4 °C and the supernatant was used to determine GSH level. A total of 1500 µL of measurement buffer (200 mmol/L Tris-HCl buffer containing 0.2 mmol/L EDTA at pH 7.5), 500 µL supernatant, 100 µL DTNB (10 mmol/L) and 7900 µL methanol were added to a tube and vortexed and incubated for 30 min in 37 °C. 5,5-Dithiobis (2-nitrobenzoic acid) (DTNB) was used as a chromogen and it formed a yellow-colored complex with sulfhydryl groups. The absorbance was measured at 412 nm using a spectrophotometer (Beckman DU 500, USA). The standard curve was obtained by using reduced glutathione.

### **Superoxide dismutase (SOD) analysis**

Measurements were performed according to the method of Sun et al. (1988). (Sun et al. 1988). When xanthine is converted into uric acid by xanthine oxidase, SOD forms. If nitro blue tetrazolium (NBT) is added to this reaction, SOD reacts with NBT and a purple-colored formazan dye develops. The sample was weighed and homogenized in 2 mL of 20 mmol/L phosphate buffer containing 10 mmol/L EDTA at pH 7.8. The sample was centrifuged at 6000 rpm for 10 minutes and then the supernatant was used as assay sample. The final volume of reaction mixture was 2450 µL and contained 0.3 mmol/L xanthine, 0.6 mmol/L EDTA, 150 µmol/L NBT, 0.4 mol/L Na<sub>2</sub>CO<sub>3</sub>, 1 g/l bovine serum albumin and, 167 U/l xanthine oxidase. This reaction mixture was vortexed and then it was incubated for 10 minutes at 25 °C. At the end of the reaction, formazan occurred. The absorbance of the purple-colored formazan was measured at 560 nm. As more of the enzyme exists, the least O<sub>2</sub><sup>-</sup> radical that reacts with NBT occurs.

## Measurement of COX activity

### Preparation of reagents for COX activity analysis

The analysis buffer was prepared by diluting 3 mL of the analysis buffer in 27 mL of HPLC-grade water. The heme reagent was prepared by diluting 88  $\mu\text{L}$  of the hem solution in 1.912 mL of the previously prepared analysis buffer. The arachidonic acid solution was prepared by adding 100  $\mu\text{L}$  of KOH to 100  $\mu\text{L}$  of arachidonic acid, vortexing, and diluting with 1.8 mL of HPLC-grade water. The other substances used were the COX standard, colorimetric substrate, DuP697 (COX-2 inhibitor), and SC-560 (COX-1 inhibitor), which are available in commercial kits.

### Procedures

Samples, inhibitors and standards were labeled in a 96-well microplate. The samples stored at  $-20\text{ }^{\circ}\text{C}$  were gradually defrosted as firstly  $+4\text{ }^{\circ}\text{C}$  and then at room temperature. To prepare the blind sample, a quantity of 50  $\mu\text{L}$  from each sample was transferred into a microcentrifuge tube. The tubes were then boiled in a water bath for 5 min and centrifuged at 8000 rpm for 1 min. The supernatant was used as the blind sample. Then 150  $\mu\text{L}$  of the analysis buffer and 10  $\mu\text{L}$  of the hem solution were transferred into each wells containing COX standard, sample, and blind sample. Next, 10  $\mu\text{L}$  of the standard, sample, and blind samples were added to the wells. Each of the inhibitor wells received 140  $\mu\text{L}$  of the analysis buffer, 10  $\mu\text{L}$  of the hem solution, 10  $\mu\text{L}$  of the sample, and 10  $\mu\text{L}$  of the SC 560 solution. The plates were rotated in a plate rotator for a few seconds and then incubated at  $25^{\circ}\text{C}$  for 5 min. After incubation, first, 20  $\mu\text{L}$  of the colorimetric substrate and then 20  $\mu\text{L}$  of the arachidonic acid solution were added into each well. Again the plate was rotated for a few seconds and incubated at  $25^{\circ}\text{C}$  for 5 min, the

absorbances were then read at a wavelength of 590 nm. Using the formula given below, the total COX activity and the activities of COX-1 and COX-2 were calculated. After calculating the total COX activity of each sample, the COX activities of the SC 560 treated samples were calculated using the same formula to identify the COX-2 activities. The COX-2 activity was subtracted from the total COX activity to determine the COX-1 activity. The enzyme quantity that oxidized 1 nmol of TMPD at  $25^{\circ}\text{C}$  in 1 min was accepted as one enzyme unit, and the enzyme activity in the tissues is provided as enzyme units per gram of wet tissue.

	$\Delta A_{590}/5\text{ min}$		0.21 mL Total volume		
Total COX activity	=	0.00826 $\mu\text{M}^{-1}$	X	0.01 mL Specimen volume	$\div 2^*$

**\*The results are divided by two because 2 mol of TMPD are required to reduce  $\text{PGG}_2$  to  $\text{PGH}_2$ . The activity of COX in the tissue was expressed as nmol/min/mg protein (U/ mg protein)**

### Histopathological examination

All tissue samples were first fixed in a 10% formaldehyde solution. Following the fixation, tissue samples were washed under tap water in cassettes for 24 hours. Samples were dehydrated in ascending gradient alcohols (70%, 80%, 90%, and 100%). Tissues were then passed through xylol and embedded in paraffin. 4-5  $\mu\text{m}$  sections of each block were cut and stained with hematoxylin-eosin. Images were taken using the Olympus DP2-SAL firm ware program (Olympus® Inc. Tokyo, Japan). Ovarian tissue sections were subjected to histopathological assessment for congestion, hemorrhage, follicle cell degeneration, effusion in follicular lumen, cystic change and PNL infiltration. The severity of the histopathological findings in each section was scored from 0 to 3 (0-normal, 1-slight injury, 2-moderate injury and 3-severe injury). Histopathological assessment was carried out

by the pathologist who were blind to the study groups.

### Statistical analysis

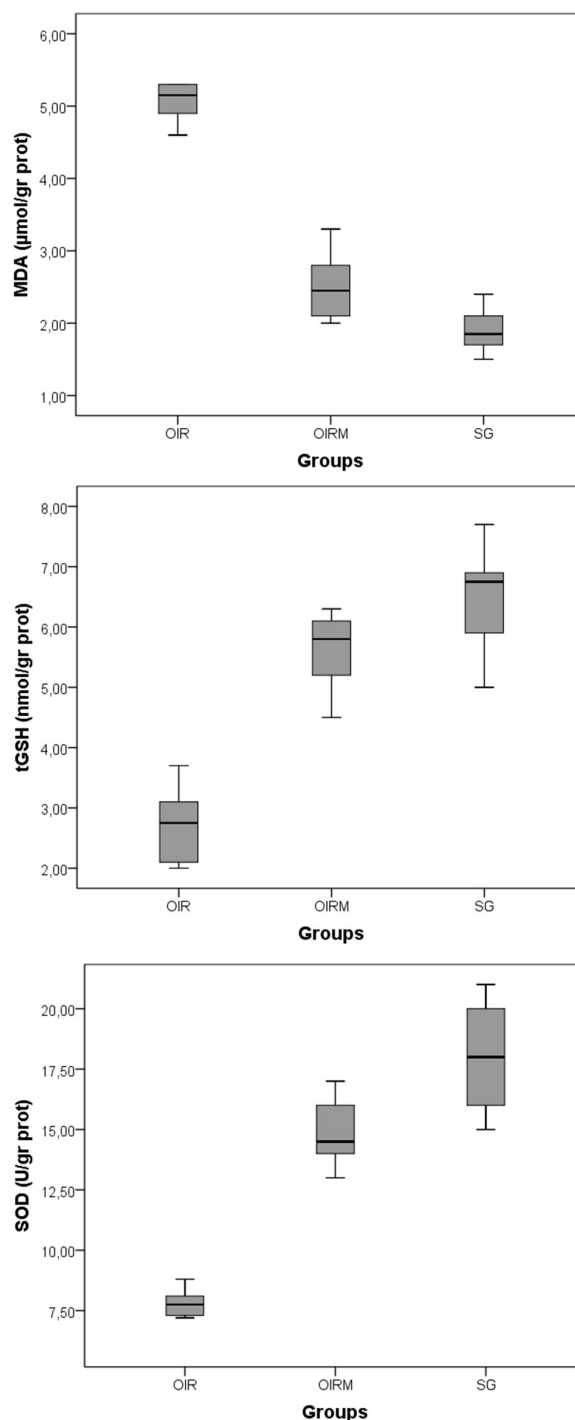
Data were analyzed using IBM SPSS 20 (IBM Corp. Released 2011. IBM SPSS Statistics for Windows, Version 20.0. Armonk, NY: IBM Corp.). The results are expressed as the mean  $\pm$  the standard error of the mean (SEM) for biochemical results. For histopathological assessment the results are expressed with mean  $\pm$  standard deviation, median (minimum-maximum) value. While comparing groups Kruskal Wallis test was used. Differences between groups were obtained using Dunn's test as a post-hoc. A p value  $<0.05$  was considered significant.

## RESULTS

### Biochemical results

#### MDA, tGSH and SOD analysis results

As is seen in figure 1, I/R caused an increase in the MDA of the ovarian tissue of the animals. Metyrosine significantly reduced the MDA increase in the ovarian tissue exposed to I/R. There was a statistically significant ( $p=0.030$ ) difference between the amounts of MDA in OIR and OIRM groups. However, the difference of the amounts of MDA in OIRM and SG groups was statistically insignificant ( $p=0.130$ ). Furthermore, the I/R imposed on the ovarian tissue led to an instant decrease in the amount of tGSH. Yet, metyrosine inhibited tGSH decrease associated with I/R. Whereas there was a significant difference between OIR and OIRM groups in terms of the amount of tGSH ( $p=0.019$ ), the difference was insignificant ( $p=0.256$ ) between OIRM and SG groups. I/R on the ovarian tissue resulted with significant decrease in the SOD activity. Metyrosine inhibited the decrease in the SOD activity by way of I/R. Whereas there was



**Figure 1. Biochemical analysis results of MDA, tGSH and SOD parameters. Values are expressed as mean  $\pm$  SEM.**

a significant difference between OIR and IRM groups with respect to the SOD activity ( $p=0.028$ ), the difference between OIRM and SG groups was insignificant ( $p=0.143$ ). Descriptive statistics of

MDA, tGSH and SOD analysis results are given in Table I.

### COX-1 and COX-2 analysis results

As is seen in figure 2, I/R applied on the ovarian tissue significantly decreased COX-1 activity. Metyrosine inhibited I/R-induced decrease in the COX-1 activity of the ovarian tissue. Whereas COX-1 activity revealed a significant difference between OIR and OIRM groups ( $p=0.023$ ), the difference was insignificant between OIRM and SG groups ( $p=0.194$ ). I/R increased COX-2 activity of the ovarian tissue. Metyrosine significantly suppressed the increase in the COX-2 activity. Statistical analyses showed a significant increase in the COX-2 activity in OIR group ( $p<0.001$ ) compared to OIRM group. The difference between OIRM and SG groups was significant ( $p=0.041$ ) for COX-2 activity. Descriptive statistics of COX activity results are given in Table I.

### Histopathological assessment results

As is seen in figure 3, normal follicular structure and corpus luteum were observed only in SG animal group subjected to sham operation. Ovarian tissues of OIR group animals subjected to I/R displayed extensive congestion or hemorrhage (Figure 4). Follicle cells of the ovarian tissue of OIR group displayed degeneration, effusion in follicular lumen and cystic change (Figure 5). The ovarian tissue of OIR group also displayed polymorphic nuclear leucocyte

infiltration (Figure 6). The ovarian tissue of OIRM group treated with metyrosine displayed a decrease in follicle cell degeneration, cystic change, congestion, hemorrhage and effusion in follicular lumen (Figure 7). The statistical evaluation of histopathological results is presented in Table II. (FCD: Follicular cell degeneration, FALF: Fluid accumulation in the lumen of the follicle, CC: Cystic change, PNL: Polymorphous nuclear leukocyte)

## DISCUSSION

The effect of metyrosine on IR-induced ovarian injury in rats was assessed in terms of biochemistry and histopathology. Understanding of the biochemical mechanisms of I/R injury is significant for the development of new ways of treatment to reduce I/R injury (Homer-Vanniasinkam et al. 1997). The rich amount of  $O_2$  and hydrogen peroxide ( $H_2O_2$ ) offered to the ischemic tissue during reperfusion facilitates the critical biochemical pathways leading to hydroxyl ( $OH\cdot$ ) and superoxide radicals ( $O_2^{\cdot-}$ ) (Ozcan et al. 2015). These radicals, which are known as ROSs, lead to the oxidation of the cellular membrane lipids (LPO) and cellular injury (Catalá 2006). As can be understood from our experimental findings, I/R increased MDA production in the ovarian tissue, which suggests that I/R facilitates LPO reaction in the ovarian tissue. In a research conducted by Demiryılmaz

**Table I. Descriptive statistics of biochemical results in study groups.**

	Groups			p*
	OIR	OIRM	SG	
	Mean $\pm$ SEM	Mean $\pm$ SEM	Mean $\pm$ SEM	
MDA	5.17 $\pm$ 0.18 <sup>a</sup>	2.52 $\pm$ 0.20 <sup>b</sup>	1.90 $\pm$ 0.13	0.001
tGSH	2.73 $\pm$ 0.27 <sup>a</sup>	5.62 $\pm$ 0.27 <sup>b</sup>	6.50 $\pm$ 0.38	0.002
SOD	7.82 $\pm$ 0.25 <sup>a</sup>	14.83 $\pm$ 0.60 <sup>b</sup>	18.00 $\pm$ 0.97	0.001
COX-1	1.75 $\pm$ 0.10 <sup>a</sup>	4.23 $\pm$ 0.19 <sup>b</sup>	5.10 $\pm$ 0.33	0.001
COX-2	7.73 $\pm$ 0.37 <sup>a</sup>	1.73 $\pm$ 0.13 <sup>a,b</sup>	0.86 $\pm$ 0.05	0.001

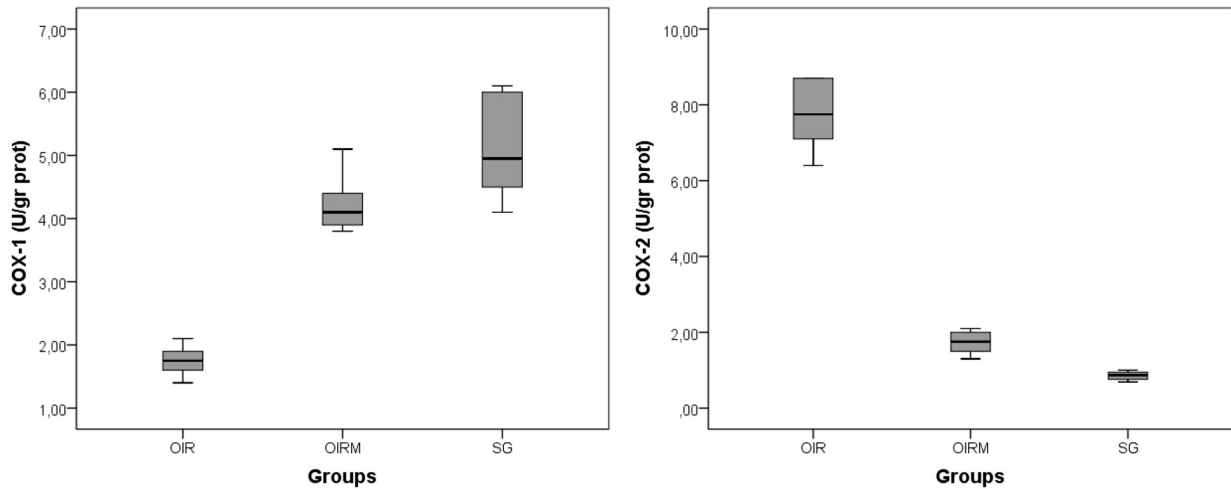
\*Kruskalwallis test results. For post-hoc test a:  $p<0.05$  when compared with SG. b:  $p<0.05$  when compared with OIR.



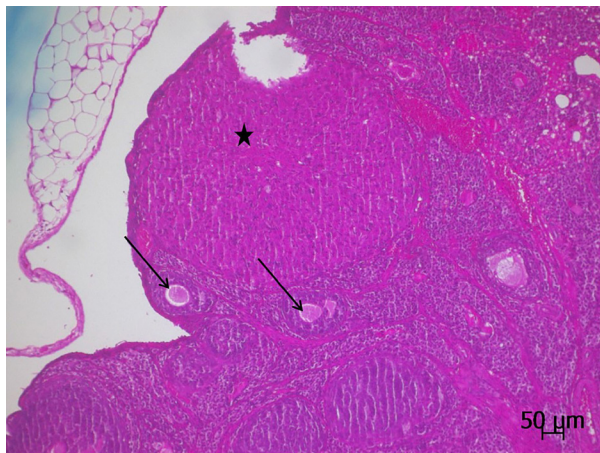
et al. (2013), I/R was reported to be increasing the production of LPO and its final product, MDA in the ovarian tissue (Demiryilmaz et al. 2013). Consequently, the increase in the MDA in a tissue suggests the increase in the ROSs. MDA, which is the resultant of LPO, is toxic and may lead to further injuries (Draper & Hadley 1990). In this research where the protective effect of metyrosine against I/R injury was investigated, the amount of MDA in the metyrosine group was very similar to the amount of MDA in the healthy group. The protective effect of metyrosine arising from the inhibition of MDA production was also suggested by another study (Yigiter et

al. 2012). Literature review revealed no research about the effect of metyrosine on ovarian I/R injury. On the other hand, recent research findings have revealed that metyrosine protects the gastric tissue against the oxidative damage of I/R (Çimen et al. 2018).

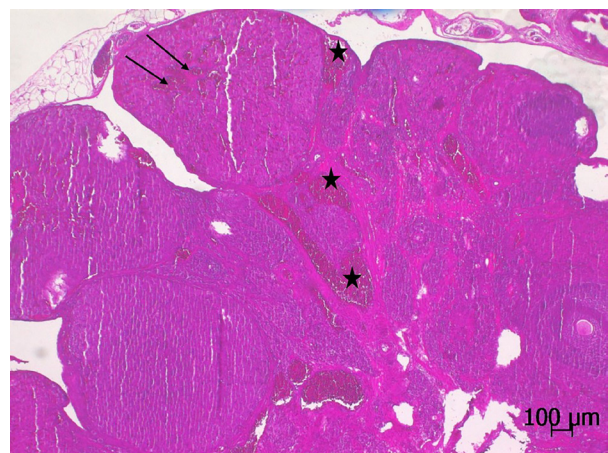
Our experimental findings revealed a decrease in the amount of tGSH, which is an endogenic anti-oxidant, in the ovarian tissue subjected to I/R. Furthermore, metyrosine significantly inhibited the decrease in the tGSH associated with I/R-induced oxidative damage in the ovarian tissue. Oxidative-damage-induced tissue injury is known to be



**Figure 2.** Biochemical analysis results of COX-1 and COX-2 parameters. Values are expressed as mean ± SEM.



**Figure 3.** Ovarian tissue of the animal group subjected to sham operation (SG) displays corpus luteum (star) and follicular structures (arrows) (H&E).



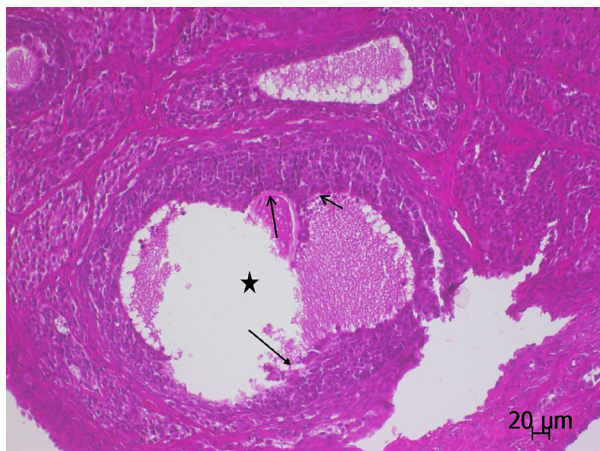**Figure 4.** Ovarian tissue of the OIR group displays extensive congestion (star) and severe hemorrhage (arrows) (H&E).

treated with anti-oxidants. Anti-oxidants both inhibit pre-injury radical formation and heal the existing oxidative damage (Sorg 2004). GSH is a common and important anti-oxidant in living tissues. GSH reacts with  $H_2O_2$  and organic peroxides under the catalyzing effect of GPx, an enzyme involving selenium in the active region, produces a detoxifying effect and protects the cells from ROS injury (Murray et al. 2000). The histopathological findings available in literature reveal that I/R-induced oxidative damage is slighter in the ovarian tissue maintaining its tGSH level (Turkler et al. 2018). In some studies, metyrosine is proven to be inhibiting the decrease in the tGSH in heart tissue caused by a cardio-toxic agent (Ahiskalioglu et al. 2015).

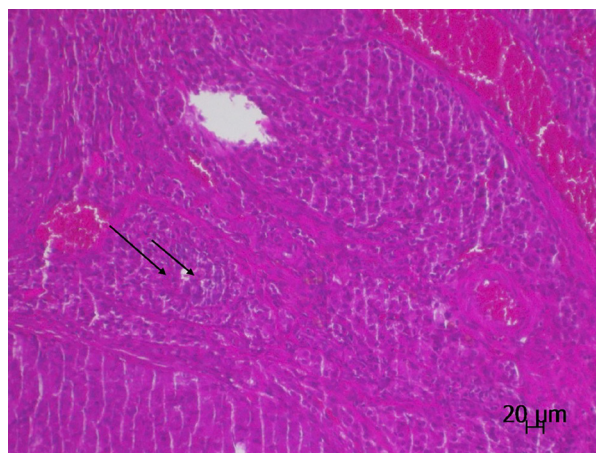
SOD has been another endogenous anti-oxidant parameter which has decreased in the ovarian tissue subjected to I/R. This is an enzyme catalyzing superoxide's transformation into  $H_2O_2$  and  $O_2$ . All types of SOD may catalyze dismutation reaction of superoxide (Buettner et al. 2006). The level of SOD in metyrosine group is close to reference levels, suggesting that it protects the tissue against the harmful effects of ROS. Kurt et al. (2011) also report that SOD activity is decreased in damaged ovarian tissue

(Kurt et al. 2011). In another study, anti-oxidant drugs inhibiting the depletion of SOD level are reported to protect the ovarian tissue against I/R injury (Cadirci et al. 2010). To the best of our knowledge, no research studying the effect of metyrosine in minimizing the ovarian SOD by I/R was found. However, Cimen et al. (2018) have shown that SOD was decreased in the gastric tissue injured by I/R operation. They have also reported that gastric injury was less in the metyrosine group with a high SOD level (Çimen et al. 2018).

Studies have shown that, phospholipase A2 got activated with the increase in the intracellular calcium in ischemic period. Phospholipase increases the production of arachidonic acid, which is one of the membrane phospholipids. In I/R, cyclooxygenase-2 (COX-2) enzyme becomes active and releases pro-inflammatory prostaglandins and free oxygen radicals from arachidonic acid (Yapca et al. 2013). In this research, the ovarian tissue subjected to I/R had high COX-2 and oxidant levels whereas low COX-1 activity. On the contrary, COX-1 level was high and COX-2 level was low in metyrosine group. The brain tissue subjected to I/R displayed that, COX-2 enzyme activity increased

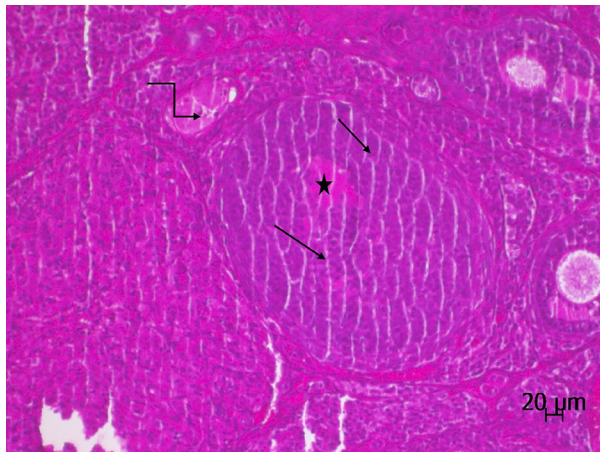


**Figure 5.** The section displaying the cystic change (star) and follicle cell degeneration (arrow) in the ovarian follicles of the OIR group (H&E).



**Figure 6.** The section displaying the neutrophil infiltration (arrows) in the ovarian tissue of the OIR group (H&E).





**Figure 7.** A section of ovarian tissue of the OIRM group showing cystic change (asterisks) with a small amount of fluid accumulation in the lumen and a small number of follicular cells, (arrow), mild congestion (zigzag arrow), (H&E).

in parallel with the increase in the oxidant parameters (Wicha et al. 2017). As is known, COX-1 enzyme is responsible for the synthesis of cyto-protective prostaglandins whereas COX-2 is responsible for the synthesis of pro-inflammatory prostaglandins (Smith et al. 1996). Consequently, while COX-1 enzyme inhibition leads to tissue injury, COX-2 inhibition protects the tissue from inflammatory injury (Suleyman

et al. 2010, 2009). While there is no finding showing the effect of metyrosine on COX in the ovarian tissue, there are findings suggesting that metyrosine antagonizes the decrease in the COX-1 activity and the increase in the COX-2 activity in the gastric tissue, creating a gastro-protective effect (Albayrak et al. 2010).

Our biochemical findings obtained from the ovarian tissues of all animal groups included in the experiment are conformant with our histopathological findings. Histopathological findings such as severe congestion, hemorrhage, follicle degeneration, effusion in follicular lumen, cystic change and polymorphous nuclear leucocyte (PNL) infiltration were observed in the animal ovarian tissue subjected to I/R only. Ovarian tissues of the animals treated with metyrosine were found to have subsided. In previous studies it has been shown that, severe histopathological injury developed in the ovarian tissue of the I/R group with high oxidant values and COX-2 level and low anti-oxidant values and COX-1 level (Isaoglu et al. 2012, Turkler et al. 2018). Unlubilgin et al. (2017) reported histopathological symptoms such as

**Table II.** Histopathological assessment in study groups.

	Groups			p*
	OIR	OIRM	SG	
Congestion	2.8±0.4 <sup>a</sup> 3(2-3)	1.0±0.6 <sup>b</sup> 1(0-2)	0±0 0(0-0)	0.001
Haemorrhage	3.0±0.0 <sup>a</sup> 3(3-3)	1.3±0.5 <sup>b</sup> 1(1-2)	0±0 0(0-0)	<0.001
FCD	2.7±0.5 <sup>a</sup> 3(2-3)	1.2±0.8 <sup>b</sup> 1(0-2)	0±0 0(0-0)	0.001
FALF	2.8±0.4 <sup>a</sup> 3(2-3)	1.2±0.4 <sup>b</sup> 1(1-2)	0±0 0(0-0)	0.001
CC	2.3±0.5 <sup>a</sup> 2(2-3)	0.7±0.5 <sup>b</sup> 1(0-1)	0±0 0(0-0)	0.001
PNL	2.8±0.4 <sup>a</sup> 3(2-3)	0.3±0.5 <sup>b</sup> 0(0-1)	0±0 0(0-0)	0.001

Results were presented as mean ± SD, median (min-max) value. 0-normal, 1-slight injury, 2-moderate injury and 3-severe injury. \*Kruskalwallis test results. For post-hoc test a:p<0.05 when compared with SG. b: p<0.05 when compared with OIR. FCD: Follicular cell degeneration, FALF: Fluid accumulation in the lumen of the follicle, CC: Cystic change, PNL: Polymorphous nuclear leucocyte.

hemorrhage, congestion, follicle degeneration and PNL infiltration in the ovarian tissue with increased oxidative stress and pro-inflammatory indicators associated with I/R (Unlubilgin et al. 2017). PNLs play a key role in the exacerbation of oxidative stress and inflammatory injury during reperfusion (Yapca et al. 2013). In conclusion: I/R led to oxidative stress and inflammatory injury in the ovarian tissue. In terms of biochemistry and histopathology evaluations, metyrosine was shown to be suppressing the oxidative and pro-inflammatory injury associated with I/R. These suggest that metyrosine could be useful in the treatment of I/R-induced ovarian injury.

## REFERENCES

- AHISKALIOGLU A, INCE I, AKSOY M, AHISKALIOGLU EO, COMEZ M, DOSTBIL A, CELIK M, ALP HH, COSKUN R & TAGHIZADEHGHALEHJOUGH I. 2015. Comparative investigation of protective effects of metyrosine and metoprolol against ketamine cardiotoxicity in rats. *Cardiovasc Toxicol* 15: 336-344.
- ALBAYRAK A, POLAT B, CADIRCI E, HACIMUFTUOGLU A, HALICI Z, GULAPOGLU M, ALBAYRAK F & SULEYMAN H. 2010. Gastric anti-ulcerative and anti-inflammatory activity of metyrosine in rats. *Pharmacol Rep* 62: 113-119.
- BUETTNER GR, NG CF, WANG M, RODGERS V & SCHAFFER FQ. 2006. A new paradigm: manganese superoxide dismutase influences the production of H<sub>2</sub>O<sub>2</sub> in cells and thereby their biological state. *Free Radic Biol Med* 41: 1338-1350.
- CADIRCI E, ORAL A, ODABASOGLU F, KILIC C, COSKUN K, HALICI Z, SULEYMAN H, KELES ON & UNAL B. 2010. Atorvastatin reduces tissue damage in rat ovaries subjected to torsion and detorsion: biochemical and histopathologic evaluation. *Naunyn Schmiedeberg's Arch Pharmacol* 381: 455-466.
- CATALÁ A. 2006. An overview of lipid peroxidation with emphasis in outer segments of photoreceptors and the chemiluminescence assay. *Int J Biochem Cell Biol* 38: 1482-1495.
- ÇIMEN O, ÇIMEN FK, GÜLABOĞLU M, BILGIN AÖ, ÇEKİÇ AB, EKEN H, SÜLEYMAN Z, BILGIN Y & ALTUNER D. 2018. The effect of metyrosine on oxidative gastric damage induced by ischemia/reperfusion in rats. *Biochemical and histopathological evaluation. Acta Cir Bras* 33: 259-267.
- DEL MAESTRO RF. 1980. An approach to free radicals in medicine and biology. *Acta Physiol Scand Suppl* 492: 153-168.
- DEMIRYILMAZ I, SENER E, CETIN N, ALTUNER D, AKCAY F & SULEYMAN H. 2013. A comparative investigation of biochemical and histopathological effects of thiamine and thiamine pyrophosphate on ischemia-reperfusion induced oxidative damage in rat ovarian tissue. *Arch Pharm Res* 36: 1133-1139.
- DRAPER H & HADLEY M. 1990. [43] Malondialdehyde determination as index of lipid Peroxidation. *Meth Enzymol: Elsevier* 186: 421-431.
- HOMER-VANNIASINKAM S, CRINNION J & GOUGH M. 1997. Post-ischaemic organ dysfunction: a review. *Eur J Vasc Endovasc Surg* 14: 195-203.
- HUANG C, HONG M-K & DING D-C. 2017. A review of ovary torsion. *Tzu-chi Med J* 29: 143.
- ISAOGLU U, YILMAZ M, SENER E, CETIN N, ALTUNER D, BILEN H, YAPCA O, DEMIRYILMAZ I, ISAOGLU N & GÜL M. 2012. The impaired balances of oxidant/antioxidant and COX-1/COX-2 in ovarian ischemia-reperfusion injury and prevention by nimesulide. *Latin Am J Pharm* 31: 1481-1488.
- KURT A, ISAOGLU U, YILMAZ M, CALIK M, POLAT B, HAKAN H, INGEC M & SULEYMAN H. 2011. Biochemical and histological investigation of famotidine effect on postischemic reperfusion injury in the rat ovary. *J Pediatr Surg* 46: 1817-1823.
- LINDSAY TF, LIAUW S, ROMASCHIN AD & WALKER PM. 1990. The effect of ischemia/reperfusion on adenine nucleotide metabolism and xanthine oxidase production in skeletal muscle. *J Vasc Surg* 12: 8-15.
- MURRAY RK, GRANNER DK, MAYES PA & RODWELL VW. 2000. *Harper's Biochemistry*, Health Profession Division, 25 th ed, New York: McGraw-Hill.
- NASRALLAH HA, DONNELLY EF, BIGELOW LB, RIVERA-CALIMLIM L, ROGOL A, POTKIN S, RAUSCHER FP, WYATT RJ & GILLIN JC. 1977. Inhibition of dopamine synthesis in chronic schizophrenia: Clinical ineffectiveness of metyrosine. *Arch Gen Psychiatry* 34: 649-655.
- NAYKI UA, NAYKI C, CETIN N, CIMEN FK, COBAN A, MAMMADOV R, TAS IH & MALKOC I. 2016. Effect of Kineret® on ovarian ischemia reperfusion injury in a rat model. *J Obstet Gynaecol Res* 42: 1525-1533.
- NEWMAYER DD & FERGUSON-MILLER S. 2003. Mitochondria: releasing power for life and unleashing the machineries of death. *Cell* 112: 481-490.

OHKAWA H, OHISHI N & YAGI K. 1979. Assay for lipid peroxides in animal tissues by thiobarbituric acid reaction. *Anal Biochem* 95: 351-358.

OZCAN O, ERDAL H & YONDEN Z. 2015. Biochemical aspect of oxidative stress related to ischemia-reperfusion damage. *Mustafa Kemal Üniv Tıp Derg* 6: 27-33.

PARKS DA & GRANGER DN. 1986. Contributions of ischemia and reperfusion to mucosal lesion formation. *Am J Physiol Gastrointest Liver Physiol* 250: G749-G753.

SEDLAK J & LINDSAY RH. 1968. Estimation of total, protein-bound, and nonprotein sulfhydryl groups in tissue with Ellman's reagent. *Anal Biochem* 25: 192-205.

SMITH WL, GARAVITO RM & DEWITT DL. 1996. Prostaglandin endoperoxide H synthases (cyclooxygenases)-1 and- 2. *J Biol Chem* 271: 33157-33160.

SORG O. 2004. Oxidative stress: a theoretical model or a biological reality? *C R Biol* 327: 649-662.

SULEYMAN H, ALBAYRAK A, BILICI M, CADIRCI E & HALICI Z. 2010. Different mechanisms in formation and prevention of indomethacin-induced gastric ulcers. *Inflammation* 33: 224-234.

SULEYMAN H, DURSUN H, BILICI M, CADIRCI E, HALICI Z, GULABOGLU M & ALBAYRAK F. 2009. Relation of adrenergic receptors, which have roles in gastroprotective and anti-inflammatory effect of adrenal gland hormones, with cyclooxygenase enzyme levels in rats. *J Physiol Pharmacol* 60: 129-134.

SUN Y, OBERLEY LW & LI Y. 1988. A simple method for clinical assay of superoxide dismutase. *Clin Chem* 34: 497-500.

TURKLER C, KULHAN N, ATA N, KIREMITLI T, CIMEN F & SULEYMAN H. 2018. The ameliorative effect of lutein on ovarian ischemia-reperfusion injury in rats. *Bratisl Lek Listy* 119: 713-717.

UNLUBILGIN E, SULEYMAN B, BALCI G, AL RA, CANKAYA M, NAYKI UA & SULEYMAN H. 2017. Prevention of infertility induced by ovarian ischemia reperfusion injury by benidipine in rats: Biochemical, gene expression, histopathological and immunohistochemical evaluation. *J Gynecol Obstet Hum Reprod* 46: 267-273.

WICHA P, TOCHARUS J, JANYOU A, JITTIWAT J, CHANGTAM C, SUKSAMRARN A & TOCHARUS C. 2017. Hexahydrocurcumin protects against cerebral ischemia/reperfusion injury, attenuates inflammation, and improves antioxidant defenses in a rat stroke model. *PLoS ONE* 12: e0189211.

YAPCA OE, BOREKCI B & SULEYMAN H. 2013. Ischemia-reperfusion damage. *Eurasian J Med* 45: 126.

YIGITER M, YILDIZ A, POLAT B, ALP HH, KELES ON, SALMAN AB & SULEYMAN H. 2012. The protective effects of metyrosine, lacidipine, clonidine, and moxonidine on kidney damage induced by unilateral ureteral obstruction in rats. *Surg Today* 42: 1051-1060.

ZIMMERMAN BJ & GRANGER DN. 1992. Reperfusion injury. *Surg Clin North Am* 72: 65-83.

#### How to cite

YAPCA OE, YILDIZ GA, MAMMADOV R, KURT N, GUNDOGDU B, ARSLAN YK, SULEYMAN H & CETIN N. 2023. The effects of metyrosine on ischemia-reperfusion-induced oxidative ovarian injury in rats: Biochemical and histopathological assessment. *An Acad Bras Cienc* 95: e20201586. DOI 10.1590/0001-3765202320201586.

*Manuscript received on October 8, 2020;*  
*accepted for publication on December 8, 2020*

#### OMER E. YAPCA<sup>1</sup>

<https://orcid.org/0000-0002-5578-0126>

#### GULSAH A. YILDIZ<sup>1</sup>

<https://orcid.org/0000-0002-3283-7783>

#### RENAD MAMMADOV<sup>2</sup>

<https://orcid.org/0000-0002-5785-1960>

#### NEZAHAT KURT<sup>3</sup>

<https://orcid.org/0000-0002-1685-5332>

#### BETUL GUNDOGDU<sup>4</sup>

<https://orcid.org/0000-0002-3786-3286>

#### YUSUF K. ARSLAN<sup>5</sup>

<https://orcid.org/0000-0003-1308-8569>

#### HALIS SULEYMAN<sup>2</sup>

<https://orcid.org/0000-0002-9239-4099>

#### NIHAL CETIN<sup>6</sup>

<https://orcid.org/0000-0003-3233-8009>

<sup>1</sup>Department of Obstetrics and Gynaecology, Faculty of Medicine, Atatürk University, 25240, Erzurum, Turkey

<sup>2</sup>Department of Pharmacology, Faculty of Medicine, Erzincan Binali Yildirim University, 24100, Erzincan, Turkey

<sup>3</sup>Department of Biochemistry, Faculty of Medicine, Erzincan Binali Yildirim University, 24100, Erzincan, Turkey

<sup>4</sup>Department of Pathology, Faculty of Medicine, Atatürk University, 25240, Erzurum, Turkey

<sup>5</sup>Department of Biostatistics, Faculty of Medicine, Erzincan Binali Yildirim University, 24100, Erzincan, Turkey

<sup>6</sup>Department of Pharmacology, Faculty of Medicine,  
Selcuk University, 42131, Konya, Turkey

Correspondence to: **Nihal Cetin**  
E-mail: [nihalcetin84@gmail.com](mailto:nihalcetin84@gmail.com)

### Authors contributions

OEY and GAY conceived the original idea. RM and NC were in charge of overall direction and planning. HS supervised the project. RM helped supervise the project. OEY, GAY, RM, and HS carried out the experiments. YKA performed the computations and analyzed the data. BG and NK supervised the findings of this work. OEY and GAY wrote the manuscript with support from HS and NC. All authors discussed the results and contributed to the final manuscript.

