

2022-RA-594-ESGO

APPLICATION OF ULTRASOUND IN CERVICAL CANCER (A CASE REPORT AND UPDATED LITERATURE REVIEW)

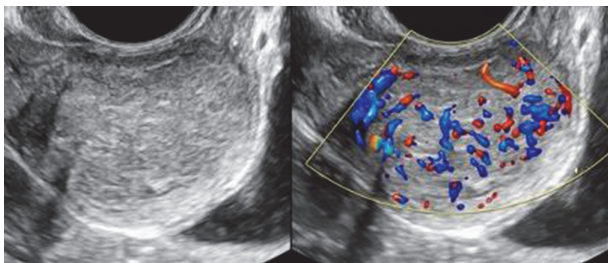
^{1,2,3}Dusan Djokovic, ²Conceição Telhado, ²José Silva Pereira, ²Pedro Conde. ¹*Gynecology and Obstetrics (MAC), CHULC, Lisboa, Portugal;* ²*Hospital CUF Descobertas, Lisbon, Portugal;* ³*NOVA Medical School, NOVA University of Lisbon, Lisbon, Portugal*

10.1136/ijgc-2022-ESGO.33

Introduction/Background Technological development and specialized training of operators have led to the increasing usefulness of ultrasonography (US) in patients with cervical cancer (CC). Most women with squamous cell CC (SCC) present hypoechoic lesions and increased vascularity, while rare-type CC are commonly isoechoic. This communication presents a case of SCC with less frequent US characteristics and summarizes updated information on the role of US in CC.

Methodology Case report and non-systematic literature review (MEDLINE, 2012 – 2022).

Results A 38-year-old nulliparous woman, with an irrelevant medical history, no desire to procreate, never involved in the immunization and CC screening programs by personal decision, was admitted to our department due to intense acute genital hemorrhage. Physical examination revealed a bleeding nodular lesion, apparently protruding from the cervical canal. Bleeding was controlled by tamponade. Transrectal US indicated an anterior cervical isoechoic lesion (34 x 21 x 30 mm), with an ovoid shape, regular edges and lateral acoustic shadows (see accompanying images). Although these were not the most common US characteristics of CC, the Doppler study (color score 3) raised suspicion. No signs of parametrial affection were observed. Colposcopy with biopsy was performed (histological diagnosis: non-keratinizing SCC). Pre-treatment gynecological US and magnetic resonance imaging (MRI) provided concordant information while thoraco-abdominal computerized tomography did not evidence secondary lesions (T1b1N0M0). The patient underwent radical hysterectomy (type C), bilateral salpingectomy, bilateral pelvic lymph node dissection and ovarian transposition. In accordance with the literature: transvaginal/transrectal expert US provides highly accurate information on detecting CC, being a convenient and cost-effective modality for assessing local extension (accuracy similar to that of MRI). Doppler studies may be useful for evaluating responses to various treatments. US guidance may be helpful in the delivery of intracavitary brachytherapy.



Abstract 2022-RA-594-ESGO Figure 1

Conclusion Expert US provides valuable information for detecting invasive CC and assessing the local tumor spread.

2022-RA-601-ESGO

FIGHTING CERVICAL CANCER IN CAMEROON

¹Cristina Juan Jimenez, ²Gutiérrez Martínez Ana María, ³Maria Rosario Noguero Meseguer, ³Maria Purificación Domínguez Franjo, ³Ana Laura Luque Pérez, ¹Maria Jesus De la Fuente, ¹Emilie Ngonu, ¹Rodrigo Ferrán Cristina, ¹Villalobos Nery. ¹*Fundación Recover, Hospitales para África, Madrid, Spain;* ²*Hospital Lisungi, Kinshasa, Congo, Democratic Republic of the;* ³*Hospital Universitario Rey Juan Carlos, Madrid, Spain*

10.1136/ijgc-2022-ESGO.34

Introduction/Background Cameroon is a country located in Central Africa comprising a population close to 26 million. Due to its government's expenditure devotes less than 5% of its annual budget to the healthcare sector, it is worth noting the lack of prevention campaigns. It concerns cervical cancer which according to World Health Organization (WHO), by implementing prevention activities 1 out of 4 deaths apropos the cited could be avoided. Additionally, it should be noticed a relationship betwist the refered and HIV. Recover – as a Foundation which has been working in Africa since 2006-, germane to needs expressed by its partners, started to execute prevention cervical cancer campaigns since 2018 in countless health care structures in Cameroon- excluding 2020.

Methodology Descriptive observational study relying on records of 3 last campaigns pertaining to cervical cancer launched by Foundation Recover and partners in Cameroon.

Results Convering screening of cervical cancer in the course of the mention, 3,71% (119) of smear cervical test out a total of 3205, have submitted an outcome precancerous lesions. It is worth mentioning that 2 of the 3 campaigns carried out included surgical interventions to avoid progression to cancer requested at least 81,54% of women with abnormal outcomes. Additionally, 66,93% of women screened had performed HIV test, resulting 11,27% positives. The cited percentage could be even higher if all the women had run the test.



Abstract 2022-RA-601-ESGO Figure 1