

# Endovascular Treatment of Aorto-iliac Occlusive Disease Using the Kissing Balloon Technique: Mid-term Follow-up

© Metin Yılmaz<sup>1</sup>, © Anıl Özen<sup>2</sup>, © Görkem Yiğit<sup>2</sup>, © Murat Gül<sup>3</sup>, © Zafer İşcan<sup>2</sup>

<sup>1</sup>Aksaray University Training and Research Hospital, Clinic of Cardiovascular Surgery, Aksaray, Turkey

<sup>2</sup>Ministry of Health Ankara Bilkent City Hospital, Clinic of Cardiovascular Surgery, Ankara, Turkey

<sup>3</sup>Aksaray University Training and Research Hospital, Clinic of Cardiology, Aksaray, Turkey

## Abstract

**Objectives:** This study aimed to present our mid-term experience in the endovascular treatment of aortoiliac occlusive disease using the kissing balloon technique.

**Materials and Methods:** This two-center, retrospective study included 36 patients (male, n=23; female, n=13; mean age 62.7±9.7 years) with an aortoiliac occlusive disease, who received intervention using the kissing balloon technique between January 2017 and December 2019.

**Results:** Thirty-six patients with aortoiliac occlusive disease underwent percutaneous intervention. The procedure could not be continued in three patients because of technical failure. Hence, 33 patients were successfully treated using the kissing balloon technique. The technical success rate was 91.6% and the one year patency rate was 83.3%. Of the 33 patients, 3 underwent surgery because of stent occlusion. After 1-year follow-up, in all 30 patients, all the vessels and stents were patent and no re-stenosis, no occlusion and no procedure related morbidity and mortality occurred.

**Conclusion:** The endovascular treatment of aortoiliac occlusive diseases with kissing balloon technique demonstrated high success and patency rates in appropriate cases. However, in some patients technical failure may occur and the procedure could not be completed. The use of newer recanalization devices, materials or techniques, enrollment of larger cohort and more than 1 year of follow-up may clarify the long-term results of the kissing balloon technique.

**Keywords:** Endovascular treatment, iliac artery occlusion, kissing balloon technique



**Address for Correspondence:** Metin Yılmaz, Aksaray University Training and Research Hospital, Clinic of Cardiovascular Surgery, Aksaray, Turkey

**Phone:** +90 532 164 89 50 **e-mail:** dr.metin\_yilmaz@yahoo.com **ORCID:** orcid.org/0000-0003-2878-2676

**Received:** 15.01.2022 **Accepted:** 20.08.2022

**Cite this article as:** Yılmaz M, Özen A, Yiğit G, Gül M, İşcan Z. Endovascular Treatment of Aorto-iliac Occlusive Disease Using the Kissing Balloon Technique: Mid-term Follow-up. EJCM 2022;10(3):123-129.

DOI: 10.32596/ejcm.galenos.2022.2022-01-06

## Introduction

Atherosclerotic peripheral arterial disease affects 50 million people in the United States and Europe. It is a major challenging disease that can lead to disabling ischemia, limb loss, and reduced quality of life. New interventional modalities, such as percutaneous transluminal angioplasty (PTA) with a drug-eluting balloon or plain balloon angioplasty, stent implantation and atherectomy procedures have been developed for the endovascular treatment of complex arterial occlusive diseases, particularly for extensive lesions of aortoiliac and infrainguinal arteries<sup>(1)</sup>. Endovascular strategies have become a well-recognized therapeutic alternative to bypass surgery with the aforementioned technical advancements, including the elderly population and patients with chronic total occlusions<sup>(2)</sup>. The incidence of restenosis in PTA for aortoiliac lesions is high enough not to be ignored, especially for complex lesions<sup>(3)</sup>. However, paclitaxel-coated balloons (PCBs) were found to be superior to plain balloons in preventing restenosis<sup>(4-7)</sup>. Furthermore, the durability of endovascular interventions was reported to improve with self-expanding nitinol stents<sup>(8)</sup>. The term *kissing balloon* was first used by Grüntzig and Hopff<sup>(9)</sup> to describe the percutaneous treatment of iliac bifurcation stenosis. In 1980, Velasquez et al.<sup>(10)</sup> published the first report on this technique for distal aorta angioplasty in a patient with Leriche syndrome. Later, several studies have successfully used the kissing balloon technique for treating peripheral artery disease and have taken their place in the literature<sup>(11-14)</sup>. In this study, we present our mid-term experience in the endovascular treatment of patients with aortoiliac occlusive disease using the kissing balloon technique.

## Materials and Methods

### Study Population

This two-center, retrospective study was conducted at Ankara Yüksek İhtisas Training and Research Hospital and Aksaray Training and Research Hospital between January 2017 and December 2019. Twenty-seven patients were

included from Aksaray Training and Research Hospital, whereas nine patients were from Ankara Yüksek İhtisas Training and Research Hospital. Written informed consent was obtained from each patient. The study protocol was approved by the Ethics Committee of Türkiye Yüksek İhtisas Training and Research Hospital (date: 31.01.2017, approval no. 29620911-929). The study was conducted based on the principles of the Declaration of Helsinki.

In this study, the mid-term results of 36 patients who underwent PTA and stent implantation because of chronic occlusion of iliac arteries were retrospectively analyzed. Eligible patients were those having atherosclerotic diseases of unilateral or bilateral iliac arteries with symptoms varying from moderate intermittent claudication to diffuse pedal ischemia according to the Rutherford classification (classes 2-5)<sup>(15)</sup> and those who were either ineligible for surgery due to comorbidities or refused open surgery and thus underwent endovascular procedure according to the study protocol. According to the study protocol, all patients were treated using a suitable imaging method [preferably computed tomography (CT) angiography] before the procedure. In addition to the physical examination, color Doppler ultrasonography and CT angiography were performed, when necessary, during the control evaluation after the procedure. Patients who underwent endovascular procedures for chronic total occlusions in iliac arteries but not with the kissing balloon technique and patients who had chronic occlusion lesions in other localizations were excluded from the study.

Patient information was obtained from the hospital archives, outpatient clinical records, image archives of the radiology department, and hospital registry records. Some patients were called for a control visit, and information was obtained by physical examination and radiological examinations. For those who were unable to visit the hospital, other necessary information was obtained by phone call. Patients' demographic, clinical, and procedural data were compiled and analyzed. Demographic data included age, sex, and presence of diabetes mellitus (DM), hypertension, chronic obstructive pulmonary disease

(COPD), coronary artery disease, chronic renal failure, obesity, and smoking. Clinical data included the following lesion characteristics: localization, length, and extension (patients classified according to the Trans-Atlantic Inter-Society Consensus (TASC) II classification based on the anatomical characteristics of their lesions). Previous interventions, if present, patency of the procedure, current complaints of the patients, and pre- and post-procedural ankle-brachial index (ABI) were also recorded. Procedural data included the duration of the procedure, technical success of the procedure, any additional procedures, and complications.

### Interventions

All percutaneous procedures were performed in a hybrid operating theater under local anesthesia (2% prilocaine), with the patient placed in the supine position on the operating table. In all patients, the first choice for access was either of the femoral arteries. However, in cases where the primary iliac lesion could not be crossed by femoral access, the right axillary artery was used for access. All procedures were initiated by retrograde arterial cannulation using a 6-Fr or 7-Fr introducer sheath (Radifocus Introducer II, Terumo, Europe N.V, Leuven, Belgium). After arterial cannulation, heparin was administered intravenously according to an activated clotting time of 180-200 s. A diagnostic catheter (6.0 Fr,  $\times 150$  cm, Boston Scientific, MA, USA) for angiography was delivered retrograde straightforward to the distal aorta from the side of the non-primary lesion. Following the administration of an opaque solution, bilateral iliac and femoral arteries were imaged starting from the distal aorta. The process was continued by deciding on the appropriate size of the balloon and stent according to the initial level and length of the primary iliac lesion. After the imaging procedure, all iliac lesions were crossed by catheter-assisted recanalization with a soft hydrophilic guide wire (0.035"  $\times$  150 cm, nitinol guide wire, Terumo) and shapable support catheter (SpeXR, 0.035"  $\times$  150 cm, Reflow Medical Inc., San Clemente, CA, USA). Subsequently, angioplasty was performed using an appropriate-sized LuminorR PCB

catheter (iVascular, S.L.U., Barcelona, Spain) and bailout therapy with appropriate-sized iVolutionR self-expanding nitinol stent (iVascular, S.L.U., Barcelona, Spain) for chronic occlusion lesions (vessel/balloon ratio of 1:1 based on the visual estimate for a total inflation time of 3 min at 6-14 atm) for all patients. Balloons were inflated once. However, when control angiography revealed a residual segmental lesion ( $>50\%$  stenosis), flow-limiting dissection, or atherosclerotic plaque deformation, a second PCB was performed and dilatation was maintained for a longer period ( $>3$  min). In patients with axillary access, a long, braided introducer sheath (7 Fr, Terumo) was used to continue the procedure. After the procedures, control imaging was performed to check the intra-arterial flow patency, stent configuration, and presence of residual stenosis (Figure 1).

### Statistical Analysis

Statistical analysis was performed using IBM SPSS Statistics for Windows, version 25.0 (IBM Corp., Armonk, NY, USA). Descriptive data were expressed as mean  $\pm$  standard deviation or median (min.-max.) for continuous variables and in number and frequency for categorical variables. The Shapiro-Wilk test was used to check the normal distribution of continuous variables. Paired-sample t-test was used to analyze and compare ABI values before and after the procedures. The Kaplan-Meier survival analysis was used to test the primary and cumulative patency rates of interventions at and during the follow-up period. The significance level was set at  $\alpha=0.05$ ;  $p<0.05$  was considered significant.

## Results

### Baseline Characteristics

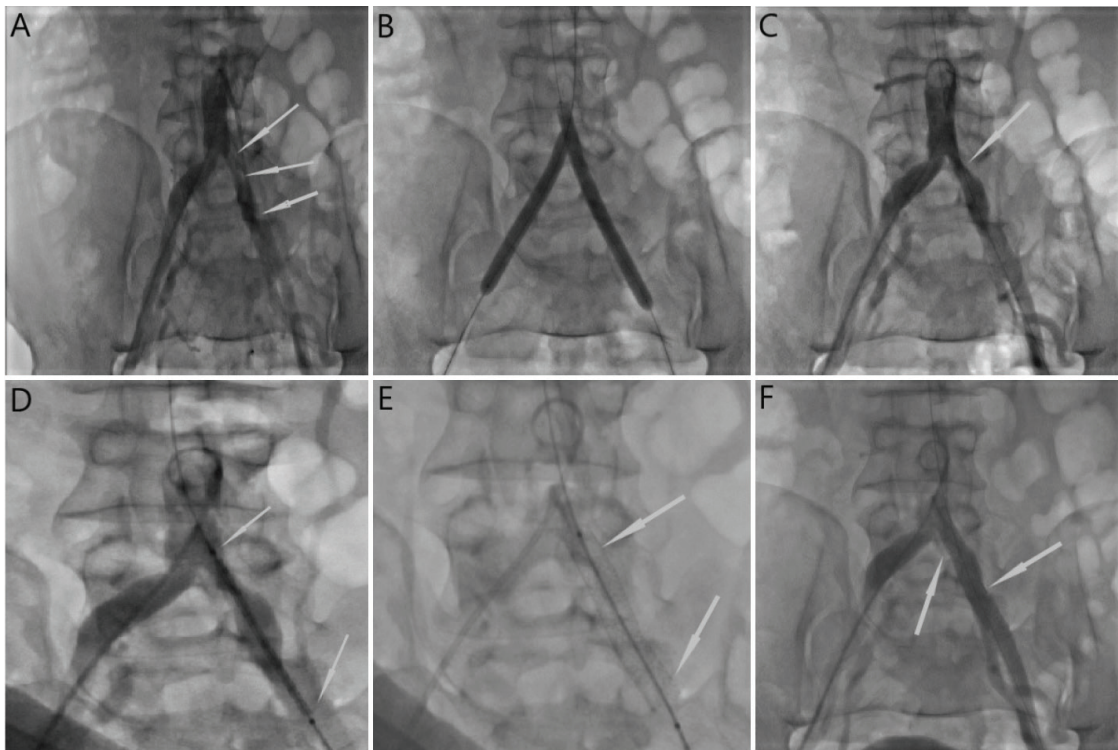
The mean age was  $62.7\pm 9.7$  years, 23 patients were male, and 13 patients were female. Moreover, 38.9% of the patients had DM; 44.4%, hypertension; 47.2%, hyperlipidemia; 30.6%, COPD; 27.8%, coronary artery disease; and 13.9%, chronic kidney disease. Additionally, 41.7% of the patients were current smokers. Claudication

was the only symptom in 86.1% of the patients, 11.1% had rest pain, and 2.8% had an ischemic wound on one foot. According to the TASC II classification, 5 (13.8%) patients were included in TASC A, 9 patients in TASC B (25%), 15 patients in TASC C (41.6%), 7 (19.4%) patients in TASC D.

### Operative Findings

The mean intervention time was  $76.7 \pm 8.7$  min. A total of 36 patients received interventions for aortoiliac occlusive disease. Three patients with additional femoro-popliteal lesions located on the ipsilateral side of the iliac occlusive lesion received interventions simultaneously. Retrograde sub-intimal aortic dissection developed in two patients due to the failure of pass the iliac lesion to reach the aortic

lumen during the guide-wire and catheter manipulation, after which the procedure was terminated. In one patient, the procedure was terminated because the iliac lesion could not be crossed at all. Moreover, in four patients, the procedure was continued from the right axillary access because of failure via the femoral access so that the procedure could be completed. In total, 33 patients were successfully treated by this technique, with a success rate of 91.6%. Moreover, six patients developed procedure-related complications. The procedure was terminated in two patients who developed retrograde aortic dissection, and who underwent open surgery immediately after the intervention under elective conditions. Two patients developed a hematoma in the groin, and another patient had femoral artery pseudoaneurysm; these complications



**Figure 1.** Angiographic images of a 61-year-old man presented with claudication in left leg caused by aorta-iliac occlusive disease in left common iliac artery. This patient intervened with kissing balloon technique and serial images show whole procedure step by step. **(A)** Angiographic imaging shows a diffuse atherosclerotic plaque begins from initial level of iliac bifurcation and extends to left external iliac artery (arrows). **(B)** After catheter supported recanalization of occlusive segment, kissing balloon dilatation was performed with paclitaxel coated balloons (7x100 mm for left, 7x120 mm for right iliac arteries). **(C)** After balloon dilatation, control imaging shows a successful recanalization with residual stenosis (arrow). **(D)** Image shows assessment of true localization of an 8x80 mm self-expandable nitinol stent before deployment. Stent's proximal and distal markers are visible (arrows). **(E)** Control imaging shows successfully deployment of the stent (arrows). **(F)** After all the procedure control imaging shows successfully treatment of occlusive segment and stent configuration and arterial lumen patency seems to be excellent



resolved spontaneously without surgery. In one patient, acute severe ischemia was observed in the treated extremity because of procedure-related debris embolism, and then urgent open surgery was performed.

### Other Findings and Follow-up

Approximately 12 h after the procedure, one patient underwent urgent open surgery because of severe ischemia and leg pain. Left aorto-femoro-popliteal bypass surgery was performed in the same session via the retroperitoneal approach. Intraoperative exploration of the aorta revealed a plaque shift and debris embolism that occluded the iliac artery lumen, which required intervention. The patient was discharged on postoperative day 7 and recovered completely. In one patient, open surgery was performed under elective conditions after 1 month because of sub-acute stent occlusion. In one patient, open surgery was performed after 6 months under elective conditions due to chronic re-occlusion of the stent that was previously inserted before the procedure. After 1 year, all stents were patent, and no misconfiguration, residual stenosis, and occlusion occurred in any of the 30 patients. Although all patients were preoperatively symptomatic and had claudication, 76.7% of them were asymptomatic and 23.3% had mild symptoms at the end of the follow-up period. ABI values were improved significantly in the treated extremity during the post-procedural period ( $p < 0.001$ ).

### Discussion

Both PTA and stenting are commonly used endovascular interventions for iliac artery occlusive disease. A stenotic or occlusive lesions of the iliac artery can be successfully treated with PTA alone. If PTA alone is technically unsuccessful, additional stent placement is indicated (provisional stenting). Alternatively, a stent could be placed primarily to treat iliac artery stenosis or occlusion (primary stenting). However, which endovascular treatment strategy is superior for stenotic and occlusive lesions of the iliac arteries is barely known given the limited evidence available<sup>(16)</sup>. The availability of

endovascular stents has significantly increased the number of aortoiliac lesions that may be treated percutaneous by providing a larger acute gain in luminal diameter, scaffolding the lumen to prevent embolization of debris and enhancing long-term patency compared with balloon angioplasty alone. For common iliac bifurcation lesions, kissing balloon expandable stents have become the preferred option<sup>(17,18)</sup>. The TASC II document describes characteristic lesion morphology for ideal (type A) and unfavorable (type D) iliac lesions for endovascular therapy<sup>(19)</sup>. Surgical and percutaneous treatments of TASC II type B and C lesions have been compared in a nonrandomized observational study<sup>(20)</sup>. No difference was found in limb salvage or patient survival at 5 years, but vessel patency was reduced in limbs with poor runoff and those treated with stents compared with surgery. Other trials comparing surgery with percutaneous intervention for iliac occlusive diseases include a randomized comparison of balloon angioplasty with surgery for 157 iliac lesions, which found no difference in the 3-year cumulative rate for death, amputation, or revascularization failure<sup>(21)</sup>. Another randomized controlled trial of surgery versus angioplasty in 102 patients with severe claudication and limb-threatening ischemia demonstrated no difference at 1 year for angioplasty or surgery<sup>(22)</sup>. On the basis of these and other trial data, current recommendations favor endovascular procedures for TASC II A and B lesions and selected C lesions. Generally, patients with TASC II D lesions will be considered candidates for surgery, but with newer technologies (reentry devices and covered stent grafts) these patients are being increasingly considered for endovascular therapy on a case-by-case basis<sup>(23)</sup>. However, in a systematic review, twenty-one studies presented 1,390 patients. Rutherford classification 1/2/3 was the indication in 76.2% of patients, and 48.4% of the lesions were classified as Trans-Atlantic Inter-Society Consensus C or D. The technical success rate was 98.7%, and the complication rate was 10.8%. The clinical improvement at 30 days was achieved in 89.9%. Primary patency at 12, 24, and 60 months was 89.3%, 78.6%, and 69.0%, respectively<sup>(24)</sup>.

We successfully treated 33 patients using the kissing balloon technique. We also used catheter-supported recanalization and primary-stenting techniques to complete the procedure. The main problem appears to be the recanalization process in patients with TASC II D lesions with procedural options and material settings that we used. Excimer laser-assisted recanalization is one of the most frequently used methods for the recanalization of chronic total occlusions. Although this technique was used in many studies in the 1990s and early 2000s<sup>(25-28)</sup> and achieved early successful results, it is no longer used nowadays, as it was found to have high restenosis rates due to severe vascular inflammation in long-term follow-up compared with other recanalization techniques in later studies<sup>(29)</sup>. In a series of 48 patients, published in 1999, all stents were placed successfully, and no major complications occurred. In this study, primary stenting was used in addition to the kissing balloon technique similar to our study, but excimer laser-assisted recanalization was used as the recanalization method of chronic total aortoiliac occlusive lesions. All patients experienced symptomatic improvement, and the 2-year patency rate was 87%<sup>(13)</sup>.

## Conclusion

The early and mid-term results of this study revealed that the kissing balloon technique is a successful treatment option for aortoiliac lesions. However, patients with TASC II D group lesions demonstrated poor outcomes, which may be due to the ineffective recanalization method employed. In this group, better results may be obtained using more effective recanalization methods in addition to the kissing balloon technique.

## Ethics

**Ethics Committee Approval:** The study protocol was approved by the Ethics Committee of Türkiye Yüksek İhtisas Training and Research Hospital (date: 31.01.2017, approval no. 29620911-929).

**Informed Consent:** Written informed consent was obtained from each patient.

**Peer-review:** Externally peer-reviewed.

## Authorship Contributions

Surgical and Medical Practices: Yılmaz M, Özen A, Yiğit G, Gül M, İşcan Z, Concept: İşcan Z, Design: Yılmaz M, Data Collection and/or Processing: Yılmaz M, Yiğit G, Analysis of Interpretation: Gül M, Literature Search: Yılmaz M, Özen A, Writing: Yılmaz M, Özen A, Yiğit G.

**Conflict of Interest:** No conflict of interest was declared by the author.

**Financial Disclosure:** No financial resources have been used for this article.

## References

1. 'IN.PACT Admiral' Drug-Coated Balloon From Medtronic Outperforms Standard Angioplasty In Landmark Study. Medtronic. News and Information. April 5, 2014. Available at: <https://news.medtronic.com/2014-04-05-IN-PACT-Admiral-Drug-Coated-Balloon-From-Medtronic-Outperforms-Standard-Angioplasty-In-Landmark-Study>
2. Yiğit G, Sarıcaoğlu MC, Çetinkaya F, Özen A, İşcan HZ. Endovascular treatment of chronic total occlusion of iliac/femoral arteries: Mid-term follow-up. *Turk J Vasc Surg* 2020;29:7-12.
3. Davies MG, Anaya-Ayala JE. Endovascular techniques in limb salvage: cutting, cryo, brachy, and drug-eluting balloons. *Methodist Debakey Cardiovasc J* 2013;9:69-72.
4. Werk M, Langner S, Reinkensmeier B, et al. Inhibition of restenosis in femoropopliteal arteries: paclitaxel-coated versus uncoated balloon: femoral paclitaxel randomized pilot trial. *Circulation* 2008;118:1358-65.
5. Tepe G, Zeller T, Albrecht T, et al. Local delivery of paclitaxel to inhibit restenosis during angioplasty of the leg. *N Engl J Med* 2008;358:689-99.
6. Micari A, Cioppa A, Vadala G, et al. A new paclitaxel-eluting balloon for angioplasty of femoropopliteal obstructions: acute and midterm results. *EuroIntervention* 2011;7(Suppl K):77-82.
7. Rosenfield K, Jaff MR, White CJ, et al. Trial of a paclitaxel-coated balloon for femoropopliteal artery disease. *N Engl J Med* 2015;373:145-53.
8. Laird JR, Schneider PA, Tepe G, et al. Durability of Treatment Effect Using a Drug-Coated Balloon for Femoropopliteal Lesions 24-Month Results of IN.PACT SFA. *J Am Coll Cardiol* 2015;66:2329-38.
9. Grüntzig A, Hopff H. Percutaneous recanalization after chronic arterial occlusion with a new dilator-catheter (modification of the Dotter technique) (author's transl)]. *Dtsch Med Wochenschr* 1974;99:2502-10.
10. Velasquez G, Castaneda-Zuniga W, Formanek A, et al. Nonsurgical aortoplasty in Leriche syndrome. *Radiology* 1980;134:359-60.
11. Mewissen MW, Beres RA, Bessette JC, Lipchik EO. Kissing-balloon technique for angioplasty of the popliteal artery trifurcation. *AJR Am J Roentgenol* 1991;156:823-4.

12. Sagic D, Grujicic S, Peric M, Popovic Z, Radevic B, Bojic M. "Kissing-balloon" technique for abdominal aorta angioplasty. Initial results and long term outcome. *Int Angiol* 1995;14:364-7.
13. Scheinert D, Schröder M, Balzer JO, Steinkamp H, Biamino G. Stent-supported reconstruction of the aortoiliac bifurcation with the kissing balloon technique. *Circulation* 1999;100(Suppl 19):295-300.
14. Pfister M, Chatterjee T, Walther F, Vogt B, Baumgartner I. "Kissing balloon technique" for bilateral iliac artery obstruction in retroperitoneal fibrosis. *Eur J Vasc Endovasc Surg* 2000;20:394-6.
15. Rutherford RB, Baker JD, Ernst C, et al. Recommended standards for reports dealing with lower extremity ischemia: revised version. *J Vasc Surg* 1997;26:517-38.
16. Jongsma H, Bekken J, Ayez N, Hoogewerf CJ, Van Weel V, Fioole B. Angioplasty versus stenting for iliac artery lesions. *Cochrane Database Syst Rev* 2015;12:CD007561.
17. Sullivan TM, Childs MB, Bacharach JM, Gray BH, Piedmonte MR. Percutaneous transluminal angioplasty and primary stenting of the iliac arteries in 288 patients. *J Vasc Surg* 1997;25:829-38.
18. de Vries JP, van Den Heuvel DA, Vos JA, van Den Berg JC, Moll FL. Freedom from secondary interventions to treat stenotic disease after percutaneous transluminal angioplasty of infrarenal aorta: long-term results. *J Vasc Surg* 2004;39:427-31.
19. Norgren L, Hiatt WR, Dormandy JA, et al. Inter-Society Consensus for the Management of Peripheral Arterial Disease (TASC II). *J Vasc Surg* 2007;45(Suppl):5-67.
20. Timaran CH, Prault TL, Stevens SL, Freeman MB, Goldman MH. Iliac artery stenting versus surgical reconstruction for TASC (TransAtlantic Inter-Society Consensus) type B and type C iliac lesions. *J Vasc Surg* 2003;38:272-8.
21. Wilson SE, Wolf GL, Cross AP. Percutaneous transluminal angioplasty versus operation for peripheral arteriosclerosis: report of a prospective randomized trial in a selected group of patients. *J Vasc Surg* 1989;9:1-9.
22. Holm J, Arfvidsson B, Jivegard L, et al. Chronic lower limb ischaemia: a prospective randomised controlled study comparing the 1-year results of vascular surgery and percutaneous transluminal angioplasty. *Eur J Vasc Surg* 1991;5:517-22.
23. White CJ, Gray WA. Endovascular therapies for peripheral arterial disease: an evidence-based review. *Circulation* 2007;116:2203-15.
24. Groot Jebbink E, Holewijn S, Slump CH, Lardenoije JW, Reijnen MMPJ. Systematic review of results of kissing stents in the treatment of aortoiliac occlusive disease. *Ann Vasc Surg* 2017;42:328-36.
25. Wollenek G, Laufer G, Grabenwöger F. Percutaneous transluminal excimer laser artery occlusion in man. *Lasers Surg Med* 1988;8:464-8.
26. Belli AM, Cumberland DC, Procter AE, Welsh CL. Total peripheral artery occlusions: conventional versus laser thermal recanalization with a hybrid probe in percutaneous angioplasty--results of a randomized trial. *Radiology* 1991;181:57-60.
27. Scheinert D, Laird JR Jr, Schröder M, Steinkamp H, Balzer JO, Biamino G. Excimer Laser-Assisted Recanalization of Long, Chronic Superficial Femoral Artery Occlusions. *J Endovasc Ther* 2001;8:156-66.
28. Steinkamp HJ, Werk M, Beck A, Teichgräber U, Haufe M, Felix R. Excimer laser-assisted recanalisation of femoral arterial stenosis or occlusion caused by the use of Angio-Seal. *Eur Radiol* 2001;11:1364-70.
29. Wu TY, Chou HH, Chang SH, et al. Comparison of immediate and 2-year outcomes between excimer laser-assisted angioplasty with spot stent and primary stenting in intermediate to long femoropopliteal disease. *ScientificWorldJournal* 2013;2013:247102.