

2018

Atrioventricular Junctional Tachycardia with Exit Block in an Adolescent

Nicholas M. Cundiff
Heritage College of Osteopathic Medicine

Jeffrey A. Robinson
University of Nebraska Medical Center, jeffrey.robinson@unmc.edu

Bryan C. Cannon
Mayo Clinic

Christopher S. Snyder
Case Western Reserve University School of Medicine

Tell us how you used this information in this [short survey](#).

Follow this and additional works at: https://digitalcommons.unmc.edu/com_peds_articles



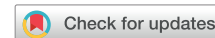Part of the [Pediatrics Commons](#)

Recommended Citation

Cundiff, Nicholas M.; Robinson, Jeffrey A.; Cannon, Bryan C.; and Snyder, Christopher S., "Atrioventricular Junctional Tachycardia with Exit Block in an Adolescent" (2018). *Journal Articles: Pediatrics*. 33.
https://digitalcommons.unmc.edu/com_peds_articles/33

This Article is brought to you for free and open access by the Pediatrics at DigitalCommons@UNMC. It has been accepted for inclusion in Journal Articles: Pediatrics by an authorized administrator of DigitalCommons@UNMC. For more information, please contact digitalcommons@unmc.edu.

Atrioventricular junctional tachycardia with exit block in an adolescent



Nicholas M. Cundiff, DO,^{*} Jeffrey A. Robinson, MD,[†] Bryan C. Cannon, MD, FHRS,[‡] Christopher S. Snyder, MD, FAAP, FACC[†]

From the ^{*}Centers for Osteopathic Research and Education, Heritage College of Osteopathic Medicine, Athens, Ohio, [†]The Congenital Heart Collaborative, Rainbow Babies and Children's Hospital, Case Western Reserve University School of Medicine, Cleveland, Ohio, and [‡]Division of Pediatric Cardiology, Mayo Clinic, Rochester, Minnesota.

Introduction

Atrioventricular (AV) junctional tachycardia is an abnormal rhythm that arises from a focus of enhanced automaticity within or adjacent to the His bundle or AV junction.^{1,2} This dysrhythmia is often described as arising idiopathically or postoperatively.³ Exit block is defined as the failed electrical propagation of an impulse, generated by any cardiac pacemaker, into the surrounding myocardium.⁴

Here we report the case of an otherwise healthy adolescent female who presented with a history of vasovagal syncope. Independent of symptoms, the patient had what seemed to be intermittent episodes of advanced, second-degree AV block. Medical evaluation identified a final diagnosis of idiopathic AV junctional tachycardia with exit block that was successfully managed with flecainide and eventually cured with cryoablation. This arrhythmia has not previously been described in a pediatric patient.

Case report

A 17-year-old, healthy Caucasian girl presented with a 2-year history of post-exercise-related palpitations, shortness of breath, and chest tightness. Episodes lasted up to 45 minutes and resolved with rest. An ambulatory heart rhythm monitor (ZIO XT Patch, iRhythm Technologies, Inc, San Francisco, CA) showed sinus rhythm during symptoms. Independently, episodes of second-degree (Mobitz type I) AV block as well as advanced, second-degree AV block with asymptomatic pauses in AV conduction lasting up to 4.8 seconds occurred (Figure 1).

The patient was admitted to the hospital telemetry unit for evaluation and management of AV block. Workup revealed a

normal physical examination, vital signs, and 15-lead electrocardiogram (ECG). Results of a laboratory panel revealed normal serum electrolytes, complete blood count, erythrocyte sedimentation rate, antinuclear antibody panel, Lyme antibody panel, and streptolysin O antibodies. Transthoracic echocardiography and cardiac magnetic resonance imaging showed normal cardiac structure and function with no evidence of myocarditis. The patient continued to have episodes of advanced, second-degree AV block, particularly during periods of startle (awakening by alarm clock). A treadmill stress test revealed sinus rhythm throughout exercise and recovery, with a peak heart rate of 206 bpm but no dysrhythmia.

Because of her conduction system's response to startle, the patient underwent a 30-minute head-up tilt table test to assess for increased vagal tone. Ten minutes into the tilt, the patient developed symptoms consistent with her chief complaints of palpitations, shortness of breath, chest tightness, dizziness along with pallor, and syncope. At that time, sinus bradycardia (40 bpm) and a decrease in blood pressure were documented; however, no significant ectopy or arrhythmia was noted on continuous ECG. The patient maintained normal sinus rhythm with 1:1 AV conduction throughout the tilt and during recovery.

The patient continued to demonstrate frequent episodes of prolonged advanced, second-degree AV block every day on telemetry. A dose of atropine 1 mg was administered intravenously to inhibit potential elevated vagal tone with no effect.

Based on the intermittent character of the advanced, second-degree AV block and the patient's symptoms during tilt table test elicited during sinus rhythm, the diagnoses of AV junctional tachycardia with exit block and concurrent vasovagal syncope were considered. To prove this, the decision was made to initiate flecainide 130 mg/m²/day by mouth divided twice daily, which was prescribed based on standard adult dosing. By the third dose of flecainide, the patient's telemetry and ECG monitoring showed normal sinus rhythm without episodes of advanced, second-degree AV block. The patient was observed for 3 additional days without any symptoms and was discharged home. Outpatient Holter

KEYWORDS Atrioventricular block; Cryoablation; Flecainide; Junctional tachycardia; Vasovagal syncope
(Heart Rhythm Case Reports 2018;4:594–597)

Address reprint requests and correspondence: Dr Christopher S. Snyder, Division of Pediatric Cardiology, Rainbow Babies and Children's Hospital, MS RBC 6011, 11100 Euclid Ave, Cleveland, OH 44106. E-mail address: Christopher.Snyder@UHhospitals.org.

KEY TEACHING POINTS

- Atrioventricular (AV) junctional tachycardia with exit block should be considered in the differential diagnosis of an adolescent with intermittent advanced, second-degree AV block.
- Flecainide is useful for the diagnosis and treatment of AV junctional tachycardia with exit block.
- The diagnosis of arrhythmia does not exclude concurrent vasovagal syncope.

monitoring identified no episodes of AV junctional tachycardia over a period of 1 year. However, she was later found to be noncompliant with the medication, and the dysrhythmia returned on subsequent Holter monitoring.

The patient was then referred for electrophysiological (EP) study. EP study showed normal intervals at baseline (AH interval 66 ms, HV interval 41 ms) and decremental conduction over the AV node (AV Wenckebach with rapid atrial pacing at 410 ms, AV nodal effective refractory period 600/310 ms), with no evidence of dual AV nodal physiology. The abnormal rhythm was not inducible during EP study.

A junctional modification was performed, and the ectopic focus was empirically identified based on previous clinical experience. It was localized anatomically by mapping the His bundle and moving the catheter inferiorly where no further His bundle was recognized. Three-dimensional mapping placed the lesion <5 mm from the His position. A broad cryothermal lesion set was placed in the right inferior input of the AV node using a Medtronic Freezor AX 8-mm tip, 9F cryoablation catheter (Medtronic CryoCath LP, Pointe-Claire, Quebec, Canada). AV nodal conduction properties were unchanged after the lesion set as determined by incremental atrial pacing and a single atrial extrastimulus. No complications or signs of transient heart block occurred during the procedure. Flecainide was discontinued, and the patient was discharged to home the next day. Follow-up over the next year showed no recurrence of AV junctional tachycardia without flecainide on multiple ambulatory heart rhythm monitors.

Discussion

AV junctional tachycardia is an abnormal rhythm that arises from a focus of enhanced automaticity within or adjacent to the His bundle or AV junction.^{1,2} This results in a narrow complex tachycardia, heart rates that vary from 120–220 bpm, and classic signs of AV dissociation.⁵ This arrhythmia often presents with normal sinus P-wave conduction that is subsequently blocked by the ectopic junctional beat. In some patients, conduction from the junctional focus to the

atrium may be seen. P waves, if present, may arise before, during, or after the QRS complex and classically are inverted in the inferior leads (II, III, and aVF) and upright in aVR.^{3,6} AV junctional tachycardia can be described based on etiology (idiopathic and postoperative) or timing (paroxysmal and nonparoxysmal). In the pediatric population, junctional tachycardia presents in 3 forms: congenital, postoperative, or an “adult” form.³

Exit block is the failed electrical propagation of an impulse, generated by any cardiac pacemaker, into the surrounding myocardium.⁴ Exit block is described as type I, or Wenckebach, with a progressive delay in conduction that is apparent by grouped beating or a decreasing P-P (atrial) or R-R (junctional or ventricular) interval before the blocked beat; or type II, which is characterized by a blocked beat that occurs in the absence of preliminary signs with a length that is a multiple of the basic interval. ECG diagnosis of an exit block is based on intermittent P-P interval prolongation in multiples (doubling, tripling, etc) of the normal P-P interval.⁷

Nonpostoperative AV junctional tachycardia with exit block in the pediatric population has not been previously described. Historically, this arrhythmia has been documented in the elderly population, most commonly associated with digoxin toxicity or myocardial infarction.^{4,8–11} One case study described this arrhythmia, which occurred nonpostoperatively in the context of normal digoxin levels and exercise and was successfully managed with propranolol.¹²

Few cases have strong parallels to our particular case presentation. One report described at 72-year-old previously healthy man with complete AV block and AV junctional tachycardia with exit block.⁷ Another report described a 52-year-old previously healthy man with a negative workup who in the absence of digoxin demonstrated on His-bundle electrogram a junctional ectopic rhythm with exit block that blocked the sinus P wave. The patient was successfully managed with flecainide 50 mg/day by mouth.¹³

The case presented here exhibited both AV junctional tachycardia with exit block and vasovagal syncope. Evaluation for the arrhythmia included a differential diagnosis of high vagal tone, Lyme carditis, rheumatic fever, myocarditis, lupus, and fibrosis/sclerosis of the conduction system, yet the respective studies were negative. Because of the vague correlation of symptoms, the patient underwent a 30-minute head-up tilt test, which reproduced her presenting symptoms but with maintenance of sinus rhythm and fully conducting all P waves, consistent with vasovagal syncope. We worked through the preliminary diagnosis of advanced, second-degree AV block that was suspected; however, the intermittent occurrence of the arrhythmia suggested AV junctional tachycardia with exit block. This diagnosis is consistent with the recordings shown in [Figure 1](#), which show consistent P-wave intervals with intermittent failure to conduct a QRS secondary to junctional extrasystoles with exit block.

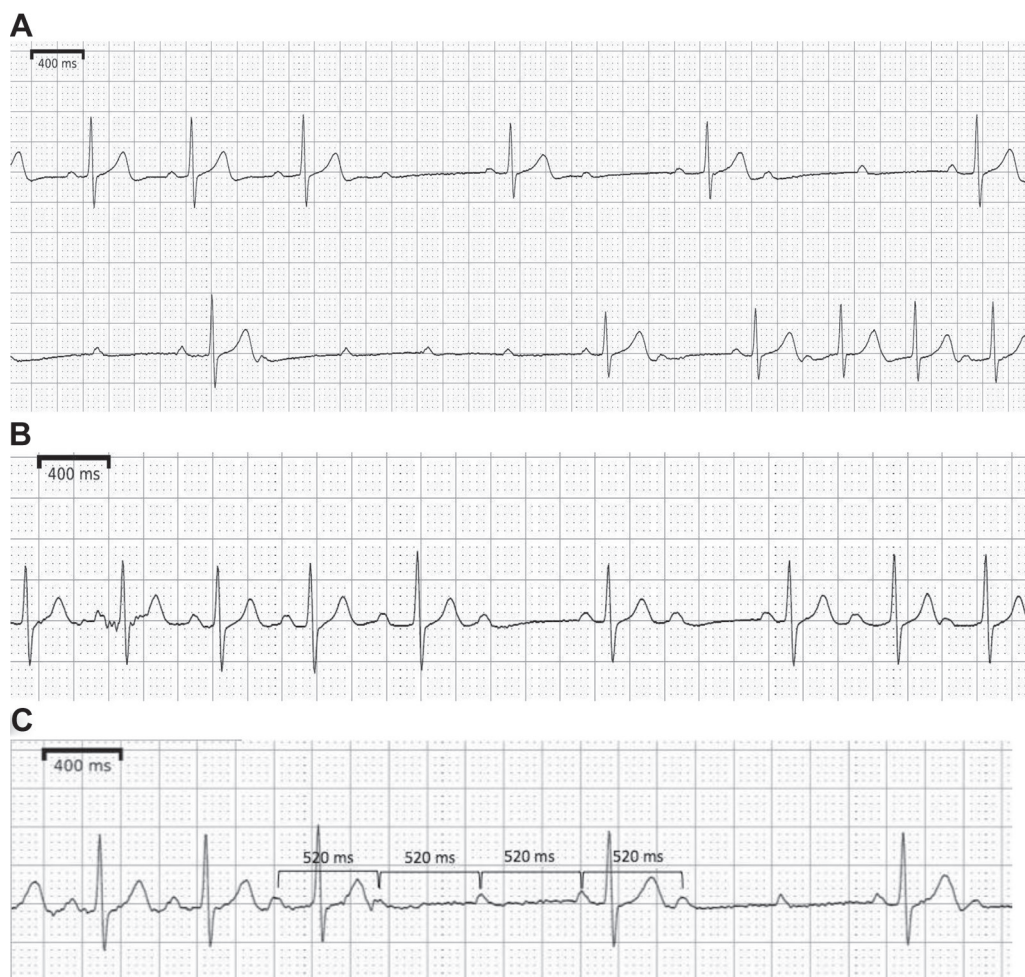


Figure 1 Ambulatory electrocardiographic recordings showing (A) the rhythm suspected to be advanced, second-degree atrioventricular (AV) block with post block AV conduction variability; (B) an episode of second-degree, Mobitz type I AV block; and (C) a rhythm showing the regularity of the P-wave intervals.

Flecainide, which is contraindicated in patients with AV block, was found to effectively treat the AV junctional tachycardia with exit block. After a year of successful treatment with flecainide, the patient started to experience recurrent episodes of dysrhythmia secondary to noncompliance. Because cryoablation has been shown to effectively treat nonpostoperative junctional tachycardia in the pediatric population, an elective cryoablation of the AV junction was performed, which successfully treated the dysrhythmia.^{14,15} After the EP study, the patient has shown normal cardiac conduction without episodes of AV junctional tachycardia with exit block based on multiple ambulatory heart rhythm monitors recorded over the following year.

Conclusion

Idiopathic AV junctional tachycardia with exit block is a rare arrhythmia in pediatric patients. In this case, AV junctional tachycardia exit block was initially resolved by flecainide and definitively treated by junctional modification with cryoablation. Symptoms of vasovagal syncope persisted and were conservatively managed with increased intake of fluids and salt.

Acknowledgments

The authors would like to thank Albert L. Waldo, MD, PhD, for his critical appraisal of this manuscript. The authors would like to thank Jennifer M. Staley, MLIS, for assisting with the literature review for this manuscript.

References

1. Cannon B, Snyder C. Disorders of cardiac rhythm and conduction. In: Allen HD, Driscoll DJ, Shaddy RE, Feltes TF, eds. *Moss and Adams' Heart Disease in Infants, Children, and Adolescents, Including the Fetus and Young Adult*, 8th ed. Philadelphia, PA: Lippincott Williams & Wilkins; 2013:441–482.
2. Page R, Joglar J, Caldwell M. 2015 ACC/AHA/HRS guideline for the management of adult patients with supraventricular tachycardia: executive summary. *J Am Coll Cardiol* 2016;67:1575–1623.
3. Van Hare G. Supraventricular tachycardia. In: Gillette PC, Garson A, eds. *Clinical Pediatric Arrhythmias*, 2nd ed. Philadelphia, PA: WB Saunders; 1999:113.
4. Watanabe Y. Terminology and electrophysiologic concepts in cardiac arrhythmias. III. Exit block, entrance block, and protection block. *Pacing Clin Electrophysiol* 1978;1:498–509.
5. Ruder M, Davis J, Edler M, Abbott J, Seger J, Scheinman M. Clinical and electrophysiologic characterization of automatic junctional tachycardia in adults. *Circulation* 1986;73:930–937.
6. Rosen K. Junctional tachycardia—mechanisms, diagnosis, differential diagnosis, and management. *Circulation* 1973;47:654–664.
7. Mirowski M, Antonopoulos A, Mower M. Exit block around a junctional pacemaker. *Chest* 1974;65:687–688.

8. Fisch C. Junctional tachycardia with a 2:1 exit block. *Cardiol Rev* 1999;7:172.
9. Barold S, Hayes D. Non-paroxysmal junctional tachycardia with type I exit block. *Heart* 2002;88:208.
10. Kastor J. Digitalis intoxication in patients with atrial fibrillation. *Circulation* 1973; 47:888–896.
11. Spodick D. 4:3 Atrioventricular Wenckebach exit block with (probable) Ashman phenomenon during junctional tachycardia. *Am J Geriatr Cardiol* 2004;13:285.
12. Luca C. Nonparoxysmal AV junctional tachycardia with 2/1 exit block during atrial fibrillation in the absence of digitalis toxicity. The effect of exercise. *Med Interne* 1981;19:247–249.
13. Shin W, Kim S, Oh Y, Jang S, Kim J, Choi M, Lee M, Seung K, Rho T. Pseudoatrioventricular block manifesting as a 2:1 atrioventricular block and advanced atrioventricular block because of concealed junctional ectopic impulses. *J Am Coll Cardiol* 2010;56:e17.
14. Collins K, Van Hare G, Kertesz N, et al. Pediatric nonpost-operative junctional ectopic tachycardia medical management and interventional therapies. *J Am Coll Cardiol* 2009;53:690–697.
15. Pierick A, Muldonado J, Von Bergen N. Junctional ectopic tachycardia localization and procedural approach using cryoablation. *Pacing Clin Electrophysiol* 2017;40:655–660.