

RHINOLOGY

# Septal flip flap for anterior skull base reconstruction after endoscopic resection of sinonasal cancers: preliminary outcomes

## *Septal flip flap per la ricostruzione del basicranio anteriore dopo resezione di tumori nasosinusal: risultati preliminari*

P. BATTAGLIA<sup>1,2</sup>, M. TURRI-ZANONI<sup>1,2</sup>, F. DE BERNARDI<sup>1</sup>, P. DEHGANI MOBARAKI<sup>3</sup>, A. KARLIGKIOTIS<sup>1</sup>, F. LEONE<sup>1</sup>, P. CASTELNUOVO<sup>1,2</sup>

<sup>1</sup> Division of Otorhinolaryngology, Department of Biotechnology and Life Sciences (DBSV), University of Insubria, Varese, Italy; <sup>2</sup> Head and Neck Surgery & Forensic Dissection Research center (HNS&FDRc), DBSV, University of Insubria, Varese, Italy; <sup>3</sup> Section of Otorhinolaryngology, Head and Neck Surgery, Department of Surgery and Biomedical Science, S.M. della Misericordia Hospital, University of Perugia, Italy, Association "Naso Sano" Onlus, Umbria Regional Registry of Volunteers, Corciano, Italy

### SUMMARY

Over the past decade surgery for sinonasal malignancies encroaching into the anterior skull base (ASB) has evolved from open craniofacial resection to the use of minimally invasive transnasal endoscopic approaches. Using these techniques, ASB reconstruction is most often performed in a multi-layer fashion with autologous free grafts (fascia lata or iliotibial tract) which leads to the production of abundant nasal crusting in the postoperative months and discomfort for patients. In carefully selected cases, we propose harvesting a flap from the contralateral nasal septum based on the septal branches of the anterior and posterior ethmoidal arteries (Septal Flip Flap, SFF), which can be rotated to resurface the ASB defect. The exclusion criteria for using the SFF were as follows: cases where the tumour extended to both ethmoid complexes; cases where there was nasal septum or planum sphe-no-ethmoidalis involvement by the disease; cases of sinonasal malignant tumour with multifocal histology. In our tertiary care referral centre, skull base reconstruction using the SFF was performed in four patients; one was affected by ethmoidal teratocarcinoma, one by persistence of sinonasal undifferentiated carcinoma after radio-chemotherapy, another by olfactory cleft esthesioneuroblastoma and the fourth by ethmoidal squamous cell carcinoma. Successful skull base reconstruction was obtained in all four cases without any intra- or post-operative complications. Post-operatively, nasal crusting was significantly reduced with faster healing of the surgical cavity. No recurrences of disease have been observed after a mean follow-up of 15 months. The SFF can be considered as a safe and effective technique for ASB reconstruction with high success rates similar to those obtained with other pedicled flaps. This flap also ensured a faster healing process with reduction of nasal crusting and improvement in the quality of life of patients in the postoperative period. This technique appears to be a safe and effective option for ASB reconstruction after endonasal resection of sinonasal malignancies in selected cases. Larger case series with a longer follow-up are needed to validate the preliminary results obtained with such an innovative and promising surgical technique.

**KEY WORDS:** Cerebrospinal fluid leak • Endoscopic endonasal • Nasoseptal flap • Quality of life • Skull base reconstruction • Sinonasal malignancies

### RIASSUNTO

*Il trattamento chirurgico dei tumori maligni nasosinusal estesi al basicranio anteriore si è evoluto nel corso degli ultimi decenni, passando dalla resezione craniofaciale tradizionale agli approcci endoscopici endonasali. In questi approcci mini-invasivi, il basicranio anteriore viene generalmente ricostruito con tecnica multistrato, utilizzando innesti di materiale autologo (fascia lata o tratto ileo-tibiale), che determinano la produzione di abbondanti crostosità a livello della neocavità chirurgica con conseguente disagio e fastidio per il paziente. In casi selezionati, proponiamo di allestire un lembo di mucopericondrio e mucoperiosio di setto nasale controlateralmente rispetto alla neoplasia, peduncolato sui rami settali delle arterie etmoidali anteriore e posteriore (Septal Flip-Flap, SFF), che può essere ruotato a ricostruire il difetto del basicranio anteriore. Criteri di esclusione per l'allestimento di questo lembo locale sono: tumori con estensione bilaterale ad interessare entrambi i complessi etmoidali; infiltrazione neoplastica del setto nasale e/o del planum sfeno-etmoidale; tumore maligno nasosinusale con istologia potenzialmente multifocale. Nel nostro centro di riferimento di terzo livello, la ricostruzione del basicranio mediante SFF è stata eseguita in 4 pazienti affetti dalle seguenti patologie: teratocarcinoma etmoidale in un caso, persistenza di carcinoma indifferenziato nasosinusale (in esiti di trattamento radio-chemioterapico) in un caso, estesioneuroblastoma della fessura olfattoria in un caso, e carcinoma spinocellulare etmoidale in un caso. Non si sono verificate complicanze intra/post-operatorie, ottenendo il successo della ricostruzione del basicranio nella totalità dei casi. Nel postoperatorio si è osservata una netta riduzione delle crostosità intranasali, con rapida guarigione della neocavità chirurgica. Attualmente, non si sono registrate recidive di malattia, con un follow-up medio di 15 mesi. La ricostruzione del basicranio anteriore mediante SFF si è dimostrata sicura ed efficace, con percentuali di successo elevate, simili a quelle ottenute con altri lembi locali pedunculati. Il SFF garantisce inoltre una maggiore rapidità nel processo di guarigione della plastica del basicranio, con una diminuzione delle crostosità nasali nel postoperatorio e conseguente miglioramento della qualità di vita del paziente. Questa tecnica appare essere valida anche dal punto di vista oncologico per casi estremamente selezionati di tumore maligno nasosinusale. Casistiche più ampie con follow-up a lungo termine sono necessarie per validare i risultati preliminari di questa innovativa e promettente tecnica chirurgica.*

**PAROLE CHIAVE:** Fistola rinoliquorale • Approcci endoscopici endonasali • Lembo nasosettale • Qualità di vita • Ricostruzione del basicranio • Tumori maligni nasosinusal

## Introduction

Endoscopic endonasal resection, when properly planned and in expert hands, has an accepted role with precise indications in the treatment of sinonasal and skull base malignancies<sup>1</sup>. Reconstruction of anterior skull base (ASB) defects remains the most challenging issue in this field with post-operative CSF (cerebrospinal fluid) leak rates ranging from 3.3% to 4.3%<sup>1</sup>.

Various surgical techniques and different materials are employed to repair ASB defects. Free grafts such as nasal mucoperiosteum, iliotibial tract, fascia temporalis and fat tissue are mainly used and have acceptable closure outcomes. However, free grafts, especially extra-nasal tissues placed overlay, are usually not completely integrated thus leading to the production in the postoperative months of abundant nasal crusting with subsequent patient discomfort.

Alternatively, regional pedicled flaps, such as pericranial and temporo-parietal, offer the best results in terms of watertight closure, but harvesting them involves external incisions with the subsequent possibility of cosmetic problems and prolonged hospitalisation<sup>2</sup>.

In certain cases, when the contralateral nasal fossa and the nasal septum are not involved by the disease, several local pedicled flaps harvested from the nasal cavities can be used. In this regard, the introduction of the Hadad nasoseptal flap (NSF) has dramatically decreased rates of postoperative CSF-leak and improved quality of life of patients, reducing post-operative nasal crusting and hospitalisation<sup>2-4</sup>. However, there are some cases where the NSF has a limited application, particularly in reaching defects involving the most anterior portion of the cribriform plate. Furthermore, in revision cases where large sphenoidotomies and/or posterior septectomies have been performed, the pedicle of the NSF could be damaged, precluding its use. Evidently, surgical alternatives to the NSF are required for ASB reconstruction in such cases. This study describes anatomical details and provides surgical notes for harvesting a pedicled flap based on the septal branches of ethmoidal arteries (septal flip flap, SFF) used in the repair of ASB defects after removal of malignant tumours.

## Materials and methods

All patients who underwent endoscopic endonasal resection of sinonasal malignancies were retrospectively reviewed using information retrieved from the database dedicated to skull base procedures of a single Institution. Only patients who underwent skull base reconstruction using the SFF were included.

From an oncological viewpoint, exclusion criteria for SFF utilisation were as follows: cases where the tumour extended on both ethmoid complexes; cases where there was nasal septum or planum sphenothmoidalis involvement by the disease; cases of sinonasal malignant tumour

with multifocal histology (e.g. intestinal-type adenocarcinoma).

From a technical viewpoint, previous nasal septum surgery (e.g. septoplasty) and cauterisation of ethmoidal artery(ies) for epistaxis or other reasons should be considered as restrictions precluding the use of the SFF. On the other hand, previous radiotherapy and/or chemotherapy do not represent contraindications for the harvesting of such a flap. This study was performed in accordance with policies approved by the local Ethics Committee.

### *Surgical technique*

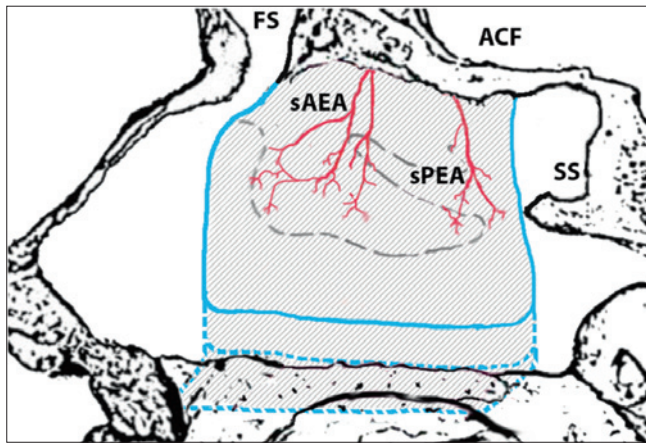
The endoscopic endonasal resection of malignancies encroaching into the ASB has been described elsewhere<sup>5</sup>. The procedure starts with the endoscopic debulking of the sinonasal tumour in order to assess the extent of disease and its origin and exclude any involvement of the nasal septum (cartilage or bone).

A frontal sinusotomy according to Draf type IIb is performed on the same side as the lesion, exposing the first olfactory fibre which represents the anterior limit of the surgical dissection. A wide sphenoidotomy with removal of the sphenoidal rostrum and intersinus septum is then performed, representing the posterior limit of the resection.

Next, subperiosteal dissection of the naso-ethmoidal-sphenoidal complex, together with the removal of the ipsilateral mucoperiosteum and mucoperichondrium of the nasal septum is performed to radically resect the tumour. The septal cartilage and perpendicular plate of the ethmoid are removed, taking care to preserve the contralateral mucoperiosteum and mucoperichondrium. Intraoperative frozen sections of the contralateral nasal septum mucosa are strongly recommended to exclude tumour involvement.

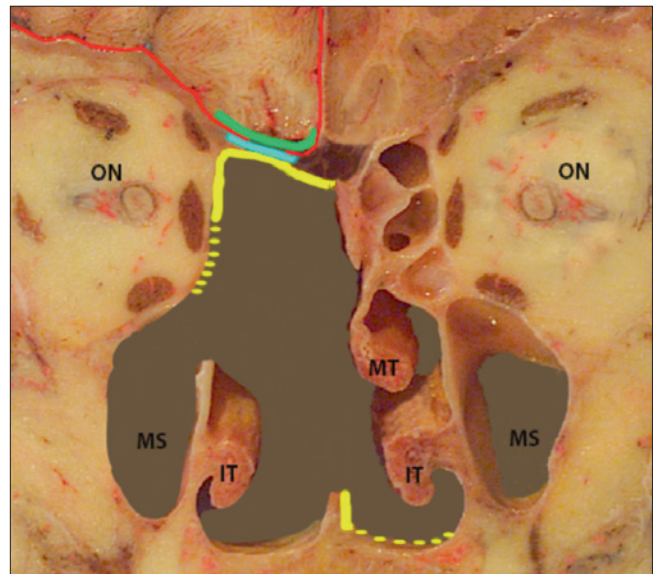
Once the bony ASB is exposed, the anterior and posterior ethmoidal arteries ipsilateral to the tumour are cauterised and divided. Next, the bony ethmoidal roof is drilled out using a diamond burr and the crista galli carefully detached and removed, exposing the dura of the ASB. The epidural gap is gently detached by inserting cottonoid pledgets between the dural layer and the residual borders of the bony ASB. The dura is then circumferentially incised with angled scissors and resected at a safe distance from the suspected area of tumour invasion.

The resulting skull base defect is reconstructed transnasally in a multilayer fashion using free grafts of iliotibial tract. In detail, the first layer is placed intradurally and the second in the epidural gap. The duraplasty is then resurfaced using the SFF. This pedicled flap is based on the septal branches of the contralateral ethmoidal arteries (Fig. 1) and is harvested using the contralateral mucoperiosteum and mucoperichondrium of the nasal septum as follows: the anterior incision starts superiorly at the level of the posterior wall of the frontal sinus and is carried



**Fig. 1.** Anatomical representation of the septal flip flap in sagittal view. The blue lines indicate the incisions on the septal mucoperiosteum/mucoperichondrium for harvesting the flap. The inferior incision (blue dotted line) can be tailored to the size of the skull base defect. Legend: ACF, anterior cranial fossa; FS, frontal sinus; SS, sphenoid sinus; sAEA, septal branches of anterior ethmoidal artery; sPEA, septal branches of posterior ethmoidal artery.

on anteriorly, reaching the frontal beak, and downward reaching the nasal floor. Posteriorly, the incision is made vertically from the sphenoidal planum downward to the nasal floor, paying attention not to damage the soft palate. In this phase, the septal branches of the sphenopalatine artery passing over the nasal choana are cauterised and cut. Finally, the two incisions are connected through a horizontal incision back to front at the level of the contralateral nasal floor, including the inferior meatus if necessary. In this way, the SFF is superiorly hinged and freely rotated to cover the ASB defect as a third layer (Fig. 2). The flap is then properly fixed with fibrin glue and Surgical (Johnson & Johnson Medical, Arlington, TX) and the nasal cavities are packed bilaterally with Merocel 2000 (Medtronic Xomed Surgical Products, Jacksonville, FL)



**Fig. 2.** Anatomical picture in coronal view representing the multilayer reconstruction of an anterior skull base defect. The red line highlights the dural layer; the green line represents the first layer of iliotibial tract (intradural); the blue lines represent the second layer of iliotibial tract (placed in the epidural gap); the yellow line indicates the septal flip flap resurfacing the defect, also covering the exposed orbital content when needed (yellow dotted line).

for about 48 hours. No Foley balloon catheter is needed to buttress the flap.

for about 48 hours. No Foley balloon catheter is needed to buttress the flap.

## Results

Four male patients with a mean age of 49.8 years (range 16-69 years) underwent a SFF for ASB reconstruction after transnasal resection of sinonasal cancer. Patient data are summarised in Table I. Successful skull base recon-

**Table I.** Summary of clinicopathological features of the four patients.

	Patient #1	Patient #2	Patient #3	Patient #4
<b>Age/Sex</b>	44/M	69/M	16/M	67/M
<b>Histopathology</b>	Teratocarcinosarcoma	Persistence of sinonasal undifferentiated carcinoma	Olfactory neuroblastoma	Squamous cell carcinoma
<b>Grading</b>	G2	n.a.	Hyams II	G3
<b>Staging</b>	T3 NO MO	T4b NO MO	Kadish C	T3 NO MO
<b>Side/site of origin</b>	Right/olfactory cleft	Left/ethmoid	Left/olfactory cleft	Left/ethmoid
<b>Previous treatment</b>	Induction chemotherapy (CDDP+ADM)	Chemotherapy (Carboplatin+Taxol) + IMRT (62 Gy)	Induction chemotherapy (VCR+ADM+EDX)	None
<b>Extent of surgery</b>	Unilateral ERTC	Unilateral ERTC	Unilateral ERTC	Unilateral ERTC
<b>Adjuvant therapy</b>	IMRT (60Gy)	None	IMRT (70.2 Gy)	IMRT (62 Gy)
<b>Complications</b>	None	None	None	None
<b>Follow-up</b>	12 months	12 months	18 months	18 months
<b>Patient status</b>	NED	NED	NED	NED

Abbreviations: M, male; n.a., not applicable; CDDP, cisplatin (cis-diamminedichloroplatinum-II); VCR, vincristine; ADM, adriamycin; EDX, cyclophosphamide; ERTC, endoscopic resection with transnasal craniectomy; IMRT, intensity modulated radiotherapy; NED, no evidence of disease.

struction was obtained in all four cases without any intra- or post-operative complications (Fig. 3). Post-operatively, patients were followed-up with multiple endoscopic evaluations at given intervals<sup>5</sup> and nasal toilette with removal of nasal crusting as needed. None of the patients developed necrosis of the flap after adjuvant radiotherapy. Regular follow-up was planned with contrast-enhanced MRI scans at given intervals<sup>5</sup>. Currently, there are no recurrences of disease after a mean follow-up of 15 months.

## Discussion

Various intranasal pedicled flaps have been described for ASB reconstruction following resection of sinonasal cancers with the aim of reducing CSF leak rates and obtaining better outcomes in terms of nasal morbidity<sup>2-4</sup>. Nowadays, the workhorse for such procedures is represented by the NSF which is extensively used in the management of anterior, middle and posterior skull base defects<sup>2-4</sup>.

The SFF described here is an easy to harvest flap, based on the septal branches of the ethmoidal arteries and could be an effective option for ASB reconstruction after malignant tumour removal, offering an alternative to the NSF and giving additional value in its greater coverage of the anterior portion of the ASB defect.

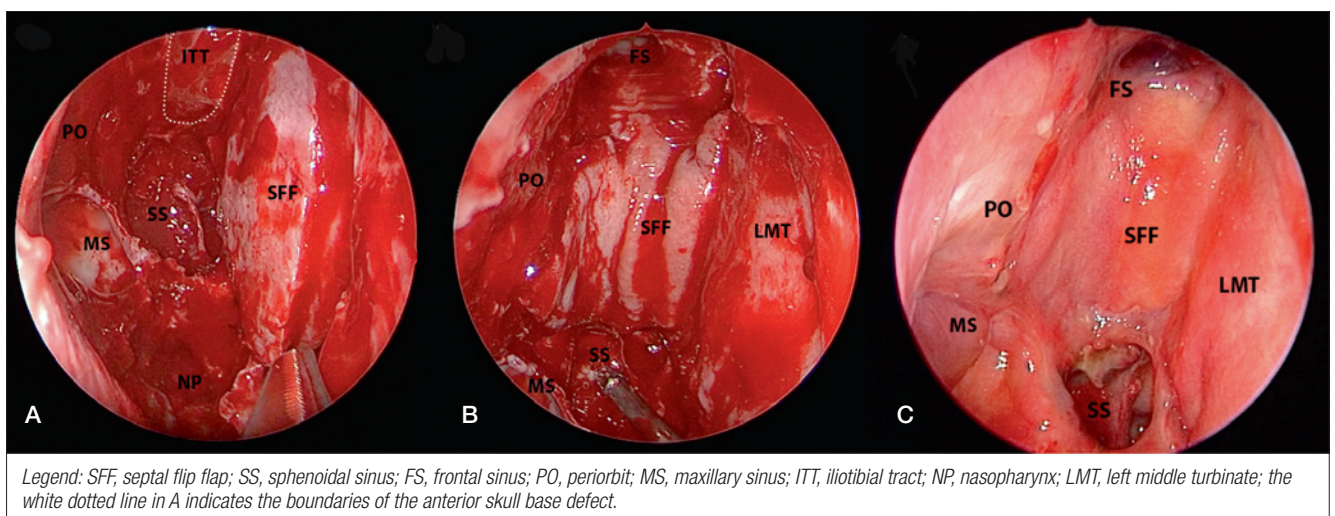
We believe that the SFF can be considered as a safe flap because it is supported by a large pedicle with a strong blood supply that makes it very resilient. In this regard, anatomical studies reported the presence of multiple septal branches coming from the anterior and posterior ethmoidal arteries supplying this flap<sup>6</sup>. From a technical point of view, the removal of the crista galli, with its anterior attachment, represents the key point for the ASB reconstruction, not only for inserting the first two layers

of iliotibial tract, but also for avoiding hindrances while rotating the SFF. In addition, a surgical trick in harvesting the flap is to bring the anterior incision forward to the frontal beak, allowing the resurfacing of very anteriorly extended skull base defects.

Furthermore, it is advisable to keep the contralateral mucoperiosteum and mucoperichondrium of the nasal septum attached and stretched during tumour removal and to harvest the SFF only at the end of tumour resection in order to better tailor its dimensions to the size and extension of the dural defect and the area to be resurfaced. For example, in cases where the removal of the lamina papyracea and periorbit might be necessary, it is possible to extend the SFF to include the mucoperiosteum of the contralateral nasal floor up to the inferior meatus to increase the length of the flap. In this way, the 'extended' SFF is also able to resurface the exposed orbital content.

Similar to what has been observed with other intranasal flaps<sup>7</sup>, we found very encouraging outcomes using the SFF not only in terms of skull base closure, but also in improvement of patients' quality of life. This was especially evident in comparison with extranasal grafts like the iliotibial tract placed overlay. The SFF allows the resurfacing of the surgical cavity with nasal mucosa, preserving the physiological mucociliary clearance and enabling rapid healing with reduction of post-operative crusting.

For these reasons, we believe that in selected cases the SFF might be the most adequate and useful option for ASB reconstruction, even when compared to the Hadad flap, especially in cases of anteriorly extended skull base defects and in conditions where it is necessary to resurface the orbital content. In such situations, the pedicle of



**Fig. 3.** Endoscopic endonasal images of an anterior skull base reconstruction using the septal flip flap (SFF). A) Intraoperative harvesting of the SFF from the septal mucoperiosteum and mucoperichondrium of the left side. There is a visible anterior skull base defect on the right side, extended from the frontal sinus back to the planum sphenoidalis. B) The SFF is rotated to resurface the skull base defect at the end of the surgical procedure. C) Post-operative endoscopic control one month after surgery.

the Hadad flap is too far posterior, limiting the anterior rotation of the flap.

At present, one of the limitations for the use of the SFF may be full-thickness tumour infiltration of the upper part of the nasal septum. In such situations, a conventional NSF, harvested using only the lower portion of the contralateral nasal septum, might possibly be considered a better option.

In every case, multiple intraoperative frozen sections analyses are mandatory to assess the contralateral mucoperiosteum of the nasal septum before its use for ASB reconstruction.

## Conclusions

The SFF is a safe and effective technique for ASB reconstruction with high success rates similar to those obtained using other pedicled flaps. This flap also ensures greater speed in the healing process, with a reduction of nasal crusting and corresponding patient discomfort. This technique appears to be a viable option for ASB reconstruction after endonasal resection of sinonasal malignancies in well-selected cases. Larger case series with a longer follow-up are needed to validate these preliminary results.

## References

- <sup>1</sup> Lund VJ, Stammberger H, Nicolai P, et al. *European position paper on endoscopic management of tumours of the nose, paranasal sinuses and skull base*. *Rhinology Suppl* 2010;22:1-143.
- <sup>2</sup> Hadad G, Bassagasteguy L, Carrau RL, et al. *A novel reconstructive technique after endoscopic expanded endonasal approaches: vascular pedicle nasoseptal flap*. *Laryngoscope* 2006;116:1882-6.
- <sup>3</sup> Clavenna MJ, Turner JH, Chandra RK. *Pedicled flaps in endoscopic skull base reconstruction: review of current techniques*. *Curr Opin Otolaryngol Head Neck Surg* 2015; 23:71-7.
- <sup>4</sup> Thorp BD, Sreenath SB, Ebert CS, et al. *Endoscopic skull base reconstruction: a review and clinical case series of 152 vascularized flaps used for surgical skull base defects in the setting of intraoperative cerebrospinal fluid leak*. *Neurosurg Focus* 2014;37:E4.
- <sup>5</sup> Castelnovo P, Battaglia P, Turri-Zanoni M, et al. *Endoscopic endonasal surgery for malignancies of the anterior cranial base*. *World Neurosurg* 2014;82:22-31.
- <sup>6</sup> Castelnovo P, Ferrel F, Khodaei I, et al. *Anterior ethmoidal artery septal flap for the management of septal perforation*. *Arch Facial Plast Surg* 2011;13:411-4.
- <sup>7</sup> Castelnovo P, Lepera D, Turri-Zanoni M, et al. *Quality of life following endoscopic endonasal resection of anterior skull base cancers*. *J Neurosurgery* 2013;119:1401-9.

Received: June 18, 2015 - Accepted: November 8, 2015

Address for correspondence: Puya Dehgani Mobaraki, Section of Otorhinolaryngology, Head and Neck Surgery, Department of Surgery and Biomedical Science, Santa Maria della Misericordia Hospital, University of Perugia, piazzale G. Menghini, 06100 Perugia, Italy. Fax +39 075 5783236. E-mail: dehganipuya@gmail.com