

HEAD AND NECK

# Evaluation of three-dimensional mandibular movements after reconstruction with free fibula flap

## *Valutazione tridimensionale dei movimenti mandibolari dopo ricostruzione con lembo libero di fibula*

A. BOLZONI<sup>1</sup>, A. MAPELLI<sup>2,3</sup>, A. BAJ<sup>1</sup>, F.V. SIDEQUERSKY<sup>2,3</sup>, A.B. GIANNÌ<sup>1</sup>, C. SFORZA<sup>2</sup>

<sup>1</sup>Maxillofacial and Odontostomatology Unit, IRCSS Fondazione Ca' Granda Ospedale Maggiore Policlinico, Department of Biomedical Surgical and Dental Sciences, Università degli Studi di Milano, Italy; <sup>2</sup>Functional Anatomy Research Center (FARC), Department of Biomedical Sciences for Health, Università degli Studi di Milano, Italy;

<sup>3</sup>Department of Ophthalmology, Otorhinolaryngology, and Head and Neck Surgery, School of Medicine, Ribeirão Preto, University of São Paulo, Brazil

### SUMMARY

Seven patients who underwent mandibular reconstruction with a fibula free flap (one on the midline, six on either right or left side) and were rehabilitated with implant supported prostheses, performed free mandibular border movements (maximal mouth opening and closing, right and left lateral excursions, protrusion) that were recorded by a non-invasive motion analyser. Temporomandibular joint (TMJ) kinematic parameters were compared to those calculated in healthy control subjects using z-scores. Maximum mouth opening was reduced in all patients, with z-scores ranging from -2.742 to -0.106, and performed with a reduced sagittal plane mandibular rotation. Interincisal point forward movement during protrusion was reduced in all but one patient. Lateral mandibular movements (displacement of the interincisal point) and bilateral condylar movements during mouth opening were very variable and sometimes asymmetrical. Mandibular rotation was also variable, with z-scores ranging from -1.265 to 1.388. Together with mandibular range of motion, we investigated biomechanical characteristics of TMJ motion that can provide further information about the joint without submitting the patient to harmful procedures, and that can be followed-up during healing. The investigation indicates those areas that need to be given special attention in preoperative planning, patient information and rehabilitation.

KEY WORDS: Fibula free flap • Temporomandibular joint • Border movements • Motion analysis

### RIASSUNTO

*In questo studio sono stati analizzati sette pazienti a cui è stata ricostruita la mandibola utilizzando un lembo libero di fibula. Un paziente è stato operato medialmente e gli altri sul lato destro o sinistro. I pazienti sono stati riabilitati con protesi su impianti, ed hanno eseguito una serie di movimenti limite mandibolari (massima apertura e chiusura della bocca, laterotrusioni destra e sinistra, protrusione), che sono stati registrati nelle tre dimensioni dello spazio da un sistema non invasivo di analisi del movimento. I relativi parametri cinematici dell'articolazione temporomandibolare sono stati confrontati con quelli ottenuti in un gruppo di soggetti sani di controllo utilizzando gli z-score. La massima apertura della bocca è risultata ridotta in tutti i pazienti, con z-scores compresi tra -2.742 e -0.106, ed è stata effettuata con una minore rotazione mandibolare sul piano sagittale. In tutti i pazienti salvo uno si è rilevata una riduzione del movimento del punto interincisale durante la protrusione. Nei pazienti, i movimenti del punto interincisivo in laterotrusione e i movimenti condilari durante l'apertura della bocca sono risultati molto variabili e talvolta asimmetrici. Anche la rotazione mandibolare è risultata molto variabile, con z-scores compresi tra -1.265 e 1.388. Insieme all'ampiezza dei movimenti, sono state indagate alcune caratteristiche biomeccaniche dell'articolazione, che possono fornire informazioni relativamente ai capi articolari senza sottoporre i pazienti a procedure pericolose. Le valutazioni possono essere eseguite longitudinalmente durante il follow-up. I dati forniti da questo studio indicano quali aree facciali e quali strutture devono essere attentamente valutate durante la pianificazione preoperatoria, nell'illustrazione dei problemi al paziente e durante la riabilitazione.*

PAROLE CHIAVE: Lembo libero di fibula • Articolazione temporomandibolare • Movimenti limite • Analisi del movimento

Acta Otorhinolaryngol Ital 2015;35:371-378

### Introduction

During the past decade, the free fibula flap (FFF) has become the method of choice for reconstruction of major mandibular and maxillary defects<sup>1,2</sup>. When compared to several microvascular transplant options, fibular bone best matches the properties of the jaws, and its ample length

allows bone reconstruction after extended resections<sup>2,4</sup>. Skeletal and cutaneous components can be harvested as a single composite flap, thus allowing simultaneous replacement of bone and soft tissue defects<sup>5</sup>. Donor site morbidity has been described as mild, without a significant decrease in lower limb performance<sup>3</sup>. In

particular, no functional limitations during gait and stair performance has been found<sup>6</sup>.

Oral function and postoperative facial aesthetics have a major impact on the patient's perception of outcome after ablative surgery. Numerous investigations have been carried out to assess function and quality of life after head and neck tumour resection through validated questionnaires and clinical measurements<sup>7-14</sup>. In general, long term follow-up studies judged facial appearance, speech, food tolerance and deglutition to be satisfactory<sup>15</sup>.

In these studies, patient outcome after surgical reconstruction with a FFF was mainly evaluated according to clinician-rated observations. Objective assessments, made with actual measurements, were rarely provided. In particular, no quantitative investigations about the biomechanical characteristics of the temporomandibular joint (TMJ) have been made. Biomechanical investigations permit a closer assessment of the motional characteristics of this complex joint, dividing overall movement into its gliding and rotational components that can be measured and eventually followed-up during healing<sup>16-18</sup>.

In our laboratory, we have devised a method for the three-dimensional detection, reconstruction and measurement of TMJ motion characteristics, and data about normal subjects, as well as surgical and dental patients, have been published<sup>16-19</sup>. Free mandibular movements are recorded by an optoelectronic digitiser that detects the three-dimensional position of several oral and extraoral landmarks. The instrument and measurement protocol involve minimal interference to natural jaw motion, allowing data collection in a very natural condition<sup>16</sup>. The only require-

ment is the presence of teeth in the central portion of the mandibular dental arch, where a small framework is fixed to allow detection of mandibular movements.

The aim of the current study was to quantitatively assess the kinematic characteristics of free mandibular movements in patients who underwent mandibular bone reconstruction with a FFF. These data can quantify alterations in mandibular movements after reconstruction, thus guiding the choice of the best surgical, prosthodontic and functional treatments.

## Materials and methods

### Patients

Between 2005 and 2014, 28 patients underwent reconstruction of the mandibular or maxillary region with FFF at the Department of Maxillo Facial Surgery at the Policlinico Hospital of Milan and Galeazzi Institute of Milan. Seven of these patients (four men, three women, age range 17-67 years, 25% of the initial group), who had a reconstruction in their mandible, agreed to participate in the present study (Table I). Follow-up time ranged from 9 to 32 months. At the time of data collection, all participants were rehabilitated with dental prostheses, and did not report major problems in mastication or mandibular movements. The remaining patients were excluded due to lack of central mandibular teeth, refusal to participate, moving from the area, or death. Four patients (F2, M1, M4, M5) underwent adjuvant radiotherapy. M1 was also submitted to adjuvant chemotherapy. Prior to surgery, M4 had a pathological fracture of the mandibular body, and M5 was in trismus; the pathology did not involve the TMJ in any case.

**Table I.** Anthropometric data, follow-up time and surgical data.

Patients	Age (y)	Follow-up (months)	Pathology	Soft tissue sacrifice	Neck dissection	Adjuvant therapy (RT/CT)	FFF type/side	Reconstructed Segment	Reconstruction technique
F2	67	24	Spinocellular carcinoma recurrence	Alveolar mucosa	MRND Left	RT	OC right	Mandibular body left	Manual flap remodelling
F3	56	32	Fibroma ossificans	No	No	No	O left	Symphysis, mandibular body left	Manual flap remodelling
F4	37	9	Ameloblastoma	No	No	No	O right	Mandibular body, ramus right	Computerised virtual planning; custom made plate
M1	17	11	Osteosarcoma	No	No	CT	O left	Mandibular body, ramus left	Preplating
M2	38	12	Fibrous dysplasia	No	No	No	O right	Symphysis + canine teeth	Preplating
M4	59	32	Spinocellular carcinoma	Alveolar mucosa	SOHND right	RT	O right	Mandibular body right	Preplating
M5	58	12	Spinocellular carcinoma	Alveolar mucosa, cheek, oral pelvis	MRND right	RT	OMC left	Mandibular body, ramus right	Manual flap remodelling
Mean	47	19							
SD	17	10							

MRND: modified radical neck dissection; SOHND: supra-omohyoid neck dissection; RT: radiotherapy; CT: chemotherapy; O: bone flap, OC: osteocutaneous flap, OMC: osteomyocutaneous flap.

All patients were informed in detail about the study and signed an informed form. The patient under 18 years provided verbal consent and signed consent was provided by his parents. Approval was obtained by the local ethics committee. All procedures were non-invasive, and did not cause pain or discomfort.

Data were compared with those collected in healthy subjects, who had a complete permanent dentition, no TMJ or craniocervical disorders, no anterior or lateral reverse occlusion and no previous history of craniofacial surgery, trauma, or congenital anomalies. Some of these data have been previously published<sup>16-19</sup>.

#### *Surgical technique*

Careful anamnesis was collected, angiography of the legs and disease staging were performed and patients were submitted to surgery in a single session. Six patients underwent only bone resection with a minimum sacrifice of soft tissue, while soft tissue resection included the retro-molar trigon, floor of the mouth and gingivae in only one case (M5). No patient had condylar resections, and the TMJ capsule was respected in all cases (Table I). Three patients received neck treatment: two had a MRND III and one had a selective SOHND.

In all patients, the FFF harvests were performed with a lateral approach<sup>20</sup>, including only minimal muscle cuff around the fibula to ensure preservation of periosteal circulation. In particular, the surgical technique devised by Baj et al.<sup>21</sup> was used. FFF was harvested from the left or right leg after study of the leg's vessels. Generally, the fibula ipsilateral to the facial lesion was used when only bone defects had to be reconstructed (patients F3, F4, M1, M4), while the contralateral fibula was used when osteocutaneous or osteomyocutaneous defects were present (patients F2, M3, M5). In patients with a midline defect (F1, M2), the lower limb with the most suitable vessels was used.

The fibula was osteotomised proximally and distally, preserving 6 cm of bone on either side to maintain knee and ankle stability. To preserve great toe flexion function, the flexor hallucis longus muscle was sutured to the tibialis posterior muscle and to the remaining interosseous membrane with proper tension.

A FFF was used for mandibular reconstruction in all patients, and the flaps were modelled individually as necessary<sup>2</sup>. In particular, in three cases a preplating technique was used to facilitate fibular modelling, while in patient F4 a computerised virtual reconstruction was made. F2, F3 and M5 had an altered mandibular contour, and manual remodelling was performed. In these patients, a preliminary intermaxillary fixation and a clinical condyle repositioning were used to permit correct occlusal relationships. For bone fixation, a custom-made plate was used in patient F4, while in the other patients 2.0 mini-plates were used.

Mandibular tumour ablations were performed taking care to preserve the facial vessels for the subsequent graft anas-

tomoses. The pedicle length was defined by the length of the bone necessary for the reconstruction. For mandibular reconstruction, the cheek was tunnelled above the periosteum at the level of the mandibular ridge. Vascular anastomoses were made between the peroneal and facial arteries and between one of the satellite veins and facial vein.

When only bone was harvested, the skin wound of the donor site was closed primarily, while the other donor sites received split thickness skin grafts.

The donor sites with skin graft received splints with the ankle at 90° for 10 days, in the other occasions splints were not applied. At 1-2 weeks after surgery, all patients started lower limb rehabilitation with the physiotherapist, and 15 days after surgery they started rehabilitation of mandibular movements.

Two patients (M3, M4) were rehabilitated with implant support prostheses and the others had removable prostheses.

#### *Data collection*

The data collection procedure has been previously defined in our laboratory<sup>16-19</sup>. Free mandibular border movements (maximal mouth opening and closing, right and left lateral excursions, and protrusion) were made by patients and recorded using a motion analyser with a 60 Hz sampling rate (SMART System, BTS S.p.a., Garbagnate Milanese, Italy). Before each acquisition session, metric calibration and correction of optical and electronic distortions were made. During data collection, the patient sat on a stool without backrest, facing six high-resolution infrared sensitive charge-coupled device video cameras. The cameras define a working volume of 77 (width) cm × 66 (height) cm × 77 (depth) cm that contains the face of the patient. The cameras are coupled with a video processor, and during the execution of the movements the coordinates of the centroid of a set of passive retroreflective markers are obtained by the system, and converted to metric data. Therefore, in each frame that constituted the movement, a set of three-dimensional (XYZ) coordinates was obtained for each marker. Mean dynamic accuracy and precision indices were lower than 0.15 mm.

A set of nine 6-mm spherical markers was used: three cranial markers identified nasion, right and left frontotemporale (cranial reference plane); three mandibular markers (mandibular plane) were positioned on an extra-oral triangular framework fixed on the gingiva at midline level using surgical adhesive (Stomahesive; Convatec Inc., Deeside, United Kingdom); one marker identified the midline of the mandibular incisal edge (interincisal point), and two markers were positioned on the cutaneous projections of the right and left lateral condylar poles. The local coordinates (relative to the mandibular reference system) of the last three markers were recorded in two static acquisitions: one with open mouth, for the interincisal point; the other with closed mouth, for the condylar poles. Next, their positions during actual mandibular borders movements were virtu-

ally reconstructed relative to the cranial reference system using the movements of the mandibular plane<sup>16-18</sup>.

Each patient performed three repetitions per movement, and mean values were computed.

The method error of mandibular movements had already been assessed, without significant differences among repeated sessions<sup>18</sup>.

*Data analysis*

At first, all coordinates were referred to the cranial reference plane, thus mathematically eliminating head and neck movements. Mandibular width (unit: mm) was estimated as the distance between the right and left condylar markers after subtracting the two markers' radii; mandibular length (unit: mm) was estimated as the distance between the dental marker (interincisal point) and the midpoint of the intercondylar axis<sup>16 18</sup>.

Mandibular movements were described by reconstructed motions of the interincisal and condylar points. In each motion frame, the rotation angles made by the mandible around the three cranial axes were calculated using Cardan angles. The range of mandibular movements (interincisal point) was assessed at maximum mouth opening, right and left lateral excursions, and protrusion (unit: mm). At maximum mouth opening, the sagittal mandibular angle was calculated (unit: degree), as well as the right and left total condylar translations, both as absolute distance (unit: mm) and relative percentage, standardised with their concomitant rotation (unit: %)<sup>16 18</sup>.

*Statistical analysis*

To better assess the clinical significance of data, all right and left values (of laterality or condyle) were referred to "operated" and "not operated" side. One patient (M2) was submitted to midline surgery: conventionally, his right side was considered as "not operated".

Patient data were compared to those collected in healthy volunteers<sup>16-19</sup> by computing z-scores. The individual measurements obtained in the seven patients were transformed to z scores by subtracting from each value its sex reference mean value and dividing by the relevant reference standard deviation.

The z-score measures the difference between a single patient value and its reference value in terms of standard deviation: negative values indicate that the patient value is minor than the reference mean value, while positive values indicate the opposite. Z-scores comprised between -2 and 2 indicate that the patient value is within 2 SD of the reference value, while values outside this interval indicate larger deviations from the norm.

Descriptive statistics (mean and standard deviation) were computed for the values of the z-scores.

**Results**

No patients developed significant complications at donor or recipient sites. Mandibular movements were assessed in the patients after a mean follow-up of 19 months (SD 10). At the interview before data collection, no patient reported difficulty in performing daily activities such as talking, eating, or drinking. Additionally, no significant weight loss was observed after surgery. Only patient F2 lamented slight difficulty in speech, but reported a good mastication especially after implant rehabilitation.

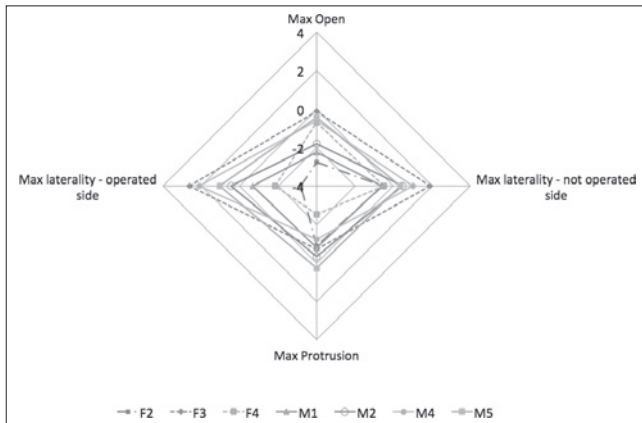
All patients could perform the movements without major impairments or problems. On average, mandibular length was smaller and mandibular width larger than in reference subjects (Table II). In particular, the mandible in patients M2 and M5 was about 4 SD wider than that of reference men.

Maximum mouth opening was reduced in all patients, with z-scores ranging from -2.742 (F2) to -0.106 (F3,

**Table II.** Kinematic characteristics of patients during the execution of mandibular border movements compared with the healthy control group.

Patients	Mandible		Max mouth open		Absolute translation open		Relative translation open		Maximal laterality		Protrusion (mm)
	Length (mm)	Width (mm)	Distance (mm)	Sagittal angle (°)	Not operated (mm)	Operated (mm)	Not operated (%)	Operated (%)	Not operated (mm)	Operated (mm)	
F2	72.3	125.2	26.2	21.6	10.5	8.8	28	24	6.9	2.7	5.8
F3	85.1	112.7	43.6	30.6	12.3	13.1	28	27	10.1	15.9	6.1
F4	88.0	115.0	39.7	30.1	14.1	15.2	23	25	7.0	5.1	3.0
M1	70.4	118.5	33.5	23.8	8.8	9.7	23	25	5.9	4.6	4.0
M2	84.1	138.4	36.8	18.8	11.4	15.1	29	35	9.0	9.2	5.6
M4	83.7	132.6	45.8	30.0	15.1	12.4	23	22	10.8	16.0	2.5
M5	81.8	140.5	47.1	30.3	20.6	22.9	32	35	8.8	11.7	7.6
Z-scores											
Mean	-0.988	1.441	-1.230	-1.036	0.208	-0.796	0.008	0.128	0.151	0.296	-0.887
SD	1.221	2.520	1.018	0.830	1.404	3.025	1.005	1.042	0.690	2.460	0.866

Z-score values were obtained using sex-specific reference data collected in our laboratory<sup>16-19</sup>.



**Fig. 1.** Z-scores of the interincisal point excursions in each patient's maximal mandibular border movements.

Fig. 1), and it was performed with a reduced sagittal plane mandibular rotation (Fig. 2). Two patients (F2, M1) had a reduction in mouth opening larger than 2 SD. In general, patients submitted to radiotherapy had a larger reduction in mouth opening.

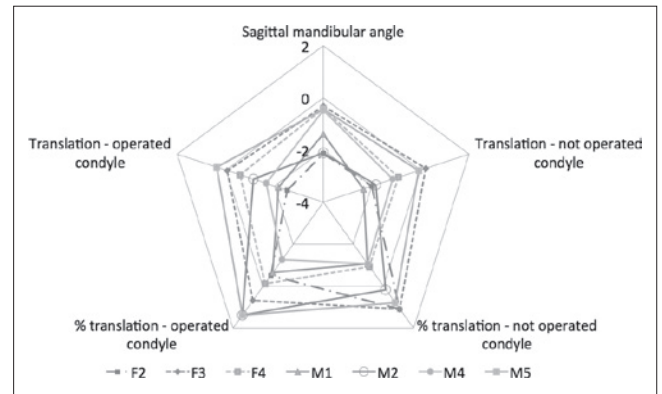
Focusing on condylar translation during mouth opening, patients F2 and M1 had a particularly reduced absolute translation (z-scores smaller than -2). Patients M3 and M4 showed a notable asymmetry, one with a larger movement of the condyle of the side that was not operated on (M3), and the other with the opposite performance. In general, patients submitted to radiotherapy had a larger reduction in condylar translation.

Interincisal point forward movement during protrusion was reduced in all but one patient (M5). Overall, lateral mandibular movements (displacement of the interincisal point) were very variable; those towards the not operated side were somewhat reduced in three patients, and increased in the other four. Those towards the operated side had an increased movement, larger than 2 SD, in M4 and F3, and a remarkable reduction in F2 (z-score = -3.167). Overall, if only the distance variables are considered, on average, only one patient had remarkably reduced motion than the reference subjects (F2, mean z-score for motion components -1.975), while all the other patients had mean limitations smaller than 1.5 z-scores.

## Discussion

Current surgical treatment of patients with carcinoma of the oral cavity must include both the aim of complete tumour removal, and the maintenance of an acceptable quality of life through immediate and definitive reconstruction. Reconstruction should consider both function (speaking, feeding, swallowing) and aesthetics at the same time<sup>15</sup>.

Fibular free flaps are considered the first choice for mandibular or maxillary reconstruction of extensive defects



**Fig. 2.** Z-scores of the maximum mouth opening components in each patient. Condylar translations are reported for both operated and non-operated sides.

or to cover simultaneously soft-tissue defects<sup>1,21</sup>. The FFF possesses several favourable characteristics: the vascular pedicle, peroneal artery and its venae comitans are constant and with sufficient length and size. The bone is of exceptional quality, allowing for multiple segmental osteotomies for contouring, and it is of sufficient thickness for the subsequent positioning of dental implants. Primary insertion of osseointegrated implants can be reliably performed, but only in selected patients with benign disorders that do not need adjuvant post-surgical radiotherapy, good health and favourable prognosis<sup>22,23</sup>. Indeed, in the current patients oral rehabilitation was performed in a second occasion, with either mucosal-supported or implant-supported prostheses, as recently suggested<sup>2</sup>.

The fibula, however, is usually unable to establish adequate alveolar height, especially for mandibular reconstructions. In patients in whom osseointegrated implants are planned, several manoeuvres should be considered in both jaws. The fibula should be placed about 0.5 to 1 cm above the inferior border of the native mandible, closer to the superior alveolar edge to facilitate placement of implants<sup>22,24</sup>. In most cases, the overlying soft tissue is able to camouflage the inferior border irregularities. A double barrel fibula can also be used<sup>25</sup>. Finally, vertical distraction osteogenesis of the fibular segment can be used to increase its height.

Many studies in literature have evaluated FFF donor site morbidity through questionnaires and quantitative methods such as balance tests and gait analysis<sup>6,26</sup>. The results achieved in these studies have been exceeding satisfactory: today, the FFF is one of the most widely performed free flaps for the reconstruction of defects in the oral cavity involving bone and soft tissue.

Moreover, several retrospective studies have been carried out to investigate the post-operative outcome of oral cavity reconstruction with FFF<sup>27</sup>. In these studies, assessment of the recipient site was evaluated with clinical evaluation and questionnaires.

The most common problems reported by patients after surgery are difficulty in swallowing, chewing and speech. Shpitzer et al.<sup>1</sup> reported that about 37% of 48 patients had problems with deglutition after FFF reconstruction, while Hidalgo and Pusic<sup>28</sup> described that 30% of 19 patients had problems with mastication after receiving a FFF.

Indeed, the literature lacks studies with objective, quantitative assessments for mandibular function after FFF surgery. In the current investigation, we collected free mandibular movements in a small group of patients using a three-dimensional computerised motion analyser. We applied a previously devised method that had already been employed to assess normal subjects, surgical and dental patients<sup>16-19</sup>.

The method is non-invasive, but requires the presence of teeth in the central portion of the mandibular dental arch. This constraint limited the assessment to a restricted number of patients, and we are currently investigating novel systems to position and fix the small framework necessary for the detection of mandibular movements.

Considering the pilot nature of the current study, it is difficult to estimate differences in percentage of postoperative complications. Additionally, no information about the presurgical biomechanical characteristics of the patients' TMJ was available, and some of the post-surgical differences may be related to individual anatomical (mandibular dimensions) and functional (mandibular range of motion, TMJ biomechanics) features<sup>18</sup>. Also, control subjects were younger than most of the patients analysed in the current study, but no previous studies about the effect of aging on the biomechanical characteristics of the TMJ has been reported.

Nonetheless, some of the quantitative data found in the current study can be related to the clinical situation of each patient. In general, maximum mouth opening was reduced in all patients, but the worst results were reported for patient F2. Indeed, she had undergone three previous surgical treatments for squamous cell carcinoma of the oral cavity that were performed without reconstruction, as well as adjuvant radiotherapy.

Repeated surgical intervention, muscle dissection and resection, and radiotherapy provoked the formation of substantial scar tissue. Scars are a major cause of morbidity in the recipient site, and scar tissue often replaces many mandibular and lingual muscles that are cut during surgery and often sacrificed together with the tumour mass. This repair tissue leads to loss of the functional properties of muscles and reduces the elasticity of the oral mucosa<sup>15</sup>. Radiotherapy does not help tissue healing, favouring the formation of an inelastic tissue<sup>29</sup>. Fortunately, in only one patient did this complication occur causing slight difficulties in speech.

Lateral mandibular movements (displacement of the interincisal point) and bilateral condylar movements during mouth opening were very variable and sometimes asym-

metrical in the patients analysed, even in M2 who was operated on the midline. Considering that his left side was arbitrarily set as "operated", we also re-made all calculations changing the side, but no particular differences were observed (data not shown).

Together with mandibular range of motion, the current study investigated biomechanical characteristics of TMJ motion that can provide further information about the joint, and that can be followed-up during healing without submitting the patient to harmful procedures<sup>16-18</sup>. Indeed, the major variations in mandibular rotation were observed for patients F2 and M2. This last was operated at his symphysis, a region where no masticatory muscles insert, and that is not involved in TMJ or in its ligaments. Indeed, during surgical removal of oral cavity cancers many muscles like the mylohyoid, the digastric or the extrinsic tongue muscles are resected, or even radically dissected during a concomitant neck dissection. Anatomical reconstruction of muscle insertions should be made whenever possible; nonetheless, this destructive surgery and the subsequent scars can potentially reduce mandibular movements.

Currently, no clear clinical information is available about the medium- or long-term implications of alterations in TMJ rotation and translation characteristics. Previous studies found an increased rotation component in patients operated on for condylar fractures<sup>18</sup>, and in patients submitted to orthognathic surgery for either skeletal Class II or III malformations<sup>17</sup>. Surgical intervention and modifications of the biomechanical characteristics of the facial skeleton and muscles may play a role in these alterations.

One additional limitation of the current study is the lack of chewing assessments, the actual function of the stomatognathic system that should be tested in the patients<sup>19,30</sup>. Indeed, in the current study, we only interviewed patients about their possible limitation for alimentation, but did not use any structured questionnaire that may help in better defining their actual situation<sup>19,30</sup>. Future studies should also involve the assessment of mandibular kinematics during mastication of standardised test foods.

It is clear that surgery (ablation of the tumour and reconstruction with a FFF)<sup>31,32</sup> is just one of the interventions that may alter TMJ function, and other aspects should be considered, starting from radiotherapy. Some differences were observed in the current group of patients, with a general increased reduction in mouth opening and condylar translation in the patients submitted to radiotherapy relative to those who did not receive this treatment. This topic should be specifically investigated in a larger number of patients. Indeed, a specifically devised rehabilitative intervention may concur to improve the follow-up efficacy of a successful surgical approach.

## Conclusions

The current investigation confirms the value of using FFF in mandibular reconstruction. Valuable insight is provided into areas that need to be given special attention in preoperative planning, patient information and rehabilitation. Moreover, the functional and cosmetic dimensions of reconstruction need to be considered carefully in preoperative planning.

The small size of the current group of patients does not allow comparison of the alterations of mandibular movements with the reconstructed portion of the oral cavity: this is one of the aims of forthcoming studies. One additional target of our future investigations is the effect of concomitant treatments: in particular, the additional tissue damages caused by radiotherapy should be assessed.

## Acknowledgements

A. Mapelli and F.V. Sidequersky are currently receiving a grant (Atração de Jovens Talentos – Pesquisador Colaborador no Brasil – BJT – Programa Ciência Sem Fronteiras) from the Ministério da Ciência e Tecnologia – MCT Conselho Nacional de Desenvolvimento Científico e Tecnológico – CNP.

## References

- Shpitzer T, Neligan PC, Gullane PJ, et al. *The free iliac crest and fibula flaps in vascularised oromandibular reconstruction: comparison and long-term evaluation*. *Head Neck* 1999;21:639-47.
- Hakim SG, Kimmerle H, Trenkle T, et al. *Masticatory rehabilitation following upper and lower jaw reconstruction using vascularised free fibula flap and enossal implants-19 years of experience with a comprehensive concept*. *Clin Oral Investig* 2015;19:525-34.
- Shpitzer T, Neligan PC, Gullane PJ, et al. *Oromandibular reconstruction with the fibular free flap. Analysis of 50 consecutive flaps*. *Arch Otolaryngol Head Neck Surg* 1997;123:939-44.
- Seikaly H, Chau J, Li F, et al. *Bone that best matches the properties of the mandible*. *J Otolaryngol* 2003;32:262-5.
- Wei FC, Seah CS, Tsai YC, et al. *Fibula osteoseptocutaneous flap for reconstruction of composite mandibular defects*. *Plast Reconstr Surg* 1994;93:294-304.
- Baj A, Lovecchio N, Bolzoni A, et al. *Stair ascent and descent in assessing donor site morbidity following osteocutaneous free fibula transfer. A preliminary study*. *J Oral Maxillofac Surg* 2015;73:184-93.
- Bundgaard T, Tandrup O, Elbrønd O. *A functional evaluation of patients treated for oral cancer. A prospective study*. *Int J Oral Maxillofac Surg* 1993;22:28-34.
- Haribhakti VV, Kavarana NM, Tibrewala AN. *Oral cavity reconstruction: an objective assessment of function*. *Head Neck* 1993;15:119-24.
- Bjardal K, Ahlner-Elmqvist M, Tolleson E, et al. *Development of a European Organization for Research and Treatment of Cancer (EORTC) questionnaire module to be used in quality of life assessments in head and neck cancer patients*. *EORTC Quality of Life Study Group*. *Acta Oncol* 1994;33:879-85.
- Schliephake H, Schmelzeisen R, Schönweiler R, et al. *Speech, deglutition and life quality after intraoral tumour resection. A prospective study*. *Int J Oral Maxillofac Surg* 1998;27:99-105.
- Rogers SN, Lowe D, Fisher SE, et al. *Health-related quality of life and clinical function after primary surgery for oral cancer*. *Br J Oral Maxillofac Surg* 2002;40:11-8.
- Rogers SN, Lowe D, Patel M, et al. *Clinical function after primary surgery for oral and oropharyngeal cancer: an 11-item examination*. *Br J Oral Maxillofac Surg* 2002;40:1-10.
- Hara I, Gellrich NC, Duker J, et al. *Swallowing and speech function after intraoral soft tissue reconstruction with lateral upper arm free flap and radial forearm free flap*. *Br J Oral Maxillofac Surg* 2003;41:161-9.
- Zhu J, Xiao Y, Liu F, et al. *Measures of health-related quality of life and socio-cultural aspects in young patients who after mandible primary reconstruction with free fibula flap*. *World J Surg Oncol* 2013;2:11:250.
- Shujaat S, Khambay BS, Ju X, et al. *The clinical application of three-dimensional motion capture (4D): a novel approach to quantify the dynamics of facial animations*. *Int J Oral Maxillofac Surg* 2014;43:907-16.
- Mapelli A, Galante D, Lovecchio N, et al. *Translation and rotation movements of the mandible during mouth opening and closing*. *Clin Anat* 2009;22:311-8.
- Sforza C, Ugolini A, Rocchetta D, et al. *Mandibular kinematics after orthognathic surgical treatment a pilot study*. *Br J Oral Maxillofac Surg* 2010;48:110-4.
- Sforza C, Ugolini A, Sozzi D, et al. *Three-dimensional mandibular motion after closed and open reduction of unilateral mandibular condylar process fractures*. *J Craniomaxillofac Surg* 2011;39:249-55.
- De Felício CM, Mapelli A, Sidequersky FV, et al. *Mandibular kinematics and masticatory muscles EMG in patients with short lasting TMD of mild-moderate severity*. *J Electromyogr Kinesiol* 2013;23:627-33.
- Gilbert A. *Vascularized transfer of the fibular shaft*. *Int J Microsurg* 1979;1:100-9.
- Baj A, Beltramini GA, Massarelli O, et al. *Minimally invasive harvest of free fibula flap*. *Plast Reconstr Surg* 2013;131:474e-7e.
- Kildal M, Wei FC, Chang YM, et al. *Mandibular reconstruction with fibula osteoseptocutaneous free flap and osseointegrated dental implants*. *Clin Plast Surg* 2001;28:403-10.
- Chang YM, Coskunfirat OK, Wei FC, et al. *Maxillary reconstruction with a fibula osteoseptocutaneous free flap and simultaneous insertion of osseointegrated dental implants*. *Plast Reconstr Surg* 2004;1;113:1140-5.
- Sclaroff A, Haughey B, Gay WD, et al. *Immediate mandibular reconstruction and placement of dental implants. At the time of ablative surgery*. *Oral Surg Oral Med Oral Pathol* 1994;78:711-7.
- Horiuchi K, Hattori A, Inada I, et al. *Mandibular recon-*

- struction using the double barrel fibular graft. *Microsurgery* 1995;16:450-4.
- <sup>26</sup> Lin JY, Djohan R, Dobryansky M, et al. *Assessment of donor-site morbidity using balance and gait tests after bilateral fibula osteoseptocutaneous free flap transfer* *Ann Plast Surg* 2009;62:246-51.
- <sup>27</sup> Hölzle F, Kesting MR, Hölzle G, et al. *Clinical outcome and patient satisfaction after mandibular reconstruction with free fibula flaps*. *Int J Oral Maxillofac Surg* 2007;36:802-6.
- <sup>28</sup> Hidalgo DA, Pusic AL. *Free-flap mandibular reconstruction: a 10-year follow-up study*. *Plast Reconstr Surg* 2002;110:438-49.
- <sup>29</sup> Wetzels JW, Merckx MA, de Haan AF, et al. *Maximum mouth opening and trismus in 143 patients treated for oral cancer: A 1-year prospective study*. *Head Neck* 2014;36:1754-62.
- <sup>30</sup> Ferreira CL, Machado BC, Borges CG, et al. *Impaired orofacial motor functions on chronic temporomandibular disorders*. *J Electromyogr Kinesiol* 2014;24:565-71.
- <sup>31</sup> Colletti G, Autelitano L, Rabbiosi D, et al. *Technical refinements in mandibular reconstruction with free fibula flaps: outcome-oriented retrospective review of 99 cases*. *Acta Otorhinolaryngol Ital* 2014;34:342-8.
- <sup>32</sup> Tarsitano A, Sgarzani R, Betti E, et al. *Vascular pedicle ossification of free fibular flap: is it a rare phenomenon? Is it possible to avoid this risk?* *Acta Otorhinolaryngol Ital* 2013;33:307-10.

Received: November 16, 2014 - Accepted: June 15, 2015