

## Micro-Fragmented Adipose Tissue: A New Minimally Invasive Method for Treatment of Anal Fistula? A Pilot Study

D'Urbano F<sup>1</sup>, Fabbri N<sup>1\*</sup>, Resta G<sup>2</sup>, Ascanelli S<sup>3</sup>, Ferrocci G<sup>2</sup>, Anania G<sup>2</sup>, Cavallesco G<sup>2</sup>, Carcoforo P<sup>3</sup>

<sup>1</sup>Department of Morphology, Experimental Medicine and Surgery, University of Ferrara, Ferrara, Italy

<sup>2</sup>Department of Morphology, Experimental Medicine and Surgery, Unit of General Surgery 1, University of Ferrara, Ferrara, Italy

<sup>3</sup>Department of Morphology, Experimental Medicine and Surgery, Unit of General Surgery 2, University of Ferrara, Ferrara, Italy

\*Corresponding author: Fabbri Nicola, Department of Morphology, Experimental Medicine and Surgery, University of Ferrara, Ferrara, Italy. Email: nicolo.fabbri@student.unife.it

**Citation:** D'Urbano F, Fabbri N, Resta G, Ascanelli S, Ferrocci G, et al. (2019) Micro-Fragmented Adipose Tissue: A New Minimally Invasive Method for Treatment of Anal Fistula? A Pilot Study. J Surg 12: 1224. DOI: 10.29011/2575-9760.001224

**Received Date:** 18 May, 2019; **Accepted Date:** 29 May, 2019; **Published Date:** 04 June, 2019

### Abstract

The treatment of Anal fistula continues to be one of the most challenging clinical problems in anorectal surgery. Many sphincter-preserving procedures for the treatment of anal fistula have been recently introduced with the common goal of minimising the injury to the anal sphincters and preserving optimal function. Micro-fragmented adipose tissue injection associated closure of the internal opening with Lipogems<sup>®</sup> technique is one of them. The properties of autologous adipose-derived stem cells for regenerating tissues and suppressing inflammatory response must be better investigated on anal fistulae, and studies remain in progress. The aim of the present article is to evaluate the safety and efficacy of autologous, micro-fragmented and minimally manipulated adipose tissue injection associated with closure of the internal opening in promoting anal fistula healing.

**Keywords:** Adipose Tissue; Anal Canal; Fistula; Lipogems<sup>®</sup>

disturbance posed by surgically managing these fistulas [1].

### Introduction

Anal fistula is one of the commonest conditions known in surgical clinics dealing with anorectal diseases. Anal fistula is an epithelized communication between the rectum or anal canal and the perianal region, of infectious origin. One of the most widely accepted etiologic factor for the formation of fistulae is when an infected perianal gland forms an abscess and ruptures into anal canal on one side and perianal skin on the other side. Patients with anal fistulae typically complain of pain, drainage of pus or stool, pruritus, and excoriation of adjacent tissue. Though not life-threatening, these symptoms often significantly impact patients' social, intimate and work lives.

A fistula-in-ano can be "Simple" or "Complex". Simple fistula includes intersphincteric and low trans-sphincteric with less than 30% of the external and internal anal sphincter involved. It is termed "Complex" when the track crosses more than 30% to 50% of the external sphincter (high transsphincteric, suprasphincteric and extrasphincteric fistulas), is anterior in a female, is recurrent, has multiple tracks or the patient has pre-existing incontinence, local irradiation or Crohn's disease with higher risk of continence

Fistulotomy/fistulectomy is still considered the gold standard for the treatment of the simple type, but has lot of postoperative pain, takes more time to heal and has another important problem, anal sphincter injury which can result in incontinence. On the other hand, the treatment of the complex type is still very challenging, and a gold standard procedure is not available. Studies have shown that complex, branched, or recurrent fistulas are at a higher risk of treatment failure and complications [2]. In normal wound healing, extensive cell signaling and activation of a well-orchestrated cascade of cytokines, growth factors, and interleukins carry on the process of healing [3]. In contrast, in chronic wounds there is a disturbance in this cascade. There are both comorbid factors, such as smoking, and local factors, such as critical bacterial colonization, that can impair wound healing [4]. Recently, new therapeutic approaches, such as the use of mesenchymal stem cells (MSCs), have been proposed and the regenerative capabilities of fat with mesenchymal properties [Adipose-Derived Mesenchymal Stem Cells (ASCs)] have been explored [5,6]. MSCs have been reported to be able to activate and influence the microenvironment

due to the secretion of mitogenic and immunomodulatory factors [7]. Taking advantage of this rationality, a technology has been developed -Lipogems® - capable of processing lipo-aspirated fat, with minimal manipulation, obtaining a ready-to-use autologous micro-fragmented tissue that maintains the vasculo-stromal architecture of the adipose tissue itself.

The aim of the present study is to evaluate the safety and efficacy of autologous, micro-fragmented and minimally manipulated adipose tissue injection associated with closure of the internal opening in promoting anal fistula healing.

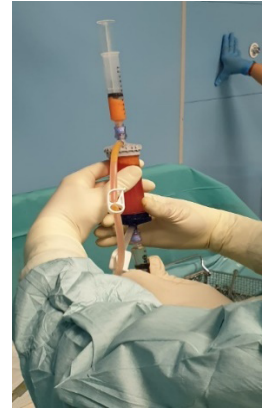
## Materials and Methods

The study was designed as a non-randomized, prospective, observational pilot study. The aim of the study is to evaluate the outcome of the inoculation of autologous adipose tissue micro-fragmented with Lipogems® technique in the treatment of recurrent intersphincteric perianal fistulas. From 2016 to 2018, a total of 8 patients with recurrent intersphincteric anal fistula who qualified for elective surgery were recruited at Sant'Anna Hospital in Ferrara. All patients performed a digital rectal examination and underwent a preoperative Magnetic Resonance Imaging (MRI) to identify the fistula tract and internal opening. We assessed subjective pain one week after surgery and documented. The scale ranged from 0 to 10, where 0 stands for no pain and 10 stands for worst pain ever faced. After discharge all patients were followed for a period of one year and any recurrence of the disease noted. Any complications occurring in the postoperative period and during follow-up were noted. Recurrence was defined as persistence of fistula at the same site or reappearance of any new fistula at the operated site. Every patient was informed of the procedure and consent taken. The plan of study was submitted to hospital ethics committee and their approval was taken.

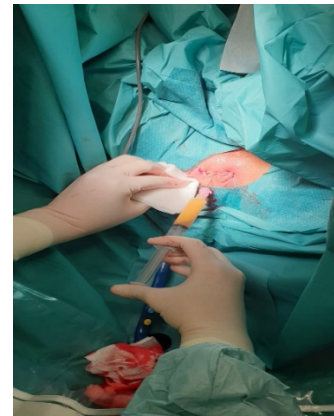
## Surgical Technique

The initial procedure includes two phases: lipo-aspiration (harvesting) and processing. Lower or lateral abdomen was chosen as donor site. Before harvesting the fat, the area was injected with local anesthetic (20 ml lidocaine 20 mg/ml and diluted with 1 ml adrenaline for vasoconstriction). After infiltration, the adipose tissue is harvested using standard liposuction technique, a 19cm 13G blunt cannula was used to prevent additional trauma to cells during the aspiration process. The harvested fat was then processed in the Lipogems® processing kit, a disposable device that gradually reduces the size of the adipose tissue clusters while eliminating oily substances and blood residues with pro-inflammatory properties. The entire process was performed in complete immersion in saline solution minimizing any traumatic action on cell products. The resulting micro fragmented adipose tissue was collected in a 10-ml syringe and positioned for decant the excess of saline solution. At the end, the product was transferred to several 1-ml syringes with

a 22G and 30-mm length needle to be injected into the patient, the entire process takes between 15-20 minutes (Figures 1,2).



**Figure 1:** LIPOGEMS device: filter for processing fat.



**Figure 2:** Injections of microfragment adipose tissue.

The first step of the surgical procedure was the debridement of the internal opening, and then, the closure of the muscular layer was carried out with 2/0 Polydioxanone (PDS) stitches after undermining the mucosal edges in order to raise an amount of tissue 1 cm wider than the size of the enlarged. The product was injected into the submucosal layer surrounding the inner orifice and along the walls of the fistula's tract. All the operations were performed by a single experienced surgeon.

## Results

From 2016 to 2018 a total of 8 patients (5 males and 3 females) with recurrent intersphincteric anal fistula and were all previously treated unsuccessfully with seton placement., had sphincteric-saving procedure with Lipogems® technique. No intra-operative difficulties related to the use of the kit were recorded. The mean degree of postoperative pain at 1 week from 0 to 10 was 0 (range 0-2). Patients were evaluated for a 12 months' follow-up time. Recurrence was defined as persistence of fistula at the same

site or reappearance of any new fistula at the operated site. At 3 months' follow-up we had 2 recurrences, at 6 months' follow-up we had 4 recurrences, at 12 months' follow-up we had 2 recurrences. Overall after 12 months' follow-up we had 8 out of 8 recurrences of the disease, whereas no fistula healing occurred.

## Discussion

Fistula-in-ano can be labelled as one of the diseases with high incidence and high recurrence rates posing a challenge to the surgeon. The increasing interest in finding new approaches to improve surgical outcomes, recovery time, and patient's quality of life has led to the development of innovative approaches, including the use of MSCs and therefore Lipogems® technique.

The promising results on centrifuged adipose tissue have induced to search a system capable of processing lipo-aspirated fat, with minimal manipulation to promote anal fistula healing. Therefore, we used the Lipogems® technique. Mesenchymal stem cells derived from subcutaneous fat have been trialled in two studies to treat complex perianal fistulae [8,9]. In a study of 35 patients treated with injection of ASC along with fibrin glue, the fistula healing rate was reported to be 71% and at 1 year the fistula recurred in 17% of patients. ASC were used either on its own or along with fibrin glue in another study of 200 patients and the healing rate was reported to range from 52% to 57% without any serious adverse event [9].

Based on our data, patients treated with Lipogems® technique do not require numerous ambulatory accesses for post-operative medications. Postoperative pain and discomfort reported by our patients was limited when compared with patients treated with other techniques like seton with and without fistulectomy. Furthermore, using autologous adipose tissue always allows compatible material to be available and ready to be used without major complications nor adverse events. The reduced amount of adipose tissue needed for each patient doesn't limit the use of this technique to patients with high BMI only. However, the high recurrence rate that occurred in our experience and the high cost of the product doesn't allow us to suggest its use as a first-line treatment for anal fistula. But it could be taken into consideration as a possible second-line treatment after informing the patient about the relative advantages and risks. The high recurrence rate after treatment with Lipogems® technique could be explained by the type of fistula treated. In fact, all patients had already been treated seton placement unsuccessfully. However, the choice

made by our Centre was to have all the operations performed by a single experienced surgeon, to standardize as much as possible the surgical procedure, reducing any bias.

## Conclusions

The injection of autologous, micro-fragmented and minimally manipulated adipose tissue with Lipogems® technique is a safe and reproducible procedure, unfortunately according to our experience, it does not promote fistula healing in patients with recurrent intersphincteric anal fistula. New studies with more patients are needed to verify the real effectiveness of this procedure. Actually we do not suggest the use of this technique as a first-line treatment.

## References

1. Sandborn WJ, Fazio VW, Feagan BG, Hanauer SB (2003) AGA technical review on perianal Crohn's disease. *Gastroenterology* 125: 1508-1530.
2. Amato A, Bottini C, De NP, Giamundo P4, Lauretta A, et al. (2015) Evaluation and management of perianal abscess and anal fistula: a consensus statement developed by the Italian Society of Colorectal Surgery (SICCR). *Tech Coloproctol* 19: 595-606.
3. Barrientos S, Stojadinovic O, Golinko MS, Brem H, Tomic-Canic M (2008) Growth factors and cytokines in wound healing. *Wound Repair Regen* 16: 585-601.
4. Guo S, Dipietro LA (2010) Factors affecting wound healing. *J Dent Res* 89: 219-229.
5. Gimble JM, Guilak F, Bunnell BA (2010) Clinical and preclinical translation of cell-based therapies using adipose tissue-derived cells. *Stem Cell Res Ther* 1: 19.
6. Zuk PA, Zhu M, Mizuno H, Huang J, Futrell JW, et al. (2001) Multi-lineage cells from human adipose tissue: implications for cell-based therapies. *Tissue Eng* 7: 211-228.
7. Caplan AI, Correa D (2011) The MSC: an injury drugstore. *Cell Stem Cell* 9: 11-15.
8. Garcia-Olmo D, Garcia-Arranz M, Herreros D (2008) Expanded adipose-derived stem cells for the treatment of complex perianal fistula including Crohn's disease. *Expert Opin Biol Ther* 8: 1417e23.
9. Herreros MD, Garcia-Arranz M, Guadalajara H, De-La-Quintana P, Garcia-Olmo D, et al. (2012) Autologous expanded adipose-derived stem cells for the treatment of complex cryptoglandular perianal fistulas: a phase III randomized clinical trial (FATT 1: fistula Advanced Therapy Trial 1) and long-term evaluation. *Dis Colon Rectum* 55: 762e72.