



Title	Bilateral subchondral insufficiency fractures of the femoral head in a normally active adolescent patient : A case report
Author(s)	Ishizu, Hotaka; Shimizu, Tomohiro; Kaibara, Takuma; Asano, Tsuyoshi; Terkawi, Mohamad Alaa; Takahashi, Daisuke; Iwasaki, Norimasa
Citation	Journal of orthopaedic science, 27(2), 492-494 <a href="https://doi.org/10.1016/j.jos.2019.05.013">https://doi.org/10.1016/j.jos.2019.05.013</a>
Issue Date	2022-03
Doc URL	<a href="http://hdl.handle.net/2115/88230">http://hdl.handle.net/2115/88230</a>
Rights	© 2019. This manuscript version is made available under the CC-BY-NC-ND 4.0 license <a href="http://creativecommons.org/licenses/by-nc-nd/4.0/">http://creativecommons.org/licenses/by-nc-nd/4.0/</a>
Rights(URL)	<a href="http://creativecommons.org/licenses/by-nc-nd/4.0/">http://creativecommons.org/licenses/by-nc-nd/4.0/</a>
Type	article (author version)
File Information	JOS 27(2) 492-494.pdf



[Instructions for use](#)

**Bilateral subchondral insufficiency fractures of the femoral head in a normally active adolescent patient: A case report**

Hotaka Ishizu<sup>1</sup>, Tomohiro Shimizu<sup>1</sup>, Takuma Kaibara<sup>1</sup>, Tsuyoshi Asano<sup>1</sup>, Mohamad Alaa Terkawi<sup>1</sup>,  
Daisuke Takahashi<sup>1</sup>, Norimasa Iwasaki<sup>1</sup>

<sup>1</sup>Department of Orthopaedic Surgery, Faculty of Medicine and Graduate School of Medicine,  
Hokkaido University

Corresponding author: Tomohiro Shimizu

Department of Orthopaedic Surgery, Faculty of Medicine and Graduate School of Medicine,  
Hokkaido University, Kita-15 Nishi-7, Kita-ku, Sapporo, 060-8638, JAPAN.

Phone: +81-11-716-1161 ext. 5936; Fax +81-11-706-6054

E-mail: [simitom@wg8.so-net.ne.jp](mailto:simitom@wg8.so-net.ne.jp)

- 1 **Bilateral subchondral insufficiency fractures of the femoral head in a normally active**
- 2 **adolescent patient: A case report**
- 3

1 **Introduction**

2 A subchondral insufficiency fracture (SIF) of the femoral head occurs mainly in elderly  
3 women with osteoporosis as well as in patients who have undergone renal transplantation[(1-3).  
4 SIF of the femoral head should be included in the differential diagnosis of acute onset of  
5 coxarthrosis, along with osteonecrosis of the femoral head (ONFH) and transient osteoporosis of  
6 the hip (TOH)(4). Because SIF of the femoral head has been reported to have a clinical course  
7 completely different from that of ONFH, the differential diagnosis of these two diseases is  
8 especially important [(5, 6). On the other hand, there may be a close relationship between SIF of  
9 the femoral head and TOH, but the patient populations and the main location of bone marrow  
10 edema (BME) differ(5, 7, 8). More specifically, TOH usually affects middle-aged men and  
11 pregnant women, mostly those without prior trauma or a sudden increase in activity.

12 SIF of the femoral head has also been reported to occur as a fatigue-type stress fracture in  
13 healthy young military recruits as well as in patients with bone fragility (9). Iwasaki et al.  
14 reported five cases of SIF of the femoral head in young adults who had no history of  
15 overexertion or antecedent trauma (10). They concluded that SIF of the femoral head needs to be  
16 seriously considered as a possibility even in younger patients presenting with hip pain. Although  
17 most reports mention unilateral onset or a definite time interval between the two sides (11, 12),  
18 simultaneous bilateral SIF of the femoral head is extremely rare.

19 Herein, we report the rare case of a normally active adolescent who developed bilateral  
20 SIF of the femoral head. The patient and her family were informed about this report and agreed  
21 to its publication.

22

23 **Report of the Case**

1           A 14-year-old girl presented with bilateral hip joint pain without apparent trauma. She had  
2 sprained the left Lisfranc joint while playing basketball and had recovered with conservative  
3 treatment (weight bearing strictly within the limits of pain for 4 weeks). Two months later, bilateral  
4 hip joint pain occurred during load bearing, for which she visited the nearest hospital. She was  
5 referred to our hospital visit three weeks after the hip joint pain first occurred. Although she had a  
6 history of using a topical corticosteroid (betamethasone butyrate propionate) on her back for her  
7 atopic dermatitis for two years, she had no history of corticosteroid intake or alcohol abuse. She  
8 was 164 cm tall and weighed 70 kg (body mass index; 26.4 kg/m<sup>2</sup>). A blood examination revealed  
9 no abnormality in the renal or liver function. The serum tartrate-resistant acid phosphatase 5b  
10 (TRACP-5b), intact procollagen type 1 N-terminal propeptide (P1NP), 25-hydroxy vitamin D  
11 (25OHD), and intact parathyroid hormone (PTH) level was 375 mU/dL, 53.5 ng/mL, 12.4 ng/mL  
12 and 55 pg/mL, respectively. Total bone mineral density (BMD) of the femur was 0.851 g/cm<sup>2</sup>  
13 (young adult mean value (YAM); 90%), determined by performing dual x-ray absorptiometry; all  
14 measurements were within normal ranges. On her first visit to our hospital, her Harris Hip Score  
15 was 54 points on the right side and 46 points on the left side.

16           A plain hip radiograph at the first visit revealed no abnormalities except for bilateral hip  
17 dysplasia (Center-Edge angle; right 12 degrees, left 19 degrees. Sharp angle; right 51 degrees, left  
18 43 degrees) (Fig. 1A). A coronal T1-weighted MR image showed low-intensity band (Fig. 1B) and  
19 a short TI inversion recovery (STIR) image showed extensive bone marrow edema pattern in both  
20 hips (Fig. 1C) at the previous clinic visit. To exclude ossification failure, hip arthrography was  
21 performed. Thickened cartilage, which characterizes cartilage ossification failure, was not  
22 observed in the hip arthrography (Fig. 2).

1           Because collapse of the femoral head was not present, we instructed her and her mother to  
2 use the crutch and avoid any physical exertion. At three months after the first visit, the coronal T1-  
3 weighed MR image showed a decrease in the low intensity area (Fig. 3A). At eight months after  
4 the first visit, the low intensity area had almost disappeared; a hip radiograph did not show collapse  
5 and progression of joint space narrowing (Fig. 3B). At the last follow-up, she reported no hip pain  
6 or other symptoms, and her Harris Hip Score was 100 points. Because vitamin D deficiency (low  
7 25 OHD level) in this case was determined to be caused by insufficient intake and lack of daylight  
8 exposure, we guided the patient regarding supplement intake and advised sunbathing.

9

## 10 **Discussion**

11           The magnetic resonance imaging (MRI) finding of the right side in this case was  
12 consistent with previous reports of SIF of the femoral head; the shape of the low intensity band  
13 on T1-weighted images was irregular, serpiginous, and convex to the articular surface (1, 3, 4,  
14 13). In contrast, the low intensity band on T1-weighted images of the left side in this case at the  
15 baseline and 3 months after the first visiting seemed smooth and circumscribed. When  
16 considered with the longitudinal MRI finding that low intensity band decreased from baseline to  
17 8 months after the first visit, this case could be diagnosed as bilateral SIF of the femoral head.  
18 The important differential diagnoses in determining SIF of the femoral head in adolescents are  
19 ONFH, TOH, and ossification failure. In this case, TOH and cartilage ossification failure could  
20 be excluded by examining the MRI finding (which showed a clear band pattern) (14) and the hip  
21 arthrography finding, respectively.

22           There have been two case reports of bilateral SIF of the femoral head in patients  
23 receiving renal transplantation (3, 15); however, this case was, to the best of our knowledge, the

1 first report of bilateral SIF of the femoral head in an adolescent without comorbidities.  
2 Additionally, because her activity level was moderate and not high such as in athletes or military  
3 personnel, this case was thought to be insufficiency fracture rather than a fatigue fracture.  
4 Therefore, SIF of the femoral head needs to be considered in patients presenting with hip pain,  
5 even in normally active adolescents.

6 The present case is thought to be induced by the complex causes previously reported such  
7 as glucocorticoid use, hip dysplasia (16), osteopenia (10, 17) and other unknown factors.  
8 Additionally, the present case showed vitamin D insufficiency (12.4 ng/mL). Low vitamin D  
9 concentrations have been reported in the majority of elderly patients suffering fragility fractures  
10 (18-20). On the other hand, the prevalence of vitamin D insufficient is not rare in Japan (21,  
11 22). The Japanese population-based osteoporosis (JPOS) cohort study reported that low 25(OH)D  
12 levels, especially < 20 ng/ml, were associated with elevated fracture risks in Japanese women  
13 (23). However, because mean age in this JPOS study was over sixty years old, it is unclear if low  
14 vitamin D level in the current case induced bone fragility. Additionally, although vitamin D plays  
15 a crucial role in maintaining bone health and muscle strength in healthy children (24-26), the  
16 optimum 25OHD level that needs to be maintained remains uncertain (27).

17 In conclusion, we present our experience with a case of simultaneous bilateral SIF of the  
18 femoral head in a normally active adolescent. Subchondral insufficiency fractures of the femoral  
19 head should be considered in the differential diagnosis of hip pain in adolescents with hip  
20 dysplasia, osteopenia or vitamin D insufficiency.

21

## 22 **Conflict of interest**

23 The authors declare that they have no conflict of interest.

## 1 **References**

- 2 1. Vande Berg BC, Malghem J, Goffin EJ, Duprez TP, Maldague BE. Transient epiphyseal  
3 lesions in renal transplant recipients: presumed insufficiency stress fractures. *Radiology*1994  
4 May;191(2):403-7.
- 5 2. Bangil M, Soubrier M, Dubost JJ, Rami S, Carcanagues Y, Ristori JM, Bussiere JL.  
6 Subchondral insufficiency fracture of the femoral head. *Rev Rhum Engl Ed*1996  
7 Dec;63(11):859-61.
- 8 3. Ikemura S, Yamamoto T, Nakashima Y, Shuto T, Jingushi S, Iwamoto Y. Bilateral  
9 subchondral insufficiency fracture of the femoral head after renal transplantation: a case report.  
10 *Arthritis Rheum*2005 Apr;52(4):1293-6.
- 11 4. Yamamoto T, Bullough PG. Subchondral insufficiency fracture of the femoral head: a  
12 differential diagnosis in acute onset of coxarthrosis in the elderly. *Arthritis Rheum*1999  
13 Dec;42(12):2719-23.
- 14 5. Guerra JJ, Steinberg ME. Distinguishing transient osteoporosis from avascular necrosis  
15 of the hip. *J Bone Joint Surg Am*1995 Apr;77(4):616-24.
- 16 6. Motomura G, Yamamoto T, Miyanishi K, Shirasawa K, Noguchi Y, Iwamoto Y.  
17 Subchondral insufficiency fracture of the femoral head and acetabulum : a case report. *J Bone*  
18 *Joint Surg Am*2002 Jul;84-A(7):1205-9.
- 19 7. Buttaro M, Della Valle AG, Morandi A, Sabas M, Pietrani M, Piccaluga F. Insufficiency  
20 subchondral fracture of the femoral head: report of 4 cases and review of the literature. *J*  
21 *Arthroplasty*2003 Apr;18(3):377-82.



- 1 8. Yamaguchi R, Yamamoto T, Motomura G, Ikemura S, Iwasaki K, Zhao G, Iwamoto Y.  
2 Radiological morphology variances of transient osteoporosis of the hip. *J Orthop Sci*2017  
3 Jul;22(4):687-92.
- 4 9. Song WS, Yoo JJ, Koo KH, Yoon KS, Kim YM, Kim HJ. Subchondral fatigue fracture of  
5 the femoral head in military recruits. *J Bone Joint Surg Am*2004 Sep;86-A(9):1917-24.
- 6 10. Iwasaki K, Yamamoto T, Motomura G, Mawatari T, Nakashima Y, Iwamoto Y.  
7 Subchondral insufficiency fracture of the femoral head in young adults. *Clin Imaging*2011 May-  
8 Jun;35(3):208-13.
- 9 11. Yamamoto T, Iwamoto Y, Schneider R, Bullough PG. Histopathological prevalence of  
10 subchondral insufficiency fracture of the femoral head. *Ann Rheum Dis*2008 Feb;67(2):150-3.
- 11 12. Yamamoto T. Subchondral insufficiency fractures of the femoral head. *Clin Orthop*  
12 *Surg*2012 Sep;4(3):173-80.
- 13 13. Rafii M, Mitnick H, Klug J, Firooznia H. Insufficiency fracture of the femoral head: MR  
14 imaging in three patients. *AJR Am J Roentgenol*1997 Jan;168(1):159-63.
- 15 14. Kim JW, Yoo JJ, Min BW, Hong SH, Kim HJ. Subchondral fracture of the femoral head  
16 in healthy adults. *Clin Orthop Relat Res*2007 Nov;464:196-204.
- 17 15. Ohtsuru T, Yamamoto T, Murata Y, Morita Y, Munakata Y, Kato Y. Bilateral subchondral  
18 insufficiency fractures of the femoral head in patients with living renal transplantation: A report  
19 of two cases. *J Orthop Sci*2017 Sep;22(5):972-5.
- 20 16. Ishihara K, Miyanishi K, Ihara H, Jingushi S, Torisu T. Subchondral insufficiency  
21 fracture of the femoral head may be associated with hip dysplasia: a pilot study. *Clin Orthop*  
22 *Relat Res*2010 May;468(5):1331-5.

- 1 17. Yamamoto T, Nakashima Y, Shuto T, Jinguishi S, Iwamoto Y. Subchondral insufficiency  
2 fracture of the femoral head in younger adults. *Skeletal Radiol*2007 Jun;36 Suppl 1:S38-42.
- 3 18. Moniz C, Dew T, Dixon T. Prevalence of vitamin D inadequacy in osteoporotic hip  
4 fracture patients in London. *Curr Med Res Opin*2005 Dec;21(12):1891-4.
- 5 19. Dixon T, Mitchell P, Beringer T, Gallacher S, Moniz C, Patel S, Pearson G, Ryan P. An  
6 overview of the prevalence of 25-hydroxy-vitamin D inadequacy amongst elderly patients with  
7 or without fragility fracture in the United Kingdom. *Curr Med Res Opin*2006 Feb;22(2):405-15.
- 8 20. Beringer T, Heyburn G, Finch M, McNally C, McQuilken M, Duncan M, Dixon T.  
9 Prevalence of vitamin D inadequacy in Belfast following fragility fracture. *Curr Med Res*  
10 *Opin*2006 Jan;22(1):101-5.
- 11 21. Yoshimura N, Muraki S, Oka H, Morita M, Yamada H, Tanaka S, Kawaguchi H,  
12 Nakamura K, Akune T. Profiles of vitamin D insufficiency and deficiency in Japanese men and  
13 women: association with biological, environmental, and nutritional factors and coexisting  
14 disorders: the ROAD study. *Osteoporos Int*2013 Nov;24(11):2775-87.
- 15 22. Nakamura K, Kitamura K, Takachi R, Saito T, Kobayashi R, Oshiki R, Watanabe Y,  
16 Tsugane S, Sasaki A, Yamazaki O. Impact of demographic, environmental, and lifestyle factors  
17 on vitamin D sufficiency in 9084 Japanese adults. *Bone*2015 May;74:10-7.
- 18 23. Tamaki J, Iki M, Sato Y, Kajita E, Nishino H, Akiba T, Matsumoto T, Kagamimori S,  
19 Group JS. Total 25-hydroxyvitamin D levels predict fracture risk: results from the 15-year  
20 follow-up of the Japanese Population-based Osteoporosis (JPOS) Cohort Study. *Osteoporos*  
21 *Int*2017 Jun;28(6):1903-13.
- 22 24. Holick MF. Vitamin D deficiency. *N Engl J Med*2007 Jul 19;357(3):266-81.

- 1 25. Hossein-nezhad A, Holick MF. Vitamin D for health: a global perspective. Mayo Clin  
2 Proc2013 Jul;88(7):720-55.
- 3 26. Fiscoletti M, Stewart P, Munns CF. The importance of vitamin D in maternal and child  
4 health: a global perspective. Public Health Rev2017;38:19.
- 5 27. Willett AM. Vitamin D status and its relationship with parathyroid hormone and bone  
6 mineral status in older adolescents. Proc Nutr Soc2005 May;64(2):193-203.
- 7

1 **Figure legends**

2 **Fig. 1 Images obtained at the first visit.**

3 (A) Anteroposterior radiograph of the hip at the first visit. (B) Coronal T1-weighted magnetic  
4 resonance image of the hip at the same month. Low-intensity band pattern in the both femoral  
5 head (arrow). (C) Coronal Short TI Inversion Recovery (STIR) image of the hip in the same  
6 month.

7 **Fig. 2 Hip arthrography images**

8

9 Left panel: Arthrography image of the left hip. Right panel: Computed tomography arthrography  
10 image

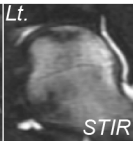
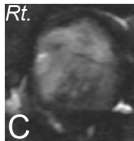
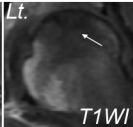
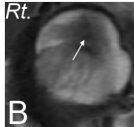
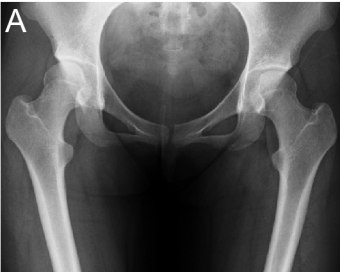11 **Fig. 3 Longitudinal magnetic resonance images and radiograph at the final follow up**

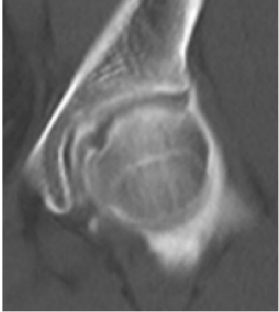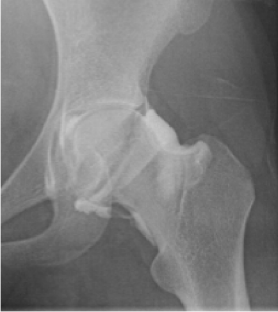12

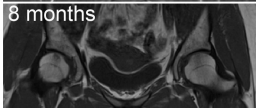
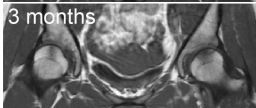
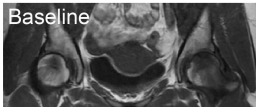
13 (A) Longitudinal coronal T1-weighted magnetic resonance image of the hip. (B) Anteroposterior  
14 radiograph of the hip at the final follow-up.

15

16





**A****B**