

biblio.ugent.be

The UGent Institutional Repository is the electronic archiving and dissemination platform for all UGent research publications. Ghent University has implemented a mandate stipulating that all academic publications of UGent researchers should be deposited and archived in this repository. Except for items where current copyright restrictions apply, these papers are available in Open Access.

This item is the archived peer-reviewed author-version of:

Title: [Differentiation between peri-anastomotic inflammatory changes and local recurrence following neoadjuvant radiochemotherapy surgery for colorectal cancer using visual and semiquantitative analysis of PET-CT data.](#)

Authors: Smeets P, Ham H, Ceelen W, Boterberg T, Verstraete K, Goethals I.

In: *Journal, Volume (Issue), pages, year.* Q J Nucl Med Mol Imaging 54(3):327-32. Epub 2010 Feb 18

Optional: [link to the article](#)

To refer to or to cite this work, please use the citation to the published version:

Authors (year). Title. journal Volume(Issue) page-page. Doi

Smeets P, Ham H, Ceelen W, Boterberg T, Verstraete K, Goethals I. (2010). Q J Nucl Med Mol Imaging 54 (3) 327-32.

Abstract

Aim: To evaluate the usefulness of visual and semiquantitative ^{18}F -FDG PET-CT data for the diagnosis of a peri-anastomotic colorectal cancer recurrence taking into account the time period between the surgery and the ^{18}F -FDG PET-CT scanning.

Method: The study population consisted of 70 patients who had prior pre-operative radiochemotherapy and surgical resection of the primary tumour and who underwent whole body ^{18}F -FDG PET-CT scanning for the detection of recurrent disease. Visual and semiquantitative (SUV_{max}) analysis of the ^{18}F -FDG uptake at the peri-anastomosis was performed. The final diagnosis was based on pathological proof or clinical and/or imaging follow-up data.

Results: On visual reading, 27 patients exhibited an increased ^{18}F -FDG uptake at the peri-anastomosis. Of those, 11 (41%) patients had a local tumour recurrence and 16 (59%) patients had no recurrent tumour. Among 43 patients without increased ^{18}F -FDG uptake at the peri-anastomosis, none had a local tumour recurrence. On semiquantitation, SUV_{max} in patients with and without a local recurrence overlapped. However, if the time period between the surgery and the ^{18}F -FDG PET-CT scanning was taken into account, overlap of SUV_{max} was mainly observed within a postoperative time period of ≤ 12 months. Thereafter, a threshold SUV_{max} of 3.2 discriminated between benign and malignant lesions in all but one patient.

Conclusion: In our series, visually increased ^{18}F -FDG uptake at the peri-anastomosis was 100% sensitive but non-specific (specificity of 73%) for the

diagnosis of a local tumour recurrence. On the other hand, normal ^{18}F -FDG uptake at the peri-anastomosis precluded a local tumour recurrence (negative predictive value of 100%). In addition, semiquantitative (SUV_{max}) analysis of the ^{18}F -FDG uptake at the peri-anastomosis may increase specificity (up to 97%), while preserving maximum sensitivity, if the postoperative time period is > 12 months.

Key words: ^{18}F -fluorodeoxyglucose – combined PET-CT scanning – maximal standard uptake value – anastomosis – colorectal cancer recurrence.

Introduction

Surgical resection is the primary treatment modality for early stage colorectal cancer (CRC). Despite potentially curative surgery and the use of modern adjuvant chemotherapy and/or radiation therapy (RT), more than 40 percent of patients who present with stage II or III disease will have a disease recurrence following primary therapy, usually developing within 2 years of the primary surgery [1]. The most common metastatic sites are the regional lymph nodes, liver, lungs, and peritoneum [2]. After potentially curative resection of CRC, the purpose of surveillance is early identification of those patients who are potentially eligible for further curative therapy. Recent data support the view that intensive surveillance strategies improve survival because all forms of recurrences are detected early [3-5]. Furthermore, data supporting periodic imaging to detect early potentially resectable recurrences led the American Society of Clinical Oncology (ASCO) to reverse its previous recommendation against including CT scans as a component of the post-treatment surveillance strategy in 2005 [6].

Because of the high ^{18}F -fluorodeoxyglucose (^{18}F -FDG) uptake in primary colorectal carcinomas and their recurrences, ^{18}F -FDG PET or combined ^{18}F -FDG PET-CT that allows identification of increased glucose metabolism by PET with the display of the underlying anatomy by CT may also have a role in the evaluation of colorectal cancer recurrence (CRCR) [7,8]. However, the differentiation between local CRCR and changes attributable to previous surgery and/or radiotherapy often constitutes a major diagnostic challenge [9]. Because of the well-known ^{18}F -FDG uptake associated with inflammatory lesions [10],

evaluation of the anastomosis, the stoma, the post-operative abdominal wall and the port sites after laparoscopic surgery may be difficult [11]. Moreover, the CT scan may not be very helpful in these cases because there are often no morphological changes associated with focal inflammation [12].

The aim of this retrospective study was to investigate the usefulness of visual and semiquantitative ^{18}F -FDG PET-CT data for the diagnosis of a peri-anastomotic colorectal cancer recurrence taking into account the time period between the surgery and the ^{18}F -FDG PET-CT scanning.

Patients and Methods

Patients

For this retrospective study, the study population consisted of 70 patients (43 men and 27 women) who underwent whole body ^{18}F -FDG PET-CT scanning at our institution. All had prior pre-operative radiochemotherapy (total dose of 45 Gy in 25 fractions; 1.8 Gy per fraction; in combination with 5-fluorouracil during the first and the fifth week). Surgery was performed 6 weeks after the end of the radiotherapy course. ^{18}F -FDG PET-CT scanning was performed at different time points after surgery (mean \pm standard deviation, 26 months \pm 20; range, 0-88 months). Indications for PET-CT scanning were an unexplained increase in carcinoembryonic antigen (CEA) values (n=39), suspected intra- or extra-abdominal tumour recurrence based on abnormal findings on CT or other imaging modalities (n=19), restaging prior to surgical removal of presumably resectable liver metastasis (n=4), monitoring of therapy (n=4) and staging of a

second primary tumour (n=4). None of these patients had inflammatory bowel disease, post-operative and/or radiotherapy-induced complications, such as fistula, abscess or retroperitoneal fibrosis.

¹⁸F-FDG PET-CT scanning

All examinations were performed according to the standard protocol at the Ghent University Hospital. The patients fasted at least 4 hours prior to intravenous injection of ¹⁸F-FDG (3.7 MBq/kg body weight). Blood glucose levels were checked prior to the injection of ¹⁸F-FDG and did not exceed 140 mg/dL. Iodinated intravenous contrast (Iohexol (Omnipaque®) 300 or iomeprol (Iomeron®) 400) was administered immediately before the CT scanning. Iodinated oral contrast material was not administered and patients who had undergone a CT examination with iodine-based peroral contrast medium for the opacification of the bowel within 1 week of the PET-CT scanning were excluded from the study. Patients were imaged with the Gemini PET-CT imaging system (Philips Co., Cleveland, USA), which consists of a gadolinium oxyorthosilicate (GSO) full-ring PET scanner with 5.0 mm spatial resolution and a 16-slice helical CT scanner. After a 60-min uptake period, during which patients were instructed to rest silently, images were acquired. First, a CT surviiew (30 mA, 120 kV, FOV 500 mm, collimation 0.75 mm) was performed from the base of the skull through the mid thigh. This was followed by a low-dose CT (30 mA, 120 kV, FOV 600 mm, 0.5 s rotation time, pitch 0.9, collimation 16 × 1.5 mm) and a high-quality CT (150 mA, 120 kV, FOV 500 mm, 0.5 s rotation time, pitch of 0.9, collimation 16 ×

1.5 mm, slice thickness and increment 5 mm) without specific breath-holding instructions and arms at the side of the torso. PET scanning was performed immediately after acquisition of the CT images, without changing the patient position. Between 5 and 8 bed positions were used, with an acquisition time of 3 min per bed position. PET images were reconstructed by using an iterative 3D-RAMLA (Row Action Maximum Likelihood Algorithm) algorithm provided by Philips. Low-dose CT data were used for attenuation correction.

Image analysis

Images were interpreted at a workstation equipped with fusion software (Syntegra, version 2.1E, Philips) that enables the display of CT, PET and PET-CT images. In keeping with the purpose of this study, visual and semiquantitative assessment of the ^{18}F -FDG uptake was focused on the peri-anastomotic region that was defined on the CT part of the integrated PET-CT images (see below). Combined PET-CT images were interpreted in a consensus reading by two observers who were blind to the clinical findings. Other intra- and extra-abdominal sites with increased ^{18}F -FDG uptake were also recorded, but they were not included in the analysis of the results.

The procedure for the semiquantitative assessment of the ^{18}F -FDG uptake at the peri-anastomotic region was divided into the following steps: axial CT slices of the PET-CT images were used to identify the suture line. The peri-anastomotic region was defined as the CT volume that contained all continuous axial slices (range 2-10) in which radio-opaque suture material could be visualized and an

additional, arbitrarily chosen, 10 slices (or 50 mm) proximal and distal of the suture line. This was done because only a few local recurrences are primarily anastomotic, occurring at the suture line [13]. Subsequently, the SUV_{max} in this volume was calculated on the co-registered attenuation corrected PET images. This parameter reflected the ratio of the activity in tissue per millilitre to the activity in the injected dose per patient body weight in kilograms.

Data analysis

In patients with visually increased ^{18}F -FDG uptake, the final diagnosis was based on pathological proof obtained by colonoscopy and/or laparotomy. In patients with normal ^{18}F -FDG uptake at the peri-anastomosis, the final diagnosis was given by clinical and/or imaging follow-up data during at least 24 months after surgery (mean \pm SD, 56 months \pm 23, range, 25-115). The local ethics committee approved the retrospective analysis of patient files and images.

Results

Of the 70 patients included in this study (mean age \pm SD, 65 years \pm 9; range, 46-80 years), 43 were men (mean age 67 years \pm 7), and 27 were women (mean age 62 years \pm 10). Patient characteristics are described in Table 1. Of these patients, 59 had no local tumour recurrence and 11 patients had evidence of a recurrent tumour. On visual reading, 27 patients exhibited an increased ^{18}F -FDG uptake at the peri-anastomosis. Of those, 11 (41%) patients had a local tumour recurrence, whereas 16 patients (59%) had no recurrent tumour. However,

recurrent disease in other locations was frequently recorded. Among 43 patients without increased ^{18}F -FDG uptake at the peri-anastomosis, none had a tumour recurrence (see also Table 2).

On semiquantitation of the ^{18}F -FDG uptake, SUV_{max} in patients with and without a local recurrence overlapped (see Figure 1). However, if the time period between the surgery and the ^{18}F -FDG PET-CT scanning was taken into account, overlap of SUV_{max} was observed mainly within a postoperative period of ≤ 12 months (see also Figure 2). Thereafter, a threshold SUV_{max} of 3.2 discriminated between benign and malignant lesions in all but one patient (see also Figure 2). Colonoscopy in this patient was negative for malignancy.

Discussion

PET imaging using ^{18}F -FDG is well accepted in the imaging work-up of various malignancies. PET is recognized as a useful tool to manage colorectal cancer and was shown to have an additional value in the detection of CRCR [14,15]. The overall accuracy of PET may further be increased by using the integrated PET-CT imaging modality, which combines the benefits of PET with those of anatomical imaging [9,12,16]. However, the differentiation between local CRCR and benign changes associated with previous surgery and/or radiotherapy often remains challenging [9]. Our findings agree with those in the literature in that we found that visual reading on PET was 100% sensitive (11 patients with a recurrent tumour had increased ^{18}F -FDG uptake at the peri-anastomosis (100%)), but non-specific for the diagnosis of a peri-anastomotic CRCR (16 out

of 27 patients (59%) with visually increased ^{18}F -FDG uptake at the peri-anastomosis had no recurrent tumour). This result may be explained, at least partly, by the fact that visual analysis is heavily dependent on observer experience and training and lacks a clearly defined cut-off to distinguish between normal and pathological findings. We therefore hypothesized that semi-quantitative measurement of local ^{18}F -FDG uptake might increase specificity. However, on semiquantitation, SUV_{max} in patients with and without a local recurrence overlapped (see also Figure 1). Thus, our findings seem not to support the usefulness of quantifying ^{18}F -FDG uptake. This is in line with other findings in the literature [9,17]. In the report by Delbeke et al. [17], the authors investigated the role of ^{18}F -FDG PET in the staging of recurrent CRC based on a visual interpretation of CT and ^{18}F -FDG PET images. The authors also investigated whether the standard uptake ratio (SUR) could be used to discriminate malignant from benign lesions. SUR was calculated as the ratio of the activity in the region of interest drawn over the areas of maximal activity per millilitre to the activity in the injected dose per patient body weight in kilograms. They found that SUR was useful in differentiating malignant from benign lesions in the liver, but that SUR was not useful for the identification of extrahepatic recurrent disease because physiological bowel uptake could not reliably be discriminated from tumour recurrence. In a more recent report, Even-Sapir et al. [9] investigated the role of combined ^{18}F -FDG PET-CT in the evaluation of pelvic tumour recurrence in patients who had undergone surgery for rectal cancer, based on visual interpretation of the PET-CT images. In addition, they

investigated the potential value of the maximal standard ^{18}F -FDG uptake (SUV_{max}) as a semiquantitative parameter to differentiate pelvic tumour recurrence from benign pelvic lesions. They found that the average SUV_{max} of a tumour recurrence was not significantly different from the average value of non-tumoural pelvic lesions. However, it may be argued that the discriminatory power of SUV_{max} measurements may be enhanced by taking the postoperative time period into account. We found that a threshold SUV_{max} of 3.2 discriminated between malignant and benign changes in all but one patient, if the postoperative time period was > 12 months (specificity of 97%). Contrarily, within 12 months postoperatively, the use of ^{18}F -FDG PET for the detection of a peri-anastomotic tumour recurrence warrants caution (specificity of only 80%). It is well known that false-positive cases are most likely due to inflammatory changes that have increased ^{18}F -FDG uptake [18], and therefore can be mistaken for tumour recurrence. After a postoperative time period of > 12 months, increased ^{18}F -FDG uptake at the peri-anastomosis corresponded with a tumour recurrence, although we cannot explain the finding of increased ^{18}F -FDG uptake (SUV_{max} 3.9) in a case without a recurrent tumour 57 months postoperatively (see also Figure 3). The threshold SUV_{max} value of 3.2 should be considered with caution, as the number of subjects in this study was limited and the optimal value of the threshold may vary for different patient populations. Moreover, recent studies have shown that SUV measures depend on camera type and on acquisition and reconstruction parameters [19-21].

Conclusion

Normal ^{18}F -FDG uptake at the peri-anastomosis is highly specific for the absence of a local CRCR (negative predictive value of 100%). On the other hand, visually increased ^{18}F -FDG uptake at the peri-anastomosis can correspond to a tumour recurrence or to postoperative inflammatory changes. SUV_{max} measurements might help to further discriminate between benign and malignant lesions, if the postoperative time period is > 12 months. Based on our findings, a threshold SUV_{max} of 3.2 may be proposed. Further studies are needed to confirm the consistency of this threshold value.

References

1. Manfredi S, Bouvier AM, Lepage C, Hatem C, Dancourt V, Faivre J. Incidence and patterns of recurrence after resection for cure of colonic cancer in a well defined population. *Br J Surg* 2006;93:1115-1122
2. Galandiuk S, Wieand HS, Moertel CG, et al. Patterns of recurrence after curative resection of carcinoma of the colon and rectum. *Surg Gynecol Obstet* 1992;174:27-32
3. Jeffery GM, Hickey BE, Hider P. Follow-up strategies for patients treated for non-metastatic colorectal cancer. *Cochrane Database Syst Rev* 2002;CD002200
4. Renehan AG, Egger M, Saunders MP, O'Dwyer ST. Impact on survival of intensive follow up after curative resection for colorectal cancer: systematic review and meta-analysis of randomised trials. *BMJ* 2002;324:813
5. Figueredo A, Rumble RB, Maroun J, et al. Follow-up of patients with curatively resected colorectal cancer: a practice guideline. *BMC Cancer* 2003;3:26
6. Desch CE, Benson AB, III, Somerfield MR, et al. Colorectal cancer surveillance: 2005 update of an American Society of Clinical Oncology practice guideline. *J Clin Oncol* 2005;23:8512-8519

7. Hustinx R. PET imaging in assessing gastrointestinal tumors. *Radiol Clin North Am* 2004;42:1123-39, ix
8. Geus-Oei LF, Ruers TJ, Punt CJ, Leer JW, Corstens FH, Oyen WJ. FDG-PET in colorectal cancer. *Cancer Imaging* 2006;6:S71-S81
9. Even-Sapir E, Parag Y, Lerman H, et al. Detection of recurrence in patients with rectal cancer: PET/CT after abdominoperineal or anterior resection. *Radiology* 2004;232:815-822
10. Mahfouz T, Miceli MH, Saghafifar F, et al. 18F-fluorodeoxyglucose positron emission tomography contributes to the diagnosis and management of infections in patients with multiple myeloma: a study of 165 infectious episodes. *J Clin Oncol* 2005;23:7857-7863
11. Goshen E, Davidson T, Aderka D, Zwas ST. PET/CT detects abdominal wall and port site metastases of colorectal carcinoma. *Br J Radiol* 2006;79:572-577
12. Votrubova J, Belohlavek O, Jaruskova M, et al. The role of FDG-PET/CT in the detection of recurrent colorectal cancer. *Eur J Nucl Med Mol Imaging* 2006;33:779-784
13. Thomson WH, Foy CJ, Longman RJ. The nature of local recurrence after colorectal cancer resection. *Colorectal Dis* 2007;

14. Flamen P. Positron emission tomography in colorectal cancer. *Best Pract Res Clin Gastroenterol* 2002;16:237-251
15. Selvaggi F, Cuocolo A, Sciaudone G, Maurea S, Giuliani A, Mainolfi C. FGD-PET in the follow-up of recurrent colorectal cancer. *Colorectal Dis* 2003;5:496-500
16. Cohade C, Osman M, Leal J, Wahl RL. Direct comparison of (18)F-FDG PET and PET/CT in patients with colorectal carcinoma. *J Nucl Med* 2003;44:1797-1803
17. Delbeke D, Vitola JV, Sandler MP, et al. Staging recurrent metastatic colorectal carcinoma with PET. *J Nucl Med* 1997;38:1196-1201
18. Tatlidil R, Jadvar H, Bading JR, Conti PS. Incidental colonic fluorodeoxyglucose uptake: correlation with colonoscopic and histopathologic findings. *Radiology* 2002;224:783-787
19. Boellaard R, Krak N, Hoekstra O, Lammertsma A. Effects of noise, image resolution, and ROI definition on the accuracy of standard uptake values: a simulation study. *J Nucl Med* 2004; 45: 1519-1527
20. Krak N, Boellaard R, Hoekstra O, Twisk J, Hoekstra C, Lammertsma A. Effects of ROI definition and reconstruction method on quantitative outcome and applicability in a response monitoring trial. *Eur J Nucl Med Mol Imaging* 2005; 32: 294-301

21. Westerterp M, Pruim J, Oyen W, et al. Quantification of FDG PET studies using standardised uptake values in multi-centre trials: effects of image reconstruction, resolution and ROI definition parameters. *Eur J Nucl Med Mol Imaging* 2007; 34: 392-404

Tables

Table 1: Patient characteristics, tumour stage, and indications for PET-CT in patients with colorectal cancer .

Total number of patients		70
Gender (n)	men	43
	women	27
Age (years, mean \pm SD)		65 \pm 9
Primary tumour site	sigmoid	46
	rectum	24
Tumour stage at diagnosis	I	8
	IIA	12
	IIB	3
	IIIA	9
	IIIB	20
	IV	18
Indication for PET-CT scanning	elevated CEA	39
	suspected tumour recurrence, anywhere	19
	evaluation resectability of liver mets	4
	therapy response	4
	staging second primary tumour	4
Postoperative delay	1-12 months	24
	12-24 months	16
	> 24 months	30

Table 2: Visual analysis of the ^{18}F -FDG uptake at the peri-anastomosis in patients with and without a tumour recurrence.

^{18}F -FDG uptake (visually)	tumour recurrence (histology as the gold standard)	no tumour recurrence (histology and/or follow- up information as the gold standard)	
increased	11	16	27
normal	0	43	43
	11	59	70

Figures

Figure 1: scatter plot of SUV_{max} showing overlap between patients with (R+) and without (R-) a peri-anastomotic tumour recurrence.

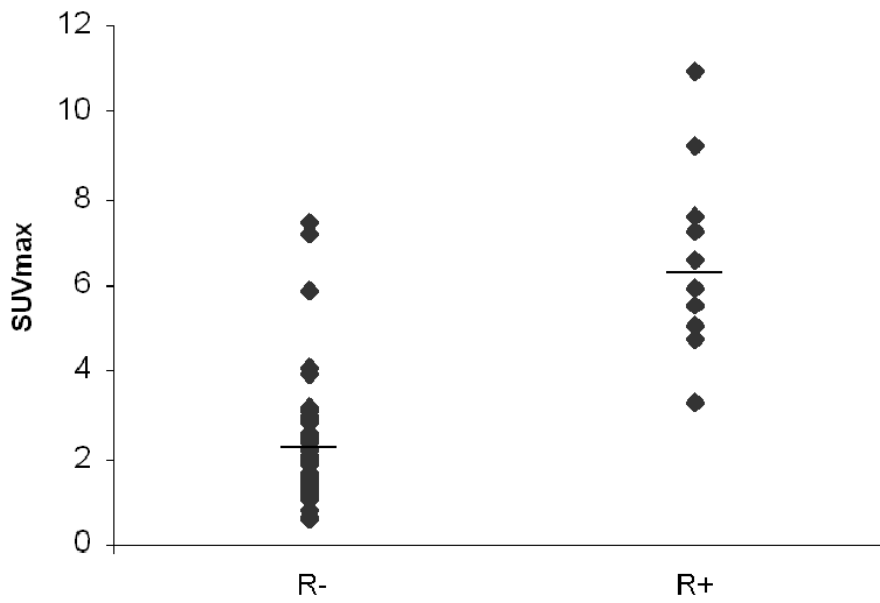


Figure 2: Two-dimensional representation of SUV_{max} at the peri-anastomosis after surgery in patients with and without a tumour recurrence showing overlap of SUV_{max} between benign and malignant lesions within 12 months postoperatively. Thereafter, a threshold SUV_{max} of 3.2 (dotted line) discriminated between inflammation and tumour recurrence in all but one patient.

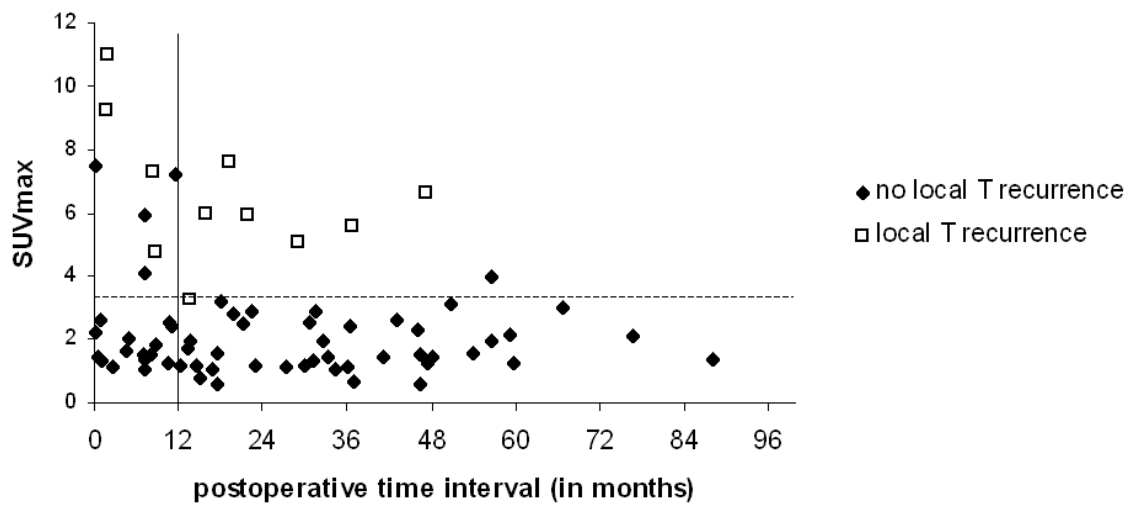


Figure 3:

Representative CT and PET images of the case with the lowest SUV_{max} value for a proven tumour recurrence at 14 months postoperatively (*upper row*) and the single false positive case at 57 months postoperatively (*lower row*).

Upper row: Transaxial CT image (left) showing asymmetric thickening of the bowel wall at the perianastomotic region. Focally enhanced ^{18}F -FDG uptake on the corresponding transaxial PET image (middle). SUV_{max} (=3.264) was just above the threshold value. Visualization of the radio-opaque suture material on the corresponding sagittal CT image (right).

Lower row: On the transaxial CT image (left) radio-opaque suture material is visible at the normal anastomosis. Increased ^{18}F -FDG uptake is noted on the corresponding transverse (middle) and sagittal (right) PET image. SUV_{max} (= 3.937) was above the threshold value. Colonoscopy in this patient was negative for malignancy.

