

Technical Note

Isolated Meniscotibial Ligament Rupture: The Medial Meniscus “Belt Lesion”

Sylvain Guy, M.D., Alexandre Ferreira, M.D., Alessandro Carrozzo, M.D., Jean-Romain Delaloye, M.D., Etienne Cavaignac, M.D., Ph.D., Thais Dutra Vieira, M.D., and Bertrand Sonnery-Cottet, M.D.

Abstract: Ramp lesions play a major role in both anteroposterior and rotational instability following anterior cruciate ligament rupture. The meniscotibial ligament (MTL) is the most important structure to repair and is the primary stabilizer of the posterior horn of the medial meniscus. The posteroinferior insertion of the MTL on the posterior horn of the medial has been described, forming a posterior “belt.” Isolated MTL lesion diagnosis can be challenging, as the absence of a meniscocapsular ligament lesion prevents its correct visualization through transnotch vision. This article details a technique to diagnose and repair the “belt lesion” of the medial meniscus.

First described in the 1980s, the literature regarding ramp lesions has grown substantially over the last decade.^{1,2} Defined as posterior longitudinal tears at the meniscocapsular junction, their major role in both anteroposterior and rotational instability following anterior cruciate ligament (ACL) rupture has been revealed.³⁻⁵ Since preoperative diagnosis is problematic due to the low sensitivity of magnetic resonance imaging, arthroscopic evaluation using transnotch vision during ACL reconstruction remains the gold standard.⁶⁻¹⁰ Given their frequency, estimated to be

between 9.3% and 29.6% of ACL rupture cases, additional systematic research on ramp lesions by exploring the posteromedial compartment is necessary.⁶⁻¹¹

The anatomy of the posterior horn of the medial meniscus (PHMM) has been studied to better understand these lesions, their injury mechanism, and the structures to be repaired. In 2019, DePhillipo et al.¹² described a common insertion of the meniscotibial (MTL) and meniscocapsular (MCL) ligaments on the posterior aspect of the PHMM. This anatomy has been further developed in 2021 by Cavaignac et al., revealing a distinguished posteroinferior insertion of the MTL forming a posterior “belt” of the PHMM (Fig 1).¹³ Isolated MTL tears can be categorized as type III ramp lesions according to Thauinat et al.¹⁴ and may cause meniscal extrusion or rotational instability (Fig 2).^{15,16} However, their diagnosis is particularly challenging, as the absence of an MCL lesion prevents correct visualization of the MTL through transnotch vision. The present technique describes the arthroscopic exploration and repair of these medial meniscus “belt lesions” (Video 1, Table 1).

Surgical Technique (With Video Illustration)

Patient Setup

The patient is placed supine on a standard operative table. A lateral post is positioned just proximal to the knee upon the tourniquet to block external hip rotation. A foot roll is positioned so that the knee could be installed at 90° of flexion. The knee is free and can be mobilized in all amplitudes.

From the Centre Orthopedique Santy, FIFA Medical Center of Excellence, Hôpital Privé Jean Mermoz, Groupe GDS-Ramsay, Lyon, France (S.G., A.F., A.C., T.D.V., B.S.-C.); Clinic of Orthopedics and Traumatology, Department of Surgery, Kantonsspital, Winterthur, Switzerland (J.-R.D.); and Department of Orthopedic Surgery and Trauma, Hôpital Pierre-Paul Riquet, Toulouse, France (E.C.).

Investigations were performed at Centre Orthopédique Santy, Lyon, France.

The authors report the following potential conflicts of interest or sources of funding: S.G., A.F., and E.C. report grants from Arthrex. B.S.-C. is a paid consultant, receives royalties and research support, and has made presentations for Arthrex. Full ICMJE author disclosure forms are available for this article online, as [supplementary material](#).

Received July 15, 2021; accepted September 29, 2021.

Address correspondence to Thais Dutra Vieira, M.D., Centre Orthopédique Santy, FIFA Medical Center of Excellence, Hôpital Privé Jean Mermoz, Groupe Ramsay GDS, 69008 Lyon, France. E-mail: thaisdutravieira@hotmail.com

© 2021 The Authors. Published by Elsevier Inc. on behalf of the Arthroscopy Association of North America. This is an open access article under the CC BY-NC-ND license (<http://creativecommons.org/licenses/by-nc-nd/4.0/>).

2212-6287/211014

<https://doi.org/10.1016/j.eats.2021.09.013>

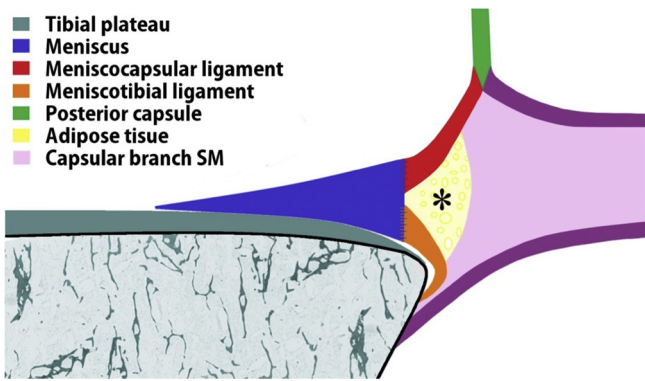


Fig 1. Diagram of a sagittal cut of the posteromedial corner of the knee proposed by Cavaignac et al.¹³ The proximal insertion of the meniscotibial ligament is on the inferior edge of the base of the medial meniscus. *Adipose tissue located between the meniscus in front and the tendinous capsular branch of the semimembranosus (SM). (Reprinted with permission from *The American Journal of Sports Medicine*.)

Injury Assessment

A high anterolateral portal is performed to spare the infrapatellar fat pad.¹⁷ An anteromedial portal is performed as standard. PHMM instability is first assessed by meticulous probing through anterior visualization. A transnotch approach is then performed for posteromedial retro-condylar exploration. Internal rotation of

the tibia is performed to tension the posteromedial capsule and investigate for MCL tears. In the event of discordance between unexplained anterior meniscal hypermobility despite the integrity of the MCL, an isolated MTL injury was suspected (Fig 3). Through anterior vision, the PHMM is lifted with a probe. The MTL is revealed, and a rupture can be diagnosed as an interruption of the posterior "belt" (Fig 4).

"Belt Lesion" Repair

A posteromedial portal is performed under transnotch vision. With the tibia positioned in internal rotation, the MCL was debrided using a needle or a shaver (Fig 5). The "belt lesion" is then visible, and the tibial plateau passes through it.

A Suture Hook (Arthrex, Naples, FL) is introduced by the posteromedial portal and loaded with a no. 0 absorbable monofilament suture (polydioxanone). A left curved hook device is used for the right knee and vice versa. It is first passed through both the MCL and MTL and then through the posterior meniscal wall. The polydioxanone suture is extracted and collected by the posteromedial portal using a grasper. A self-locking sliding knot is tied using a knot-pusher, secured by two inverted half-keys. Separate points are performed in the same way to repair the entire lesion, going from the most medial to the most lateral one (Fig 6). Once

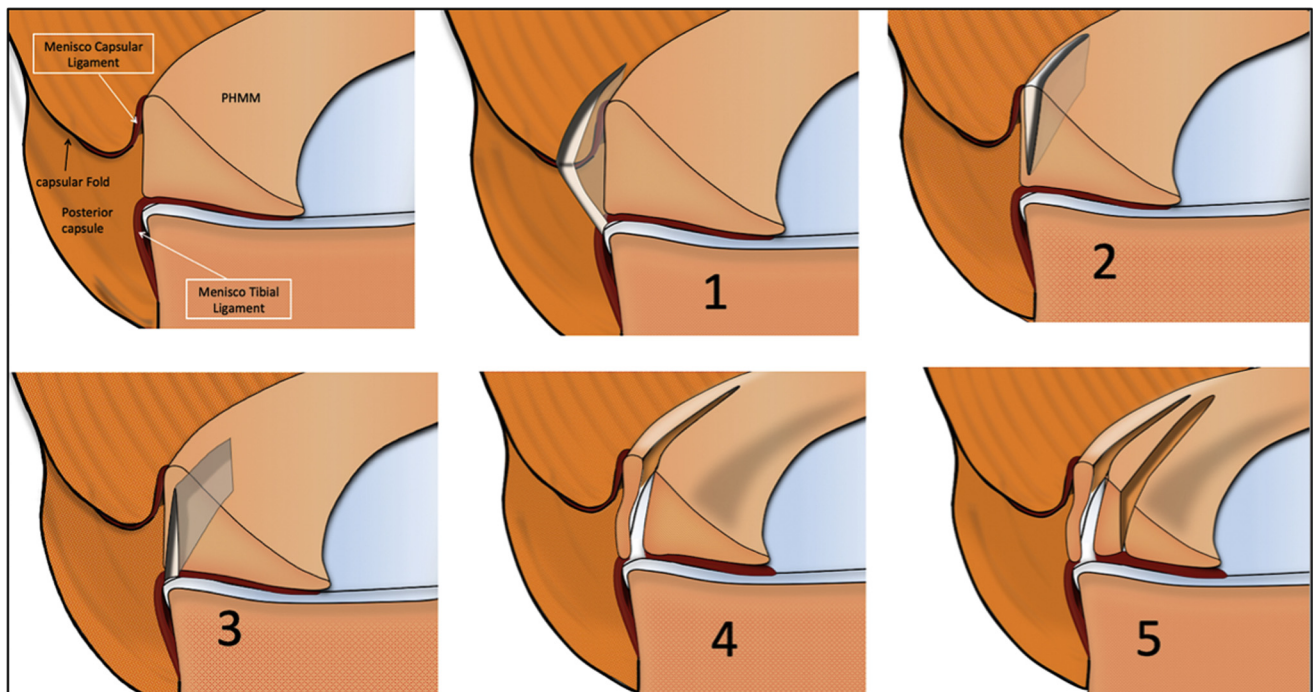


Fig 2. Ramp lesion subtypes according to Thaanat's classification.¹⁴ Representation of the meniscocapsular area of the posterior horn of the medial meniscus (PHMM) with the 5 subtypes of ramp lesions: 1, capsulosynovial junction complete tear; 2, red zone partial superior tear; 3, red zone partial inferior tear; 4, red zone complete tear; 5, complete double tear. Isolated MTL tears, or "belt lesions," can be classified as type 3. (Reprinted with permission from *The American Journal of Sports Medicine*.) (MTL, meniscotibial ligament.)

Table 1. Surgical Steps and Pearls and Pitfalls of "Belt Lesion" Repair

Surgical Step	Pearls	Pitfalls and Tips
• Anterior probing	• Anterior probing allows reliable testing of the posterior stability of the medial meniscus.	• An anterior probing found normal must not be free of a more accurate transnotch vision to confirm the absence of ramp lesion.
• Transnotch vision	• Transnotch vision allows an accurate evaluation of capsulomeniscal lesions.	• To not to miss a ramp lesion, an internal rotation of the tibia must be performed to tension the posteromedial capsule. The capsulomeniscal junction can then be evaluated with a needle.
• MTL evaluation	• Lifting the meniscus with a probe exposes its posteroinferior portion, thus evaluating the integrity of the MTL.	• Sufficient work space must be created to properly expose the MTL. The knee must be positioned in valgus and full extension. If the medial compartment is still constrained, a release of the medial collateral Ligament can be achieved.
• Posteromedial portal achievement	• Correct positioning of the posteromedial portal avoids neurovascular injury.	• To avoid neurovascular injury, the portal must be performed with the knee at 90° of flexion. A needle is used, positioned under arthroscopic control with the help of trans-illumination. The safe zone is located proximal and posterior to the tibial plateau. It then guides the scalpel when the portal is achieved.
• MCL debridement	• Shaver or needle debridement of the MCL reveals the "belt lesion."	• To avoid any neurovascular lesions, the head of the shaver must always point forward.
• « Belt lesion » repair	• The use of a Suture Hook (Arthrex) allows precise reinsertion of the MCL and MTL to the meniscal wall.	• The learning curve for posterior repair is long. To facilitate understanding of the procedure, it can be divided into 4 steps: <ol style="list-style-type: none"> 1. The tip of the hook is directed downwards, perpendicular to the MCL and MTL. The operator raises a hand to pinch the ligaments. 2. A rotational movement is performed, hook in place, to bring its tip out between the ligaments and the meniscus. 3. The tip of the hook is directed forward, perpendicular to the meniscal wall. The operator pushes a hand to pinch the meniscal wall. 4. A rotational movement is performed, hook in place, to bring its tip out at the most proximal part of the meniscal wall.

MCL, meniscocapsular ligament; MTL, meniscotibial ligament.

the repair is completed, anterior probing is performed through anterior vision. The correction of posterior instability is checked. The meniscus can be lifted again to evaluate the proper reinsertion of the MTL on the lower portion of the PHMM (Fig 7).

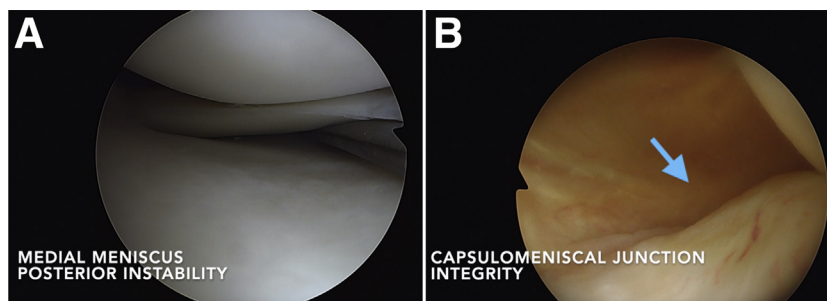
Rehabilitation

Weight-bearing is partial in the immediate post-operative period and protected by crutches until the fourth week. Knee flexion is limited to 90° for 6 weeks. Early rehabilitation is focused on the restoration of full extension. Cycling is allowed at 6 weeks, nonpivoting sports at 4 months, pivoting noncontact sports at 6 months and pivoting contact sports at 8 to 9 months.

Discussion

The presented technique involves the arthroscopic exploration and repair of an isolated MTL rupture. Several hypotheses have been described regarding the injury mechanism of ramp lesions. Hughston¹⁸ supposed that excessive anterior tibial translation in the context of ACL tears could cause reflex contraction of the semimembranosus, leading through the capsular branch to a traction lesion of the MCL and/or MTL. He also suggested that in this setting, the meniscus could be trapped between the femur and tibia, resulting in PHMM injury. These hypotheses are consistent with recent anatomical and histologic descriptions. In 2021, Cavaignac et al.¹³ described 2 distinct ligament

Fig 3. Anterior probing and transnotch vision. (A) Anterior arthroscopic view of the medial meniscus: PHMM posterior instability is assessed by anterior probing. (B) Transnotch view of the posterior horn of the medial meniscus: The capsulomeniscal junction is found intact through transnotch vision (blue arrow).



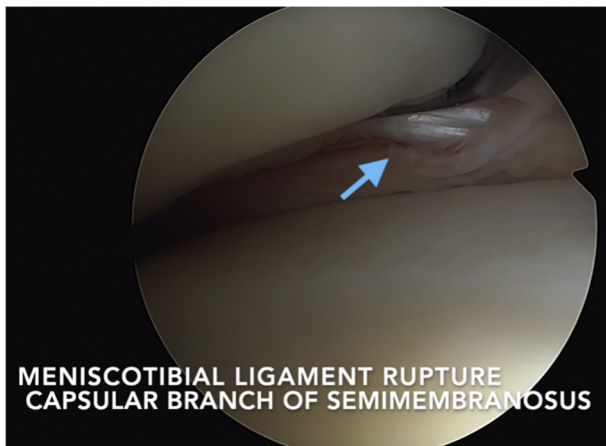


Fig 4. Anterior arthroscopic view of the medial meniscus: MTL integrity checking. A complete rupture of the MTL is diagnosed, and the capsular branch of the semimembranosus is visible through it (blue arrow). (MTL, meniscotibial ligament.)

insertions on the PHMM, one posterosuperior for the MCL and one posteroinferior for the MTL. A capsular branch of the semimembranosus also has been described, directly attached to the MCL, the MTL and the posteromedial joint capsule. This is in line with our observation of an isolated lesion of the MTL and the capsular branch of the semimembranosus visualized through it (Video 1).

Ramp lesions can lead to posteromedial instability.² Biomechanical studies have reported a significant increase in both anteroposterior³⁻⁵ and rotational laxity^{3,4,16} when a ramp lesion is associated with an

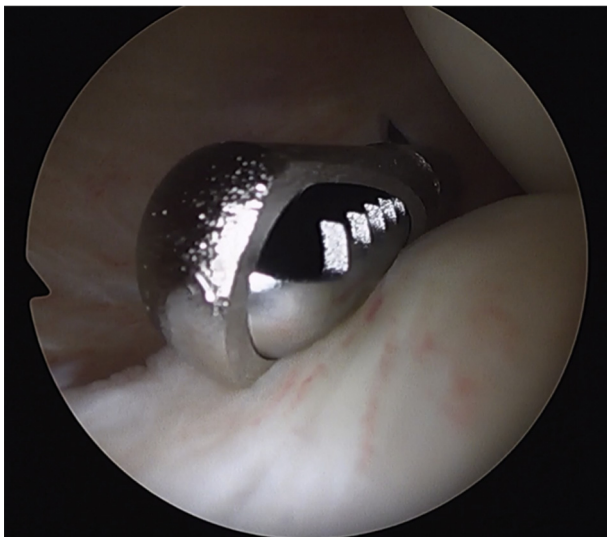


Fig 5. Transnotch view of the posterior horn of the medial meniscus: MCL debridement. The MCL was debrided with a shaver by a posteromedial portal to reveal the MTL lesion. (MCL, meniscocapsular ligament; MTL, meniscotibial ligament.)

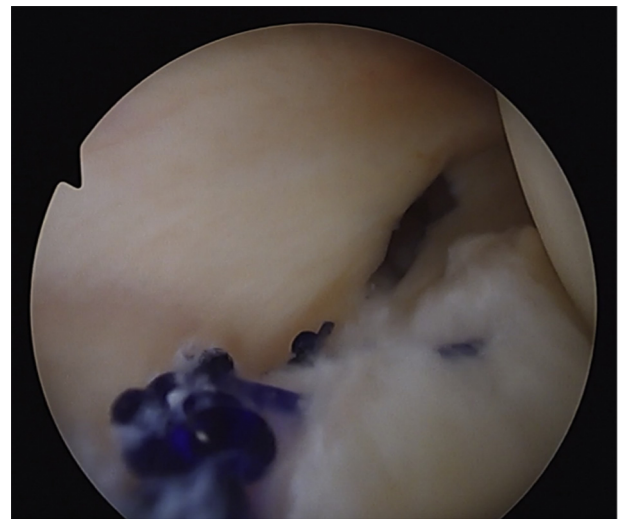


Fig 6. Transnotch view of the posterior horn of the medial meniscus. MTL lesion repair with separate points. Separate points performed through the posteromedial approach allow for precise MTL lesion repair under arthroscopic control. (MTL, meniscotibial ligament.)

ACL tear. The MTL appears to be the primary stabilizer of PHMM, as similar results have been found in the case of an isolated rupture.^{3,15,16} Thus, it acts as a true posterior “belt” for the medial meniscus. The diagnosis of this lesion is a challenge in itself, and its biomechanical importance has prompted us to pay particular attention to its investigation and management. To our knowledge, this Technical Note is the first to focus on the diagnosis and repair of an isolated MTL lesion.

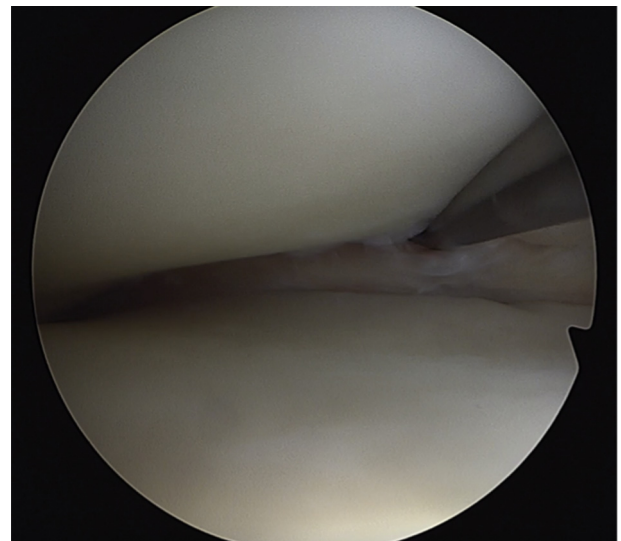


Fig 7. Anterior arthroscopic view of the medial meniscus. MTL repair evaluation. Complete closure of the MTL lesion was evaluated with anterior probing. The stability of the PHMM is checked. (MTL, meniscotibial ligament; PHMM, posterior horn of the medial meniscus.)

Table 2. Advantages and Disadvantages of the Present Technique

Advantages	Disadvantages
<ul style="list-style-type: none"> • Better visualization of the PHMM • Improved visualization of the "belt lesion" • Improved debridement of the lesion • Direct visualization of the meniscotibial repair • Vertical suture perpendicular to MTL 	<ul style="list-style-type: none"> • Posteromedial portal • Risk of saphenous nerve or venous injury • Learning curve for PM portal and suture hook • Meniscocapsular debridement

MTL, meniscotibial ligament; PHMM, posterior horn of the medial meniscus; PM, posteromedial.

Different techniques have been described to repair PHMM, particularly ramp lesions.¹⁹ Despite technical improvements, the failure rate remains high.²⁰ With the classic anteromedial portal, debridement of the lesion may be limited, and the all-inside anchor sutures cannot provide a complete closure of the lesion. Since 2013, we have observed a decrease in the secondary meniscectomy rate for any type of medial meniscus repair from 25%²⁰ to 7%,¹¹ with a 5-year mean follow-up. These results follow the routine performance of a transnotch vision combined with anterior probing associated with posteromedial hook repair in the case of ramp lesions. Regarding isolated MTL lesions, we chose to use a posterior meniscocapsular opening to debride the MTL lesion, allowing us to monitor its complete closure through hook sutures via the posteromedial portal.

The main disadvantage of this technique is the need for an additional posteromedial portal with risks of vasculo-nervous injury. However, this approach is safe as long as a few prerequisites are respected. Another disadvantage of this technique is the learning curve for the execution of this approach and for meniscal hook repair. The advantages and disadvantages are summarized in Table 2.

References

1. Hamberg P, Gillquist J, Lysholm J. Suture of new and old peripheral meniscus tears. *J Bone Joint Surg Am* 1983;65: 193-197.
2. Sonnery-Cottet B, Serra Cruz R, Vieira TD, Goes RA, Saithna A. Ramp lesions: An unrecognized posteromedial instability? *Clin Sports Med* 2020;39:69-81.
3. DePhillipo NN, Moatshe G, Brady A, et al. Effect of meniscocapsular and meniscotibial lesions in ACL-deficient and ACL-reconstructed knees: A biomechanical study. *Am J Sports Med* 2018;46:2422-2431.
4. Stephen JM, Halewood C, Kitl C, Bollen SR, Williams A, Amis AA. Posteromedial meniscocapsular lesions increase tibiofemoral joint laxity with anterior cruciate ligament deficiency, and their repair reduces laxity. *Am J Sports Med* 2016;44:400-408.
5. Ahn JH, Bae TS, Kang K-S, Kang SY, Lee SH. Longitudinal tear of the medial meniscus posterior horn in the anterior cruciate ligament-deficient knee significantly influences anterior stability. *Am J Sports Med* 2011;39:2187-2193.
6. Bollen SR. Posteromedial meniscocapsular injury associated with rupture of the anterior cruciate ligament: A previously unrecognized association. *J Bone Joint Surg Br* 2010;92:222-223.
7. DePhillipo NN, Cinque ME, Chahla J, Geeslin AG, Engebretsen L, LaPrade RF. Incidence and detection of meniscal ramp lesions on magnetic resonance imaging in patients with anterior cruciate ligament reconstruction. *Am J Sports Med* 2017;45:2233-2237.
8. Hatayama K, Terauchi M, Saito K, Aoki J, Nonaka S, Higuchi H. Magnetic resonance imaging diagnosis of medial meniscal ramp lesions in patients with anterior cruciate ligament injuries. *Arthroscopy* 2018;34:1631-1637.
9. Liu X, Feng H, Zhang H, Hong L, Wang XS, Zhang J. Arthroscopic prevalence of ramp lesion in 868 patients with anterior cruciate ligament injury. *Am J Sports Med* 2011;39:832-837.
10. Sonnery-Cottet B, Conteduca J, Thaunat M, Gunepin FX, Seil R. Hidden lesions of the posterior horn of the medial meniscus: A systematic arthroscopic exploration of the concealed portion of the knee. *Am J Sports Med* 2014;42: 921-926.
11. Sonnery-Cottet B, Praz C, Rosenstiel N, et al. Epidemiological evaluation of meniscal ramp lesions in 3214 anterior cruciate ligament-injured knees from the SANTI Study Group Database: A risk factor analysis and study of secondary meniscectomy rates following 769 ramp repairs. *Am J Sports Med* 2018;46:3189-3197.
12. DePhillipo NN, Moatshe G, Chahla J, et al. Quantitative and qualitative assessment of the posterior medial meniscus anatomy: Defining meniscal ramp lesions. *Am J Sports Med* 2019;47:372-378.
13. Cavaignac E, Sylvie R, Teulières M, et al. What is the relationship between the distal semimembranosus tendon and the medial meniscus? A gross and microscopic analysis from the SANTI Study Group. *Am J Sports Med* 2021;49:459-466.
14. Thaunat M, Ingale P, Penet A, et al. Ramp lesion subtypes: Prevalence, imaging, and arthroscopic findings in 2156 anterior cruciate ligament reconstructions [Published online April 21, 2021]. *Am J Sports Med*. <https://doi.org/10.1177/03635465211006103>
15. Paletta GA, Crane DM, Konicek J, et al. Surgical treatment of meniscal extrusion: A biomechanical study on the role of the medial meniscotibial ligaments with early clinical validation. *Orthop J Sports Med* 2020;8. 2325967120936672.
16. Peltier A, Lording T, Maubisson L, Ballis R, Neyret P, Lustig S. The role of the meniscotibial ligament in posteromedial rotational knee stability. *Knee Surg Sports Traumatol Arthrosc* 2015;23:2967-2973.
17. Sonnery-Cottet B, Archbold P, Zayni R, et al. High lateral portal for sparing the infrapatellar fat-pad during ACL

- reconstruction. *Orthop Traumatol Surg Res* 2011;97:870-873.
18. Hughston JC. *Knee ligaments: Injury and repair*. Saint Louis, MO: Mosby, 1993.
 19. Acosta J, Ravaei S, Brown SM, Mulcahey MK. Examining techniques for treatment of medial meniscal ramp lesions during anterior cruciate ligament reconstruction: A systematic review. *Arthroscopy* 2020;36:2921-2933.
 20. Rochongar G, Cucurulo T, Ameline T, et al. Meniscal survival rate after anterior cruciate ligament reconstruction. *Orthop Traumatol Surg Res* 2015;101:S323-326 (suppl 8).