



Universiteit
Leiden
The Netherlands

Imaging standardisation in metastatic colorectal cancer: a joint EORTC-ESOI-ESGAR expert consensus recommendation

Unterrainer, M.; Deroose, C.M.; Herrmann, K.; Moehler, M.; Blomqvist, L.; Cannella, R.; ...
; European Soc Gastrointestinal Abdominal Radiology (ESGAR)

Citation

Unterrainer, M., Deroose, C. M., Herrmann, K., Moehler, M., Blomqvist, L., Cannella, R., ...
Kunz, W. G. (2022). Imaging standardisation in metastatic colorectal cancer: a joint
EORTC-ESOI-ESGAR expert consensus recommendation. *European Journal Of Cancer*, 176,
193-206. doi:10.1016/j.ejca.2022.09.012

Version: Publisher's Version

License: [Creative Commons CC BY 4.0 license](#)

Downloaded from: <https://hdl.handle.net/1887/3567647>

Note: To cite this publication please use the final published version (if applicable).



Original Research

Imaging standardisation in metastatic colorectal cancer: A joint EORTC-ESOI-ESGAR expert consensus recommendation



Marcus Unterrainer^{a,b}, Christophe M. Deroose^{b,f}, Ken Herrmann^{b,c,g}, Markus Moehler^{c,h}, Lennart Blomqvist^{b,i,j}, Roberto Cannella^{b,e,k,l}, Caroline Caramella^{b,m}, Damiano Caruso^{d,n}, Manil D. Chouhan^{b,o}, Timm Denecke^{b,p}, Carolina De la Pinta^{b,q}, Lioe-Fee De Geus-Oei^{b,r,s}, Audrius Dulskas^{b,t}, Michel Eisenblätter^{b,u}, Kieran G. Foley^{b,e,v}, Sofia Gourtsoyianni^{d,e,w}, Frederic E. Lecouvet^{b,x}, Egesta Lopci^{b,y}, Monique Maas^{b,z}, Markus M. Obmann^{b,e,aa}, Daniela E. Oprea-Lager^{b,ab}, Joost J.C. Verhoeff^{b,ac}, Ines Santiago^{b,ad}, Sylvain Terraz^{b,ae}, Melvin D'Anastasi^{b,af}, Daniele Regge^{e,ag,ah}, Andrea Laghi^{d,e,m}, Regina G.H. Beets-Tan^{b,ai}, Volker Heinemann^{aj}, Florian Lordick^{c,ak}, Elizabeth C. Smyth^{c,al}, Jens Ricke^{a,c}, Wolfgang G. Kunz^{a,b,c,d,*} on behalf of the European Organisation for Research and Treatment of Cancer (EORTC) Imaging Group, the European Organisation for Research and Treatment of Cancer (EORTC) Gastrointestinal Tract Cancer Group, the European Society of Oncologic Imaging (ESOI) and the European Society of Gastrointestinal and Abdominal Radiology (ESGAR)

^a Department of Radiology, University Hospital, LMU Munich, Munich, Germany

^b Imaging Group, European Organisation of Research and Treatment in Cancer (EORTC), Brussels, Belgium

^c Gastrointestinal Tract Cancer Group, European Organisation of Research and Treatment in Cancer (EORTC), Brussels, Belgium

^d European Society of Oncologic Imaging (ESOI), European Society of Radiology, Vienna, Austria

^e European Society of Gastrointestinal and Abdominal Radiology (ESGAR), Vienna, Austria

^f Nuclear Medicine, University Hospitals Leuven, Leuven, Belgium

* Corresponding author: Head of Oncologic Imaging, Research Group PI Oncologic Imaging, EORTC Imaging Group Subcommittee Chair Quality Assurance/Quality Control, Department of Radiology, University Hospital, LMU Munich, Marchioninstr. 15, 81377 Munich, Germany. E-mail address: wolfgang.kunz@med.lmu.de (W.G. Kunz).

[@LMU_Radiology](#) (M. Unterrainer), [@deroose_c](#) (C.M. Deroose), [@ProfKHerrmann](#) (K. Herrmann), [@CCaramellaCICT](#) (C. Caramella), [@MdDamians](#) (D. Caruso), [@DrManil_Rad](#) (M.D. Chouhan), [@LopciEgesta](#) (E. Lopci), [@Doc_X_Ray](#) (M.M. Obmann), [@joostverhoeff](#) (J.J.C. Verhoeff), [@Andrea_Laghi_MD](#) (A. Laghi), [@rbeetstan](#) (R.G.H. Beets-Tan), [@FlorianLordick](#) (F. Lordick), [@LizzySmyth1](#) (E.C. Smyth), [@WolfgangGKunzMD](#) (W.G. Kunz), [@EORTC](#).

^g Department of Nuclear Medicine, University of Duisburg-Essen, and German Cancer Consortium (DKTK)-University Hospital Essen, Essen, Germany

^h Department of Medicine, Johannes Gutenberg-University Clinic, University of Mainz, Mainz, Germany

ⁱ Department of Medical Radiation Physics and Nuclear Medicine, Karolinska University Hospital, Stockholm, Sweden

^j Department of Molecular Medicine and Surgery, Karolinska Institute, Stockholm, Sweden

^k Section of Radiology – Department of Biomedicine, Neuroscience and Advanced Diagnostics (BiND), University Hospital “Paolo Giaccone”, Via Del Vespro 129, Palermo 90127, Italy

^l Department of Health Promotion, Mother and Child Care, Internal Medicine and Medical Specialties (PROMISE), University of Palermo, Via Del Vespro, 129, 90127 Palermo, Italy

^m Department of Radiology, Groupe Hospitalier Paris Saint-Joseph, Paris, Île-de-France, France

ⁿ Department of Medical Surgical Sciences and Translational Medicine, Sapienza – University of Rome, Radiology Unit – Sant’Andrea University Hospital, Italy

^o Division of Medicine, Centre for Medical Imaging, University College London (UCL), London, UK

^p Department of Diagnostic and Interventional Radiology, University Hospital Leipzig, Leipzig, Germany

^q Radiation Oncology Department, Ramón y Cajal Hospital, IRYCIS, Madrid, Spain

^r Department of Radiology, Leiden University Medical Center, Leiden, the Netherlands

^s Biomedical Photonic Imaging Group, University of Twente, Enschede, the Netherlands

^t Department of Abdominal and General Surgery and Oncology, National Cancer Institute, Vilnius, Lithuania

^u Department of Radiology, University Hospital Freiburg, Freiburg, Germany

^v Division of Cancer & Genetics, School of Medicine, Cardiff University, UK

^w 1st Department of Radiology, School of Medicine, National and Kapodistrian University of Athens, Areteion Hospital, Athens, Greece

^x Department of Radiology, Institut de Recherche Expérimentale et Clinique (IREC), Cliniques Universitaires Saint Luc, Université Catholique de Louvain (UCLouvain), Brussels, Belgium

^y Nuclear Medicine, IRCCS Humanitas Research Hospital, Via Manzoni 56, 20089 Rozzano (MI), Italy

^z Department of Radiology, Netherlands Cancer Institute, Amsterdam, the Netherlands

^{aa} Clinic of Radiology and Nuclear Imaging, University Hospital Basel, Petersgraben 4, 4051 Basel, Switzerland

^{ab} Department of Radiology and Nuclear Medicine, Amsterdam University Medical Centers, VU Medical Center, Amsterdam, the Netherlands

^{ac} Department of Radiation Oncology, University Medical Center Utrecht, Utrecht, the Netherlands

^{ad} Department of Radiology, Champalimaud Foundation, Av. Brasília, 1400-038 Lisbon, Portugal

^{ae} Unit of Interventional Radiology, Division of Radiology, Department of Diagnostics, University Hospitals of Geneva, Geneva, Switzerland

^{af} Medical Imaging Department, Mater Dei Hospital, University of Malta, Msida, Malta

^{ag} Department of Surgical Sciences, University of Turin, Turin, 10124, Italy

^{ah} Radiology Unit, Candiolo Cancer Institute, FPO-IRCCS, Candiolo, 10060, Italy

^{ai} Department of Radiology, The Netherlands Cancer Institute, Amsterdam, the Netherlands

^{aj} Department of Medicine III, University Hospital, LMU Munich, Munich, Germany

^{ak} Department of Medicine II and University Cancer Center Leipzig, University of Leipzig Medical Center, Leipzig, Germany

^{al} Department of Oncology, Cambridge University Hospitals NHS Foundation Trust, Cambridge, UK

Received 19 July 2022; received in revised form 13 September 2022; accepted 14 September 2022

Available online 28 September 2022

KEYWORDS

Colorectal cancer;
Imaging;
Computed
tomography;
Positron emission
tomography;
Standardisation;
Radiomics;
Artificial intelligence

Abstract Background: Treatment monitoring in metastatic colorectal cancer (mCRC) relies on imaging to evaluate the tumour burden. Response Evaluation Criteria in Solid Tumors provide a framework on reporting and interpretation of imaging findings yet offer no guidance on a standardised imaging protocol tailored to patients with mCRC. Imaging protocol heterogeneity remains a challenge for the reproducibility of conventional imaging end-points and is an obstacle for research on novel imaging end-points.

Patients and methods: Acknowledging the recently highlighted potential of radiomics and artificial intelligence tools as decision support for patient care in mCRC, a multidisciplinary, international and expert panel of imaging specialists was formed to find consensus on mCRC imaging protocols using the Delphi method.

Results: Under the guidance of the European Organisation for Research and Treatment of Cancer (EORTC) Imaging and Gastrointestinal Tract Cancer Groups, the European Society of Oncologic Imaging (ESOI) and the European Society of Gastrointestinal and Abdominal Radiology (ESGAR), the EORTC-ESOI-ESGAR core imaging protocol was identified.

Conclusion: This consensus protocol attempts to promote standardisation and to diminish variations in patient preparation, scan acquisition and scan reconstruction. We anticipate that this standardisation will increase reproducibility of radiomics and artificial intelligence studies and serve as a catalyst for future research on imaging end-points. For ongoing and future

mCRC trials, we encourage principal investigators to support the dissemination of these imaging standards across recruiting centres.

© 2022 The Author(s). Published by Elsevier Ltd. This is an open access article under the CC BY license (<http://creativecommons.org/licenses/by/4.0/>).

1. Introduction

The imaging assessment of tumour burden plays a key role in the clinical evaluation and management of almost all solid tumours. A standardised and structured documentation in the change of tumour burden has been pivotal for the implementation of imaging end-points in the scientific evaluation of cancer therapeutics, namely the Response Evaluation Criteria in Solid Tumors (RECIST) published 2009 in the latest version 1.1 [1]. Tumour regression as captured by an objective response is routinely used to serve as a measure of drug activity in phase II trials, progression-free survival as an, albeit imperfect, surrogate for overall survival.

In metastatic colorectal cancer (mCRC), therapy monitoring is routinely performed with computed tomography (CT) imaging [2]. It is well documented that intralesional metastatic changes visible to the human eye precede size-based changes during response and progression [3]. Beyond the subjective assessment, new imaging features can be quantified using modern image analysis (termed radiomics). The use of radiomics and artificial intelligence (AI) harbours great potential for early response assessment [4] and has been extensively studied in mCRC [5–8].

However, one of the biggest obstacles for applicability in trials and for generalisability towards clinical practice is the intra- and inter-institutional heterogeneity of imaging procedures. This heterogeneity significantly impacts radiomics stability and reproducibility and limits external applications of AI algorithms [4,9]. These issues arise largely from modifiable parameters such as contrast phases, contrast timing, and image reconstruction. These equally affect the CT component of positron emission tomography (PET)/CT examinations [10].

In a European effort across multiple oncology and imaging societies including several national comprehensive cancer centres, we conducted a Delphi consensus finding survey with the goal to standardise the imaging procedures for patients with mCRC.

2. Methods

2.1. Panel composition

For the abovementioned issue, we established a panel of European experts involved in the management of

patients with mCRC. Panelists were actively recruited under auspices of the European Organisation for Research and Treatment of Cancer (EORTC) Imaging Group, the EORTC Gastrointestinal Tract Cancer Group, the European Society of Oncologic Imaging and the European Society of Gastrointestinal and Abdominal Radiology and their chairpersons or presidents, respectively. Panelists were invited based on the clinical expertise, publication records and society guideline involvement with special emphasis on mCRC. Involvement of different European countries was sought. The expert panelists involved in this initiative are presented in Table 1; the country representation is shown in Fig. 1.

2.2. Delphi consensus process

We conducted a prospective, multistep, modified, non-anonymous Delphi consensus approach to assess imaging properties and specifications regarding mCRC imaging among European mCRC experts [11,12]. Two local facilitators from LMU Munich (MU & WGK) edited the questionnaires and moderated the consensus finding process. Questionnaires were edited by Google forms (<https://www.google.com/forms/about/>), and access links were directly forwarded to the expert panelists to initiate every poll. This study received endorsement by the EORTC.

The first step collected general information regarding local specifications and panelists in order to identify common practice and distinct differences among European centres. In the next two steps, further imaging specification regarding CT and PET/CT imaging in mCRC was assessed. The results of each round were forwarded to the panelists to further foster consensus and to influence opinion-forming among the expert panelists (Supp. Files 1 to 3). The composition of the panel was not anonymous; however, individual answers were not attributable to individual expert panelists. The final aim was to reach consensus regarding a potential mCRC imaging protocol for imaging standardisation. In case of questions with binary answers, an agreement of 70% was considered a consensus. In questions with multiple-choice character, an agreement of at least 50% was considered consensus. A schematic of the applied Delphi process is displayed in Fig. 2.

Table 1
Participating expert panelists.

Name	Affiliation	City	Country
Lennart Blomqvist	Karolinska Institutet	Solna	Sweden
Roberto Cannella	Università degli Studi di Palermo	Palermo	Italy
Caramella Caroline	Institut de Cancérologie Gustave Roussy	Villejuif	France
Damiano Caruso	Sapienza University of Rome	Rome	Italy
Manil Chouhan	University College London, UCL Centre for Medical Imaging	London	United Kingdom
Melvin D'Anastasi	Mater Dei Hospital, Department of Medical Imaging, Malta	Msida	Malta
Timm Denecke	University of Leipzig	Leipzig	Germany
Christophe Deroose	University Hospitals Leuven	Leuven	Belgium
Audrius Dulskas	National Cancer Institute Vilnius	Vilnius	Lithuania
Lioe-Fee De Geus-Oei	Leiden University Medical Center	Leiden	Netherlands
Carolina de la Pinta	Hospital Universitario Ramón y Cajal	Madrid	Spain
Michel Eisenblätter	University of Freiburg	Freiburg	Germany
Kieran Foley	Cardiff University	Cardiff	United Kingdom
Sofia Gourtsoyianni	National and Kapodistrian University of Athens	Athens	Greece
Ken Herrmann	University of Essen	Essen	Germany
Frederic Lecouvet	Cliniques Universitaires Saint Luc, UCLouvain	Brussels	Belgium
Egesta Lopci	Humanitas Clinical and Research Center, University of Milan	Milan	Italy
Monique Maas	The Netherlands Cancer Institute	Amsterdam	Netherlands
Markus Obmann	University of Basel	Basel	Switzerland
Daniela Oprea-Lager	Amsterdam University Medical Center, Amsterdam (VUmc)	Amsterdam	Netherlands
Daniele Regge	Università degli Studi di Torino	Torino	Italy
Jens Ricke	University Hospital, LMU Munich	Munich	Germany
Ines Santiago	Champalimaud Foundation, Lisbon	Lisbon	Portugal
Sylvain Terraz	Université de Genève	Geneva	Switzerland
Joost Verhoeff	University of Utrecht	Utrecht	Netherlands

The panelists are listed in alphabetical order by last name.

2.3. Trial registration

This prospective survey was registered on clinicaltrials.gov (registry number NCT04656782) and can be accessed using this link: <https://clinicaltrials.gov/ct2/show/NCT04656782>.

3. Results

3.1. Panel characteristics

Twenty-five expert panelists were included to ensure broad representation among European centres. Prerequisites for inclusion were activity in a respective imaging society/oncology-related society and board certification in imaging specialities or oncology-related specialities. Panelists were recruited from 13 European countries with most representatives being from both the Netherlands and Italy (four expert panelists each). In total, 14/25 were radiologists, 5/25 nuclear medicine physicians, 3/25 both radiologists and nuclear medicine physicians, 2/25 radiation oncologists and 1/25 a colorectal surgeon. Most panelists have a clear clinical focus on reporting standard morphological imaging using CT and MRI (19/25, 76%) and 6/25 (24%) have a primary focus on hybrid imaging, e.g., using PET/CT. The panelist responses from the final consensus survey round are listed in [Table 2](#).

3.2. General information and institutional specifications

Among the panelists' institutions, a broad majority participate in imaging for randomised controlled trials

(RCTs) (22/25, 88%), and most institutions currently include patients in RCTs involving mCRC (16/25, 64%); 18/25 panelists experienced the need of imaging protocol adaptations due to the specific requirements of the respective sponsor, even 4/25 (16%) experience imaging protocol changes in at least 50% of clinical trials. Among the participating panelists' institutions, there was a median number of five (range, 1–15) CT scanners and a median number of two (range, 0–4) PET/CTs. Predominant vendors of CT scanners were (multiple answers possible) Siemens Healthineers (56%), Philips Healthcare (48%) and GE Healthcare (48%); predominant vendors of PET/CT scanners were (multiple answers possible) Philips Healthcare (40%), Siemens Healthineers (36%) and GE Healthcare (28%). Regarding PET/CT and CT imaging protocols, only 44% of centres apply a homogeneously aligned protocol. Within their own department, 28% of panelists have experienced diverging imaging protocols across CT scanners, e.g., due to diverging slice thickness or diverging reconstruction algorithms. However, 56% of panelists experienced diverging imaging protocols across CT scanners among different institutions; 92% of institutions are experienced with radiomics analyses; here, 72% of panelists have experienced problems during data processing due to diverging protocols across CT scanners.

Here, 100% of expert panelists reported that imaging harmonisation could be useful for multicentre imaging studies and Europe-wide standardised protocols could facilitate radiomics and AI research. Hence, 24/25 (96%)

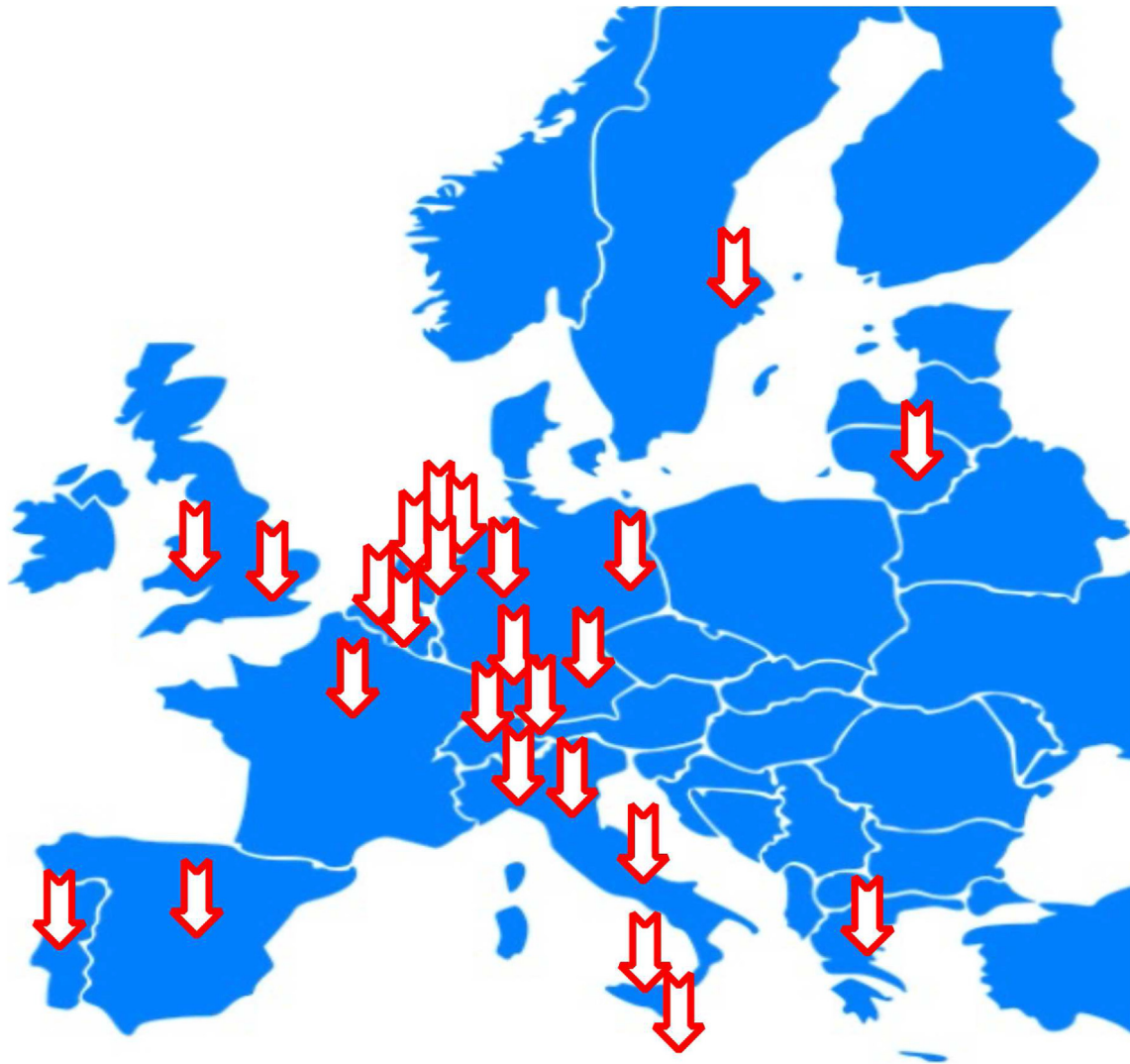

Fig. 1. **Schematic country representation in the panel.** Each arrow indicates the location of the participating panelists' affiliations on this schematic.

expert panelists are willing or probably willing to incorporate a potential standardised imaging protocol.

3.3. CT scan acquisition

The vast majority of 84% do not give oral contrast for mCRC CT staging purposes, even 88% of expert panelists do not consider oral contrast as essential part of mCRC staging; 92% of included centres give intravenous contrast for CT imaging; here, <5% of scans must be performed without contrast agent due to contraindications (96% of cases), in one centre, 10–15% of cases were performed without contrast agent. In an open question regarding contrast agent dosage, most frequent contrast dosages applied were 1.5 mg/kg for most, 1.0 mg/kg for some cases (24%), 1.5 mg/kg for all cases (16%) and 1.0 mg/kg for most, 1.5 mg/kg for some cases (12%); all values indicate per patient body weight. In an open question regarding contrast agent concentration,

most frequent contrast concentrations applied were 300 mg/mL contrast agent (32%) and 350 mg/mL contrast agent (32%).

mCRC staging does not regularly include neck studies in 96% of centres. If neck studies were included, mostly venous phase (56%) or late arterial phase (36%) was obtained. Thoracic studies were most commonly performed in the venous phase (56%), and the second most common acquisition was in the late arterial phase (36%). Most centres use the venous phase for abdominal CT imaging (88%), whereas late arterial phases were not common (20%) (multiple answers possible in case of multiphase approach). Image acquisition is performed in a monophasic approach in 56% of the included centres.

3.3.1. CT scan acquisition consensus round

In total, 92% of the expert panelists agreed that oral contrast application is not an essential part of a

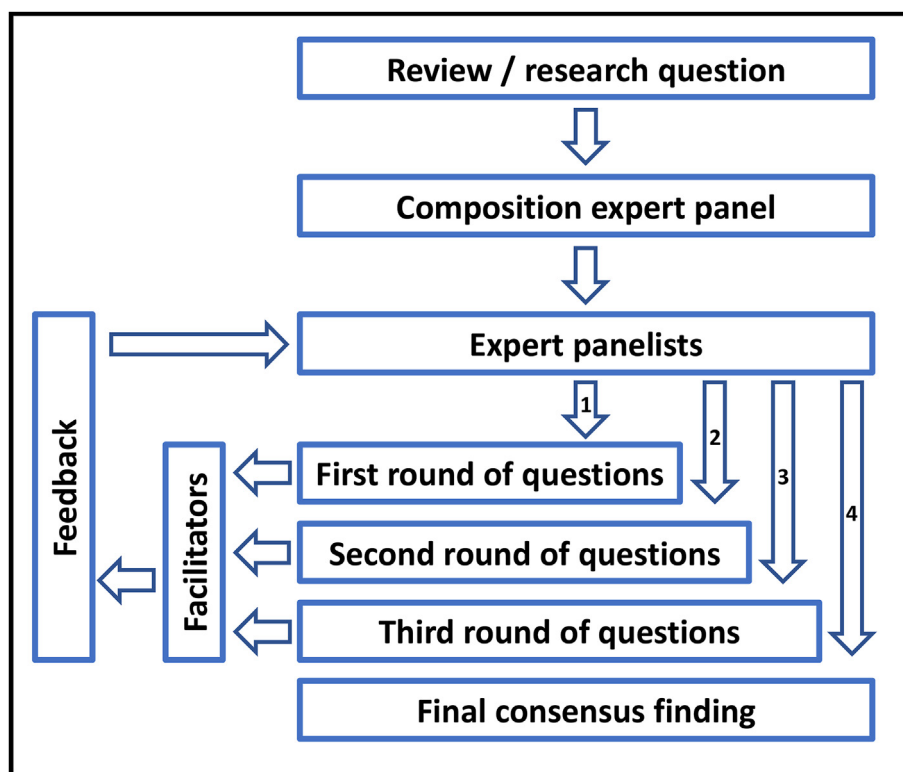


Fig. 2. Schematic of the applied Delphi approach. This figure illustrates the different steps and feedback mechanisms of the applied Delphi approach.

standard mCRC CT imaging protocol. The application of intravenous contrast agent was deemed mandatory by all experts (100%). A majority (76%) agreed that a dosage of 1.0–2.0 mg/kg bodyweight of contrast agent should be applied on CT imaging (followed by <1.0 mg/kg bodyweight (16%). A majority (88%) argued in favour of an iodine concentration of 200–400 mg/mL contrast agent followed by <200 mg/mL contrast agent (12%) regarding CT imaging. Thoracic and abdominal series should be acquired in a monophasic approach (72% agreement).

Neck studies are not a mandatory part of mCRC CT imaging (92%), but thoracic studies are a mandatory part of mCRC imaging (96% agreement) and should be performed using a venous phase (64% agreement). Abdominal studies are mandatory (100% agreement) and should be performed using a venous phase (100% agreement).

3.4. CT scan reconstruction

Regarding CT reconstruction, 76% of included centres do apply dedicated soft tissue reconstructions and 80% use dedicated lung reconstruction algorithms, whereas a dedicated bone reconstruction algorithm is only used in 40% of the centres. The most applied slice thickness is 3 mm for soft tissue reconstructions (36%) followed by 1 mm (20%). Using dedicated lung reconstructions, 48%

used 1 mm slice thickness, followed by 2 mm slice thickness (24%), whereas the most applied slice thickness for bone reconstructions, when applied, was 2 mm (24%) and 1 mm (20%).

3.4.1. CT scan reconstruction consensus round

All panelists agreed that a dedicated soft tissue reconstruction should be applied (100%); also, a majority of 84% argued in favour of applying a dedicated lung reconstruction algorithm and 60% in favour of a bone reconstruction algorithm. A majority of 52% voted in favour of 3 mm slice thickness for soft tissue reconstructions, 64% argued for 1 mm slice thickness for lung reconstructions and 56% for 2 mm slice thickness regarding bone reconstructions on CT imaging, if applied. Thoracic studies should include axial soft tissue reconstructions (84% agreement) and axial lung reconstructions (84% agreement), but no axial bone reconstruction (64% agreement). Abdominal imaging should include an axial soft tissue reconstruction (96% agreement). A bone reconstruction was not considered mandatory by the majority of panelists (60% agreement).

3.5. ¹⁸F-FDG PET/CT scan acquisition

The vast majority of panelists (96%) does not apply oral contrast for mCRC CT staging purposes, and 96% of

Table 2
Panelist responses from the final consensus survey round.

Statement	Answer option of reference	Agreement	Consensus reached
CT imaging			
In a mCRC consensus protocol, the application of oral contrast in CT scans should NOT be included as mandatory for mCRC staging?	Agree	92%	Yes
In a mCRC consensus protocol, the application of intravenous contrast in CT scans should be included as mandatory for mCRC?	Agree	100%	Yes
Which dosage of intravenous contrast (mg per kg bodyweight) should be implemented in a mCRC protocol for CT scans (in case intravenous contrast is applied)? ^a	1.0–2.0 mg/kg body weight	76%	Yes
Which iodine concentration (mg per mL intravenous contrast agent) should be included in a mCRC imaging protocol for CT imaging? ^a	200–400 mg/mL contrast	88%	Yes
Within a core imaging protocol, a dedicated soft tissue kernel should be used for reconstruction?	Agree	100%	Yes
Within a core imaging protocol, a dedicated lung tissue kernel should be used for reconstruction?	Agree	88%	Yes
Within a core imaging protocol, a dedicated bone tissue kernel should be used for reconstruction?	Yes	60%	No
The following slice thickness should be applied for soft tissue reconstructions on CT imaging in mCRC? ^a	3 mm	52%	Yes
The following slice thickness should be applied for lung tissue reconstructions on CT imaging in mCRC? ^a	1 mm	64%	Yes
The following slice thickness should be applied for bone tissue reconstructions on CT imaging in mCRC? ^a	2 mm	60%	Yes
Dual energy or spectral CT imaging in mCRC is NOT a mandatory part of a core mCRC imaging protocol?	Agree	92%	Yes
Thoracic and abdominal series should be acquired in a monophasic approach?	Agree	72%	Yes
Neck studies in mCRC CT staging should NOT be included in a core protocol as regular imaging studies?	Agree	92%	Yes
Thorax studies in mCRC CT staging should be included in a core protocol as regular imaging studies?	Agree	96%	Yes
Thorax studies in mCRC CT staging should include a venous phase as minimum requirement for a core protocol?	Agree	64%	No
Thorax studies in mCRC CT staging should include an axial soft-tissue reconstruction as minimum requirement for a core protocol?	Agree	84%	Yes
Thorax studies in mCRC CT staging should include an axial lung reconstruction as minimum requirement for a core protocol?	Agree	84%	Yes
Thorax studies in mCRC CT staging should include an axial bone reconstruction as minimum requirement for a core protocol?	Agree	36%	No
Abdominal studies in mCRC CT staging should be included in a core protocol as regular imaging studies?	Agree	100%	Yes
Abdominal studies in mCRC CT staging should include a venous phase as minimum requirement for a core protocol?	Agree	100%	Yes
Abdominal studies in mCRC CT staging should include an axial soft-tissue reconstruction as minimum requirement for a core protocol?	Agree	96%	Yes
Abdominal studies in mCRC CT staging should include an axial bone reconstruction as minimum requirement for a core protocol?	Agree	40%	No
PET/CT imaging			
In a mCRC consensus protocol, the application of oral contrast in PET/CT scans should NOT be included as mandatory?	Agree	100%	Yes
In a mCRC consensus protocol, the application of intravenous contrast in PET/CT scans should be included as mandatory for mCRC?	Agree	48%	No
Which dosage of intravenous contrast (mg per kg bodyweight) should be implemented in a mCRC protocol for CT scans (in case intravenous contrast is applied)? ^a	1.0–2.0 mg/kg body weight	80%	Yes
Which iodine concentration (mg per mL intravenous contrast agent) should be included in a mCRC imaging protocol for PET/CT imaging? ^a	200–400 mg/mL contrast	88%	Yes
The following slice thickness should be applied for soft tissue reconstructions on PET/CT imaging in mCRC? ^a	3 mm	52%	Yes
The following slice thickness should be applied for lung tissue reconstructions on PET/CT imaging in mCRC? ^a	1 mm	56%	Yes

(continued on next page)

Table 2 (continued)

Statement	Answer option of reference	Agreement	Consensus reached
The following slice thickness should be applied for bone tissue reconstructions on PET/CT imaging in mCRC? ^a	2 mm	60%	Yes
Neck studies in mCRC PET/CT staging should NOT be included in a core protocol as regular imaging studies?	Agree	56%	No
Thorax studies in mCRC PET/CT staging should be included in a core protocol as regular imaging studies?	Agree	96%	Yes
If contrast is applied, thorax studies in mCRC PET/CT staging should include a venous phase as minimum requirement for a core protocol?	Agree	84%	Yes
Thorax studies in mCRC PET/CT staging should include an axial soft-tissue reconstruction as minimum requirement for a core protocol?	Agree	84%	Yes
Thorax studies in mCRC PET/CT staging should include an axial lung reconstruction as minimum requirement for a core protocol?	Agree	84%	Yes
Thorax studies in mCRC PET/CT staging should include an axial bone reconstruction as minimum requirement for a core protocol?	Agree	32%	No
Abdominal studies in mCRC PET/CT staging should be included in a core protocol as regular imaging studies?	Agree	100%	Yes
Abdominal studies in mCRC PET/CT staging should include a venous phase as minimum requirement for a core protocol?	Agree	96%	Yes
Abdominal studies in mCRC PET/CT staging should include an axial soft-tissue reconstruction as minimum requirement for a core protocol?	Agree	92%	Yes
Abdominal studies in mCRC PET/CT staging should include an axial bone reconstruction as minimum requirement for a core protocol?	Agree	32%	No

^a Multiple-choice statement. The statements indicate questions that have evolved towards the final consensus survey round based on the panelists' feedback. The questions have hence already been adapted to incorporate the general view of the panel.

expert panelists do not consider oral contrast as an essential part of mCRC PET/CT imaging; 52% of included centres do apply intravenous contrast for PET/CT imaging; in only 44% of centres, contrast agent is omitted in <5% of cases. In open question regarding contrast agent dosage, most frequent contrast dosages (including 'not available') were 1.5 mg/kg for most, 1.0 mg/kg for some cases (12%), 1.5 mg/kg for all cases (8%), 1.0 mg/kg for all cases (8%) and 1.0 mg/kg for most, 1.5 mg/kg for some cases (8%). In an open question regarding contrast agent concentration (including 'not available'), most frequent contrast concentrations applied were 350 mg/mL contrast agent (28%) and 300 mg/mL contrast agent (16%).

Contrast agent for PET/CT imaging is mostly provided by Bayer in 28% of centres, by GE Healthcare in 20% of centres and by Bracco Imaging in 16% of included centres. Regarding different phases, most centres (96%) do not apply multiphase imaging on PET/CT for mCRC imaging. Image acquisition on PET/CT is performed in a monophasic approach in 68% of cases.

3.5.1. PET/CT scan acquisition consensus round

Here, 100% of the expert panelists agreed that oral contrast application is not essential for standard mCRC CT imaging protocols. No consensus could be reached regarding the application of contrast agents for PET/CT imaging; 52% of the panelists deemed the application of contrast agents not mandatory for PET/CT imaging. A majority of 80% agreed that a dosage of 1.0–2.0 mg/kg bodyweight of contrast agent should be applied on

PET/CT imaging (followed by <1.0 mg/kg bodyweight (16%)), in case contrast agent is applied. A majority of 88% argued in favour for an iodine concentration of 200–400 mg/mL contrast agent followed by <200 mg/mL contrast agent (12%) regarding PET/CT imaging. Thoracic and abdominal series should be acquired in a monophasic approach (72% agreement). Neck acquisitions are not a mandatory part of mCRC imaging (92% agreement), but thoracic series are a mandatory part of mCRC imaging (96% agreement) and should be performed using a venous phase (72% agreement), if contrast is applied. Abdominal series are mandatory (100% agreement) and should be performed using a venous phase (96% agreement) if contrast is applied.

3.6. PET/CT scan reconstruction

Regarding reconstruction of the CT component on PET/CT imaging, 60% of included centres do apply dedicated soft tissue reconstructions and 52% use dedicated lung reconstruction algorithms, whereas a dedicated bone reconstruction algorithm is only used in 20% of the included centres. The most applied slice thickness is 2 mm and 5 mm for soft tissue reconstructions (20% each) followed by 3 mm (16%). Using dedicated lung reconstructions, 24% used 1 mm and 2 mm slice thickness, respectively, followed by 5 mm slice thickness (16%), whereas the mostly applied slice thickness for bone reconstructions on PET/CT imaging, in case it was applied, was 1 mm and 2 mm (16% each), respectively.


Core Protocol Parameters	Requirement	Conformity
Patient Preparation		
Intravenous Contrast in CT Exams	Required	[]
Intravenous Contrast in PET-CT Exams	Optional*	[]
Intravenous Iodine Concentration	200-400 mg / mL	[]
Intravenous Contrast Dosage	1.0-2.0 mg / kg [§]	[]
Oral Contrast in CT / PET-CT Exams	Not Required [#]	[]
Scan Acquisition		
Monophasic Acquisition	Required	[]
Contrast Phase Acquisition Chest	Venous	[]
Contrast Phase Acquisition Abdomen	Venous	[]
Scan Reconstruction		
Soft Tissue Kernel - Orientation	Axial	[]
Soft Tissue Kernel - Slice Thickness	3 mm	[]
Lung Kernel - Orientation	Axial	[]
Lung Kernel - Slice Thickness	1 mm	[]
Protocol Extension		
Additional Reconstructions	As Per Institution	N/A
Additional Contrast Phase Acquisition	As Per Institution	N/A
<i>This core imaging protocol is endorsed by:</i>		
		

Fig. 3. **Imaging scorecard for implementation of the consensus core protocol.** This figure illustrates the core components of this panel's consensus recommendation on imaging in patients with mCRC. The imaging scorecard was developed to facilitate implementation of the standardised protocol in cancer and imaging centres that participate in accrual for RCTs. *If PET/CT is the only exam at a certain timepoint, intravenous contrast as would be needed to ensure compatibility with the RECIST1.1 requirements [1]; this does not apply if the PET/CT is performed in close temporal proximity of a dedicated CT. [§]Value refers to per patient body weight. [#]Oral contrast may be considered if lesion conspicuity in diffuse peritoneal disease is expected to impact response assessment.

3.6.1. PET/CT scan reconstruction consensus round

Regarding dedicated CT reconstruction algorithms please see CT section above. A majority of 52% voted in favour of 3 mm slice thickness for soft tissue reconstructions, 56% argued for 1 mm slice thickness for lung reconstructions and 60% for 2 mm slice thickness regarding bone reconstructions on PET/CT imaging.

Thoracic PET/CT series should include axial soft tissue reconstructions (80% agreement) and axial lung reconstructions (84% agreement), but no bone reconstructions (68% agreement). Abdominal PET/CT imaging should include an axial soft tissue reconstruction (92% agreement), but no bone reconstruction (68% agreement).

3.7. Dual energy or spectral CT imaging

Dual energy or spectral CT imaging is part of the clinical routine for mCRC imaging in only 32% of the included centres. Also, no expert panelists experienced sponsor requirements towards inclusion of dual energy or spectral CT imaging in RCT imaging protocols.

3.7.1. Dual energy or spectral CT imaging consensus round

This is not a mandatory part of a potential core protocol (92% agreement).

3.8. Core imaging protocol

3.8.1. CT mCRC core imaging protocol

Patient preparation and acquisition: No oral contrast. Intravenous contrast dosage: 1.0–2.0 mg/kg bodyweight. Iodine concentration: 200–400 mg/mL. Monophasic acquisition.

Thorax: Venous phase. Axial soft tissue reconstruction with 3 mm slice thickness. Axial lung reconstruction with 1 mm slice thickness. No bone reconstruction mandatory.

Abdomen: Venous phase. Axial soft tissue reconstruction with 3 mm slice thickness. No bone reconstruction mandatory.

Further phases, reconstructions, etc. can be added with emphasis on local specifications and clinical necessities.

3.8.2. PET/CT mCRC core imaging protocol

Acquisition: No oral contrast. If intravenous contrast is applied, contrast dosage: 1.0–2.0 mg/kg bodyweight. Iodine concentration: 200–400 mg/mL. Monophasic acquisition.

Thorax: Unenhanced or venous phase if contrast is applied. Axial soft tissue reconstruction with 3 mm slice thickness. Lung reconstruction with 1 mm slice thickness. No bone reconstruction mandatory.

Abdomen: Unenhanced or venous phase if contrast is applied. Axial soft tissue reconstruction with 3 mm slice thickness. No bone reconstruction mandatory.

Further phases, reconstructions etc. can be added with emphasis on local specifications and clinical necessities.

3.9. Imaging scorecard

The main components of the consensus core protocol are summarised and illustrated in the Imaging Scorecard as provided in Fig. 3. All questions and responses during the survey process are presented in Supplementary Files 1–3.

4. Discussion

In this European collaboration across multiple societies, we conducted a successful consensus finding survey on mCRC imaging applying the Delphi process. The survey included imaging specialists with a focus on mCRC from cancer centres across Europe as panelists. The first

rounds during the survey illustrated the existing heterogeneity of CT imaging protocols. During the Delphi process, the imaging panelists agreed on standardisations for the imaging of patients with mCRC. This standardisation covers patient preparation, scan acquisition and scan reconstruction; all of which are known factors that limit data reproducibility. Examples of imaging protocol heterogeneity in an mCRC trial are illustrated in Fig. 4.

This consortium supports the use of a standardised core imaging protocol that will build the backbone for the imaging data in mCRC trials. This concept was introduced to facilitate the implementation of new imaging standards as institutional and individual preferences could affect their acceptance. This approach will give institutions the choice to fully switch to this proposed protocol or to keep existing protocols by adding the required image reconstructions. Notably, all imaging panelists indicated that their institutions are either committed or likely willing to implement this core imaging protocol. Notably, spectral imaging was not deemed mandatory among the participating experts.

The heterogeneity of imaging protocols remains a significant challenge for reproducibility of conventional as well as novel imaging end-points [4]. As examples for the size-based RECIST1.1 criteria, CT acquisition and reconstruction parameters affect reproducibility of lymph node [13] and liver lesion size assessments [14]. Efforts by the International Biomarker Standardisation Initiative have standardised the image post-processing and analysis [15] yet not addressed heterogeneity arising from imaging protocols. Regarding novel imaging end-points, however, differences in CT acquisition and reconstruction parameters have been repeatedly shown to affect radiomics feature reproducibility [9,16].

With this core imaging protocol, which reached consensus by the participating oncology and imaging societies, we expect to reduce protocol heterogeneity and pave the way for future research on modern imaging end-points. The use of radiomics data has significant potential in treatment monitoring of mCRC [17]. Basic radiomics features of liver metastases predict a poor outcome at 2 months with the same performance as RECIST1.1 evaluation at 6 months in first-line mCRC treatment [5]. In another application, a radiomics signature outperformed existing biomarkers (KRAS-mutational status, tumour shrinkage) in predicting survival as well as in the detection of treatment sensitivity to cetuximab [6].

The application of AI has significant potential for even further improvement in early response assessment. Deep learning methods enabled prediction of early on-treatment response using conventional CT imaging in patients with mCRC [7]. The quantitative characterisation of tumour morphological changes from pretreatment to follow-up CT scans significantly strengthened the association with patient survival and may be used

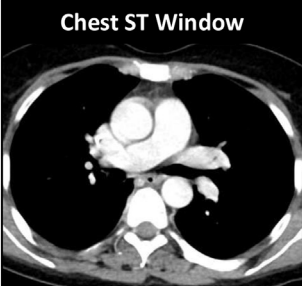

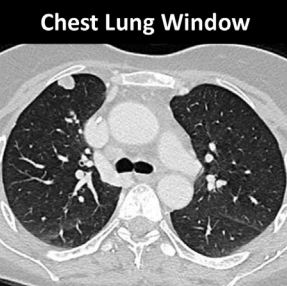



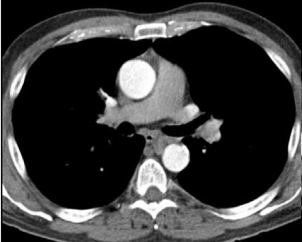

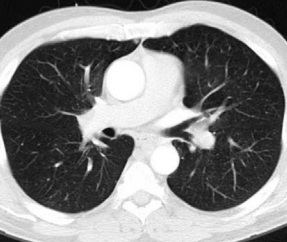






Chest ST Window	Abdomen ST Window	Chest Lung Window	Protocol Parameters	Conformity
			Acquisition	Monophasic
			ST Slice Thickness	3 mm
			Lung Slice Thickness	1 mm
			Lung Kernel Available	Yes
			Oral Contrast	No
			Acquisition	Monophasic
			ST Slice Thickness	5 & 6 mm
			Lung Slice Thickness	3 mm
			Lung Kernel Available	Yes
			Oral Contrast	Yes
			Acquisition	Biphasic
			ST Slice Thickness	5 & 6 mm
			Lung Slice Thickness	5 mm
			Lung Kernel Available	Yes
			Oral Contrast	Yes
			Acquisition	Biphasic
			ST Slice Thickness	5 & 6 mm
			Lung Slice Thickness	5 mm
			Lung Kernel Available	No
			Oral Contrast	Yes
			Acquisition	Triphasic
			ST Slice Thickness	3.75 & 5 mm
			Lung Slice Thickness	3.75 mm
			Lung Kernel Available	No
			Oral Contrast	No

Fig. 4. Examples of imaging protocol heterogeneity in a randomised controlled trial. Illustration of imaging protocol heterogeneity in patients with mCRC included in the FIRE-3 RCT [32]. ST refers to soft tissue, i.e., the windowing settings to evaluate mediastinal and visceral organs. The first and second column portray the available ST kernel reconstructions and the third column shows lung kernel reconstructions if available. The last column indicates conformity with the core imaging protocol according to this panel's consensus recommendation (green: compliant; red: non-compliant). (For interpretation of the references to colour in this figure legend, the reader is referred to the Web version of this article).

for early on-treatment decision-making. Notably, all these radiomics and AI studies excluded trial patients based on imaging protocol deviations (which were avoidable, i.e., not due to medical contraindications).

For patients with mCRC, robust assessment of such novel imaging end-points will open avenues towards new trial designs. In the field of mCRC, there are no imaging response-adapted trial designs. The pioneering effort of response-adapted treatment guidance has been

made in the management of Hodgkin's lymphoma, using positron-emission tomography for decisions on additive radiation [18] or treatment de-escalation [19]. In solid malignancies, response-adapted treatment de-escalation of immunotherapy has been successfully tested in a phase II trial in metastatic melanoma [20]. Similar trial designs could pave the way for personalised treatment of mCRC patients based on reliable and robust imaging end-points.

International efforts for standardisation of imaging procedures in oncology have significantly increased over the past few years, and consensus recommendations were either achieved with or without the use of dedicated methods (e.g. the Delphi process). Imaging recommendations are often part of guidelines that cover acquisition, interpretation and reporting. Protocol recommendations with high adherence in clinical trials exist for prostate cancer screening [21], metastatic prostate cancer [22], breast cancer [23], endometrial cancer [24], multiple myeloma [25] and lung cancer [26].

Interpretation and reporting of mCRC imaging studies are covered by the RECIST1.1 criteria [1]. Yet there are no consensus recommendations available to standardise imaging protocols for patients with mCRC. Dedicated recommendations for imaging protocol standardisation have been previously published for primary brain tumours [27] and for brain metastases [28], which have been instrumental for successful AI applications [29]. Our protocol recommendations could thereby serve as a catalyst to accelerate such research efforts in mCRC.

Strengths of our study are the participation of leading oncology and imaging societies and adherence to the Delphi process. We thereby ensure that our recommendations represent the collective position of all key opinion leaders without individual overrepresentation. Our and other protocol recommendations cannot elude lack of inter-vendor standardisation, yet this limitation represents a subordinate impact on radiomics feature assessment [15]. The time delays between contrast administration and different phase acquisitions could not be standardised as panelist responses were mostly given in ranges or as rough estimates. We did not include magnetic resonance imaging due to the technical complexity and very strong dependence on vendor-specific sequences. Among the panelists, there may be differences in technical proficiency regarding CT and/or PET/CT imaging based on training. Overall, a Delphi process was considered a suitable approach for consensus finding in a set of European experts, as this approach enables an inclusion of a wide range of expertise among panelists. These can express their own opinion on questions more individually compared to the dynamic of a group discussion; however, certain limitations have to be listed, e.g. such as a potentially dominant influence of the facilitators or a high consumption of time and resources. Moreover, the process depends on expertise and motivation of the panelists [11,12,30,31].

In conclusion, this group of imaging experts reached consensus through a Delphi survey on a standardised CT imaging protocol with easy-to-implement core components for patients with mCRC. We anticipate that this standardisation will increase reproducibility of radiomics and AI studies and serve as a catalyst for

future research on imaging end-points. For ongoing and future mCRC trials, we encourage principal investigators to support the dissemination of these imaging standards across recruiting centres.

Author contribution

M.U., C.M.D., J.R. and W.G.K. contributed to the conception, design and planning of the study. M.U., C.M.D., M.M., A.L., R.B.-T., F.L., E.C.S., J.R. and W.G.K. contributed to conduct of the data. C.M.D., K.H., L.B., R.C., D.C., M.D.C., T.D., C.D.L.P., L.-F.D.G.-O., A.D., M.E., K.G.F., S.G., F.L., E.L., M.M., M.O., D.E.O.-L., J.J.C.V., I.S., S.T., M.D., D.R. and J.R. participated in the acquisition of the survey data. M.U., C.M.D., M.M., L.-F.D.G.-O., F.L., D.E.O.-L., A.L., R.B.-T., V.H., F.L., E.C.S., J.R. and W.G.K. contributed to the interpretation of the results. M.U. and W.G.K. drafted the manuscript. All authors critically reviewed or revised the manuscript for important intellectual content and approved the final version to be submitted. This final manuscript received endorsement by the EORTC.

Funding

The authors received no specific funding for this work.

Conflict of interest statement

The authors declare the following financial interests/personal relationships which may be considered as potential competing interests: K.H. reports personal fees from Bayer, personal fees and other from Sofie Biosciences, personal fees from SIRTEX, non-financial support from ABX, personal fees from Adacap, personal fees from Curium, personal fees from Endocyte, grants and personal fees from BTG, personal fees from IPSEN, personal fees from Siemens Healthineers, personal fees from GE Healthcare, personal fees from Amgen, personal fees from Novartis, personal fees from Y-mAbs, all outside the submitted work. L.B. is a cofounder of Collective Minds Radiology. R.C. reports travel support by Bracco Imaging. T.D. reports honorary fees and travel support by Siemens, Canon, Bayer, b.e. imaging and research grants by Siemens Healthineers, Bayer, Guerbet and b.e. imaging. E.L. reports receiving research grants from AIRC and from the Italian Ministry of Health, and faculty remuneration from ESMIT (European School of Multimodality Imaging and Therapy) and MI&T Congress. D.E.O.-L. received expert remuneration from EAU for participating in PET PSMA Consensus Meeting in January 2022. The remaining authors declare that they have no

conflict of interest related to this study. W.G.K. reports personal fees from Bristol-Myers Squibb.

Appendix A. Supplementary data

Supplementary data to this article can be found online at <https://doi.org/10.1016/j.ejca.2022.09.012>.

References

- [1] Eisenhauer EA, Therasse P, Bogaerts J, Schwartz LH, Sargent D, Ford R, et al. New response evaluation criteria in solid tumours: revised RECIST guideline (version 1.1). *Eur J Cancer* 2009;45:228–47.
- [2] Van Cutsem E, Cervantes A, Adam R, Sobrero A, Van Krieken JH, Aderka D, et al. ESMO consensus guidelines for the management of patients with metastatic colorectal cancer. *Ann Oncol* 2016;27:1386–422.
- [3] Chun YS, Vauthey JN, Boonsirikamchai P, Maru DM, Kopetz S, Palavecino M, et al. Association of computed tomography morphologic criteria with pathologic response and survival in patients treated with bevacizumab for colorectal liver metastases. *JAMA* 2009;302:2338–44.
- [4] Bera K, Braman N, Gupta A, Velcheti V, Madabhushi A. Predicting cancer outcomes with radiomics and artificial intelligence in radiology. *Nat Rev Clin Oncol* 2022;19:132–46.
- [5] Dohan A, Gallix B, Guiu B, Le Malicot K, Reinhold C, Soyer P, et al. Early evaluation using a radiomic signature of unresectable hepatic metastases to predict outcome in patients with colorectal cancer treated with FOLFIRI and bevacizumab. *Gut* 2020 Mar;69(3):531–9. <https://doi.org/10.1136/gutjnl-2018-316407>. Epub 2019 May 17.
- [6] Derclé L, Lu L, Schwartz LH, Qian M, Tejpar S, Eggleton P, et al. Radiomics response signature for identification of metastatic colorectal cancer sensitive to therapies targeting EGFR pathway. *J Natl Cancer Inst* 2020.
- [7] Lu L, Derclé L, Zhao B, Schwartz LH. Deep learning for the prediction of early on-treatment response in metastatic colorectal cancer from serial medical imaging. *Nat Commun* 2021;12:6654.
- [8] Giannini V, Pusceddu L, Defeudis A, Nicoletti G, Cappello G, Mazzetti S, et al. Delta-radiomics predicts response to first-line oxaliplatin-based chemotherapy in colorectal cancer patients with liver metastases. *Cancers (Basel)* 2022;14.
- [9] Meyer M, Ronald J, Vernuccio F, Nelson RC, Ramirez-Giraldo JC, Solomon J, et al. Reproducibility of CT radiomic features within the same patient: influence of radiation dose and CT reconstruction settings. *Radiology* 2019;190928.
- [10] Bijlstra OD, Boreel MME, van Mossel S, Burgmans MC, Kapiteijn EHW, Oprea-Lager DE, et al. The value of (18)F-FDG-PET-CT imaging in treatment evaluation of colorectal liver metastases: a systematic review. *Diagnostics (Basel)* 2022;12.
- [11] Linstone HA, Turoff M. The Delphi method: techniques and applications. Addison-Wesley; 1975.
- [12] Jones J, Hunter D. Consensus methods for medical and health services research. *BMJ* 1995;311:376–80.
- [13] Onuma Y, Tsuruta C, Okita K, Hamabe A, Ogura K, Takemasa I, et al. CT reconstruction with thick slices not only underestimates lymph node size but also reduces data reproducibility in colorectal cancer. *Acta Radiol* 2021;62:1275–82.
- [14] Li Q, Liang Y, Huang Q, Zong M, Berman B, Gavrielides MA, et al. Volumetry of low-contrast liver lesions with CT: investigation of estimation uncertainties in a phantom study. *Med Phys* 2016;43:6608.
- [15] Zwanenburg A, Vallieres M, Abdalah MA, Aerts H, Andrearczyk V, Apte A, et al. The image biomarker standardization initiative: standardized quantitative radiomics for high-throughput image-based phenotyping. *Radiology* 2020;295:328–38.
- [16] Berenguer R, Pastor-Juan MDR, Canales-Vazquez J, Castro-Garcia M, Villas MV, Mansilla Legorburo F, et al. Radiomics of CT features may be nonreproducible and redundant: influence of CT acquisition parameters. *Radiology* 2018;288:407–15.
- [17] Staal FCR, van der Reijdt DJ, Taghavi M, Lambregts DMJ, Beets-Tan RGH, Maas M. Radiomics for the prediction of treatment outcome and survival in patients with colorectal cancer: a systematic review. *Clin Colorectal Cancer* 2021 Mar;20(1):52–71. <https://doi.org/10.1016/j.clcc.2020.11.001>. Epub 2020 Nov 7.
- [18] Engert A, Haverkamp H, Kobe C, Markova J, Renner C, Ho A, et al. Reduced-intensity chemotherapy and PET-guided radiotherapy in patients with advanced stage Hodgkin's lymphoma (HD15 trial): a randomised, open-label, phase 3 non-inferiority trial. *Lancet* 2012;379:1791–9.
- [19] Johnson P, Federico M, Kirkwood A, Fossa A, Berkahn L, Carella A, et al. Adapted treatment guided by interim PET-CT scan in advanced Hodgkin's lymphoma. *N Engl J Med* 2016;374:2419–29.
- [20] Postow MA. Adaptive dosing of nivolumab 1 ipilimumab immunotherapy based upon early, interim radiographic assessment in advanced melanoma (the ADAPT-IT study). *J Clin Oncol* 2022 Apr 1;40(10):1059–67. <https://doi.org/10.1200/JCO.21.01570>. Epub 2021 Dec 20.
- [21] Turkbey B, Rosenkrantz AB, Haider MA, Padhani AR, Villeirs G, Macura KJ, et al. Prostate Imaging Reporting and Data System version 2.1: 2019 update of Prostate Imaging Reporting and Data System version 2. *Eur Urol* 2019;76:340–51.
- [22] Padhani AR, Lecouvet FE, Tunariu N, Koh DM, De Keyzer F, Collins DJ, et al. METastasis reporting and data system for prostate cancer: practical guidelines for acquisition, interpretation, and reporting of whole-body magnetic resonance imaging-based evaluations of multiorgan involvement in advanced prostate cancer. *Eur Urol* 2017;71:81–92.
- [23] Baltzer P, Mann RM, Iima M, Sigmund EE, Clauser P, Gilbert FJ, et al. Diffusion-weighted imaging of the breast—a consensus and mission statement from the EUSOBI International Breast Diffusion-Weighted Imaging working group. *Eur Radiol* 2020;30:1436–50.
- [24] Nougaret S, Horta M, Sala E, Lakhman Y, Thomassin-Naggara I, Kido A, et al. Endometrial cancer MRI staging: updated guidelines of the European Society of Urogenital Radiology. *Eur Radiol* 2019;29:792–805.
- [25] Messiou C, Hillengass J, Delorme S, Lecouvet FE, Mouloupoulos LA, Collins DJ, et al. Guidelines for acquisition, interpretation, and reporting of whole-body MRI in myeloma: Myeloma Response Assessment and Diagnosis System (MY-RADS). *Radiology* 2019;291:5–13.
- [26] Chen DL, Ballout S, Chen L, Cheriyan J, Choudhury G, Denis-Bacelar AM, et al. Consensus recommendations on the use of (18)F-FDG PET/CT in lung disease. *J Nucl Med* 2020 Dec;61(12):1701–7. <https://doi.org/10.2967/jnumed.120.244780>. Epub 2020 Sep 18.
- [27] Ellingson BM, Bendszus M, Boxerman J, Barboriak D, Erickson BJ, Smits M, et al. Consensus recommendations for a standardized Brain Tumor Imaging Protocol in clinical trials. *Neuro Oncol* 2015;17:1188–98.
- [28] Kaufmann TJ, Smits M, Boxerman J, Huang R, Barboriak DP, Weller M, et al. Consensus recommendations for a standardized brain tumor imaging protocol for clinical trials in brain metastases. *Neuro Oncol* 2020;22:757–72.
- [29] Kickingereder P, Isensee F, Tursunova I, Petersen J, Neuberger U, Bonekamp D, et al. Automated quantitative tumour response assessment of MRI in neuro-oncology with artificial neural networks: a multicentre, retrospective study. *Lancet Oncol* 2019;20:728–40.

- [30] Vernon W. The Delphi technique: a review. *Int J Ther Rehabil* 2009;16:69–76.
- [31] Thangaratinam S, Redman CW. The Delphi technique. *Obstet Gynaecol* 2005;7:120–5.
- [32] Heinemann V, von Weikersthal LF, Decker T, Kiani A, Vehling-Kaiser U, Al-Batran SE, et al. FOLFIRI plus cetuximab versus FOLFIRI plus bevacizumab as first-line treatment for patients with metastatic colorectal cancer (FIRE-3): a randomised, open-label, phase 3 trial. *Lancet Oncol* 2014;15:1065–75.