



Universiteit
Leiden
The Netherlands

Preservation of the pectoral fascia in mastectomy with immediate reconstruction: a nationwide survey

Blok, Y.L.; Suijker, J.; Tol, M.P. van den; Pol, C.C. van der; Mureau, M.A.M.; Hage, J.A. van der; Krekel, N.M.A.

Citation

Blok, Y. L., Suijker, J., Tol, M. P. van den, Pol, C. C. van der, Mureau, M. A. M., Hage, J. A. van der, & Krekel, N. M. A. (2022). Preservation of the pectoral fascia in mastectomy with immediate reconstruction: a nationwide survey. *Journal Of Surgical Research*, 284, 101-105.
doi:10.1016/j.jss.2022.10.031

Version: Publisher's Version
License: [Creative Commons CC BY 4.0 license](https://creativecommons.org/licenses/by/4.0/)
Downloaded from: <https://hdl.handle.net/1887/3567053>

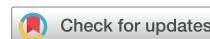Note: To cite this publication please use the final published version (if applicable).

Available online at www.sciencedirect.com

ScienceDirect

journal homepage: www.JournalofSurgicalResearch.com

Preservation of the Pectoral Fascia in Mastectomy With Immediate Reconstruction: A Nationwide Survey



Yara Lynn Blok, MD,^{a,*} Jaco Suijker, MD,^b
 Monique P. van den Tol, MD, PhD,^c Carmen C. van der Pol, MD,^d
 Marc A.M. Mureau, MD, PhD,^e Jos A. van der Hage, MD, PhD,^f
 and Nicole M.A. Krekel, MD, PhD^g

^aDepartment of Plastic and Reconstructive surgery, Leiden University Medical Center, Leiden, the Netherlands

^bDepartment of surgery, Red Cross Hospital, Beverwijk, the Netherlands

^cDepartment of Surgical Oncology, Medical Center Leeuwarden, Leeuwarden, the Netherlands

^dDepartment of Surgical Oncology, Alrijne Ziekenhuis, Leiderdorp, the Netherlands

^eDepartment of Plastic and Reconstructive surgery, Erasmus MC Cancer Institute, University Medical Center Rotterdam, Rotterdam, the Netherlands

^fDepartment of Surgical Oncology, Leiden University Medical Center, Leiden, the Netherlands

^gDepartment of Plastic and Reconstructive surgery, Alrijne Ziekenhuis, Leiderdorp, the Netherlands

ARTICLE INFO

Article history:

Received 21 July 2022

Received in revised form

12 September 2022

Accepted 16 October 2022

Available online 21 December 2022

Keywords:

Breast reconstruction

Complications

Cosmetic outcomes

Fascia pectoralis

Mastectomy

Oncological safety

ABSTRACT

Introduction: Pectoral fascia (PF) removal during mastectomy still seems to be the standard procedure. However, preservation of the PF might improve postoperative and cosmetic outcomes, without compromising oncological safety. Here, we report on a national survey among Dutch plastic surgeons and oncological breast surgeons to evaluate their techniques and opinions regarding the PF.

Materials and methods: A survey based study was performed in the Netherlands, in which both plastic surgeons and oncological breast surgeons were included, each receiving a different version of the survey. The surveys were distributed to 460 and 150 e-mail addresses, respectively.

Results: A total of 68 responses were included from more than half of all Dutch medical centers. The results of this study indicate that circa one in five plastic surgeons and breast surgeons routinely preserve the PF during mastectomies and even more surgeons preserve the PF in specific cases. The surgical techniques and opinions regarding PF preservation widely differ between surgeons.

Conclusions: Preservation of the PF does occur in a substantial part of the Dutch medical centers and techniques and opinions are contradictory. Future studies on this topic should clarify the effect of PF preservation on oncological safety, complication rates, postoperative pain, cosmetic outcomes, and patient satisfaction.

© 2022 The Author(s). Published by Elsevier Inc. This is an open access article under the CC BY license (<http://creativecommons.org/licenses/by/4.0/>).

* Corresponding author. Leiden University Medical Center (LUMC), Albinusdreef 2, 2333 ZA, Leiden, the Netherlands. Tel.: +31649763950.

E-mail address: y.l.blok@lumc.nl (Y.L. Blok).

0022-4804/\$ – see front matter © 2022 The Author(s). Published by Elsevier Inc. This is an open access article under the CC BY license (<http://creativecommons.org/licenses/by/4.0/>).

<https://doi.org/10.1016/j.jss.2022.10.031>

Introduction

Although breast-conserving surgery has gained popularity over the past decades, mastectomy remains indicated in a substantial part of breast cancer patients. In 2019, a mastectomy was performed in 31.4% of patients with invasive breast cancer and in 25.9% of patients with ductal carcinoma *in situ* in the Netherlands.¹ Furthermore, there is a notable rise in contralateral and bilateral prophylactic mastectomies.^{2,3} Thus, studies toward improving outcomes of mastectomies remain relevant.

During a skin-sparing mastectomy, removal of the pectoral fascia (PF) is widely performed. However, its necessity to do so is questionable. Historically, the PF was excised to ensure that no remnant breast tissue was left behind. However, the PF is part of the muscular anatomy instead of the breast glandular tissue. Therefore, the oncological benefit of PF excision is unlikely, except in rare cases of tumor invasion into the PF.⁴ In fact, PF preservation may improve postoperative and breast reconstructive outcomes. It prevents surgical damage to the pectoralis major muscle (PM), thereby possibly enhancing breast implant coverage and decreasing seroma formation, postoperative bleeding, and pain.⁵ It has been hypothesized that PF preservation may reduce reoperation rates and improve cosmetic outcomes.⁶

Although the potential benefits of PF preservation seem evident, the literature on this subject is scarce. Previous studies described heterogeneous outcomes based on small samples.⁴ For this reason, there is currently insufficient evidence to support implementation of PF preservation as the standard approach in the national guidelines. Here we report on a national survey in which attitudes on PF preservation among Dutch breast surgeons and plastic surgeons were studied.

Methods

A survey-based study was performed, in which both plastic surgeons and oncological breast surgeons were included, each receiving a different version of the survey. The surveys were distributed through the Dutch Society of Plastic Surgery (NVPC) and the Dutch Society of Surgical Oncology (NVCO). In the Netherlands, it is required for all plastic surgeons and breast surgeons (i.e., all oncological surgeons specialized in oncological breast surgery) to be a member of the NVPC or NVCO. Because no patients were involved, no permission of a medical ethics committee or informed consent was required.

The survey for the plastic surgeons was sent twice to 460 e-mail addresses by the NVPC with a 3-week time interval. The survey for the breast surgeons was sent to 150 e-mail addresses by the NVCO and in a newsletter of the clinical research center of the Leiden University Medical Center 2 mo later. As the breast surgeon response rate (RR) was low, the survey was resent directly to nonresponding breast surgeons.

The RR calculation was based on the total amount of e-mail addresses of plastic surgeons registered by the NVPC and of breast surgeons registered by the NVCO to whom the surveys

were sent to, which were 460 and 150 e-mail addresses, respectively.

Results

A total of 68 responses were included, consisting of 46 plastic surgeons (RR 10%) and 22 breast surgeons (RR 15%) from 41 different medical centers. These represent more than half of all Dutch medical centers (59%) and included both academic and peripheral medical centers, one oncological center and one specialized breast cancer center.

Plastic surgeons

Of all plastic surgeons, 17% indicated that the PF was preserved at all times during a mastectomy with an immediate reconstruction; 44% answered that the PF was never preserved; 33% answered that the PF was preserved in some cases; and 7% did not know whether the PF was preserved or excised.

According to the plastic surgeons who responded that the PF was never preserved, oncological safety was the main reason (80%).

Of all plastic surgery respondents, 57% believed that PF preservation may improve implant coverage, 44% that it may reduce complication rates, and 28% that it may improve cosmetic outcomes.

Breast surgeons

Of all breast surgeons, 18% responded that the PF was preserved at all times; 64% responded that the PF was routinely excised; and 18% responded that the PF was preserved only in those cases when the tumor is located at a safe distance from the fascia, which varied between 1 mm and 2 cm. This distance is set intraoperatively in 25% and preoperatively in 75% by using mammography (50%) or magnetic resonance imaging (50%).

According to the breast surgeons who responded that the PF was excised, oncological safety was the main reason (50%), followed by not being familiar with this technique (29%). In this group, 21% does exceptionally preserve the PF in prophylactic mastectomies.

Questions and responses of the plastic surgeons and breast surgeons are shown in [Figures 1 and 2](#), respectively.

Discussion

This study provides an overview on the current practice and opinions among Dutch plastic surgeons and breast surgeons toward handling of the PF during mastectomy. The results indicate that circa one in five plastic surgeons and breast surgeons routinely preserve the PF during mastectomies. Including those who responded that the PF is preserved on an occasional basis, half of the plastic surgeons and more than one-third of the breast surgeons do not stick to the standard dogmatic PF removal.

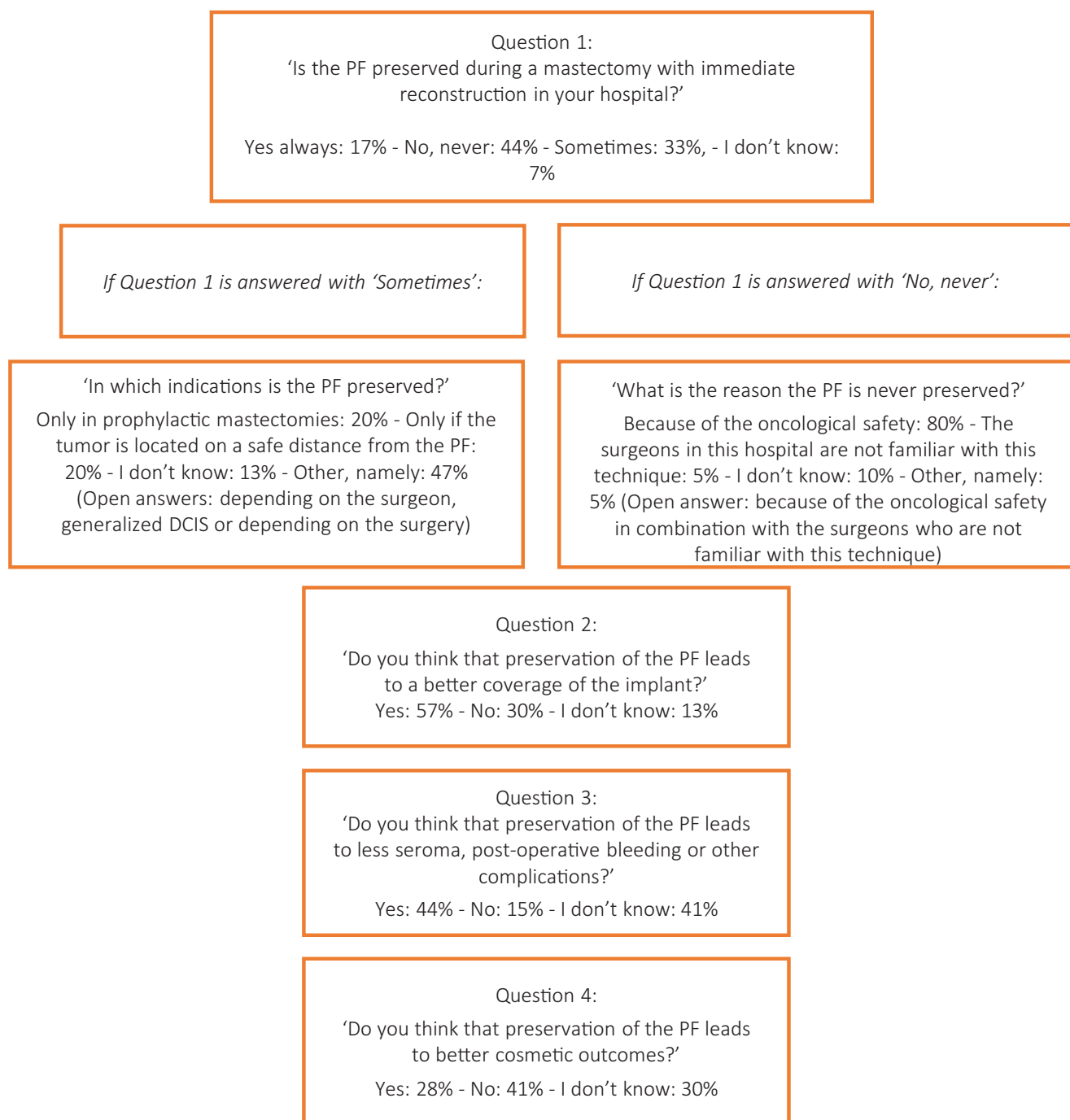


Fig. 1 – Survey overview on the practice of and attitudes toward PF preservation and answers as provided by 46 included plastic surgeons. PF = pectoral fascia.

The survey of the plastic surgeons shows that opinions differ on whether PF preservation may improve postoperative outcomes. Of all plastic surgical respondents, 57% believes that PF preservation may improve implant coverage, 44% believes that it may reduce postoperative complications, and 28% thinks that it may improve cosmetic outcomes.

Literature shows that the PF could be a valuable aid for implant coverage because it is a thin but strong fibroelastic layer.⁷ The PF is even used as a layer to cover the breast implant in a subfascial way, emphasizing its strength.^{8,9} Furthermore, it could be hypothesized that preservation of

the PF reduces postoperative complications, as 50% of postoperative hemorrhage requiring surgery originates from the PM.¹⁰ Moreover, seroma is mainly caused by muscle damage. One study on PF preservation indeed found a decrease in postoperative seroma formation.⁵

The main reason why the PF was never preserved according to the respondents of both surveys was because of oncological safety, although there is no proof of this statement in the current literature.⁶ Thereby, according to the breast surgeons, circa one in five responded that the PF was preserved only in those cases when the tumor is located at a safe

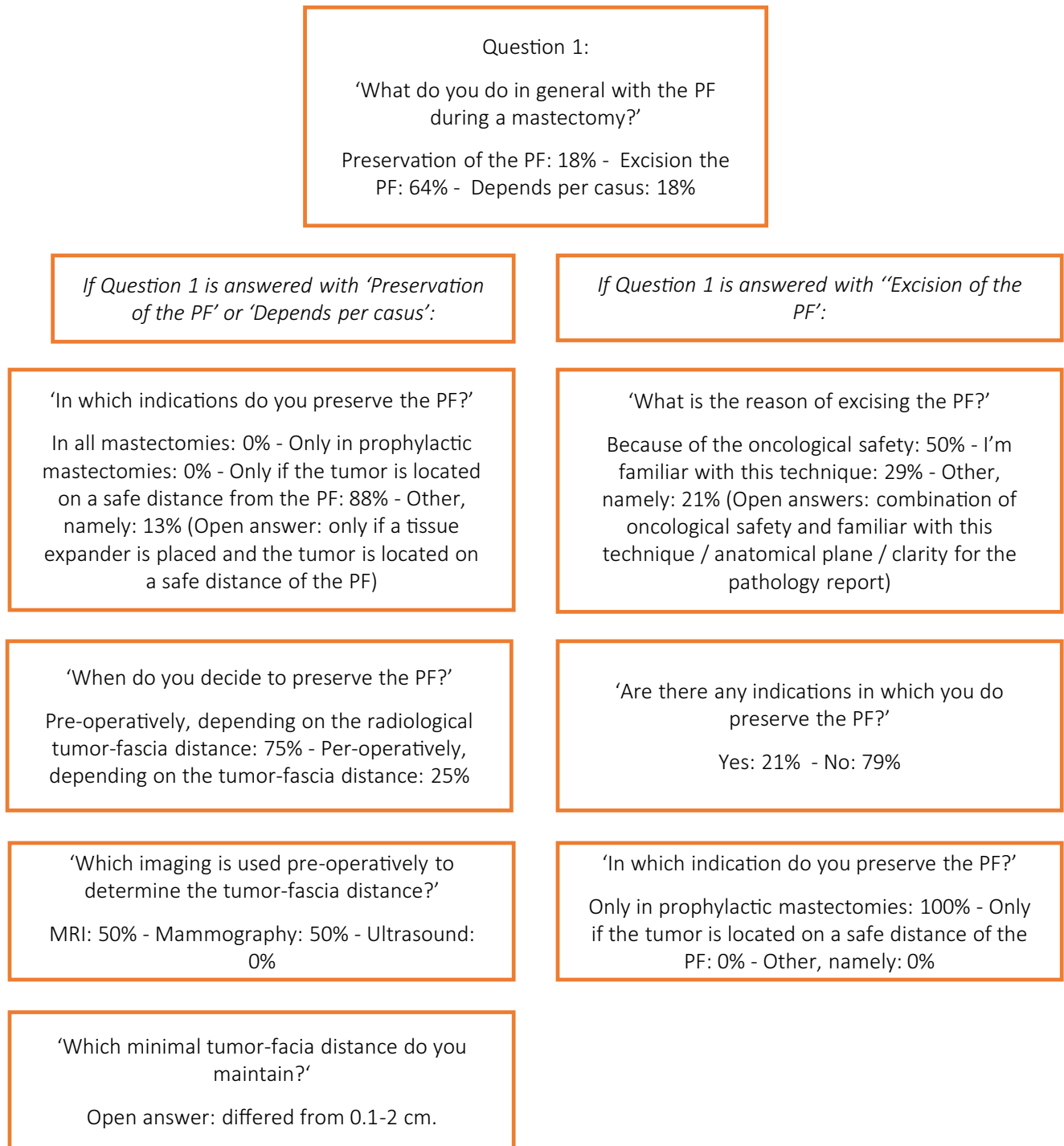


Fig. 2 – Survey overview on the practice of and attitudes toward PF preservation and answers as provided by 22 included breast surgeons. PF = pectoral fascia.

distance from the fascia, which varied between 1 mm and 2 cm. This implies that there is no consensus regarding the definition of this 'safe distance'.

If the oncological safety would be compromised by PF preservation, this should result in an increased rate of chest-wall recurrences, caused by invasion in the PF. However, previous studies show that chest-wall recurrences are rare, with an incidence of 0.97%-1.68%.^{11,12}

A previous trial comparing PF preservation with PF removal found no significant differences in oncological outcomes (local recurrence, regional recurrence, or distant metastasis).¹³ However, several studies have shown that PF invasion can occur when tumors are located within 5 mm of the PF and are unlikely to occur with more than 5-mm distance.^{4,14} This suggests that a tumor-fascia distance of more than 5 mm could be interpreted as safe.⁶

Another important reason why the PF was never preserved according to the breast surgeons was because they are not familiar with this technique. However, although the PF and the PM muscle should be considered together as one myofascial unit, excision of the PF is not the most understandable choice from a surgical technical point of view.^{6,7} Moreover, at least one-third of the Dutch breast surgeons already uses this PF-preserving technique.

The strength of this study is that the surveys were sent to all plastic surgeons and breast surgeons with respondents operating in the majority of Dutch medical centers, which implies that this study provides a valuable overview of handling of the PF during mastectomies in the Dutch practice.

However, RRs were low. Although the surveys were compact and sent multiple times, the RR remained 10%-15%, compared to substantial higher rates of 53% in other doctor surveys.¹⁵ This could be explained by the fact that not all plastic surgeons are specialized in breast surgery, so plastic surgeons with less interest in this topic were probably less likely to participate. Also, there could be some selection bias, as breast surgeons and plastic surgeons with a special interest in this subject were more tending to respond.

This study reported a preliminary overview of the Dutch practice and opinions regarding preservation of the PF. Yet, the results are interesting and important to draw more attention to this topic. The planned follow-up study should focus on increasing RRs by contacting the surgery and plastic surgery departments in all Dutch hospitals directly for the distribution of the surveys and additional questions should be added.

In conclusion, preservation of the PF does occur in a substantial part of the Dutch medical centers and techniques widely differ between medical centers. Future studies on this topic should clarify the effect of PF preservation on oncological safety, complication rates, postoperative pain, cosmetic outcomes, and patient satisfaction.

Author Contributions

Y.L. Blok, J. Suijker, C.C. van der Pol, and N.M.A. Krekel contributed to the concept of the article. Y.L. Blok contributed to the quality control of data, data acquisition, data analysis and interpretation, statistical analysis, and manuscript preparation. All authors contributed to the study design and manuscript editing. All authors approved the final version of the manuscript and agreed to be held accountable for all aspects of the work.

Disclosure

None declared.

Funding

None.

REFERENCES

1. Nabon Breast Cancer Audit (NBCA) jaarverslag uitkomsten 2019 (annual report 2019). Available at: <https://dica.nl/media/2511/NBCA%20Jaarverslag%202019.pdf>. Accessed June 4, 2020.
2. Albornoz CR, Bach PB, Mehrara BJ, et al. A paradigm shift in U.S. Breast reconstruction: increasing implant rates. *Plast Reconstr Surg*. 2013;131:15–23.
3. Cemal Y, Albornoz CR, Disa JJ, et al. A paradigm shift in U.S. breast reconstruction: Part 2. The influence of changing mastectomy patterns on reconstructive rate and method. *Plast Reconstr Surg*. 2013;131:320e–326e.
4. Vallejo da Silva A, Rodriguez FR, Loures CM, Lopes VG. Mastectomy in the era of implant-based reconstruction: should we be removing the pectoralis fascia? *Breast*. 2012;21:779–780.
5. Abdelhamid M, Alkilany M, Lotfy M. Pectoral fascia preservation during modified radical mastectomy: why and when. *Egypt J Surg*. 2017;36:333–335.
6. Suijker J, Blok YL, de Vries R, van den Tol MP, Krekel NMA. Pectoral fascia preservation in oncological mastectomy to reduce complications and improve reconstructions: a systematic review. *Plast Reconstr Surg Glob Open*. 2020;8:e2700.
7. Stecco A, Masiero S, Macchi V, et al. The pectoral fascia: anatomical and histological study. *J Bodyw Mov Ther*. 2009;13:255–261.
8. Benito-Ruiz J, Raigosa M, Manzano M, Salvador L. Subfascial breast augmentation: thickness of the pectoral fascia. *Plast Reconstr Surg*. 2009;123:31e–32e.
9. Jinde L, Jianliang S, Xiaoping C, et al. Anatomy and clinical significance of pectoral fascia. *Plast Reconstr Surg*. 2006;118:1557–1560.
10. Seth AK, Hirsch EM, Kim JY, et al. Hematoma after mastectomy with immediate reconstruction: an analysis of risk factors in 883 patients. *Ann Plast Surg*. 2013;71:20–23.
11. Chang JH, Shin KH, Ahn SD, et al. Chest wall recurrence in pT1-2N0-1 breast cancer patients after mastectomy without radiotherapy. *Breast Cancer Res Treat*. 2018;169:507–512.
12. McCarthy CM, Pusic AL, Sclafani L, et al. Breast cancer recurrence following prosthetic, postmastectomy reconstruction: incidence, detection, and treatment. *Plast Reconstr Surg*. 2008;121:381–388.
13. Dalberg K, Johansson H, Signomklao T, et al. A randomised study of axillary drainage and pectoral fascia preservation after mastectomy for breast cancer. *Eur J Surg Oncol*. 2004;30:602–609.
14. Nakao K, Miyata M, Aono T, et al. Cancer cell emboli in the pectoral lymphatics of patients with breast cancer. *Jpn J Surg*. 1989;19:392–397.
15. Meyer VM, Benjamens S, Moumni ME, Lange JFM, Pol RA. Global overview of response rates in patient and health care professional surveys in surgery: a systematic review. *Ann Surg*. 2022;275:e75–e81.