

<https://helda.helsinki.fi>

---

## Routine Inferior Mesenteric Artery Embolisation is Unnecessary Before Endovascular Aneurysm Repair

Väärämäki, Suvi

2023-03

---

Väärämäki , S , Viitala , H J , Laukontaus , S , Uurto , I , Björkman , P , Tulamo , R , Aho , P , Laine , M T , Suominen , V & Venermo , M 2023 , ' Routine Inferior Mesenteric Artery Embolisation is Unnecessary Before Endovascular Aneurysm Repair ' , European Journal of Vascular and Endovascular Surgery , vol. 65 , no. 2 , pp. 264-270 . <https://doi.org/10.1016/j.ejvs.2022.11.009>

---

<http://hdl.handle.net/10138/355922>

<https://doi.org/10.1016/j.ejvs.2022.11.009>

---

cc\_by

publishedVersion

---

*Downloaded from Helda, University of Helsinki institutional repository.*

*This is an electronic reprint of the original article.*

*This reprint may differ from the original in pagination and typographic detail.*

*Please cite the original version.*

# Routine Inferior Mesenteric Artery Embolisation is Unnecessary Before Endovascular Aneurysm Repair

Suvi Väärämäki <sup>a,\*</sup>, Herman Viitala <sup>b</sup>, Sani Laukontaus <sup>b</sup>, Ilkka Uurto <sup>a</sup>, Patrick Björkman <sup>b</sup>, Riikka Tulamo <sup>b</sup>, Pekka Aho <sup>b</sup>, Matti Laine <sup>b</sup>, Velipekka Suominen <sup>a,†</sup>, Maarit Venermo <sup>b,†</sup>

<sup>a</sup> Centre for Vascular Surgery and Interventional Radiology, Tampere University Hospital, and Tampere University, Faculty of Medicine and Life Sciences, Tampere, Finland

<sup>b</sup> Department of Vascular Surgery, University of Helsinki and Helsinki University Hospital, Helsinki, Finland

## WHAT THIS PAPER ADDS

The strategy of routine inferior mesenteric artery (IMA) embolisation during endovascular aneurysm repair vs. no embolisation did not yield any long term benefit in a two centre study of 732 patients. There were no differences in the rates of re-interventions for type II endoleaks, any re-interventions, aneurysm ruptures, or conversions. A strategy of routine IMA embolisation vs. no routine embolisation does not yield any significant clinical benefit.

**Objective:** A type II endoleak is the most common complication during surveillance after endovascular aneurysm repair (EVAR), and a patent inferior mesenteric artery (IMA) is a known risk factor for an endoleak. The effect of routine IMA embolisation prior to EVAR on overall outcome is unknown. The aim of the study was to compare two strategies: routine attempted IMA embolisation prior to EVAR (strategy in centre A) and leaving the IMA untouched (strategy in centre B).

**Methods:** Patients were treated with EVAR in two centres during the period 2005 – 2015, and the data were reviewed retrospectively. The primary endpoints were re-intervention rate due to type II endoleaks and the late IMA embolisation rate. Secondary endpoints included EVAR related re-intervention, sac enlargement, aneurysm rupture, and open conversion rates.

**Results:** Strategy A was used to treat 395 patients. The IMA was patent in 268 (67.8%) patients, and embolisation was performed in 164 (41.5%). The corresponding figures for strategy B were 337 patients with 279 (82.8%) patent IMAs, two (0.6%) of which were embolised. The mean duration of follow up was 70 months for strategy A and 68.2 months for strategy B. The re-intervention rates due to a type II endoleak were 12.9% and 10.4%, respectively ( $p = .29$ ), with no significant difference in the rate of re-interventions to occlude a patent IMA (2.0% and 4.7%, respectively;  $p = .039$ ). The EVAR related re-intervention rate was similar, regardless of strategy (24.1% and 24.6%, respectively;  $p = .93$ ). Significant sac enlargement was seen in 20.3% of cases treated with strategy A and in 19.6% treated with strategy B ( $p = .82$ ). The rupture and conversion rates were 2.5% and 2.1% ( $p = .69$ ) and 1.0% and 1.5% ( $p = .40$ ), respectively.

**Conclusion:** The strategy of routinely embolising the IMA does not seem to yield any significant clinical benefit and should therefore be abandoned.

**Keywords:** AAA, Embolisation, EVAR, IMA, Prophylactic, Routine

Article history: Received 19 May 2022, Accepted 1 November 2022, Available online 9 November 2022

© 2022 The Authors. Published by Elsevier B.V. on behalf of European Society for Vascular Surgery. This is an open access article under the CC BY license (<http://creativecommons.org/licenses/by/4.0/>).

## INTRODUCTION

A type II endoleak is the most common complication after endovascular aneurysm repair (EVAR) of an infrarenal

abdominal aortic aneurysm (AAA), affecting up to 50% of patients.<sup>1–3</sup> In most cases, an endoleak resolves spontaneously within six months of EVAR.<sup>1</sup> However, a persistent type II endoleak is associated with sac enlargement, conversion to open repair, and even aneurysm rupture.<sup>1,4</sup> Therefore, patients with a persistent type II endoleak require closer surveillance than those without.

A patent inferior mesenteric artery (IMA) is a strong risk factor for a type II endoleak.<sup>2,5–8</sup> Several retrospective and small randomised studies, as well as meta-analyses, have demonstrated the effectiveness of IMA embolisation in

<sup>†</sup> Shared last authorship.

\* Corresponding author. Tampere University Hospital, PO Box 2000, 33521 Tampere, Finland.

E-mail address: [suvi.vaaramaki@pshp.fi](mailto:suvi.vaaramaki@pshp.fi) (Suvi Väärämäki).

1078-5884/© 2022 The Authors. Published by Elsevier B.V. on behalf of European Society for Vascular Surgery. This is an open access article under the CC BY license (<http://creativecommons.org/licenses/by/4.0/>).

<https://doi.org/10.1016/j.ejvs.2022.11.009>

preventing type II endoleaks and sac enlargement. However, data on patients who would eventually benefit from prophylactic IMA embolisation remain inconclusive<sup>4,5,9–12</sup> due to the fact that most of pre-operatively patent IMAs occlude spontaneously after EVAR.<sup>13–15</sup>

Current guidelines lack recommendations on the treatment of a patent IMA during EVAR; therefore, various approaches exist in current clinical practice.<sup>16,17</sup> Some prefer routine preventive embolisation, while other strategies are based on size criteria (> 3 mm).<sup>11</sup> Only a few studies have shown the impact of embolisation on overall re-intervention rates.<sup>11–18</sup> Routine embolisation increases the costs of primary EVAR and is time consuming. Therefore, its efficacy with regard to the overall outcome remains controversial.

This study aimed to analyse whether the strategy of routine IMA embolisation benefits the long term outcome after elective EVAR.

## PATIENTS AND METHODS

This retrospective study consisted of all patients ( $n = 790$ ) assigned to elective treatment of an abdominal aortic aneurysm using standard EVAR in two academic institutions in Finland between 2005 and 2015. The initial indication for treatment in both institutions was an aneurysm with a diameter of  $\geq 55$  mm in men and  $\geq 50$  mm in women, or an increase of 5 mm in diameter over a period of six months. Patients were treated with four different stent grafts: Endurant (Medtronic, Santa Rosa, CA, USA); Excluder (W.L. Gore & Associates, Flagstaff, AZ, USA); Zenith (Cook, Bloomington, IN, USA); and Ovation (TriVascular, Santa Rosa, CA, USA). The number of treating specialists in both centres was limited to a few vascular surgeons and interventional radiologists. During the study period, these two academic institutions applied similar indications for primary and secondary procedures but different strategies for treating a patent IMA in patients undergoing EVAR. In hospital A, the strategy was to embolise all patent IMAs during the EVAR procedure (strategy A). The embolisations were performed by an interventional radiologist before endograft implantation during the same EVAR procedure via femoral access with a microcatheter technique using coils. Embolisation was defined as successful if the IMA was not patent on the completion angiogram. Embolisation was abstained from only if significant IMA stenosis was noted. In hospital B, the IMA was not routinely embolised during EVAR (strategy B).

The first follow up computed tomography angiography (CTA) was performed one month post-operatively in hospital A, and by three months post-operatively in hospital B. All patients were imaged at one year and annually thereafter. For sac enlargement, an additional CTA was scheduled to detect a possible endoleak. The indications for secondary procedures were the same in both centres. The indication for treating a type II endoleak was an increase in aneurysm diameter of at least 5 mm.

After approval by hospital administration, the patients' case records and all imaging data and radiology reports were reviewed carefully. Following the exclusion of patients for

whom follow up data beyond three months from the operation were not available, 732 patients were included in the long term analysis of the re-intervention rate due to sac enlargement, as well as conversion and aneurysm rupture rates. All 790 patients were included in the overall survival analysis.

Fifty-eight patients were excluded from the long term analysis of outcomes that were dependent on the surveillance imaging due to the fact that they had no or only one month imaging data available. Twenty-two patients died within 90 days of EVAR, one refused further follow up, one had widespread malignancy, and two were too frail to be included the long term analysis. The remainder of the excluded patients underwent one month CTA but died before the one year CTA. None of these 58 patients died due to a ruptured AAA or had a conversion due to aneurysm sac enlargement. These patients were included in the analysis of overall survival.

All CTAs were re-analysed for the study by the authors. The following pre-operative data were extracted: patient age and sex; maximum anteroposterior aneurysm diameter; patency of the IMA and, if patent, the diameter of the IMA 10 mm from its origin. The measurement of pre-operative aneurysm and IMA diameters was standardised between the two centres. Peri-operative data included the type of stent graft used, information on pre-operative IMA embolisation if performed, and the presence of an endoleak in the completion angiogram. The follow up imaging data were analysed for information on maximum aneurysm anteroposterior diameter and the presence and type of endoleaks. Furthermore, all re-interventions due to endoleaks or aneurysm growth were recorded, as was information regarding open conversions and aneurysm ruptures. Mortality data were extracted from the Finnish Population Registry Centre.

In the analysis, the outcomes of strategy A and strategy B were compared. Strategy A included all patients from hospital A and strategy B comprised all patients treated in hospital B. The primary endpoint measures were secondary procedure rate due to a type II endoleak and the rate of late IMA embolisations due to sac enlargement. Secondary endpoint measures were the incidence of significant aneurysm growth ( $\geq 5$  mm from the size on pre-operative imaging), incidence of open conversions, and aneurysm rupture. Furthermore, overall survival and overall secondary procedure rates were analysed.

## Statistical analysis

Demographic characteristics are expressed as  $n$  (%) and continuous variables as mean  $\pm$  standard deviation. Kaplan–Meier analysis was used to compare the freedom from selected endpoints and the log rank test to analyse the differences between the strategies. Data analysis was performed using the SPSS 22.0 statistical software (IBM, Armonk, NY, USA).

## Ethical approval

Ethics committee approval was not required for a retrospective registry study.

## RESULTS

The full cohort consisted of 732 patients (strategy A, 395 patients; strategy B, 337 patients). The baseline characteristics are presented in Table 1 and the study flow chart in Figure 1.

With strategy A, the IMA was patent in 268 (67.8%) patients. Embolisation was attempted in 209 cases and successful in 164 patients (78.5%). The main reason for abstaining from embolisation was a significant IMA ostium stenosis or the IMA was not visualised on the angiogram. With strategy B, the IMA was patent in 279 (82.8%) patients, and two (0.6%) IMA embolisations were performed at the surgeon's discretion in connection with the EVAR procedure. There were no direct complications related to IMA embolisation. On the completion angiogram, any endoleak was observed in 82 cases (20.7%) following strategy A and in 177 cases following strategy B (52.5%;  $p < .001$ ). On the first follow up CTA at one to three months post-operatively, an endoleak was noted in 71 cases (18.0%) with strategy A and in 81 cases (24.0%) with strategy B ( $p = .008$ ). Of these, 35.2% ( $n = 25$ ) in strategy A and 40.7% ( $n = 33$ ) in strategy B resolved spontaneously during later surveillance.

The mean duration of follow up was  $70.0 \pm 32$  months with strategy A and  $68.2 \pm 35.2$  months with strategy B. There was no statistically significant difference in the rates of re-interventions due to type II endoleaks (12.9% [ $n = 51$ ] in strategy A and 10.4% [ $n = 35$ ] in strategy B;  $p = .29$ ). Late IMA embolisation due to sac enlargement was performed more often with strategy B (2.0% and 4.7% for strategies A and B, respectively;  $p = .039$ ). With strategy A, eight IMA embolisations were performed during later surveillance, and they were all successful. In one of these cases, the IMA embolisation was also performed during the primary procedure. With strategy B, 16 IMA embolisations were performed, but, in one case, the sac enlargement persisted, eventually resulting in an open conversion.

Any EVAR related re-intervention was performed for 24.1% and 24.6% of the patients with strategies A and B, respectively ( $p = .93$ ). The rupture rate was 2.5% ( $n = 10$ ) for strategy A and 2.1% ( $n = 7$ ) for strategy B ( $p = .68$ ). None of the patients with persistent type II endoleak originating from the IMA died as a result of a ruptured AAA. The conversion rates were 1.0% ( $n = 4$ ) and 2.1% ( $n = 7$ ) for strategies A and B, respectively ( $p = .40$ ). Aneurysm sac enlargement of  $\geq 5$  mm during follow up was seen in 20.3% ( $n = 80$ ) of the cases with strategy A and in 19.6% ( $n = 66$ ) with strategy B ( $p = .82$ ; Table 2).

The Kaplan–Meier survival rate at 30 days was 99.1% (standard error [SE] 0.5) for strategy A and 98.6% (SE 0.6) for strategy B; the one year survival rates were 93.5% (SE 1.2) and 90.7% (SE 1.5), and the five year survival rates 66.3% (SE 2.3) and 65.1% (SE 2.6) for strategies A and B, respectively. In logistic regression analysis, factors that were independently associated with long term survival were age at the time of EVAR (odds ratio [OR] 1.083, 95% confidence interval [CI] 1.061 – 1.107;  $p < .001$ ) and aneurysm diameter (cm) on the pre-operative CTA (OR 1.2, 95% CI 1.03 – 1.35;  $p < .001$ ). Survival was not associated with strategy (strategy A vs. strategy B: OR 1.059, 95% CI 0.784 – 1.531 [ $p = .71$ ]).

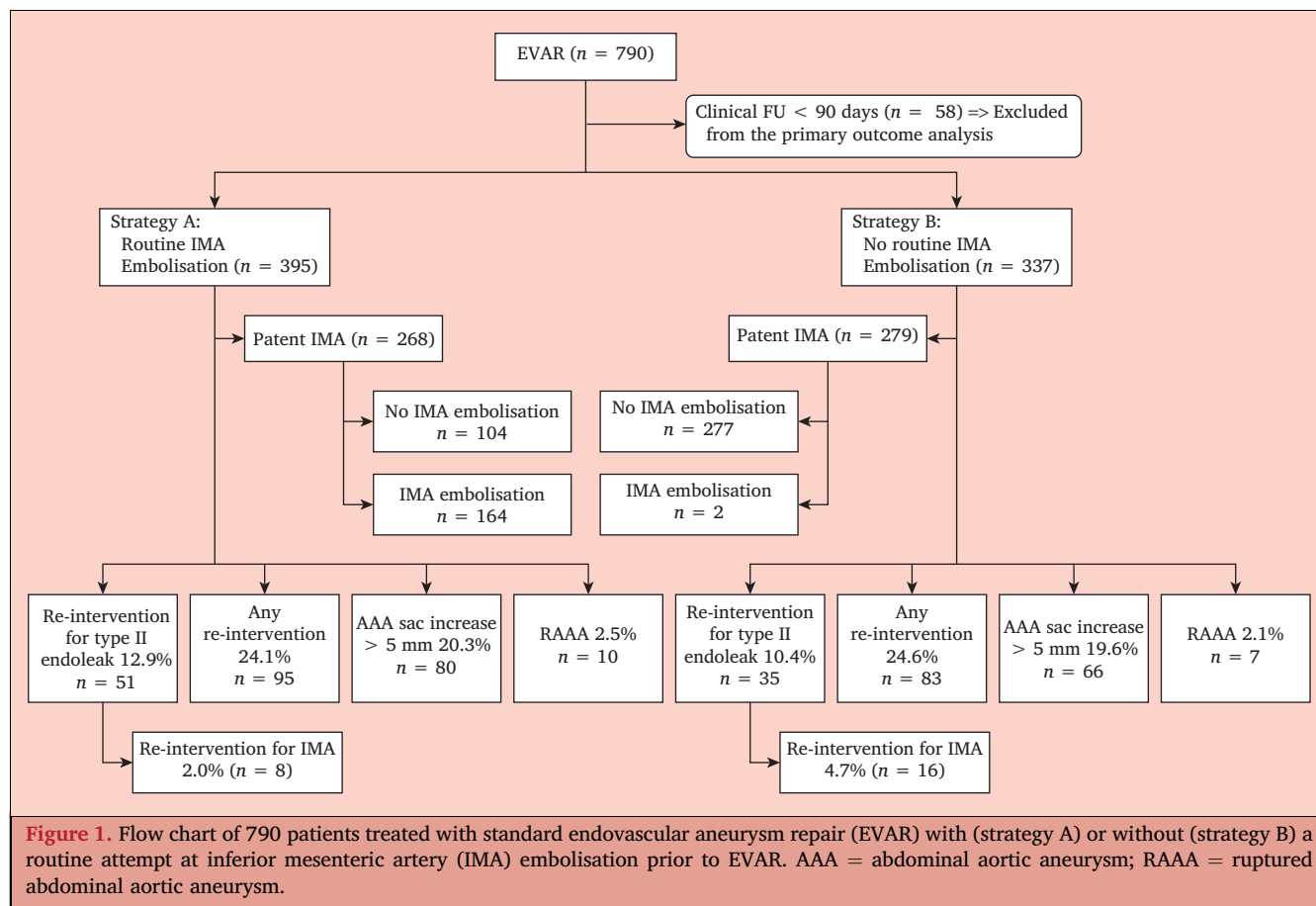
### Subgroup analysis

A subgroup analysis was conducted of patients whose IMA was patent on the pre-operative CT, comparing patients who underwent successful IMA embolisation (subA;  $n = 166$ ) with those who did not undergo embolisation (subB;  $n = 381$  [Table 3]). The prevalence of endoleaks detected on the completion angiogram was higher in patients who did not undergo embolisation (subA 20.5% vs. subB 47.2%;  $p < .001$ ). On the first follow up CTA, an endoleak was observed in 17.5% and 25.5% of the patients in subgroups subA and subB, respectively ( $p = .068$ ). The respective overall re-intervention rates were 27.0% and 21.7% ( $p = .48$ ). A sac

**Table 1. Characteristics of 732 patients treated with endovascular aneurysm repair (EVAR) with (strategy A) or without (strategy B) a routine attempt at inferior mesenteric artery (IMA) embolisation prior to EVAR**

	Strategy A ( $n = 395$ )	Strategy B ( $n = 337$ )
Age – y	$76.0 \pm 7.1$	$74.6 \pm 7.9$
Male sex	352 (89.1)	293 (86.9)
Aneurysm diameter – mm	$63 \pm 10$ (44–130)	$63 \pm 9$ (43–98)
IMA diameter – mm	$3.14 \pm 0.86$	$3.16 \pm 1.09$
IMA patent, not embolised	104 (26.3)	277 (82.2)
IMA patent, embolised	164 (41.5)	2 (0.6)
IMA occluded	126 (31.9)	44 (13.1)
No contrast medium used in pre-operative CT or CT not available	1 (0.3)	14 (4.1)
<b>Device type</b>		
Endurant	66 (16.7)	139 (41.2)
Excluder	141 (35.7)	97 (28.8)
Zenith	188 (47.6)	94 (27.9)
Ovation	0	7 (2.1)

Data are presented as  $n$  (%) or mean  $\pm$  standard deviation (range). CT = computed tomography.



enlargement of  $\geq 5$  mm was observed in 21.5% and 17.5%, respectively ( $p = .30$ ).

Of the patients whose IMA was embolised pre-operatively (subA), 1.2% ( $n = 2$ ) underwent open conversion vs. the 1.7% ( $n = 7$ ) in the other subgroup ( $p = .73$ ). The secondary sac rupture rate was 2.4% in both subgroups.

Finally, patients who had a patent IMA pre-operatively but who did not undergo intra-operative embolisation were compared in two groups: those with a diameter  $< 4$  mm ( $n = 301$ ) vs.  $\geq 4$  mm ( $n = 81$ ). In these groups, the overall re-intervention rates were 25.6% and 32.1% ( $p = .26$ ), respectively, while the respective IMA embolisation rates were 4.9% and 6.2% ( $p = .13$ ), the sac enlargement ( $\geq 5$  mm) rates 20.3% and 25.9% ( $p = .29$ ), the conversion rates 1.6% and 2.5% ( $p = .64$ ), and the secondary sac rupture rates 2.6% and 2.5% ( $p = 1.0$ ). None of the differences achieved statistical significance.

## DISCUSSION

To the best of the authors' knowledge, this is among the first larger studies comparing the effects of a pre-established protocol of routine embolisation vs. no routine embolisation of the IMA before EVAR. The results show that routine IMA embolisation yields no significant long term benefit over no routine embolisation. It does not

significantly lower the rate of secondary procedures for type II endoleaks or the overall EVAR related re-intervention rate. Obviously, there were more IMA related re-interventions in the no routine embolisation group, but the overall IMA embolisation rate was only 4.7% in this group and the difference in re-intervention rates between the groups was not statistically significant. Furthermore, the main goal of EVAR is to prevent AAA rupture, and no significant difference was found in the rupture rates between the two groups.

There are no randomised controlled trials (RCTs) to support routine IMA embolisation during EVAR with respect to a better overall long term outcome. One recent RCT demonstrated a reduced incidence of type II endoleaks and aneurysm sac growth in patients who underwent routine IMA embolisation, but a positive effect of embolisation on the re-intervention rate was not established.<sup>19</sup> Type II endoleaks after EVAR were common, but the incidence of IMA based type II endoleaks was relatively low, as in the current study. Similar findings have also been reported in previous studies.<sup>10</sup> In the current series, most of the procedures performed due to type II endoleaks were lumbar artery embolisations. Some studies suggest that the routine embolisation of the IMA and large patent lumbar arteries reduces the rate of lumbar endoleaks.<sup>20–22</sup> The current study did not analyse the number or size of lumbar arteries, but there was no significant difference between the two

**Table 2.** Outcome of 732 patients treated with endovascular aneurysm repair (EVAR) with (Strategy A) or without (Strategy B) a routine attempt at inferior mesenteric artery (IMA) embolisation prior to EVAR

	Strategy A (n = 395)	Strategy B (n = 337)	Total (n = 732)	p value
Follow up – mo	70 ± 32	68 ± 35		
<i>Re-interventions</i>				.93
No re-intervention	299 (75.7)	250 (74.2)	549 (75.0)	
One re-intervention	54 (13.7)	57 (16.9)	111 (15.2)	
Two re-interventions	19 (4.8)	11 (3.3)	30 (4.1)	
Three or more re-interventions	22 (5.6)	15 (4.4)	37 (5.0)	
Late IMA embolisation	8 (2.0)	16 (4.7)	24 (3.3)	.039
Endoleak on completion angiogram	82 (20.7)	177 (52.5)	259 (35.4)	<.001
Endoleak on first imaging	71 (18.0)	81 (24.0)	152 (20.8)	.008
Sac increase > 5 mm	80 (20.2)	66 (19.6)	146 (19.9)	.82
Open conversion	4 (1.0)	7 (2.1)	11 (1.5)	.40
Post-EVAR aneurysm rupture	10 (2.5)	7 (2.1)	17 (2.3)	.68
Overall one year survival (SE)	93.5 (1.2)	90.7 (1.5)		.66

Data are presented as n (%) or mean ± standard deviation, unless stated otherwise. SE = standard error.

groups in the rate of re-interventions due to type II endoleaks in long term surveillance. A 2021 study by Petit *et al.* did not find preventive embolisation to decrease sac shrinking or redo procedures.<sup>23</sup> In this study, a third of patients were treated with fenestrated EVAR.

In this study, intra-operative IMA embolisation was safe, with no direct complications, and it was technically possible and successful in the majority of the cases. In the literature, the reported success rates of pre- or intra-operative embolisation of the IMA are high, as are those of embolisation performed during later surveillance.<sup>3,10</sup> The current study did not analyse the effect of IMA embolisation on intra-operative factors, but, in general, it is time consuming and increases radiation exposure and the use of contrast agent. Furthermore, it increases the costs of the primary procedure, as relatively expensive embolisation materials

are used. The classic method of IMA embolisation is using stainless steel or platinum coils, but several coils are usually required to achieve occlusion.<sup>5</sup> The use of vascular plugs has also been reported with good results and lower costs.<sup>24</sup> Nevertheless, based on the present findings, the expense and effort applied to routine IMA embolisation may not be justified, as the incidence of problems related to non-routine embolisation is relatively low and possible problems can usually be treated with good success.

Finally, a subgroup analysis was performed comparing patients whose IMA was occluded prophylactically with patients who had a patent IMA pre-operatively but who did not undergo IMA embolisation during EVAR. The latter subgroup had an on table endoleak on the completion angiogram significantly more often, but there was no significant difference in the endoleak rate in the first follow up

**Table 3.** Subgroup analysis of 790 patients treated with endovascular aneurysm repair (EVAR) who had a patent inferior mesenteric artery (IMA) on pre-operative computed tomography (CT) that was not embolised (subA group) or embolised (subB group), and the outcome measures of patients who had an occluded IMA on the pre-operative CT

	IMA patent, not embolised (subA; n = 381)	IMA patent, embolised (subB; n = 166)	p value*	IMA occluded on pre-operative CT (n = 185) <sup>†</sup>
<i>Re-procedures</i>	103 (27.0)	36 (21.7)	.48	36 (19.4)
No re-procedures	278 (73.0)	130 (78.3)		133 (71.9)
One re-procedure	69 (18.1)	20 (12.0)		21 (11.3)
Two re-procedure	14 (3.7)	7 (4.2)		8 (4.3)
Three or more re-procedures	20 (5.2)	9 (5.4)		7 (3.8)
Late IMA embolisation	20 (5.2)	0 (0)	.035	4 (2.2) <sup>‡</sup>
Endoleak in completion angiogram	180 (47.2)	34 (20.5)	<.001	38 (20.5)
Endoleak on first imaging	97 (25.4)	29 (17.5)	.068	24 (13.0)
Sac increase > 5 mm	82 (21.5)	29 (17.5)	.30	33 (17.8)
Open conversion	7 (1.8)	2 (1.2)	.73	2 (1.1)
Post-EVAR aneurysm rupture	9 (2.4)	4 (2.4)	1.0	4 (2.2)

Data are presented as n (%).

\* Comparison between subA and subB groups.

<sup>†</sup> Includes 15 patients in whom pre-operative CTs were not available or no contrast medium was used in the CT.

<sup>‡</sup> In three patients, the IMA was patent and occluded later but was judged to be occluded on the pre-operative CT; one patient who did not have a pre-operative CT available underwent later IMA occlusion.

CTA at one to three months. Furthermore, there was no difference in the re-intervention rate, the incidence of significant sac enlargement, or the open conversion and secondary sac rupture rates during long term surveillance. Previous studies have reported an association between the large diameter of a patent IMA ( $\geq 3$  to 3.8 mm) and a type II endoleak, but no adverse effect has been established of a large patent IMA on conversion or ruptured AAA rates.<sup>25–27</sup> In the subanalysis of the size of a patent IMA, when the IMAs were categorised into two groups ( $< 4$  mm or  $\geq 4$  mm), there was no significant difference in the primary endpoints between groups. However, as there were only 81 patients with a large IMA, the comparison lacked statistical power. In patients with an IMA diameter of  $\geq 4$  mm, the IMA was occluded with a secondary intervention at a later stage in only 6.5% of patients.

This study had several limitations. First, it was a retrospective comparative study of a real world cohort; however, the pre-operative design was almost comparable to a RCT, as the centres had a pre-established protocol in place for the procedure and surveillance. Also, these two academic centres applied similar indications for primary and secondary procedures, and the number of operating surgeons was limited to a few experienced hands, indicating comparable strategies. The strengths of this study include the detailed analysis of both patient groups treated in two similar academic centres. As a flaw, pre-operative CTAs were also analysed in two centres, which might, together with the fact that, in some cases, only two phase images were available, affect the analysis of the patency and size of the IMA. The measurement was standardised, but it was still dependent on the judgement of the physician, and the current study cannot be considered conclusive with regard to the size of the IMA. However, the threshold for re-interventions was the same, resulting in a similar overall outcome. Furthermore, some low flow endoleaks could have been detected by other surveillance methods, such as contrast enhanced ultrasound. This would probably have had little effect on clinical decision making, as it is widely accepted that only type II endoleaks associated with aneurysm sac growth require re-intervention.

### Conclusion

Routine IMA embolisation does not seem to yield any significant clinical benefit and should therefore be abandoned.

### CONFLICT OF INTEREST

M.V. has completed lectures and workshops for Gore & Associates, Medtronic, and Cook Medical; is a Principal Investigator in the VOYAGER trial (Bayer); and participates in the advisory board for Philips.

### FUNDING

None.

### REFERENCES

- 1 Avgerinos ED, Chaer RA, Makaroun MS. Type II endoleaks. *J Vasc Surg* 2014;**60**:1386–91.
- 2 van Marrewijk C, Buth J, Harris PL, Norgren L, Nevelsteen A, Wyatt MG. Significance of endoleaks after endovascular repair of abdominal aortic aneurysms: the EUROSTAR experience. *J Vasc Surg* 2002;**35**:461–73.
- 3 Sidloff DA, Stather PW, Choke E, Bown MJ, Sayers RD. Type II endoleak after endovascular aneurysm repair. *Br J Surg* 2013;**100**:1262–70.
- 4 Ward TJ, Cohen S, Fischman AM, Kim E, Nowakowski FS, Ellozy SH, et al. Preoperative inferior mesenteric artery embolization before endovascular aneurysm repair: decreased incidence of type II endoleak and aneurysm sac enlargement with 24-month follow-up. *J Vasc Interv Radiol* 2013;**24**:49–55.
- 5 Nevala T, Biancari F, Manninen H, Matsi P, Mäkinen K, Ylönen K, et al. Inferior mesenteric artery embolization before endovascular repair of an abdominal aortic aneurysm: effect on type II endoleak and aneurysm shrinkage. *J Vasc Interv Radiol* 2010;**21**:181–5.
- 6 Velazquez OC, Baum RA, Carpenter JP, Golden MA, Cohn M, Pyeron A, et al. Relationship between preoperative patency of the inferior mesenteric artery and subsequent occurrence of type II endoleak in patients undergoing endovascular repair of abdominal aortic aneurysms. *J Vasc Surg* 2000;**32**:777–88.
- 7 Sampaio SM, Panneton JM, Mozes GI, Andrews JC, Bower TC, Kalra M, et al. Aneurysm sac thrombus load predicts type II endoleaks after endovascular aneurysm repair. *Ann Vasc Surg* 2005;**19**:302–9.
- 8 Fan CM, Rafferty EA, Geller SC, Kaufman JA, Brewster DC, Cambria RP, et al. Endovascular stent-graft in abdominal aortic aneurysms: the relationship between patent vessels that arise from the aneurysmal sac and early endoleak. *Radiology* 2001;**218**:176–82.
- 9 Axelrod DJ, Lookstein RA, Guller J, Nowakowski FS, Ellozy S, Carroccio A, et al. Inferior mesenteric artery embolization before endovascular aneurysm repair: technique and initial results. *J Vasc Interv Radiol* 2004;**15**:1263–7.
- 10 Muthu C, Maani J, Plank LD, Holden A, Hill A. Strategies to reduce the rate of type II endoleaks: routine intraoperative embolization of the inferior mesenteric artery and thrombin injection into the aneurysm sac. *J Endovasc Ther* 2007;**14**:661–8.
- 11 Manunga JM, Cragg A, Garberich R, Urbach JA, Skeik N, Alexander J, et al. Preoperative inferior mesenteric artery embolization: a valid method to reduce the rate of type II endoleak after EVAR? *Ann Vasc Surg* 2017;**39**:40–7.
- 12 Chew DK, Dong S, Schroeder AC, Hsu HW, Franko J. The role of the inferior mesenteric artery in predicting secondary intervention for type II endoleak following endovascular aneurysm repair. *J Vasc Surg* 2019;**70**:1463–8.
- 13 Jones JE, Atkins MD, Brewster DC, Chung TK, Kwolek CJ, LaMuraglia GM, et al. Persistent type 2 endoleak after endovascular repair of abdominal aortic aneurysm is associated with adverse late outcomes. *J Vasc Surg* 2007;**46**:1–8.
- 14 Tolia AJ, Landis R, Lamparello P, Rosen R, Macari M. Type II endoleaks after endovascular repair of abdominal aortic aneurysms: natural history. *Radiology* 2005;**235**:683–6.
- 15 Dorffner R, Schoder M, Mostbeck G, Hölzenbein T, Thurnher S, Lammer J. Inferior mesenteric artery as outflow vessel in endoleaks after abdominal aortic stent-graft implantation: 36-month follow-up CT study. *Eur Radiol* 2001;**11**:2252–7.
- 16 Wanhainen A, Verzini F, Van Herzele I, Allaire E, Bown M, Cohnert T, et al. European Society for Vascular Surgery (ESVS) 2019 Clinical Practice Guidelines on the Management of Abdominal Aortoiliac Artery Aneurysms. *Eur J Vasc Endovasc Surg* 2019;**57**:8–93.
- 17 Chaikof EL, Brewster DC, Dalman RL, Makaroun MS, Illig KA, Sicard GA, et al. SVS practice guidelines for the care of patients with an abdominal aortic aneurysm: executive summary. *J Vasc Surg* 2009;**50**:880–96.

- 18 Vaillant M, Barral PA, Mancini J, De Masi M, Bal L, Piquet P, et al. Preoperative inferior mesenteric artery embolization is a cost-effective technique that may reduce the rate of aneurysm sac diameter enlargement and reintervention after EVAR. *Ann Vasc Surg* 2019;**60**:85–94.
- 19 Samura M, Morikage N, Otsuka R, Mizoguchi T, Takeuchi Y, Nagase T, et al. Endovascular aneurysm repair with inferior mesenteric artery embolization for preventing type II endoleak: a prospective randomized controlled trial. *Ann Surg* 2020;**271**: 238–44.
- 20 Kray J, Kirk S, Franko J, Chew DK. Role of type II endoleak in sac regression after endovascular repair of infrarenal abdominal aortic aneurysms. *J Vasc Surg* 2015;**61**:869–74.
- 21 Parry DJ, Kessel DO, Robertson I, Denton L, Patel JV, Berridge DC, et al. Type II endoleaks: predictable, preventable, and sometimes treatable? *J Vasc Surg* 2002;**36**:105–10.
- 22 Fukuda T, Matsuda H, Tanaka H, Sanda Y, Morita Y, Seike Y. Selective inferior mesenteric artery embolization during endovascular abdominal aortic aneurysm repair to prevent type II endoleak. *Kobe J Med Sci* 2018;**63**:E130–5.
- 23 Petit P, Hertault A, Mesnard T, Bianchini A, Lopez B, Patterson BO, et al. Outcomes of Preventive embolization of the inferior mesenteric artery during EVAR. *J Vasc Interv Radiol* 2021;**32**:1360–70.
- 24 Burbelko M, Kalinowski M, Heverhagen JT, Piechowiak E, Kiessling A, Figiel J, et al. Prevention of type II endoleak using the AMPLATZER vascular plug before endovascular aneurysm repair. *Eur J Vasc Endovasc Surg* 2014;**47**:28–36.
- 25 Löwenthal D, Herzog L, Rogits B, Bulla K, Weston S, Meyer F, et al. Identification of predictive CT angiographic factors in the development of high-risk type 2 endoleaks after endovascular aneurysm repair in patients with infrarenal aortic aneurysms. *Rofu* 2015;**187**:49–55.
- 26 Müller-Wille R, Schötz S, Zeman F, Uller W, Güntner O, Pfister K, et al. CT features of early type II endoleaks after endovascular repair of abdominal aortic aneurysms help predict aneurysm sac enlargement. *Radiology* 2015;**274**:906–16.
- 27 Samura M, Morikage N, Mizoguchi T, Takeuchi Y, Ueda K, Harada T, et al. Identification of anatomical risk factors for type II endoleak to guide selective inferior mesenteric artery embolization. *Ann Vasc Surg* 2018;**48**:166–73.

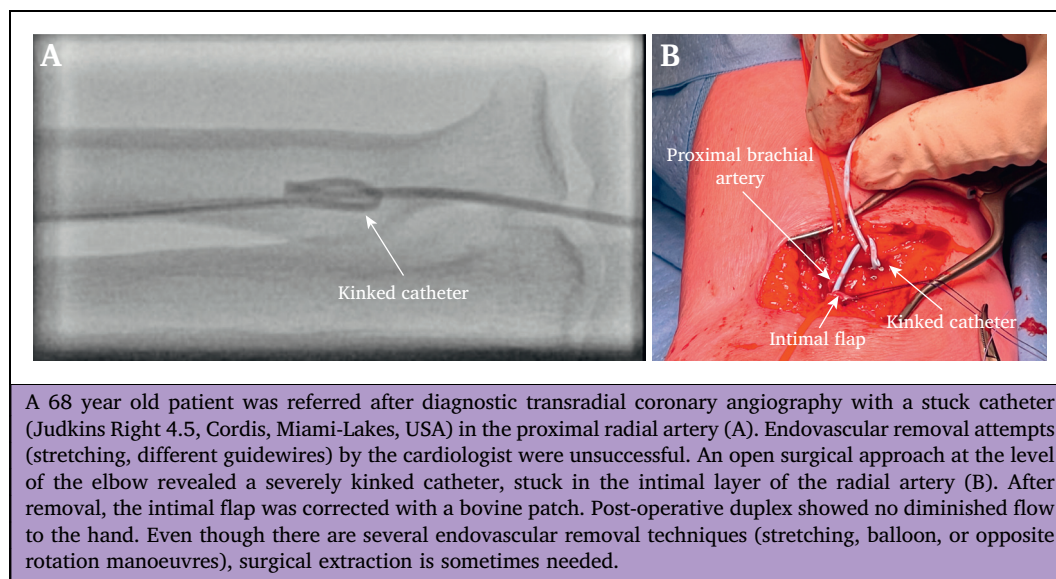
Eur J Vasc Endovasc Surg (2023) 65, 270

## COUP D'OEIL

# Severely Kinked Catheter Removal After Transradial Coronary Angiography: Sometimes Surgery is Unpreventable

Joris J. Blok<sup>\*</sup>, Peter M. Schlejen

Department of Surgery, Groene Hart Ziekenhuis, Gouda, the Netherlands



\* Corresponding author. Joris J. Blok, Department of Surgery, Groene Hart Ziekenhuis, Bleulandweg 10, 2800 BB Gouda, the Netherlands.

E-mail address: [joris.blok@ghz.nl](mailto:joris.blok@ghz.nl) (Joris J. Blok).

1078-5884/© 2022 Published by Elsevier B.V. on behalf of European Society for Vascular Surgery.

<https://doi.org/10.1016/j.ejvs.2022.10.019>