

## CASE REPORT

# A Case of Angiomatoid Epithelioid Sarcoma Mimicking an Epithelioid Vascular Neoplasm

Shau-Kong Lai<sup>1</sup>, Ling Tze Tan<sup>2</sup>, Lii-Jye Tan<sup>3</sup>, Cai Ping Koh<sup>4</sup>, Balqis Yahaya<sup>1</sup>, Huzlinda Hussin<sup>1</sup>

<sup>1</sup> Department of Pathology, Faculty of Medicine and Health Sciences, Universiti Putra Malaysia, 43400 Serdang, Selangor, Malaysia.

<sup>2</sup> Department of Pathology, Hospital Raja Permaisuri Bainun, Jalan Raja Ashman Shah, 30450 Ipoh, Perak, Malaysia.

<sup>3</sup> Department of Forensic Pathology, Hospital Raja Permaisuri Bainun, Jalan Raja Ashman Shah, 30450 Ipoh, Perak, Malaysia.

<sup>4</sup> Department of Biochemistry, Faculty of Medicine, Quest International University, 30250 Ipoh, Perak, Malaysia

### ABSTRACT

Epithelioid sarcoma is a rare but aggressive soft tissue sarcoma that presents a significant diagnostic and management challenge to clinicians. We report a 31-year-old female who presented with a non-healing ulcer of three years' duration on her left thumb after a burn. Examination revealed an ulcerative tumour invading the bone with areas of haemorrhage. Microscopic examination showed an epithelioid neoplasm with central necrosis. The neoplastic cells formed dyscohesive sheets, slit-like channels, and pseudovascular spaces. Erythrocytes were frequently observed in these areas. The neoplastic malignant cells were diffusely positive for cytokeratin AE1/AE3, EMA, vimentin, Fli-1; while focally positive for CD34 and CD31. The morphology and immunophenotype overlap with a vascular neoplasm. Additional immunohistochemical stain revealed loss of SMARCB1/INI1 expression supporting the diagnosis of epithelioid sarcoma of distal type, angiomatoid variant. We present a distinctive case of angiomatoid epithelioid sarcoma that developed in a burn ulcer and highlight pathological characteristics that distinguish it from epithelioid vascular neoplasms.

*Malaysian Journal of Medicine and Health Sciences* (2022) 18(SUPP21): 122-125. doi:10.47836/mjmhs18.s21.19

**Keywords:** Angiosarcoma, Epithelioid Sarcoma, Kaposi Sarcoma, Ulcer

### Corresponding Author:

Shau-Kong Lai, DrPath

Email: shaukong@upm.edu.my

Tel: +603-97692392

### INTRODUCTION

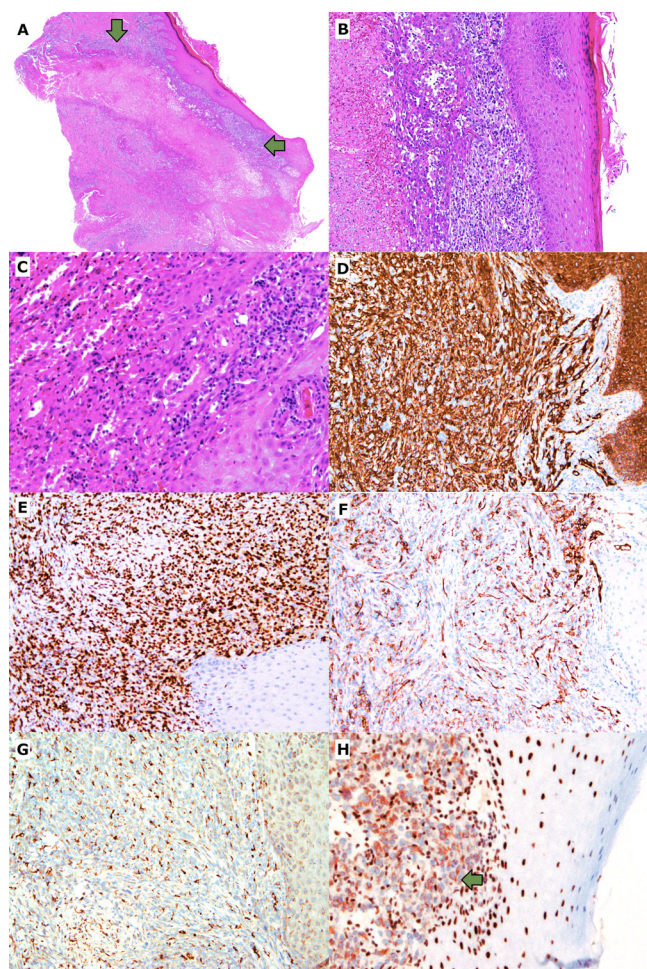
Epithelioid sarcoma (EpS) is a highly aggressive neoplasm that accounts for less than 1% of all soft tissue sarcoma (1). It is a mesenchymal neoplasm with multidirectional differentiation, including epithelial, endothelial, and myofibroblastic phenotype (1). These tumours are characterized by the absence of SMARCB1/INI1 protein expression and, in a subset of cases, recurrent mutations in the 22q region of the chromosome (2). EpS are classified into two subtypes: distal-type and proximal-type. The distal-type EpS might have an indolent character and gradual growth, which could lead to misdiagnosis or delayed diagnosis (1). Histological similarities to non-neoplastic inflammatory lesions such as necrotizing granuloma and granuloma annulare are also possibilities of histological misdiagnosis (1). The proximal-type EpS has a more aggressive clinical course, forming deep infiltrating soft tissue lesions frequently (1). We describe a rare variant of EpS imitating a vascular neoplasm, discuss the differential diagnosis, and review

the latest relevant literatures on its tumorigenesis.

### CASE REPORT

A 31-year-old previously healthy female presented with a non-healing ulcer of three years' duration on her left thumb. Her left thumb was first burned by a hot utensil. After a week, the burn wound hardened and formed a "callus-like" lesion. Within a year, the callus ulcerated and became non-healing. She had no other local or systemic symptoms. Physical examination revealed an ulcer at the distal phalanx of her left thumb with a clean base and granulation tissue surrounding it. The phalangeal bone was visible at the ulcer floor. She did not have diabetes mellitus and the results of routine blood investigations were within normal limits. There was no documented treatment or visit to any hospital prior to this presentation. A tissue biopsy was performed and was reported as epithelioid sarcoma. Magnetic resonance imaging (MRI) of her left thumb revealed an ill-defined soft tissue mass measured 2.0 x 1.0 x 0.4 cm with cortical disruption of the distal phalangeal bone and no involvement of the interphalangeal joint. She had her left thumb amputated at the level of the metacarpo-phalangeal joint.

Macroscopic examination of the amputated left thumb revealed an ulcerated tumour at the medial volar aspect of the distal phalanx. The ulcerative tumour measured 10 x 8 x 5 mm with areas of haemorrhage. The tumour infiltrated into the muscles. Microscopic examination revealed an ulcerated tumour involving the dermis and subcutaneous tissue that also infiltrated the bone. The tumour comprised of epithelioid cells with a pseudo-granulomatous appearance due to central necrosis (Fig. 1A). At the tumour's periphery, spindle cells were more noticeable. Geographic necrosis accounted for 30% of the tumour. The malignant cells were characterized by large ovoid nuclei with vesicular chromatin and



**Figure 1:** Microscopic examination of the biopsy (A) reveals the edge of an ulcerative tumour involving the dermis and subcutaneous tissue with central necrosis and tumour cells (green arrows) palisade around it, imparts a pseudogranulomatous appearance. (haematoxylin and eosin [H&E], x20). (B) The area of pseudovascular spaces and slit-like channels lined by tumour cells. (H&E, x100). (C) Spindle to epithelioid malignant cells exhibit eosinophilic cytoplasm and form dyscohesive sheets. Red blood cells are frequently observed. (H&E, x100). Immunohistochemical studies show the tumour cells are diffusely positive for (D) cytokeratin AE1/AE3 and (E) Fli-1. (each x100). Focal tumour expression of CD34 (F) and CD31 (G) are observed. (each x100). (H) The tumour cells (green arrow) show loss of SMARCB1/INI1 expression, while the epidermis on the right shows retained nucleus staining. (x200).

prominent nucleoli. The cytoplasm was eosinophilic. There were up to 6 mitotic figures in 10 high-power fields (HPF). Pseudovascular spaces, slit-like channels lined by tumour cells, and dyscohesive sheets of tumour cell were all present. In these areas, erythrocytes were frequently seen (Fig. 1B-C). Acanthosis and parakeratosis were present adjacent to the ulcer. A moderate degree of chronic inflammation was observed. Immunohistochemical studies showed that the tumour cells were diffuse strong positive for cytokeratin AE1/AE3 (Fig. 1D), EMA, vimentin and Fli-1 (Fig. 1E). The tumour cells were focally positive for CD34 and CD31 (Fig. 1F-G). The SMARCB1/INI1 expression was loss (Fig. 1H). The final pathological diagnosis was epithelioid sarcoma of distal type, angiomatoid variant. The tumour grading by FNCLCC (Fédération Nationale des Centres de Lutte Contre le Cancer) system was grade two. Following surgery, the patient was given chemotherapy.

## DISCUSSION

We reported a young adult with left thumb epithelioid sarcoma of distal type, angiomatoid variant. Distal-type EpS typically affects the deep dermis of the distal extremities in young adults (1). About 27% of the EpS cases had a history of trauma or scarring, the majority of which were related to physical or chemical injury. Only a few case reports described EpS with burn scars (1). However, it is not restricted to these individuals and can afflict anybody, at various location (1). EpS is characterised histologically by nodules with geographic necrosis in the centre and palisade tumour cells around the necrotic regions, resulting in a zonal granulomatous appearance. The tumour cells are often large or intermediate in size with eosinophilic cytoplasm. The tumour cells may show an epithelioid, spindle, or polygonal morphology. There may be cytoplasmic vacuolation on occasion (1, 3). A rare angiomatoid variant with blood-filled clefts, slit-like channels, irregular dilated spaces lined by hobnailing tumour cells, and dyscohesive sheets of tumour cells has been described. It is typically linked with prominent areas of tumour haemorrhage and foci of blood-filled spaces (3). Several EpS immunohistochemistry investigations are found to overlap with vascular neoplasm. This includes positivity for CD34 (50-73%), CD31 (0-7%), D2-40 (71%), Fli-1 (93%), and ERG (38%) (1, 3). SMARCB1/INI1 deficiency was thought to be highly sensitive (93%) but variable in its specificity for EpS (2-4). Majority of the EpS express pan-cytokeratin and EMA (1).

Due to overlapping histological morphology and immunohistochemical profile, EpS might mimic a vascular neoplasm with epithelioid form. The differential diagnoses that need to be considered include epithelioid angiosarcoma, pseudomyogenic haemangioendothelioma, anaplastic Kaposi sarcoma and epithelioid Kaposi sarcoma. We describe the classical and currently accepted characteristics of

these differential diagnoses. Epithelioid angiosarcomas are composed of epithelioid tumour cells that grow in a diffuse sheet-like pattern with haemorrhage but no distinct vasoformative architecture (1). Epithelioid angiosarcomas can be suggested by spaces containing red blood cells with papillary projections, cytoplasmic vacuolation, or intracellular red blood cells. Pseudomyogenic haemangioendothelioma is comprised of plump spindle cells in a collagenous stroma arranged in a storiform pattern or diffuse sheets. The tumour cells are rather bland, with vesicular nuclei, variably prominent nucleoli, and conspicuous eosinophilic cytoplasm. They can sometimes appear rhabdomyoblast-like with varying neutrophilic infiltration (1). Anaplastic Kaposi sarcoma is a rare tumour that can develop after many years of initial diagnosis of Kaposi sarcoma. Anaplastic Kaposi sarcoma is characterized by dense proliferation of medium to large epithelioid cells with conspicuous nucleoli on histological examination. Typically, the pseudo-cohesive cells are arranged in sheets with cracks. This tumour is often linked with osteoarticular tissue invasion, necrosis and a higher mitotic count (5). Epithelioid Kaposi sarcoma is a newly identified morphological variant of Kaposi sarcoma. It is described as a solid tumour comprised of sheets of epithelioid cells in the dermis and subcutaneous layers. It frequently shows numerous mitotic figures and extravasated erythrocytes. Necrosis is not a characteristic of epithelioid Kaposi sarcoma. Table 1 summarises relevant immunohistochemical markers of these entities. It is crucial to distinguish EpS from other mimickers. A complete surgical excision is the preferred treatment for EpS (2). Tazemetostat, an EZH2 methyltransferase inhibitor, was recently licenced for the treatment of a subgroup of individuals with EpS but not for other sarcomas (2). The EpS recurrence rate was 63.4%, the metastasis rate was 40.3% and the 5-year overall survival rate was 55.7% (1, 2).

The histogenesis and tumorigenesis of EpS has garnered a great deal of interest. EpS has a complex genomic profile, characterised by frequent changes in DNA copy number and a high mutational burden. Considering that the SMARCB1/INI1 expression is typically absent in EpS, alteration of the SWI/SNF complex is most likely an early genetic event. (1). The *SMARCB1* gene, located on 22q11.23, encodes SMARCB1/INI1 protein

that is part of the SWI/SNF chromatin remodelling complex. The SMARCB1/INI1 protein is involved in the coordination of gene expression. It is essential for lineage determination and genomic stability (1, 4). The *SMARCB1* gene can be disrupted in EpS through a variety of mechanism, resulting in loss of SMARCB1/INI1 expression by immunohistochemistry. The mechanism includes biallelic *SMARCB1* deletions, monoallelic *SMARCB1* deletions, chromosomal rearrangements, and microRNA-mediated negative regulation of *SMARCB1* transcripts (3, 4). Once SMARCB1/INI1 protein is reduced, the enhancer of zeste homolog 2 (EZH2) protein becomes an oncogenic modifier. Overactivation of EZH2 induces histone methylation and neoplastic transformation. As a result, EZH2 inhibition with small-molecule lysine methyltransferase inhibitors is a treatment option in a subset of EpS patients (2). Aside from that, high levels of vascular endothelial growth factor (VEGF), an angiogenic factor, have been found in EpS samples (2). *FLI1*, located on 11q21 and *ERG*, located on 21q22, are members of the ETS family and are important in endothelium development (3). Although EpS often expresses most of the vascular markers, FVIIIIR and CD31 are seldom positive (1). Overexpression of Fli-1 in EpS is hypothesized to be caused by 11q copy number gains (3). The reason for other vascular markers' expression in EpS, such as ERG and D2-40, is mostly unexplained.

## CONCLUSION

EpS is a rare aggressive soft tissue sarcoma that presents a significant diagnostic and treatment challenge to doctors and patients. It is important to bring attention to EpS angiomatoid variant, which may be difficult to identify owing to the overlapping histological characteristics. Misinterpretation of this rare entity may lead to inappropriate treatment. Tumour histogenesis are multifactorial and are continuously being studied.

## REFERENCES

1. Thway K, Jones RL, Noujaim J, Fisher C. Epithelioid sarcoma: diagnostic features and genetics. *Adv Anat Pathol*. 2016;23(1):41-9. doi:10.1097/PAP.000000000000102.
2. Czarnecka AM, Sobczuk P, Kostrzanowski M,

**Table 1: Immunohistochemical markers of angiomatoid epithelioid sarcoma and its mimickers**

Diagnosis	D2-40	Fli-1	ERG	CD34	CD31	CK	EMA	HHV-8 LANA	SMARCB1/INI1
Angiomatoid epithelioid sarcoma	+	+	±*	+	-	+	+	-	-
Epithelioid angiosarcoma	+	+	+	+	+	±	-	-	±
Pseudomyogenic haemangioendothelioma	+	+	+	-	+	+	-	-	+
Anaplastic or epithelioid Kaposi sarcoma	+	+	+	+	+	-	-	+	+

CK - Cytokeratin

\* ERG N-terminus has higher positivity (68%) than ERG C-terminus (3%) in EpS.

- Spalek M, Chojnacka M, Szumera-Cieckiewicz A, et al. Epithelioid sarcoma—from genetics to clinical practice. *Cancers*. 2020;12(8):2112. doi:10.3390/cancers12082112.
3. Stockman DL, Hornick JL, Deavers MT, Lev DC, Lazar AJ, Wang WL. ERG and FLI1 protein expression in epithelioid sarcoma. *Mod Pathol*. 2014;27(4):496-501. doi: 10.1038/modpathol.2013.161.
  4. Song L, Stashek KM, Benyounes A, Davis DL, Mulligan ME, Ng VY, et al. Epithelioid sarcoma with retained INI1 (SMARCB1) expression. *Histopathology*. 2020;78(3):464-6. doi:10.1111/his.14236.
  5. Basra P, Paramo J, Alexis J. Disseminated Kaposi sarcoma with epithelioid morphology in an HIV/AIDS patient: a previously unreported variant. *J Cutan Pathol*. 2018;45(7):526-9. doi: 10.1111/cup.13254.