




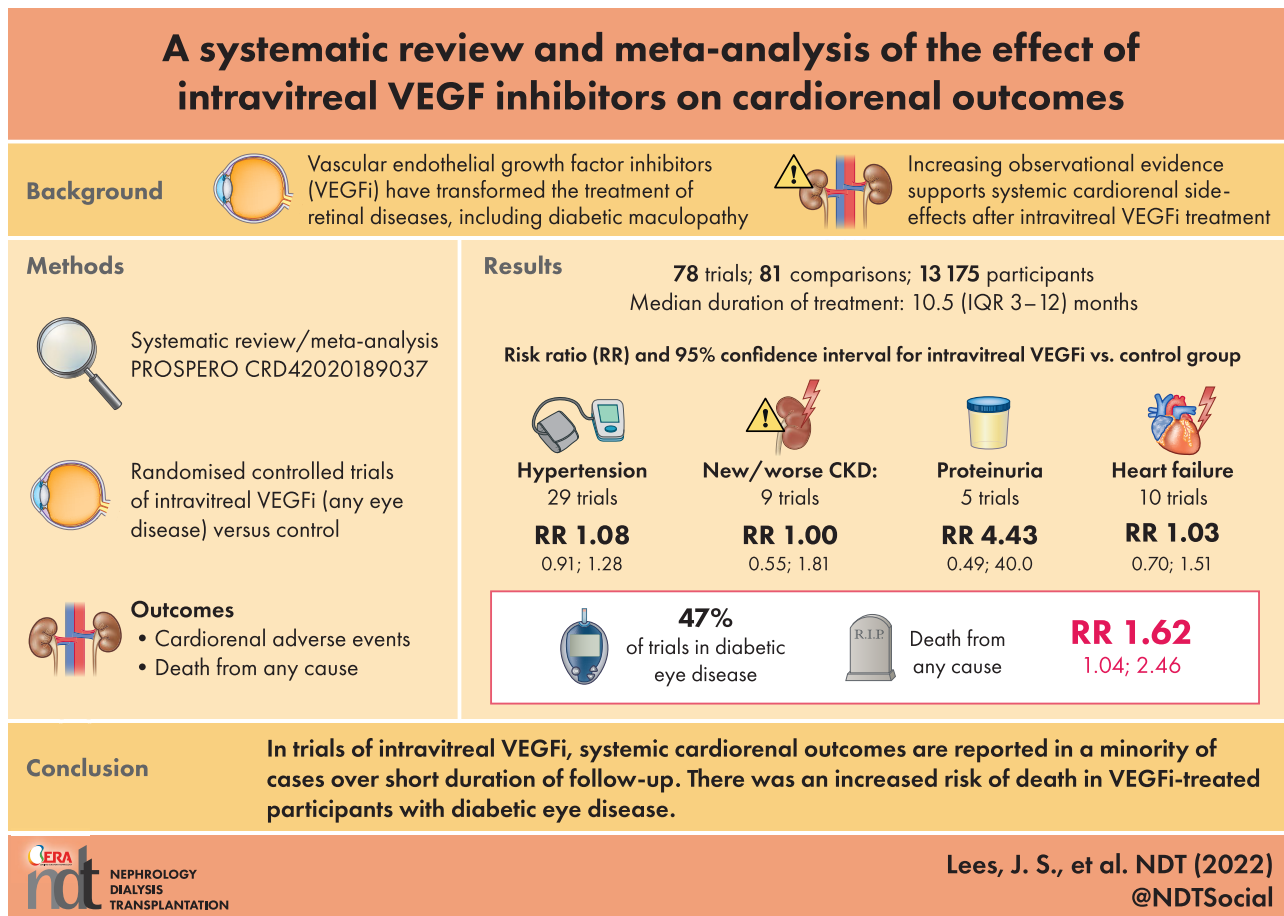
A systematic review and meta-analysis of the effect of intravitreal VEGF inhibitors on cardiorenal outcomes

Jennifer S. Lees ¹, Stephen J.H. Dobbin¹, Benjamin M.P. Elyan¹, David F. Gilmour², Laurie P. Tomlinson ³, Ninian N. Lang¹ and Patrick B. Mark ¹

¹School of Cardiovascular and Metabolic Health, College of Medical and Veterinary Sciences, University of Glasgow, Glasgow, UK, ²Glasgow Centre for Ophthalmic Research, NHS Greater Glasgow and Clyde, Glasgow, UK and ³Faculty of Epidemiology and Population Health, London School of Hygiene and Tropical Medicine, London, UK

Correspondence to: Jennifer S. Lees; E-mail: jennifer.lees@glasgow.ac.uk; Twitter:  [jennifer_s_lees](https://twitter.com/jennifer_s_lees)

GRAPHICAL ABSTRACT



ABSTRACT

Background. Vascular endothelial growth factor inhibitors (VEGF_i) have transformed the treatment of many retinal diseases, including diabetic maculopathy. Increasing evidence

supports systemic absorption of intravitreal VEGF_i and development of significant cardiorenal side effects.

Methods. We conducted a systematic review and meta-analysis (PROSPERO: CRD42020189037) of randomised controlled trials of intravitreal VEGF_i treatments (bevacizumab,

KEY LEARNING POINTS

What is already known about this subject?

- Intravitreal vascular endothelial growth factor inhibitors (VEGFis) are commonly used in the treatment of diabetic eye disease.
- There is increasing evidence of systemic absorption of intravitreal VEGFi associated with exacerbation of cardiorenal side effects such as hypertension, proteinuria, decline in kidney function and heart failure.

What this study adds?

- Trials of intravitreal VEGFi do not routinely report cardiorenal side effects, although mechanistically these side effects are plausible, especially in patients with diabetes and pre-existing kidney disease.
- In patients with diabetic eye disease (who commonly also have kidney disease), treatment with intravitreal VEGFi is associated with an increased risk of death, with potential implications for obtaining informed consent.

What impact this may have on practice or policy?

- Additional scrutiny of post-licensing observational data may improve recognition of safety concerns in VEGFi-treated patients.
- Monitoring for cardiorenal side effects should be considered, especially in high-risk patients with diabetes and kidney disease who are treated with intravitreal VEGFi.

ranibizumab and aflibercept) for any eye disease. Outcomes of interest were cardiorenal side effects (hypertension, proteinuria, kidney function decline and heart failure). Fixed effects meta-analyses were conducted where possible.

Results. There were 78 trials (81 comparisons; 13 175 participants) that met the criteria for inclusion: 47% were trials in diabetic eye disease. Hypertension (29 trials; 8570 participants) was equally common in VEGFi and control groups {7.3 versus 5.4%; relative risk [RR] 1.08 [95% confidence interval (CI) 0.91–1.28]}. New or worsening heart failure (10 trials; 3384 participants) had a similar incidence in VEGFi and control groups [RR 1.03 (95% CI 0.70–1.51)]. Proteinuria (5 trials; 1902 participants) was detectable in some VEGFi-treated participants (0.2%) but not controls [0.0%; RR 4.43 (95% CI 0.49–40.0)]. Kidney function decline (9 trials; 3471 participants) was similar in VEGFi and control groups. In participants with diabetic eye disease, the risk of all-cause mortality was higher in VEGFi-treated participants [RR 1.62 (95% CI 1.04–2.46)].

Conclusion. In trials of intravitreal VEGFi, we did not identify an increased risk of cardiorenal outcomes, although these outcomes were reported in only a minority of cases. There was an increased risk of death in VEGFi-treated participants with diabetic eye disease. Additional scrutiny of post-licensing observational data may improve the recognition of safety concerns in VEGFi-treated patients.

Keywords: CKD, diabetes mellitus, hypertension, proteinuria, systematic review

INTRODUCTION

Vascular endothelial growth factor inhibitors (VEGFis) have transformed the treatment of many retinal diseases [1] but are most commonly used in the management of diabetic macular oedema (DME) [2], neovascular age-related macular degeneration (nAMD) [3] and retinal vein occlusion [4]. The VEGFi ranibizumab (Lucentis, Novartis UK, London, UK) and aflibercept (Eylea, Regeneron Pharmaceuticals, Tarrytown,

NY, USA) were specifically designed for intravitreal treatment. Bevacizumab (Avastin, Genentech, South San Francisco, CA, USA) was originally developed for systemic administration in the treatment of various cancers but is used extensively off-label across the globe (less so in the UK) for retinal disease because of the significant cost savings associated with using a more established treatment. Brolucizumab (Beovu, Novartis UK) is also licenced by the US Food and Drug Administration (2019) and the European Medicines Agency (2020) after landmark studies showed efficacy for the treatment of nAMD and DME. Due to its more recent marketing authorisation, brolucizumab is not considered further in this review.

A treatment course of intravitreal VEGFi typically consists of a loading phase of monthly injections over 2–4 months followed by an extension phase based on the treatment response. These treatments are commonly used in patients with diabetes: ≈50% of patients with type 1 diabetes and >25% of patients with type 2 diabetes have evidence of diabetic retinopathy [5]. Although only 2–4% of patients with diabetes require ophthalmic treatment, the absolute number of people with any diabetic eye disease is forecast to increase in Europe from 6.4 million to 8.6 million in 2050, which will substantially increase the number of patients eligible for intravitreal VEGFi treatment [6].

In the case of bevacizumab, intravitreal VEGFi is administered at <15% of the intravenous dose and was previously thought to exert predominantly local effects within the eye [7]; however, increasing evidence supports pronounced systemic absorption [8]. In 56 patients with age-related macular degeneration, intravitreal administrations of ranibizumab, aflibercept and bevacizumab were all rapidly detectable in the circulation [9]. Ranibizumab (48-kDa monoclonal antibody fragment) was cleared relatively quickly (within days), but aflibercept (115-kDa fusion protein) and bevacizumab (149-kDa full-length monoclonal antibody) accumulated over repeated doses and suppressed free plasma VEGF [9] for at least 7 days [9] and up to 30 days after intravitreal injection [10]. In 82 patients with nAMD, intravitreal administration of

bevacizumab was associated with both *de novo* blood pressure (BP) dysregulation and exacerbation of pre-existing hypertension [11], although this has not been a consistent finding in all studies nor for all intravitreal VEGFi treatments [12]. Systemic VEGFi, when used primarily as an anticancer therapy, is almost universally associated with the development or exacerbation of hypertension [13]. Hypertension and endothelial damage associated with VEGFi are associated with end-organ damage, including heart failure [14], nephropathy and kidney failure [13]. Caution is advised in administering systemic VEGFi in patients with pre-existing hypertension, proteinuria, cardiovascular disease and severe kidney impairment, and monitoring for hypertension, proteinuria and heart failure is recommended [15]. No such monitoring recommendations exist for intravitreal VEGFi administration.

Particularly in patients with diabetes—already at a higher risk of end-organ damage—the potential for systemic absorption of intraocular therapies and accelerated albuminuria, heart failure and progression to end-stage kidney disease is a major concern. The cardiorenal side effects of intravitreal VEGFis may be identifiable from initial trials: any cardiorenal safety signal seen in these groups should highlight the need for greater vigilance in patients receiving VEGFi, either systemically for cancer or locally for ophthalmological indications.

The aims of this review were to identify the prevalence of cardiorenal side effects after intravitreal administration of VEGFi and to identify factors associated with cardiorenal side effects after intravitreal VEGFi administration.

MATERIALS AND METHODS

This review was prospectively registered on PROSPERO (CRD42020189037) and reported according to the Preferred Reporting Items for Systematic Reviews and Meta-Analyses (PRISMA) methodology. PICOS (Population, Intervention, Comparison, Outcome, Setting) criteria for inclusion are detailed in Table 1.

Types of studies

Randomised controlled trials that report outcomes in those receiving intravitreal VEGFi treatments versus control groups [no treatment/sham or non-VEGFi treatment (e.g. laser photocoagulation)] were eligible for inclusion. We included trials that administered a minimum of two intravitreal injections of VEGFi with follow-up for at least 4 weeks with a minimum of 20 participants.

Types of participants

Participants receiving VEGFi treatment for any eye disease, with any baseline level of eye disease, cardiovascular disease and kidney function, were eligible for inclusion. The following was recorded for all eligible studies: VEGFi type, number of injections (intended or mean administered dose), duration of VEGFi treatment and duration of follow-up. We intended to record baseline demographics for the included populations: sex, age, ethnicity, kidney function [estimated

Table 1: PICOS criteria for study inclusion.

Population	Any maculopathy Any baseline level of eye disease, cardiovascular disease and kidney function
Intervention	Intravitreal VEGF inhibitor, with a minimum of two injections: Bevacizumab Ranibizumab Aflibercept
Comparison	Control group No treatment Sham treatment Non-VEGFi treatment, e.g. laser photocoagulation
Outcomes	Cardiorenal outcomes: Hypertension Proteinuria New or worsening heart failure Heart failure hospitalisation New CKD (<i>de novo</i> reduction in eGFR to <60 ml/min/1.73 m ²) Decrease in eGFR by ≥30% Doubling serum creatinine Need for dialysis or transplant eGFR slope Arterial thrombotic cardiovascular events: MI, stroke, peripheral arterial disease Venous thromboembolism: pulmonary embolus, deep vein thrombosis Death from cardiovascular cause (MI, stroke, HF) Death from kidney failure All-cause mortality
Setting	Randomised controlled trials

glomerular filtration rate (eGFR)], BP, urinary protein content (spot urinary protein:creatinine ratio or albumin:creatinine ratio or 24-h urine protein:albumin ratio), hypertension (or prescription of antihypertensive medications), diabetes (%) and cardiovascular disease, including coronary artery disease, myocardial infarction (MI), stroke, peripheral arterial disease (%) and heart failure (%) and severity [ejection fraction (EF)] if available.

Types of interventions

We examined the following VEGFis delivered as intravitreal injections with a minimum of two injections, assuming there were follow-up data available at least 4 weeks after the interventions started: bevacizumab, ranibizumab and aflibercept.

Outcome measures

We extracted data on the following outcome measures, where available: hypertension, proteinuria, new or worsening heart failure, heart failure hospitalisation, new CKD (defined as *de novo* reduction in eGFR to <60 ml/min/1.73 m²), a decrease in eGFR by ≥30%, doubling of serum creatinine, need for dialysis or transplant, eGFR slope, arterial thrombotic cardiovascular events (MI, stroke, peripheral arterial disease), venous thromboembolism (pulmonary embolus, deep vein thrombosis), all-cause mortality, death from a cardiovascular cause (MI, stroke, heart failure) and death from kidney failure.

Search strategy

The search period spanned 1966 to the end of May 2020. We searched PubMed, Cochrane Library (CENTRAL), Google (for grey literature) and the ISRCTN registry (for ongoing studies) for relevant studies. Hand searching was performed, including references of included articles and references from previous reviews of intravitreal VEGFi therapy. No language restriction was applied to eligible reports (although there were no identified reports that were not published in English). Abstracts were eligible for inclusion if relevant data were available (although no studies were included in abstract-only form).

Search terms

We used the following search terms to identify eligible reports: (vascular endothelial growth factor OR VEGF OR bevacizumab OR ranibizumab OR aflibercept) AND (intravitreal OR intraocular) AND (clinical trial OR randomized controlled trial).

Review methods

All possible randomised controlled trials were identified independently by two researchers (J.S.L. and S.J.H.D.) and entered into Mendeley Reference Manager software. Two researchers independently assessed titles and abstracts of all possible relevant studies. When eligibility was not clear from the title and/or abstract, the full article was reviewed. Differences were resolved by discussion between the two researchers. Data were abstracted by two researchers (J.S.L. and S.J.H.D.) using a pre-specified form. Where available, the trial registration identifier (from clinical trial registries) was extracted to identify repeat publications for each trial. The first relevant trial publication was included, as this tended to contain the most complete baseline demographic information. We performed an exploratory search using the trial identifier from each included trial to perform a targeted search for later trial publications with the maximum published duration of follow-up that also reported cardiorenal outcomes.

Statistical analysis

We conducted frequentist meta-analysis to report risk ratios (RRs) and 95% confidence intervals (CIs) using fixed effects models, stratified for VEGFi type, where adequate data were available for outcomes of interest. Weights were assigned by the inverse variance method. Statistical heterogeneity was assessed using I^2 ($\geq 50\%$ was considered to represent significant heterogeneity) and τ^2 (as an estimate of between-study heterogeneity; a lower value suggests lower between-study heterogeneity). Meta-regression models were used to assess potential sources of heterogeneity, including VEGFi type, number of injections, duration of treatment and treated eye disease (diabetic versus non-diabetic indication). Variables accounting for heterogeneity among studies were identified if their inclusion in the model resulted in a significant reduction in τ^2 . Meta-regression identified treated eye disease (diabetic

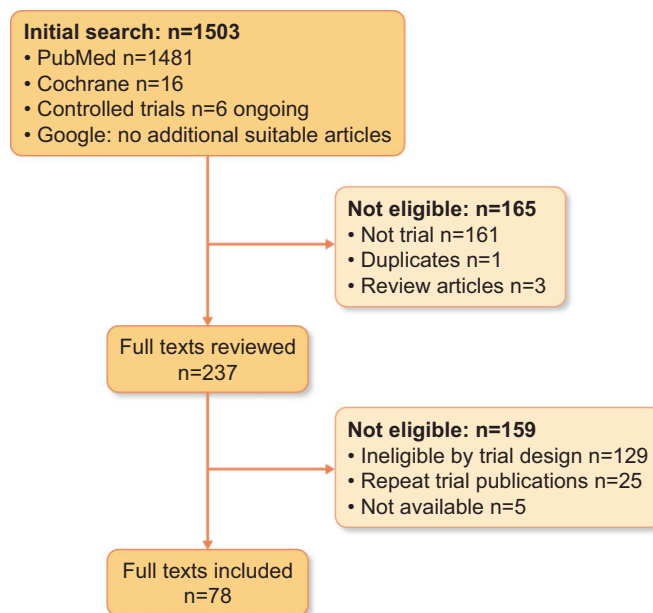


Figure 1: Flow chart of included studies and reasons for exclusion.

versus non-diabetic) as a significant source of heterogeneity for death outcome: forest plots were generated for all cardiorenal outcomes and were stratified by diabetic versus non-diabetic eye disease. Evidence of publication bias was sought by visual inspection of funnel plots and trim-and-fill analysis.

RESULTS

Trial characteristics

Of 1503 articles identified on systematic searching, there were 78 eligible full texts containing 81 comparisons in 13 175 participants (Fig. 1). There were 31 comparisons of intravitreal bevacizumab {mean 4.0 injections [standard deviation (SD) 2.4]}, 44 comparisons of intravitreal ranibizumab [mean 8.3 injections (SD 6.3)] and 6 comparisons of intravitreal aflibercept [mean 7.2 injections (SD 1.6)]. The median duration of treatment was 10.5 months [interquartile range (IQR) 3–12] and the median duration of follow-up was 12 months (IQR 6–12) (Table 2).

There were 37 trials performed for diabetic indications (27 diabetic macular oedema and 10 proliferative diabetic nephropathy), 11 trials for nAMD, 23 for retinal vein occlusion and 10 for other indications (most commonly for neovascular glaucoma or polypoidal choroidal vasculopathy; Table 2). In the 44 trials conducted for non-diabetic indications, the presence or absence of diabetes at baseline was recorded in 7 trials (15.9%).

Across all trials, there was a male preponderance of 55.3% and the mean age was 63 years (SD 8). Ethnicity was recorded in 58.0% of studies; of these, 80.9% of trials had a Caucasian majority.

Baseline comorbidities

Baseline BP or a history of hypertension was recorded in nine trials (11.0%; 1690 participants), unspecified

Table 2: Characteristics of included trials.

Author	Year	Trial ID	Country	Eye disease	Men (%)	Age (years), mean	Treatment, n	Controls, n	VEGFi type	Injections (n), mean	Duration of treatment (months)	Duration of follow-up (months)
Abraham <i>et al.</i> [39]	2010	NCT0090623	USA	nAMD	40.2	78.4	121	63	Ranibizumab	10	24	24
Arceiri <i>et al.</i> [40]	2015	ACTRN12607000577415	Brazil	Neovascular glaucoma	60.0	60.8	20	20	Bevacizumab	3	2	24
Bae <i>et al.</i> [41]	2014	NCT01325181	Korea	Chronic central serous chorioretinopathy	82.4	50.8	16	18	Ranibizumab	3	2	12
Baker <i>et al.</i> [42]	2019	NCT01909791	USA	Diabetic macular oedema	62.3	59	226	476	Aflibercept	8.3	24	24
Bandello <i>et al.</i> [43]	2018	NCT01427751	Italy	Branch retinal vein occlusion	58.3	67	153	154	Ranibizumab	8	12	12
Bashshur <i>et al.</i> [44]	2007	NR	Lebanon	nAMD	50.0	75	32	30	Bevacizumab	2.4	6	6
Beaulieu <i>et al.</i> [45]	2016	NCT01489189	USA	Proliferative diabetic retinopathy	56.0	53.5	102	114	Ranibizumab	10	24	24
Berger <i>et al.</i> [46]	2015	NCT01135914	Canada	Diabetic macular oedema	60.0	61.7	148	72	Ranibizumab	9	12	12
Bhavsar <i>et al.</i> [47]	2014	NCT00996437	USA	Proliferative diabetic retinopathy	48.0	58	125	136	Ranibizumab	3	2	4
Bhayana <i>et al.</i> [48]	2015	NR	India	Diabetic macular oedema	40.0	57.7	12	18	Bevacizumab	2.6	6	6
Boyer <i>et al.</i> [49]	2012	NCT00943072	International	Central retinal vein occlusion	57.0	66.3	114	74	Aflibercept	6	6	12
Brown <i>et al.</i> [50]	2006	NCT00061594	USA	nAMD	48.7	77	280	143	Ranibizumab	11	12	12
Brown <i>et al.</i> [51]	2010	NCT00485836	USA	Central retinal vein occlusion	57.0	68	132	130	Ranibizumab	5.7	6	6
Brown <i>et al.</i> [51]	2010	NCT00485836	USA	Central retinal vein occlusion	57.0	68	130	130	Ranibizumab	5.7	6	6
Brown <i>et al.</i> [52]	2011	NCT00486018	USA	Branch retinal vein occlusion	44.8	77.7	140	143	Ranibizumab	5.7	6	12
Brown <i>et al.</i> [53]	2009	NR	International	nAMD	44.8	77.7	140	143	Ranibizumab	22	24	24
Callanan <i>et al.</i> [54]	2017	NCT01492400	USA	Diabetic macular oedema	62.8	63.6	182	181	Ranibizumab	8.7	12	12
Campo Chiaro <i>et al.</i> [55]	2016	NCT02050828	USA	Diabetic macular oedema	59.0	61.3	48	46	Ranibizumab	3	3	3
Chelala <i>et al.</i> [56]	2018	NR	Lebanon	Proliferative diabetic retinopathy	53.4	68.6	71	62	Ranibizumab	3.7	4	4
Comyn <i>et al.</i> [57]	2014	NCT01223612	UK	Diabetic macular oedema	63.6	57.7	22	11	Ranibizumab	9	12	12
Ding <i>et al.</i> [58]	2011	NR	China	Central retinal vein occlusion	54.8	54.6	16	16	Bevacizumab	2.4	9	9
Elman <i>et al.</i> [59]	2010	NCT00445003	USA	Diabetic macular oedema	56.0	63	375	479	Ranibizumab	9	12	24
Epstein <i>et al.</i> [60]	2012	NCT00906685	Sweden	Central retinal vein occlusion	60.0	70.5	30	30	Bevacizumab	4	6	6
Ferraz <i>et al.</i> [61]	2015	NCT01746563	Brazil	Proliferative diabetic retinopathy	46.4	52.6	14	15	Ranibizumab	2	1	6
Figueira <i>et al.</i> [62]	2016	NCT01280929	Portugal	Proliferative diabetic retinopathy	74.3	57	22	13	Ranibizumab	5	12	12
Figueira <i>et al.</i> [63]	2018	NCT01941329	International	Proliferative diabetic retinopathy	63.0	55.2	41	46	Bevacizumab	3	3	12
Gado and Macky [64]	2014	OzuBevaCRVOME-1	Egypt	Central retinal vein occlusion	66.6	68.8	30	30	Bevacizumab	4.3	6	6
Gale <i>et al.</i> [65]	2018	NCT01994291	International	Diabetic macular oedema	62.1	62.3	99	99	Ranibizumab	3	3	4
Gross <i>et al.</i> [66]	2018	NCT01489189	USA	Proliferative diabetic retinopathy	56.0	52	191	203	Ranibizumab	19.2	60	60
Hattenbach <i>et al.</i> [67]	2018	NCT01396057	Germany	Branch retinal vein occlusion	32.5	78.5	19	21	Ranibizumab	4.71	6	6
Hatz <i>et al.</i> [68]	2015	NCT00429962	Switzerland	nAMD	46.9	74.1	106	56	Ranibizumab	3	1	12
Heier <i>et al.</i> [69]	2006	NCT00056823	USA	nAMD	46.9	74.1	106	56	Ranibizumab	24	24	24
Higashiyama <i>et al.</i> [70]	2013	UMIN000001546	Japan	Branch retinal vein occlusion	39.5	68.4	22	21	Bevacizumab	2.2	12	12

Table 2: Continued.

Author	Year	Trial ID	Country	Eye disease	Men (%)	Age (years), mean	Treatment, n	Controls, n	VEGFi type	Injections (n), mean	Duration of treatment (months)	Duration of follow-up (months)
Hoerauf <i>et al.</i> [71]	2016	NCT01396083	Germany	Central retinal vein occlusion	59.7	66.1	124	119	Ranibizumab	4.52	6	6
Ishibashi <i>et al.</i> [72]	2015	NCT00989989	International	Diabetic macular oedema	54.0	61.4	132	131	Ranibizumab	7	12	12
Karadzic <i>et al.</i> [73]	2015	NR	Serbia	Branch retinal vein occlusion	60.0	60.5	11	9	Bevacizumab	2	3	3
Kinge <i>et al.</i> [74]	2010	NCT00567697	Norway	Central retinal vein occlusion	55.1	72	15	14	Ranibizumab	4.3	6	6
Koh <i>et al.</i> [75]	2012	NCT00674323	International	Polyoidal choroidal vasculopathy	65.0	63	19	21	Ranibizumab	3.9	6	6
Korobelnik <i>et al.</i> [76]	2014	NCT01331681	International	Diabetic macular oedema	62.2	64.1	135	132	Aflibercept	8	12	12
Korobelnik <i>et al.</i> [76]	2014	NCT01363440	USA	Diabetic macular oedema	53.4	62.4	151	154	Aflibercept	8	12	12
Kriechbaum [77]	2014	NR	Austria	Diabetic macular oedema	40.0	59	15	15	Bevacizumab	9	12	12
Kumar <i>et al.</i> [78]	2019	NR	India	Branch retinal vein occlusion	51.7	56.2	15	45	Ranibizumab	3	3	6
Lai <i>et al.</i> [79]	2018	NCT03459144	China	Polyoidal choroidal vasculopathy	63.1	62	34	23	Ranibizumab	3	12	12
Lang <i>et al.</i> [80]	2018	NCT01131585	Germany	Diabetic macular oedema	62.5	63.5	85	43	Ranibizumab	5	12	12
Li <i>et al.</i> [81]	2019	NCT02259088	China	Diabetic macular oedema	46.4	58.7	307	77	Ranibizumab	7.9	12	12
Lim <i>et al.</i> [82]	2016	ACTRN12611000888965	Australia	Diabetic macular oedema	73.2	66.4	17	24	Bevacizumab	2.71	6	6
Lucaito <i>et al.</i> [83]	2017	NR	Brazil	Central retinal vein occlusion	60.0	59.5	14	21	Bevacizumab	NR	12	12
Massin <i>et al.</i> [84]	2010	NCT00284050	France	Diabetic macular oedema	53.6	64	102	49	Ranibizumab	10.2	12	12
Mitchell <i>et al.</i> [85]	2011	NCT00687804	Australia	Diabetic macular oedema	58.2	63.5	234	111	Ranibizumab	7	12	12
Moradian <i>et al.</i> [86]	2011	NCT00370851	Iran	Branch retinal vein occlusion	41.9	57.6	42	39	Bevacizumab	2	2	3
Motta <i>et al.</i> [87]	2019	NCT02308644	Italy	Diabetic macular oedema	48.8	61.8	20	21	Bevacizumab	2	2	3
Nguyen <i>et al.</i> [88]	2012	NCT00473330	USA	Diabetic macular oedema	57.3	62.7	252	130	Ranibizumab	21.2	24	24
Nguyen <i>et al.</i> [88]	2012	NCT00473382	USA	Diabetic macular oedema	56.2	62.1	250	127	Ranibizumab	21.2	24	24
Nguyen <i>et al.</i> [89]	2019	NCT02302079	USA	Diabetic macular oedema	50.0	61.5	64	32	Ranibizumab	4	3	6
Ogura <i>et al.</i> [90]	2014	NCT01012973	Japan	Central retinal vein occlusion	55.6	61.5	106	71	Aflibercept	8.5	12	18
Parodi <i>et al.</i> [91]	2012	NCT01327222	Italy	Juxtafoveal choroidal neovascularisation	38.1	71.5	11	10	Bevacizumab	NR	6	6
Parodi <i>et al.</i> [92]	2010	NR	Italy	nAMD	31.5	47.9	19	35	Bevacizumab	3.8	24	24
Parodi <i>et al.</i> [93]	2015	UMIN000005014	Italy	Branch retinal vein occlusion	100.0	66.8	17	18	Bevacizumab	6	12	12
Patwardhan <i>et al.</i> [94]	2011	NR	India	Vitreous haemorrhage	100.0	26	10	10	Bevacizumab	NR	3	3
Pielen <i>et al.</i> [95]	2015	NCT00562406	Germany	Branch retinal vein occlusion	50.0	66.3	20	10	Ranibizumab	3	3	6
Preti <i>et al.</i> [96]	2013	NCT01389505	Brazil	Proliferative diabetic retinopathy	66.6	56	35	35	Bevacizumab	2	1	6
Raizada <i>et al.</i> [97]	2015	NR	Kuwait	Diabetic macular oedema	53.9	53.9	22	22	Bevacizumab	3	3	3
Rajendram <i>et al.</i> [98]	2012	2007-000847-89	UK	Diabetic macular oedema	68.8	64.2	42	38	Bevacizumab	3	3	24

Table 2: Continued.

Author	Year	Trial ID	Country	Eye disease	Men (%)	Age (years), mean	Treatment, n	Controls, n	VEGFi type	Injections (n), mean	Duration of treatment (months)	Duration of follow-up (months)
Ramezani <i>et al.</i> [99]	2012	NCT01178697	Iran	Central retinal vein occlusion	55.0	60	50	32	Bevacizumab	11.3	12	12
Rodrigues <i>et al.</i> [100]	2020	NCT02985619	Brazil	Diabetic macular oedema	41.5	62.4	478	238	Ranibizumab	24	24	24
Rosenfeld <i>et al.</i> [101]	2006	NCT00056836	USA	nAMD	35.2	77	26	11	Ranibizumab	5.9	6	6
Rouvas <i>et al.</i> [102]	2009	NR	Greece	Retinal angiomatous proliferation	37.0	77	19	11	Ranibizumab	6	12	12
Rouvas <i>et al.</i> [103]	2011	NR	Greece	Polypoidal choroidal vasculopathy	43.3	67	14	14	Bevacizumab	6.8	12	12
Sacu <i>et al.</i> [104]	2009	2005-003288-21	Austria	nAMD	32.1	78	25	25	Bevacizumab	3	3	4
Sameen <i>et al.</i> [105]	2017	NR	Pakistan	Proliferative diabetic retinopathy	73.0	56.6	68	19	Bevacizumab	2	2	3
Scott <i>et al.</i> [106]	2007	NCT00336323	USA	Diabetic macular oedema	61.0	65	73	62	Ranibizumab	5	12	12
Seibel <i>et al.</i> [107]	2020	2011-004463-69	Germany	Radiation retinopathy	81.0	67	23	27	Bevacizumab	7	6	7
Shah <i>et al.</i> [108]	2016	NR	USA	Diabetic macular oedema	50.0	63.2	116	116	Aflibercept	4.4	12	12
Sivaprasad <i>et al.</i> [109]	2017	ISRCTN32207582	UK	Proliferative diabetic retinopathy	66.8	51.2	51	50	Bevacizumab	2.6	24	24
Sohellian <i>et al.</i> [110]	2012	NCT00370669	Iran	Diabetic macular oedema	50.7	61	363	13	Ranibizumab	11	24	24
Tadayoni <i>et al.</i> [111]	2017	NCT01599650	France	Branch retinal vein occlusion	50.4	66.1	429	13	Ranibizumab	11	24	24
Tadayoni <i>et al.</i> [111]	2017	NCT01599650	France	Branch retinal vein occlusion	59.7	66.3	15	21	Ranibizumab	NR	12	12
Tan <i>et al.</i> [112]	2014	ACTRN12607000262404	Australia	Branch retinal vein occlusion	47.2	67.9	65	66	Bevacizumab	7.1	12	12
Tufail <i>et al.</i> [113]	2010	ISRCTN83325075	UK	nAMD	59.5	81	14	14	Bevacizumab	4.5	6	6
Weigert <i>et al.</i> [114]	2008	NR	Switzerland	nAMD	32.1	78	14	12	Bevacizumab	3	3	6
Yazdani <i>et al.</i> [115]	2009	NR	Iran	Neovascular glaucoma	80.7	60	121	63	Ranibizumab	10	24	24

NR: not reported.

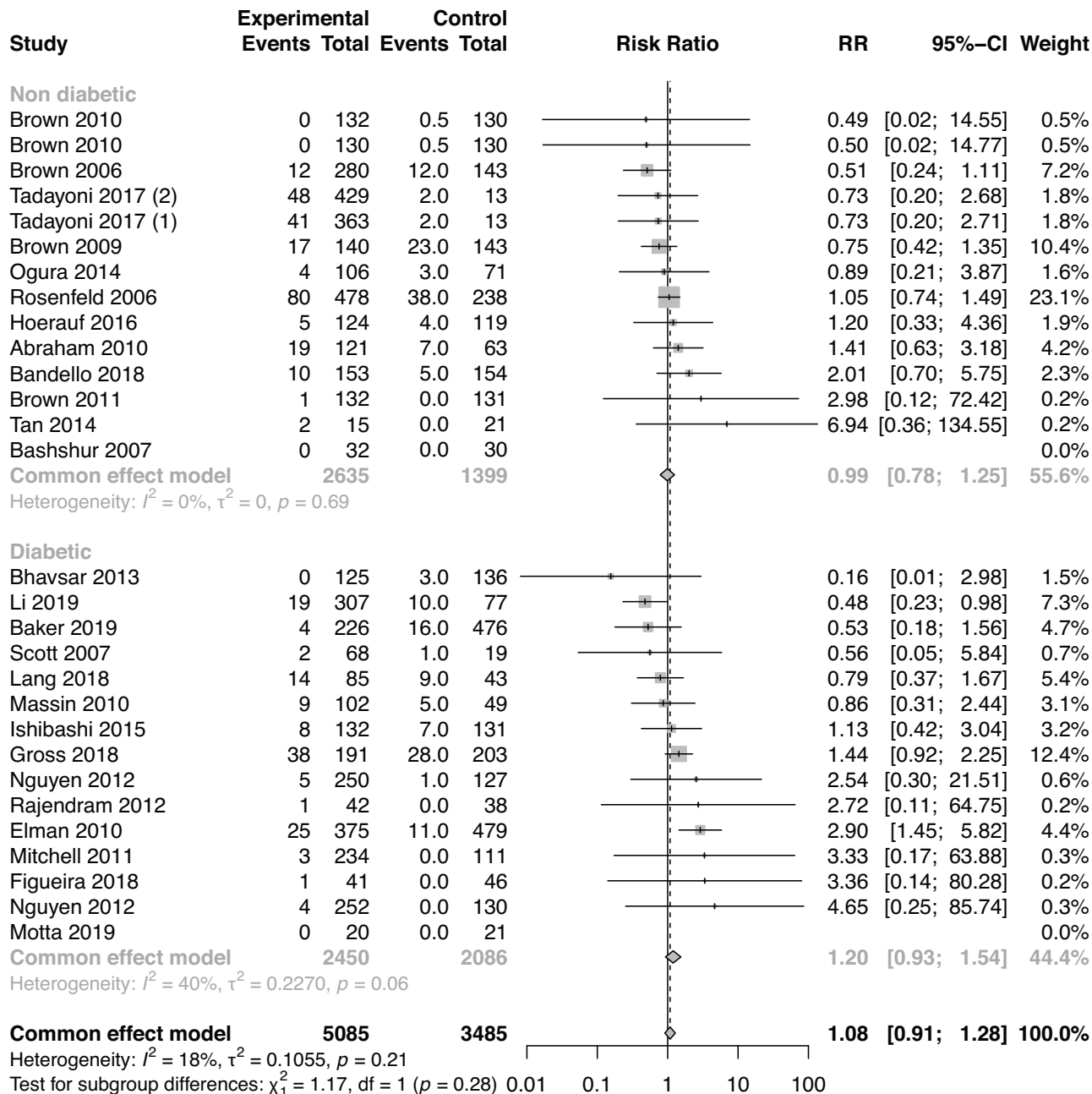


Figure 2: Forest plot of RRs for hypertension: frequentist meta-analysis using fixed and random effects models, stratified by diabetic versus non-diabetic eye disease.

cardiovascular disease in two trials (2.4%; 1115 participants) trials, previous MI or stroke in one trial (1.2%; 702 participants) and eGFR in one trial (1.2%; 41 participants: Table 2). Baseline proteinuria or a history of heart failure was not reported in any trial.

Cardiorenal outcomes

Cardiorenal outcomes were reported in only a minority of trials. Of these, hypertension was recorded most often in 29 trials (35.4%; 8570 participants). Hypertension was not more common in those treated with VEGFi versus controls [7.3 versus 5.4%; RR 1.08 (95% CI 0.91–1.28), $P = .369$; Fig. 2].

New or worsening heart failure was recorded in 10 trials (12.2%; 3384 participants), with an incidence of 2.8% versus 3.2% in VEGFi-treated patients and controls, respectively [RR 1.03 (95% CI 0.70–1.51), $P = .894$; Fig. 3A]; proteinuria was recorded in 5 trials (6.1%; 1902 participants) and was detectable in some VEGFi-treated participants (0.2%) but not controls [0.0%; RR 4.43 (95% CI 0.49–40.0), $P = .185$; Fig. 3B]. *De novo* CKD or nephropathy was recorded in nine trials (11.0%; 3471 participants), with a similar proportion in the VEGFi (1.8%) versus control groups [1.4%; RR 1.00 (95% CI 0.55–1.81), $P = 1.00$; Fig. 3C]; however, absolute values of eGFR were not recorded in any trial. Meta-regression analyses did not identify any variation in heterogeneity according to

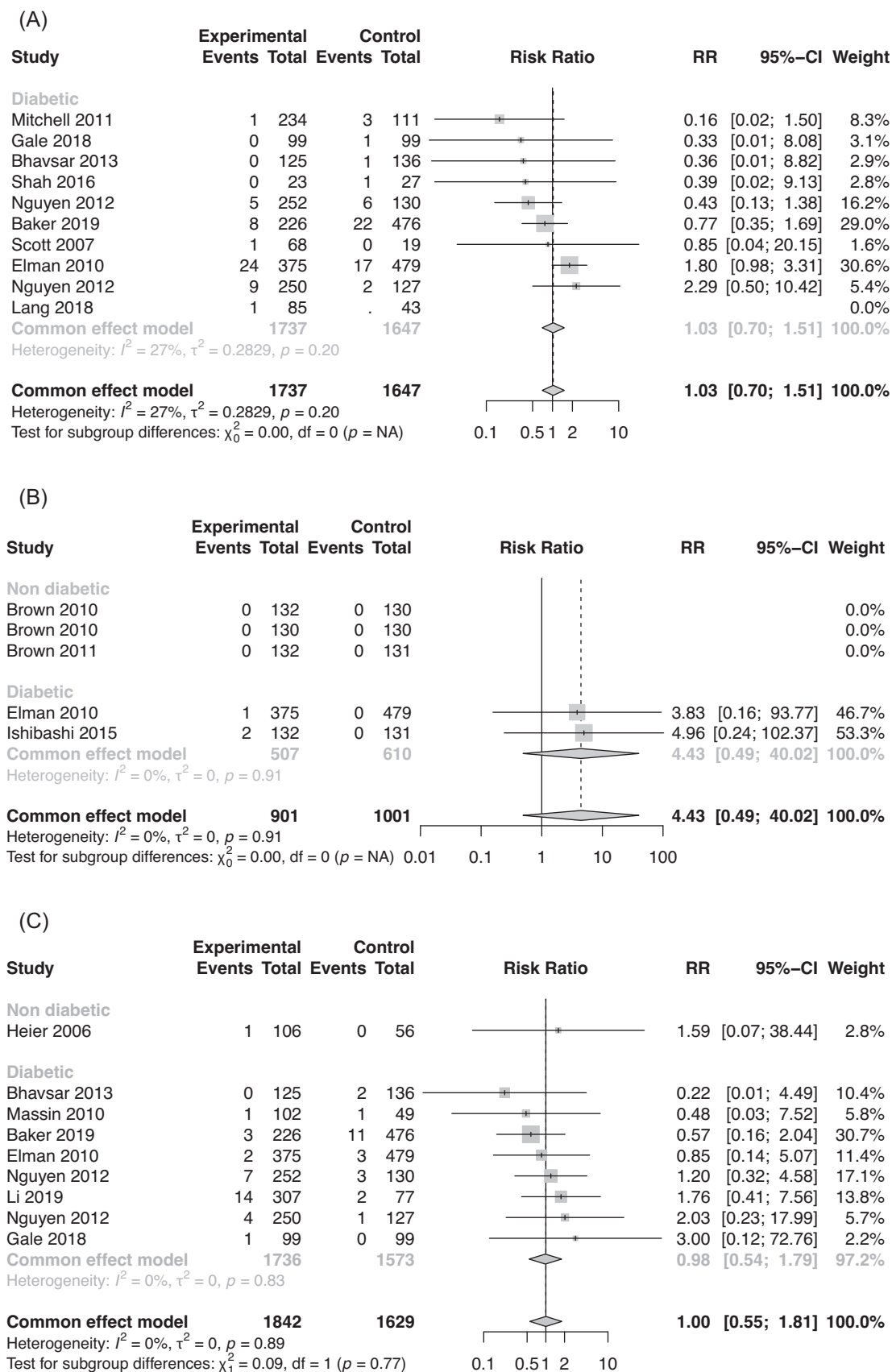


Figure 3: Forest plot of RRs for (A) heart failure, (B) proteinuria and (C) CKD: frequentist meta-analysis using fixed and random effects models, only recorded in trials of diabetic eye disease.

VEGF_i subtype, number of injections, duration of treatment or eye disease treated (Supplementary Table S1). Funnel plots and trim-and-fill analyses did not detect any substantial evidence of publication bias for any of the outcomes (although the proteinuria outcome was not tested due to insufficient data; Supplementary Figs. S2–S4).

Arterial thrombotic cardiovascular events and death

In 39 comparisons (48.1%) including 10 133 participants, the absolute incidence of arterial thrombotic cardiovascular events (MI, stroke and peripheral arterial disease) was similar in the VEGF_i-treated groups compared with controls [3.2 versus 3.0%, respectively; RR 1.19 (95% CI 0.95–1.48), $P = .122$; Supplementary Fig. S1]. In 41 comparisons (50.6%; 9877 participants), the rate of all-cause mortality was similar in the VEGF_i and control groups [1.6 versus 1.3%; RR 1.24 (95% CI 0.89–1.73), $P = .198$]. Meta-regression analysis identified an increased risk of death in patients treated for diabetic eye disease (Supplementary Table S1 and Supplementary Fig. S5). In the subgroup of participants treated for diabetic eye disease, the rate of all-cause mortality was higher in the VEGF_i-treated group [RR 1.62 (95% CI 1.04–2.46), $P = .020$; Fig. 4]. Funnel plots and trim-and-fill analyses did not detect any substantial evidence of publication bias for cardiovascular event (Supplementary Fig. S6) or all-cause mortality models (Supplementary Fig. S7).

Longer follow-up studies

Three studies were identified as constituting extended follow-up from initial trials and reporting cardiorenal adverse events or death [16–18]. Of these, none were suitable for additional analysis: two were excluded, as all treatment groups were eligible to receive intravitreal VEGF_i [17, 19] and one was excluded because it reported total systemic adverse events per group without quantifying cardiorenal events and/or death [18].

DISCUSSION

We have not identified an increased risk of cardiorenal outcomes—including hypertension, proteinuria, heart failure and *de novo* CKD—in randomised controlled trials of intravitreal VEGF_is nor have we identified an increased risk of arterial thrombotic cardiovascular events, even though populations in which these agents are used are at high risk for these events. However, there are insufficient reported data to definitively confirm or refute any link between these agents and adverse cardiorenal outcomes. In the subgroup of patients treated for diabetic eye disease, we identified an increased risk of death associated with VEGF_i treatment.

This is the first systematic review to explore the incidence and reporting of renal adverse events and heart failure after intravitreal VEGF_i. Prior reviews have made a disproportionate effort to capture arterial thrombotic cardiovascular events and death [20–23], although mechanistically hypertension, heart failure and CKD are more likely sequelae [24]. In a systematic

review of systematic reviews, intravitreal VEGF_i treatments were not found to be associated with an increased risk of systemic adverse events, predominantly focusing on arterial thrombotic cardiovascular events and death [20]. However, in restricted analyses in participants with diabetic eye disease, associations have been demonstrated between intravitreal VEGF_i and risk of stroke and vascular death [22] and with all-cause mortality [25]. We have similarly found an association between intravitreal VEGF_i and death in the subset of patients treated for diabetic eye disease.

If intravitreal VEGF_is are associated with a higher risk of premature death, this may have important implications for informed consent for patients with diabetes and kidney disease, who are already at higher risk from their underlying disease. However, the absolute risk of death associated with VEGF_is may be outweighed by benefits to quality of life, such as preservation of visual acuity in VEGF_i-treated patients. We do not believe the current trial data are adequate to quantify differences in the absolute risks—of death with treatment and visual loss without—to inform the consent process. First, only a minority of trials report cardiorenal, arterial thrombotic and death events: the risk of death or other significant events may be underestimated due to underreporting. Second, the duration of follow-up in trials is relatively short: except one trial with a 5-year follow-up, the maximum observation period in the included trials was 2 years. This is unlikely to be long enough to capture the cumulative risks associated with prolonged treatment with intravitreal VEGF_is, particularly as kidney disease and heart failure may not manifest clinically until much later in the disease course. Third, patients in higher-risk populations, such as those with diabetes, pre-existing CKD, heart failure or a combination of these may be at increased risk, but this is not adequately recorded to assess in current trials. Fourth, it has been observed that patients with multiple medical conditions are underrepresented in clinical trials [26], with higher recorded adverse events in the general population compared with the trial populations [27]: this is also likely to be true for trials of intravitreal treatments. We may be able to quantify absolute risks of visual loss, cardiorenal side effects and death through the analysis of large, long-term, real-world databases ('big data'); however, with many confounding factors in population studies, particularly in cohorts of patients requiring VEGF_is for diabetic eye disease, we acknowledge that it will be challenging to identify causal relationships.

We have not identified an increased risk of cardiorenal outcomes in intravitreal VEGF_i-treated participants in the published trials. Since hypertension is an almost ubiquitous sequela in patients treated with intravenous VEGF_i [24], it may be that the definitions or thresholds used within the trials were not sensitive enough to detect treatment-related hypertension. None of the 29 trials reporting hypertension as an outcome specified a definition of hypertension and there were inadequate raw data reported to assess absolute changes in BP over the treatment period. Similarly, reporting of renal outcomes were inconsistent, insensitive and non-specific across studies. One trial [28] reported >10 renal complications (including 'acute kidney injury', 'acute renal failure', 'chronic

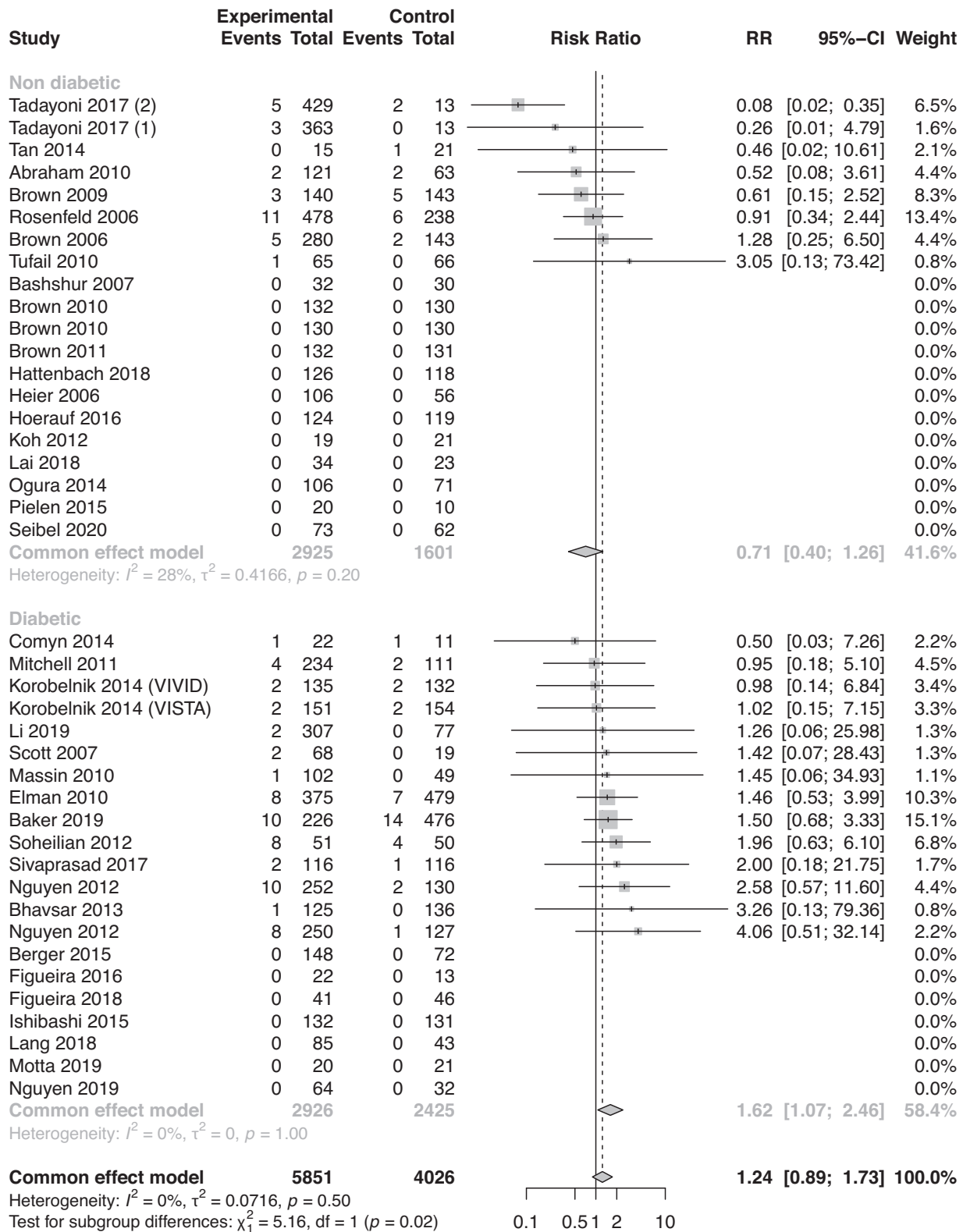


Figure 4: Forest plot of RRs for all-cause mortality: frequentist meta-analysis using fixed and random effects models, stratified by diabetic versus non-diabetic eye disease.

kidney disease, 'kidney failure', 'end-stage kidney disease'), many of which are likely to be overlapping. It is impossible to know whether raw data values are available in the trial site files but have not reached publication. This review illustrates the potential utility of presenting absolute values of pre- and post-treatment BP, proteinuria, kidney function (e.g. eGFR) and objective measures of heart failure (e.g. N-terminal brain natriuretic peptide and left ventricular EF) in patients treated with VEGFis by any route. These would be substantially more informative and sensitive to detecting treatment-related side effects.

Recent evidence highlights the importance of assessing and reporting important systemic outcomes in trials, particularly in high-risk groups. Rosiglitazone was previously used widely for glycaemic control in type 2 diabetes; however, scrutiny of the published trial data showed that rosiglitazone was unexpectedly associated with increased odds of MI and death [29]. Bardoxolone methyl was tested to slow progression of diabetic kidney disease, but the trial was stopped early due to an increased rate of cardiovascular events in the treatment group compared with placebo [30]. Atrasentan, tested in patients with diabetic kidney disease, was shown to reduce the risk of renal decline or end-stage kidney disease, but there was a signal towards an increased rate of heart failure hospitalisations [31]. In clinical practice, hypertension, proteinuria, renal decline and heart failure are all common in patients with diabetes. In the absence of guidelines to test and monitor for cardiorenal side effects after introducing intravitreal VEGFi, it may be difficult to distinguish whether new or worsened cardiorenal effects are related to the progression of diabetic complications or whether they could have been exacerbated by intravitreal treatments. There are numerous published case reports of *de novo* renal sequelae after intravitreal VEGFi—particularly bevacizumab and aflibercept—including proteinuria, hypertension, heart failure and progressive renal injury [7, 32–35]. Ranibizumab is similarly absorbed, but is cleared far more quickly due to its structure and size. Although ranibizumab is associated with fewer reports of cardiorenal side effects compared with bevacizumab and aflibercept, it has also been associated with hypertension, thrombotic microangiopathy and renal injury [36–38]. It is desirable to scrutinise population and prescription data to assess the prevalence of these cardiorenal sequelae after intravitreal VEGFi treatments. If concerns about cardiorenal safety are confirmed, this may encourage trialists, regulators and guideline developers to monitor for these potential sequelae, adjust ophthalmic treatment regimens and provide better information for informed consent for patients.

We acknowledge some limitations of this work. First and most important, the cardiorenal adverse events were secondary outcomes in these trials: only a limited number of trials reported the incidence of our cardiorenal outcomes of interest, limiting the power to detect a signal for cardiorenal side effects. We did not find evidence of additional reporting of systemic adverse events in secondary trial publications. Second, the

baseline cardiometabolic phenotype of the participants in these trials was not well-described: both comorbidities and absolute values of markers of cardiorenal disease (eGFR, BP, proteinuria, EF) were rarely reported, although it is likely that vital signs/BP were measured in most. It was not possible to identify subgroups who may be at higher risk of cardiorenal sequelae in the trial populations. Third, in the limited trials that reported rates of cardiorenal adverse events, there was a limited duration of follow-up to detect these risks over the longer term—a common issue in prospective trials. Repeated exposure to systemic absorption of VEGFis over a longer time period may be associated with a high risk of developing cardiorenal side effects that are not detectable within the relatively short follow-up (range 3–60 months, but the majority <24 months).

CONCLUSION

In published trials of intravitreal VEGFis, we did not identify an increased risk of cardiorenal outcomes—including hypertension, proteinuria, heart failure and *de novo* CKD—however, there are insufficient data definitively to confirm or refute any link between these agents and adverse cardiorenal outcomes. In keeping with previous analyses, we did not identify an increased risk of arterial thrombotic cardiovascular events, but there was an increased risk of death in the subgroup of patients treated with intravitreal VEGFis for diabetic indications. However, there is increasing evidence for systemic cardiorenal sequelae of intravitreal VEGFis. Additional scrutiny of post-licensing population data may help identify if there are implications for cardiorenal safety and monitoring when prescribing these medications, particularly in high-risk patients with diabetes.

SUPPLEMENTARY DATA

Supplementary data are available at *ndt* online.

FUNDING

J.S.L. is funded by a Chief Scientist Office (Scotland) Postdoctoral Lectureship Award (PCL/20/10). S.J.H.D. and N.N.L are supported by a British Heart Foundation Centre of Excellence Award (RE/18/6/34217).

AUTHORS' CONTRIBUTIONS

All authors designed the research and critically reviewed and approved the final manuscript. J.S.L. and S.J.H.D. performed the search and extracted data. J.S.L. collated the data, performed statistical analysis and wrote the first draft of the manuscript.

DATA AVAILABILITY STATEMENT

Extracted data and analysis code will be available from the project GitHub repository on publication (https://github.com/jennifer-s-lees/vegf_sr_meta_analysis_public).

CONFLICT OF INTEREST STATEMENT

J.S.L. has received personal honoraria from Bristol-Myers Squibb, Pfizer and AstraZeneca, outside the submitted work. P.B.M. has received personal honoraria from Vifor, Pharmacosmos, Napp, AstraZeneca, GlaxoSmithKline and Astellas and grants from Boehringer Ingelheim. The University of Glasgow, which employs N.N.L., has received research grant funding from Roche Diagnostics, AstraZeneca and Boehringer Ingelheim (outside the submitted work) and has received speaker fees/advisory board fees from Roche, Pharmacosmos, AstraZeneca and Novartis. The results presented in this article have not been published previously in whole or in part except in abstract form.

REFERENCES

1. Rothen M, Jablon E, Monares G *et al*. Anti-macular degeneration agents. *Ophthalmol Clin North Am* 2005;18:561–7.
2. Virgili G, Parravano M, Evans JR *et al*. Anti-vascular endothelial growth factor for diabetic macular oedema: a network meta-analysis. *Cochrane Database Syst Rev* 2017;6:CD007419. <http://dx.doi.org/10.1002/14651858.CD007419.pub6>
3. Solomon SD, Lindsley K, Vedula SS *et al*. Anti-vascular endothelial growth factor for neovascular age-related macular degeneration. *Cochrane Database Syst Rev* 2019;3:CD005139.
4. Shalchi Z, Mahroo O, Bunce C *et al*. Anti-vascular endothelial growth factor for macular oedema secondary to branch retinal vein occlusion. *Cochrane Database Syst Rev* 2020;7:CD009510.
5. Mathur R, Bhaskaran K, Edwards E *et al*. Population trends in the 10-year incidence and prevalence of diabetic retinopathy in the UK: a cohort study in the Clinical Practice Research Datalink 2004–2014. *BMJ Open* 2017;7:e014444. <http://dx.doi.org/10.1136/bmjopen-2016-014444>
6. Li JQ, Welchowski T, Schmid M *et al*. Prevalence, incidence and future projection of diabetic eye disease in europe: a systematic review and meta-analysis. *Eur J Epidemiol* 2020;35:11–23. <http://dx.doi.org/10.1007/s10654-019-00560-z>
7. Hanna RM, Barsoum M, Arman F *et al*. Nephrotoxicity induced by intravitreal vascular endothelial growth factor inhibitors: emerging evidence. *Kidney Int* 2019;96:572–80. <http://dx.doi.org/10.1016/j.kint.2019.02.042>
8. Hirano T, Toriyama Y, Iesato Y *et al*. Changes in plasma vascular endothelial growth factor level after intravitreal injection of bevacizumab, aflibercept, or ranibizumab for diabetic macular edema. *Retina* 2018;38:1801–8. <http://dx.doi.org/10.1097/IAE.0000000000002004>
9. Avery R, Castellarin A, Steinle N *et al*. Systemic pharmacokinetics and pharmacodynamics of intravitreal aflibercept, bevacizumab, and ranibizumab. *Retina* 2017;37:1847–58. <http://dx.doi.org/10.1097/IAE.0000000000001493>
10. Rogers C, Scott L, Reeves B *et al*. Serum vascular endothelial growth factor levels in the IVAN trial; relationships with drug, dosing, and systemic serious adverse events. *Ophthalmol Retina* 2018;2:118–27. <http://dx.doi.org/10.1016/j.oret.2017.05.015>
11. Rasier R, Artunay O, Yuzbasioglu E *et al*. The effect of intravitreal bevacizumab (Avastin) administration on systemic hypertension. *Eye* 2009;23:1714–8. <http://dx.doi.org/10.1038/eye.2008.360>
12. Glassman AR, Liu D, Jampol LM *et al*. Changes in blood pressure and urine albumin-creatinine ratio in a randomized clinical trial comparing aflibercept, bevacizumab, and ranibizumab for diabetic macular edema. *Invest Ophthalmol Vis Sci* 2018;59:1199–205.
13. Touyz RM, Lang NN. Hypertension and antiangiogenesis: the Janus face of VEGF inhibitors. *JACC CardioOncol* 2019;1:37–40. <http://dx.doi.org/10.1016/j.jacc.2019.08.010>
14. Dobbin SJH, Cameron AC, Petrie MC *et al*. Toxicity of cancer therapy: what the cardiologist needs to know about angiogenesis inhibitors. *Heart* 2018;104:1995–2002. <http://dx.doi.org/10.1136/heartjnl-2018-313726>
15. National Institute for Health and Care Excellence. British National Formulary. 2020. <https://www.bnf.org/>.
16. Bressler SB, Glassman AR, Almkhhtar T *et al*. Five-year outcomes of ranibizumab with prompt or deferred laser versus laser or triamcinolone plus deferred ranibizumab for diabetic macular edema. *Am J Ophthalmol* 2016;164:57–68. <http://dx.doi.org/10.1016/j.ajo.2015.12.025>
17. Heier JS, Korobelnik J-F, Brown DM *et al*. Intravitreal aflibercept for diabetic macular edema: 148-week results from the VISTA and VIVID studies. *Ophthalmology* 2016;123:2376–85. <http://dx.doi.org/10.1016/j.ophtha.2016.07.032>
18. Hutton DW, Stein JD, Glassman AR *et al*. Five-year cost-effectiveness of intravitreal ranibizumab therapy vs panretinal photocoagulation for treating proliferative diabetic retinopathy: a secondary analysis of a randomized clinical trial. *JAMA Ophthalmol* 2019;137:1424–32. <http://dx.doi.org/10.1001/jamaophthalmol.2019.4284>
19. Bressler SB, Glassman AR, Almkhhtar T *et al*. Five-year outcomes of ranibizumab with prompt or deferred laser versus laser or triamcinolone plus deferred ranibizumab for diabetic macular edema. *Am J Ophthalmol* 2016;164:57–68. <http://dx.doi.org/10.1016/j.ajo.2015.12.025>
20. Thulliez M, Angoulvant D, Pisella PJ *et al*. Overview of systematic reviews and meta-analyses on systemic adverse events associated with intravitreal anti-vascular endothelial growth factor medication use. *JAMA Ophthalmol* 2018;136:557–66. <http://dx.doi.org/10.1001/jamaophthalmol.2018.0002>
21. Thulliez M, Angoulvant D, Le Lez M *et al*. Cardiovascular events and bleeding risk associated with intravitreal anti-vascular endothelial growth factor monoclonal antibodies: systematic review and meta-analysis. *JAMA Ophthalmol* 2014;132:1317–26. <http://dx.doi.org/10.1001/jamaophthalmol.2014.2333>
22. Avery RL, Gordon GM. Systemic safety of prolonged monthly anti-vascular endothelial growth factor therapy for diabetic macular edema: a systematic review and meta-analysis. *JAMA Ophthalmol* 2016;134:21–29. <http://dx.doi.org/10.1001/jamaophthalmol.2015.4070>
23. Reibaldi M, Fallico M, Avitabile T *et al*. Risk of death associated with intravitreal anti-vascular endothelial growth factor therapy: a systematic review and meta-analysis. *JAMA Ophthalmol* 2020;138:50–57. <http://dx.doi.org/10.1001/jamaophthalmol.2019.4636>
24. Dobbin SJH, Cameron AC, Petrie MC *et al*. Toxicity of cancer therapy: what the cardiologist needs to know about angiogenesis inhibitors. *Heart* 2018;104:1995–2002. <http://dx.doi.org/10.1136/heartjnl-2018-313726>
25. Ngo Ntjam N, Thulliez M, Paintaud G *et al*. Cardiovascular adverse events with intravitreal anti-vascular endothelial growth factor drugs. *JAMA Ophthalmol* 2021;139:1–11. <http://dx.doi.org/10.1001/jamaophthalmol.2021.0640>
26. Hanlon P, Hannigan L, Rodriguez-Perez J *et al*. Representation of people with comorbidity and multimorbidity in clinical trials of novel drug therapies: an individual-level participant data analysis. *BMC Med* 2019;17:201. <http://dx.doi.org/10.1186/s12916-019-1427-1>
27. Hanlon P, Corcoran N, Rughani G *et al*. Observed and expected serious adverse event rates in randomised clinical trials for hypertension: an observational study comparing trials that do and do not focus on older people. *Lancet Healthy Longev* 2021;2:e398–406. [http://dx.doi.org/10.1016/S2666-7568\(21\)00092-1](http://dx.doi.org/10.1016/S2666-7568(21)00092-1)
28. Baker CW, Glassman AR, Beaulieu WT *et al*. Effect of initial management with aflibercept vs laser photocoagulation vs observation on vision loss among patients with diabetic macular edema involving the center of the macula and good visual acuity: a randomized clinical trial. *JAMA* 2019;321:1880–94. <http://dx.doi.org/10.1001/jama.2019.5790>
29. Nissen S, Wolski K. Effect of rosiglitazone on the risk of myocardial infarction and death from cardiovascular causes. *N Engl J Med* 2007;356:2457–71. <http://dx.doi.org/10.1056/NEJMoa072761>
30. de Zeeuw D, Akizawa T, Audhya P *et al*. BardoXolone methyl in type 2 diabetes and stage 4 chronic kidney disease. *N Engl J Med* 2013;369:2492–503. <http://dx.doi.org/10.1056/NEJMoa1306033>

31. Heerspink HJL, Parving HH, Andress DL *et al.* Atrasentan and renal events in patients with type 2 diabetes and chronic kidney disease (SONAR): a double-blind, randomised, placebo-controlled trial. *Lancet* 2019;**393**:1937–47. [http://dx.doi.org/10.1016/S0140-6736\(19\)30772-X](http://dx.doi.org/10.1016/S0140-6736(19)30772-X)
32. Hanna RM, Lopez EA, Hasnain H *et al.* Three patients with injection of intravitreal vascular endothelial growth factor inhibitors and subsequent exacerbation of chronic proteinuria and hypertension. *Clin Kidney J* 2019;**12**:92–100. <http://dx.doi.org/10.1093/ckj/sfy060>
33. Crowe K, Lang NN, Mark PB. Intravitreal anti vascular endothelial growth factor-driven deterioration in proteinuria, renal function, and hypertension in the context of diabetic nephropathy: a case report. *Hypertens J* 2022;**7**:153–6.
34. Campbell RJ, Gill SS, Bronskill SE *et al.* Adverse events with intravitreal injection of vascular endothelial growth factor inhibitors: nested case-control study. *BMJ* 2012;**345**:e4203.
35. Ahmed M, Alouch N, Ahmed A *et al.* Worsening of renal function and uncontrolled hypertension from intravitreal bevacizumab injections. *Proc (Bayl Univ Med Cent)* 2021;**34**:527–9. <http://dx.doi.org/10.1080/08998280.2021.1885285>
36. Pell G, Shweke N, Van Huyen JPD *et al.* Systemic and kidney toxicity of intraocular administration of vascular endothelial growth factor inhibitors. *Am J Kidney Dis* 2011;**57**:756–9. <http://dx.doi.org/10.1053/j.ajkd.2010.11.030>
37. Phadke G, Hanna RM, Ferrey A *et al.* Review of intravitreal VEGF inhibitor toxicity and report of collapsing FSGS with TMA in a patient with age-related macular degeneration. *Clin Kidney J* 2021;**14**:2158–65. <http://dx.doi.org/10.1093/ckj/sfab066>
38. Tournon N, Bertrand L, Bagheri H *et al.* Severe hypertensive flare-up after intravitreal injection of ranibizumab for retinal venous branch occlusion. *Fundam Clin Pharmacol* 2021;**35**:785–8. <http://dx.doi.org/10.1111/fcp.12632>
39. Abraham P, Yue H, Wilson L. Randomized, double-masked, sham-controlled trial of ranibizumab for neovascular age-related macular degeneration: PIER study year 2. *Am J Ophthalmol* 2010;**150**:315–24.e1. <http://dx.doi.org/10.1016/j.ajo.2010.04.011>
40. Arcieri ES, Paula JS, Jorge R *et al.* Efficacy and safety of intravitreal bevacizumab in eyes with neovascular glaucoma undergoing Ahmed glaucoma valve implantation: 2-year follow-up. *Acta Ophthalmol* 2015;**93**:e1–6. <http://dx.doi.org/10.1111/aos.12493>
41. Bae SH, Heo J, Kim C *et al.* Low-fluence photodynamic therapy versus ranibizumab for chronic central serous chorioretinopathy: one-year results of a randomized trial. *Ophthalmology* 2014;**121**:558–65. <http://dx.doi.org/10.1016/j.ophtha.2013.09.024>
42. Baker CW, Glassman AR, Beaulieu WT *et al.* Effect of initial management with aflibercept vs laser photocoagulation vs observation on vision loss among patients with diabetic macular edema involving the center of the macula and good visual acuity: a randomized clinical trial. *JAMA* 2019;**321**:1880–94. <http://dx.doi.org/10.1001/jama.2019.5790>
43. Bandello F, Augustin A, Tufail A *et al.* A 12-month, multicenter, parallel group comparison of dexamethasone intravitreal implant versus ranibizumab in branch retinal vein occlusion. *Eur J Ophthalmol* 2018;**28**:697–705. <http://dx.doi.org/10.1177/1120672117750058>
44. Bashshur ZF, Schakal A, Hamam RN *et al.* Intravitreal bevacizumab vs verteporfin photodynamic therapy for neovascular age-related macular degeneration. *Arch Ophthalmol* 2007;**125**:1357–61. <http://dx.doi.org/10.1001/archophth.125.10.1357>
45. Beaulieu WT, Bressler NM, Melia M *et al.* Panretinal photocoagulation versus ranibizumab for proliferative diabetic retinopathy: patient-centered outcomes from a randomized clinical trial. *Am J Ophthalmol* 2016;**170**:206–13. <http://dx.doi.org/10.1016/j.ajo.2016.08.008>
46. Berger A, Sheidow T, Cruess AF *et al.* Efficacy/safety of ranibizumab monotherapy or with laser versus laser monotherapy in DME. *Can J Ophthalmol* 2015;**50**:209–16. <http://dx.doi.org/10.1016/j.cjco.2014.12.014>
47. Bhavsar A, Torres K, Beck R *et al.* Randomized clinical trial evaluating intravitreal ranibizumab or saline for vitreous hemorrhage from proliferative diabetic retinopathy. *JAMA Ophthalmol* 2013;**131**:283–93.
48. Bhayana S, Sood S, Narang S *et al.* Intravitreal bevacizumab versus posterior subtenon triamcinolone in diffuse diabetic macular edema. *Int Ophthalmol* 2015;**35**:519–25. <http://dx.doi.org/10.1007/s10792-014-9978-9>
49. Boyer D, Heier J, Brown DM *et al.* Vascular endothelial growth factor Trap-Eye for macular edema secondary to central retinal vein occlusion: six-month results of the phase 3 COPERNICUS study. *Ophthalmology* 2012;**119**:1024–32. <http://dx.doi.org/10.1016/j.ophtha.2012.01.042>
50. Brown DM, Kaiser PK, Michels M *et al.* Ranibizumab versus verteporfin for neovascular age-related macular degeneration. *N Engl J Med* 2006;**355**:1432–44. <http://dx.doi.org/10.1056/NEJMoa062655>
51. Brown DM, Campochiaro PA, Singh RP *et al.* Ranibizumab for macular edema following central retinal vein occlusion: six-month primary end point results of a phase III study. *Ophthalmology* 2010;**117**:1124–1133.e1. <http://dx.doi.org/10.1016/j.ophtha.2010.02.022>
52. Brown DM, Campochiaro PA, Bhisitkul RB *et al.* Sustained benefits from ranibizumab for macular edema following branch retinal vein occlusion: 12-month outcomes of a phase III study. *Ophthalmology* 2011;**118**:1594–602. <http://dx.doi.org/10.1016/j.ophtha.2011.02.022>
53. Brown DM, Michels M, Kaiser PK *et al.* Ranibizumab versus verteporfin photodynamic therapy for neovascular age-related macular degeneration: two-year results of the ANCHOR study. *Ophthalmology* 2009;**116**:57–65.e5. <http://dx.doi.org/10.1016/j.ophtha.2008.10.018>
54. Callanan DG, Loewenstein A, Patel SS *et al.* A multicenter, 12-month randomized study comparing dexamethasone intravitreal implant with ranibizumab in patients with diabetic macular edema. *Graefes Arch Clin Exp Ophthalmol* 2017;**255**:463–73.
55. Campochiaro PA, Khanani A, Singer M *et al.* Enhanced benefit in diabetic macular edema from AKB-9778 Tie2 activation combined with vascular endothelial growth factor suppression. *Ophthalmology* 2016;**123**:1722–30. <http://dx.doi.org/10.1016/j.ophtha.2016.04.025>
56. Chelala E, Nehme J, El Rami H *et al.* Efficacy of intravitreal ranibizumab injections in the treatment of vitreous hemorrhage related to proliferative diabetic retinopathy. *Retina* 2018;**38**:1127–33. <http://dx.doi.org/10.1097/IAE.0000000000001673>
57. Comyn O, Sivaprasad S, Peto T *et al.* A randomized trial to assess functional and structural effects of ranibizumab versus laser in diabetic macular edema (the LUCIDATE study). *Am J Ophthalmol* 2014;**157**:960–70.e2. <http://dx.doi.org/10.1016/j.ajo.2014.02.019>
58. Ding X, Li J, Hu X *et al.* Prospective study of intravitreal triamcinolone acetonide versus bevacizumab for macular edema secondary to central retinal vein occlusion. *Retina* 2011;**31**:838–45. <http://dx.doi.org/10.1097/IAE.0b013e3181f4420d>
59. Elman MJ, Aiello LP, Beck RW *et al.* Randomized trial evaluating ranibizumab plus prompt or deferred laser or triamcinolone plus prompt laser for diabetic macular edema. *Ophthalmology* 2010;**117**:1064–77.e35. <http://dx.doi.org/10.1016/j.ophtha.2010.02.031>
60. Epstein DLJ, Algvere PV, von Wendt G *et al.* Bevacizumab for macular edema in central retinal vein occlusion: a prospective, randomized, double-masked clinical study. *Ophthalmology* 2012;**119**:1184–9. <http://dx.doi.org/10.1016/j.ophtha.2012.01.022>
61. Ferraz DA, Vasquez LM, Preti RC *et al.* A randomized controlled trial of panretinal photocoagulation with and without intravitreal ranibizumab in treatment-naïve eyes with non-high-risk proliferative diabetic retinopathy. *Retina* 2015;**35**:280–7. <http://dx.doi.org/10.1097/IAE.0000000000000363>
62. Figueira J, Silva R, Henriques J *et al.* Ranibizumab for high-risk proliferative diabetic retinopathy: an exploratory randomized controlled trial. *Ophthalmologica* 2016;**235**:34–41. <http://dx.doi.org/10.1159/000442026>
63. Figueira J, Fletcher E, Massin P *et al.* Ranibizumab Plus Panretinal Photocoagulation Versus Panretinal Photocoagulation Alone for High-Risk Proliferative Diabetic Retinopathy (PROTEUS Study). *Ophthalmology* 2018;**125**:691–700. <http://dx.doi.org/10.1016/j.ophtha.2017.12.008>
64. Gado AS, Macky TA. Dexamethasone intravitreal implant versus bevacizumab for central retinal vein occlusion-related macular oedema: a prospective randomized comparison. *Clin Exp Ophthalmol* 2014;**42**:650–5.
65. Gale JD, Berger B, Gilbert S *et al.* A CCR2/5 inhibitor, PF-04634817, is inferior to monthly ranibizumab in the treatment of diabetic macular edema. *Invest Ophthalmol Vis Sci* 2018;**59**:2659–69.
66. Gross JG, Glassman AR, Liu D *et al.* Five-year outcomes of panretinal photocoagulation vs intravitreal ranibizumab for proliferative diabetic retinopathy: a randomized clinical trial. *JAMA Ophthalmol*

- mol* 2018;**136**:1138–48. <http://dx.doi.org/10.1001/jamaophthalmol.2018.3255>
67. Hattenbach L-O, Feltgen N, Bertelmann T *et al.* Head-to-head comparison of ranibizumab PRN versus single-dose dexamethasone for branch retinal vein occlusion (COMRADE-B). *Acta Ophthalmol* 2018;**96**:e10–8. <http://dx.doi.org/10.1111/aos.13381>
 68. Hatz K, Schneider U, Henrich PB *et al.* Ranibizumab plus verteporfin photodynamic therapy in neovascular age-related macular degeneration: 12 months of retreatment and vision outcomes from a randomized study. *Ophthalmologica* 2015;**233**:66–73. <http://dx.doi.org/10.1159/000367603>
 69. Heier JS, Boyer DS, Ciulla TA *et al.* Ranibizumab combined with verteporfin photodynamic therapy in neovascular age-related macular degeneration: year 1 results of the FOCUS study. *Arch Ophthalmol* 2006;**124**:1532–42. <http://dx.doi.org/10.1001/archophth.124.11.1532>
 70. Higashiyama T, Sawada O, Kakinoki M *et al.* Prospective comparisons of intravitreal injections of triamcinolone acetonide and bevacizumab for macular oedema due to branch retinal vein occlusion. *Acta Ophthalmol* 2013;**91**:318–24. <http://dx.doi.org/10.1111/j.1755-3768.2011.02298.x>
 71. Hoerauf H, Feltgen N, Weiss C *et al.* Clinical Efficacy and Safety of Ranibizumab versus Dexamethasone for Central Retinal Vein Occlusion (COMRADE C): a European label study. *Am J Ophthalmol* 2016;**169**:258–67. <http://dx.doi.org/10.1016/j.ajo.2016.04.020>
 72. Ishibashi T, Li X, Koh A *et al.* The REVEAL study: ranibizumab monotherapy or combined with laser versus laser monotherapy in Asian patients with diabetic macular edema. *Ophthalmology* 2015;**122**:1402–15. <http://dx.doi.org/10.1016/j.ophtha.2015.02.006>
 73. Karadžić J, Kovačević I, Ljekar J *et al.* Pharmacological intravitreal treatment for macular edema in branch retinal vein occlusion – three-month results. *Med Pregl* 2015;**68**:295–300. <http://dx.doi.org/10.2298/MPNS1510295K>
 74. Kinge B, Stordahl PB, Forsaa V *et al.* Efficacy of ranibizumab in patients with macular edema secondary to central retinal vein occlusion: results from the sham-controlled ROCC study. *Am J Ophthalmol* 2010;**150**:310–4. <http://dx.doi.org/10.1016/j.ajo.2010.03.028>
 75. Koh A, Lee WK, Chen L-J *et al.* EVEREST study: efficacy and safety of verteporfin photodynamic therapy in combination with ranibizumab or alone versus ranibizumab monotherapy in patients with symptomatic macular polypoidal choroidal vasculopathy. *Retina* 2012;**32**:1453–64. <http://dx.doi.org/10.1097/IAE.0b013e31824f91e8>
 76. Korobelnik J-F, Do D V, Schmidt-Erfurth U *et al.* Intravitreal aflibercept for diabetic macular edema. *Ophthalmology* 2014;**121**:2247–54. <http://dx.doi.org/10.1016/j.ophtha.2014.05.006>
 77. Kriechbaum K, Prager S, Mylonas G *et al.* Intravitreal bevacizumab (Avastin) versus triamcinolone (Volon A) for treatment of diabetic macular edema: one-year results. *Eye* 2014;**28**:9–16; quiz 16. <http://dx.doi.org/10.1038/eye.2013.242>
 78. Kumar P, Sharma YR, Chandra P *et al.* Comparison of the safety and efficacy of intravitreal ranibizumab with or without laser photocoagulation versus dexamethasone intravitreal implant with or without laser photocoagulation for macular edema secondary to branch retinal vein occlusion. *Folia Med (Plovdiv)* 2019;**61**:240–8. <http://dx.doi.org/10.2478/folmed-2018-0081>
 79. Lai K, Li Y, Zhou L *et al.* Comparison of the effects of photodynamic therapy, intravitreal ranibizumab and combination for polypoidal choroidal vasculopathy under 1 + PRN regimen. *BMC Ophthalmol* 2018;**18**:144. <http://dx.doi.org/10.1186/s12886-018-0801-7>
 80. Lang GE, Liakopoulos S, Vögeler J *et al.* The RELATION study: efficacy and safety of ranibizumab combined with laser photocoagulation treatment versus laser monotherapy in NPDR and PDR patients with diabetic macular oedema. *Acta Ophthalmol* 2018;**96**:e377–85. <http://dx.doi.org/10.1111/aos.13574>
 81. Li X, Dai H, Li X *et al.* Efficacy and safety of ranibizumab 0.5 mg in Chinese patients with visual impairment due to diabetic macular edema: results from the 12-month REFINE study. *Graefes Arch Clin Exp Ophthalmol* 2019;**257**:529–41.
 82. Lim LL, Morrison JL, Constantinou M *et al.* Diabetic macular edema at the time of cataract surgery trial: a prospective, randomized clinical trial of intravitreal bevacizumab versus triamcinolone in patients with diabetic macular oedema at the time of cataract surgery - preliminary 6 month result. *Clin Exp Ophthalmol* 2016;**44**:233–42.
 83. Lucatto LFA, Magalhães-Junior O, Prazeres JMB *et al.* Incidence of anterior segment neovascularization during intravitreal treatment for macular edema secondary to central retinal vein occlusion. *Arq Bras Oftalmol* 2017;**80**:97–103. <http://dx.doi.org/10.5935/0004-2749.20170024>
 84. Massin P, Bandello F, Garweg JG *et al.* Safety and efficacy of ranibizumab in diabetic macular edema (RESOLVE study): a 12-month, randomized, controlled, double-masked, multicenter phase II study. *Diabetes Care* 2010;**33**:2399–405. <http://dx.doi.org/10.2337/dc10-0493>
 85. Mitchell P, Bandello F, Schmidt-Erfurth U *et al.* The RESTORE study: ranibizumab monotherapy or combined with laser versus laser monotherapy for diabetic macular edema. *Ophthalmology* 2011;**118**:615–25. <http://dx.doi.org/10.1016/j.ophtha.2011.01.031>
 86. Moradian S, Faghihi H, Sadeghi B *et al.* Intravitreal bevacizumab vs. sham treatment in acute branch retinal vein occlusion with macular edema: results at 3 months (Report 1). *Graefes Arch Clin Exp Ophthalmol* 2011;**249**:193–200.
 87. Motta AAL, Bonanomi MTBC, Ferraz DA *et al.* Short-term effects of intravitreal bevacizumab on contrast sensitivity of patients with diabetic macular edema and optimizing glycemic control. *Diabetes Res Clin Pract* 2019;**149**:170–8. <http://dx.doi.org/10.1016/j.diabres.2019.02.002>
 88. Nguyen QD, Brown DM, Marcus DM *et al.* Ranibizumab for diabetic macular edema: results from 2 phase III randomized trials: RISE and RIDE. *Ophthalmology* 2012;**119**:789–801. <http://dx.doi.org/10.1016/j.ophtha.2011.12.039>
 89. Nguyen QD, Sepah YJ, Berger B *et al.* Primary outcomes of the VIDDI study: phase 2, double-masked, randomized, active-controlled study of ASP8232 for diabetic macular edema. *Int J Retina Vitreous* 2019;**5**:28. <http://dx.doi.org/10.1186/s40942-019-0178-7>
 90. Ogura Y, Roeder J, Korobelnik J-F *et al.* Intravitreal aflibercept for macular edema secondary to central retinal vein occlusion: 18-month results of the phase 3 GALILEO study. *Am J Ophthalmol* 2014;**158**:1032–8.e2. <http://dx.doi.org/10.1016/j.ajo.2014.07.027>
 91. Parodi MB, Cascavilla M, Papayannis A *et al.* Intravitreal bevacizumab in advanced-stage neovascular age-related macular degeneration with visual acuity lower than 20/200. *Arch Ophthalmol* 2012;**130**:934–5. <http://dx.doi.org/10.1001/archophthalmol.2011.2617>
 92. Parodi MB, Iacono P, Papayannis A *et al.* Laser photocoagulation, photodynamic therapy, and intravitreal bevacizumab for the treatment of juxtafoveal choroidal neovascularization secondary to pathologic myopia. *Arch Ophthalmol* 2010;**128**:437–42. <http://dx.doi.org/10.1001/archophthalmol.2009.408>
 93. Parodi MB, Iacono P, Bandello F. Subthreshold grid laser versus intravitreal bevacizumab as second-line therapy for macular edema in branch retinal vein occlusion recurring after conventional grid laser treatment. *Graefes Arch Clin Exp Ophthalmol* 2015;**253**:1647–51.
 94. Patwardhan SD, Azad R, Shah BM *et al.* Role of intravitreal bevacizumab in Eales disease with dense vitreous hemorrhage: a prospective randomized control study. *Retina* 2011;**31**:866–70. <http://dx.doi.org/10.1097/IAE.0b013e3181f2a27f>
 95. Pielon A, Mirshahi A, Feltgen N *et al.* Ranibizumab for Branch Retinal Vein Occlusion Associated Macular Edema Study (RABAMES): six-month results of a prospective randomized clinical trial. *Acta Ophthalmol* 2015;**93**:e29–37. <http://dx.doi.org/10.1111/aos.12488>
 96. Preti RC, Ramirez LMV, Monteiro MLR *et al.* Contrast sensitivity evaluation in high risk proliferative diabetic retinopathy treated with panretinal photocoagulation associated or not with intravitreal bevacizumab injections: a randomised clinical trial. *Br J Ophthalmol* 2013;**97**:885–9. <http://dx.doi.org/10.1136/bjophthalmol-2012-302675>
 97. Raizada S, Al Kandari J, Al Diab F *et al.* Pars plana vitrectomy versus three intravitreal injections of bevacizumab for nontractional diabetic macular edema. A prospective, randomized comparative study. *Indian J Ophthalmol* 2015;**63**:504–10. <http://dx.doi.org/10.4103/0301-4738.162602>
 98. Rajendram R, Fraser-Bell S, Kaines A *et al.* A 2-year prospective randomized controlled trial of intravitreal bevacizumab or laser therapy (BOLT) in the management of diabetic macular edema: 24-month data: report 3. *Arch Ophthalmol* 2012;**130**:972–9.
 99. Ramezani A, Esfandiari H, Entezari M *et al.* Three intravitreal bevacizumab versus two intravitreal triamcinolone injections in recent-onset branch retinal vein occlusion. *Graefes Arch Clin Exp Ophthalmol* 2012;**250**:1149–60.

100. Rodrigues MW, Cardillo JA, Messias A *et al.* Bevacizumab versus triamcinolone for persistent diabetic macular edema: a randomized clinical trial. *Graefes Arch Clin Exp Ophthalmol* 2020;**258**:479–90.
101. Rosenfeld PJ, Brown DM, Heier JS *et al.* Ranibizumab for neovascular age-related macular degeneration. *N Engl J Med* 2006;**355**:1419–31. <http://dx.doi.org/10.1056/NEJMoa054481>
102. Rouvas AA, Papakostas TD, Vavvas D *et al.* Intravitreal ranibizumab, intravitreal ranibizumab with PDT, and intravitreal triamcinolone with PDT for the treatment of retinal angiomatous proliferation: a prospective study. *Retina* 2009;**29**:536–44. <http://dx.doi.org/10.1097/IAE.0b013e318196b1de>
103. Rouvas AA, Papakostas TD, Ntouraki A *et al.* Photodynamic therapy, ranibizumab, and ranibizumab with photodynamic therapy for the treatment of polypoidal choroidal vasculopathy. *Retina* 2011;**31**:464–74. <http://dx.doi.org/10.1097/IAE.0b013e3181f274ec>
104. Sacu S, Michels S, Prager F *et al.* Randomised clinical trial of intravitreal Avastin vs photodynamic therapy and intravitreal triamcinolone: long-term results. *Eye* 2009;**23**:2223–7. <http://dx.doi.org/10.1038/eye.2008.423>
105. Sameen M, Khan MS, Mukhtar A *et al.* Efficacy of intravitreal bevacizumab combined with pan retinal photocoagulation versus panretinal photocoagulation alone in treatment of proliferative diabetic retinopathy. *Pak J Med Sci* 2017;**33**:142–5. <http://dx.doi.org/10.12669/pjms.331.11497>
106. Scott IU, Edwards AR, Beck RW *et al.* A phase II randomized clinical trial of intravitreal bevacizumab for diabetic macular edema. *Ophthalmology* 2007;**114**:1860–7.
107. Seibel I, Vollhardt D, Riechardt AI *et al.* Influence of ranibizumab versus laser photocoagulation on radiation retinopathy (RadiRet) – a prospective randomized controlled trial. *Graefes Arch Clin Exp Ophthalmol* 2020;**258**:869–78.
108. Shah SU, Harless A, Bleau L *et al.* Prospective randomized subject-masked study of intravitreal bevacizumab monotherapy versus dexamethasone implant monotherapy in the treatment of persistent diabetic macular edema. *Retina* 2016;**36**:1986–96. <http://dx.doi.org/10.1097/IAE.0000000000001038>
109. Sivaprasad S, Prevost AT, Vasconcelos JC *et al.* Clinical efficacy of intravitreal aflibercept versus panretinal photocoagulation for best corrected visual acuity in patients with proliferative diabetic retinopathy at 52 weeks (CLARITY): a multicentre, single-blinded, randomised, controlled, phase 2b. *Lancet* 2017;**389**:2193–203. [http://dx.doi.org/10.1016/S0140-6736\(17\)31193-5](http://dx.doi.org/10.1016/S0140-6736(17)31193-5)
110. Soheilian M, Garfami KH, Ramezani A *et al.* Two-year results of a randomized trial of intravitreal bevacizumab alone or combined with triamcinolone versus laser in diabetic macular edema. *Retina* 2012;**32**:314–21. <http://dx.doi.org/10.1097/IAE.0b013e31822f55de>
111. Tadayoni R, Waldstein SM, Boscia F *et al.* Sustained benefits of ranibizumab with or without laser in branch retinal vein occlusion: 24-month results of the BRIGHTER study. *Ophthalmology* 2017;**124**:1778–87. <http://dx.doi.org/10.1016/j.ophtha.2017.06.027>
112. Tan MH, McAllister IL, Gillies ME *et al.* Randomized controlled trial of intravitreal ranibizumab versus standard grid laser for macular edema following branch retinal vein occlusion. *Am J Ophthalmol* 2014;**157**:237–47.e1. <http://dx.doi.org/10.1016/j.ajo.2013.08.013>
113. Tufail A, Patel PJ, Egan C *et al.* Bevacizumab for neovascular age related macular degeneration (ABC trial): multicentre randomised double masked study. *BMJ* 2010;**340**:c2459. <http://dx.doi.org/10.1136/bmj.c2459>
114. Weigert G, Michels S, Sacu S *et al.* Intravitreal bevacizumab (Avastin) therapy versus photodynamic therapy plus intravitreal triamcinolone for neovascular age-related macular degeneration: 6-month results of a prospective, randomised, controlled clinical study. *Br J Ophthalmol* 2008;**92**:356–60. <http://dx.doi.org/10.1136/bjo.2007.125823>
115. Yazdani S, Hendi K, Pakravan M *et al.* Intravitreal bevacizumab for neovascular glaucoma: a randomized controlled trial. *J Glaucoma* 2009;**18**:632–7. <http://dx.doi.org/10.1097/IJG.0b013e3181997211>

Received: 23.8.2022; Editorial decision: 23.10.2022